Cusi K et al: American Association of Clinical Endocrinology clinical practice guideline for the diagnosis and management of nonalcoholic fatty liver disease in primary care and endocrinology clinical settings: Co-sponsored by the American Association for the Study of Liver Diseases (AASLD). Endocr Pract 28:528, 2022.

Diehl AM, Day CSC: Cause, pathogenesis, and treatment of nonalcoholic steatohepatitis. N Engl J Med 377:2063, 2017.

European Association for the Study of the Liver (EASL) et al: EASL-EASD-EASO Clinical Practice Guidelines for the management of non-alcoholic fatty liver disease. J Hepatol 64:1388, 2016.

Harrison SA et al: A phase 3, randomized, controlled trial of resmetirom in NASH with liver fibrosis. N Engl J Med 390:497, 2024.

Kanwal F et al: Clinical care pathway for the risk stratification and management of patients with nonalcoholic fatty liver disease. Gastroenterology 161:1657, 2021.

Rinella ME et al: AASLD practice guidance on the clinical assessment and management of nonalcoholic fatty liver disease. Hepatology 77:1797, 2023.

Vos MB et al: NASPGHAN clinical practice guideline for the diagnosis and treatment of nonalcoholic fatty liver disease in children: Recommendations from the Expert Committee on NAFLD (ECON) and the North American Society of Pediatric Gastroenterology, Hepatology and Nutrition (NASPGHAN). J Pediatr Gastroenterol Nutr 64:319, 2017.

Younossi ZM et al: The global epidemiology of nonalcoholic fatty liver disease (NAFLD) and nonalcoholic steatohepatitis (NASH): A systematic review. Hepatology 77:1335, 2023.

355 Cirrhosis and Its Complications

Alex S. Befeler, Bruce R. Bacon

Cirrhosis is a condition that is defined histopathologically and has a variety of clinical manifestations and complications, some of which can be life-threatening. In the past, it has been thought that cirrhosis was never reversible; however, it has become apparent that when the underlying insult that has caused the cirrhosis has been removed, there can be reversal of fibrosis. This is most apparent with the successful treatment of chronic hepatitis C; however, reversal of fibrosis is also seen in patients with hemochromatosis after iron removal and in patients with alcohol-associated liver disease who have discontinued alcohol use.

Regardless of the cause of cirrhosis, the pathologic features consist of the development of fibrosis to the point that there is architectural distortion with the formation of regenerative nodules. This results in a decrease in hepatocellular mass, and thus function, and an alteration of blood flow. The induction of fibrosis occurs with activation of hepatic stellate cells, resulting in the formation of increased amounts of collagen and other components of the extracellular matrix.

Clinical features of cirrhosis are the result of pathologic changes and mirror the severity of the liver disease. Most hepatic pathologists provide an assessment of grading and staging when evaluating liver biopsy samples. These schemes vary between disease states and have been developed for most conditions, including chronic viral hepatitis, nonalcoholic fatty liver disease, and primary biliary cholangitis. Advanced fibrosis usually includes bridging fibrosis with nodularity designated as stage 3 and cirrhosis designated as stage 4. Patients who have cirrhosis have varying degrees of liver function, and clinicians need to differentiate between those who have stable, compensated cirrhosis and those who have decompensated cirrhosis. Patients who have developed ascites, hepatic encephalopathy, or variceal bleeding are classified as decompensated. They should be considered for liver transplantation, particularly if the decompensations are poorly controlled. Many of the complications of cirrhosis will require specific therapy. *Portal hypertension* is a significant complicating feature of decompensated cirrhosis and is responsible for the development of ascites and bleeding from esophagogastric varices. Loss of hepatocellular function results in jaundice, coagulation disorders, and hypoalbuminemia and contributes to the causes of portosystemic encephalopathy. The complications of cirrhosis are basically the same regardless of the etiology. Nonetheless, it is useful to classify patients by the cause of their liver disease (Table 355-1); patients can be divided into broad groups, including those with alcohol-associated cirrhosis, cirrhosis due to chronic viral hepatitis, biliary cirrhosis, metabolic dysfunction–associated steatotic liver disease (the new consensus term for nonalcoholic fatty liver disease), and other, less common causes, such as cardiac cirrhosis, cryptogenic cirrhosis, and other miscellaneous causes.

TABLE 355-1 Causes of Cirrhosis

Alcohol	Cardiac cirrhosis
Chronic viral hepatitis	Inherited metabolic liver disease
Hepatitis B	Hemochromatosis
Hepatitis C	Wilson's disease
Autoimmune hepatitis	α_1 Antitrypsin deficiency
Metabolic dysfunction-associated steatohepatitis	Cystic fibrosis
Biliary cirrhosis	Cryptogenic cirrhosis
Primary biliary cholangitis	
Primary sclerosing cholangitis	
Autoimmune cholangiopathy	

ALCOHOL-ASSOCIATED CIRRHOSIS

Excessive chronic alcohol use can cause several different types of chronic liver disease, including alcohol-associated fatty liver, alcoholic hepatitis, and alcohol-associated cirrhosis. Furthermore, use of excessive alcohol can contribute to liver damage in patients with other liver diseases, such as hepatitis C, hemochromatosis, and metabolic dysfunction–associated steatotic liver disease. Chronic alcohol use can produce fibrosis in the absence of accompanying inflammation and/or necrosis. Fibrosis can be centrilobular, pericellular, or periportal. When fibrosis reaches a certain degree, there is disruption of the normal liver architecture and replacement of liver cells by regenerative nodules. In alcohol-associated cirrhosis, the nodules are usually <3 mm in diameter; this form of cirrhosis is referred to as *micronodular*. With cessation of alcohol use, larger nodules may form, resulting in a mixed micronodular and macronodular cirrhosis.

Pathogenesis Alcohol is the most commonly used drug in the United States, and >70% of adults drink alcohol each year. Twenty percent have had a binge within the past month, and >7% of adults regularly consume more than four or five drinks five or more times a month. Unfortunately, >14 million adults in the United States meet the diagnostic criteria for alcohol use disorder. In the United States, chronic liver disease is the tenth most common cause of death in adults, and alcohol-associated cirrhosis accounts for ~48% of deaths due to cirrhosis.

Ethanol is mainly absorbed by the small intestine and, to a lesser degree, through the stomach. Gastric alcohol dehydrogenase (ADH) initiates alcohol metabolism. Three enzyme systems account for metabolism of alcohol in the liver. These include cytosolic ADH, the microsomal ethanol oxidizing system (MEOS) utilizing the inducible cytochrome P450 CYP2E1, and peroxisomal catalase. Normally the majority of ethanol oxidation occurs via ADH to form acetaldehyde, which is a highly reactive molecule that may have multiple effects. The MEOS pathway in chronic alcohol use causes induction of CYP2E1, which leads to generation of reactive oxygen species and produces more acetaldehyde. Ultimately, acetaldehyde is metabolized to acetate

by aldehyde dehydrogenase (ALDH). Intake of ethanol increases intracellular accumulation of triglycerides by increasing fatty acid uptake and by reducing fatty acid oxidation and lipoprotein secretion. Protein synthesis, glycosylation, and secretion are impaired. Oxidative damage to hepatocyte membranes occurs due to the formation of reactive oxygen species; acetaldehyde is a highly reactive molecule that combines with proteins and nucleic acids to form acetaldehyde adducts. These adducts may interfere with specific enzyme activities, including microtubular formation and hepatic protein trafficking. With acetaldehyde-mediated hepatocyte damage, certain reactive oxygen species can result in Kupffer cell activation. As a result, profibrogenic cytokines are produced that initiate and perpetuate stellate cell activation, with the resultant production of excess collagen and extracellular matrix. Connective tissue appears in both periportal and pericentral zones and eventually connects portal triads with central veins forming regenerative nodules. Hepatocyte loss occurs, and with increased collagen production and deposition, together with continuing hepatocyte destruction, the liver contracts and shrinks in size. This process generally takes from years to decades to occur and requires repeated insults.

Clinical Features The diagnosis of alcohol-associated liver disease requires an accurate history regarding both amount (>2 drinks per day in women and >3 drinks per day in men) and duration (>12 months) of alcohol consumption. Patients with alcohol-associated liver disease can present with nonspecific symptoms such as vague right upper quadrant abdominal pain, fever, nausea and vomiting, diarrhea, anorexia, and malaise. Alternatively, they may present with complications of chronic liver disease, including ascites, edema, upper gastrointestinal (GI) hemorrhage, jaundice, or encephalopathy. Many cases present incidentally at the time of autopsy or elective surgery. Other patients may be identified during an evaluation of routine laboratory studies that are found to be abnormal. On physical examination, the liver and spleen may be enlarged, with the liver edge being firm and nodular. Other frequent findings include scleral icterus, palmar erythema **(Fig. 355-1)**, spider angiomas **(Fig. 355-2)**, parotid gland enlargement, digital clubbing, muscle wasting, edema, and ascites. Men may have decreased body hair, gynecomastia, and testicular atrophy, which may be a consequence of hormonal abnormalities or a direct toxic effect of alcohol on the testes. In women with advanced disease, menstrual irregularities usually occur including amenorrhea. These changes are often reversible following cessation of alcohol ingestion.

Laboratory tests may be completely normal in patients with early compensated alcohol-associated cirrhosis. Alternatively, in advanced liver disease, many abnormalities usually are present. Patients may be anemic from chronic GI blood loss, nutritional deficiencies, or hypersplenism or as a direct suppressive effect of alcohol on the bone marrow. A unique form of hemolytic anemia (with spur cells and acanthocytes) called *Zieve's syndrome* can occur in patients with severe alcoholic hepatitis. Platelet counts are often reduced early in the disease, reflective of portal hypertension with hypersplenism. Serum total bilirubin can be normal or elevated with advanced disease. Prothrombin times are often prolonged and usually do not respond to administration of parenteral vitamin K. Serum sodium levels are usually normal unless patients have ascites and then can be depressed, largely due to ingestion of excess free water. Serum alanine and aspartate aminotransferases (ALT, AST) are typically elevated but <400 IU/mL, with AST levels being higher than ALT levels, usually by a 2:1 ratio, particularly in patients who continue to drink.

FIGURE 355-1 Palmar erythema. This figure shows palmar erythema in a patient with alcohol-associated cirrhosis. The erythema is peripheral over the palm with central pallor.

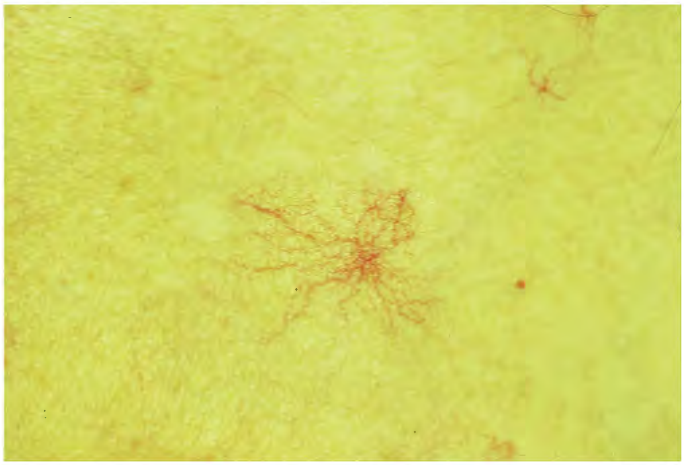

FIGURE 355-2 Spider angioma. This figure shows a spider angioma in a patient with hepatitis C cirrhosis. With release of central compression, the arteriole fills from the center and spreads out peripherally.

Diagnosis Patients who have any of the above-mentioned clinical features, physical examination findings, or laboratory studies in the setting of chronic alcohol consumption should be considered to have alcohol-associated liver disease. Furthermore, other forms of chronic liver disease (e.g., chronic viral hepatitis or metabolic or autoimmune liver diseases) must be considered or ruled out, or if present, an estimate of relative causality along with the alcohol use should be determined. Liver biopsy can be helpful to confirm a diagnosis but generally is not performed unless there is a suspicion of an alternative diagnosis.

In patients who have had complications of cirrhosis and who continue to drink, there is a <50% 5-year survival. In contrast, in patients who remain abstinent, the prognosis is significantly improved, particularly when they have resolution of liver complications; however, some individuals who remain abstinent do not improve and liver transplantation is a viable option.

TREATMENT

Alcohol-Associated Cirrhosis and Alcoholic Hepatitis

Abstinence is the cornerstone of therapy for patients with alcohol-associated liver disease. New clinically available biomarkers of recent alcohol consumption such as phosphatidylethanol (Peth) can be helpful in evaluating abstinence. In addition, patients require good nutrition and long-term medical supervision to manage underlying complications that may develop. Complications such as the development of ascites and edema, variceal hemorrhage, or portosystemic encephalopathy all require specific management and treatment. Liver transplantation can be an effective long-term treatment in those who have been deemed a low enough risk for alcohol relapse and do not respond to other treatments.

Glucocorticoids are occasionally used in patients with severe alcoholic hepatitis in the absence of infection. Short-term survival has been shown to be improved in certain studies and meta-analysis, although 6-month survival is more dependent on abstinence. Treatment is restricted to patients with a discriminant function (DF) value of >32. The DF is calculated as the serum total bilirubin plus the difference in the patient's prothrombin time

compared to upper limit of control (in seconds) multiplied by 4.6. Failure to improve total bilirubin after 7 days predicts treatment failure, and glucocorticoids can be stopped; otherwise, they are continued for 28 days.

There is modest evidence that intravenous *N*-acetylcysteine plus glucocorticoids may have a short-term survival benefit in alcoholic hepatitis if the DF is >32. Other therapies including oral pentoxifylline, inhibitors of tumor necrosis factor (TNF) α, anabolic steroids, propylthiouracil, antioxidants, colchicine, and penicillamine have not shown clear-cut benefits and are not recommended. A variety of nutritional therapies have been tried, both parenteral and enteral feedings; however, there is no clear evidence of improved survival. There is evidence that persons who consume >21.5 kcal/kg body weight per day have better survival, so achieving better caloric intake is recommended. Finally, in highly selected patients with good social support structure who fail other treatments for alcoholic hepatitis, early liver transplant can be an effective treatment.

Cessation of alcohol use is key. Recent experience with medications that reduce craving for alcohol, such as acamprosate calcium and baclofen, have been favorable. Patients may take other necessary medications even in the presence of cirrhosis. Acetaminophen use is often discouraged in patients with liver disease; however, if no more than 2 g of acetaminophen per day are consumed, there generally are no problems unless there is active alcohol use.

CIRRHOSIS DUE TO CHRONIC VIRAL HEPATITIS B OR C

Of patients exposed to the hepatitis C virus (HCV), ~80% develop chronic hepatitis C, and of those, ~20–30% will develop cirrhosis over 20–30 years. Many of these patients have had concomitant alcohol use, and the true incidence of cirrhosis due to hepatitis C alone is unknown. It is expected that an even higher percentage will go on to develop cirrhosis over longer periods of time. In the United States, ~5–6 million people have been exposed to HCV, and ~4–5 million are chronically viremic. Worldwide, ~170 million individuals have hepatitis C, with some areas of the world (e.g., Egypt) having up to 15% of the population infected. HCV is a noncytopathic virus, and liver damage is probably immune-mediated. Progression of liver disease due to chronic hepatitis C is characterized by portal-based fibrosis with bridging fibrosis and nodularity developing, ultimately culminating in the development of cirrhosis. In cirrhosis due to chronic hepatitis C, the liver is small and shrunken with characteristic features of a mixed micro- and macronodular cirrhosis seen on liver biopsy. In addition, an inflammatory infiltrate is found in portal areas with interface hepatitis and occasionally some lobular hepatocellular injury and inflammation. In patients with HCV genotype 3, steatosis is often present.

Similar findings are seen in patients with cirrhosis due to chronic hepatitis B. Of adult patients exposed to hepatitis B, ~5% develop chronic hepatitis B, and ~20% of those patients will go on to develop cirrhosis. Special stains for hepatitis B core (HBc) and hepatitis B surface (HBs) antigen will be positive, and ground-glass hepatocytes signify HBs antigen (HBsAg) may be present. In the United States, there are ~2 million carriers of hepatitis B, whereas in other parts of the world where hepatitis B virus (HBV) is endemic (i.e., Asia, Southeast Asia, sub-Saharan Africa), up to 15% of the population may be infected, having acquired the infection vertically at the time of birth. Thus, >300–400 million individuals are thought to have hepatitis B worldwide. Approximately 25% of these individuals may ultimately develop cirrhosis.

Clinical Features and Diagnosis Patients with cirrhosis due to either chronic hepatitis C or B can present with the usual symptoms and signs of chronic liver disease. Fatigue, malaise, vague right upper quadrant pain, and laboratory abnormalities are frequent presenting features. Diagnosis requires a thorough laboratory evaluation, including quantitative HCV RNA testing and analysis for HCV genotype, or hepatitis B serologies to include HBsAg, HBeAg (hepatitis B e antigen), anti-HBe, and quantitative HBV DNA levels.

TREATMENT

Cirrhosis due to Chronic Viral Hepatitis B or C

Management of complications of cirrhosis revolves around specific therapy for treatment of whatever complications occur (e.g., esophageal variceal hemorrhage, development of ascites and edema, or encephalopathy). In patients with chronic hepatitis B, numerous studies have shown beneficial effects of antiviral therapy, which is effective at viral suppression, as evidenced by reducing aminotransferase levels and HBV DNA levels and improving histology by reducing inflammation and fibrosis. Several clinical trials and case series have demonstrated that patients with decompensated liver disease can become compensated with the use of antiviral therapy directed against hepatitis B. Currently available therapy includes lamivudine, adefovir, telbivudine, entecavir, and tenofovir, with the latter two strongly preferred because of reduced risk of viral resistance. Interferon α can also be used for treating hepatitis B, but it should not be used in cirrhotics **(see Chap. 352)**.

Treatment of patients with cirrhosis due to hepatitis C with direct-acting antiviral protocols is highly successful (>95% cure rate), well tolerated, and usually of short duration (8–12 weeks) **(see Chap. 352)**.

CIRRHOSIS FROM AUTOIMMUNE HEPATITIS AND METABOLIC DYSFUNCTION–ASSOCIATED STEATOTIC LIVER DISEASE

Other causes of posthepatitic cirrhosis include autoimmune hepatitis (AIH) and metabolic dysfunction–associated steatohepatitis (MASH), which was previously called nonalcoholic steatohepatitis. Many patients with AIH present with cirrhosis that is already established. Typically, these patients will not benefit from immunosuppressive therapy with glucocorticoids or azathioprine because the AIH is "burned out." In this situation, liver biopsy does not show a significant inflammatory infiltrate. Diagnosis in this setting requires positive autoimmune markers such as antinuclear antibody (ANA) or anti-smooth-muscle antibody (ASMA). When patients with AIH present with cirrhosis and active inflammation accompanied by elevated liver enzymes, there can be considerable benefit from the use of immunosuppressive therapy.

Patients with MASH are increasingly being found to have progressed to cirrhosis. With the epidemic of obesity that continues in Western countries, more and more patients are identified with metabolic dysfunction–associated steatotic liver disease **(Chap. 354)**. Of these, a significant subset has MASH and can progress to increased fibrosis and cirrhosis. Over the past several years, it has been increasingly recognized that many patients who were thought to have cryptogenic cirrhosis in fact have MASH. As their cirrhosis progresses, they become catabolic and then lose the telltale signs of steatosis seen on biopsy. Management of complications of cirrhosis due to either AIH or MASH is similar to that for other forms of cirrhosis.

BILIARY CIRRHOSIS

Biliary cirrhosis has pathologic features that are different from either alcohol-associated cirrhosis or posthepatitic cirrhosis, yet the manifestations of end-stage liver disease are the same. Cholestatic liver disease may result from necroinflammatory lesions, congenital or metabolic processes, or external bile duct compression. Thus, two broad categories reflect the anatomic sites of abnormal bile retention: *intrahepatic* and *extrahepatic*. The distinction is important for obvious therapeutic reasons. Extrahepatic obstruction may benefit from surgical or endoscopic biliary tract decompression, whereas intrahepatic cholestatic processes will not improve with such interventions and require a different approach.

The major causes of chronic cholestatic syndromes are primary biliary cholangitis (PBC), autoimmune cholangitis (AIC), primary sclerosing cholangitis (PSC), and idiopathic adulthood ductopenia. These syndromes are usually clinically distinguished from each other

by antibody testing, cholangiographic findings, and clinical presentation. However, they all share the histopathologic features of chronic cholestasis, including cholate stasis; copper deposition; xanthomatous transformation of hepatocytes; and irregular, so-called biliary fibrosis. In addition, there may be chronic portal inflammation, interface activity, and chronic lobular inflammation. Ductopenia is a result of progressive disease as patients develop cirrhosis.

PRIMARY BILIARY CHOLANGITIS

PBC is seen in about 100–200 individuals per million, with a strong female preponderance and a median age of ~50 years at the time of diagnosis. The cause of PBC is unknown; it is characterized by portal inflammation and necrosis of cholangiocytes in small- and medium-sized bile ducts. Cholestatic features prevail, and biliary cirrhosis is characterized by an elevated bilirubin level and progressive liver failure. Liver transplantation is the treatment of choice for patients with decompensated cirrhosis due to PBC.

Antimitochondrial antibodies (AMAs) are present in ~95% of patients with PBC. These autoantibodies recognize lipoic acid on the inner mitochondrial membrane proteins that are enzymes of the pyruvate dehydrogenase complex (PDC), the branched-chain 2-oxoacid dehydrogenase complex, and the 2-oxogluterate dehydrogenase complex. These autoantibodies are not pathogenic, but rather are useful markers for making a diagnosis.

Pathology Histopathologic analysis identifies four distinct stages of the disease as it progresses. The earliest lesion is termed *chronic nonsuppurative destructive cholangitis* and is a necrotizing inflammatory process of the portal tracts. Medium and small bile ducts are infiltrated with lymphocytes and undergo duct destruction. Mild fibrosis and sometimes bile stasis can occur. With progression, the inflammatory infiltrate becomes less prominent, but the number of bile ducts is reduced and there is proliferation of smaller bile ductules. Increased fibrosis ensues with the expansion of periportal fibrosis to bridging fibrosis. Finally, cirrhosis, which may be micronodular or macronodular, develops.

Clinical Features Currently, most patients with PBC are middle-aged women diagnosed well before the end-stage manifestations of the disease are present, and as such, most patients are asymptomatic. When symptoms are present, they most prominently include a significant degree of fatigue out of proportion to either the severity of the liver disease or the age of the patient. Pruritus is seen in ~50% of patients at the time of diagnosis, and it can be debilitating. It might be intermittent and usually is most bothersome in the evening. In some patients, pruritus can develop toward the end of pregnancy and can be mistaken for cholestasis of pregnancy. Pruritus that presents prior to the development of jaundice indicates severe disease and a poor prognosis.

Physical examination can show jaundice and other complications of chronic liver disease including hepatomegaly, splenomegaly, ascites, and edema. Other features that are unique to PBC include hyperpigmentation, xanthelasma, and xanthomata, which are related to altered cholesterol metabolism. Hyperpigmentation is evident on the trunk and the arms and is seen in areas of exfoliation and lichenification associated with progressive scratching related to the pruritus. Bone pain resulting from osteopenia or osteoporosis is occasionally seen at diagnosis.

Laboratory Findings Laboratory findings in PBC show cholestatic liver enzyme abnormalities with an elevation in γ-glutamyl transpeptidase and alkaline phosphatase (ALP) along with mild elevations in aminotransferases (ALT and AST). Immunoglobulins, particularly IgM, are typically increased. Hyperbilirubinemia usually is seen once cirrhosis has developed. Thrombocytopenia, leukopenia, and anemia may be seen in patients with portal hypertension and hypersplenism. Liver biopsy shows characteristic features as described above and should be evident to any experienced hepatopathologist. Up to 10% of patients with characteristic PBC will have features of AIH (moderate to severe interphase hepatitis on biopsy, elevated ALT >5× the upper limit of normal, and elevated IgG levels) as well and are defined as having "overlap" syndrome. These patients are usually treated as PBC patients and progress to cirrhosis with the same frequency as typical PBC patients. Some patients require immunosuppressive medications as well.

Diagnosis PBC should be considered in patients with chronic cholestatic liver enzyme abnormalities. AMA testing may be negative in as many as 5–10% of patients with PBC. These patients usually are positive for other PBC-specific autoantibodies including sp100 or gp210, although these tests are not universally available. Liver biopsy is most important in this setting of AMA-negative PBC. In patients who are AMA negative with cholestatic liver enzymes, PSC should be ruled out by way of cholangiography.

TREATMENT

Primary Biliary Cholangitis

Treatment of the typical manifestations of cirrhosis is no different for PBC than for other forms of cirrhosis. Ursodeoxycholic acid (UDCA) has been shown to improve both biochemical and histologic features of the disease, thus slowing but not reversing or curing the disease. Improvement is greatest when therapy is initiated early; the likelihood of significant improvement with UDCA is low in patients with PBC who present with manifestations of cirrhosis. UDCA is given in doses of 13–15 mg/kg per d; the medication is usually well tolerated, although some patients have worsening pruritus with initiation of therapy. A small proportion of patients may have diarrhea or headache as a side effect of the drug. About 30–40% of patients with PBC do not have a satisfactory response to UDCA; more than half of these patients will have significant improvement with obeticholic acid, elafibranor or seladelpar though these medication should be avoided in the setting of cirrhosis with portal hypertension or decompensation. Patients with PBC require long-term follow-up by a physician experienced with the disease. Certain patients may need to be considered for liver transplantation should their liver disease decompensate.

The main symptoms of PBC are fatigue and pruritus. Several therapies have been tried for treatment of fatigue, but none of them has been successful; frequent naps should be encouraged. Pruritus is treated with antihistamines, narcotic receptor antagonists (naltrexone), selective serotonin reuptake inhibitors, and rifampin. Cholestyramine, a bile salt–sequestering agent, has been helpful in some patients but is somewhat tedious and difficult to take. Plasmapheresis has been used rarely in patients with severe intractable pruritus. There is an increased incidence of osteopenia and osteoporosis in patients with cholestatic liver disease, and bone density testing should be performed. Oral calcium and vitamin D are also recommended. Treatment with a bisphosphonate should be instituted when bone disease is identified. Screening for fat-soluble vitamin deficiency (A, D, E, K) should done if total bilirubin is >2 mg/dL.

PRIMARY SCLEROSING CHOLANGITIS

As in PBC, the cause of PSC remains unknown. PSC is a chronic cholestatic syndrome that is characterized by diffuse inflammation and fibrosis involving the entire biliary tree, resulting in chronic cholestasis. This pathologic process ultimately results in obliteration of both the intra- and extrahepatic biliary tree, leading to biliary cirrhosis, portal hypertension, and liver failure. The cause of PSC remains unknown despite extensive investigation into various mechanisms related to bacterial and viral infections, toxins, genetic predisposition, and immunologic mechanisms, all of which have been postulated to contribute to the pathogenesis and progression of this syndrome.

Liver biopsy changes in PSC are not pathognomonic, and establishing the diagnosis of PSC must involve imaging of the biliary tree. Pathologic changes occurring in PSC show bile duct proliferation as well as ductopenia and fibrous cholangitis (pericholangitis). Periductal fibrosis is occasionally seen on biopsy specimens and can be quite

helpful in making the diagnosis. As the disease progresses, biliary cirrhosis is the end-stage manifestation of PSC.

Clinical Features The usual clinical features of PSC are those found in cholestatic liver disease, with fatigue, pruritus, steatorrhea, deficiencies of fat-soluble vitamins, and the associated consequences. As in PBC, the fatigue is profound and nonspecific. Pruritus can often be debilitating and is related to the cholestasis. The severity of pruritus does not correlate with the severity of the disease. Metabolic bone disease, as seen in PBC, can occur with PSC and should be treated (see above).

Laboratory Findings Patients with PSC typically are identified during an evaluation of abnormal liver enzymes. Most patients have at least a twofold increase in ALP and may have elevated aminotransferases as well. Albumin levels may be decreased, and prothrombin times can be prolonged at the time of diagnosis. Some degree of correction of a prolonged prothrombin time may occur with parenteral vitamin K. A small subset of patients has aminotransferase elevations >5× the upper limit of normal and may have features of AIH on biopsy indicating an overlap syndrome between PSC and AIH. Autoantibodies are frequently positive in patients with the overlap syndrome but are typically negative in patients who only have PSC. One autoantibody, the perinuclear antineutrophil cytoplasmic antibody (pANCA), is positive in ~65% of patients with PSC. Sixty to eighty percent of patients with PSC have inflammatory bowel disease, predominately ulcerative colitis (UC); thus, a colonoscopy is recommended at diagnosis.

Diagnosis The definitive diagnosis of PSC requires cholangiographic imaging. Magnetic resonance imaging (MRI) with magnetic resonance cholangiopancreatography (MRCP) is the imaging technique of choice for initial evaluation. Endoscopic retrograde cholangiopancreatography (ERCP) can be considered if the MRCP provided suboptimal images or if there is newly elevated total bilirubin or MRCP evidence of a dominant stricture. Typical cholangiographic findings in PSC are multifocal stricturing and beading involving both the intrahepatic and extrahepatic biliary tree. These strictures are typically short and with intervening segments of normal or slightly dilated bile ducts that are distributed diffusely, producing the classic beaded appearance. The gallbladder and cystic duct can be involved in up to 15% of cases. Gradually, biliary cirrhosis develops, and patients will progress to decompensated liver disease with manifestations of ascites, esophageal variceal hemorrhage, and encephalopathy.

TREATMENT

Primary Sclerosing Cholangitis

There is no specific proven treatment for PSC. Some clinicians use UDCA at "PBC dosages" of 13–15 mg/kg per d with anecdotal improvement, although no study has shown convincing evidence of clinical benefit. A study of high-dose (28–30 mg/kg per d) UDCA found it to be harmful. Endoscopic dilatation of dominant strictures can be helpful, but the ultimate treatment is liver transplantation when decompensated cirrhosis develops. Episodes of cholangitis should be treated with antibiotics and can be an indication for liver transplantation. A dreaded complication of PSC is the development of cholangiocarcinoma, which is a relative contraindication to liver transplantation.

CARDIAC CIRRHOSIS

Definition Patients with long-standing right-sided congestive heart failure may develop chronic liver injury from congestive hepatopathy sometimes resulting in cardiac cirrhosis. This is an increasingly uncommon, if not rare, cause of chronic liver disease given the advances made in the care of patients with heart failure, particularly valvular heart disease, but there has been an increase in patients with congenital heart disease particularly after the Fontan operation.

Etiology and Pathology In the case of long-term right-sided heart failure, there is an elevated venous pressure transmitted via the inferior vena cava and hepatic veins to the sinusoids of the liver, which become dilated and engorged with blood. The liver becomes enlarged and swollen, and with long-term passive congestion and relative ischemia due to poor circulation, centrilobular hepatocytes can become necrotic, leading to pericentral fibrosis. This fibrotic pattern can extend to the periphery of the lobule outward until a unique pattern of fibrosis causing cirrhosis can occur.

Clinical Features Patients typically have signs of congestive heart failure and will manifest an enlarged firm liver on physical examination. ALP levels are characteristically elevated, and aminotransferases may be normal or slightly increased, with AST usually higher than ALT. It is unlikely that patients will develop variceal hemorrhage or encephalopathy.

Diagnosis The diagnosis is usually made in someone with clear-cut cardiac disease who has an elevated ALP and an enlarged liver. Liver biopsy shows a pattern of fibrosis that can be recognized by an experienced hepatopathologist. Differentiation from Budd-Chiari syndrome (BCS) can be made by seeing extravasation of red blood cells in BCS, but not in cardiac hepatopathy. Venoocclusive disease, now termed sinusoidal obstructive syndrome (SOS), can also affect hepatic outflow and has characteristic features on liver biopsy. SOS can be seen under the circumstances of conditioning for bone marrow transplant with radiation and chemotherapy; it can also be seen with the ingestion of certain herbal teas as well as pyrrolizidine alkaloids. This is typically seen in Caribbean countries and rarely in the United States. Treatment is based on management of the underlying cardiac disease.

OTHER TYPES OF CIRRHOSIS

There are several other less common causes of chronic liver disease that can progress to cirrhosis. These include inherited metabolic liver diseases such as hemochromatosis, Wilson's disease, α_1 antitrypsin (α_1AT) deficiency, and cystic fibrosis. For these disorders, the manifestations of cirrhosis are similar, with some minor variations, to those seen in other patients with other causes of cirrhosis.

Hemochromatosis is an inherited disorder of iron metabolism that results in a progressive increase in hepatic iron deposition, which, over time, can lead to a portal-based fibrosis progressing to cirrhosis, liver failure, and hepatocellular cancer. While the frequency of hemochromatosis is relatively common, with genetic susceptibility occurring in 1 in 250 individuals, the frequency of end-stage manifestations due to the disease is relatively low, and <5% of those patients who are genotypically susceptible will go on to develop severe liver disease from hemochromatosis. Diagnosis is made with serum iron studies showing an elevated transferrin saturation and an elevated ferritin level, along with abnormalities identified by *HFE* mutation analysis. Treatment is straightforward, with regular therapeutic phlebotomy.

Wilson's disease is an inherited disorder of copper homeostasis with failure to excrete excess amounts of copper, leading to an accumulation in the liver. This disorder is relatively uncommon, affecting 1 in 30,000 individuals. Wilson's disease typically affects adolescents and young adults. Prompt diagnosis before end-stage manifestations become irreversible can lead to significant clinical improvement. Diagnosis requires determination of ceruloplasmin levels, which are low; 24-h urine copper levels, which are elevated; typical physical examination findings, including Kayser-Fleischer corneal rings; and characteristic liver biopsy findings. Treatment consists of copper-chelating medications.

α_1AT deficiency results from an inherited disorder that causes abnormal folding of the α_1AT protein, resulting in failure of secretion of that protein from the liver. It is unknown how the retained protein leads to liver disease. Patients with α_1AT deficiency at greatest risk for developing chronic liver disease have the ZZ phenotype, but only ~10–20% of such individuals will develop chronic liver disease. Diagnosis is made by determining α_1AT levels and phenotype. Characteristic periodic acid–Schiff (PAS)–positive, diastase-resistant globules are seen on liver biopsy. The only effective treatment is liver transplantation, which is curative.

TABLE 355-2 Complications of Cirrhosis

Portal hypertension	Coagulopathy
Gastroesophageal varices	Factor deficiency
Portal hypertensive gastropathy	Fibrinolysis
Splenomegaly, hypersplenism	Thrombocytopenia
Ascites	Bone disease
Spontaneous bacterial peritonitis	Osteopenia
Acute kidney injury-hepatorenal syndrome	Osteoporosis
Chronic kidney disease-hepatorenal syndrome	Osteomalacia
	Hematologic abnormalities
Hepatic encephalopathy	Anemia
Hepatopulmonary syndrome	Hemolysis
Portopulmonary hypertension	Thrombocytopenia
Malnutrition	Neutropenia

Cystic fibrosis is an uncommon inherited disorder affecting whites of northern European descent. A biliary-type cirrhosis can occur, and some patients derive benefit from the chronic use of UDCA.

MAJOR COMPLICATIONS OF CIRRHOSIS

These include gastroesophageal variceal hemorrhage, splenomegaly, ascites, hepatic encephalopathy, spontaneous bacterial peritonitis (SBP), hepatorenal syndrome (HRS), and hepatocellular carcinoma (Table 355-2). There are also more rare complications in the pulmonary system including hepatopulmonary syndrome and portopulmonary hypertension.

PORTAL HYPERTENSION

Portal hypertension is defined as the elevation of the hepatic venous pressure gradient (HVPG) to >5 mmHg. The portal venous system normally drains blood from most of the GI tract including the stomach, small and large intestines, spleen, pancreas, and gallbladder. Portal hypertension is caused by a combination of two simultaneously occurring hemodynamic processes: (1) increased intrahepatic resistance to the passage of blood flow through the liver due to cirrhosis, regenerative nodules, and microthrombi, and (2) increased splanchnic blood flow secondary to vasodilation within the splanchnic vascular bed. In more advanced stages, there is also activation of neurohumoral responses and vasoconstrictive systems resulting in sodium and water retention, increased blood volume, and hyperdynamic circulatory system producing more portal hypertension. There is usually an initial stage of compensated cirrhosis with HVPG between 5 and 10 mmHg that can be asymptomatic and last for ≥10 years, but when clinically significant portal hypertension (CSPH) develops (defined as a HVPG ≥10 mmHg), there is substantial risk of decompensation with variceal bleeding, ascites, or hepatic encephalopathy. With decompensation, median mortality is <2 years.

The causes of portal hypertension are usually subcategorized as prehepatic, intrahepatic, and posthepatic (Table 355-3). Prehepatic causes of portal hypertension are those affecting the portal venous system before it enters the liver; they include portal vein thrombosis and splenic vein thrombosis. Posthepatic causes encompass those affecting the hepatic veins and venous drainage to the heart; they include BCS and chronic right-sided cardiac congestion. Intrahepatic causes account for >95% of cases of portal hypertension and are represented by the major forms of cirrhosis. Intrahepatic causes of portal hypertension can be further subdivided into presinusoidal, sinusoidal, and postsinusoidal causes. Postsinusoidal causes include venoocclusive disease, whereas presinusoidal causes include congenital hepatic fibrosis and schistosomiasis. Sinusoidal causes are related to cirrhosis from various causes.

Cirrhosis is overwhelmingly the most common cause of portal hypertension in the United States. Portal vein thrombosis may contribute to portal hypertension and is most often associated with cirrhosis but may be idiopathic or can occur in association with infection, pancreatitis, or abdominal trauma. Coagulation disorders that can lead to the development of portal vein thrombosis include polycythemia vera; essential thrombocytosis; deficiencies in protein C, protein S, antithrombin III, and factor V Leiden; and abnormalities in the gene-regulating prothrombin production. Some patients may have a subclinical myeloproliferative disorder.

TABLE 355-3 Classification of Portal Hypertension

Prehepatic
Portal vein thrombosis
Splenic vein thrombosis
Massive splenomegaly (Banti's syndrome)
Hepatic
Presinusoidal
Schistosomiasis
Congenital hepatic fibrosis
Sinusoidal
Cirrhosis—many causes
Alcoholic hepatitis
Postsinusoidal
Hepatic sinusoidal obstruction (venoocclusive syndrome)
Posthepatic
Budd-Chiari syndrome
Inferior vena caval webs
Cardiac causes
Restrictive cardiomyopathy
Constrictive pericarditis
Severe congestive heart failure

Clinical Features The three primary complications of portal hypertension are gastroesophageal varices with hemorrhage, ascites, and hypersplenism. Thus, patients may present with upper GI bleeding, which, on endoscopy, is found to be due to esophageal or gastric varices; with the development of ascites along with peripheral edema; or with an enlarged spleen with associated reduction in platelets and white blood cells on routine laboratory testing.

ESOPHAGEAL VARICES *Variceal hemorrhage* is an immediate life-threatening problem with a 20–30% mortality rate associated with each episode of bleeding. Over the past decade, it has become common practice to screen known cirrhotics with endoscopy to look for esophageal varices. Such screening studies have shown that approximately one-third of patients with histologically confirmed cirrhosis have varices. Approximately 5–15% of cirrhotics per year develop varices, and it is estimated that the majority of patients with cirrhosis will develop varices over their lifetimes. Furthermore, it is anticipated that roughly one-third of patients with varices will develop bleeding. Several factors predict the risk of bleeding, including the severity of cirrhosis (Child-Pugh class, Model for End-Stage Liver Disease [MELD] score); the height of wedged-hepatic vein pressure; the size of the varix; the location of the varix; and certain endoscopic stigmata, including red wale signs, hematocystic spots, diffuse erythema, bluish color, cherry red spots, or white-nipple spots. Patients with tense ascites are also at increased risk for bleeding from varices.

Diagnosis In patients with cirrhosis who are being followed chronically, the development of portal hypertension is usually revealed by the presence of thrombocytopenia; the appearance of an enlarged spleen; or the development of ascites, encephalopathy, and/or esophageal varices with or without bleeding. In previously undiagnosed patients, any of these features should prompt further evaluation to determine the presence of portal hypertension and liver disease. Varices should be identified by endoscopy. Contrasted-enhanced abdominal imaging, either by computed tomography (CT) or MRI, can be helpful in demonstrating a nodular liver and in finding changes of portal hypertension with intraabdominal collateral circulation. Rarely, the HVPG is

 measured by interventional radiology. Patients with a gradient >12 mmHg are at risk for variceal hemorrhage.

TREATMENT

Variceal Hemorrhage

Treatment for esophageal varices as a complication of portal hypertension is divided into two main categories: (1) primary prophylaxis and (2) prevention of rebleeding once there has been an initial variceal hemorrhage. Primary prophylaxis requires routine surveillance by endoscopy. Upper endoscopies are recommended at diagnosis of compensated cirrhosis and then every 2 years if the liver disease is active or every 3 years if inactive (alcohol cessation, viral hepatitis eradication). In the absence of thrombocytopenia and with a liver stiffness by transient elastography <20 kPa, high-risk varices are rare and thus screening is not needed. Endoscopy is also recommended at the time of hepatic decompensation. Once varices that are at increased risk for bleeding are identified, usually defined as medium or large varices or small varices with high-risk stigmata or in decompensated cirrhosis, primary prophylaxis can be achieved either through traditional nonselective beta blockade (NSBB) (propranolol or nadolol) titrated with a goal heart rate of 55–60 beats/min with systolic blood pressure >90 mmHg or by variceal band ligation. Carvedilol is becoming the NSBB of choice. Given its additional anti-α_1-adrenergic vasodilating properties, it more effectively lowers portal pressure, lacks the need for heart rate goals, and has emerging data that suggest it can prevent hepatic decompensation and improve survival in persons with CSPH.

Endoscopic variceal ligation (EVL) has been compared to traditional NSBB and carvedilol for primary prophylaxis against variceal bleeding, and EVL appears to have equivalent efficacy at preventing bleeding. NSBBs, especially carvedilol, are generally recommended as first-line treatment for primary prophylaxis of bleeding if tolerated, given their additional benefits. Once primary prophylaxis has been initiated, repeat endoscopy for surveillance of varices is unnecessary.

The approach to patients once they have had a variceal bleed is first to treat the acute bleed, which can be life-threatening, and then to prevent further bleeding. Treatment of acute bleeding requires both fluid and red blood cell replacement to stabilize hemodynamics. A randomized trial of restricted transfusion starting when hemoglobin is <7 g/dL with a goal hemoglobin of 7–9 g/dL, compared to a more liberal strategy, resulted in reduced early rebleeding and mortality. This strategy is recommended, although adjustments should be made based on cardiac risks and hemodynamics. Correcting an elevated prothrombin time with fresh frozen plasma is not recommended unless there is evidence of coagulopathy (bleeding at other sites such as IV lines). The use of vasoconstricting agents, usually somatostatin or octreotide, has been shown to improve initial bleeding control and reduce transfusion requirements and all-cause mortality. Prophylactic antibiotics, usually with ceftriaxone, started prior to endoscopy result in reduced infections, recurrent bleeding, and mortality. Balloon tamponade (Sengstaken-Blakemore tube or Minnesota tube) or placement of self-expandable metal stents can be used in patients who need stabilization prior to endoscopic therapy or as a bridge to transjugular intrahepatic portosystemic shunt (TIPS) after endoscopic failure. Control of bleeding can be achieved in the vast majority of cases; however, bleeding recurs in the majority of patients if definitive endoscopic therapy has not been instituted. Upper endoscopy is used as first-line treatment to diagnose the cause of the bleeding and to control bleeding acutely with EVL. When esophageal varices extend into the proximal stomach or the bleeding varices are entirely within the stomach, band ligation is often unsuccessful. In these situations, consideration for a TIPS should be made. This technique creates a portosystemic shunt by a percutaneous approach using an expandable metal stent, which is advanced under angiographic guidance to the hepatic veins and then through the substance of the liver to create a direct portocaval shunt. Encephalopathy can occur in as many as 20% of patients after TIPS and is particularly problematic in elderly patients and in patients with preexisting encephalopathy. TIPS is usually reserved for individuals who fail or are unable to receive endoscopic therapy, although there is emerging evidence that patients who are highly selected to be at high risk for rebleeding may also benefit. TIPS can sometimes be used as a bridge to transplantation, and all patients requiring TIPS should be considered for transplant evaluation. Some gastric varices are associated with a splenorenal shunt and can be effectively treated with a balloon-occluded retrograde transvenous obliteration (BRTO) of varices sometimes in combination with a TIPS. Prevention of further bleeding is usually accomplished with repeated variceal band ligation until varices are obliterated in combination with NSBB. If recurrent variceal bleeding occurs, then TIPS should be performed for long-term prevention of bleeding. Once a TIPS has been performed, there is no need for further endoscopies for variceal surveillance; however, the TIPS should be periodically monitored with Doppler ultrasound for stenosis **(Fig. 355-3)**.

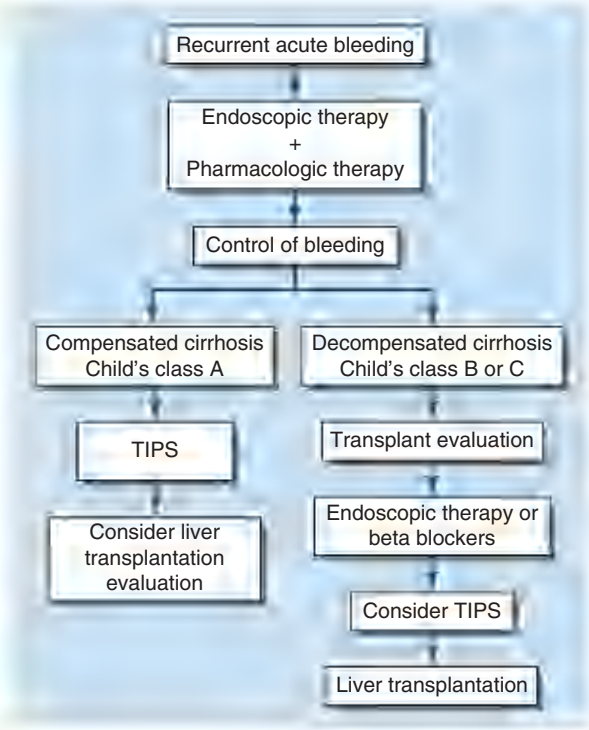

FIGURE 355-3 Management of recurrent variceal hemorrhage. This algorithm describes an approach to management of patients who have recurrent bleeding from esophageal varices. Initial therapy is generally with endoscopic therapy often supplemented by pharmacologic therapy. With control of bleeding, a decision needs to be made as to whether patients should go on to transjugular intrahepatic portosystemic shunt (TIPS; if they are Child's class A) or if they should have TIPS and be considered for transplant (if they are Child's class B or C).

PORTAL HYPERTENSIVE GASTROPATHY

Portal hypertensive gastropathy can cause both acute clinical GI bleeding and chronic bleeding resulting in iron-deficiency anemia. It is associated with all causes of portal hypertension and is diagnosed by characteristic endoscopy findings showing a snakeskin-like mosaic pattern of gastric mucosa often with central red or brown spots. When there is bleeding, treatment is with NSBB and iron repletion. Refractory bleeding may respond to TIPS.

SPLENOMEGALY AND HYPERSPLENISM

Congestive splenomegaly with hypersplenism is common in patients with portal hypertension and is usually the first indication of portal hypertension. Clinical features include the presence of an enlarged spleen on physical examination and the development of thrombocytopenia and leukopenia in patients who have cirrhosis. Some patients will have significant left-sided and left upper quadrant abdominal pain

related to an enlarged spleen. Splenomegaly itself usually requires no specific treatment.

ASCITES

Definition Ascites is the accumulation of fluid within the peritoneal cavity. Overwhelmingly, the most common cause of ascites is portal hypertension related to cirrhosis; however, clinicians should remember that malignant, infectious, and cardiac causes of ascites can be present as well, and careful differentiation of these other causes is obviously important for patient care.

Pathogenesis The presence of portal hypertension contributes to the development of ascites in patients who have cirrhosis (Fig. 355-4). There is an increase in intrahepatic resistance, causing increased portal pressure, but there is also vasodilation of the splanchnic arterial system, which, in turn, results in an increase in portal venous inflow. Both abnormalities result in increased production of splanchnic lymph. Vasodilating factors such as nitric oxide are responsible for the vasodilatory effect. There is activation of the renin-angiotensin-aldosterone system with the development of hyperaldosteronism and activation of the sympathetic nervous system as a consequence of a homeostatic response caused by underfilling of the arterial circulation secondary to arterial vasodilation in the splanchnic vascular bed. The renal effects of increased aldosterone and activation of the sympathetic nervous system lead to sodium retention causing fluid accumulation and expansion of the extracellular fluid volume, resulting in peripheral edema and ascites. Because the retained fluid is constantly leaking out of the intravascular compartment into the peritoneal cavity, the sensation of vascular filling is not achieved, and the process continues. Hypoalbuminemia from decreased synthetic function in a cirrhotic liver results in reduced plasma oncotic pressure and contributes to the loss of fluid from the vascular compartment into the peritoneal cavity.

Clinical Features Patients typically note an increase in abdominal girth that is often accompanied by peripheral edema. The development of ascites is often insidious, and it is surprising that some patients wait so long and become so distended before seeking medical attention. Patients usually have at least 1–2 L of fluid in the abdomen before they are aware that there is an increase. If ascitic fluid is massive, respiratory function can be compromised, causing dyspnea. Hepatic hydrothorax may also contribute to respiratory symptoms. Patients with massive ascites are often malnourished and have muscle wasting and excessive fatigue and weakness.

Diagnosis Diagnosis of ascites is by physical examination and is often aided by abdominal imaging. Patients will have bulging flanks and may have a fluid wave or the presence of shifting dullness. This is determined by taking patients from a supine position to lying on either their left or right side and noting the movement of the dullness to percussion. Subtle amounts of ascites can be detected by ultrasound or CT scanning. Hepatic hydrothorax is more common on the right side and implicates a rent in the diaphragm with free flow of ascitic fluid into the thoracic cavity.

When patients present with ascites for the first time, it is recommended that a diagnostic paracentesis be performed to characterize the fluid. This should include the determination of total protein and albumin content, blood cell counts with differential, and cultures. In the appropriate setting, amylase may be measured and cytology performed. In patients with cirrhosis, the protein concentration of the ascitic fluid is low, usually <2.5 g/dL. The serum ascites-to-albumin gradient (SAAG), calculated by subtracting the fluid albumin level from the serum albumin level, has replaced the description of exudative or transudative fluid. When the SAAG is >1.1 g/dL, the cause of the ascites is most likely due to portal hypertension; this is usually in the setting of cirrhosis. Cardiac ascites can be identified by SAAG >1.1 g/dL and ascites protein >2.5g/dL. When the SAAG is <1.1 g/dL, infectious or malignant causes of ascites should be considered. When ascitic fluid protein is very low, <1.5 g/dL, patients are at increased risk for developing SBP. A high level of red blood cells in the ascitic fluid usually signifies a traumatic tap but can also rarely occur with hepatocellular cancer or a ruptured omental varix. When the absolute level of polymorphonuclear leukocytes is >250/μL, infection is likely.

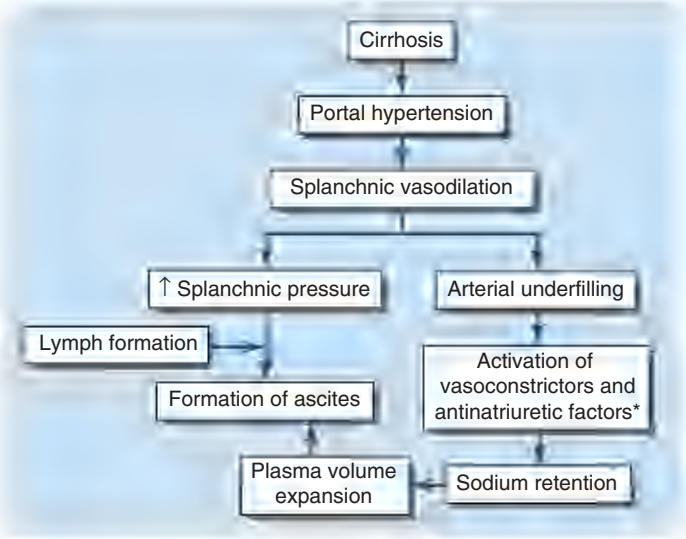

FIGURE 355-4 Development of ascites in cirrhosis. This flow diagram illustrates the importance of portal hypertension with splanchnic vasodilation in the development of ascites. *Antinatriuretic factors include the renin-angiotensin-aldosterone system and the sympathetic nervous system.

TREATMENT

Ascites

Patients with small amounts of ascites can usually be managed with dietary sodium restriction alone. Most average diets in the United States contain 6–8 g of sodium per day, and if patients eat at restaurants or fast-food outlets, the amount of sodium in their diet can exceed this amount. Thus, it is often extremely difficult to get patients to change their dietary habits to ingest 2 g of sodium per day, equivalent to slightly more than three-quarters of a teaspoon of salt, which is the recommended amount. Sodium educational pamphlets are helpful. Often, a simple recommendation is to eat fresh or frozen foods, avoiding canned or processed foods. When a moderate amount of ascites is present, diuretic therapy is usually necessary. Traditionally, spironolactone at 100 mg/d as a single dose is started, and furosemide may be added at 40 mg/d, particularly in patients who have peripheral edema. Failure of the diuretics suggests that patients may not be compliant with a low-sodium diet. If compliance is confirmed and ascitic fluid is not being mobilized, there should be incremental increases in spironolactone to a maximum of 400 mg/d and furosemide to 160 mg/d. If a large amount of ascites is still present on diuretics in patients who are compliant with a low-sodium diet, then they are defined as having *refractory ascites*, and alternative treatment modalities including repeated large-volume paracentesis (LVP) or a TIPS procedure should be considered (Fig. 355-5). After LVP of ≥5 L, IV 25% albumin at a dose of 6–8 g/L of removed ascites should be given to prevent circulatory dysfunction. Multiple studies have shown that TIPS, although effective at managing the ascites, does not improve survival. Unfortunately, TIPS is often associated with an increased frequency of hepatic encephalopathy and must be considered carefully on a case-by-case basis. The prognosis for patients with cirrhosis with ascites is poor, and some studies have shown that <50% of patients survive 2 years after the onset of ascites. Thus, there should be consideration for liver transplantation in patients with ascites. Patients with cirrhosis and ascites are at increased risk for renal failure from certain medications including nonsteroidal anti-inflammatory drugs and aminoglycosides; therefore, these medications should generally be avoided. Angiotensin-converting enzyme inhibitors and angiotensin receptor blockers should be used cautiously with close monitoring of blood pressure and renal function.

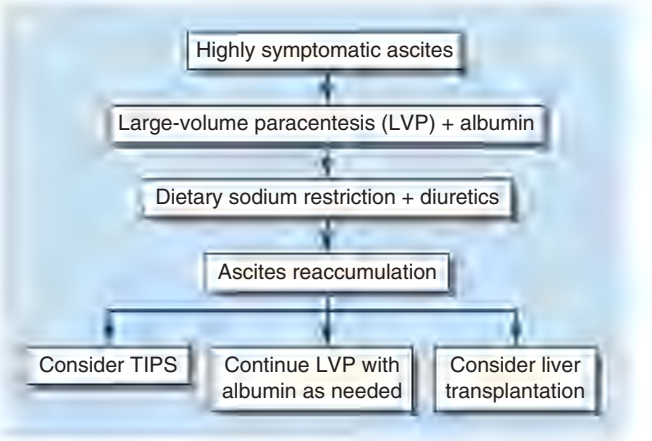

FIGURE 355-5 Treatment of refractory ascites. In patients who develop azotemia in the course of receiving diuretics in the management of their ascites, some will require repeated large-volume paracentesis (LVP), some may be considered for transjugular intrahepatic portosystemic shunt (TIPS), and some would be good candidates for liver transplantation. These decisions are all individualized.

SPONTANEOUS BACTERIAL PERITONITIS

SBP is a common and severe complication of ascites characterized by spontaneous infection of the ascitic fluid without an intraabdominal source. In hospitalized patients with cirrhosis and ascites, SBP can occur in up to 30% of individuals and can have a 25% in-hospital mortality rate. Bacterial translocation is the presumed mechanism for development of SBP, with gut flora traversing the intestine into mesenteric lymph nodes, leading to bacteremia and seeding of the ascitic fluid. The most common organisms are *Escherichia coli* and other gut bacteria; however, gram-positive bacteria, including *Streptococcus viridans*, *Staphylococcus aureus*, and *Enterococcus* spp., can also be found. If more than two organisms are identified, secondary bacterial peritonitis due to a perforated viscus should be considered. The diagnosis of SBP is made when the fluid sample has an absolute neutrophil count >250/μL. Bedside cultures should be obtained by direct injection of ascitic fluid into blood culture bottles. Patients with ascites may present with fever, altered mental status, elevated white blood cell count, abdominal pain or discomfort, and acute kidney injury, or they may present without any of these features. Therefore, it is necessary to have a high degree of clinical suspicion, and peritoneal taps are recommended for cirrhosis patients hospitalized with ascites and cirrhosis complications or signs of infection. Treatment is commonly with intravenous third-generation cephalosporin for 5 days. In addition, intravenous albumin (1.5 g/kg body weight on day 1 and 1.0 g/kg on day 3) has been shown to reduce the risk of renal failure and to improve survival. In patients with variceal hemorrhage, the frequency of SBP is significantly increased, and prophylaxis against SBP is recommended at presentation with upper GI bleeding. Furthermore, in patients who have had an episode of SBP and recovered, quinolone antibiotic prophylaxis should be given to prevent recurrent SBP.

HEPATORENAL SYNDROME

HRS is a form of functional renal failure without renal pathology that occurs in ~10% of patients with advanced cirrhosis or acute liver failure. There are marked disturbances in the arterial renal circulation in patients with HRS; these include an increase in vascular resistance accompanied by a reduction in systemic vascular resistance. The reason for renal vasoconstriction is most likely multifactorial and is poorly understood. The diagnosis is made usually in the presence of a large amount of ascites in patients who have a stepwise progressive increase in creatinine. Acute kidney injury (AKI) is defined by a 0.3-mg/dL rise in creatinine over 48 h or a 50% rise in creatinine from baseline. HRS-AKI, the new term for type 1 HRS, is characterized by a progressive rapid impairment in renal function. Type 2 HRS, now termed HRS–chronic kidney disease (CKD), is characterized by a reduction in glomerular filtration rate with an elevation of serum creatinine level, but it is stable and is associated with a better outcome than that of type 1 HRS.

HRS-AKI requires exclusion of other causes of acute renal failure, most notably volume depletion. Diuretics should be stopped, and infusion of albumin 1 g/kg per d for 48 h without significant improvements is required. Other causes of AKI, including intrinsic (acute tubular necrosis, acute interstitial nephritis, and glomerulonephritis) and obstructive kidney disease, should be excluded. Treatment is with vasoconstrictors such as terlipressin or, if not available, low-dose norepinephrine, which requires intensive care unit monitoring. Midodrine, an α-agonist, along with octreotide and intravenous albumin are also commonly used in the United States but are now third line. If treatment fails, then renal replacement therapy can be initiated. The best therapy for HRS is liver transplantation; recovery of renal function is typical in this setting. In patients with either AKI-HRS or CKD-HRS, the prognosis is poor unless transplant can be achieved.

HEPATIC ENCEPHALOPATHY

Hepatic encephalopathy is a serious complication of chronic liver disease and is broadly defined as an alteration in mental status and cognitive function occurring as a consequence of liver failure. In severe acute liver injury, the development of encephalopathy is a requirement for a diagnosis of acute liver failure and can be seen in association with life-threatening brain edema, which is not a feature in chronic liver disease. Hepatic encephalopathy is much more commonly seen in patients with chronic liver disease. Gut-derived neurotoxins that are not removed by the liver because of vascular shunting and decreased hepatic mass reach the brain and cause the symptoms known as hepatic encephalopathy. Ammonia levels are typically elevated, but the correlation between severity of liver disease and height of ammonia levels is often poor, and most hepatologists do not rely on ammonia levels to make a diagnosis or follow clinical progress. Other compounds and metabolites that may contribute to the development of encephalopathy include certain false neurotransmitters and mercaptans.

Clinical Features In acute liver failure, changes in mental status can occur rapidly. Brain edema can be seen in these patients, with severe encephalopathy associated with swelling of the gray matter. Cerebral herniation is a feared complication of brain edema in acute liver failure, and treatment to decrease edema is with hypertonic saline or mannitol.

In patients with cirrhosis, encephalopathy is often found as a result of precipitating events such as volume depletion, gastrointestinal bleeding, hyponatremia, infection, or constipation. Patients may be confused or exhibit a change in personality. They may be quite violent and difficult to manage; alternatively, patients may be very sleepy and difficult to rouse. If patients have ascites, this should be tapped to rule out infection. Evidence of GI bleeding should be sought, and patients should be appropriately hydrated. Electrolytes should be measured, and abnormalities corrected. In patients presenting with encephalopathy, asterixis is often present. Asterixis can be elicited by having patients extend their arms and bend their wrists back. Patients who are encephalopathic have a "liver flap"—that is, a sudden forward movement of the wrist. This requires patients to be able to cooperate with the examiner. Alternative causes for altered mental status should also be considered.

The diagnosis of hepatic encephalopathy is clinical and requires an experienced clinician to recognize and put together all the various features. Often when patients have encephalopathy for the first time, they (and/or their caregivers) are unaware of what is transpiring, but once they have been through the experience, they can identify when this is developing in subsequent situations and can often self-medicate to prevent the development or worsening of encephalopathy.

TREATMENT

Hepatic Encephalopathy

Treatment is multifactorial and includes management of the above-mentioned precipitating factors. Sometimes hydration and correction of electrolyte imbalance are all that is necessary. In the past, restriction of dietary protein was used; however, the negative impact of that maneuver on overall nutrition is thought to outweigh the

benefit, and it is thus strongly discouraged. The mainstay of treatment for encephalopathy is to use lactulose, a nonabsorbable disaccharide, which results in colonic acidification. Catharsis ensues, contributing to the elimination of nitrogenous products in the gut that are responsible for the development of encephalopathy. The goal of lactulose therapy is to promote two to three soft stools per day. Patients are asked to titrate their amount of ingested lactulose to achieve the desired effect. Lactulose is usually continued after the initial episode of encephalopathy. Poorly absorbed antibiotics are often used as adjunctive therapies for patients who have a difficult time with lactulose or in those with recurrent episodes. Rifaximin has replaced neomycin and metronidazole (because of their significant toxicity). The dose is 550 mg twice daily and is very effective in preventing recurrent encephalopathy. In patients with recurrent symptoms despite treatment, closure of large portosystemic shunts can be helpful. Zinc supplementation is sometimes helpful and is relatively harmless. The development of encephalopathy in patients with chronic liver disease is a poor prognostic sign, but this complication can be managed in the vast majority of patients.

ACUTE-ON-CHRONIC LIVER FAILURE

Acute-on-chronic liver failure (ACLF) is a recently recognized clinical syndrome that is characterized by acutely decompensating cirrhosis with associated failure of one or more organ systems, including liver, kidneys, brain, lung, circulatory system, and coagulation. It occurs in the setting of chronic liver disease almost always with cirrhosis and is a major cause of mortality in persons with cirrhosis. ACLF is precipitated by either direct injury to the liver (most commonly from alcoholic hepatitis and less often from new or flaring viral hepatitis, autoimmune hepatitis, or drug-induced liver injury) or systemic effects (most commonly bacterial or fungal infection and less often GI bleeding or the postoperative state), resulting in a marked systemic inflammatory response followed by organ failure and is analogous to sepsis syndrome. Mortality at 28 days ranges from 20 to 70% and increases with the number of organ failures. Clinicians should search for and treat precipitating causes of ACLF, determine if intensive care unit (ICU) care is needed, and consider immediate referral for liver transplantation. Complications of cirrhosis should be treated as described elsewhere in this chapter. If after 3–7 days of ICU support, there continue to be four or more organ failures and liver transplantation is not an option, consideration for a transition to palliative care is recommended.

LIVER-LUNG SYNDROMES

Hepatopulmonary syndrome (HPS) is characterized by arterial hypoxemia in a patient with cirrhosis without significant lung disease. The liver disease causes intrapulmonary vascular dilations, resulting in blood shunting past alveoli and significant ventilation-perfusion mismatch. Clinical symptoms include dyspnea and platypnea. HPS is common, occurring in 4–32% of patients with cirrhosis; however, it is often mild. Diagnosis involves demonstrating hypoxemia, without evidence of significant lung disease, and shunt on bubble echocardiography. Treatment is with oxygen supplementation and liver transplantation.

Portopulmonary hypertension (PPHT) is pulmonary hypertension in a patient with portal hypertension. The portal hypertension results in the production of vasoconstrictor substances that affect the pulmonary artery. Many patients are asymptomatic, especially early in the disease; however, they later can develop dyspnea on exertion and fatigue. PPHT is rare, occurring in ~5% of patients with advanced cirrhosis. Diagnosis includes initial identification on echocardiogram and confirmation on right heart catheterization showing elevated mean pulmonary artery pressure, elevated pulmonary vascular resistance, and normal pulmonary capillary wedge pressure. Prognosis is poor, although liver transplantation after effective reduction in pulmonary artery pressure with vasodilatory medications can be effective.

MALNUTRITION IN CIRRHOSIS

Because the liver is principally involved in the regulation of protein and energy metabolism in the body, patients with decompensated cirrhosis often develop malnutrition, insufficient intake of nutrients, which manifests clinically as sarcopenia, a loss in muscle mass and function resulting in frailty, decreased physical reserve, and increased susceptibility to health stressors. In the setting of cirrhosis and subsequent hepatic decompensation, patients become more catabolic with increased energy needs but often have decreased caloric intake due to anorexia, early satiety, ascites, restrictive diets (low sodium, potassium, and fluid) and hepatic encephalopathy. Obesity and edema may mask underlying sarcopenia. Lack of physical activity can further exacerbate the sarcopenia and resulting frailty. Sarcopenia and frailty have been associated with increased resource utilization and risk of death and poorer quality of life. Guidelines recommend (1) education for patients and families both with asymptomatic compensated and symptomatic decompensated cirrhosis on appropriate nutritional intake (both calories and protein) and the benefits of regular exercise; (2) periodic clinical assessments for malnutrition, sarcopenia, and frailty with increasing frequency as the patient decompensates; and (3) early referrals to registered dietician and physical therapy to develop a personalized therapeutic plan. Generally, patients with cirrhosis should consume 35 kcal/kg per d based on actual weight with estimated discounting for edema and ascites and 1.2–1.5 g/kg per d of protein based upon ideal body weight. Caloric intake goals should be reduced for patients with body mass index over 35 kg/m^2. Multiple small meals are recommended throughout waking hours to minimize muscle wasting during the fasted state. Relaxation in sodium restriction should be considered in those who are not meeting caloric intake goals. Optimization of care for hepatic encephalopathy and ascites is also beneficial. General exercise recommendations include 150–300 min of aerobic exercise a week and 2 days of muscle-strengthening exercises per week, though these recommendations should be tailored, particularly in decompensated cirrhosis.

ABNORMALITIES IN COAGULATION

Coagulation disorders in cirrhosis are poorly understood, and typical clinical measures of coagulation, such as the prothrombin time and international normalized ratio, are not reliable measures of clotting ability. There is decreased synthesis of both pro- and anticoagulant factors and thus some rebalancing in coagulation; however, the coagulation cascade can easily tip toward thrombosis or bleeding. In addition, patients may have thrombocytopenia from hypersplenism due to portal hypertension and some platelet dysfunction, which is counterbalanced with increased von Willebrand factor. Adequate thrombin formation can occur with platelet levels from cirrhosis patients >50,000–60,000/L. Synthesis of vitamin K–dependent clotting factors II, VII, IX, and X is diminished in patients with chronic cholestatic syndromes because absorption of vitamin K requires good bile flow. Intravenous or intramuscular vitamin K can quickly correct this abnormality. Overall, the status of coagulation in a cirrhotic patient needs to be judged clinically rather than relying on current laboratory tests. Standard prophylaxis for deep venous thrombosis when hospitalized is generally recommended. Routine correction of international normalized ratio before procedures or with variceal bleeding is generally not required.

BONE DISEASE IN CIRRHOSIS

Osteoporosis is common in patients with chronic cholestatic liver disease because of malabsorption of vitamin D and decreased calcium ingestion. The rate of bone resorption exceeds that of new bone formation in patients with cirrhosis, resulting in bone loss. Dual-energy x-ray absorptiometry (DEXA) is a useful method for determining osteoporosis or osteopenia. When a DEXA scan shows osteoporosis, treatment with bisphosphonates is effective.

HEMATOLOGIC ABNORMALITIES IN CIRRHOSIS

Numerous hematologic manifestations of cirrhosis are present, including anemia from a variety of causes including hypersplenism, hemolysis, iron deficiency, and perhaps folate deficiency from malnutrition. Macrocytosis is a common abnormality in red blood cell morphology seen in patients with chronic liver disease, and neutropenia may be a result of hypersplenism.