375 The Vasculitis Syndromes

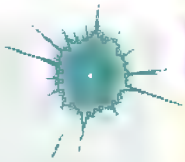

Carol A. Langford, Anthony S. Fauci

DEFINITION

Vasculitis is a clinicopathologic process characterized by inflammation of and damage to blood vessels. The vessel lumen is usually compromised, and this is associated with ischemia of the tissues supplied by the involved vessel. A broad and heterogeneous group of syndromes may result from this process, since any type, size, and location of blood vessel may be involved. Vasculitis and its consequences may be the primary or sole manifestation of a disease; alternatively, vasculitis may be a secondary component of another disease. Vasculitis may be confined to a single organ, such as the skin, or it may simultaneously involve several organ systems.

CLASSIFICATION

The vasculitic syndromes as a group have a great deal of heterogeneity while also possessing a considerable degree of overlap. Table 375-1 lists the major vasculitis syndromes. The distinguishing and overlapping features of these syndromes are discussed below.

PATHOPHYSIOLOGY AND PATHOGENESIS

Generally, most of the vasculitic syndromes are assumed to be mediated at least in part by immunopathogenic mechanisms that occur in response to certain antigenic stimuli. However, evidence supporting this hypothesis is for the most part indirect and may reflect epiphenomena as opposed to true causality. Furthermore, it is unknown why some individuals might develop vasculitis in response to certain antigenic stimuli, whereas others do not. It is likely that a number of factors are involved in the ultimate expression of a vasculitic syndrome. These include the genetic predisposition, environmental exposures, and the regulatory mechanisms associated with immune response to certain antigens. Although immune complex formation, antineutrophil cytoplasmic antibodies (ANCA), and pathogenic T lymphocyte responses (Table 375-2) have been among the prominent hypothesized mechanisms, the pathogenesis of individual forms of vasculitis remains complex and varied.

TABLE 375-1 Vasculitis Syndromes

PRIMARY VASCULITIS SYNDROMES	SECONDARY VASCULITIS SYNDROMES
Granulomatosis with polyangiitis	Vasculitis associated with probable etiology
Microscopic polyangiitis	Drug-induced vasculitis
Eosinophilic granulomatosis with polyangiitis (Churg-Strauss)	Hepatitis C virus–associated cryoglobulinemic vasculitis
IgA vasculitis (Henoch-Schönlein)	Hepatitis B virus–associated vasculitis
Cryoglobulinemic vasculitis	Cancer-associated vasculitis
Polyarteritis nodosa	Vasculitis associated with systemic disease
Kawasaki disease	Lupus vasculitis
Giant cell arteritis	Rheumatoid vasculitis
Takayasu arteritis	Sarcoid vasculitis
Behçet's disease	Others
Cogan's syndrome	
Single-organ vasculitis	
Cutaneous leukocytoclastic angiitis	
Cutaneous arteritis	
Primary central nervous system vasculitis	
Isolated aortitis	

Source: Adapted from JC Jennette et al: Arthritis Rheum 65:1, 2013.

TABLE 375-2 Potential Mechanisms of Vessel Damage in Vasculitis Syndromes

Pathogenic immune-complex formation and/or deposition
IgA vasculitis (Henoch-Schönlein)
Lupus vasculitis
Serum sickness and cutaneous vasculitis syndromes
Hepatitis C virus–associated cryoglobulinemic vasculitis
Hepatitis B virus–associated vasculitis
Production of antineutrophilic cytoplasmic antibodies
Granulomatosis with polyangiitis
Microscopic polyangiitis
Eosinophilic granulomatosis with polyangiitis (Churg-Strauss)
Pathogenic T lymphocyte responses and granuloma formation
Giant cell arteritis
Takayasu arteritis
Granulomatosis with polyangiitis
Eosinophilic granulomatosis with polyangiitis (Churg-Strauss)

Source: Reproduced with permission from MC Sneller, AS Fauci: Pathogenesis of vasculitis syndromes. Med Clin North Am 81:221, 1997.

PATHOGENIC IMMUNE-COMPLEX FORMATION

Deposition of immune complexes was the first and most widely accepted pathogenic mechanism of vasculitis. However, the causal role of immune complexes has not been clearly established in most of the vasculitic syndromes. Circulating immune complexes need not result in deposition of the complexes in blood vessels with ensuing vasculitis, and many patients with active vasculitis do not have demonstrable circulating or deposited immune complexes. The actual antigen contained in the immune complex has only rarely been identified in vasculitic syndromes. In this regard, hepatitis B antigen has been identified in both the circulating and deposited immune complexes in a subset of patients who have features of a systemic vasculitis clinically similar to polyarteritis nodosa (see "Polyarteritis Nodosa"). Cryoglobulinemic vasculitis is strongly associated with hepatitis C virus infection; hepatitis C virions and hepatitis C virus antigen-antibody complexes have been identified in the cryoprecipitates of these patients (see "Cryoglobulinemic Vasculitis").

The mechanisms of tissue damage in immune complex–mediated vasculitis resemble those described for serum sickness. In this model, antigen-antibody complexes are formed in antigen excess and are deposited in vessel walls whose permeability has been increased by vasoactive amines such as histamine, bradykinin, and leukotrienes released from platelets or from mast cells as a result of IgE-triggered mechanisms. The deposition of complexes results in activation of complement components, particularly C5a, which is strongly chemotactic for neutrophils. These cells then infiltrate the vessel wall, phagocytose the immune complexes, and release their intracytoplasmic enzymes, which damage the vessel wall. As the process becomes subacute or chronic, mononuclear cells infiltrate the vessel wall resulting in compromise of the vessel lumen with ischemic changes in the tissues supplied by the involved vessel. Several variables may explain why only certain types of immune complexes cause vasculitis and why only certain vessels are affected in individual patients. These include the ability of the reticuloendothelial system to clear circulating complexes from the blood, the size and physicochemical properties of immune complexes, the relative degree of turbulence of blood flow, the intravascular hydrostatic pressure in different vessels, and the preexisting integrity of the vessel endothelium.

ANTINEUTROPHIL CYTOPLASMIC ANTIBODIES

ANCA are antibodies directed against certain proteins in the cytoplasmic granules of neutrophils and monocytes. These autoantibodies are present in a high percentage of patients with active granulomatosis with polyangiitis and microscopic polyangiitis and in a lower percentage of patients with eosinophilic granulomatosis with polyangiitis. Because these diseases share the presence of ANCA

and small-vessel vasculitis, they have been grouped collectively as "ANCA-associated vasculitis." However, since these diseases possess unique clinical phenotypes, they should continue to be viewed as separate entities.

There are two major categories of ANCA based on different targets for the antibodies. The terminology of *cytoplasmic ANCA* (cANCA) refers to the diffuse, granular cytoplasmic staining pattern observed by immunofluorescence microscopy when serum antibodies bind to indicator neutrophils. Proteinase-3, a 29-kDa neutral serine proteinase present in neutrophil azurophilic granules, is the major cANCA antigen. More than 90% of patients with active granulomatosis with polyangiitis have detectable antibodies to proteinase-3 (see below). The terminology of *perinuclear ANCA* (pANCA) refers to the more localized perinuclear or nuclear staining pattern of the indicator neutrophils. The major target for pANCA is the enzyme myeloperoxidase; other targets that can produce a pANCA pattern include elastase, cathepsin G, lactoferrin, lysozyme, and bactericidal/permeability-increasing protein. However, only antibodies to myeloperoxidase have been convincingly associated with vasculitis. Antimyeloperoxidase antibodies have been reported in a variable percentage of patients with microscopic polyangiitis, eosinophilic granulomatosis with polyangiitis, isolated necrotizing crescentic glomerulonephritis, and granulomatosis with polyangiitis (see below). A pANCA pattern that is not due to antimyeloperoxidase antibodies has been associated with nonvasculitic entities such as rheumatic and nonrheumatic autoimmune diseases, inflammatory bowel disease, certain drugs, and infections such as endocarditis and bacterial airway infections in patients with cystic fibrosis.

It is unclear why patients with these vasculitis syndromes develop antibodies to myeloperoxidase or proteinase-3 or what role these antibodies play in disease pathogenesis. There are a number of in vitro observations that suggest possible mechanisms whereby these antibodies can contribute to the pathogenesis of the vasculitis syndromes. Proteinase-3 and myeloperoxidase reside in the azurophilic granules and lysosomes of resting neutrophils and monocytes, where they are apparently inaccessible to serum antibodies. However, when neutrophils or monocytes are primed by tumor necrosis factor α (TNF-α) or interleukin 1 (IL-1), or activation of the alternative complement cascade, proteinase-3 and myeloperoxidase translocate to the cell membrane, where they can interact with extracellular ANCA. The neutrophils then degranulate and produce reactive oxygen species that can cause tissue damage. Furthermore, ANCA-activated neutrophils can adhere to and kill endothelial cells in vitro. Activation of neutrophils and monocytes by ANCA also induces the release of proinflammatory cytokines such as IL-1 and IL-8. Adoptive transfer experiments in genetically engineered mice provide further evidence for a direct pathogenic role of ANCA in vivo. In contradiction, however, a number of clinical and laboratory observations argue against a primary pathogenic role for ANCA. Patients may have active granulomatosis with polyangiitis in the absence of ANCA; the absolute height of the antibody titers does not correlate well with disease activity; and patients with granulomatosis with polyangiitis in remission may continue to have high ANCA levels for years (see below).

PATHOGENIC T LYMPHOCYTE RESPONSES AND GRANULOMA FORMATION

The histopathologic feature of granulomatous vasculitis has provided evidence to support a role of pathogenic T lymphocyte responses and cell-mediated immune injury. Vascular endothelial cells can express human leukocyte antigen (HLA) class II molecules following activation by cytokines such as interferon (IFN) γ. This allows these cells to participate in immunologic reactions such as interaction with CD4+ T lymphocytes in a manner similar to antigen-presenting macrophages. Endothelial cells can secrete IL-1, which may activate T lymphocytes and initiate or propagate in situ immunologic processes within the blood vessel. In addition, IL-1 and TNF-α are potent inducers of endothelial-leukocyte adhesion molecule 1 (ELAM-1) and vascular cell adhesion molecule 1 (VCAM-1), which may enhance the adhesion of leukocytes to endothelial cells in the blood vessel wall.

APPROACH TO THE PATIENT

General Principles of Diagnosis

The diagnosis of vasculitis should be considered in any patient with an unexplained systemic illness. However, there are certain clinical features that should suggest a diagnosis of vasculitis. These include palpable purpura, pulmonary infiltrates and microscopic hematuria, chronic sinusitis, mononeuritis multiplex, unexplained ischemic events, and glomerulonephritis with evidence of multisystem disease. As a number of nonvasculitic diseases may also produce these abnormalities, the first step in the workup of a patient with suspected vasculitis is to exclude other diseases that can mimic vasculitis **(Table 375-3)**. It is particularly important to exclude infectious diseases with features that overlap those of vasculitis, especially if the patient's clinical condition is deteriorating rapidly and empirical immunosuppressive treatment is being contemplated.

Once diseases that mimic vasculitis have been excluded, the workup should follow a series of progressive steps that establish the diagnosis of vasculitis and determine, where possible, the category of the vasculitis syndrome **(Fig. 375-1)**. This approach is of considerable importance since several of the vasculitis syndromes require aggressive therapy with glucocorticoids and other immunosuppressive agents, whereas other syndromes usually resolve spontaneously and require symptomatic treatment only. The definitive diagnosis of vasculitis is usually made based on biopsy of involved tissue. The yield of "blind" biopsies of organs with no subjective or objective evidence of involvement is very low and should be avoided.

TABLE 375-3 Conditions That Can Mimic Vasculitis

Infectious Diseases
Bacterial endocarditis
Disseminated gonococcal infection
Pulmonary histoplasmosis
Coccidioidomycosis
Syphilis
Lyme disease
Rocky Mountain spotted fever
Whipple's disease
Coagulopathies/Thrombotic Microangiopathies
Antiphospholipid syndrome
Thrombotic thrombocytopenic purpura
Neoplasms
Atrial myxoma
Lymphoma
Carcinomatosis
Drug Toxicity
Cocaine
Levamisole
Amphetamines
Ergot alkaloids
Methysergide
Arsenic
Other
Sarcoidosis
Atheroembolic disease
Antiglomerular basement membrane disease (Goodpasture's syndrome)
Amyloidosis
Migraine
Fibromuscular dysplasia
Heritable disorders of connective tissue
Segmental arterial mediolysis (SAM)
Reversible cerebral vasoconstrictive syndrome

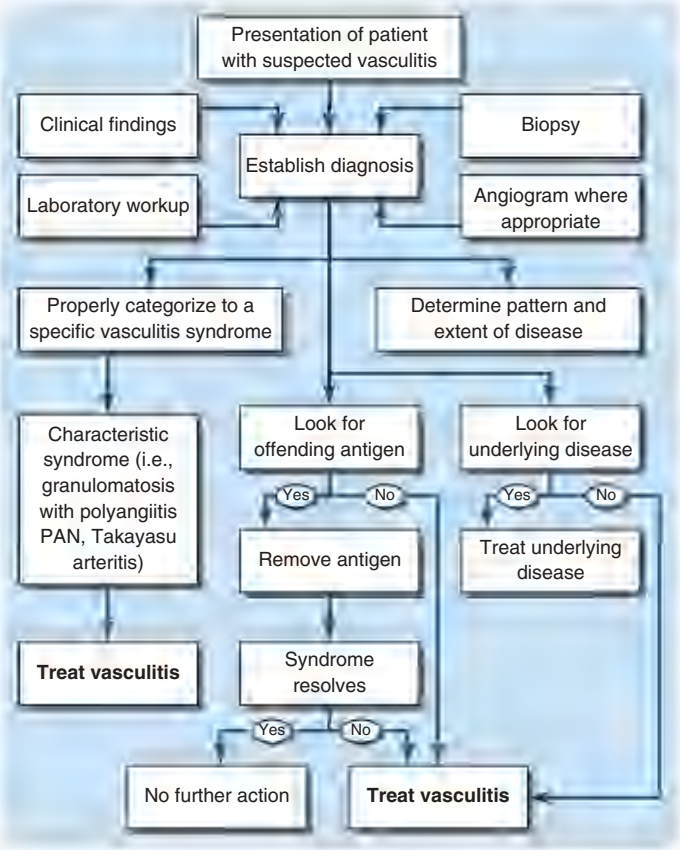

FIGURE 375-1 Algorithm for the approach to a patient with suspected diagnosis of vasculitis. PAN, polyarteritis nodosa.

When syndromes such as polyarteritis nodosa, Takayasu arteritis, or primary central nervous system (CNS) vasculitis are suspected, arteriogram of organs with suspected involvement should be performed.

GENERAL PRINCIPLES OF TREATMENT

Once a diagnosis of vasculitis has been established, a decision regarding therapeutic strategy must be made (Fig. 375-1). If an offending antigen that precipitates the vasculitis is recognized, the antigen should be removed where possible. If the vasculitis is associated with an underlying disease such as an infection, neoplasm, or connective tissue disease, the underlying disease should be treated. If the syndrome represents a primary vasculitic disease, treatment should be initiated according to the category of the vasculitis syndrome. Specific therapeutic regimens are discussed below for the individual vasculitis syndromes; however, certain general principles regarding therapy should be considered. Decisions regarding treatment should be based on the use of regimens for which there has been published literature supporting efficacy for that particular vasculitic disease. Since the potential toxic side effects of certain therapeutic regimens may be substantial, the risk-versus-benefit ratio of any therapeutic approach should be weighed carefully. Glucocorticoids and/or other immunosuppressive agents should be instituted immediately in diseases where irreversible organ system dysfunction and high morbidity and mortality rates have been clearly established. Granulomatosis with polyangiitis is the prototype of a severe systemic vasculitis requiring such a therapeutic approach (see below). Conversely, aggressive therapy should be avoided for vasculitic manifestations that rarely result in irreversible organ system dysfunction such as isolated idiopathic cutaneous vasculitis. Glucocorticoids should be initiated in those systemic vasculitides that cannot be specifically categorized or for which there is no established standard therapy, with other immunosuppressive agents being added if an adequate response does not result or if remission can only be achieved and maintained with an unacceptably toxic regimen of glucocorticoids. Following improvement, one should continually attempt to taper glucocorticoids and discontinue when possible. When using other immunosuppressive regimens, one should base the choice of agent upon the available therapeutic data supporting efficacy in that disease, the site and severity of organ involvement, and the toxicity profile of the drug.

Most forms of vasculitis carry the potential for relapse such that treatment planning needs to include assessment of relapse risk for that vasculitis and the medication regimen being used.

Physicians should be thoroughly aware of the acute and long-term side effects associated with the agents that are commonly used to treat different forms of vasculitis **(Table 375-4)**.

Morbidity and mortality can occur as a result of treatment, and strategies to monitor for and prevent toxicity represent an essential part of patient care.

Addressing the risk of bone loss is important in all patients receiving glucocorticoids. Daily cyclophosphamide should be taken all at once in the morning with a large amount of fluid throughout the day to reduce the risk of bladder injury, and monitoring for bladder cancer should continue indefinitely.

Maintaining the white blood cell (WBC) count at >3000/μL and the neutrophil count at >1500/μL is essential to reduce the risk of life-threatening infections. Monitoring of the complete blood count every 1–2 weeks for as long as the patient receives cyclophosphamide can effectively prevent cytopenias. Methotrexate, azathioprine, and mycophenolate mofetil are also associated with bone marrow suppression, and complete blood counts should be obtained every 1–2 weeks for the first 1–2 months after their initiation and once a month thereafter. To lessen toxicity, methotrexate is often given together with folic acid, 1 mg daily, or folinic acid, 5–10 mg once a week 24 h following methotrexate. Methotrexate is eliminated by the kidney and contraindicated in renal insufficiency as this increases the risk for toxicity. Prior to initiation of azathioprine, thiopurine methyltransferase (TPMT), an enzyme involved in the metabolism of azathioprine, should be assayed because inadequate levels may result in severe cytopenia.

Rituximab can be associated with infusion reactions. In addition to administering this within a skilled infusion center, these reactions can be lessened by the use of premedications. There is a risk of hepatitis B reactivation with rituximab such that all patients should be screened for this infection prior to its use. Immunoglobulins should be monitored with rituximab use.

Tocilizumab and sarilumab are associated with cytopenias, hepatotoxicity, and hyperlipidemia. Laboratory monitoring for drug toxicity should be performed 4–8 weeks after start of therapy and every 3 months thereafter.

Infection represents a significant toxicity for all vasculitis patients treated with immunosuppressive therapy. Infections with *Pneumocystis jirovecii* and certain fungi can be seen even when the WBC count is within normal limits, particularly in patients receiving glucocorticoids. Use of prophylactic therapy to prevent *P. jirovecii* infection should be based on the treatment regimen being used. Patients with granulomatosis with polyangiitis or microscopic polyangiitis who are receiving induction treatment with glucocorticoids in combination with another immunosuppressive agent should receive trimethoprim-sulfamethoxazole (TMP-SMX) or a different preventive medication. Continuation of *Pneumocystis* prophylaxis during maintenance therapy should be strongly considered in most patients, particularly for those receiving rituximab or who have persistent lymphopenia.

In recent years, national and regional organizations have published treatment guidelines that can provide additional direction to clinicians. It should be emphasized that each patient is unique and requires individual decision-making. Information from guidelines as well as this chapter should serve as a framework for the application of evidence-based approaches with incorporation of patient-specific goals to provide maximal therapeutic efficacy with minimal toxic side effects.

TABLE 375-4 Major Toxic Side Effects of Drugs Used in the Treatment of Vasculitis[a]

CONVENTIONAL IMMUNOSUPPRESSIVE AGENTS	
Glucocorticoids	
Osteoporosis	Growth suppression in children
Cataracts	Hypertension
Glaucoma	Avascular necrosis of bone
Diabetes mellitus	Myopathy
Electrolyte abnormalities	Alterations in mood
Metabolic abnormalities	Psychosis
Severe and opportunistic infections	Pseudotumor cerebri
Cushingoid features	Peptic ulcer diathesis
	Pancreatitis
Cyclophosphamide	
Bone marrow suppression	Hypogammaglobulinemia
Cystitis	Pulmonary fibrosis
Bladder carcinoma	Myelodysplasia
Gonadal suppression	Oncogenesis
Gastrointestinal intolerance	Teratogenicity
	Severe and opportunistic infections
Methotrexate	
Gastrointestinal intolerance	Pneumonitis
Stomatitis	Teratogenicity
Bone marrow suppression	Severe and opportunistic infections
Hepatotoxicity (may lead to fibrosis or cirrhosis)	
Azathioprine	
Gastrointestinal intolerance	Severe and opportunistic infections
Bone marrow suppression	Hypersensitivity
Hepatotoxicity	
Mycophenolate mofetil	
Bone marrow suppression	Severe and opportunistic infections
Gastrointestinal intolerance	Teratogenicity
BIOLOGIC AGENTS AND SMALL-MOLECULE INHIBITORS	
Rituximab (granulomatosis with polyangiitis and microscopic polyangiitis)	
Infusion reactions	Severe and opportunistic infections
Progressive multifocal leukoencephalopathy	Hepatitis B reactivation
Mucocutaneous reactions	Tumor lysis syndrome
Hypogammaglobulinemia	Late-onset neutropenia
Impaired vaccine response	
Tocilizumab (giant cell arteritis)	
Sarilumab (polymyalgia rheumatica)	
Bone marrow suppression	Severe and opportunistic infections
Hepatotoxicity	Gastrointestinal perforation
Hyperlipidemia	Hypersensitivity reactions
Mepolizumab (eosinophilic granulomatosis with polyangiitis [Churg-Strauss])	
Hypersensitivity reactions	Opportunistic infections: herpes zoster
Apremilast (Behçet's syndrome; see Chap. 376)	
Diarrhea, nausea, and vomiting	Weight decrease
Depression	
Avacopan (severe granulomatosis with polyangiitis and microscopic polyangiitis)	
Hepatotoxicity	Hepatitis B reactivation
Hypersensitivity reactions	Serious infections

[a]Consult the drug package insert for a full listing of side effects.

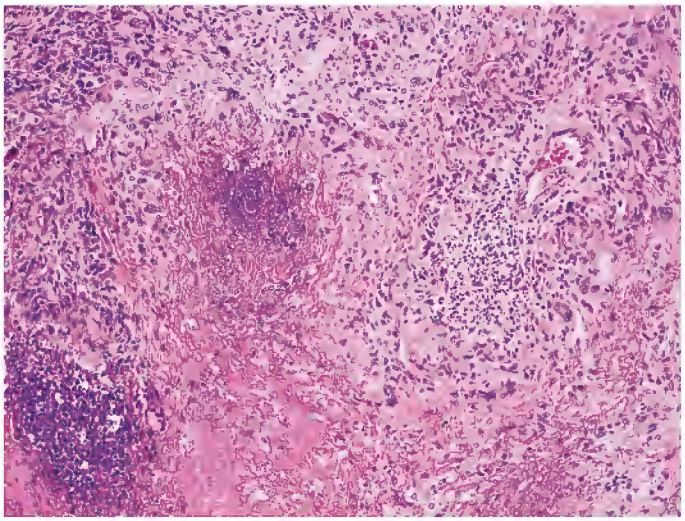

FIGURE 375-2 Lung histology in granulomatosis with polyangiitis. This area of geographic necrosis has a serpiginous border of histiocytes and giant cells surrounding a central necrotic zone. Vasculitis is also present with neutrophils and lymphocytes infiltrating the wall of a small arteriole (*upper right*). *(Courtesy of William D. Travis, MD; with permission.)*

GRANULOMATOSIS WITH POLYANGIITIS

DEFINITION

Granulomatosis with polyangiitis is a distinct clinicopathologic entity characterized by granulomatous vasculitis of the upper and lower respiratory tracts together with glomerulonephritis. In addition, variable degrees of disseminated vasculitis involving both small arteries and veins may occur.

INCIDENCE AND PREVALENCE

Granulomatosis with polyangiitis has an estimated prevalence of 3 per 100,000. It is extremely rare in blacks compared with whites; the male-to-female ratio is 1:1. The disease can be seen at any age; ~15% of patients are <19 years of age, but only rarely does the disease occur before adolescence; the mean age of onset is 40–60 years.

PATHOLOGY AND PATHOGENESIS

The histopathologic hallmarks of granulomatosis with polyangiitis are necrotizing vasculitis of small arteries and veins together with granuloma formation, which may be either intravascular or extravascular (Fig. 375-2). Lung involvement typically appears as multiple, bilateral, nodular or cavitary infiltrates (Fig. 375-3), which on biopsy can reveal necrotizing granulomatous vasculitis. Upper airway lesions, particularly those in the sinuses and nasopharynx, typically reveal inflammation, necrosis, and granuloma formation, with or without vasculitis.

In its earliest form, renal involvement is characterized by a focal and segmental glomerulitis that may evolve into a rapidly progressive crescentic glomerulonephritis. Granuloma formation is only rarely seen on

FIGURE 375-3 Computed tomography scan of a patient with granulomatosis with polyangiitis. The patient developed multiple, bilateral, and cavitary infiltrates.

renal biopsy. In contrast to other forms of glomerulonephritis, immune complex deposition is not found in the renal lesion of granulomatosis with polyangiitis (pauci-immune glomerulonephritis). In addition to the classic triad of disease of the upper and lower respiratory tracts and kidney, virtually any organ can be involved with vasculitis, granuloma, or both.

The immunopathogenesis of this disease is unclear, although the involvement of upper airways and lungs with granulomatous vasculitis suggests an aberrant cell-mediated immune response to an exogenous or even endogenous antigen that enters through or resides in the upper airway. Chronic nasal carriage of *Staphylococcus aureus* has been reported to be associated with a higher relapse rate of granulomatosis with polyangiitis; however, there is no evidence for a role of this organism in the pathogenesis of the disease.

Peripheral blood mononuclear cells obtained from patients with granulomatosis with polyangiitis manifest increased secretion of IFN-γ but not of IL-4, IL-5, or IL-10 compared to healthy controls. In addition, TNF-α production from peripheral blood mononuclear cells and CD4+ T cells is elevated and monocytes from patients with granulomatosis with polyangiitis produce increased amounts of IL-12. These findings indicate an unbalanced T_H1-type T-cell cytokine pattern in this disease that may have pathogenic and perhaps therapeutic implications.

A high percentage of patients with granulomatosis with polyangiitis develop ANCA, and these autoantibodies may play a role in the pathogenesis of this disease (see above).

CLINICAL AND LABORATORY MANIFESTATIONS

Involvement of the upper airways occurs in 95% of patients with granulomatosis with polyangiitis. Patients often present with severe upper respiratory tract findings such as paranasal sinus pain and drainage and purulent or bloody nasal discharge, with or without nasal mucosal ulceration (Table 375-5). Nasal septal perforation may follow, leading to saddle nose deformity. Serous otitis media may occur as a result of eustachian tube blockage. Subglottic stenosis resulting from active disease or scarring occurs in ~16% of patients and may result in severe airway obstruction.

Pulmonary involvement (85–90% of patients) may be clinically expressed as cough, hemoptysis, dyspnea, and chest discomfort, or active disease may be asymptomatic in up to 30% of cases. Endobronchial disease, either in its active form or as a result of fibrous scarring, may lead to obstruction with atelectasis.

Eye involvement (52% of patients) may range from a mild conjunctivitis to dacryocystitis, episcleritis, scleritis, granulomatous sclerouveitis, ciliary vessel vasculitis, and retroorbital mass lesions leading to proptosis.

Skin lesions (46% of patients) appear as papules, vesicles, palpable purpura, ulcers, or subcutaneous nodules; biopsy reveals vasculitis, granuloma, or both. Cardiac involvement (8% of patients) manifests as pericarditis, coronary vasculitis, or, rarely, cardiomyopathy. Nervous system manifestations (23% of patients) include cranial neuritis, mononeuritis multiplex, or, rarely, cerebral vasculitis and/or granuloma.

Renal disease (77% of patients) generally dominates the clinical picture and, if left untreated, accounts directly or indirectly for most of the mortality in this disease. Although it may smolder in some cases as a mild glomerulitis with proteinuria, hematuria, and red blood cell casts, once clinically detectable renal functional impairment occurs, rapidly progressive renal failure usually ensues unless appropriate treatment is instituted.

While the disease is active, most patients have nonspecific symptoms and signs such as malaise, weakness, arthralgias, anorexia, and weight loss. Fever may indicate activity of the underlying disease but more often reflects secondary infection, usually of the upper airway.

Characteristic laboratory findings include an elevated erythrocyte sedimentation rate (ESR) and/or C-reactive protein (CRP), anemia and leukocytosis, and mild hypergammaglobulinemia. Thrombocytosis may be seen as an acute-phase reactant. Approximately 90% of patients with active granulomatosis with polyangiitis have a positive antiproteinase-3 ANCA. However, in the absence of active disease, the sensitivity drops to ~60–70%. A small percentage of patients with granulomatosis with polyangiitis may have antimyeloperoxidase rather than antiproteinase-3 antibodies, and up to 20% may lack ANCA.

Patients with granulomatosis with polyangiitis have been found to have an increased incidence of venous thrombotic events. Although routine anticoagulation for all patients is not recommended, a heightened awareness for any clinical features suggestive of deep-vein thrombosis or pulmonary emboli is warranted.

TABLE 375-5 Granulomatosis with Polyangiitis: Frequency of Clinical Manifestations in 158 Patients Studied at the National Institutes of Health

MANIFESTATION	PERCENTAGE AT DISEASE ONSET	PERCENTAGE THROUGHOUT COURSE OF DISEASE
Kidney		
Glomerulonephritis	18	77
Ear/Nose/Throat	**73**	**92**
Sinusitis	51	85
Nasal disease	36	68
Otitis media	25	44
Hearing loss	14	42
Subglottic stenosis	1	16
Ear pain	9	14
Oral lesions	3	10
Lung	**45**	**85**
Pulmonary infiltrates	25	66
Pulmonary nodules	24	58
Hemoptysis	12	30
Pleuritis	10	28
Eyes		
Conjunctivitis	5	18
Dacryocystitis	1	18
Scleritis	6	16
Proptosis	2	15
Eye pain	3	11
Visual loss	0	8
Retinal lesions	0	4
Corneal lesions	0	1
Iritis	0	2
Other[a]		
Arthralgias/arthritis	32	67
Fever	23	50
Cough	19	46
Skin abnormalities	13	46
Weight loss (>10% body weight)	15	35
Peripheral neuropathy	1	15
Central nervous system disease	1	8
Pericarditis	2	6
Hyperthyroidism	1	3

[a]Fewer than 1% had parotid, pulmonary artery, breast, or lower genitourinary (urethra, cervix, vagina, testicular) involvement.

Source: GS Hoffman et al: Ann Intern Med 116:488, 1992.

DIAGNOSIS

The diagnosis of granulomatosis with polyangiitis can be established by the demonstration of necrotizing granulomatous vasculitis on tissue biopsy in a patient with compatible clinical features. Pulmonary tissue offers the highest diagnostic yield, almost invariably revealing granulomatous vasculitis. Biopsy of upper airway tissue usually reveals acute and chronic inflammation but can show granulomas and/or vasculitis. Renal biopsy can confirm a pauci-immune glomerulonephritis

(Chaps. A4 and A14), which differentiates this from other causes of glomerular disease (Chap. 326).

The utility of ANCA in diagnosis varies based on the clinical presentation. The predictive value of a positive ANCA is 90% in patients with active glomerulonephritis. However, in patients who present with sinus and/or lung disease where renal disease is absent, this decreases to 30–60%. Tissue biopsy is typically necessary in these settings to rule out infection or malignancy, which can have a similar presentation and be associated with a false-positive ANCA. Biopsy should also be pursued when clinically inconsistent features are present or when ANCA is absent.

In its typical presentation, the clinicopathologic complex of granulomatosis with polyangiitis usually provides ready differentiation from other disorders. However, if all the typical features are not present at once, it needs to be differentiated from the other vasculitides, antiglomerular basement membrane disease (Goodpasture's syndrome) (Chap. 326), relapsing polychondritis (Chap. 378), tumors of the upper airway or lung, and infectious diseases such as histoplasmosis (Chap. 218), endocarditis (Chap. 133), mucocutaneous leishmaniasis (Chap. 233), and rhinoscleroma (Chap. 166) as well as noninfectious granulomatous diseases.

Of particular note is the differentiation from other *midline destructive diseases*. These diseases lead to extreme tissue destruction and mutilation localized to the midline upper airway structures including the sinuses; erosion through the skin of the face commonly occurs, a feature that is extremely rare in granulomatosis with polyangiitis. Although blood vessels may be involved in the intense inflammatory reaction and necrosis, primary vasculitis is not seen. *Upper airway neoplasms* and specifically *extranodal natural killer (NK)/T-cell lymphoma (nasal type)* are important causes of midline destructive disease. These lesions are diagnosed based on histology, which reveals polymorphous atypical lymphoid cells with an NK cell immunophenotype, typically Epstein-Barr virus (Chap. 199). Such cases are treated based on their degree of dissemination, and localized lesions have responded to irradiation. Upper airway lesions should never be irradiated in granulomatosis with polyangiitis. Cocaine-induced tissue injury can be another important mimic of granulomatosis with polyangiitis in patients who present with isolated midline destructive disease. ANCA that target human neutrophil elastase can be found in patients with cocaine-induced midline destructive lesions and can complicate the differentiation from granulomatosis with polyangiitis. This has been further confounded by the high frequency of levamisole adulteration of cocaine, which can result in cutaneous infarction and serologic changes that may mimic vasculitis. Granulocytopenia is a common finding in levamisole-induced disease that is not associated with granulomatosis with polyangiitis.

Granulomatosis with polyangiitis must also be differentiated from *lymphomatoid granulomatosis*, which is an Epstein-Barr virus–positive B-cell proliferation that is associated with an exuberant T-cell reaction. Lymphomatoid granulomatosis is characterized by lung, skin, CNS, and kidney involvement in which atypical lymphocytoid and plasmacytoid cells infiltrate nonlymphoid tissue in an angioinvasive manner. In this regard, it clearly differs from granulomatosis with polyangiitis in that it is not an inflammatory vasculitis in the classic sense but an angiocentric perivascular infiltration of atypical mononuclear cells. Up to 50% of patients may develop a true malignant lymphoma.

TREATMENT

Granulomatosis with Polyangiitis

Prior to the introduction of effective therapy, granulomatosis with polyangiitis was universally fatal within a few months of diagnosis. Glucocorticoids alone led to some symptomatic improvement, with little effect on the ultimate course of the disease. The development of treatment with cyclophosphamide dramatically changed patient outcome such that marked improvement was seen in >90% of patients, complete remission was seen in 75% of patients, and 5-year patient survival was seen in >80%.

Despite the ability to successfully induce remission, 50–70% of remissions are later associated with one or more relapses. The determination of relapse should be based on objective evidence of disease activity, taking care to rule out other features that may have a similar appearance such as infection, medication toxicity, or chronic disease sequelae. Many patients who achieve remission continue to have a positive ANCA for years, and changes in ANCA should not be used as a measure of disease activity. Results from a large prospective study found that only 43% of patients relapsed within 1 year of an increase in ANCA levels. Thus, a rise in ANCA by itself is not a harbinger of immediate disease relapse and should not lead to reinstitution or increase in immunosuppressive therapy. Reinduction of remission after relapse is almost always achieved; however, a high percentage of patients ultimately have some degree of damage from irreversible features of their disease, such as varying degrees of renal insufficiency, neurologic impairment, hearing loss, subglottic stenosis, saddle nose deformity, and chronic sinus dysfunction. Patients who developed irreversible renal failure but who achieved subsequent remission have undergone successful renal transplantation.

Treatment of granulomatosis with polyangiitis is viewed as having two phases: *induction*, where active disease is put into remission, followed by *maintenance*. Decisions regarding induction and maintenance agents are guided by published data, individual patient factors that include contraindications, relapse history, and comorbidities, and stratification based on disease severity. Severe disease is associated with life- or organ-threatening manifestations and is based not only on the degree of involvement but also the organ affected. Pulmonary involvement can be nonsevere when presenting as nodular disease without respiratory compromise or severe in the setting of alveolar hemorrhage. In contrast, active glomerulonephritis is always considered to be severe disease even when renal function remains normal.

REMISSION INDUCTION OF SEVERE DISEASE

Regimens to induce remission of severe active disease consist of either cyclophosphamide or rituximab given in combination with glucocorticoids and consideration of adjunctive avacopan. Glucocorticoids were historically given as prednisone 1 mg/kg per day for the first month, followed by tapering. In a randomized trial, use of a reduced-dose glucocorticoid regimen was noninferior to a standard-dose regimen and was associated with a lower rate of serious infection.

Avacopan (a C5a receptor inhibitor) was investigated in a randomized trial as an alternative to glucocorticoids in patients receiving induction with either cyclophosphamide or rituximab. At 52 weeks, sustained remission was higher in those who received avacopan as compared to prednisone with a similar rate of serious adverse events. Although glucocorticoids were given within the first few weeks to most patients receiving avacopan, glucocorticoid exposure in the avacopan group remained markedly less than those randomized to the prednisone treatment arm. This supported that glucocorticoids can be rapidly withdrawn in patients with severe active disease receiving avacopan together with either rituximab or cyclophosphamide.

In patients presenting with disease that is life-threatening, methylprednisolone 1000 mg daily for 3 days has been used. Adjunctive plasma exchange was found to provide no added benefit in reducing the composite outcome of end-stage renal disease or death in a large, randomized trial. Whether it may still play a role in selected patients with the most fulminant disease remains controversial. Although a low number of patients in this trial were enrolled with alveolar hemorrhage requiring mechanical ventilation, a retrospective study also showed no benefit. From a meta-analysis, patients with active glomerulonephritis and serum creatinine >5.7 mg/dL who received plasma exchange had improvement in renal function but an increased risk of serious infection. Plasma exchange should be used in patients with granulomatosis with polyangiitis or microscopic polyangiitis who are also positive for antiglomerular basement membrane autoantibody (Chap. 326). When plasma

exchange is used concurrently with rituximab, these treatments must be separated by at least 48 h to avoid removal of rituximab.

CYCLOPHOSPHAMIDE INDUCTION FOR SEVERE DISEASE

Daily cyclophosphamide combined with glucocorticoids was the first regimen proven to effectively induce remission and prolong survival. Cyclophosphamide is given in doses of 2 mg/kg per day orally, but because it is renally eliminated, dosage reduction should be considered in patients with renal insufficiency. Although we continue to favor the use of daily cyclophosphamide, a randomized trial found IV cyclophosphamide 15 mg/kg, three infusions given every 2 weeks, then every 3 weeks thereafter, to have a similar rate of remission but higher frequency of relapse compared to cyclophosphamide 2 mg/kg daily given for 3 months followed by 1.5 mg/kg daily. Although leukopenia occurred more often with daily cyclophosphamide, this was likely related to a reduced frequency of blood count monitoring after the first month.

RITUXIMAB INDUCTION FOR SEVERE DISEASE

Rituximab (anti-CD20) has been of proven effectiveness for the treatment of granulomatosis with polyangiitis and microscopic polyangiitis. In two randomized trials that enrolled patients with severe active granulomatosis with polyangiitis or microscopic polyangiitis, rituximab 375 mg/m^2 once a week for 4 weeks in combination with glucocorticoids was found to be as effective as cyclophosphamide with glucocorticoids for inducing disease remission. In the trial that also enrolled patients with relapsing disease, rituximab was found to be statistically superior to cyclophosphamide. Although rituximab does not have the bladder toxicity or infertility risks of cyclophosphamide, in both randomized trials, the rate of adverse events was similar in the rituximab and cyclophosphamide arms.

The decision about whether to utilize cyclophosphamide or rituximab for remission induction must be individually based. Factors to consider include disease severity, whether the patient has newly diagnosed or relapsing disease, medication contraindications, and individual patient factors particularly fertility concerns and risk factors for toxicity. In patients with rapidly progressive glomerulonephritis with a creatinine >4.0 mg/dL or pulmonary hemorrhage requiring mechanical ventilation, daily cyclophosphamide and glucocorticoids may be favored.

There has been no evidence to date that using cyclophosphamide and rituximab together for induction is more efficacious, and combined use raises concern for additive toxicity, particularly infection. However, in instances of toxicity or rare occurrences of inefficacy, there may be a need to switch from cyclophosphamide to rituximab or vice versa.

REMISSION MAINTENANCE OF SEVERE DISEASE

When cyclophosphamide is given for induction, it should be stopped after 3–6 months and switched to another agent for remission maintenance. Medications used in this setting with which there has been published experience from randomized trials are rituximab, azathioprine, methotrexate, and mycophenolate mofetil. A lower rate of relapse was seen with rituximab given at 500 mg for two doses followed by 500 mg every 6 months when compared to azathioprine 2 mg/kg per day. In a randomized trial comparing methotrexate to azathioprine for remission maintenance, similar rates of toxicity and relapse were seen. Methotrexate is administered orally or subcutaneously at a starting dose of 15 mg/week, which is increased by 2.5 mg every 2 weeks up to a dosage of 20–25 mg/week. In patients who are unable to receive methotrexate or azathioprine or who have experienced relapse on such treatment, mycophenolate mofetil 1000 mg twice a day may also sustain remission, but it is associated with a higher rate of relapse compared to azathioprine.

For patients who receive rituximab for remission induction, a randomized trial found that rituximab had a lower rate of relapse compared to azathioprine. Although rituximab maintenance doses have not been directly compared, use of 1000 mg every 4 months in this trial was not found to be associated with a longer length of sustained remission after discontinuation.

The optimal duration of maintenance therapy is uncertain. With regard to glucocorticoids, it has been unclear whether maintaining patients on prednisone 5 mg/d has greater risks or benefits. Maintenance therapy with azathioprine, methotrexate, or mycophenolate mofetil is usually given for a minimum of 2 years. Because there is evidence that the risk of relapse is higher once maintenance medication has been stopped, the decision is individualized regarding whether to continue treatment or taper these agents over a 6- to 12-month period until discontinuation. Patients with significant organ damage or a history of relapse may benefit from longer-term maintenance therapy. Although rituximab has been found to have a lower relapse rate, studies have similarly shown that relapses occur once treatment is discontinued. Longer term use of rituximab can be associated with hypogammaglobulinemia such that the decision for how long to continue this agent beyond 2 years must be weighed in each patient.

REMISSION INDUCTION AND MAINTENANCE OF NONSEVERE DISEASE

For patients whose disease is not immediately organ- or life-threatening, methotrexate or mycophenolate mofetil together with glucocorticoids, often initiated at a lower dose, may be given to induce and then maintain remission. Rituximab can also be used in this setting weighing the risks and benefits. Treatment with cyclophosphamide is rarely, if ever, justified for the treatment of nonsevere granulomatosis with polyangiitis. There have been no published studies to date with the use of avacopan in nonsevere disease.

OTHER BIOLOGIC AGENTS

Etanercept (TNF inhibitor) was not found to sustain remission when used adjunctively to standard therapy and should not be used in granulomatosis with polyangiitis. Belimumab (anti-B lymphocyte stimulator) was examined as an adjunctive therapy to azathioprine for remission maintenance but showed no added benefit in reducing the risk of relapse. Abatacept (CTLA4-Ig) was examined in a randomized trial in patients with nonsevere relapsing disease where it did not reduce the risk of relapse, disease worsening, or failure to achieve remission.

ORGAN-SPECIFIC TREATMENT

Not all manifestations of granulomatosis with polyangiitis require or respond to immunosuppressive therapy, and differentiation of active disease from damage is necessary. As sinus disease can disrupt the mucociliary barrier, patients should be instructed on the use of local care with moisturization and humidification. Although certain reports have indicated that TMP-SMX may be of benefit in the treatment of granulomatosis with polyangiitis isolated to the sinonasal tissues, it should never be used alone to treat active granulomatosis with polyangiitis involving other organs. Subglottic stenosis can often scar and responds optimally to nonmedical intervention with dilation and glucocorticoid injection.

MICROSCOPIC POLYANGIITIS

DEFINITION

The term *microscopic polyarteritis* was introduced into the literature by Davson in 1948 in recognition of the presence of glomerulonephritis in patients with polyarteritis nodosa. In 1992, the Chapel Hill Consensus Conference on the Nomenclature of Systemic Vasculitis adopted the term *microscopic polyangiitis* to connote a necrotizing vasculitis with few or no immune complexes affecting small vessels (capillaries, venules, or arterioles). Glomerulonephritis is very common in microscopic polyangiitis, and pulmonary capillaritis often occurs. The absence of granulomatous inflammation in microscopic polyangiitis is said to differentiate it from granulomatosis with polyangiitis.

INCIDENCE AND PREVALENCE

The incidence of microscopic polyangiitis is estimated to be 3–5/100,000. The mean age of onset is ~57 years, and males are slightly more frequently affected than females.

PATHOLOGY AND PATHOGENESIS

Microscopic polyangiitis has a predilection to involve capillaries and venules in addition to small- and medium-sized arteries. Immunohistochemical staining reveals a paucity of immunoglobulin deposition in the vascular lesion of microscopic polyangiitis, suggesting that immune-complex formation does not play a role in the pathogenesis of this syndrome. The renal lesion seen in microscopic polyangiitis is histologically identical to that of granulomatosis with polyangiitis. Like granulomatosis with polyangiitis, microscopic polyangiitis is highly associated with ANCA, which may play a role in pathogenesis of this syndrome (see above).

CLINICAL AND LABORATORY MANIFESTATIONS

Because of its predilection to involve the small vessels, microscopic polyangiitis and granulomatosis with polyangiitis share similar clinical features. Disease onset may be gradual, with initial symptoms of fever, weight loss, and musculoskeletal pain; however, it is often acute. Glomerulonephritis occurs in at least 79% of patients and can be rapidly progressive, leading to renal failure. Hemoptysis may be the first symptom of alveolar hemorrhage, which occurs in 12% of patients. Other manifestations include mononeuritis multiplex and gastrointestinal tract and cutaneous vasculitis. Upper airway disease and pulmonary nodules are not typically found in microscopic polyangiitis and, if present, suggest granulomatosis with polyangiitis.

Features of inflammation may be seen, including an elevated ESR and/or CRP, anemia, leukocytosis, and thrombocytosis. ANCA are present in 75% of patients with microscopic polyangiitis, with antimyeloperoxidase antibodies being the predominant antigen association.

DIAGNOSIS

The diagnosis is based on histologic evidence of vasculitis or pauci-immune glomerulonephritis in a patient with compatible clinical features of multisystem disease. Although microscopic polyangiitis is strongly ANCA-associated, tissue biopsy should continue to be pursued in patients who do not have a clinically compatible picture.

TREATMENT

Microscopic Polyangiitis

The 5-year survival rate for patients with treated microscopic polyangiitis is 74%, with disease-related mortality occurring from alveolar hemorrhage or gastrointestinal, cardiac, or renal disease. Studies on treatment have come from trials that have included patients with granulomatosis with polyangiitis or microscopic polyangiitis. Currently, the treatment approach for microscopic polyangiitis is the same as is used for granulomatosis with polyangiitis (see "Granulomatosis with Polyangiitis" for a detailed description of this therapeutic regimen). Disease relapse has been observed in at least 34% of patients. Treatment for such relapses would be based on site and severity of disease.

EOSINOPHILIC GRANULOMATOSIS WITH POLYANGIITIS (CHURG-STRAUSS)

DEFINITION

Eosinophilic granulomatosis with polyangiitis was described in 1951 by Churg and Strauss and is characterized by asthma, peripheral and tissue eosinophilia, extravascular granuloma formation, and vasculitis of multiple organ systems.

INCIDENCE AND PREVALENCE

Eosinophilic granulomatosis with polyangiitis is an uncommon disease with an estimated annual incidence of 1–3 per million. The disease can occur at any age with the possible exception of infants. The mean age of onset is 48 years, with a female-to-male ratio of 1.2:1.

PATHOLOGY AND PATHOGENESIS

The necrotizing vasculitis of eosinophilic granulomatosis with polyangiitis involves small- and medium-sized muscular arteries, capillaries, veins, and venules. A characteristic histopathologic feature of eosinophilic granulomatosis with polyangiitis is granuloma that may be present in the tissues or even within the walls of the vessels themselves. These are usually associated with infiltration of the tissues with eosinophils. This process can occur in any organ in the body; lung involvement is predominant, with skin, cardiovascular system, kidney, peripheral nervous system, and gastrointestinal tract also commonly involved. Although the precise pathogenesis of this disease is uncertain, its strong association with asthma and its clinicopathologic manifestations, including eosinophilia, granuloma, and vasculitis, point to aberrant immunologic phenomena.

CLINICAL AND LABORATORY MANIFESTATIONS

Patients with eosinophilic granulomatosis with polyangiitis often exhibit nonspecific manifestations such as fever, malaise, anorexia, and weight loss, which are characteristic of a multisystem disease. The pulmonary findings in eosinophilic granulomatosis with polyangiitis dominate the clinical picture with asthmatic attacks and the presence of pulmonary infiltrates. Mononeuritis multiplex is the second most common manifestation and occurs in up to 72% of patients. Allergic rhinitis and sinusitis develop in up to 61% of patients and are often observed early in the course of disease. Clinically recognizable heart disease with myocarditis, pericarditis, endocarditis, or coronary vasculitis occurs in ~14% of patients and is an important cause of mortality. Skin lesions occur in ~51% of patients and include purpura in addition to cutaneous and subcutaneous nodules. Renal disease in eosinophilic granulomatosis with polyangiitis is less common than that of granulomatosis with polyangiitis and microscopic polyangiitis.

The characteristic laboratory finding in virtually all patients with eosinophilic granulomatosis with polyangiitis is a striking eosinophilia, which reaches levels >1000 cells/μL in >80% of patients. Evidence of inflammation as evidenced by elevated ESR and/or CRP, fibrinogen, or α_2-globulins can be found in 81% of patients. The other laboratory findings reflect the organ systems involved. Approximately 48% of patients with eosinophilic granulomatosis with polyangiitis have circulating ANCA that is usually antimyeloperoxidase.

DIAGNOSIS

Although the diagnosis of eosinophilic granulomatosis with polyangiitis is optimally made by biopsy in a patient with the characteristic clinical manifestations (see above), histologic confirmation can be challenging because the pathognomonic features often do not occur simultaneously. In order to be diagnosed with eosinophilic granulomatosis with polyangiitis, a patient should have evidence of asthma, peripheral blood eosinophilia, and clinical features consistent with vasculitis.

TREATMENT

Eosinophilic Granulomatosis with Polyangiitis

The prognosis of untreated eosinophilic granulomatosis with polyangiitis is poor, with a reported 5-year survival of 25%. With treatment, prognosis is favorable, with one study finding a 78-month actuarial survival rate of 72%. Myocardial involvement is the most frequent cause of death and is responsible for 39% of patient mortality. Echocardiography should be performed in all newly diagnosed patients because this may influence therapeutic decisions.

Glucocorticoids alone appear to be effective in many patients. Dosage tapering is often limited by asthma, with asthma often persisting after clinical recovery from vasculitis. In patients who present with fulminant multisystem disease, particularly cardiac involvement, the treatment of choice is daily cyclophosphamide and prednisone followed by azathioprine or methotrexate (see "Granulomatosis with Polyangiitis" for a detailed description of this therapeutic regimen). Use of rituximab and prednisone can be considered, particularly in ANCA-positive patients who have glomerulonephritis or other features of severe small-vessel vasculitis.

Mepolizumab (anti-IL-5 antibody) 300 mg given subcutaneously once a month was studied in a randomized trial and found

to be more effective than placebo, with a higher number of weeks in remission (28% vs 3%) and a higher proportion of patients in remission (32% vs 3%). Patients with life-threatening eosinophilic granulomatosis with polyangiitis were excluded from this trial, and mepolizumab should not be used for the treatment of severe disease. Mepolizumab may have a particularly beneficial role in the setting of relapsing or resistant asthma requiring glucocorticoids, sinus disease, mild to moderate eosinophilic disease features, or mild vasculitis. In a recent study, benralizumab, which also inhibits IL-5, demonstrated noninferior rates of remission compared to mepolizumab in patients with relapsing or refractory, non-life-threatening eosinophilic granulomatosis with polyangiitis.

POLYARTERITIS NODOSA

DEFINITION

Polyarteritis nodosa was described in 1866 by Kussmaul and Maier. It is a multisystem, necrotizing vasculitis of small- and medium-sized muscular arteries characteristically involving the renal and visceral arteries. Polyarteritis nodosa does not involve pulmonary arteries, although bronchial vessels may be involved; glomerulonephritis, granuloma, and significant eosinophilia are not seen.

INCIDENCE AND PREVALENCE

It is difficult to establish an accurate incidence of polyarteritis nodosa because previous reports have included microscopic polyangiitis as well as other related vasculitides. Polyarteritis nodosa, as currently defined, is felt to be a very uncommon disease.

PATHOLOGY AND PATHOGENESIS

The vascular lesion in polyarteritis nodosa is a necrotizing inflammation of small- and medium-sized muscular arteries. The lesions are segmental and tend to involve bifurcations and branchings of arteries. They may spread circumferentially to involve adjacent veins. However, involvement of venules is not seen in polyarteritis nodosa and, if present, suggests microscopic polyangiitis (see below). In the acute stages of disease, polymorphonuclear neutrophils infiltrate all layers of the vessel wall and perivascular areas, which results in intimal proliferation and degeneration of the vessel wall. Mononuclear cells infiltrate the area as the lesions progress to the subacute and chronic stages. Fibrinoid necrosis of the vessels ensues with compromise of the lumen, thrombosis, infarction of the tissues supplied by the involved vessel, and, in some cases, hemorrhage. As the lesions heal, there is collagen deposition, which may lead to further occlusion of the vessel lumen. Aneurysmal dilations up to 1 cm in size along the involved arteries are characteristic.

Multiple organ systems are involved, and the clinicopathologic findings reflect the degree and location of vessel involvement and the resulting ischemic changes. As mentioned above, pulmonary arteries are not involved, and bronchial artery involvement is uncommon. The pathology in the kidney is that of arteritis without glomerulonephritis. In patients with significant hypertension, typical pathologic features of glomerulosclerosis may be seen. In addition, pathologic sequelae of hypertension may be found elsewhere in the body.

The presence of a polyarteritis nodosa–like vasculitis in patients with hepatitis B together with the isolation of circulating immune complexes composed of hepatitis B antigen and immunoglobulin and the demonstration by immunofluorescence of hepatitis B antigen, IgM, and complement in the blood vessel walls strongly suggest the role of immunologic phenomena in the pathogenesis of this disease. A polyarteritis nodosa–like vasculitis has also been reported in patients with hepatitis C. Hairy cell leukemia can be associated with polyarteritis nodosa; the pathogenic mechanisms of this association are unclear.

A polyarteritis nodosa–like vasculitis has been described in conjunction with deficiency of adenosine deaminase type 2 (DADA2). Patients with DADA2 usually present in childhood with a variable pattern of clinical features and vascular pathology that is responsive to TNF inhibitors. As this differs from the usual treatment for polyarteritis nodosa, DADA2 should be considered in patients with suggestive clinical features, particularly those with early-onset disease.

TABLE 375-6 Clinical Manifestations Related to Organ System Involvement in Polyarteritis Nodosa

ORGAN SYSTEM	PERCENT INCIDENCE	CLINICAL MANIFESTATIONS
Renal	60	Renal failure, hypertension
Musculoskeletal	64	Arthritis, arthralgia, myalgia
Peripheral nervous system	51	Peripheral neuropathy, mononeuritis multiplex
Gastrointestinal tract	44	Abdominal pain, nausea and vomiting, bleeding, bowel infarction and perforation, cholecystitis, hepatic infarction, pancreatic infarction
Skin	43	Rash, purpura, nodules, cutaneous infarcts, livedo reticularis, Raynaud's phenomenon
Cardiac	36	Congestive heart failure, myocardial infarction, pericarditis
Genitourinary	25	Testicular, ovarian, or epididymal pain
Central nervous system	23	Cerebral vascular accident, altered mental status, seizure

Source: Reproduced with permission from TR Cupps, AS Fauci: The vasculitides. Major Probl Intern Med 21:1, 1981.

CLINICAL AND LABORATORY MANIFESTATIONS

Nonspecific signs and symptoms are the hallmarks of polyarteritis nodosa. Fever, weight loss, and malaise are present in over one-half of cases. Patients usually present with vague symptoms such as weakness, malaise, headache, abdominal pain, and myalgias that can rapidly progress to a fulminant illness. Specific complaints related to the vascular involvement within a particular organ system may also dominate the presenting clinical picture as well as the entire course of the illness (Table 375-6). Renal involvement most commonly manifests as hypertension, renal insufficiency, or hemorrhage due to microaneurysms.

There are no diagnostic serologic tests for polyarteritis nodosa. In >75% of patients, the leukocyte count is elevated with a predominance of neutrophils. Eosinophilia is rare and, when present at high levels, suggests the diagnosis of eosinophilic granulomatosis with polyangiitis. The anemia of chronic disease may be seen, and an elevated ESR and/or CRP is almost always present. Other laboratory findings reflect the particular organ involved. Hypergammaglobulinemia may be present, and all patients should be screened for hepatitis B and C. ANCA are rarely found.

DIAGNOSIS

The diagnosis of polyarteritis nodosa is based on the demonstration of characteristic findings of vasculitis on biopsy material of involved organs. Biopsy of symptomatic organs such as nodular skin lesions, painful testes, and nerve/muscle provides the highest diagnostic yields. In the absence of easily accessible tissue for biopsy, the arteriographic demonstration of involved vessels, particularly in the form of aneurysms of small- and medium-sized arteries in the renal, hepatic, and visceral vasculature, is sufficient to make the diagnosis. This should consist of a catheter-directed dye arteriogram because magnetic resonance and computed tomography arteriograms do not have sufficient resolution at the current time to visualize the affected vessels. Aneurysms of vessels are not pathognomonic of polyarteritis nodosa; furthermore, aneurysms may not always be present, and arteriographic findings may be limited to stenotic segments and obliteration of vessels.

TREATMENT

Polyarteritis Nodosa

The prognosis of untreated polyarteritis nodosa is extremely poor, with a reported 5-year survival rate between 10 and 20%. Death usually results from gastrointestinal complications, particularly bowel infarcts and perforation, and cardiovascular causes. Intractable

hypertension often compounds dysfunction in other organ systems, such as the kidneys, heart, and CNS, leading to additional late morbidity and mortality. The combination of prednisone and cyclophosphamide has been found to significantly improve the survival rate (see "Granulomatosis with Polyangiitis" for a description of this therapeutic regimen). In less severe cases, glucocorticoids alone have resulted in disease remission. Treatment of hypertension can lessen vascular complications. Following remission, relapse has been estimated to occur in 10–20% of patients. In patients with hepatitis B or C who have a polyarteritis nodosa–like vasculitis, antiviral therapy is an essential part of management, with immunosuppression being given concurrently for severe vasculitis and then withdrawn once the vasculitis is controlled. Plasma exchange has been used in some series of hepatitis virus-associated polyarteritis nodosa.

GIANT CELL ARTERITIS AND POLYMYALGIA RHEUMATICA

DEFINITION

Giant cell arteritis, historically referred to as *temporal arteritis*, is an inflammation of medium- and large-sized arteries. It characteristically involves one or more branches of the carotid artery, particularly the temporal artery. However, it is a systemic disease that can involve arteries in multiple locations, particularly the aorta and its main branches.

Giant cell arteritis is closely associated with *polymyalgia rheumatica*, which is characterized by stiffness, aching, and pain in the muscles of the neck, shoulders, lower back, hips, and thighs. Most commonly, polymyalgia rheumatica occurs in isolation, but it may be seen in 40–50% of patients with giant cell arteritis. In addition, ~10–20% of patients who initially present with features of isolated polymyalgia rheumatica later go on to develop giant cell arteritis. A careful history and physical examination at initial and subsequent visits should be performed in patients with polymyalgia rheumatica to look for features suggestive of giant cell arteritis. This strong clinical association together with data from pathophysiologic studies has supported that giant cell arteritis and polymyalgia rheumatica represent differing clinical spectrums of a single disease process.

INCIDENCE AND PREVALENCE

Giant cell arteritis occurs almost exclusively in individuals aged >50 years. It is more common in women than in men and is rare in blacks. The incidence of giant cell arteritis varies widely in different studies and in different geographic regions. A high incidence has been found in Scandinavia and in regions of the United States with large Scandinavian populations, compared to a lower incidence in southern Europe. The annual incidence rates in individuals aged ≥50 years range from 6.9 to 32.8 per 100,000 population. Familial aggregation has been reported, as has an association with HLA-DR4. In addition, genetic linkage studies have demonstrated an association of giant cell arteritis with alleles at the HLA-DRB1 locus, particularly HLA-DRB1*04 variants. In Olmsted County, Minnesota, the annual incidence of polymyalgia rheumatica in individuals aged ≥50 years is 58.7 per 100,000 population.

PATHOLOGY AND PATHOGENESIS

Although the temporal artery is most frequently involved in giant cell arteritis, patients often have a systemic vasculitis of multiple medium- and large-sized arteries, which may go undetected. Histopathologically, the disease is a panarteritis with inflammatory mononuclear cell infiltrates within the vessel wall with frequent giant cell formation. There is proliferation of the intima and fragmentation of the internal elastic lamina. Pathophysiologic findings in organs result from the ischemia related to the involved vessels.

Experimental data support that giant cell arteritis is an antigen-driven disease in which activated T lymphocytes, macrophages, and dendritic cells play a critical role in pathogenesis. Sequence analysis of the T-cell receptor of tissue-infiltrating T cells in lesions of giant cell arteritis indicates restricted clonal expansion, suggesting the presence of an antigen residing in the arterial wall. Giant cell arteritis is believed to be initiated in the adventitia where CD4+ T cells enter through the vasa vasorum, become activated, and orchestrate macrophage differentiation. T cells recruited to vasculitic lesions in patients with giant cell arteritis produce predominantly IL-2 and IFN-γ, and the latter has been suggested to be involved in the progression to arteritis. Laboratory-based data demonstrate that at least two separate lineages of CD4 T cells—IFN-γ-producing T_H1 cells and IL-17-producing T_H17 cells—participate in vascular inflammation and may have differing levels of responsiveness to glucocorticoids.

CLINICAL AND LABORATORY MANIFESTATIONS

Giant cell arteritis is most commonly characterized clinically by the complex of fever, anemia, high ESR and/or CRP, and headaches in a patient aged >50 years. Four phenotypic manifestations can be seen including cranial arteritis, polymyalgia rheumatica, large-vessel disease, and features of systemic inflammation. These can occur together, in isolation, or at different times.

In patients with involvement of the cranial arteries, headache is the predominant symptom and may be associated with a tender, thickened, or nodular artery, which may pulsate early in the disease but may become occluded later. Scalp pain and claudication of the jaw and tongue may occur. A well-recognized and dreaded complication of giant cell arteritis, particularly in untreated patients, is ischemic optic neuropathy, which may lead to serious visual symptoms, including sudden blindness in some patients. However, most patients have complaints relating to the head or eyes before visual loss. Attention to such symptoms with institution of appropriate therapy (see below) lessens the risk of this complication. Other cranial ischemic complications include strokes and scalp or tongue infarction.

Up to one-third of patients can have large-vessel disease that can be the primary presentation of giant cell arteritis or can emerge at a later point in patients who have had previous cranial arteritis features or polymyalgia rheumatica. Manifestations of large-vessel disease can include subclavian artery stenosis that can present as arm claudication or aortic aneurysms involving the thoracic and to a lesser degree the abdominal aorta, which carry risks of rupture or dissection.

Clinical features of systemic inflammation can include malaise, fatigue, anorexia, weight loss, and sweats. Laboratory findings can also support an inflammatory process. An elevated ESR and/or CRP will be seen in most patients. Therapeutic blockade of IL-6 signaling prevents the hepatic production of CRP and other acute-phase proteins like ESR. These values will therefore normalize in patients who are treated with an IL-6 inhibitor, eliminating the ability to utilize CRP and ESR in monitoring disease activity or infection assessment in this setting. Other laboratory features include a normochromic or slightly hypochromic anemia. Liver function abnormalities are common, particularly increased alkaline phosphatase levels. Increased levels of IgG and complement have been reported.

DIAGNOSIS

The diagnosis of giant cell arteritis can often be suggested clinically by the demonstration of the complex of fever, anemia, and high ESR and/or CRP with or without symptoms of polymyalgia rheumatica in a patient >50 years old. The diagnosis can be confirmed by biopsy of the temporal artery but may not be positive in all patients due to patchy histologic findings. Since involvement of the vessel may be segmental, positive yield is increased by obtaining a biopsy segment of 3–5 cm together with serial sectioning of biopsy specimens. Ultrasonography of the temporal arteries alone or in combination with the axillary arteries demonstrating a noncompressible "halo" sign has been used in supporting the diagnosis. Therapy should not be delayed pending the performance of diagnostic studies. In this regard, it has been reported that temporal artery biopsies may show vasculitis even after ~14 days of glucocorticoid therapy. A dramatic clinical response to a trial of glucocorticoid therapy can further support the diagnosis.

Large-vessel disease may be suggested by symptoms and findings on physical examination such as diminished pulses or bruits. It is confirmed by vascular imaging, most commonly through magnetic

resonance or computed tomography. Positron emission tomography has become increasingly investigated, although its role in diagnosis and monitoring remains unclear.

Isolated polymyalgia rheumatica is a clinical diagnosis made by the presence of typical symptoms of stiffness, aching, and pain in the muscles of the hip and shoulder girdle, an increased ESR and/or CRP, the absence of clinical features suggestive of giant cell arteritis, and a prompt therapeutic response to low-dose prednisone. Polymyalgia rheumatica can be associated with a peripheral arthritis that can mimic rheumatoid arthritis (Chap. 370). Rheumatoid factor and anti–cyclic citrullinated peptide (CCP) should be negative. In patients who develop a worsening pattern of peripheral arthritis, the potential for a seronegative rheumatoid arthritis or other inflammatory arthropathy should be considered. Levels of enzymes indicative of muscle damage such as serum creatine kinase are not elevated.

TREATMENT

Giant Cell Arteritis

Acute disease–related mortality directly from giant cell arteritis is uncommon, with fatalities occurring from cerebrovascular events or myocardial infarction. However, patients are at risk of late mortality from aortic aneurysm rupture or dissection as patients with giant cell arteritis are 18 times more likely to develop thoracic aortic aneurysms than the general population.

The goals of treatment in giant cell arteritis are to reduce symptoms and, most importantly, to prevent visual loss. The treatment approach for cranial arteritis and large-vessel disease in giant cell arteritis is currently the same.

Giant cell arteritis and its associated symptoms are responsive to glucocorticoid therapy. Treatment should begin with prednisone 40–60 mg/d for ~1 month, followed by a gradual tapering. When ocular signs and symptoms occur, consideration should be given for the use of methylprednisolone 1000 mg daily for 3 days to protect remaining vision. Although the optimal duration of glucocorticoid therapy has not been established, most series have found that patients require treatment for ≥2 years. Symptom recurrence during prednisone tapering develops in 60–85% of patients with giant cell arteritis, requiring a dosage increase. For patients treated with prednisone alone, the ESR and/or CRP can serve as an indicator of inflammatory disease activity in monitoring and tapering therapy and can be used to guide the tapering schedule. However, minor increases in the ESR and/or CRP can occur as glucocorticoids are being tapered and do not necessarily reflect an exacerbation of arteritis, particularly if the patient remains symptom-free. Under these circumstances, the tapering should continue with caution. An increase in ESR and/or CRP can also occur for other reasons, including infection. Glucocorticoid toxicity occurs in 35–65% of patients and represents an important cause of patient morbidity.

Tocilizumab (anti-IL-6 receptor) 162 mg given subcutaneously once every week or once every other week combined with a 26-week prednisone taper was found to be superior to prednisone alone in sustaining glucocorticoid-free remission in a randomized trial. The decision about when to use tocilizumab in giant cell arteritis is individually based, taking into account comorbidities, glucocorticoid toxicity, and the side effects of tocilizumab. Pharmacokinetic studies supported that tocilizumab 6 mg/kg given intravenously every 4 weeks could also be used as a treatment option in giant cell arteritis.

The use of methotrexate as a glucocorticoid-sparing agent was examined in two randomized placebo-controlled trials that reached conflicting conclusions. It may be considered in select patients with glucocorticoid toxicity who are unable to take or are intolerant of tocilizumab.

Abatacept (CTLA4-Ig) was examined in a small randomized trial in giant cell arteritis and demonstrated greater efficacy than glucocorticoids alone. Infliximab, a monoclonal antibody to TNF, was studied in a randomized trial and was not found to provide benefit.

Aspirin 81 mg daily has been found in retrospective studies to reduce the occurrence of cranial ischemic complications in giant cell arteritis, and adjunctive use should be considered in patients who do not have contraindications.

Polymyalgia Rheumatica

Patients with isolated polymyalgia rheumatica respond promptly to prednisone given at a dose of 10–20 mg/d. Similar to giant cell arteritis, the ESR and/or CRP can serve as a useful indicator in monitoring prednisone reduction in those treated with glucocorticoids alone. Recurrent polymyalgia symptoms develop in the majority of patients during prednisone tapering.

Sarilumab (anti-IL-6 receptor) was found to be effective in a randomized trial of patients with glucocorticoid-resistant polymyalgia rheumatica who relapsed on prednisone ≥7.5 mg/d. In this trial, sarilumab 200 mg given subcutaneously every 2 weeks plus a 14-week glucocorticoid taper was associated with a higher rate of sustained remission compared to glucocorticoids alone. As most patients with polymyalgia rheumatica can be successfully treated with glucocorticoids alone, use of sarilumab should be restricted to those who have had an inadequate response to glucocorticoids or who relapse with a glucocorticoid taper.

One study of methotrexate found that this reduced the prednisone dose on average by only 1 mg and did not decrease prednisone-related side effects. A randomized trial in polymyalgia rheumatica did not find infliximab to lessen relapse or glucocorticoid requirements.

TAKAYASU ARTERITIS

DEFINITION

Takayasu arteritis is an inflammatory disease of large-sized arteries characterized by a strong predilection for the aortic arch and its branches.

INCIDENCE AND PREVALENCE

Takayasu arteritis is an uncommon disease with an estimated annual incidence rate of 1.2–2.6 cases per million. It is most prevalent in adolescent girls and young women. Although it is more common in Asia, it is neither racially nor geographically restricted.

PATHOLOGY AND PATHOGENESIS

The disease involves large-sized arteries, with a strong predilection for the aortic arch and its branches; the pulmonary artery may also be involved. The most commonly affected arteries seen by arteriography are listed in Table 375-7. The involvement of the major branches of

TABLE 375-7 Frequency of Arteriographic Abnormalities and Potential Clinical Manifestations of Arterial Involvement in Takayasu Arteritis

ARTERY	PERCENTAGE OF ARTERIOGRAPHIC ABNORMALITIES	POTENTIAL CLINICAL MANIFESTATIONS
Subclavian	93	Arm claudication, Raynaud's phenomenon
Common carotid	58	Visual changes, syncope, transient ischemic attacks, stroke
Abdominal aorta[a]	47	Abdominal pain, nausea, vomiting
Renal	38	Hypertension, renal failure
Aortic arch or root	35	Aortic insufficiency, congestive heart failure
Vertebral	35	Visual changes, dizziness
Coeliac axis[a]	18	Abdominal pain, nausea, vomiting
Superior mesenteric[a]	18	Abdominal pain, nausea, vomiting
Iliac	17	Leg claudication
Pulmonary	10–40	Atypical chest pain, dyspnea
Coronary	<10	Chest pain, myocardial infarction

[a]Arteriographic lesions at these locations are usually asymptomatic but may potentially cause these symptoms.

Source: G Kerr et al: Ann Intern Med 120:919, 1994.

the aorta is much more marked at their origin than distally. The disease is a panarteritis with inflammatory mononuclear cell infiltrates and occasionally giant cells. There are marked intimal proliferation and fibrosis, scarring and vascularization of the media, and disruption and degeneration of the elastic lamina. The vasa vasorum are frequently involved. Narrowing of the lumen occurs with or without thrombosis. Pathologic changes in various organs typically reflect reduced blood flow through these vascular stenoses. Aneurysms can also occur due to weakening of the vessel wall.

Immunopathogenic mechanisms, the precise nature of which is uncertain, are suspected in this disease. As with several of the vasculitis syndromes, circulating immune complexes have been demonstrated, but their pathogenic significance is unclear.

CLINICAL AND LABORATORY MANIFESTATIONS

Takayasu arteritis is a systemic disease with generalized as well as vascular symptoms. The generalized symptoms include malaise, fever, night sweats, arthralgias, anorexia, and weight loss, which may occur months before vessel involvement is apparent. These symptoms may merge into those related to vascular compromise and organ ischemia. Pulses are commonly absent in the involved vessels, particularly the subclavian artery. The frequency of arteriographic abnormalities and the potentially associated clinical manifestations are listed in Table 375-7. Hypertension occurs in 32–93% of patients and contributes to renal, cardiac, and cerebral injury.

Characteristic laboratory findings include an elevated ESR and/or CRP, mild anemia, and elevated immunoglobulin levels.

DIAGNOSIS

The diagnosis of Takayasu arteritis should be suspected strongly in a young woman who develops a decrease or absence of peripheral pulses, a discrepancy in blood pressure between arms, or arterial bruits. The diagnosis is confirmed by the characteristic pattern on arteriography, which includes irregular vessel walls, stenosis, poststenotic dilation, aneurysm formation, occlusion, and evidence of increased collateral circulation. Complete imaging of the aorta and its major branches by magnetic resonance or computed tomography arteriography should be obtained to fully delineate the distribution and degree of arterial disease. Because of the involvement of the large vessels, tissue is rarely available or necessary as a means of diagnosis and obtained only if vascular surgery is necessary. IgG4-related disease **(Chap. 380)** is a potential cause of aortitis and periaortitis that is histologically differentiated from Takayasu arteritis by a dense lymphoplasmacytic infiltrate rich in IgG4-positive plasma cells, a storiform pattern of fibrosis, and obliterative phlebitis.

TREATMENT

Takayasu Arteritis

The long-term outcome of patients with Takayasu arteritis has varied widely between studies. Although two North American reports found overall survival to be ≥94%, the 5-year mortality rate from other studies has ranged from 0 to 35%. Disease-related mortality most often occurs from congestive heart failure, cerebrovascular events, myocardial infarction, aneurysm rupture, or renal failure. Even in the absence of life-threatening disease, Takayasu arteritis can be associated with significant morbidity. The course of the disease is variable, and although spontaneous remissions may occur, Takayasu arteritis is most often chronic and relapsing. Although glucocorticoids, given as prednisone 40–60 mg/d followed by a taper, alleviate symptoms, there are no convincing studies that indicate that it increases survival. The combination of glucocorticoid therapy for acute signs and symptoms and an aggressive surgical and/or arterioplastic approach to stenosed vessels has markedly improved outcome and decreased morbidity by lessening the risk of stroke, correcting hypertension due to renal artery stenosis, and improving blood flow to ischemic viscera and limbs. Unless it is urgently required, surgical correction of stenosed arteries should be undertaken only when the vascular inflammatory process is well controlled with medical therapy.

In individuals who are refractory to or unable to taper glucocorticoids, methotrexate in doses up to 25 mg per week has been used with positive results. Retrospective series with anti-TNF therapies have shown benefit, but these agents have not been studied through randomized trials to determine efficacy.

Tocilizumab has been investigated in a randomized trial where it did not reach its primary efficacy endpoint, although it was found to be associated with glucocorticoid-sparing effects and improvements in well-being. Encouraging results have also been seen in retrospective studies such that the utility of this agent remains an active question. Abatacept was examined in a randomized trial in Takayasu arteritis but did not demonstrate efficacy beyond glucocorticoids alone.

IGA VASCULITIS (HENOCH-SCHÖNLEIN)

DEFINITION

IgA vasculitis (Henoch-Schönlein) is a small-vessel vasculitis characterized by palpable purpura (most commonly distributed over the buttocks and lower extremities), arthralgias, gastrointestinal signs and symptoms, and glomerulonephritis.

INCIDENCE AND PREVALENCE

IgA vasculitis is usually seen in children ages 4–7 years; however, the disease may also be seen in infants and adults. It is not a rare disease; in one series, it accounted for between 5 and 24 admissions per year at a pediatric hospital. The male-to-female ratio is 1.5:1. A seasonal variation with a peak incidence in spring has been noted.

PATHOLOGY AND PATHOGENESIS

The presumptive pathogenic mechanism for IgA vasculitis is immune-complex deposition. A number of inciting antigens have been suggested including upper respiratory tract infections, various drugs, foods, insect bites, and immunizations. IgA is the antibody class most often seen in the immune complexes and has been demonstrated in the renal biopsies of these patients.

CLINICAL AND LABORATORY MANIFESTATIONS

In pediatric patients, palpable purpura is seen in virtually all patients; most patients develop polyarthralgias in the absence of frank arthritis. Gastrointestinal involvement, which is seen in almost 70% of pediatric patients, is characterized by colicky abdominal pain usually associated with nausea, vomiting, diarrhea, or constipation, and is frequently accompanied by the passage of blood and mucus per rectum; bowel intussusception may occur. Renal involvement occurs in 10–50% of patients and is usually characterized by mild glomerulonephritis leading to proteinuria and microscopic hematuria, with red blood cell casts in the majority of patients; it usually resolves spontaneously without therapy. Progressive glomerulonephritis rarely develops. In adults, presenting symptoms are most frequently related to the skin and joints, while initial complaints related to the gut are less common. Although certain studies have found that renal disease is more frequent and more severe in adults, this has not been a consistent finding. However, the course of renal disease in adults may be more insidious and thus requires close follow-up. Myocardial involvement can occur in adults but is rare in children.

Laboratory studies generally show a mild leukocytosis, a normal platelet count, and occasionally eosinophilia. Serum complement components are normal, and IgA levels are elevated in about one-half of patients.

DIAGNOSIS

The diagnosis of IgA vasculitis is based on clinical signs and symptoms. Skin biopsy specimen can be useful in confirming leukocytoclastic vasculitis with IgA and C3 deposition by immunofluorescence. Renal biopsy is rarely needed for diagnosis but may provide prognostic information in some patients.

TREATMENT

IgA Vasculitis

The prognosis of IgA vasculitis is excellent. Mortality is exceedingly rare, and 1–5% of children progress to end-stage renal disease, although renal failure may be more common in adults. Most patients recover completely, and some do not require therapy. When glucocorticoids are required, prednisone, 1 mg/kg per day and tapered according to clinical response, has been shown to be useful in decreasing tissue edema, arthralgias, and abdominal discomfort; however, it has not proved beneficial in the treatment of skin or renal disease and does not appear to shorten the duration of active disease or lessen the chance of recurrence. Patients with rapidly progressive glomerulonephritis have been anecdotally reported to benefit from glucocorticoids used in combination with another immunosuppressive agent. Disease recurrences have been reported in 10–40% of patients.

CRYOGLOBULINEMIC VASCULITIS

DEFINITION

Cryoglobulins are cold-precipitable monoclonal or polyclonal immunoglobulins. Cryoglobulinemia may be associated with a systemic vasculitis characterized by palpable purpura, arthralgias, weakness, neuropathy, and glomerulonephritis. The most common association has been with hepatitis C, although cryoglobulinemia can be observed in association with a variety of underlying disorders including multiple myeloma, lymphoproliferative disorders, connective tissue diseases, infection, and liver disease and can be idiopathic.

INCIDENCE AND PREVALENCE

The incidence of cryoglobulinemic vasculitis has not been established. It has been estimated that 5% of patients with chronic hepatitis C will develop cryoglobulinemic vasculitis.

PATHOLOGY AND PATHOGENESIS

Skin biopsies in cryoglobulinemic vasculitis reveal an inflammatory infiltrate surrounding and involving blood vessel walls, with fibrinoid necrosis, endothelial cell hyperplasia, and hemorrhage. Deposition of immunoglobulin and complement is common. Abnormalities of uninvolved skin including basement membrane alterations and deposits in vessel walls may be found. Membranoproliferative glomerulonephritis is responsible for 80% of all renal lesions in cryoglobulinemic vasculitis.

The association between hepatitis C and cryoglobulinemic vasculitis has been supported by the high frequency of documented hepatitis C infection, the presence of hepatitis C RNA and anti–hepatitis C antibodies in serum cryoprecipitates, evidence of hepatitis C antigens in vasculitic skin lesions, and the effectiveness of antiviral therapy. Current evidence suggests that in the majority of cases, cryoglobulinemic vasculitis occurs when an aberrant immune response to hepatitis C infection leads to the formation of immune complexes consisting of hepatitis C antigens, polyclonal hepatitis C–specific IgG, and monoclonal IgM rheumatoid factor. The deposition of these immune complexes in blood vessel walls triggers an inflammatory cascade that results in cryoglobulinemic vasculitis.

CLINICAL AND LABORATORY MANIFESTATIONS

The most common clinical manifestations of cryoglobulinemic vasculitis are cutaneous vasculitis, arthritis, peripheral neuropathy, and glomerulonephritis. Renal disease develops in 10–30% of patients. Life-threatening rapidly progressive glomerulonephritis or vasculitis of the CNS, gastrointestinal tract, or heart occurs infrequently.

The presence of circulating cryoprecipitates is the fundamental finding in cryoglobulinemic vasculitis. Rheumatoid factor is almost always found and may be a useful clue to the disease when cryoglobulins are not detected. Hypocomplementemia occurs in 90% of patients. An elevated ESR and/or CRP and anemia occur frequently. Evidence for hepatitis C infection must be sought in all patients by testing for hepatitis C antibodies and hepatitis C RNA.

TREATMENT

Cryoglobulinemic Vasculitis

Acute mortality directly from cryoglobulinemic vasculitis is uncommon, but the presence of glomerulonephritis is a poor prognostic sign for overall outcome. In such patients, 15% progress to end-stage renal disease, with 40% later experiencing fatal cardiovascular disease, infection, or liver failure. As indicated above, the majority of cases are associated with hepatitis C infection. In such patients, treatment with antiviral therapy (Chap. 352) is first-line therapy for hepatitis C–associated cryoglobulinemic vasculitis, particularly given the efficacy of current hepatitis C therapies. Clinical improvement with antiviral therapy is dependent on the virologic response. Patients who clear hepatitis C from the blood have objective improvement in their vasculitis along with significant reductions in levels of circulating cryoglobulins, IgM, and rheumatoid factor. While transient improvement can be observed with glucocorticoids, a complete response is seen in only 7% of patients. Plasma exchange and cytotoxic agents have been used in anecdotal reports. These observations have not been confirmed, and such therapies carry significant risks. Randomized trials with rituximab in hepatitis C–associated cryoglobulinemic vasculitis showed evidence of benefit such that this should be considered in patients with active vasculitis either in combination with antiviral therapy or alone in patients who have relapsed through, are intolerant to, or have contraindications to antiviral agents.

SINGLE-ORGAN VASCULITIS

Single-organ vasculitis has been defined as vasculitis in arteries or veins of any size in a single organ that has no features that indicate that it is a limited expression of a systemic vasculitis. Examples include isolated aortitis, testicular vasculitis, vasculitis of the breast, isolated cutaneous vasculitis, and primary CNS vasculitis. In some instances, this may be discovered at the time of surgery such as orchiectomy for a testicular mass where there is concern for neoplasm that is found instead to be vasculitis. Some patients originally diagnosed with single-organ vasculitis may later develop additional manifestations of a more systemic disease. In instances where there is no evidence of systemic vasculitis and the affected organ has been removed in its entirety, the patient may be followed closely without immunosuppressive therapy. In other instances, such as primary CNS vasculitis, medical intervention is necessary.

IDIOPATHIC CUTANEOUS VASCULITIS

DEFINITION

The term *cutaneous vasculitis* is defined broadly as inflammation of the blood vessels of the dermis. Because of its heterogeneity, cutaneous vasculitis has been described by a variety of terms including *hypersensitivity vasculitis* and *cutaneous leukocytoclastic angiitis*. However, cutaneous vasculitis is not one specific disease but a manifestation that can be seen in a variety of settings. In >70% of cases, cutaneous vasculitis occurs either as part of a primary systemic vasculitis or as a secondary vasculitis related to an inciting agent or an underlying disease (see "Secondary Vasculitis," below). In the remaining 30% of cases, cutaneous vasculitis occurs idiopathically.

INCIDENCE AND PREVALENCE

Cutaneous vasculitis represents the most commonly encountered vasculitis in clinical practice. The exact incidence of idiopathic cutaneous vasculitis has not been determined due to the predilection for cutaneous vasculitis to be associated with an underlying process and the variability of its clinical course.

PATHOLOGY AND PATHOGENESIS

The typical histopathologic feature of cutaneous vasculitis is the presence of vasculitis of small vessels. Postcapillary venules are the most commonly involved vessels; capillaries and arterioles may be involved less frequently. This vasculitis is characterized by a *leukocytoclasis*, a

term that refers to the nuclear debris remaining from the neutrophils that have infiltrated in and around the vessels during the acute stages. In the subacute or chronic stages, mononuclear cells predominate; in certain subgroups, eosinophilic infiltration is seen. Erythrocytes often extravasate from the involved vessels, leading to palpable purpura. *Cutaneous arteritis* can also occur, which involves slightly larger-sized vessels within the dermis.

CLINICAL AND LABORATORY MANIFESTATIONS

The hallmark of idiopathic cutaneous vasculitis is the predominance of skin involvement. Skin lesions may appear typically as palpable purpura; however, other cutaneous manifestations of the vasculitis may occur, including macules, papules, vesicles, bullae, subcutaneous nodules, ulcers, and recurrent or chronic urticaria. The skin lesions may be pruritic or painful, with a burning or stinging sensation. Lesions most commonly occur in the lower extremities in ambulatory patients or in the sacral area in bedridden patients due to the effects of hydrostatic forces on the postcapillary venules. Edema may accompany certain lesions, and hyperpigmentation often occurs in areas of recurrent or chronic lesions.

There are no specific laboratory tests diagnostic of idiopathic cutaneous vasculitis. A mild leukocytosis with or without eosinophilia is characteristic, as is an elevated ESR and/or CRP. Laboratory studies should be aimed toward ruling out features to suggest an underlying disease or a systemic vasculitis.

DIAGNOSIS

The diagnosis of cutaneous vasculitis is made by the demonstration of vasculitis on biopsy. An important diagnostic principle in patients with cutaneous vasculitis is to search for an etiology of the vasculitis—be it an exogenous agent, such as a drug or an infection, or an endogenous underlying disease (Fig. 375-1). In addition, a careful history, physical, and laboratory examination should be performed to rule out the possibility of coexisting systemic vasculitis.

TREATMENT

Idiopathic Cutaneous Vasculitis

When an antigenic stimulus is recognized as the precipitating factor in the cutaneous vasculitis, it should be removed; if this is a microbe, appropriate antimicrobial therapy should be instituted. If the vasculitis is associated with another underlying disease, treatment of the latter often results in resolution of the former. In situations where disease is apparently self-limited, no therapy, except possibly symptomatic therapy, is indicated. When cutaneous vasculitis persists and when there is no evidence of an inciting agent, an associated disease, or an underlying systemic vasculitis, the decision to treat should be based on weighing the balance between the degree of symptoms and the risk of treatment. Some cases of idiopathic cutaneous vasculitis resolve spontaneously, whereas others remit and relapse. In patients with persistent vasculitis, a variety of therapeutic regimens have been tried with variable results. In general, the treatment of idiopathic cutaneous vasculitis has not been satisfactory. Fortunately, since the disease is generally limited to the skin, this lack of consistent response to therapy usually does not lead to a life-threatening situation. Agents with which there have been anecdotal reports of success include dapsone, colchicine, hydroxychloroquine, and nonsteroidal anti-inflammatory agents. Glucocorticoids are often used in the treatment of idiopathic cutaneous vasculitis. Therapy is usually instituted with the lowest effective dose of prednisone with rapid tapering to discontinuation. In cases that prove refractory to glucocorticoids, a trial of another immunosuppressive agent may be indicated. Patients with chronic vasculitis isolated to cutaneous venules rarely respond dramatically to any therapeutic regimen, and other immunosuppressive agents should be used only as a last resort in these patients. Methotrexate and azathioprine have been used in such situations in anecdotal reports. Cyclophosphamide should almost never be used for idiopathic cutaneous vasculitis because of the potential toxicity.

PRIMARY CENTRAL NERVOUS SYSTEM VASCULITIS

Primary CNS vasculitis is an uncommon clinicopathologic entity characterized by vasculitis restricted to the vessels of the CNS without other apparent systemic vasculitis. The inflammatory process is usually composed of mononuclear cell infiltrates with or without granuloma formation.

Patients may present with headaches, altered mental function, and focal neurologic defects. Systemic symptoms are generally absent. Devastating neurologic abnormalities may occur depending on the extent of vessel involvement. The diagnosis can be suggested by abnormal magnetic resonance imaging of the brain, an abnormal lumbar puncture, and/or demonstration of characteristic vessel abnormalities on arteriography **(Fig. 375-4)**, but it is confirmed by biopsy of the brain parenchyma and leptomeninges. In the absence of a brain biopsy, care should be taken not to misinterpret as true primary vasculitis arteriographic abnormalities that might actually be related to another cause. An important entity in the differential diagnosis is reversible cerebral vasoconstrictive syndrome, which typically presents with "thunderclap" headache and is associated with reversible arteriographic abnormalities that mimic primary CNS vasculitis. Other diagnostic considerations include infection, atherosclerosis, emboli, connective tissue disease, sarcoidosis, malignancy, and drug-associated causes. The prognosis of granulomatous primary CNS vasculitis is poor; however, some reports indicate that glucocorticoid therapy, alone or together with cyclophosphamide administered as described above, has induced clinical remissions. Following disease remission, cyclophosphamide should be switched to azathioprine or mycophenolate mofetil as these have good penetration into the CNS.

BEHÇET'S DISEASE

Behçet's disease is a clinicopathologic entity characterized by recurrent episodes of oral and genital ulcers, iritis, and cutaneous lesions. The underlying pathologic process is a leukocytoclastic venulitis, although vessels of any size and in any organ can be involved. **This disorder is described in detail in Chap. 376.**

COGAN'S SYNDROME

Cogan's syndrome is characterized by interstitial keratitis together with vestibuloauditory symptoms. It may be associated with a systemic vasculitis, particularly aortitis with involvement of the aortic valve.

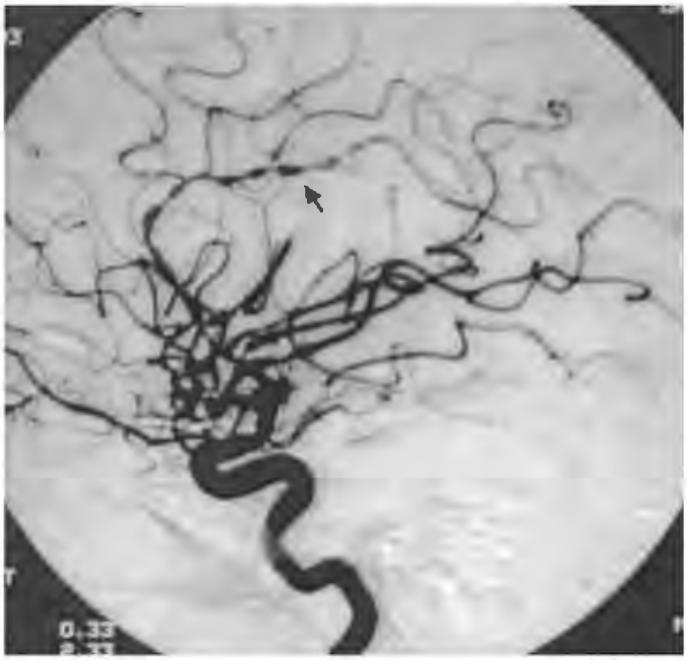

FIGURE 375-4 Cerebral arteriogram from a 32-year-old man with primary central nervous system vasculitis. Dramatic beading (*arrow*) typical of vasculitis is seen.

Glucocorticoids are the mainstay of treatment. Initiation of treatment as early as possible after the onset of hearing loss improves the likelihood of a favorable outcome.

KAWASAKI'S DISEASE

Kawasaki's disease is an acute, febrile, multisystem disease of children. Some 80% of cases occur prior to the age of 5, with the peak incidence occurring at ≤2 years. It is characterized by nonsuppurative cervical adenitis and changes in the skin and mucous membranes such as edema; congested conjunctivae; erythema of the oral cavity, lips, and palms; and desquamation of the skin of the fingertips. Although the disease is generally benign and self-limited, it is associated with coronary artery aneurysms in ~25% of cases, with an overall case-fatality rate of 0.5–2.8%. These complications usually occur between the third and fourth weeks of illness during the convalescent stage. Vasculitis of the coronary arteries is seen in almost all the fatal cases that have been autopsied and can cause complications into adulthood. There is typical intimal proliferation and infiltration of the vessel wall with mononuclear cells. Beadlike aneurysms and thromboses may be seen along the artery. Other manifestations include pericarditis, myocarditis, myocardial ischemia and infarction, and cardiomegaly.

Apart from the up to 2.8% of patients who develop fatal complications, the prognosis of this disease for uneventful recovery is excellent. High-dose IV γ-globulin (2 g/kg as a single infusion over 10 h) together with aspirin (100 mg/kg per day for 14 days followed by 3–5 mg/kg per day for several weeks) has been shown to be effective in reducing the prevalence of coronary artery abnormalities when administered early in the course of the disease. Surgery may be necessary for Kawasaki disease patients who have giant coronary artery aneurysms or other coronary complications. Surgical treatment most commonly includes thromboendarterectomy, thrombus clearing, aneurysmal reconstruction, and coronary artery bypass grafting.

Multisystem inflammatory syndrome (MIS-C), a serious condition that may resemble Kawasaki's disease, has been observed with infections due to SARS-CoV-2 **(Chap. 205)**. Although clinical features consistent with Kawasaki's disease have been observed, these patients can also have manifestations atypical for Kawasaki's disease, including gastrointestinal symptoms, myocarditis, neurocognitive symptoms, and shock. Any patient who presents with a clinical picture suggestive of Kawasaki's disease should be tested for SARS-CoV-2 to guide management.

POLYANGIITIS OVERLAP SYNDROMES

Some patients with systemic vasculitis manifest clinicopathologic characteristics that do not fit into a specific disease but have overlapping features of different vasculitides. The diagnostic and therapeutic considerations as well as the prognosis for these patients depend on the sites and severity of active vasculitis. Patients with vasculitis that could cause irreversible damage to a major organ system should be treated as described under "Granulomatosis with Polyangiitis."

SECONDARY VASCULITIS

DRUG-INDUCED VASCULITIS

Vasculitis associated with drug reactions usually presents as palpable purpura that may be generalized or limited to the lower extremities or other dependent areas; however, urticarial lesions, ulcers, and hemorrhagic blisters may also occur **(Chap. 63)**. Signs and symptoms may be limited to the skin, although systemic manifestations such as fever, malaise, and polyarthralgias may occur. Although the skin is the predominant organ involved, systemic vasculitis may result from drug reactions. Drugs that have been implicated in vasculitis include allopurinol, thiazides, gold, sulfonamides, phenytoin, and penicillin **(Chap. 63)**.

An increasing number of drugs have been reported to cause vasculitis associated with ANCA. Of these, the best evidence of causality exists for hydralazine and propylthiouracil. The clinical manifestations in ANCA-positive drug-induced vasculitis can range from cutaneous lesions to glomerulonephritis and pulmonary hemorrhage. Outside of drug discontinuation, treatment should be based on the severity of the vasculitis. Patients with immediately life-threatening small-vessel vasculitis should initially be treated with glucocorticoids and cyclophosphamide as described for granulomatosis with polyangiitis. Following clinical improvement, consideration may be given for tapering such agents along a more rapid schedule.

SERUM SICKNESS AND SERUM SICKNESS–LIKE REACTIONS

These reactions are characterized by the occurrence of fever, urticaria, polyarthralgias, and lymphadenopathy 7–10 days after primary exposure and 2–4 days after secondary exposure to a heterologous protein (classic serum sickness) or a nonprotein drug such as penicillin or sulfa (serum sickness–like reaction). Most manifestations are not due to vasculitis; however, occasional patients will have typical cutaneous venulitis that may progress rarely to a systemic vasculitis.

VASCULITIS ASSOCIATED WITH OTHER UNDERLYING DISEASES

Certain *infections* may directly trigger an inflammatory vasculitic process. For example, rickettsias can invade and proliferate in the endothelial cells of small blood vessels causing a vasculitis **(Chap. 192)**. In addition, the inflammatory response around blood vessels associated with certain systemic fungal diseases such as histoplasmosis **(Chap. 218)** may mimic a primary vasculitic process. A cutaneous leukocytoclastic vasculitis with occasional involvement of other organs may be a component of some infections. These include *subacute bacterial endocarditis*, *Epstein-Barr virus infection*, *HIV infection*, and a number of other infections.

Vasculitis can be associated with certain *malignancies*, particularly leukemic, lymphoid, or reticuloendothelial neoplasms. Leukocytoclastic venulitis confined to the skin is the most common finding; however, systemic vasculitis may occur.

A number of *connective tissue diseases* have vasculitis as a secondary manifestation of the underlying primary process. Foremost among these are *systemic lupus erythematosus* **(Chap. 368)**, *rheumatoid arthritis* **(Chap. 370)**, *inflammatory myositis* **(Chap. 377)**, *relapsing polychondritis* **(Chap. 378)**, and *Sjögren's syndrome* **(Chap. 373)**. The most common form of vasculitis in these conditions is the small-vessel venulitis isolated to the skin. However, certain patients may develop a fulminant systemic necrotizing vasculitis.

Secondary vasculitis has also been observed in association with *ulcerative colitis*, *congenital deficiencies of various complement components*, *sarcoidosis*, *primary biliary cirrhosis*, α_1*-antitrypsin deficiency*, and *intestinal bypass surgery*.

FURTHER READING

Finkielman JD et al: Antiproteinase 3 antineutrophil cytoplasmic antibodies and disease activity in Wegener granulomatosis. Ann Intern Med 147:611, 2007.

Jayne D et al: A randomized trial of maintenance therapy for vasculitis associated with antineutrophil cytoplasmic autoantibodies. N Engl J Med 349:36, 2003.

Jayne DRW et al: Avacopan for the treatment of ANCA-associated vasculitis. N Engl J Med 18:599, 2021.

Jennette JC et al: 2012 revised International Chapel Hill Consensus Conference Nomenclature of Vasculitides. Arthritis Rheum 65:1, 2013.

Smith RM et al: Rituximab versus azathioprine for maintenance of remission for patients with ANCA-associated vasculitis and relapsing disease: An international randomised controlled trial. Ann Rheum Dis 82:937, 2023.

Spiera RF et al: Sarilumab for relapse of polymyalgia rheumatica during glucocorticoid taper. N Engl J Med 389:1263, 2023.

Stone JH et al: Rituximab versus cyclophosphamide for ANCA-associated vasculitis. N Engl J Med 363:221, 2010.

Stone JH et al: Trial of tocilizumab in giant-cell arteritis. N Engl J Med 377:317, 2017.

Walsh M et al: Plasma exchange and glucocorticoids in severe ANCA-associated vasculitis. N Engl J Med 382:622, 2020.

Wechsler ME et al: Mepolizumab or placebo for eosinophilic granulomatosis with polyangiitis. N Engl J Med 376:1921, 2017.