RP to define the extent of disease involvement. *Direct laryngoscopy* can be useful to visualize cartilage damage and inflammation in the upper airway; however, *bronchoscopy* to visualize the lower airway can exacerbate disease and should be performed with caution. *Echocardiography* can assess valvular heart disease. *Fluorodeoxyglucose–positron emission tomography* may have utility to detect inflammation in the large arteries and the larger airways. *Biopsy of affected cartilage* often yields nonspecific findings and should be reserved to exclude mimicking conditions.

TREATMENT

Relapsing Polychondritis

Patients with RP can present to diverse specialists prior to diagnosis that can include multiple emergency room visits. Internal medicine doctors are typically among the first to encounter patients who present with the initial manifestations of RP and are instrumental in starting the initial treatment regimen.

Because RP is a systemic and heterogeneous disease, clinical management should typically involve multidisciplinary teams, including otolaryngologists (ear, nose, and throat specialists) and pulmonologists. Given the disease's propensity to progressively involve various organs, it is crucial to perform initial testing to define organ damage. If possible, patients should be referred to a rheumatologist for comprehensive evaluation, diagnosis confirmation, and the establishment of a tailored treatment plan.

Glucocorticoids are the cornerstone of initial treatment for inflammation in RP, with dosages tailored to the severity of the disease and the specific organs involved. In cases where life-threatening organ involvement, such as the airway, is present, high doses of glucocorticoids (e.g., 1 mg/kg of prednisone or an equivalent glucocorticoid) should be rapidly initiated. For patients with milder disease, lower doses of glucocorticoids can be trialed. Different disease-modifying agents can be used to treat the disease including methotrexate, leflunomide, mycophenolate, anti-interleukin-6, or tumor necrosis factor inhibitors. Due to the heterogeneity of the disease, treatment strategies are often determined by the predominant clinical phenotype.

FURTHER READING

Beck DB et al: Somatic mutations in UBA1 and severe adult-onset autoinflammatory disease. N Engl J Med 383:2628, 2020.

Ferrada M et al: Defining clinical subgroups in relapsing polychondritis: A prospective observational cohort study. Arthritis Rheum 72:1396, 2020.

379 Sarcoidosis

Alicia K. Gerke

Sarcoidosis is a systemic inflammatory disease of unknown cause characterized by the formation of nonnecrotizing granulomatous inflammation. Sarcoidosis affects the lung in >90% of cases but can afflict almost any other organ system as well. The disease was first described >150 years ago by Dr. Jonathan Hutchinson of London, England, as a skin malady of symmetrical purple plaques (later termed lupus pernio) and raised red lesions (Mortimer's malady). In 1899, the skin lesions were noted to be "sarkoid" by Caeser Boeck, a Norwegian dermatologist, as they resembled sarcoma, albeit the lesions were largely benign and granulomatous in their histology. The advent of imaging and other clinical technology later unveiled the multiorgan involvement associated with sarcoidosis. However, despite even modern advances in immunology, genetics, and genomics, there is still considerable mystery regarding the exact etiology of the inflammation and the factors that contribute to variability of disease presentation and clinical course. Because of this considerable heterogeneity and lack of large, randomized treatment trials, decisions regarding diagnosis and management continue to be challenging.

EPIDEMIOLOGY

Sarcoidosis occurs throughout the world, affecting all genders, races, and ages. Epidemiologic studies regarding the incidence, prevalence, and mortality rates of sarcoidosis are difficult to conduct and compare; this is due to the potential for nonstandardized case definition, differing methods of case acquisition, and lack of known etiology. Regional variabilities due to race and gender, as well as phenotypic variability, further confound epidemiologic measurements. Taken as a whole, epidemiologic studies highlight the variation in disease globally.

INCIDENCE AND PREVALENCE

The incidence and prevalence of sarcoidosis vary by race, gender, geographic region, ethnicity, and season. An increased familial risk has been noted. The highest incidence in the world occurs in African Americans (35.5 per 100,000) and Northern European populations (24 per 100,000) as described by studies from the United States and Sweden. A higher incidence occurring in women is consistent across most studies, although the ratio does not usually exceed 2:1. The U.S. Black Women's Health Study cohort found a particularly high annual incidence of 71 per 100,000 and a prevalence of 2%. Some studies suggest an increase in incidence over time in the populations of some countries such as the United States and Japan. Peak incidence of the disease occurs between 35 and 45 years of age, but a significant proportion of cases do happen after age 55, with men manifesting disease earlier than women. The overall perceived incidence rate may be underestimated, as identification of subclinical sarcoidosis may only be possible in screening population studies or at autopsy. Certain occupations and exposures and an elevated body mass index have been identified as risk factors for development of sarcoidosis, whereas smoking is associated with reduced odds of incident sarcoidosis. Seasonal variation is also reported, with a predominance of diagnoses occurring in the springtime.

Differences in presentation and severity are also seen among populations. Cardiac and ocular involvement are more commonly observed in Japanese populations, whereas Europeans tend to develop erythema nodosum, which is uncommon among Japanese and black populations. Several studies suggest that overall severity is higher in black populations, with black patients presenting with more frequent involvement of extrapulmonary disease and three times the likelihood of familial disease. Women are at increased risk for developing erythema nodosum and ocular, musculoskeletal, and neurologic disease, while men are at higher risk for hypercalcemia. While most sarcoidosis patients have lung involvement, black and female patients tend to have more severe lung disease. Finally, lower income has also been associated with severity of disease and potentially greater disability and impairment (particularly increased dyspnea and onset of new organ involvement), suggesting that socioeconomic status may impact disease course.

MORTALITY

Mortality rates vary considerably based on the study setting, with population screenings noting lower rates of mortality than those reported from referral centers. These occurrences may reflect differences in disease severity. Analysis of death certificates from the United States shows an average age- and gender-adjusted mortality rate of 4.32 per 1,000,000. Mortality rates are higher in women and in African Americans. Pulmonary fibrosis is the leading cause of death in this population. Lower mortality rates are seen in Japan, with estimates at 0.1 per million people. In Japan, mortality from sarcoidosis itself is usually attributed to cardiac involvement, whereas in Europeans and Americans, respiratory mortality predominates.

ETIOLOGY

The cause of sarcoidosis is unknown; however, current evidence strongly indicates a heightened host immune response to an undetermined environmental exposure in a genetically susceptible individual. It is unknown if there are multiple different antigens that induce the same disease process. The immunologic response in sarcoidosis appears to be physiologic, although it is either exaggerated or is deficient in its regulatory mechanisms. The transmissibility of the immune response also supports the presence of an antigen. For example, the Kveim-Siltzbach reagent (historically used to diagnose sarcoidosis) is a homogenate of human splenic tissue from patients with sarcoidosis that, when injected into the skin, induces a systemic granulomatous response in patients with early sarcoidosis. In a similar fashion, transplant recipients can develop a sarcoid-like inflammatory response after receiving organ tissue from another person with sarcoidosis.

Histologic inflammatory responses like sarcoidosis occur in the lungs of patients with known inorganic and organic exposures such as beryllium, mycobacteria, or fungi, resulting in these antigens being studied as potential causes. Mycobacterial proteins (e.g., mKatG, ESAT-6, mycobacterial superoxide dismutase A, antigen 85A, heat shock proteins) have been found disproportionately in sarcoidosis granulomas. Heightened macrophage immune responses against these peptides within blood and bronchoalveolar lavage (BAL) have also been noted in patients with sarcoidosis. In a similar manner in other cohorts, *Cutibacterium acnes* (formerly *Propionibacterium acnes*) has been implicated. A genetic predisposition is also suspected, as antigen recognition and presentation molecule polymorphisms have been associated with sarcoidosis development and phenotype. Similarly, gene–environment interactions have been identified, suggesting a complex interaction of a susceptible host in a predisposing environment.

Epidemiologically, the role of antigens in pulmonary sarcoidosis is further supported by case-cluster events and occupational association. Whereas numerous familial case clusters support a genetic predisposition to sarcoidosis in at least a proportion of cases, spatial clustering of nonrelated sarcoidosis cases suggests exposure to an inciting environmental antigen. For example, a baseline higher incidence is noted in U.S. firefighters, with an annual incidence of sarcoidosis occurring in 13–15 per 100,000 individuals. Following the World Trade Center event and building collapses, the rates of "sarcoid-like" disease were 86 per 100,000 in the first year and 22 per 100,000 over the next 4 years, with the highest risk associated with working in the debris piles. Interestingly, the cases included not only those with lung disease but also those with multisystem involvement, which would not be expected from a localized inhalational exposure. Additionally, employment in agriculture, teaching, metalworking, radiation, cotton ginning, and automobiles has also been associated with sarcoidosis.

Increased rates of sarcoidosis have been found in association with environmental exposures. Musty or humid environments, mold and mildew, insecticides, air conditioning, raising birds, and exposure to wood stoves/burning and fireplaces have been associated with increased risk of sarcoidosis. On the other hand, smoking is consistently a negative predictor of disease; the mechanism of this is unknown, although it is perhaps related to immunomodulatory effects of nicotine and smoke. These epidemiologic studies would indicate that the inciting exposure may be a bioaerosol or an inorganic agent, which may explain some of the epidemiologic variability of clinical presentation by race, age, gender, and ethnicity. Additionally, the inciting antigen may not be a single agent; rather, differing antigens may exist for each individual or population.

PATHOGENESIS

Like other granulomatous processes, granulomas of sarcoidosis are presumably forming around a poorly degradable or insoluble material that is identified and presented to lymphocytes by dendritic cells or macrophages via the major histocompatibility complex (Fig. 379-1). The initial innate immune response triggers the production of cytokines and chemokines that begin the cascade of granulomatous inflammation, attracting cells of the adaptive immune response. Activated lymphocytes and mononuclear cells migrate to the site of granulomatous inflammation in a process driven by amplification of oligoclonal T cells of undefined antigenic specificity. Type 1 (T_H1) immune polarization is the immunopathogenic hallmark of sarcoidosis, characterized by highly polarized CD4+ T_H1 lymphocytes and less so by CD8+ lymphocytes,

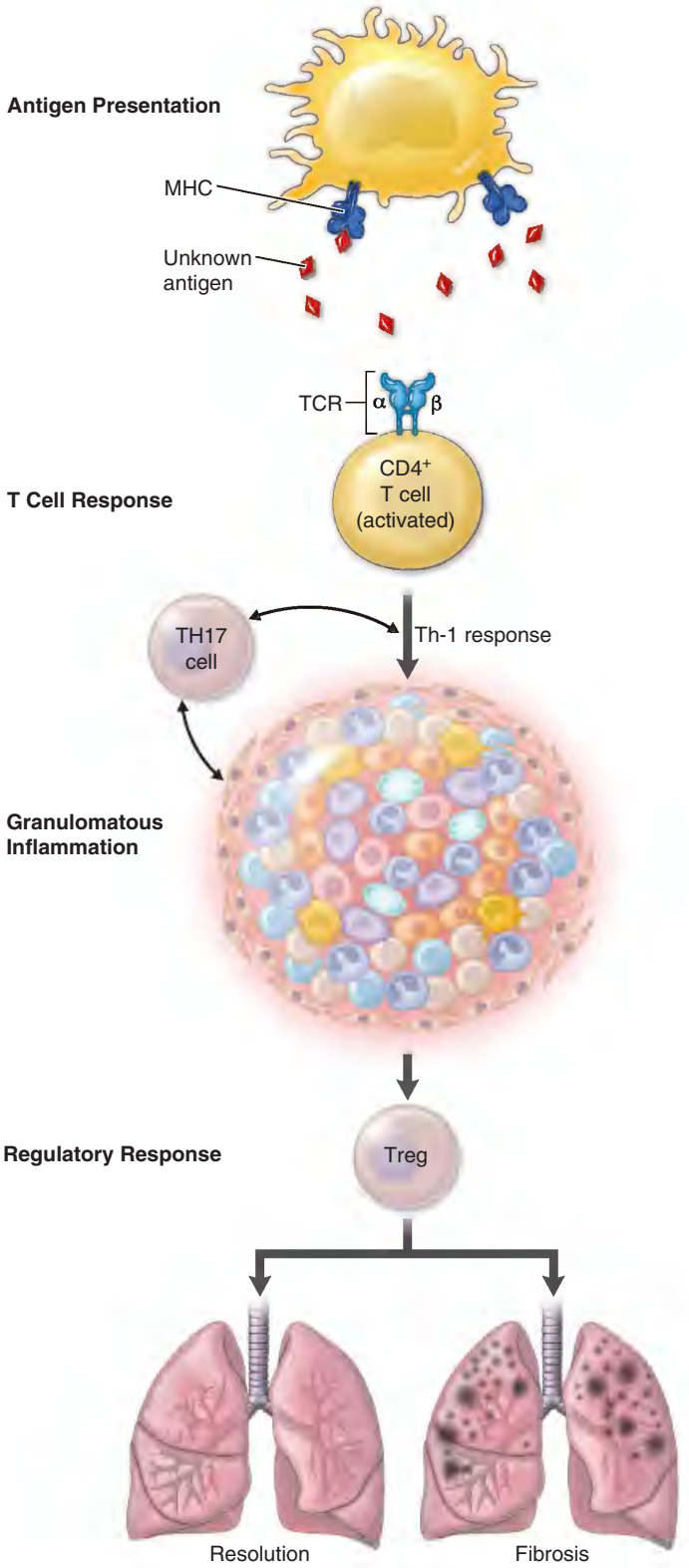

FIGURE 379-1 Immunopathogenesis of sarcoidosis. Granulomatous inflammation of sarcoidosis is presumed to be due to a heightened immune response to an undetermined antigen in a genetically predisposed individual. The antigen presentation via the major histocompatibility complex (MHC) activates CD4+ T cells, leading to a polarized T_H1 response. Activated lymphocytes, macrophages, and monocytes migrate to sites of inflammation, leading to a cascade of tightly formed noncaseating granulomas. Altered T-regulatory (Treg) and T_H17 responses are thought to be involved in lack of resolution of granulomatous inflammation or progression to fibrosis in some cases.

producing interferon-gamma (IFN-γ). T_H1-promoting immunoregulatory cytokines and chemokines (interleukin [IL]-1, IL-2, IL-15, IL-18, CXCR3) are consistently upregulated at sites of inflammation, propagating the immune response, activating macrophages, and forming granulomas. The accumulation of inflammatory cells at granuloma formation sites appears to be the result of both in situ proliferation and redistribution of the peripheral blood to the lung. Alterations in regulatory T cells and T_H17 cells may also play a role in the body's inability to control the inflammation. Although most patients with sarcoidosis eventually recover, the critical step as to why some patients with sarcoidosis transition to fibrosis is not understood.

CLINICAL PRESENTATION

The clinical presentation of patients varies considerably from asymptomatic to progressive organ dysfunction. Acute-onset presentation is seen in Löfgren syndrome in up to 10% of sarcoidosis cases (fever, erythema nodosum, ankle arthralgias, bilateral hilar lymphadenopathy) and, less commonly, Heerfordt syndrome (facial nerve palsy, fever, anterior uveitis, and bilateral enlargement of the parotid glands). These acute presentations typically have an excellent prognosis with full spontaneous resolution. In subacute or chronic cases, symptoms such as chronic cough, dyspnea, atypical chest pain, or intermittent joint or muscle pain tend to have a more insidious onset. In rare cases, presentation of sarcoidosis can be fatal, usually related to heart failure, sudden cardiac death, or neurologic involvement.

Symptoms vary depending on organ involvement and intensity of inflammatory response; therefore, patients can present to different clinical specialists. Nonspecific symptoms of fevers, malaise, night sweats, and weight loss are often present. More fulminant and organ-threatening symptoms can include acute hypercalcemia, blindness, arrhythmias, heart block, or neurologic demise, necessitating hospitalization. Cardiopulmonary symptoms such as cough, chest pain, or shortness of breath can mimic more common diseases, contributing to delays in diagnosis. In many cases, findings of sarcoidosis are found incidentally on imaging, prompting further workup.

ESTABLISHING A DIAGNOSIS

The diagnosis of sarcoidosis is made using three main criteria: (1) a compatible clinical presentation, (2) the presence of nonnecrotizing granulomatous inflammation in one or more tissues, and (3) exclusion of alternative causes of granulomatous inflammation. The diagnostic workup for sarcoidosis should also include assessment of extent and severity of organ involvement, a review of prognostic factors, and a determination of whether therapy will benefit the patient.

If a compatible clinical picture or radiographic finding suggests sarcoidosis, then biopsy should be considered as the next step. There are no well-established, clinically useful diagnostic serum biomarkers that can secure a diagnosis. Noninvasive sites for biopsy can include skin, conjunctiva, or superficial lymph nodes, but in cases where lung involvement and mediastinal/hilar lymphadenopathy are the prominent feature, bronchoscopy is the preferred method for diagnosis. Endobronchial ultrasound-guided lymph node sampling has high diagnostic yield and low procedural risk. BAL studies of lymphocyte subpopulations can be performed and characteristically reveal an elevated percentage of lymphocytes. A CD4:CD8 lymphocyte ratio >3.5 supports a diagnosis of sarcoidosis, particularly when combined with consistent clinical and radiographic findings (albeit a normal ratio does not exclude sarcoidosis). BAL is also important to exclude infection. Granulomas can line all segments of airway walls, providing the "cobblestone" appearance seen during bronchoscopy. If needed, transbronchial lung tissue biopsies can also be done to confirm sarcoidosis with lung infiltrates. Endoscopic ultrasound through the esophagus can be considered as an alternative biopsy approach based on clinical presentation and location of inflammation. Rarely, surgical lung biopsy or mediastinoscopy may be indicated when less invasive procedures have proven nondiagnostic and no other accessible sites for biopsy have been identified. ^{18}F-fluorodeoxyglucose (FDG) positron emission tomography (PET)–computed tomography (CT) can also be helpful to identify active tissue inflammation and a site to biopsy in difficult cases.

In some cases, the clinical presentation can be so compelling that lymph node sampling may not be necessary. For example, this can occur in patients with classic Löfgren syndrome, Heerfordt syndrome, or lupus pernio. Similarly, deferring biopsy in asymptomatic patients with symmetrical bilateral hilar lymphadenopathy may be considered based on patient-oriented discussions. In all cases, however, close clinical follow-up is still recommended, as the diagnosis of sarcoidosis is never fully secure.

PATHOLOGY

The sarcoidosis granuloma is an organized collection of macrophages, epithelioid cells, and multinucleated giant cells (which form as the epithelioid cells fuse). These cells are surrounded by a well-circumscribed rim of lymphocytes and fibroblasts. CD4+ T lymphocytes are also found interspersed within the granuloma center, while CD8+ T lymphocytes and B lymphocytes reside at the periphery. Sarcoidosis granulomas are nonnecrotizing; however, punctuate necrosis may be present on rare occasions. More abundant necrosis strongly indicates alternative causes of granulomatous inflammation such as infection, and loosely formed nonnecrotizing granulomas would suggest an alternative diagnosis such as hypersensitivity pneumonitis (Fig. 379-2). Additionally, inclusions occasionally appear in sarcoidosis granulomas; these can include asteroid bodies, birefringent calcium carbonate or oxalate crystals, Schaumann bodies, and Hamazaki-Wesenberg bodies (especially in lymph nodes). Although most inflammatory granulomas tend to resolve, hyalinization and fibrosis of the granulomas can occur.

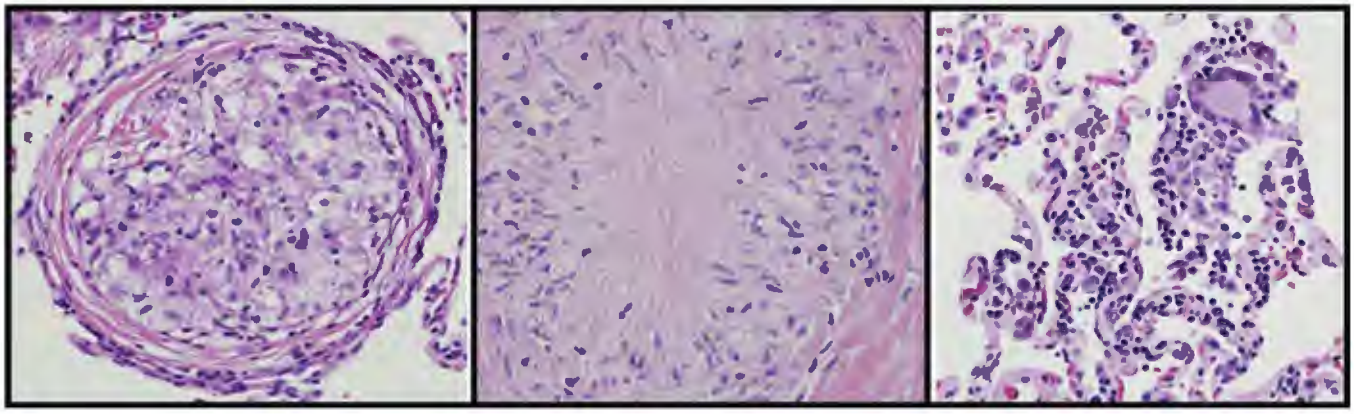

FIGURE 379-2 Comparison of granulomas. (***A***) The sarcoidosis granuloma is tightly formed and nonnecrotizing. (***B***) The infectious granuloma as seen in tuberculosis or fungal infections is tightly formed but with a necrotizing center. (***C***) The granuloma in hypersensitivity pneumonitis is loosely formed and without necrosis.

TABLE 379-1 Common Exclusionary Causes of Granulomatous Disease in the Diagnosis of Sarcoidosis

INFECTIONS	OTHER INFLAMMATORY DISEASES	MALIGNANCY RELATED
Mycobacterial infection • Tuberculosis • Atypical mycobacteria Fungal infection • Histoplasmosis • Coccidiomycosis • Blastomycosis • Aspergillosis • Cryptococcus Parasitic infection • Toxoplasmosis • Schistosomiasis Other bacterial and viral infection (less common) • Herpes zoster • Tularemia (*Francisella tularensis*) • Q fever (*Coxiella burnetii*) • *Bartonella henselae*	Environmental exposure • Hypersensitivity pneumonitis • Aspiration pneumonitis • Chronic beryllium disease • Silicosis • Talc inhalation or injection • Local or systemic reaction to tattoo ink Medication sarcoid-like reaction • Immune checkpoint inhibitors • Antiretroviral therapy • Interferon • TNF-α antagonist Autoimmune/Inflammatory • ANCA-associated vasculitis • Granulomatous-lymphocytic interstitial lung disease (associated with common variable immunodeficiency) • IgG4-related disease • Rheumatoid nodules • Inflammatory bowel disease • Bronchocentric granulomatosis	Malignancy • Local granulomatous reaction surrounding tumor • Systemic sarcoid-like reaction to malignancy Chemotherapy or immunotherapy • Sarcoid-like reaction

Abbreviations: ANCA, antineutrophil cytoplasmic antibodies; TNF, tumor necrosis factor.

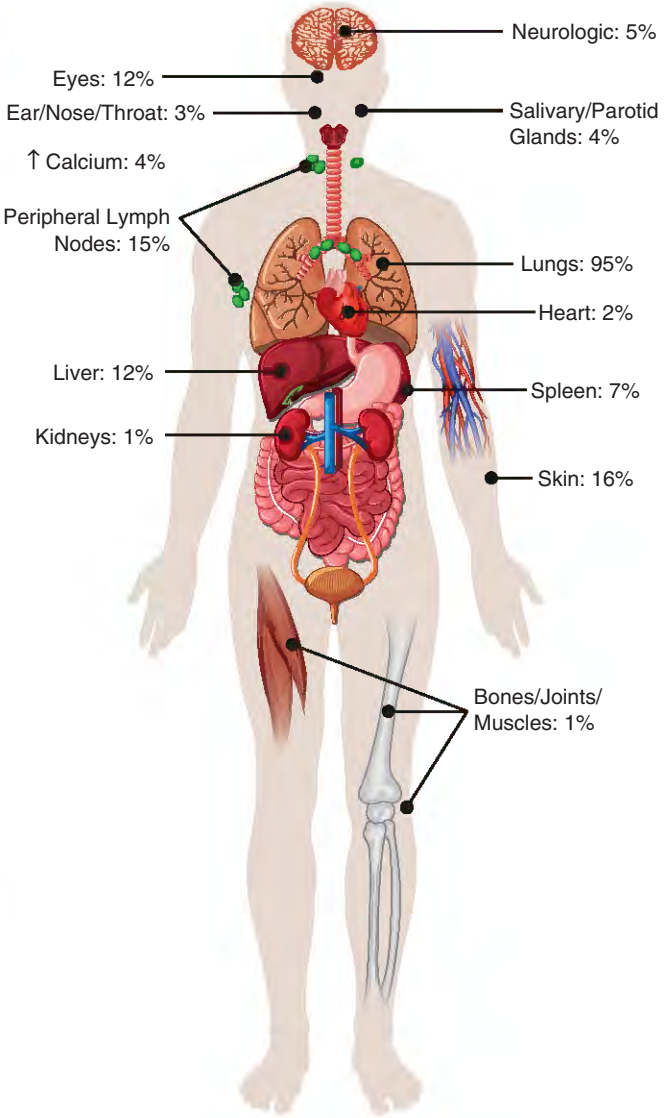

FIGURE 379-3 Frequency of organ involvement in sarcoidosis. Organ involvement upon presentation. *(RP Baughman et al: Am J Respir Crit Care Med 164:1885, 2001.)*

A histopathologic examination of the involved organ tissue reveals granulomas in sarcoidosis; however, diagnosis heavily relies on exclusion of other causes of granulomas. The differential diagnosis can be broad and must be considered in the clinical context (Table 379-1). A careful history assessment for environmental exposures or other inflammatory diseases is imperative to secure confidence in the diagnosis of sarcoidosis. Infections can be difficult to differentiate from sarcoidosis and require special histologic stains and cultures. Necrotizing sarcoidosis granulomatosis, characterized by necrosis, is a rare and less well-established entity that often involves vasculitis. Given the numerous causes of granulomatous inflammation and disease mimics, the diagnosis of sarcoidosis is never made with absolute certainty, and new symptoms or signs that occur during the disease process should be fully evaluated.

DIAGNOSTIC EVALUATION

The initial evaluation of sarcoidosis patients includes a complete history and physical exam, as well as assessment of organ involvement and severity of disease. Once diagnosis is suspected, a full review of symptoms is warranted to elucidate any potential pulmonary and extrapulmonary involvement, as about half of patients will have extrapulmonary involvement. Almost every organ system in the body can be affected by sarcoidosis (Fig. 379-3). A baseline set of testing (at minimum) should be done in all patients on initial evaluation, including pulmonary function tests, chest imaging, a baseline ophthalmologic investigation to evaluate for clinically silent uveitis, and an electrocardiogram (ECG) (Table 379-2). Serum tests for abnormal calcium metabolism and any significant hepatic, renal, or hematologic involvement should also be performed. Hematologic abnormalities are frequent and can be attributed to redistribution of T cells to sites of disease, splenic sequestration, granulomatous bone marrow involvement, or immune mediation. Routine asymptomatic follow-up testing is more controversial regarding its utility, but repeat testing should be done to evaluate the onset of any new signs or symptoms as the disease evolves. Abnormal initial testing may require further workup.

ORGAN INVOLVEMENT

LUNGS

The lungs are involved in >90% of patients with sarcoidosis. Pulmonary function tests are important to measure initial lung impairment and to assess improvement or deterioration over time. Many patients have normal lung function testing or a normal lung exam despite the presence of granulomatous inflammation and abnormal imaging findings. A restrictive pattern is often seen in those with more

TABLE 379-2 Baseline Testing upon Initial Diagnosis of Sarcoidosis

Full history, review of systems, physical exam
Pulmonary function testing
Chest imaging
Eye exam
Serum creatinine, alkaline phosphatase, calcium level, complete blood counts
25- and 1,25-hydroxyvitamin D levels if assessing vitamin D metabolism
Electrocardiogram

Note: Further testing is dependent upon signs or symptoms indicating potential organ involvement.

advanced disease, and airflow obstruction can occur in up to one-third of patients. Sarcoidosis tends to be upper-lobe predominant on lung imaging. Chest x-rays are classically used to "stage," or describe the pattern of presentation in the lungs, known as Scadding stages (Fig. 379-4). Although chest CT is not indicated in every patient, it is commonly performed to determine extent of lung disease and to guide biopsies. Sarcoidosis granulomas have a lymphangitic distribution in the lung along the pleural and subpleural areas and interlobular septa and around the bronchovascular bundles. Classic findings of sarcoidosis on chest CT scans are widespread small nodules with a bronchovascular and subpleural distribution (Fig. 379-5*A*, *B*), thickened interlobular septa, mediastinal and hilar lymphadenopathy, and conglomerate masses with architectural distortion (Fig. 379-5*C*). In advanced cases of pulmonary involvement, CT findings include honeycombing, cyst or cavity formation, and bronchiectasis. Nodular sarcoidosis or necrotizing sarcoid granulomatosis can present with nodular masses. Pleural effusions tend to be indirectly related (e.g., infections, heart failure), but rarely, sarcoidosis can cause lymphocytic, exudative pleural effusions. Upper respiratory tract involvement can also occur rarely within the larynx, pharynx, and sinuses and is associated with more chronic severe disease.

Progressive pulmonary fibrosis with irreversible scarring is a significant cause of complications and death in patients with sarcoidosis. Fibrosis can be complicated by cavitary lung disease, chronic pulmonary aspergillosis or aspergillomas, and pulmonary hypertension. Airflow obstruction is common in these patients due to central airway scarring and distortion of the lung structure. Fibrosis can occur even in the setting of anti-inflammatory therapy.

HEART

Granulomas can infiltrate any part of the heart, causing rhythm abnormalities, heart failure, pericardial effusion, and even sudden death. In the broader general population, cardiac sarcoidosis is the cause of a significant proportion of cases of new-onset atrioventricular block, cardiomyopathy, and ventricular dysrhythmias, particularly in younger age groups. Clinical evidence of cardiac involvement in patients with

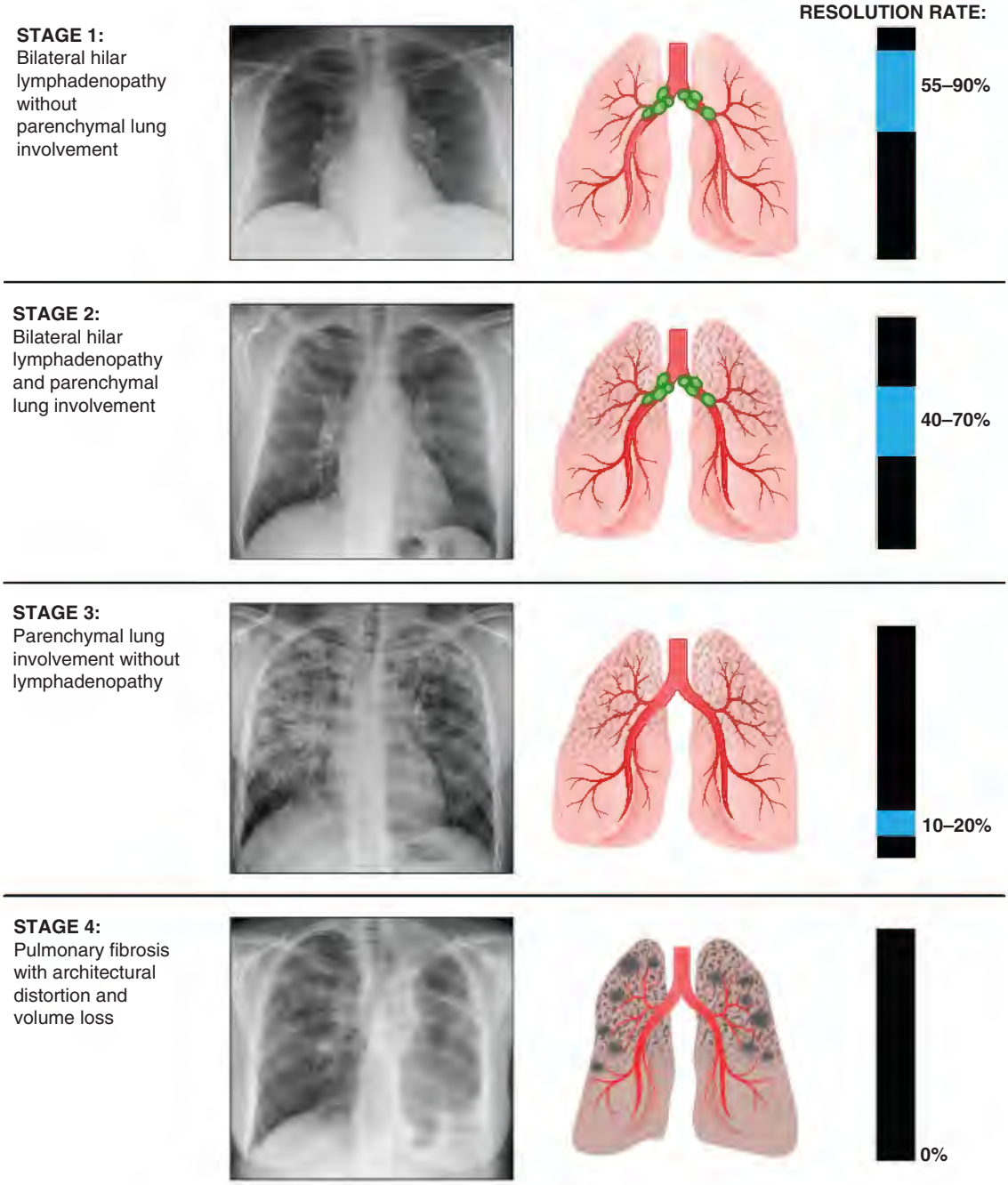

FIGURE 379-4 Scadding stages in sarcoidosis.

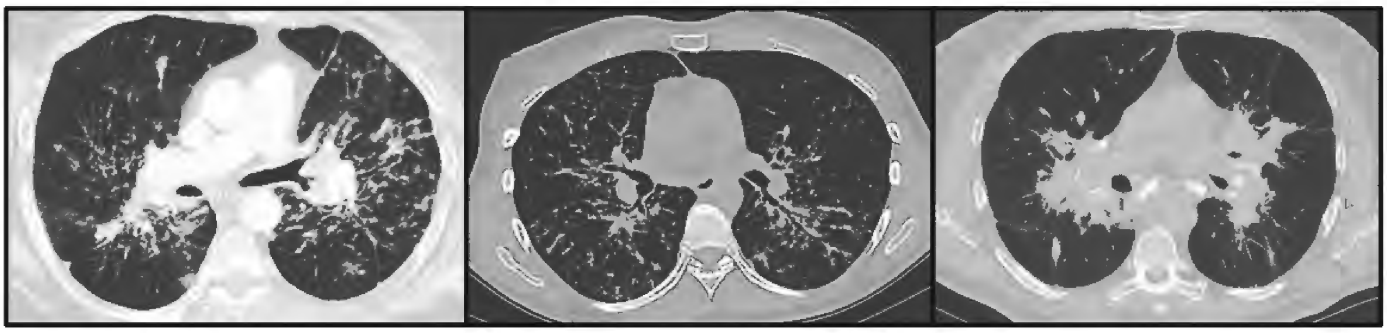

A B C

FIGURE 379-5 Imaging findings in sarcoidosis. (***A and B***) Chest computed tomography images of sarcoidosis show widespread small nodules in a perilymphatic and subpleural distribution and prominent bronchovascular bundle thickening. (***C***) Large peribronchovascular mass-like consolidations extending along the hila along with partially calcified mediastinal and hilar lymphadenopathy in a patient with sarcoidosis.

known sarcoidosis is found in <5% of U.S. sarcoidosis patients and 23% of Japanese patients, although autopsy studies suggest a higher rate of subclinical involvement. Severity of pulmonary involvement does not appear to predict the presence of cardiac sarcoidosis, and therefore every patient should be queried for potential cardiac symptoms, as cardiac sarcoidosis can have life-threatening complications. Isolated cardiac sarcoidosis can also rarely occur.

Sudden death is the most common cause of death among cardiac sarcoidosis patients, and it can occur as the initial presentation of the disease. Ventricular tachycardia is the most frequent tachyarrhythmia, but atrial tachycardias are also found in relation to ventricular dysfunction, dilated atria, or severe pulmonary disease. Heart failure is most often due to involvement of the myocardium but can also be caused by infiltration of valves or papillary muscles. Predictors of sudden death include severity of heart failure, left ventricular end-diastolic diameter, and sustained ventricular tachycardia.

Diagnosis of cardiac sarcoidosis can be difficult, since gold-standard biopsies lack sensitivity due to the patchy presence of granulomas in cardiac tissue, predominant location at base of the heart, and the lack of right ventricular involvement. ECG should be obtained on initial evaluation of every patient with sarcoidosis to reveal the presence of any conduction block, ST-T wave abnormalities, Q waves, frequent premature ventricular complexes, or resting tachycardia. Symptoms or unexpected abnormalities on ECG should prompt further cardiac evaluation, which can include a Holter monitor, signal-averaged ECG, or further cardiac imaging.

Several imaging tests are used for evaluating and diagnosing cardiac sarcoidosis. Historically, thallium-201 scintigraphy or technetium-sestamibi single-photon emission CT nuclear scans have been used to identify segmental defects that correspond either to a granulomatous disease or a fibrous scar. In contrast to coronary artery disease, patients with cardiac sarcoidosis have perfusion defects that reverse with exercise or dipyridamole, termed *reverse redistribution*. More current imaging studies now support the use of enhanced cardiac magnetic resonance imaging (MRI) as a preferred diagnostic tool due to its superior resolution and ability to detect early myocardial involvement with high sensitivity and specificity. Cardiac PET/CT can also be used in some cases to detect the presence of active inflammation in cases where cardiac MRI is unavailable, unable to be done (noncompatible devices or claustrophobia), or inconclusive. The use of these imaging techniques has largely obviated the need for myocardial biopsy in the diagnosis of cardiac involvement.

In patients with rhythm disturbances, prompt referral to an electrophysiologist is warranted for consideration of potential mapping or implantation of cardiac devices. Echocardiography can help identify ventricular dysfunction, valve dysfunction, abnormal septal wall thickness, or wall motion abnormalities that may also be contributing to the clinical picture.

Traditional treatments for cardiac arrhythmias and heart failure are indicated depending on the presentation, as well as immunosuppressive medications. The optimal amount of time dedicated to the course of immunosuppressive therapy is unclear, although the presence of cardiac sarcoidosis generally portends a more chronic and protracted course. Serial imaging and response to therapy can help guide potential therapy duration. Heart transplantation can be considered for refractory severe cardiac sarcoidosis, resulting in better short- and intermediate-term survival rates as compared to other transplant recipients.

PULMONARY ARTERY HYPERTENSION

Pulmonary hypertension (PH) in sarcoidosis, classified as a World Health Organization group 5 cause of PH, can complicate the clinical course and contribute significantly to morbidity and mortality. Pulmonary hypertension in sarcoidosis may be due to granulomatous vasculitis, pulmonary arterial occlusion by lymphadenopathy, thrombosis, pulmonary venous occlusion, destruction of the vascular bed, left heart dysfunction due to myocardial involvement, portopulmonary hypertension from associated liver cirrhosis, or hypoxic vasoconstriction related to parenchymal abnormalities. In some cases, precapillary PH can occur in the absence of other cardiopulmonary disease, resembling idiopathic PH. Evaluation for PH should be sought in patients who have symptoms that are disproportionate to the amount of parenchymal disease, have extensive parenchymal abnormalities, desaturate on 6-min walk test, or have a low diffusing capacity.

Echocardiography is a useful noninvasive technique screening test to evaluate pulmonary pressures, systolic or diastolic function, and valvular disease; however, right heart catheterization is the gold standard for diagnosis. Treating granulomatous disease with corticosteroids may result in the improvement of pulmonary pressures in some, but not all, cases, and pulmonary vasodilator therapy can be considered on a case-by-case basis.

NERVOUS SYSTEM INVOLVEMENT

Sarcoidosis affecting the nervous system is highly associated with systemic disease but also can occur in the absence of significant pulmonary or systemic disease. Cranial nerve involvement, particularly with the facial and optic nerves, is the most common manifestation and can be a result of granulomatous basal meningitis or direct involvement of the nerve. Facial nerve palsy is associated with good prognosis compared to other neurologic findings. Neurosarcoidosis has a predilection for the base of the brain. Inflammation of the hypothalamus and pituitary gland can cause neuroendocrine abnormalities that can persist even after immunosuppressive treatment. Other findings can include space-occupying masses, acute or chronic meningitis, peripheral neuropathy, and neuromuscular or spinal cord involvement. Rare presentations include seizures or neuropsychiatric symptoms.

Gadolinium-enhanced MRI is the preferred test for evaluating brain parenchyma, meninges, dura, and the spinal cord. MRI findings of leptomeningeal or parenchymal enhancement or multiple white matter lesions in a periventricular distribution are the more common abnormalities and are sensitive diagnostic findings. However, the appearance of sarcoidosis lesions is often nonspecific, mimicking malignancies or infections. Chest imaging can be helpful in diagnosis since many patients will have a pulmonary abnormality that can be biopsied. Cerebrospinal fluid (CSF) analysis most often reveals mononuclear cell pleocytosis and/or elevated proteins. Elevated CSF angiotensin-converting enzyme, high soluble IL-2 receptor, increased lysozyme,

decreased glucose, and oligoclonal bands can also be seen but are not diagnostic. CSF analysis is important to help exclude infection. Histologic confirmation of disease in the brain or spinal cord is occasionally necessary when significant diagnostic uncertainty exists or a patient is not responding to therapy. Otherwise, a diagnosis can be established with an acceptable degree of certainty by biopsy of a nonneurologic site, such as the lung, together with consistent clinical features and imaging and exclusion of other causes.

Peripheral nerves can also be affected in sarcoidosis. Pain is a common symptom among sarcoidosis patients and may be related to neuropathic or fibromyalgia syndromes. Small-fiber neuropathy has increasingly been noted to be a cause of pain and autonomic dysfunction. Large-fiber neuropathies can be evaluated by performing nerve biopsy or nerve conduction studies. Unfortunately, pain syndromes, regardless of their underlying cause, often do not respond well to immunosuppressive medications.

CUTANEOUS

Sarcoidosis causes many forms of skin lesions, with maculopapular, nodular eruptions and plaques being the most common types involving granulomatous inflammation of the tissue itself. Other skin lesions include infiltration of old scars or tattoos, hypo- and hyperpigmented areas, scales, annular lesions, ulcerations, and subcutaneous nodules or masses. Most of the time, lesions are not painful or pruritic. Nonspecific, nongranulomatous lesions of erythema nodosum are a well-established manifestation of sarcoidosis, commonly found in Europeans and women. Lesions are raised, tender, erythematous bumps or nodules found on the anterior legs and often a prominent feature of Löfgren syndrome. Lupus pernio is a distinctive chronic lesion and consists of indurated plaques and violaceous discoloration of the nose, cheeks, lips, and ears, and frequently involves the nasal mucosa **(Fig. 379-6)**. This lesion appears most commonly among members of the African-American female population. Lupus pernio is often associated with more severe disease including bone cysts, pulmonary fibrosis, and a prolonged clinical course. Overall, skin lesions can be treated with topical or injected corticosteroids, although disfiguring or symptomatic lesions may need systemic therapy.

EYE INVOLVEMENT

Ocular sarcoidosis can affect any part of the eye or orbit, with clinical manifestations ranging from asymptomatic to permanent vision loss. Given the potential for permanent vision loss, ophthalmologic examination is recommended on initial exam in sarcoidosis patients and with any change in visual symptoms. Uveitis (anterior, posterior, or panuveitis) is the most common manifestation and is often bilateral. Chronic uveitis may lead to synechiae formation, glaucoma, cataracts, cystoid macular edema, and blindness. Optic neuropathy can lead to sudden permanent vision loss and should be treated as an emergency with immediate initiation of immunosuppressive therapy. Other eye lesions include conjunctival or eyelid granulomas, lacrimal gland enlargement, keratoconjunctivitis sicca, dacryocystitis, retinal vasculitis, and periorbital swelling. If conjunctival nodules are present, biopsy can be a relatively noninvasive way to obtain diagnostic tissue.

LIVER

Hepatic granulomas are found very frequently in patients with pulmonary sarcoidosis (up to 80% in some autopsy studies) but are much less often clinically significant (up to 15%). Conversely, hepatic sarcoidosis can occur without involving the lungs. Liver function tests are abnormal in up to one-third of sarcoidosis cases, with an elevated alkaline phosphatase as the most common lab abnormality. Elevated transaminases are also frequent, while elevated bilirubin levels are more indicative of significant progressive sarcoidosis liver disease. Hepatomegaly is commonly seen. Patients who do present with symptoms experience abdominal pain, pruritus, fevers, weight loss, and jaundice. Hepatic sarcoidosis can infrequently progress to chronic cholestasis, hepatocellular disease, portal hypertension, Budd-Chiari syndrome, or cirrhosis. The pattern of presentation depends on the extent and location of granulomatous inflammation and fibrosis in the liver. Imaging of the liver often shows hepatomegaly and/or small, innumerable nodules of low attenuation. Extensive evaluation of alternative causes should be performed when cases of isolated hepatic granulomas are involved, because liver granulomas are associated with a large differential diagnosis. Immunosuppressives may be effective when a patient experiences symptomatic liver dysfunction, but not in every case. Liver transplantation remains a viable option when hepatic failure occurs.

MUSCULOSKELETAL

Acute arthritis (such as that seen in Löfgren syndrome) is common in sarcoidosis, especially early in the course of disease. Pain is a potential indication to treat. Chronic arthritis or synovitis is rarer than the acute presentations. The most common joints affected by sarcoidosis are the ankles, knees, elbows, wrists, and small joints of the hands and feet. Bone lesions, characteristically identified as lacy, reticular osteolytic lesions on radiographs, can be frequently asymptomatic but occasionally cause pain. Bone marrow involvement can cause hematologic abnormalities such as anemia and lymphopenia.

Cases of symptomatic muscle involvement present with pain, tenderness, or weakness and have physical findings that are consistent with myositis, chronic myopathy, or muscle nodules. Myopathy is more commonly found in women and can be the sole presentation of disease. MRI or nuclear bone scans are useful to identify active inflammation in patients with musculoskeletal symptoms or to differentiate nonsarcoidosis causes. Electromyogram studies and biopsy may also be helpful in the diagnostic workup.

HYPERCALCEMIA

Hypercalcemia occurs in only about 10–20% of patients with sarcoidosis, but hypercalciuria is much more frequent and is seen in up to 50%

FIGURE 379-6 Cutaneous sarcoidosis. Extensive involvement of the nose and philtrum extending onto the cheeks is seen. The lesions include confluent papules and plaques, some of which are vaguely annular on the philtrum. *(Courtesy of Dr. Misha Rosenbach, MD.)*

of patients. High calcium levels are due to dysregulated production of the active form of vitamin D (1,25-hydroxyvitamin D_3 or calcitriol) by activated macrophages and granulomas in the setting of abundant cytokines such as IFN-γ. Normally, conversion of vitamin D to its active form is a highly regulated process that occurs in the kidney via the action of 1-alpha-hydroxylase (CYP27B1) controlled by parathyroid gland. The conversion of vitamin D to calcitriol by macrophages occurs unregulated, causing increased intestinal absorption and bone resorption and thereby raising serum calcium despite low parathyroid hormone levels. Hypercalcemia, left untreated, leads to nephrocalcinosis and subsequent renal dysfunction. Patients with evidence of hypercalcemia should monitor vitamin D intake, avoid excessive sunlight, and maintain hydration. In severe acute symptomatic cases, hypercalcemia is a cause of hospital admission requiring more urgent corticosteroid therapy.

KIDNEY

Renal dysfunction is mostly related to hypercalcemia and nephrocalcinosis associated with sarcoidosis, rather than direct granulomatous infiltration. However, sarcoidosis can cause interstitial nephritis (with and without granulomas), which is generally responsive to treatment. Urinalysis usually reveals sterile pyuria, bland sediment, or mild proteinuria.

LYMPHOID SYSTEM

Peripheral lymphadenopathy can be the presenting sign of sarcoidosis in a minority of cases. The extrathoracic glands most frequently involved are the cervical, axillary, epitrochlear, and inguinal glands. Enlarged glands are discrete, movable, and nontender without ulceration or drainage. Splenomegaly in sarcoidosis is common but is usually clinically silent. Hypodense nodules can be seen on imaging. Infrequently, splenic involvement may cause pressure, pain, constitutional symptoms, or hematologic abnormalities that require splenectomy.

PAROTID GLANDS

Parotid or salivary involvement occurs in 4% of sarcoidosis patients, often associated with Heerfordt syndrome (parotitis, uveitis, fever, facial palsy). Patients with parotid gland involvement can be asymptomatic or present with painful, swollen glands or xerostomia. Parotid enlargement is self-limiting in many cases and can present like Sjögren's syndrome.

GASTROINTESTINAL TRACT

Gastrointestinal tract involvement is a rare manifestation of sarcoidosis and most commonly involves the stomach than any other parts. Patients may present with dysphagia, bleeding, nausea or vomiting, pain, weight loss, or obstructive symptoms.

REPRODUCTIVE ORGANS

Granulomas may occur in the reproductive system, most commonly appearing within the female uterus or the male epididymis. Given the rarity of involvement, any new nodules or masses in these organs require careful attention to exclude malignancy.

CLINICAL COURSE AND PROGNOSIS

In just over half of patients, the disease resolves spontaneously; however, a significant proportion (30–40%) of patients will have chronic disease that threatens vital organs or causes debilitating symptoms, necessitating treatment. Chronic symptoms can be progressive or waxing and waning. Predicting clinical course on presentation in any one individual is difficult, given lack of known prognostic biomarkers. Research studies are often confounded by the variable clinical course and the lack of correlation of serum and radiographic measures to the intensity of granulomatous response. Most cases of sarcoidosis will show improvement in chest radiography or spirometry after 2 years of follow-up, including treated and untreated. Serious extrapulmonary involvement (e.g., cardiac, central nervous system, hepatic) occurs in 4–7% of sarcoidosis patients at presentation and can develop as the disease evolves. Relapses are common and are associated with shorter treatment duration. Acute exacerbations of pulmonary sarcoidosis are thought to occur in over one-third of patients, although they are not well-defined.

Death related to sarcoidosis itself does occur in 1–5% patients because of progressive respiratory insufficiency, complications of pulmonary scarring (e.g., hemoptysis, infection, aspergilloma), central nervous system involvement, liver failure, or myocardial involvement (heart failure, cardiac block, sudden cardiac death, or arrhythmias). Differing mortality rates reflect variances in disease severity, referral bias, and diverse genetic and epidemiologic factors of the populations studied. For instance, most deaths occurring in the United States and Northern Europe are due to pulmonary complications, whereas a vast majority of deaths due to sarcoidosis in Japanese patients are from cardiac involvement. Complications of immunosuppressive therapies can also contribute indirectly to mortality. Transplantation of the lungs, heart, liver, or kidneys can be lifesaving in severe progressive cases.

CLINICAL FACTORS OF PROGNOSTIC SIGNIFICANCE

Overall, patients with a more robust initial immune response have a better prognosis than those with more subacute or chronic presentation. Patients that present with Löfgren or Heerfordt syndromes tend to have an excellent prognosis with spontaneous remission in up to 80%. Löfgren syndrome occurs in 20–30% of Caucasians with sarcoidosis, particularly Northern Europeans, and <5% of Asians and African Americans. Erythema nodosum and fever usually remit spontaneously within 6 weeks, while resolution of lymphadenopathy may be delayed for over a year. Immunosuppressive therapy is rarely necessary. On the other hand, adverse clinical prognostic factors include lupus pernio, chronic uveitis, older age, chronic hypercalcemia, nephrocalcinosis, African origins, pulmonary hypertension, fibrotic pulmonary sarcoidosis, sinus involvement, cystic bone lesions, neurosarcoidosis, and cardiac involvement. Parenchymal infiltrates associated with Scadding radiographic stages do not predict activity, progression of lung disease, or extrapulmonary involvement but do reveal overall resolution rates (Fig. 379-4).

PREDICTIVE VALUE OF SERUM, BRONCHOALVEOLAR LAVAGE, AND GENETICS

There are no current clinically used biomarkers that can predict clinical course in any one case. Serum angiotensin-converting enzyme (ACE) levels, derived from macrophages, are not largely useful as a diagnostic or prognostic tool due to low sensitivity. However, ACE levels have been employed to monitor systemic disease activity, as they correlate roughly with the granulomatous burden. Similarly, the T-cell–derived soluble IL-2 receptor lacks sensitivity for diagnosis but correlates with disease activity and may predict relapse rate. In BAL fluid, the high CD4:CD8 ratio, although supporting a diagnosis, does not correlate with disease progression or need for treatment, but higher values seem to implicate a better overall prognosis. Increased percentages of BAL neutrophils (or eosinophils) appear to be present in a higher proportion of individuals with progression. In genetics, certain human leukocyte antigen (HLA) haplotypes have been associated with acute and chronic phenotypes. Similarly, variants of butyrophilin-like 2 (*BTNL2*), tumor necrosis factor alpha (*TNF*-α), and annexin A11 (*ANXA11*) genes have been associated with worse prognosis. Unfortunately, these and multiple other serum and BAL markers lack generalizability and utility in the clinical realm for any one individual.

FOLLOW-UP AND MONITORING

To assess prognosis and determine the need for therapy, longitudinal surveillance of sarcoidosis should be most intensive during the 2-year period following presentation with decreasing frequency as time goes on. When therapy has started, follow-up of response and side effects should be done in 1–3 months and, once stable on therapy, every 3–6 months. Once in full remission, patients should be followed for a few years to assess for relapses; however, lengthier observation may be necessary based on severity of disease or residual organ dysfunction. Follow-up testing should include symptoms, a complete physical exam, imaging of affected organs, periodic pulmonary function testing, and

markers of specific organ dysfunction. Choice of imaging depends on clinical scenario and can include chest x-rays, CT scans, and in some rarer cases, PET/CT or MRI. Any development of new symptoms over time should prompt full evaluation of that organ system.

TREATMENT

Sarcoidosis

Treatment decisions in sarcoidosis are complex, and medication options tend to be guided by expert opinion, uncontrolled trials, and only a few larger randomized controlled trials. There is no cure for sarcoidosis; the goal of treatment is to suppress granulomatous inflammation, prevent irreversible organ fibrosis, and alleviate debilitating symptoms as the disease evolves. With the high side effect profile of corticosteroids and other immunosuppressive therapy, it is first important to identify those cases in which therapy is indicated. For example, treatment is not indicated for asymptomatic stage I disease, which has an inherent high rate of spontaneous resolution. Mild symptoms may be closely monitored, and topical immunosuppressive therapies are preferred for skin disease if possible. Oral immunosuppressive therapy should be reserved for those who have significant symptoms, disfigurement, or dangerous impending organ damage. In pulmonary disease, this may include worsening cough and shortness of breath, moderate to severe parenchymal lung involvement, or a progressive decline in pulmonary function. In each case of sarcoidosis, the risks and toxicity of immunosuppression must be considered in comparison to the potential benefit of treatment.

Corticosteroids remain the mainstay of first-line treatment, although controversy exists regarding whether they alter the natural history. Oral steroids have been shown to improve chest x-ray imaging scores, symptoms, and spirometry in the short term. There are limited data beyond 2 years to indicate whether oral steroids have any modifying effect on long-term disease progression or mortality. In cases of intolerance or toxicity to corticosteroids, inability to taper corticosteroids, or refractory disease, alternative steroid-sparing immunosuppressives can be considered **(Table 379-3)**. In choosing a therapy, clinicians should take into consideration the presence of comorbid conditions such as osteoporosis, diabetes, cataracts, or glaucoma that may be aggravated by corticosteroids. Organ transplantation is occasionally necessary in cases of progressive organ damage including lungs, liver, heart, and kidney. Sarcoidosis can recur in transplanted organs but is rarely a cause of organ failure after transplant.

CORTICOSTEROIDS

When it is determined that treatment is indicated, corticosteroids are generally used as first-line therapy given efficacy and ease of use. Generally, prednisone or an equivalent corticosteroid is started at 0.5 mg/kg per day or ~20–40 mg/d for 4 weeks, and then reduced to a maintenance dose that will control symptoms and disease progression, ideally below 10 mg/d. Higher starting doses are not largely effective in most cases of sarcoidosis and are associated with increased morbidity. Lower induction doses can be considered based on severity of presentation, side effect tolerance, and rate of disease progression. More aggressive therapeutic approaches with higher doses or in association with other immunosuppression can be considered in life- or organ-threatening situations such as seen in central nervous system involvement, ocular involvement leading to vision loss, or extensive myocardial inflammation. In a subgroup of cases with very mild pulmonary symptoms such as cough, inhaled corticosteroids may be considered for symptom control but have not been shown to be of benefit in the larger sarcoidosis population.

STEROID-SPARING THERAPIES

As the landscape of drug development broadens, treatment options have expanded beyond corticosteroids to include several anti-inflammatories drawn from treatment of other rheumatologic conditions (Table 379-3). The choice of steroid-sparing agent often depends on several clinical factors (e.g., alcohol use, desire for pregnancy, known pharmacogenetic profiles, comorbidities such as liver or renal dysfunction), but methotrexate is the most recommended second-line therapy due to its efficacy and favorable side effect profile. Azathioprine appears to be equally effective, although

TABLE 379-3 Treatments for Sarcoidosis

	DRUG NAME	DOSE RANGE	CONSIDERATIONS
Initial therapy	Corticosteroids (prednisone, prednisolone)	20–40 mg/d initial, tapered to 7.5–15 mg/d	Consider taper early based on clinical improvement Monitor bone health Consider implications of weight gain Assess risk of diabetes Monitor eye exams (glaucoma and cataracts)
Common second-line therapies	Methotrexate	7.5–20 mg/wk orally or subcutaneously	Concurrent administration with folic acid Monitor liver and renal function and blood counts Contraindicated with significant alcohol use
	Leflunomide	10–20 mg/d	Monitor liver and renal function and blood counts In cases of toxicity, consider cholestyramine to accelerate clearance
	Azathioprine	50–200 mg/d or 1–2 mg/kg/d	Monitor liver and renal function and blood counts Consider thiopurine methyltransferase activity level
	Mycophenolate	1000–3000 mg/d	Monitor blood counts Enteric-coated option available (note: different dose range)
	Hydroxychloroquine	200–400 mg/d	Periodic eye exams for retinopathy Assess QT (monitor drug interactions) Effective for skin or hypercalcemia, but not for pulmonary
Refractory disease or inability to taper corticosteroids	Infliximab	3–5 mg/kg intravenously at weeks 0 and 2, and then every 4–8 weeks	Tuberculosis screening prior to use Avoid use in heart failure Allergic reactions possible with infusion Longer term association with demyelination syndrome and malignancy Can induce sarcoid-like reactions
	Adalimumab	40 mg subcutaneous every 1–2 weeks (exact dose unknown)	Similar precautions and adverse events as infliximab