Section 3 Disorders of the Joints and Adjacent Tissues

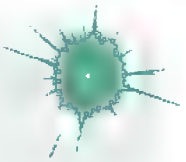

382 Approach to Articular and Musculoskeletal Disorders

John J. Cush

Musculoskeletal disorders affect one in three (approximately 127 million) in the U.S., and account for 15–25% of all outpatient visits in the United States. The Centers for Disease Control and Prevention estimates that 54.4 million U.S. adults (22.7%) have physician-diagnosed arthritis. While many patients will have self-limited conditions requiring minimal evaluation and symptomatic therapy, specific musculoskeletal presentations may herald a more serious condition that requires further evaluation or laboratory testing to establish a diagnosis. The goal of the musculoskeletal evaluation is to formulate a differential diagnosis that leads to an accurate diagnosis and timely therapy, while avoiding excessive diagnostic testing and unnecessary treatment (Table 382-1). There are several urgent conditions that must be diagnosed promptly to avoid damage and morbidity. These "red flag" diagnoses include septic arthritis, acute crystal-induced arthritis (e.g., gout), and fracture. Each is suspected by an acute onset of monoarticular or focal musculoskeletal pain.

Most individuals with musculoskeletal complaints can be diagnosed with a thorough history and a comprehensive physical and musculoskeletal examination. The initial encounter should determine whether the musculoskeletal complaint signals a red flag condition (septic arthritis, gout, or fracture) or not. The evaluation should ascertain if the complaint is (1) *articular* or *nonarticular*, (2) *inflammatory* or *noninflammatory*, (3) *acute* or *chronic*, and (4) *localized (monoarticular)* or *widespread (polyarticular)*. The term arthralgia (joint pain) is not synonymous with arthritis, with the latter implying pathology of articular structures. Arthralgia is common and may be a symptom of arthritis.

By answering these four questions, the musculoskeletal presentation can be characterized (e.g., acute inflammatory monoarthritis or a chronic noninflammatory, nonarticular widespread pain) to narrow the diagnostic possibilities. Many musculoskeletal disorders resemble each other at the outset, and some may take weeks or months (but not years) to evolve into a recognizable diagnostic entity. This consideration should temper the desire to establish a definitive diagnosis at the first encounter.

TABLE 382-1 Evaluation of Patients with Musculoskeletal Complaints

Goals
Accurate diagnosis
Timely provision of therapy
Avoidance of unnecessary diagnostic testing
Identification of "red flag" conditions
Approach
Determine the chronology (acute vs chronic)
Determine the nature of the pathologic process (inflammatory vs noninflammatory)
Anatomic localization of complaint (articular vs nonarticular)
Determine the extent of involvement (monoarticular, polyarticular, focal, widespread)
Consider the most common disorders first
Consider the need for diagnostic testing
Formulate a differential diagnosis

ARTICULAR OR NONARTICULAR

The musculoskeletal evaluation must discriminate the anatomic origin(s) of the patient's complaint. For example, ankle pain may result from pathologic conditions involving disparate anatomic structures, including gouty arthritis, calcaneal fracture, Achilles tendinitis, plantar fasciitis, or entrapment neuropathy. Distinguishing between articular and nonarticular conditions requires a thorough examination. Articular structures include the synovium, synovial fluid, articular cartilage, intraarticular ligaments, joint capsule, and juxtaarticular bone. Nonarticular (or periarticular) structures, such as supportive extraarticular ligaments, tendons, bursae, muscle, fascia, bone, nerve, and overlying skin, may be involved in the pathologic process. Musculoskeletal complaints ascribed to the joints are more frequently of nonarticular origin and may be misconstrued as arthritis. Distinguishing between articular and nonarticular/periarticular pain may be challenging to the inexperienced examiner. Articular disorders are distinguished by deep or diffuse pain, limited range of motion on active and passive movement, and swelling (from synovial proliferation, effusion, or bony enlargement), crepitation, instability, "locking," or deformity. By contrast, nonarticular disorders tend to be painful on active, but not passive (or assisted), range of motion. Periarticular conditions often demonstrate point or focal tenderness in regions adjacent to articular structures, may radiate or be elicited with a specific movement or position, and have physical findings remote from the joint capsule. Nonarticular disorders seldom demonstrate swelling, crepitus, instability, or deformity.

INFLAMMATORY OR NONINFLAMMATORY

Early on, the examiner should determine whether the underlying pathologic process is inflammatory or noninflammatory. Inflammatory disorders may be infectious (*Neisseria gonorrhoeae* or *Mycobacterium tuberculosis*), crystal-induced (gout, pseudogout), immune-related (rheumatoid arthritis [RA], systemic lupus erythematosus [SLE]), reactive (rheumatic fever, reactive arthritis), or idiopathic. Inflammatory disorders may be suggested by any of the four cardinal signs of inflammation (erythema, warmth, pain, or swelling), systemic symptoms (fever, rash, weight loss), or laboratory evidence of inflammation (elevated erythrocyte sedimentation rate [ESR] or C-reactive protein [CRP], thrombocytosis, anemia of chronic disease, or hypoalbuminemia). Articular stiffness often accompanies chronic musculoskeletal disorders. The duration of stiffness may be prolonged (hours) with inflammatory disorders (such as RA or polymyalgia rheumatica [PMR]) and improves with activity. By contrast, short-lived or intermittent stiffness (also known as gel phenomenon) is typical of noninflammatory conditions (such as osteoarthritis [OA]), is brief in duration (≤45 min), and is exacerbated by activity. Fatigue may be profound with inflammation (as seen in RA and PMR) but may also be seen with fibromyalgia (a noninflammatory disorder), chronic pain, poor sleep, depression, anemia, cardiac failure, endocrinopathy, malnutrition, deconditioning, or chronic illness.

Noninflammatory disorders may be related to trauma (rotator cuff tear), repetitive use (bursitis, tendinitis), degeneration or ineffective repair (OA), neoplasm (pigmented villonodular synovitis), or pain amplification (fibromyalgia). Noninflammatory disorders are often characterized by pain without synovial swelling or warmth, absence of inflammatory or systemic features, intermittent gel phenomena and normal (for age) or negative laboratory investigations.

The musculoskeletal complaint can be refined and categorized by noting the chronology, pathology, locale, and distribution of the complaint (e.g., acute inflammatory monoarthritis, chronic noninflammatory, nonarticular widespread pain). Narrowing the diagnostic considerations can clarify the need for immediate diagnostic or therapeutic intervention or for continued observation. Figure 382-1 presents an algorithmic approach to the evaluation of patients with musculoskeletal complaints. This approach relies on clinical and historic features, rather than laboratory testing, to diagnose the most common rheumatic disorders.

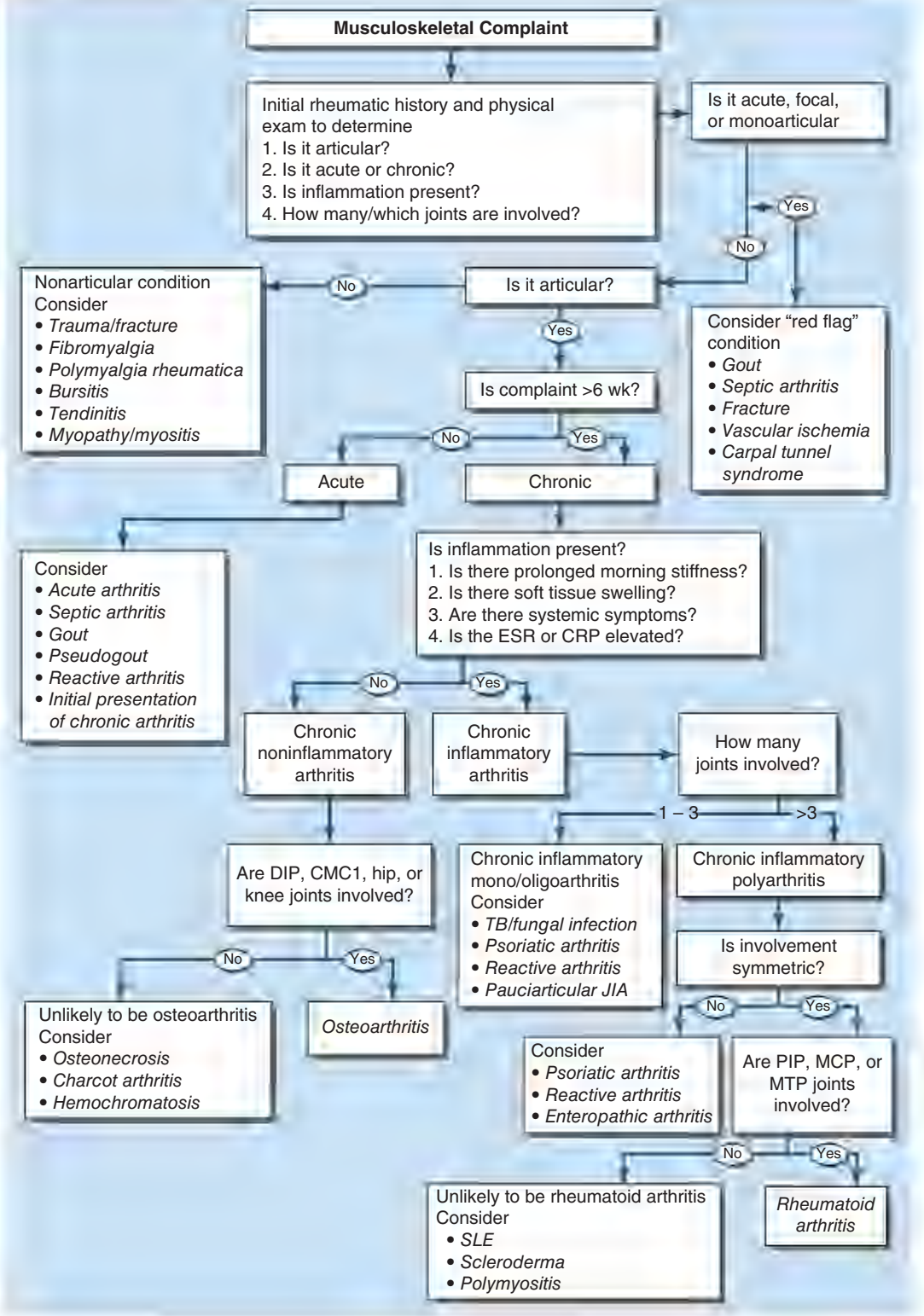

FIGURE 382-1 Algorithm for the diagnosis of musculoskeletal complaints. An approach to formulating a differential diagnosis (shown in italics). CMC, carpometacarpal; CRP, C-reactive protein; DIP, distal interphalangeal; ESR, erythrocyte sedimentation rate; JIA, juvenile idiopathic arthritis; MCP, metacarpophalangeal; MTP, metatarsophalangeal; PIP, proximal interphalangeal; PMR, polymyalgia rheumatica; SLE, systemic lupus erythematosus; TB, tuberculosis.

A simpler, alternative approach would consider the most commonly encountered conditions first, based on the age of the subject. The most prevalent causes of musculoskeletal complaints are shown in **Fig. 382-2**. Because trauma, fracture, low back pain, overuse syndromes, and fibromyalgia are among the most common causes of musculoskeletal pain, these should be considered with each new encounter. If excluded, other frequently occurring disorders should be considered according to the patient's age. Hence, those under age 60 years are commonly affected by repetitive use/strain disorders, gout (men only), RA, spondyloarthritis, and uncommonly, infectious arthritis. Patients over 60 years old are frequently affected by OA, crystal (gout and pseudogout) arthritis, PMR, osteoporotic fracture, and uncommonly, septic arthritis. Notably, these conditions are between 10 and 100 times more prevalent than other serious autoimmune conditions, such as SLE, systemic sclerosis (scleroderma), polymyositis, and vasculitis.

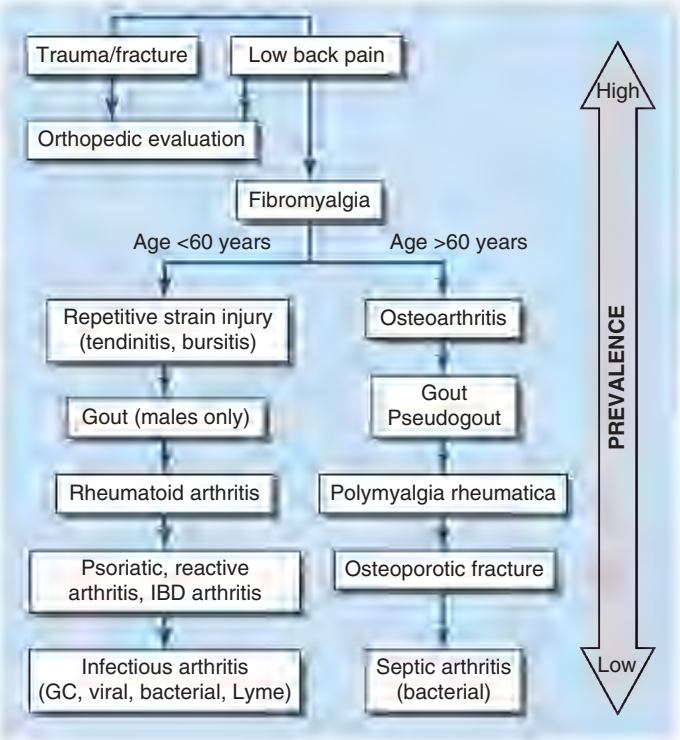

FIGURE 382-2 Algorithm for consideration of the most common musculoskeletal conditions. GC, gonococcal; IBD, inflammatory bowel disease.

CLINICAL HISTORY

Historic features may reveal important insights into the diagnosis. Aspects of the patient profile, complaint chronology, extent of joint involvement, and precipitating factors can provide important information. Certain diagnoses are more frequent in different *age* groups. SLE and gonococcal arthritis occur more frequently in young adults, whereas fibromyalgia and RA are frequent in middle age, and OA and PMR are more prevalent in the elderly. *Sex* and *race* should also be considered. Gout, spondyloarthritis, and ankylosing spondylitis are more common in men, whereas RA, lupus, fibromyalgia, osteoarthritis, and osteoporosis are more frequent in women. *Racial predilections* are common. Thus, PMR, giant cell arteritis, and granulomatosis with polyangiitis (GPA) commonly affect whites, whereas sarcoidosis and SLE more commonly affect African Americans. *Familial aggregation* is unlikely for most arthropathies but may be seen with ankylosing spondylitis, gout, and Heberden's nodes of OA.

The *onset, duration, and evolution* of the complaint are equally important. An abrupt onset is typical of septic arthritis or gout, whereas OA, RA, and fibromyalgia may have more indolent presentations. Musculoskeletal disorders are typically classified by symptom duration as either acute (≤6 weeks) or chronic (>6 weeks). Acute arthropathies tend to be infectious, crystal-induced, or reactive. Chronic conditions may include noninflammatory or immune-mediated (e.g., OA, RA, polymyositis) and nonarticular disorders (e.g., fibromyalgia).

The patients' complaints may evolve differently and be classified as chronic (OA), additive (RA, psoriatic arthritis), intermittent (crystal or Lyme arthritis), or migratory (rheumatic fever, gonococcal or viral arthritis).

The *distribution* of articular involvement is often informative. The number of joints involved defines the complaint as *monoarticular* (one joint), *oligoarticular* or *pauciarticular* (two or three joints), or *polyarticular* (four or more joints). Monoarticular and oligoarticular conditions share similar etiologies. While crystal and infectious arthritis are often mono- or oligoarticular, OA and RA are usually polyarticular. Nonarticular disorders may be classified as either focal or widespread. Tendinitis and carpal tunnel syndrome are typically focal, whereas weakness and myalgia (from polymyositis or fibromyalgia) have more widespread presentations. Joint involvement in RA tends to be symmetric and polyarticular. By contrast, spondyloarthritis, reactive arthritis, and gout are often asymmetric and oligoarticular. OA and psoriatic arthritis may be either symmetric or asymmetric and oligo- or polyarticular. The upper extremities are frequently involved in RA and OA, whereas lower extremity arthritis is characteristic of reactive arthritis and gout at their onset. Involvement of the spine is common in OA and axial spondyloarthritis but is infrequent in RA, with the notable exception of the cervical spine.

The clinical history may also identify *precipitating events*, such as trauma (osteonecrosis, meniscal tear), drug administration (Table 382-2),

TABLE 382-2 Drug-Induced Musculoskeletal Conditions

Arthralgias	Quinidine, cimetidine, beta blockers, quinolones, chronic acyclovir, interferons, IL-2, nicardipine, vaccines, rifabutin, aromatase inhibitors, HIV protease inhibitors, DPP-4 inhibitors (sitagliptin, linagliptin, alogliptin), paclitaxel, checkpoint inhibitors (ipilimumab, pembrolizumab, nivolumab, atezolizumab, durvalumab, cemiplimab), denosumab, teriparatide, abaloparatide, voriconazole
Myalgias/myopathy	Glucocorticoids, penicillamine, hydroxychloroquine, AZT, lovastatin, simvastatin, atorvastatin, pravastatin, clofibrate, amiodarone, interferon, IL-2, alcohol, cocaine, paclitaxel, docetaxel, imatinib mesylate, colchicine, quinolones, cyclosporine, tacrolimus, protease inhibitors, checkpoint inhibitors
Drug-induced dermatomyositis	Hydroxyurea, statins, lipid-lowering agents, penicillamine, immune checkpoint inhibitors, trastuzumab, and tumor necrosis factor inhibitors
Tendon rupture/tendinitis	Quinolones, glucocorticoids, isotretinoin, statins, aromatase inhibitors, collagenase injections
Drug-induced enthesitis	Dupilumab, voriconazole, immune checkpoint inhibitors, fluoroquinolones, retinoids and fluorinated agents
Gout	Diuretics, aspirin, cytotoxics, cyclosporine, tacrolimus, alcohol, moonshine, pyrazinamide, ethambutol, fructose-containing soft drinks, nicotinic acid.
Drug-induced lupus	Hydralazine, procainamide, quinidine, phenytoin, carbamazepine, methyldopa, isoniazid, chlorpromazine, lithium, penicillamine, tetracyclines, TNF inhibitors, ACE inhibitors, ticlopidine, terbinafine, aromatase inhibitors, ethosuximide, vedolizumab, immune checkpoint inhibitors, trastuzumab
Drug-induced subacute lupus	Proton pump inhibitors, calcium channel blockers (diltiazem), ACE inhibitors, TNF inhibitors, terbinafine, interferons (α and β-1a), paclitaxel, docetaxel, gemcitabine, capecitabine, aromatase inhibitors, HCTZ
Osteonecrosis/atypical fractures	Glucocorticoids, alcohol, radiation, bisphosphonates
Osteopenia	Glucocorticoids, chronic heparin, phenytoin, aromatase inhibitors, antiandrogen therapy, thiazolidinediones
Psoriasis	TNF inhibitors, beta blockers, lithium, hydroxychloroquine, chloroquine, minocycline, ACE inhibitors, terbinafine, checkpoint inhibitors
Systemic sclerosis (scleroderma)	Vinyl chloride, bleomycin, baricitinib, pentazocine, organic solvents, carbidopa, tryptophan, rapeseed oil
Raynaud's phenomenon	Cisplatin, bleomycin, beta blockers, clonidine, bromocriptine, ergot alkaloids, cocaine, methylphenidate, dextroamphetamine, phentermine, interferon therapy, tyrosine kinase inhibitors
Vasculitis	Allopurinol, amphetamines, cocaine (often levamisole adulterated), cannabis, thiazides, penicillamine, propylthiouracil, montelukast, TNF inhibitors, hepatitis B vaccine, trimethoprim/sulfamethoxazole, minocycline, hydralazine, apixaban

Abbreviations: ACE, angiotensin-converting enzyme; AZT, zidovudine; HCTZ, hydrochlorothiazide; IL-2, interleukin 2; TNF, tumor necrosis factor.

recent infection (reactive arthritis, hepatitis, chikungunya), or illnesses that may underlie the patient's complaint. Certain comorbidities may have musculoskeletal consequences. This is especially so for diabetes mellitus (carpal tunnel syndrome), renal insufficiency (gout), depression or insomnia (fibromyalgia), myeloma (spinal pain), cancer (myositis), and osteoporosis (fracture). Similarly, there may be musculoskeletal effects with drug use, such as glucocorticoids (osteonecrosis, septic arthritis), diuretics, or chemotherapy (gout) (Table 382-2).

Lastly, an adapted and thorough *rheumatic review of systems* may identify musculoskeletal diagnoses by their associated systemic features, such as fever (Still's disease, infection), rash (SLE, psoriatic arthritis), nail abnormalities (psoriatic or reactive arthritis), myalgias (fibromyalgia, statin- or drug-induced myopathy), or weakness (polymyositis, neuropathy). Musculoskeletal and autoimmune conditions can be suggested by involvement of other organ systems including the eyes (Behçet's disease, sarcoidosis, spondyloarthritis), gastrointestinal tract (systemic sclerosis, inflammatory bowel disease), genitourinary tract (reactive arthritis, gonococci), or nervous system (Lyme disease, vasculitis).

FIBROMYALGIA

Fibromyalgia is a common masquerader of musculoskeletal complaints and is often misdiagnosed or not considered. Fibromyalgia **(see Chap. 385)** is a pain amplification disorder heralded by sleep disturbance, exaggerated pain and sensitivity (owing to lowered pain thresholds), and a multiplicity of symptoms, yet a paucity of abnormalities on clinical examination or laboratory testing. Tender "trigger points" may be elicited over the epicondyles, trochanteric bursae, anserine bursae, and specific muscles (gluteal, trapezius, supraspinatus). Fibromyalgia is characterized by widespread aches and pains, even though presenting symptoms may be fewer or focal. Fibromyalgia often coexists with numerous comorbidities including irritable bowel syndrome, dysmenorrhea, migraine, depression, anxiety, memory loss, nonanatomic paresthesia or dysesthesia, fatigue, myalgias, temporomandibular joint pain, hypermobility, and multiple chemical sensitivities. Fibromyalgia affects over 5 million Americans. Early consideration of this very common disorder can avert needless investigation, therapy, and concern for those afflicted (Fig. 382-2).

THE ELDERLY PATIENT

The incidence of rheumatic diseases rises with age, such that 58% of those >65 years will have joint complaints. Musculoskeletal complaints in the elderly are usually ascribed to aging and arthritis, but may also be related to sarcopenia, deconditioning, poor sleep, and malnutrition. Musculoskeletal disorders may also be overlooked because the signs and symptoms may be insidious or overshadowed by comorbidities or care access issues. These difficulties are compounded by the diminished reliability of laboratory testing in the elderly, who often manifest nonpathologic abnormal results. For example, the ESR (that rises with age) may be misleadingly elevated, and low-titer positive tests for rheumatoid factor (RF) and antinuclear antibodies (ANAs) may be seen in up to 15% of elderly patients. Although nearly all rheumatic disorders afflict the elderly, geriatric patients are particularly prone to OA, osteoporosis, osteoporotic fractures, gout, pseudogout, rotator-cuff disorders, PMR, vasculitis, septic arthritis, depression, and drug-induced disorders (Table 382-2). The elderly should be approached in the same manner as other patients with musculoskeletal complaints, but with an emphasis on identifying the potential rheumatic consequences of comorbidities and therapies used in the elderly. The physical examination should identify the nature of the musculoskeletal complaint as well as coexisting diseases that may influence diagnosis and choice of treatment.

THE HOSPITALIZED PATIENT

The hospitalized patient with rheumatic complaints may pose a diagnostic challenge owing to symptom severity, acute plus chronic disease, and greater interplay of comorbidities. Patients with rheumatic disorders tend to be admitted for one of several reasons: (1) acute onset of inflammatory arthritis (possibly gout or septic arthritis); (2) undiagnosed systemic or febrile illness; (3) musculoskeletal trauma; (4) exacerbation or deterioration of an existing musculoskeletal disorder (e.g., SLE); or (5) new medical diagnoses (e.g., thrombotic event, lymphoma, infection) arising in patients with an established rheumatic disorder. Notably, patients with chronic inflammatory disorders (e.g., RA, SLE, psoriatic arthritis) are at increased risk of infection, cardiovascular events, pulmonary disorders, and neoplasia. Rheumatic patients need not be admitted to hospital for widespread pain, serologic abnormalities, or the initiation of new therapies.

Acute monoarticular inflammatory arthritis is a "red flag" presentation (e.g., septic arthritis, gout, pseudogout) that may require arthrocentesis and hospitalization if infection is suspected. New-onset inflammatory polyarthritis has a wide differential diagnosis (e.g., RA, hepatitis-related arthritis, chikungunya arthritis, serum sickness, drug-induced lupus, SLE, polyarticular septic arthritis) and may require targeted laboratory investigations more so than synovial fluid analyses. Patients with febrile, multisystem disorders require exclusion of crystal (gout, pseudogout), infectious, or neoplastic etiologies and an evaluation driven by the dominant symptom/finding with the greatest specificity. Febrile conditions worthy of consideration may include vasculitis (PMR, giant cell arteritis, GPA), adult-onset Still's disease, SLE, antiphospholipid syndrome, IgG4-related disease, and sarcoidosis. A preexisting rheumatic diagnosis (e.g., SLE, RA, ankylosing spondylitis) should be confirmed by careful history and examination and review of medical records, as this will influence the ensuing in-patient evaluation. Notably, when patients with established rheumatic disease are admitted to the hospital, it is usually not for their autoimmune disorder, but rather a comorbid or new medical problem or complication of drug therapy.

Acute gout, pseudogout, or infection, may arise during hospitalization and immobilization. Unfortunately, overly aggressive and unfocused laboratory testing may yield abnormal findings that are better explained by the patient's preexisting condition (chronic lung, renal, or liver disease) rather than a new inflammatory or autoimmune disorder (lupus, vasculitis).

MUSCULOSKELETAL EXAMINATION

The goal of the physical examination is to ascertain the structures involved, the nature of the underlying pathology, the functional consequences of the process, and the presence of systemic or extraarticular manifestations. A knowledge of topographic and functional anatomy is necessary to identify the primary site(s) of involvement and differentiate articular from nonarticular disorders. The musculoskeletal examination depends on careful inspection, palpation, contralateral comparison, and a variety of specific physical maneuvers to elicit diagnostic signs **(Table 382-3)**. Although most articulations of the appendicular skeleton can be examined in this manner, inspection and palpation are not possible for many axial (e.g., zygapophyseal) and inaccessible (e.g., sacroiliac or hip) joints. For such joints, there is a greater reliance on specific maneuvers and imaging for assessment.

Examination of involved and uninvolved joints will determine whether *pain, warmth, erythema*, or *swelling* is present. The locale and level of pain elicited by palpation or movement should be quantified. Examination of 28 easily palpated joints (proximal interphalangeals [PIPs], metacarpophalangeals [MCPs], wrists, elbows, shoulders, and knees) can quantify the number of tender or swollen joints (0–28) involved. Careful examination should distinguish between true articular swelling (caused by bony hypertrophy, synovial effusion or proliferation) and nonarticular (or periarticular) involvement, which usually extends beyond the normal joint margins. Cautious palpation can distinguish synovial effusion (fluctuant swelling) from synovial hypertrophy (grape-like compressibility) and bony hypertrophy (firm as a nut). Small to moderate knee effusions may be identified by the "bulge sign" or "ballottement of the patellae." Bursal effusions (e.g., effusions of the olecranon or prepatellar bursa) are often focal and periarticular, overlie

TABLE 382-3 Glossary of Musculoskeletal Terms

Crepitus	A palpable (less commonly audible) vibratory or crackling sensation elicited with joint motion; fine joint crepitus is common and often insignificant in large joints; coarse joint crepitus indicates advanced cartilaginous and degenerative changes (as in osteoarthritis)
Subluxation	Alteration of joint alignment such that articulating surfaces incompletely approximate each other
Dislocation	Abnormal displacement of articulating surfaces such that the surfaces are not in contact
Range of motion	For diarthrodial joints, the arc of measurable movement through which the joint moves in a single plane
Contracture	Loss of full movement resulting from a fixed resistance caused either by tonic spasm of muscle (reversible) or by fibrosis of periarticular structures (permanent)
Deformity	Abnormal shape, size, or alignment resulting from bony hypertrophy, malalignment of articulating structures, or damage to periarticular supportive structures
Enthesitis	Inflammation of the entheses (tendinous or ligamentous insertions on bone)
Epicondylitis	Infection or inflammation involving an epicondyle

bony prominences, and are fluctuant with defined borders. Joint *stability* (indicative of periarticular support and integrity) can be assessed by stabilizing the proximal joint and applying manual stress to the distal appendage in different planes. *Subluxation* or *dislocation*, which may be secondary to traumatic, mechanical, or inflammatory causes, can be assessed by inspection and palpation. Joint *swelling* or *volume* can be assessed by palpation. Distention of the articular capsule usually causes pain and evident enlargement or fluctuance. The patient will attempt to minimize the pain by maintaining the joint in the position of least intraarticular pressure and greatest volume (usually partial flexion). With chronicity, this may lead to flexion contracture. Active and passive *range of motion* should be assessed in all planes, with contralateral comparison. A goniometer may be used to accurately quantify the arc of movement. Each joint should be passively moved through its full range of motion (including, as appropriate, flexion, extension, rotation, abduction, adduction, lateral bending, inversion, eversion, supination, pronation, medial/lateral deviation, and plantar- or dorsiflexion). Extremes in range of motion and connective tissue laxity may be seen with hypermobility syndrome, Ehlers-Danlos syndrome, or Marfan's syndrome. Limitation of motion or contractures are frequently caused by inflammation, effusion, pain, deformity, or neuromyopathic causes. If passive motion exceeds active motion, a periarticular process (e.g., tendinitis, tendon rupture, or myopathy) should be considered. *Contractures* may reflect antecedent synovial inflammation, trauma, or chronic immobilization. Minor joint *crepitus* is common during joint palpation and maneuvers, but if it becomes coarser or louder, it may indicate significant cartilage degeneration and degenerative changes (e.g., OA). Joint *deformity* usually indicates a long-standing or aggressive pathologic process. Deformities may result from ligamentous destruction, soft tissue contracture, bony enlargement, ankylosis, erosive disease, subluxation, trauma, or loss of proprioception. Examination of the musculature will document strength, atrophy, pain, or spasm. Appendicular muscle weakness should be characterized as proximal or distal. Muscle strength should be assessed by observing the patient's performance (e.g., walking, rising from a chair, grasping, writing). Motor strength may also be graded on a 5-point scale: 0 for no movement; 1 for trace movement or twitch; 2 for movement with gravity eliminated; 3 for movement against gravity only; 4 for movement against gravity and resistance; and 5 for normal strength. The examiner should assess for (often overlooked) nonarticular or periarticular involvement, especially when articular complaints are not supported by objective findings referable to the joint capsule. The identification of soft tissue or nonarticular pain will prevent unwarranted and often expensive laboratory or imaging evaluations. Specific maneuvers may reveal common nonarticular abnormalities, such as a carpal tunnel syndrome (best identified by Durkan's test or Tinel's sign). Other examples of soft tissue abnormalities include olecranon bursitis, epicondylitis (e.g., tennis elbow), enthesitis (e.g., Achilles tendinitis), and tender trigger points associated with fibromyalgia.

REGIONAL RHEUMATIC COMPLAINTS

Focal musculoskeletal complaints may exhibit a predictable pattern of onset, evolution, and localization and are best diagnosed by their localization, along with select maneuvers or tests. Four commonly involved anatomic regions—the hand, shoulder, hip, and knee—are reviewed here.

HAND PAIN

Focal or unilateral hand pain may result from trauma, overuse, infection, or reactive or crystal-induced arthritis. By contrast, bilateral hand complaints commonly suggest a degenerative (e.g., OA), systemic, or inflammatory/immune (e.g., RA) etiology. The distribution or pattern of joint involvement is suggestive of certain disorders **(Fig. 382-3)**. Thus, OA (or degenerative arthritis) may manifest as distal interphalangeal (DIP) and PIP joint pain with bony hypertrophy leading to Heberden's and Bouchard's nodes, respectively. Pain, with or without bony swelling, involving the base of the thumb (first carpometacarpal joint) is also highly suggestive of OA. By contrast, RA manifests as an additive, symmetric, polyarticular arthritis involving the PIP, MCP, intercarpal, and carpometacarpal joints (wrist) with pain and palpable synovial tissue hypertrophy. Psoriatic arthritis may mimic the pattern of joint involvement seen in OA (DIP and PIP joints) but can be

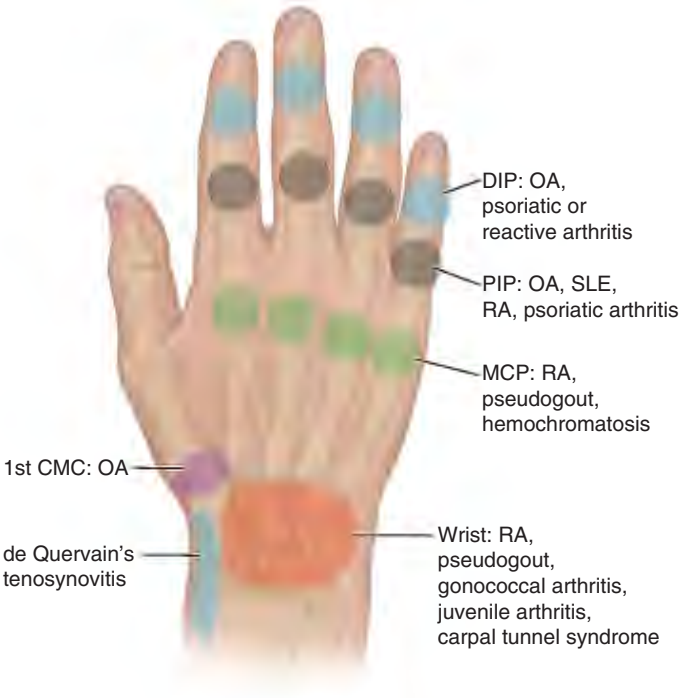

FIGURE 382-3 Sites of hand or wrist involvement and their potential disease associations. CMC, carpometacarpal; DIP, distal interphalangeal; MCP, metacarpophalangeal; OA, osteoarthritis; PIP, proximal interphalangeal; RA, rheumatoid arthritis; SLE, systemic lupus erythematosus. *(Reproduced with permission from JJ Cush et al [eds], Evaluation of musculoskeletal complaints, in Rheumatology: Diagnosis and Therapeutics, 2nd ed. Philadelphia, Lippincott Williams & Wilkins, 2005.)*

distinguished by the presence of inflammation (erythema, warmth, synovial swelling), with or without carpal involvement, nail pitting, or onycholysis. Whereas lateral or medial subluxations at the PIP or DIP joints are most likely due to inflammatory OA or psoriatic arthritis, dorsal or ventral deformities (swan neck or boutonnière deformities) are typical of RA. Hemochromatosis should be considered when degenerative changes (bony hypertrophy) are seen at the second and third MCP joints with associated radiographic chondrocalcinosis or episodic, inflammatory wrist arthritis.

Dactylitis manifests as soft tissue swelling of the whole digit and may have a sausage-like appearance. Common causes of dactylitis include psoriatic arthritis, spondyloarthritis, juvenile spondylitis, enthesitis-related arthropathy, mixed connective tissue disease, systemic sclerosis, sarcoidosis, and sickle cell disease. Soft tissue swelling over the dorsum of the hand and wrist may suggest an inflammatory extensor tendon tenosynovitis possibly caused by gonococcal infection, gout, tuberculosis, RA, or giant cell tumor. Tenosynovitis is suggested by swelling or pitting edema (with or without warmth) and may be confirmed when the soft tissue swelling tracks with tendon movement during flexion and extension of fingers, or when pain is induced while stretching the extensor tendon sheaths (flexing the digits distal to the MCP joints and maintaining the wrist in a fixed, neutral position). Volar (palmar) tendon swellings may be from tenosynovitis, Dupuytren's contractures, tendon nodules, or synovial cysts.

Focal wrist pain localized to the radial aspect may be caused by de Quervain's tenosynovitis resulting from inflammation of the tendon sheath(s) involving the abductor pollicis longus or extensor pollicis brevis (Fig. 382-3). This commonly results from occupational or repetitive overuse or follows pregnancy and can be diagnosed with Finkelstein's test. A positive test is present when radial wrist pain is induced after the thumb is flexed and placed inside a clenched fist and the patient actively deviates the hand downward with ulnar deviation at the wrist. Carpal tunnel syndrome is another common disorder of the upper extremity and results from compression of the median nerve within the carpal tunnel. Manifestations include pain in the wrist that may radiate with paresthesia to the thumb, second and third fingers, and radial half of the fourth finger and, at times, atrophy of thenar musculature. Carpal tunnel syndrome is commonly associated with pregnancy, edema, trauma, OA, inflammatory arthritis, and infiltrative disorders (e.g., amyloidosis). The diagnosis may be suggested by a positive Durkan's test or Tinel's sign. With each test, paresthesia in a median nerve distribution is induced or increased by 30 s of compression over the carpal tunnel (Durkan's test) or "thumping" the volar aspect of the wrist and median nerve (Tinel's sign). The low sensitivity and moderate specificity of these tests may require nerve conduction velocity testing to confirm a suspected diagnosis.

SHOULDER PAIN

Shoulder involvement is common in those with a history of trauma, fibromyalgia, infection, inflammatory arthritis, occupational risks, or previous cervical surgery or disease. The patient should be questioned as to the activities or movement(s) that elicit shoulder pain. While arthritis is suggested by pain on movement in all planes, pain with specific or active (not passive) motion suggests a periarticular (nonarticular) process. Shoulder pain may originate in the glenohumeral or acromioclavicular joints, subacromial (subdeltoid) bursa, or periarticular soft tissues (e.g., fibromyalgia, rotator cuff tear/tendinitis) **(Fig. 382-4)**. Shoulder pain may be referred from the cervical spine but may also be referred from intrathoracic lesions (e.g., a Pancoast tumor), gallbladder, liver, or diaphragmatic disease. These same visceral causes may also manifest as focal scapular pain. Fibromyalgia should be suspected when glenohumeral pain is accompanied by diffuse periarticular (i.e., subacromial, bicipital) pain, tender points (i.e., trapezius or supraspinatus), and a sleep disturbance. The shoulder should be put through its full range of motion, both active and passive (with examiner assistance) movements: forward flexion, extension, abduction, adduction, and internal and external rotation. Glenohumeral pain and pathology are best detected by placing the thumb anteriorly over the glenohumeral joint, just medial

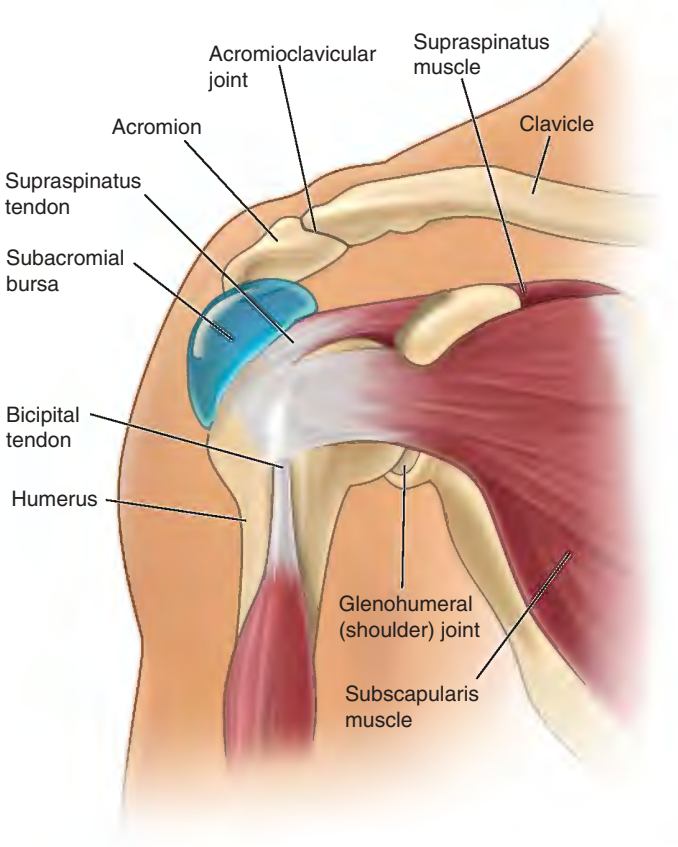

FIGURE 382-4 Origins of shoulder pain. The schematic diagram of the shoulder indicates, with *arrows*, the anatomic origins of shoulder pain.

and inferior to the coracoid process, and applying pressure anteriorly while internally and externally rotating the humeral head. Synovial effusion or tissue is seldom palpable in the shoulder, but, if present, may suggest infection, RA, amyloidosis, or an acute tear of the rotator cuff. The examiner should apply direct manual pressure over the subacromial bursa that lies lateral to and immediately beneath the acromion (Fig. 382-4). Subacromial bursitis is a frequent cause of shoulder pain. Anterior to the subacromial bursa, the bicipital tendon traverses the bicipital groove. This tendon is best identified by palpating it in its groove as the patient rotates the humerus internally and externally. Direct pressure over the tendon may reveal pain indicative of bicipital tendinitis. Palpation of the acromioclavicular joint may disclose local pain, bony hypertrophy, or, uncommonly, synovial swelling. Whereas OA and RA commonly involve the acromioclavicular joint, OA only involves the glenohumeral joint with trauma, occupational causes, or osteonecrosis.

Rotator cuff tendinitis or tears are a very common cause of shoulder pain, especially in those who are active, manual laborers or have inflammatory arthritis. Nearly 30% of the elderly with shoulder pain will have rotator cuff tendinitis or tear as a primary cause. The rotator cuff is formed by four tendons that attach the scapula to the proximal humerus (supraspinatus, infraspinatus, teres minor, and subscapularis tendons). Of these, the supraspinatus muscle is the most commonly damaged. Rotator cuff tendinitis is suggested by pain on active abduction (but not passive abduction), pain over the lateral deltoid muscle, night pain, and evidence of the impingement signs (pain with overhead arm activities). The Neer test for impingement is performed by the examiner raising the patient's arm into forced flexion while stabilizing and preventing rotation of the scapula. A positive sign is present if pain develops before 180° of forward flexion. Tear of the rotator cuff is common in the elderly and often results from trauma; it may manifest in the same manner as tendinitis. The drop arm test is abnormal with supraspinatus pathology and is demonstrated by passive abduction of the arm to 90° by the examiner. If the patient is

unable to hold the arm up actively or unable to lower the arm slowly without dropping, the test is positive. Tendinitis or tear of the rotator cuff is best confirmed by magnetic resonance imaging (MRI) or ultrasound.

KNEE PAIN

Knee pain may result from intraarticular (OA, RA) or periarticular (anserine bursitis, collateral ligament strain) processes or be referred from hip pathology (fracture). A careful history should delineate the chronology of the knee complaint and whether there are predisposing conditions, trauma, medications, or activities that may underlie the complaint. For example, patellofemoral disease (e.g., OA) may cause anterior knee pain that worsens with climbing stairs. Observing the patient's gait may identify a knee, hip, or foot disorder. The knee should be carefully inspected in the upright (weight-bearing) and supine positions for swelling, erythema, malalignment, visible trauma, muscle wasting, and leg length discrepancy (measuring from the anterior superior iliac crest to medial malleolus, with contralateral comparison). The most common malalignment in the knee is *genu varum* (bowlegs) or *genu valgum* (knock-knees) resulting from asymmetric cartilage loss medially or laterally, respectively. Bony swelling of the knee joint commonly results from hypertrophic osseous changes seen with disorders such as OA and neuropathic arthropathy. Swelling caused by hypertrophy of the synovium or synovial effusion may manifest as a fluctuant, ballotable, or soft tissue enlargement in the suprapatellar pouch (suprapatellar reflection of the synovial cavity) or regions lateral and medial to the patella. Synovial effusions may also be detected by balloting the patella downward toward the femoral groove or by eliciting a "bulge sign." With the knee extended, the examiner should manually compress, or "milk," synovial fluid down from the suprapatellar pouch and lateral to the patellae. The application of manual pressure lateral to the patella may cause an observable shift in synovial fluid (bulge) to the medial aspect. The examiner should note that this maneuver is only effective in detecting small to moderate effusions (<100 mL). Inflammatory disorders such as RA, gout, pseudogout, and psoriatic arthritis may involve the knee joint and produce significant pain, swelling, or warmth. A popliteal or *Baker's cyst* may be palpated with the knee partially flexed and is best viewed posteriorly with the patient standing and knees fully extended to visualize isolated or unilateral popliteal swelling or fullness.

Anserine bursitis is an often-missed periarticular cause of knee pain in adults. The pes anserine bursa underlies the insertion of the conjoined tendons (sartorius, gracilis, semitendinosus) on the anteromedial proximal tibia and may be painful following trauma, overuse, or inflammation (bursitis). It is often tender (rarely inflamed) in patients with fibromyalgia, obesity, and knee OA. Other forms of bursitis may also present as knee pain. The prepatellar bursa is superficial and is located over the inferior portion of the patella. The infrapatellar bursa is deeper and lies beneath the patellar ligament before its insertion into the tibial tubercle.

Internal derangement of the knee, from trauma or degenerative processes, implies mechanical disruption of articulating surfaces by damage to cartilage or ligaments or fracture. Damage to the meniscal cartilage (medial or lateral) frequently presents as chronic or intermittent knee pain. Such injury should be suspected when there is a history of trauma, athletic activity, or chronic knee arthritis, and when the patient relates symptoms of "locking," "buckling," or "giving way" of the knee. With the knee flexed 90° and the patient's foot on the table, pain elicited during palpation over the joint line or when the knee is stressed laterally or medially may suggest a meniscal tear. A positive McMurray test may also indicate a meniscal tear. To perform this test, the knee is first flexed at 90°, and the leg is then extended while the lower extremity is simultaneously torqued medially or laterally. A painful click during inward rotation may indicate a lateral meniscus tear, and pain during outward rotation may indicate a tear in the medial meniscus. Lastly, damage to the cruciate ligaments should be suspected with acute onset of pain, possibly with swelling, a history of trauma, or a synovial fluid aspirate that is grossly bloody. Examination of the cruciate ligaments is best accomplished by eliciting a drawer sign. With the patient recumbent, the knee should be partially flexed and the foot stabilized on the examining surface. The examiner should manually attempt to displace the tibia anteriorly or posteriorly with respect to the femur. If anterior movement is detected, then anterior cruciate ligament damage is likely. Conversely, significant posterior movement may indicate posterior cruciate damage. Contralateral comparison will assist the examiner in detecting significant anterior or posterior movement. Collateral ligament damage is suggested by pain on palpation or manual stretch of the ligament (medial or lateral).

HIP PAIN

The hip is best evaluated by observing the patient's gait and assessing range of motion. The vast majority of patients reporting "hip pain" localize their pain unilaterally to the posterior gluteal musculature (Fig. 382-5) with radiation down the posterolateral aspect of the thigh,

FIGURE 382-5 Origins of hip pain and dysesthesias. *(Reproduced with permission from JJ Cush et al [eds], Evaluation of musculoskeletal complaints, in Rheumatology: Diagnosis and Therapeutics, 2nd ed. Philadelphia, Lippincott Williams & Wilkins, 2005.)*

with or without associated low back pain. This presentation frequently results from degenerative arthritis of the lumbosacral spine or disks and commonly follows a dermatomal distribution with involvement of nerve roots between L4 and S1. Sciatica is caused by impingement of the L4, L5, or S1 nerve (i.e., from a herniated disk) and manifests as unilateral neuropathic pain extending from the gluteal region down the posterolateral leg to the foot. Some individuals instead localize their "hip pain" laterally to the area overlying the trochanteric bursa. Because of the depth of this bursa, swelling and warmth are usually absent. Diagnosis of trochanteric bursitis or enthesitis can be confirmed by inducing point tenderness over the trochanteric bursa. Gluteal and trochanteric pain are common findings in fibromyalgia. Range of movement may be limited by pain. Pain from the "true" hip joint is less common and tends to be located anteriorly, over the inguinal ligament; may radiate medially to the groin; and is worsened by adduction or rotation of the hip. Uncommonly, iliopsoas bursitis may mimic true hip joint pain. Pain associated with iliopsoas bursitis is localized to the groin or anterior thigh and tends to worsen with hyperextension of the hip; many patients prefer to flex and externally rotate the hip to reduce the pain from a distended iliopsoas bursa.

TELEHEALTH EVALUATION

Telemedicine has grown significantly in recent years as a means of remote patient assessment and clinical care. Engagement of patients via electronic telecommunication allows for virtual patient evaluations with a time, cost, and convenience advantage, but can be a disadvantage for the elderly or technologically disadvantaged populations. Telemedicine requires quality audio and video connections and is appropriate for patient education, monitoring, and routine disease assessments. Patients evaluated by telemedicine should undergo the same medical history and inquiry as a routine clinic evaluation but will differ in the scope of examination and maneuvers. The virtual (televideo) musculoskeletal examination may be appropriate and effective in many, with a reliance on functional observation, range of motion, patient self-examination, and contralateral comparison. Specifically, the televideo exam should assess the following: (1) patient gait (to assess lower extremity abnormalities); (2) rising from a seated position (to assess for weakness); (3) cervical range of motion (flexion, extension, lateral bending); (4) upper extremity assessment by contralateral comparison (e.g., "praying hands," "make a fist," "flex wrists," and "hands on ears, elbows out" to assess shoulder range of motion); and (5) side-by-side inspection of knees, ankles, and feet. Telehealth evaluations are contingent on clinical experience, knowledge of and familiarity with the patient, and training the patient on the use of technology and goals and limits of a televideo visit. Telephone-only assessments do not qualify as telehealth visits.

LABORATORY INVESTIGATIONS

Most musculoskeletal disorders can be logically diagnosed by a complete history and physical examination. An additional objective of the initial encounter is to determine whether additional investigations or immediate therapy is required. Laboratory evaluation is indicated with (1) monoarticular presentations; (2) traumatic or inflammatory conditions; (3) the presence of neurologic findings; (4) systemic manifestations; or (5) chronic symptoms (>6 weeks) and a lack of response to symptomatic measures. The extent and nature of the additional investigation should be dictated by the clinical features and suspected pathologic process. Laboratory tests should be used to confirm a specific clinical diagnosis and not be used to screen or evaluate patients with vague rheumatic complaints. Indiscriminate use of broad batteries of diagnostic tests and radiographic procedures is rarely a useful or cost-effective means to establish a diagnosis.

Besides a complete blood count, including a white blood cell (WBC) and differential count, the routine evaluation should include a determination of an acute-phase reactant such as the ESR or CRP, which can be useful in discriminating inflammatory from noninflammatory disorders. Both are inexpensive, easily obtained, and may be elevated with infection, inflammation, autoimmune disorders, neoplasia, pregnancy, renal insufficiency, advanced age, or hyperlipidemia. Extreme elevation of the acute-phase reactants (CRP, ESR) is seldom seen without evidence of serious illness (e.g., sepsis, pleuropericarditis, PMR, giant cell arteritis, Still's disease). Conversely, not all active, inflammatory or autoimmune conditions will have an elevated ESR or CRP; in active SLE and RA patients, nearly 50% will have normal ESR and CRP results.

Serum uric acid determinations are useful in the diagnosis of gout and in monitoring the response to urate-lowering therapy. Uric acid, the product of purine metabolism, is primarily excreted in the urine. Serum values range from 238 to 516 μmol/L (4.0–8.6 mg/dL) in men; lower values (178–351 μmol/L [3.0–5.9 mg/dL]) seen in women are caused by the uricosuric effects of estrogen. Urinary uric acid levels are normally <750 mg per 24 h. Although hyperuricemia is associated with an increased incidence of gout and nephrolithiasis, levels may not correlate with the severity of disease. Uric acid levels (and the risk of gout) may be increased by inborn errors of metabolism (Lesch-Nyhan syndrome), disease states (renal insufficiency, myeloproliferative disease, psoriasis), or drugs (alcohol, cytotoxic therapy, thiazides). Although nearly all patients with gout will demonstrate hyperuricemia at some time during their illness, up to 50% of patients will have normal serum uric acid levels during an acute gouty attack. Monitoring serum uric acid is useful in assessing the response to urate-lowering therapy or chemotherapy, with the target goal being a serum urate <6 mg/dL (<5 mg/dL if tophi are present).

Serologic tests for RF, cyclic anti-citrullinated peptide (CCP or ACPA) antibodies, ANAs, complement levels, Lyme and antineutrophil cytoplasmic antibodies (ANCAs), or antistreptolysin O (ASO) titer should be carried out only when there is sufficient clinical evidence to suggest a specific diagnosis. These have poor predictive value when used for screening, particularly when the pretest probability is low. There is little value to repeated or serial serologic testing. Although 4–5% of a healthy population will have positive tests for RF and ANAs, only 1% and <0.4% of the population will have RA or SLE, respectively. IgM RF (autoantibodies against the Fc portion of IgG) is found in 80% of patients with RA and is moderately specific as it may also be seen in low titers in patients with chronic infections (tuberculosis, leprosy, hepatitis); other autoimmune diseases (SLE, Sjögren's syndrome); and chronic pulmonary, hepatic, or renal disease. When considering RA, both serum RF and anti-CCP antibodies should be obtained, as these are complementary. Both are comparably sensitive, but CCP antibodies are more specific than RF. In RA, the presence of high titers of anti-CCP or RF antibodies, or double positivity, may indicate a greater risk for more severe, erosive polyarthritis. ANAs are found in nearly all patients with SLE and may also be seen in patients with other autoimmune diseases (polymyositis, systemic sclerosis, antiphospholipid syndrome, Sjögren's syndrome), drug-induced lupus (Table 382-2), chronic thyroid, liver, or renal disorders, and advanced age. Positive ANAs are found in 5% of adults, up to 15% of elderly or chronically ill individuals, and up to 80% of patients with thyroid disease. The ANA test is very sensitive but poorly specific for lupus, as only 1–2% of all positive results will be caused by lupus alone. The interpretation of a positive ANA test may depend on the magnitude of the titer and the pattern observed by immunofluorescence microscopy **(Table 382-4)**. Diffuse and speckled patterns are least specific, whereas a peripheral, or rim, pattern (related to autoantibodies against double-strand [native] DNA) is highly specific and suggestive of lupus. Centromeric patterns are seen in patients with limited cutaneous systemic sclerosis (*c*alcinosis, *R*aynaud's phenomenon, *e*sophageal involvement, *sclero*dactyly, *t*elangiectasia [CREST] syndrome), primary biliary sclerosis, Sjögren's syndrome, or thyroiditis, and nucleolar patterns may be seen in patients with diffuse cutaneous systemic sclerosis or inflammatory myositis. More detailed serologic autoantibody profiling may be appropriate when specific autoimmune disorders (Sjögren's, dermatomyositis, systemic sclerosis) are diagnosed, but should not be employed as screening tests.

Aspiration and analysis of synovial fluid are always indicated in acute monoarthritis or when an infectious or crystal-induced arthropathy is suspected. Synovial fluid may distinguish between noninflammatory

TABLE 382-4 Antinuclear Antibody (ANA) Patterns and Clinical Associations

ANA PATTERN	ANTIGEN IDENTIFIED	CLINICAL CORRELATE
Diffuse	Deoxyribonucleoprotein	Nonspecific
	Histones	Drug-induced lupus, lupus
Peripheral (rim)	ds-DNA	50% of SLE (specific)
Speckled	U1-RNP	>90% of MCTD
	Sm	30% of SLE (specific)
	Ro (SS-A)	Sjögren's 60%, SCLE, neonatal lupus, ANA (–) lupus
	La (SS-B)	50% of Sjögren's, 15% lupus
	Scl-70 (topoisomerase I)	40% of diffuse cutaneous systemic sclerosis
	Jo-1 (histidyl t-RNA synthetase)	PM with pneumonitis + arthritis
Nucleolar	RNA polymerase I, others	40% of PSS
Centromere	Kinetochore	75% CREST (limited cutaneous systemic sclerosis), PBC, Sjögren's, thyroiditis

Abbreviations: CREST, *c*alcinosis, *R*aynaud's phenomenon, *e*sophageal involvement, *s*clerodactyly, and *t*elangiectasia; MCTD, mixed connective tissue disease; PBC, primary biliary cirrhosis; PSS, progressive systemic sclerosis; SCLE, subacute cutaneous lupus erythematosus; SLE, systemic lupus erythematosus.

and inflammatory processes by analysis of the appearance, viscosity, and cell count. Tests for synovial fluid glucose, protein, lactate dehydrogenase, lactic acid, or autoantibodies are not recommended as they have no diagnostic value. Normal synovial fluid is clear or a pale straw color and is viscous, primarily because of the high levels of hyaluronate. Noninflammatory synovial fluid is clear, viscous, and amber-colored, with a WBC count of <2000/μL and a predominance of mononuclear cells. The viscosity of synovial fluid is assessed by expressing fluid from the syringe one drop at a time. Normally, there is a stringing effect, with a long tail behind each synovial drop. Effusions caused by OA or trauma will have normal viscosity or "string sign." Inflammatory fluid is turbid and yellow, with an increased WBC count (2000–50,000/μL) and a polymorphonuclear leukocyte predominance. Inflammatory fluid has reduced viscosity (no stringing), diminished hyaluronate, and little or no tail following each drop of synovial fluid. Such effusions are found in RA, gout, and other inflammatory arthritides. Septic fluid is opaque and purulent, with a WBC count usually >50,000/μL, a predominance of polymorphonuclear leukocytes (>75%), and low viscosity. Such effusions are typical of septic arthritis but may also occur with RA or gout. Lastly, hemorrhagic synovial fluid (hemarthrosis) may be seen with trauma (ligament or cartilage tears), osteochondral fracture, neuropathic arthritis, or coagulopathy. An algorithm for synovial fluid aspiration and analysis is shown in Fig. 382-6. Synovial fluid should be analyzed immediately for appearance, viscosity, and cell count. Monosodium urate crystals (observed in gout) are seen by polarized microscopy and are long, needle-shaped, negatively birefringent, and usually intracellular. In chondrocalcinosis and pseudogout, calcium pyrophosphate dihydrate crystals are usually short, rhomboid-shaped, and positively birefringent. Whenever infection is suspected, synovial fluid should be Gram stained and cultured and tested by metagenomic sequencing, when appropriate. If gonococcal arthritis is suspected, nucleic acid amplification tests should be used to detect either *Chlamydia trachomatis* or *N. gonorrhoeae* infection. Synovial fluid from patients with chronic monoarthritis should also be cultured for *M. tuberculosis* and fungi. Last, it should be noted that crystal-induced arthritis and septic arthritis occasionally occur together in the same joint.

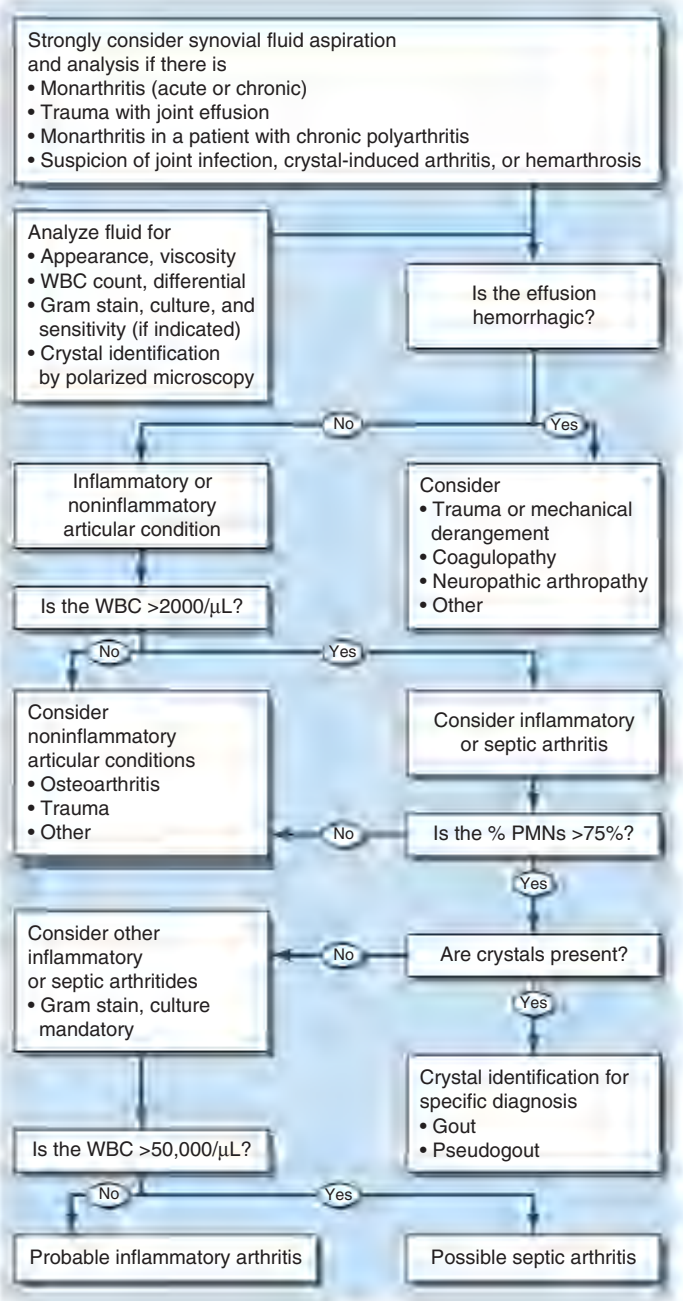

FIGURE 382-6 Algorithmic approach to the use and interpretation of synovial fluid aspiration and analysis. PMNs, polymorphonuclear (leukocytes); WBC, white blood cell count.

DIAGNOSTIC IMAGING

Conventional radiography has been a valuable tool in the diagnosis and staging of articular disorders. Plain x-rays are most appropriate and cost effective when there is a history of trauma, suspected chronic infection, progressive disability, or monoarticular involvement; when therapeutic alterations are considered; or when a baseline assessment is desired for what appears to be a chronic process. However, in acute or early arthritis, early radiography is rarely helpful in establishing a diagnosis and may only reveal soft tissue swelling or juxtaarticular demineralization. As the disease progresses, conventional radiographs may disclose calcification (of soft tissues, cartilage, or periarticular bone), joint space narrowing, erosions, bony ankylosis, new bone formation (sclerosis, osteophytes, or periostitis), or subchondral cysts may develop and suggest specific clinical entities. Advanced imaging with computed tomography (CT) or magnetic resonance imaging (MRI) is more expensive but may reveal the extent of articular or periarticular involvement. Consultation with a radiologist will help define the optimal imaging modality, technique, or positioning to optimize interpretation and prevent the need for further studies.

Additional imaging techniques may be indicated in selected circumstances or when conventional radiography is inadequate or

nondiagnostic (Table 382-5). *Ultrasonography* is useful in the detection of soft tissue abnormalities (tendinitis, tenosynovitis, enthesitis, bursitis), crystal deposition, and entrapment neuropathies. Lower cost, better technology, and enhanced site-specific transducers now allow for wider use and diagnostic specificity, especially when considering synovial (Baker's) cysts, rotator cuff tears, tendinitis (PMR) and tendon injury, and crystal deposition on cartilage. Use of power Doppler allows for early detection of synovitis and bony erosions. *Radionuclide scintigraphy* is a very sensitive, but poorly specific, means of detecting inflammatory or metabolic alterations in bone or periarticular soft tissue structures (Table 382-5). Scintigraphy is best suited for total-body assessment (extent and distribution) of skeletal involvement (neoplasia, Paget's disease) or the assessment of patients with undiagnosed polyarthralgias, looking for occult arthritis or inflammation. The use of scintigraphy has declined with greater use, specificity, and declining cost of ultrasound and MRI. MRI has largely replaced scintigraphy in diagnosing osseous infection, neoplasia, inflammation, increased blood flow, bone remodeling, heterotopic bone formation, or avascular necrosis. Gallium scanning uses ^{67}Ga, which binds serum and cellular transferrin and lactoferrin and is preferentially taken up by neutrophils, macrophages, bacteria, and tumor tissue (e.g., lymphoma). As such, it is primarily used in the identification of occult infection or malignancy. Scanning with ^{111}In-labeled WBCs has been used to detect osteomyelitis and infectious or inflammatory arthritis. Despite their utility, ^{111}In-labeled WBC and ^{67}Ga scanning have also been largely replaced by MRI, except when there is a suspicion of septic joint or prosthetic joint infections.

CT provides detailed visualization of the axial skeleton. Articulations previously considered difficult to visualize by radiography (e.g., zygapophyseal, sacroiliac, sternoclavicular, hip joints) can be evaluated using CT. CT has been demonstrated to be useful in the diagnosis of low back pain (e.g., spinal stenosis vs herniated disk), sacroiliitis, osteoid osteoma, and stress fractures. Helical or spiral CT (with or without contrast angiography) is a novel technique that is rapid, cost effective, and sensitive in diagnosing pulmonary embolism or obscure fractures, often in the setting of initially equivocal findings. High-resolution CT can be advocated in the evaluation of suspected or established infiltrative lung disease (e.g., systemic sclerosis or rheumatoid lung). The recent use of hybrid (positron emission tomography [PET] or single-photon emission CT [SPECT]) CT scans in metastatic evaluations has incorporated CT to provide better anatomic localization of scintigraphic abnormalities.

^{18}F-Fluorodeoxyglucose (FDG) is the most used radiopharmaceutical in PET scanning. FDG-PET/CT scans are rarely indicated in septic or inflammatory arthritis but have been useful in the evaluation of patients with undiagnosed fever, systemic illness, or suspected large vessel vasculitis. FDG-PET may be better at assessing inflammation, whereas MRI and CT can better define the extent of tissue damage. Dual-energy CT (DECT) scanning, developed in urology to identify urinary calculi, has been a highly sensitive and specific method used to identify and quantify uric acid deposition in tissues (Fig. 382-7).

MRI has significantly revolutionized the imaging of musculoskeletal structures, especially in patients with traumatic, systemic, infectious, or neoplastic disorders. MRI has the advantages of providing multiplanar images with fine anatomic detail and contrast resolution (Fig. 382-8) to visualize fascia, vessels, nerve, muscle, cartilage, ligaments, tendons, pannus, synovial effusions, and bone marrow.

Because of its sensitivity to changes in marrow fat, MRI is a sensitive but nonspecific means of detecting osteonecrosis, osteomyelitis, and marrow inflammation indicating overlying synovitis or osteitis (Fig. 382-8). Because of its enhanced soft tissue resolution, MRI is more sensitive than arthrography or CT in the diagnosis of soft tissue injuries (e.g., meniscal and rotator cuff tears); intraarticular derangements; marrow abnormalities (osteonecrosis, myeloma); and spinal cord or nerve root damage, synovitis, or cartilage damage or loss. Although more costly with a longer procedural time than CT, MRI has become the preferred technique when evaluating trauma and complex musculoskeletal disorders.

TABLE 382-5 Diagnostic Imaging Techniques for Musculoskeletal Disorders

METHOD	COST[a]	CURRENT INDICATIONS	CAVEATS
Ultrasound	++	Synovial (Baker's) cysts Rotator cuff tears Bursitis, tendinitis, tendon injury Enthesitis Carpal tunnel syndrome Urate or calcium pyrophosphate deposition on cartilage Early detection of synovial inflammation or erosions Ultrasound-guided injection/arthrocentesis	Operator dependent
Radionuclide scintigraphy	++	Metastatic bone survey Evaluation of Paget's disease Identifying occult arthritis in patients with undiagnosed polyarthralgia Acute infection Prosthetic infection Acute osteomyelitis Acute and chronic infection Acute osteomyelitis	Low sensitivity Resolution issues
^{99m}Tc	++	Arthritis Inflammation Degeneration Metastases Infection	Ionizing radiation exposure
^{111}In-WBC	+++	Septic arthritis	
^{67}Ga	++++	Prosthetic joint infection	
Computed tomography (CT)	++++	Herniated intervertebral disk Sacroiliitis Spinal stenosis Spinal trauma Osteoid osteoma Stress fracture	Ionizing radiation exposure Contrast use Availability of CT angiography
Dual-energy CT	+++	Uric acid deposition Tophus localization	Not widely available
Magnetic resonance imaging	++++	Avascular necrosis Osteomyelitis Septic arthritis, infected prosthetic joints Sacroiliitis Intraarticular derangement and soft tissue injury Derangements of axial skeleton and spinal cord Herniated intervertebral disk Pigmented villonodular synovitis Inflammatory and metabolic muscle pathology	Cost Contrast use No ionizing radiation Soft tissue detail
FDG-PET CT	+++++++		Very expensive Whole-body scanning Limited availability Ionizing radiation exposure

[a]Imaging cost, relative to conventional radiography.

Abbreviations: FDG-PET, fluorodeoxyglucose–positron emission tomography; WBC, white blood cell.

FIGURE 382-7 Dual-energy computed tomography (DECT) scan from a 45-year-old woman with right ankle swelling around the lateral malleolus. Three-dimensional volume-rendered coronal reformatted DECT image shows that the mass is composed of monosodium urate (*red*) in keeping with tophus (*arrow*). *(Reprinted from S Nicolaou et al: Dual-energy CT as a potential new diagnostic tool in the management of gout in the acute setting. AJR Am J Roentgenol 194:1072, 2010.)*

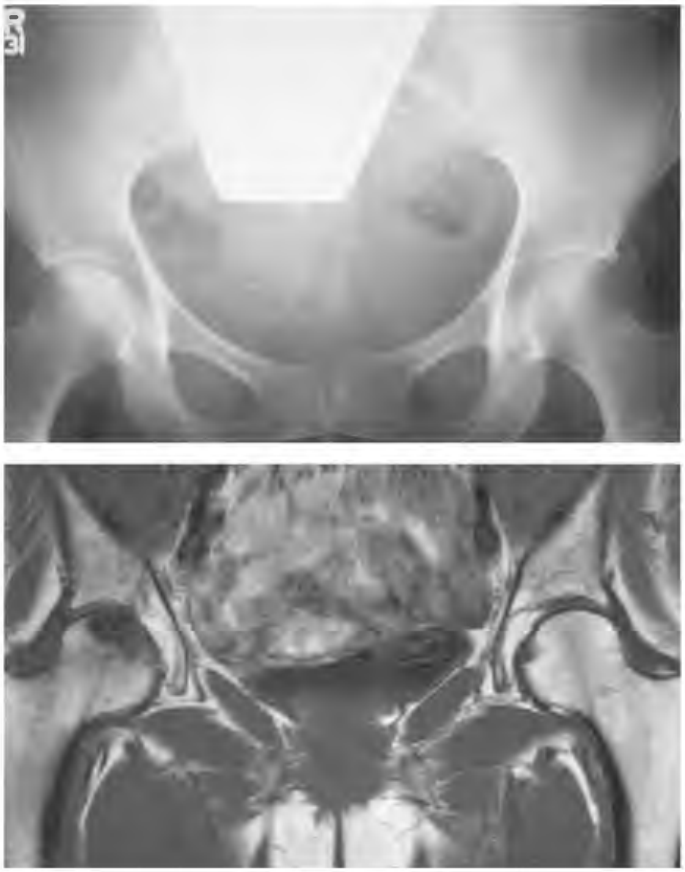

FIGURE 382-8 Superior sensitivity of magnetic resonance imaging (MRI) in the diagnosis of osteonecrosis of the femoral head. A 45-year-old woman receiving high-dose glucocorticoids developed right hip pain. Conventional x-rays (*top*) demonstrated only mild sclerosis of the right femoral head. T1-weighted MRI (*bottom*) demonstrated low-density signal in the right femoral head, diagnostic of osteonecrosis.

Acknowledgment

The author acknowledges the sage contributions of Dr. Peter E. Lipsky to this chapter in previous editions.

FURTHER READING

Cush JJ et al: Evaluation of musculoskeletal complaints. Available from *http://www.rheumaknowledgy.com/evaluation-of-musculoskeletal-complaints*. Accessed April 22, 2024.

Hubbard MJ et al: Common soft tissue musculoskeletal pain disorders. Prim Care 45:289, 2018.

Laskowski ER et al: The telemedicine musculoskeletal examination. Mayo Clinic Proc 95:1715, 2020.

Nguyen AT et al: Musculoskeletal health: An ecological study assessing disease burden and research funding. Lancet Reg Health Am 29:100661, 2024.

Olsen NJ, Karp DR: Finding lupus in the ANA haystack. Lupus Sci Med 7:e000384, 2020.

Rönnelid J et al: Autoantibodies in rheumatoid arthritis: Laboratory and clinical perspectives. Front Immunol 12:685312, 2021.

Rudwaleit M et al: How to diagnose axial spondyloarthritis early. Ann Rheum Dis 63:535, 2004.

Sciascia S et al: Autoantibodies testing in autoimmunity: Diagnostic, prognostic and classification value. Autoimmun Rev 22:103356, 2023.

Simpfendorfer CS: Radiologic approach to musculoskeletal infections. Infect Dis Clin North Am 31:299, 2017.