Recent guidelines recommend against the use of glucosamine or chondroitin for OA. Large publicly supported trials have failed to show that, compared with placebo, these compounds relieve pain in persons with disease. Curcumin has anti-inflammatory effects and may alleviate pain in OA.

Optimal pharmacologic therapy for OA is often achieved by trial and error, with each patient having idiosyncratic responses to specific treatments. Placebo (or contextual) effects may account for 50% of more of treatment effects in OA, and certain modes of treatment delivery including intraarticular injections have greater contextual effects than others such as pills. When medical therapies have failed and the patient has an unacceptable reduction in their quality of life and ongoing pain and disability, then at least for knee and hip OA, total joint arthroplasty is indicated.

SURGERY

Based on data from randomized trials, the efficacy of arthroscopic debridement and lavage in persons with OA is no greater than that of sham surgery for relief of pain or disability. Further, if a meniscal tear is present, as is often the case in persons with knee OA, trials have shown that arthroscopic meniscectomies do not relieve knee pain or improve function long-term, nor do they reduce catching or locking symptoms.

On the other hand, for patients with knee OA isolated to the medial compartment, operations to realign the knee to lessen medial loading can relieve pain. These include a high tibial osteotomy, in which the tibia is broken just below the tibial plateau and realigned to load the lateral, nondiseased compartment, or a unicompartmental replacement with realignment. Each surgery may provide the patient with years of pain relief before a total knee replacement is required.

Ultimately, when the patient with knee or hip OA has failed nonsurgical treatments with limitations of pain or function that compromise their quality of life, patients with reasonable expectations and readiness for surgery should be referred for total knee or hip arthroplasty. These are highly efficacious operations that relieve pain and improve function in the vast majority of patients, although pain elimination occurs in almost all patients getting a hip replacement but only ~80% of those undergoing knee replacement. Currently, failure rates from loosening or infection for both are ~1% per year, with higher rates in obese patients. The chance of surgical success is greater in centers where at least 25 such operations are performed yearly or with surgeons who perform multiple operations annually. The timing of knee or hip replacement is critical. If the patient suffers for many years until their functional status has declined substantially, with considerable muscle weakness, postoperative functional status may not improve to a level achieved by others who underwent operation earlier in their disease course.

Cartilage Regeneration Chondrocyte transplantation has not been found to be efficacious in OA, perhaps because OA includes pathology of joint mechanics, which is not corrected by chondrocyte transplants. Similarly, abrasion arthroplasty (chondroplasty) has not been well studied for efficacy in OA, but it produces fibrocartilage in place of damaged hyaline cartilage. Both surgical attempts to regenerate and reconstitute articular cartilage are more likely to be efficacious early in disease when joint malalignment and many of the other noncartilage abnormalities that characterize OA have not yet developed.

FURTHER READING

De Roover A et al: Fundamentals of osteoarthritis: Inflammatory mediators in osteoarthritis. Osteoarthritis Cart 31:1303, 2023.

Katz JN et al: Diagnosis and treatment of hip and knee osteoarthritis: A review. JAMA 325:568, 2021.

Kolasinski SL et al: 2019 American College of Rheumatology/Arthritis Foundation guideline for the management of osteoarthritis of the hand, hip, and knee. Arthritis Rheumatol 72:220, 2020.

384 Gout and Other Crystal-Associated Arthropathies

Hyon K. Choi

The use of polarizing light microscopy during synovial fluid analysis in 1961 by McCarty and Hollander and the subsequent application of other crystallographic techniques, such as electron microscopy, energy-dispersive elemental analysis, and x-ray diffraction, have allowed investigators to identify the pathogenic roles of different microcrystals, including monosodium urate (MSU), calcium pyrophosphate (CPP), calcium apatite (apatite), and calcium oxalate (CaOx), in inducing acute or chronic arthritis or periarthritis **(Table 384-1)**. The clinical manifestations that result from these crystals have substantial similarities but also have notable differences. Given their therapeutic implications, the need to perform synovial fluid analysis to distinguish the type of crystal involved should be emphasized. Polarized light microscopy alone can identify most typical crystals, except for apatite. Aspiration and analysis of effusions are also important to assess the possibility of infection. Crystal shedding from inert deposits triggered by certain factors is considered a key process behind episodic manifestation of acute inflammation (gout or pseudogout) involving activation of inflammasome and potent proinflammatory cytokines such as interleukin (IL) 1β. Furthermore, physical, inflammatory, and catalytic effects (involving metalloproteinase, collagenase, or prostaglandin E_2) of crystal deposits on the cartilage and other joint structures can lead to chronic erosive or destructive changes in the articular structures.

GOUT

PATHOGENESIS

Gout is a hyperuricemic metabolic condition, typically manifested by episodic inflammatory arthritis with disabling pain, typically among middle-aged to elderly men and postmenopausal women. It stems from an increased body pool of urate due to chronic hyperuricemia, leading to supersaturation and crystal formation of MSU within the joints and connective tissue and inflammatory reactions to the crystals **(Fig. 384-1)**. Although chronic hyperuricemia is a prerequisite for the development of gout, other factors influence subsequent MSU crystallization and inflammatory reactions (Fig. 384-1); a minority of hyperuricemic individuals develop gout during their lifetime. Considered often as a part of the insulin resistance syndrome, hyperuricemia and gout are associated with multiple cardiometabolic-kidney comorbidities, including obesity, hypertension, type 2 diabetes, myocardial infarction, stroke, chronic kidney disease (CKD), and urate nephrolithiasis; modifiable

TABLE 384-1 Musculoskeletal Manifestations of Crystal-Induced Arthritis

Acute arthritis (episodic)
Mono-, oligo-, or polyarthritis
Periarticular inflammation
Bursitis
Tendinitis
Enthesitis
Tophaceous deposits
Chronic arthropathy
Destructive arthropathies
Chronic inflammatory arthritis
Peculiar type of osteoarthritis
Spinal arthritis
Carpal tunnel syndrome

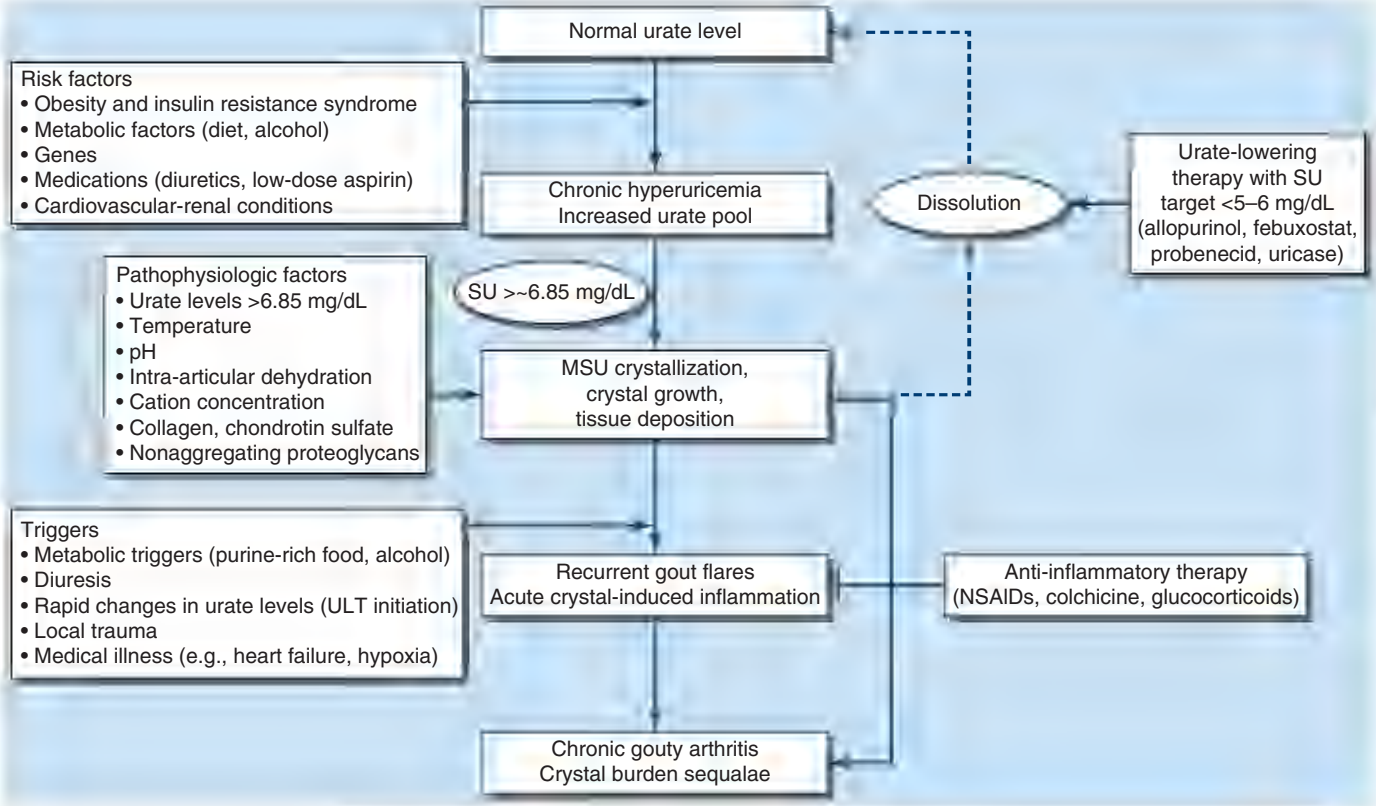

FIGURE 384-1 Pathogenesis of gout and therapeutic targets. Metabolic and some genetic factors contribute to the development of chronic hyperuricemia. Gout stems from an increased body pool of urate due to chronic hyperuricemia, leading to supersaturation and crystal formation and deposition of monosodium urate (MSU; tophi) within the joints and connective tissue. Synovial tophi are usually walled off, but certain triggers may loosen them from the organic matrix, leading to crystal shedding and interaction with synovial cell lining and residential inflammatory cells, initiating an acute gout flare. In some individuals, growing MSU crystal deposition leads to chronic gouty arthritis with subcutaneous tophi. Anti-inflammatory therapy targets the downstream process of crystal-induced inflammation, whereas ultimate control of gout requires correction of the underlying central cause, chronic hyperuricemia with increased urate pool. NSAIDs, nonsteroidal anti-inflammatory drugs; SU, sodium urate; ULT, urate-lowering therapy.

risk factors include obesity, Western diet, alcohol, sedentary lifestyle, and diuretics (Fig. 384-1).

Humans are the only mammals known to develop gout spontaneously as they often develop hyperuricemia with their evolutionary species-wide loss of uricase, which converts urate into the highly water-soluble compound allantoin. At physiologic pH, uric acid exists largely as urate, the ionized form, given its weak acidic property (pKa, 5.8).

The systemic urate concentration reflects a balance between dietary intake, endogenous synthesis, and excretion. Hyperuricemia arises predominantly from impaired urate excretion (90%) or, less commonly, from overproduction (10%), with many cases involving both mechanisms. The pathways leading to urate overproduction, implicated in hyperuricemia and gout, are delineated in **Fig. 384-2**. Most instances of endogenous urate overproduction are linked to salvaged purines from increased cell turnover in proliferative and inflammatory disorders, such as hematologic malignancies and psoriasis, pharmacologic agents that elevate urate synthesis, like chemotherapy, or tissue hypoxia. A minority of hyperuricemia cases (10%) are due to inherited metabolic disorders, including heightened activity of 5′-phosphoribosyl 1-pyrophosphate (PRPP) synthetase or deficits in hypoxanthine-guanine phosphoribosyl transferase (HPRT) (Fig. 384-2). Genetic mutations causing PRPP synthetase overactivity result in an accelerated production of PRPP, purine nucleotides, and urate, culminating in conditions like gout and urate nephrolithiasis.

Approximately two-thirds of daily uric acid elimination occurs through renal excretion, with the remaining one-third via the gastrointestinal tract. Within the renal proximal tubule, distinct transporter systems are responsible for urate reabsorption and secretion. The reabsorption of urate at the apical membrane of the proximal tubule is sodium-dependent. This process involves the sodium-driven uptake of certain anions, which in turn promotes apical urate-anion exchange primarily through URAT1 and OAT10 transporters. Subsequently, urate is excreted across the basolateral membrane via the GLUT9 transporter. This mechanism underlies the notable anti-uricosuric actions of agents like pyrazinoate (PZA) and nicotinate. Meanwhile, urate entry into the intestinal tract is facilitated in part by ABCG2, a high-capacity urate efflux transporter encoded by the *ABCG2* gene and also present in the renal proximal tubular epithelium. In the intestine, urate undergoes degradation by gut bacteria (intestinal uricolysis).

In gout, urate crystals trigger a robust inflammatory response by stimulating the synthesis and release of inflammatory mediators. Central to this process is the phagocytosis of MSU crystals by neutrophils, which amplifies inflammation. Preceding neutrophil recruitment are events in the synovium and joint vasculature, involving activation of resident synovial phagocytes, including monocytes/macrophages and mast cells, and the NOD-like receptor protein 3 (NLRP3) inflammasome. This leads to the generation of pro-interleukin (IL)-1 and IL-1β, as well as other proinflammatory molecules like IL-6, IL-8, and tumor necrosis factor (TNF)-α.

Neutrophils respond to MSU crystals with a respiratory burst, releasing inflammatory agents such as lysosomal enzymes, superoxide anion, leukotriene B4, IL-1, and other cytokines and chemokines. The cellular mechanisms for neutrophil chemotaxis and activation involve kinases, phospholipases, chemoattractants, adhesion molecules, and other factors, highlighting the intense nature of the inflammatory response in gout.

If left untreated, gout can progress to chronic gouty arthritis, frequently with low-grade persistent synovitis and erosive deformities due to growing deposition of MSU crystals surrounded by granulomatous inflammation (tophi). Tophi, often found in proteoglycan-rich tissues like joints and tendons, encapsulate this chronic inflammatory process. These tophi engage both innate and adaptive immunity, representing a dynamic response to MSU crystals. Although occasionally exhibiting acute inflammatory signs, tophi predominantly signify a chronic inflammatory state in gout.

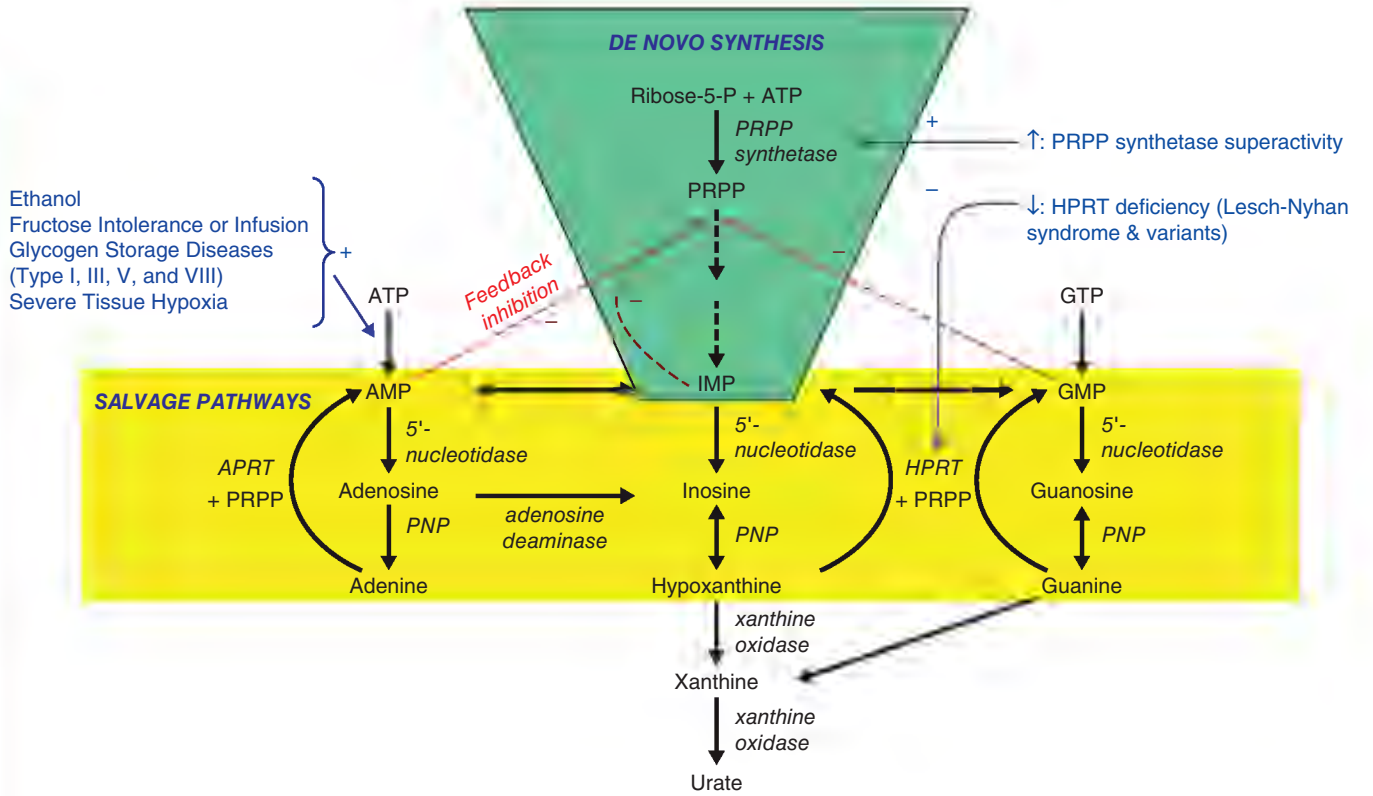

FIGURE 384-2 Urate production pathways implicated in the pathogenesis of gout. The de novo synthesis starts with 5′-phosphoribosyl 1-pyrophosphate (PRPP). PRPP is produced by addition of a further phosphate group from adenosine triphosphate (ATP) to the modified sugar ribose-5-phosphate. This step is performed by the family of PRPP synthetase (PRS) enzymes. Mutations in the PRS genes can result in overactivity of the pathway. Superactivity of PRS is an X chromosome-linked inborn error of metabolism, which leads to increased rate of PRPP, purine nucleotide, and urate production, in association with gout and urate urolithiasis. In addition, purine bases derived from tissue nucleic acids are reutilized through the salvage pathway. The enzyme hypoxanthine-guanine phosphoribosyl transferase (HPRT) salvages hypoxanthine to inosine monophosphate (IMP) and guanine to guanosine monophosphate (GMP). Mutations in the gene encoding HPRT are associated with a spectrum of disease that ranges from hyperuricemia alone to hyperuricemia with profound neurological and behavioral dysfunction (Lesch-Nyhan syndrome). Hypoxanthine cannot be reutilized without HPRT, and can only be degraded to urate. Both the underutilization of PRPP and decrease in IMP and GMP levels in the salvage pathway further contributes to hyperuricemia by feedback inhibition on de novo purine synthesis. The HPRT is located on the X chromosome and 250 different mutations of the gene have been described. Further, conditions associated with net ATP degradation lead to the accumulation of adenosine diphosphate (ADP) and adenosine monophosphate (AMP), which can be rapidly degraded to uric acid. These conditions are displayed in left upper corner. PNP, Purine nucleotide phosphorylase; APRT, adenine phosphoribosyl transferase.

CLINICAL MANIFESTATIONS

Early clinical manifestation of gout is characterized by acute recurrent gout flares. Usually, only one joint is affected initially, although oligo- and polyarticular gout flares can develop over time. The metatarsophalangeal joint of the first toe is involved in 70–90% of cases (podagra), followed by tarsal joints, ankles, and knees. Finger, wrist, and elbow joints can also be involved, although more often in elderly patients or in advanced disease. The gout flares often begin at night to early morning, constituting one of the most painful conditions experienced by humans. The affected joints and periarticular areas rapidly become warm, red, tender, and substantially swollen with a clinical appearance that often mimics that of cellulitis (pseudocellulitis). Typical flares tend to subside spontaneously within 1–2 weeks, and most patients have intervals of varying length with no residual symptoms until the next episode (intercritical gout). Triggers of gout flares include purine-rich food, alcohol, diuretic use, initial introduction of urate-lowering therapy, local trauma, and medical illnesses such as congestive heart failure and respiratory hypoxic conditions (Fig. 384-1).

Usually after years of gout flares without treatment, chronic gouty arthritis can develop, associated with ongoing synovitis, subcutaneous tophi, deformity, and bony destruction. Less commonly, chronic gouty arthritis will be the only manifestation, and more rarely, gout can manifest only as tophi. Women represent only 5–20% of all patients with gout. Most women with gout are postmenopausal and elderly; tend to have osteoarthritis, hypertension, or mild renal insufficiency; and usually are receiving diuretics. Premenopausal gout is rare, although kindreds of precocious gout in young women caused by decreased renal urate clearance and renal insufficiency have been described.

Genetic mutations in the *HPRT* gene are linked to a diverse range of clinical manifestations, extending from isolated hyperuricemia to severe neurologic and behavioral abnormalities (Lesch-Nyhan syndrome). In the absence of functional HPRT, hypoxanthine cannot be recycled and is exclusively converted to urate. This enzymatic deficiency leads to underuse of PRPP and a reduction in inosine monophosphate (IMP) and guanosine monophosphate (GMP) levels in the purine salvage pathway. These alterations contribute to hyperuricemia through feedback inhibition of de novo purine synthesis (Fig. 384-2). Owing to the X-linked inheritance of these enzyme defects, males who are homozygous for the mutation exhibit the disease phenotype. Carrier females, particularly postmenopausal, may develop gout and urinary tract stones. Notably, the presence of hyperuricemia in prepubertal boys should prompt consideration of these specific enzymatic deficits.

DIAGNOSIS

Laboratory Diagnosis Even if characteristic clinical features strongly suggest gout, the presumptive diagnosis ideally should be confirmed by needle aspiration of involved joints or tophaceous deposits. Acute septic arthritis, other crystal-associated arthropathies, palindromic rheumatism, and psoriatic arthritis can mimic clinical presentations of gout. During acute gout flares, needle-shaped MSU crystals typically are present both intracellularly and extracellularly (Fig. 384-3). Under compensated polarized light, these crystals show bright, negative birefringence. Synovial fluid appears cloudy due to the increased numbers of leukocytes (e.g., from 5000–75,000/μL). Large amounts of crystals occasionally produce a thick, pasty, chalky joint fluid or drainage from distended tophus. Because bacterial infection can coexist with MSU crystals in synovial fluid, joint fluid is often stained and cultured for potential septic arthritis. MSU crystals also can often be demonstrated in the first metatarsophalangeal joint and



A

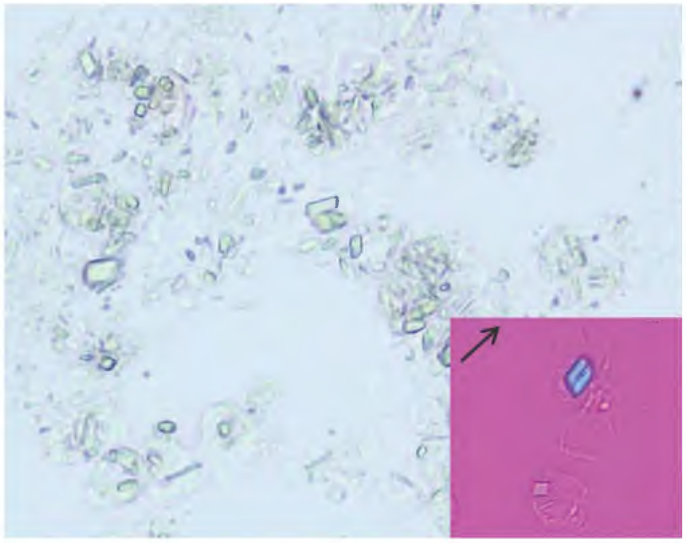

B

FIGURE 384-3 ***A.*** Extracellular and intracellular monosodium urate crystals, as seen in a fresh preparation of synovial fluid, illustrate needle- and rod-shaped crystals (400×). These crystals are strongly negative birefringent crystals under compensated polarized light microscopy. *(Inset 400×, provided by Eliseo Pascual.)* ***B.*** Intracellular and extracellular calcium pyrophosphate (CPP) crystals, as seen in a fresh preparation of synovial fluid, illustrate rectangular, rod-shaped, and rhomboid crystals (400×). These crystals are weakly positively or nonbirefringent crystals under compensated polarized light microscopy (inset 600×). *(Images provided by Eliseo Pascual.)*

in knees not acutely involved with gout, making arthrocentesis of these joints useful for the diagnosis of gout between flares.

While chronic hyperuricemia is a prerequisite in the pathogenesis of gout, serum urate levels can be normal or low at the time of an acute flare, as inflammatory cytokines' uricosuric property (e.g., IL-6) can lower the level by ~2 mg/dL. This tends to limit the value of serum urate testing in the setting of an acute flare. Nevertheless, serum urate levels are almost always elevated at some time in a gout patient's lifetime, and thus, it is important to seek historical or postflare serum urate values as a diagnostic clue or therapeutic target to urate-lowering therapy. Serum creatinine, liver function tests, hemoglobin, white blood cell (WBC) count, hemoglobin A_{1c}, and serum lipids are usually obtained at baseline to assess possible risk factor and comorbidities requiring treatment or monitored for potential adverse effects of gout treatments.

Radiographic Features Musculoskeletal ultrasound can timely aid early diagnosis by revealing a double-contour sign overlying the articular cartilage (signifying MSU deposition). Similarly, dual-energy computed tomography (CT) that utilizes two different energy beams and identifies MSU based on its chemical composition can indicate specific presence of MSU crystals. In plain radiography, cystic changes, well-defined erosions with sclerotic margins (often with overhanging bony edges), and soft tissue masses are characteristic features of advanced gout with tophaceous deposits, although these findings are typically absent in earlier stages of gout.

TREATMENT

Acute Gout Care

Although nonpharmacologic measures, such as ice pack application and rest of the involved joints, can be helpful, the mainstay of acute gout care is the administration of anti-inflammatory drugs such as colchicine, nonsteroidal anti-inflammatory drugs (NSAIDs), and glucocorticoids (Fig. 384-1). The choice of these options largely depends on the patients' comorbidities, concurrent medications, and previous response if recurrent flares. Early initiation of anti-inflammatories helps abort or reduce the severity of flares. Thus, for recurrent flares in established gout patients, patients can be provided a supply of their medications ready to start at the first sign of a flare. Oral colchicine is effective, particularly if used early in a gout flare. A low-dose regimen (1.2 mg with the first sign of a flare, followed by 0.6 mg in 1 h and subsequent-day dosing depending on response) is as effective as, and better tolerated than, the formerly used higher-dose regimens. Colchicine is eliminated from the body through P-glycoprotein (also known as MDR1) in the liver, small intestine, and kidneys as well as via enteric and hepatic cytochrome P450 3E4 (CYP3A4). As such, the dose, particularly for prolonged use, is reduced among patients with renal disease or when used with P-glycoprotein or CYP3A4 inhibitors such as clarithromycin or tacrolimus; additional caution is warranted among patients with hepatorenal impairment. NSAIDs are used most often in individuals without complicating comorbidities; NSAIDs given in full anti-inflammatory doses are effective in the vast majority of patients (e.g., indomethacin, 25–50 mg tid; naproxen, 500 mg bid; ibuprofen, 800 mg tid; and celecoxib, 800 mg followed by 400 mg 12 h later, then 400 mg bid).

Glucocorticoids given orally (e.g., prednisone, 30–50 mg/d as the initial dose and gradually tapered with the resolution of the attack) or as an intramuscular injection can be effective even in polyarticular gout. For a single joint or a few involved joints, intraarticular glucocorticoid injection is effective and well tolerated. With the central role of the inflammasome and IL-1β in gout flares, anakinra or canakinumab is a useful option when other treatments are contraindicated or have failed.

URATE-LOWERING THERAPY

Ultimate control of gout requires correction of the underlying chronic hyperuricemia with increased urate pool, the central cause for gout. Attempts to normalize serum urate to a subsaturation point (typically, <300–360 μmol/L [5.0–6.0 mg/dL]) to prevent recurrent gout flares and eliminate tophi are critical and entail a commitment to urate-lowering regimens that are required usually for life (Fig. 384-1). Urate-lowering drug therapy should be considered when, as in most patients, the hyperuricemia cannot be corrected by risk factor interventions (control of body weight, healthy diet, limitation of alcohol use, decreased consumption of fructose-rich foods and beverages, and avoidance of thiazide and loop diuretics). The decision to initiate urate-lowering drug therapy usually is made considering the number of gout flares (e.g., two or more attacks yearly), severity and duration of flares, or the patient's willingness to commit to long-term therapy. Urate-lowering therapy should be initiated in any patient who already has subcutaneous tophi or chronic gouty arthritis or known uric acid nephrolithiasis.

Allopurinol, a xanthine oxidase inhibitor, is the first-line urate-lowering drug among gout patients. Allopurinol can be given in a single morning dose, starting at 100 mg daily or less and titrating up (to 800 mg daily) to achieve a target serum urate level <5–6 mg/dL (i.e., a subsaturation point of MSU crystals) (Fig. 384-1). In patients

with CKD, the starting allopurinol dose should be lowered depending on the CKD levels; for example, with an estimated glomerular filtration rate of <30 mL/min, one would start at 50 mg daily and titrate up slowly. Starting at a low dose and titrating up reduces the risk of severe cutaneous adverse reactions (SCARs), including Stevens-Johnson syndrome and toxic epidermal necrolysis, as well as the risk of gout flares associated with rapid serum urate reduction due to introduction of urate-lowering therapy (Fig. 384-1). Allopurinol is generally well tolerated, but mild cutaneous reactions can develop in ~2% of users. SCARs to allopurinol are rare but can be life-threatening, and thus, appropriate precaution is advised. Presence of CKD, higher allopurinol initial dosing (e.g., >100 mg daily in CKD patients), and *HLA-B*5801* carriage are important risk factors. As the *HLA-B*5801* carriage rate is high among Southeast Asian (except for Japanese descendants), Pacific Islander/Native Hawaiian, and black patients (leading to racial disparity in the risk of SCARs), screening for *HLA-B*5801* should be performed before starting allopurinol in these populations. If patients carry the *HLA-B*5801* allele, an alternative urate-lowering agent should be administered. Febuxostat is another xanthine oxidase inhibitor that is predominantly metabolized by glucuronide formation and oxidation in the liver and considered to not require dose adjustment in moderate to severe chronic kidney disease. It has also been used in patients who carry the *HLA-B*5801* allele.

Uricosuric agents such as probenecid are considered second-line urate-lowering therapies for gout and can be used in patients with good renal function either alone or in combination with xanthine oxidase inhibitors such as allopurinol. Probenecid can be started at a dose of 250 mg twice daily and increased gradually as needed up to 3 g/d to achieve and maintain a target serum urate level. Probenecid is generally not effective in patients with serum creatinine levels >177 μmol/L (2 mg/dL); benzbromarone (not available in the United States) is another uricosuric drug that is more effective in patients with CKD. Pegloticase is a pegylated uricase that is available for patients who do not tolerate or fail full doses of other treatments. It is often used in combination with methotrexate to reduce immunogenicity, which can lead to a loss of efficacy and infusion reactions. Therapies used to treat common cardiometabolic comorbidities of gout can also help lower serum urate levels, including losartan, amlodipine, fenofibrate, and sodium-glucose cotransporter-2 inhibitors (SGLT2i). Given their approved multiple cardiometabolic-kidney indications, SGLT2i can be beneficial for gout patients, offering both urate reduction and comprehensive comorbidity care.

Urate-lowering drugs are generally not initiated during active ongoing gout flares, given the potential worsening of the flare by acutely lowering serum urate levels. However, urate-lowering therapy can be started during the resolution phase of or after a gout flare, together with anti-inflammatory prophylaxis (e.g., colchicine 0.6 mg one to two times daily or naproxen 250 mg twice daily) to reduce the risk of the flares that often occur with the initiation of urate-lowering therapy. These paradoxical flares are presumed to be inflammatory reactions to MSU crystals shed from dissolution of organized MSU deposits (synovial tophi) induced by rapid serum urate reduction (Fig. 384-1). As such, faster urate reduction has been associated with higher risk of flares in clinical trials of urate-lowering drugs. Continuing concomitant anti-inflammatory prophylaxis is usually recommended until the patient is normouricemic and without gouty attacks for 3–6 months or tophi disappear.

CALCIUM PYROPHOSPHATE DEPOSITION DISEASE

CPP deposition (CPPD) predominately affects the elderly, with a doubling prevalence of CPPD in articular tissues with each decade >60 years of age (e.g., prevalence of nearly 50% for those >85 years old). In most cases, this process is asymptomatic with uncertain underlying etiology, although it is likely that biochemical changes in aging or diseased cartilage favor CPP crystal nucleation. Increased levels of inorganic pyrophosphate in cartilage matrix are thought to be a central pathogenic process in patients with CPPD arthritis, analogous to hyperuricemia in gout. This pyrophosphate can combine with calcium to form CPP crystals in cartilage matrix vesicles or on collagen fibers. Most inorganic pyrophosphate in cartilage matrix originates from breakdown of extracellular ATP. The ATP efflux (and thus the levels of inorganic pyrophosphate) is tightly regulated by a multipass membrane protein, ANKH. As such, mutations in the *ANKH* gene, as described in both familial and sporadic cases, have been found to increase elaboration and extracellular transport of pyrophosphate. The increase in pyrophosphate production is also related to enhanced activity of ATP pyrophosphohydrolase and 5′-nucleotidase, which catalyze the reaction of ATP to adenosine and pyrophosphate. Decreased levels of cartilage glycosaminoglycans and increased activities of transglutaminase enzymes may contribute to the deposition of CPP crystals.

TABLE 384-2 Factors and Conditions Associated with Calcium Pyrophosphate Crystal Deposition Disease

Aging
Osteoarthritis
Postmeniscectomy or joint trauma
Familial-genetic
Endocrine-metabolic conditions
Primary hyperparathyroidism
Hemochromatosis
Hypophosphatasia
Hypomagnesemia
Certain drugs: thiazide and loop diuretics, potentially proton pump inhibitors
Malabsorption
Gitelman's syndrome
Gout
X-linked hypophosphatemic rickets
Familial hypocalciuric hypercalcemia

Similar to MSU crystals, release of CPP crystals into the joint space is followed by the phagocytosis of those crystals by monocyte-macrophages and neutrophils, which respond by releasing chemotactic and inflammatory substances and activating the inflammasome.

A minority of patients with CPPD arthropathy have metabolic abnormalities or hereditary CPPD **(Table 384-2)**. As such, the presence of CPPD arthritis in individuals aged <50 years should lead to consideration of these metabolic disorders and inherited forms of disease, including those identified in a variety of ethnic groups. Included among endocrine-metabolic conditions are hyperparathyroidism, hemochromatosis, hypophosphatasia, and hypomagnesemia. These associations suggest that a variety of different metabolic products may enhance CPP crystal deposition either by directly altering cartilage or by inhibiting inorganic pyrophosphatases. Investigation of younger patients with CPPD should include inquiry for evidence of familial aggregation and evaluation of serum calcium, phosphorus, alkaline phosphatase, magnesium, iron, and transferrin.

CLINICAL MANIFESTATIONS

Acute CPP crystal arthritis, originally termed *pseudogout* by McCarty and co-workers, often mimics acute gout flares with similar articular findings of substantial inflammation. There are several clinical clues that suggest CPP crystal arthritis. The knee is the joint most commonly affected, followed by the wrist, while the first metatarsophalangeal joint (podagra) is rarely affected. Other affected joints include the shoulder, ankle, elbow, and hands. Also, initial episodes of acute attacks tend to last longer than typical gout flares, even up to weeks to months. Acute attacks present sometimes with systemic signs such as fever, chills, and elevated acute-phase reactants. Acute CPP crystal arthritis may be precipitated by trauma, severe medical illness, or surgery, especially parathyroidectomy, as it leads to rapid diminution of serum calcium and magnesium levels, causing dissolution and shedding of crystal.

Chronic CPP crystal arthritis has several patterns; the most common form is a polyarticular arthritis resembling osteoarthritis (pseudoosteoarthritis). The clinical picture mimics that of progressive

osteoarthritis, characterized by unusually severe joint damage in atypical joints for osteoarthritis, such as metacarpophalangeal, wrist, elbow, shoulder, or ankle joints. Other less common forms include chronic symmetric synovitis that is clinically similar to rheumatoid arthritis, severe destructive disease that may radiographically mimic neuropathic arthritis, intervertebral disk and ligament calcification with restriction of spine mobility, the crowned dens syndrome, spinal stenosis (most commonly seen in the elderly), and rarely, tumoral deposits of CPP crystals in soft tissues.

If radiographs or ultrasound reveal punctate and/or linear radiodense deposits within fibrocartilaginous joint menisci or articular hyaline cartilage (*chondrocalcinosis*), the diagnostic likelihood of CPPD disease is further increased. *Definitive diagnosis* requires demonstration of typical rhomboid or rodlike crystals (generally weakly positively birefringent or nonbirefringent with polarized light) in synovial fluid or articular tissue (Fig. 384-3). In the absence of joint effusion or indications to obtain a synovial biopsy, chondrocalcinosis is presumptive of CPPD. One exception is chondrocalcinosis due to CaOx in some patients with chronic renal failure.

In as many as 50% of cases, episodes of CPP crystal-induced inflammation are associated with low-grade fever and, on occasion, temperatures as high as 40°C (104°F). In such cases, synovial fluid analysis with microbial cultures is essential to rule out the possibility of infection. In fact, infection in a joint with any microcrystalline deposition process can lead to crystal shedding and subsequent synovitis from both crystals and microorganisms. The leukocyte count in synovial fluid in acute CPPD can range from several thousand cells to 100,000 cells/μL, with the mean being ~24,000 cells/μL and the predominant cell being the neutrophil. CPP crystals may be seen inside tissue fragments and fibrin clots and in neutrophils (Fig. 384-3). CPP crystals may coexist with MSU and apatite in some cases.

TREATMENT

CPPD Disease

Anti-inflammatory treatment for acute CPP crystal arthritis is largely adapted from that for gout flares, including ice pack applications with rest, joint fluid aspiration and glucocorticoid injection, oral colchicine, NSAIDs, and systemic glucocorticoids. Severe polyarticular attacks can also be treated with the IL-1β antagonist anakinra. For patients with frequent recurrent attacks, prophylactic treatment with daily colchicine can be helpful. For chronic CPP crystal arthritis, there is no effective way to remove CPP crystal deposits from cartilage and synovium (unlike urate-lowering agents in gout). Limited studies suggest that NSAIDs (with a gastric protective agent if required), colchicine, low-dose glucocorticoids, hydroxychloroquine, or methotrexate may be helpful for chronic synovitis. Patients with progressive destructive large-joint arthropathy may require joint replacement.

CALCIUM APATITE DEPOSITION DISEASE

PATHOGENESIS

Apatite is the primary mineral of normal bone and teeth. Abnormal accumulation of basic calcium phosphates, largely carbonate substituted apatite, can occur in areas of tissue damage (dystrophic calcification), hypercalcemic or hyperparathyroid states (metastatic calcification), connective tissue diseases (calcinosis), and other conditions **(Table 384-3)**. In chronic renal failure, hyperphosphatemia can contribute to extensive apatite deposition both in and around joints (tumoral calcinosis, calciphylaxis). Familial aggregation is rarely seen. Synovial lining cell or fibroblast cultures exposed to apatite (or CPP) crystals can undergo mitosis and markedly increase the release of prostaglandin E_2, various cytokines, and collagenases and neutral proteases, underscoring the destructive potential of abnormally stimulated synovial lining cells.

Although the true incidence of apatite arthritis is not known, 30–50% of patients with osteoarthritis have apatite microcrystals in their synovial fluid. Such crystals frequently can be identified in clinically stable osteoarthritic joints, but they are more likely to come to attention in persons experiencing acute or subacute worsening of joint pain and swelling.

TABLE 384-3 Clinical Manifestations of Apatite Crystal Deposition

Periarticular
Calcific periarthritis (e.g., supraspinatus tendon apatite deposit rupture)
Bursitis and tendinitis
Hydroxyapatite pseudopodagra
Polyarticular involvement
Asymptomatic deposition
Articular
Hemorrhagic shoulder effusions in the elderly (Milwaukee shoulder)
Chronic destructive arthropathy
Chronic erosive monoarthritis (resembling erosive osteoarthritis)
Acute synovitis
Association with osteoarthritis
Secondary apatite crystal deposition
Tumoral calcinosis
Hyperparathyroidism
Calciphylaxis (renal failure/long-term dialysis)
Connective tissue diseases (e.g., systemic sclerosis, dermatomyositis)
Heterotopic calcification after neurologic catastrophes (e.g., stroke, spinal cord injury)
Fibrodysplasia ossificans progressiva

CLINICAL MANIFESTATIONS

Periarticular or articular deposits can present with acute reversible inflammation and/or chronic damage to the joint capsule, tendons, bursa, or articular surfaces (Table 384-3). The most common sites of apatite deposition include bursae and tendons in and/or around the knees, shoulders, hips, and fingers. These deposits can also be asymptomatic radiographic abnormalities.

Apatite aggregates are often present in synovial fluid in an extremely destructive chronic arthropathy of the elderly that occurs most often in the shoulders (Milwaukee shoulder) and in a similar process in hips, knees, and erosive osteoarthritis of fingers (Table 384-3). Joint destruction is associated with damage to cartilage and supporting structures, leading to instability and deformity. Progression tends to be indolent. Symptoms range from minimal to severe pain and disability that may lead to joint replacement surgery.

DIAGNOSIS

Intra- and/or periarticular calcifications with or without erosive, destructive, or hypertrophic changes may be seen on radiographs **(Fig. 384-4)**. They should be distinguished from the linear calcifications typical of CPPD.

The synovial fluid leukocyte count in apatite arthritis is usually low (<2000/μL) despite dramatic symptoms, with predominance of mononuclear cells. Definitive diagnosis of apatite arthropathy, also called basic calcium phosphate disease, depends on identification of crystals from synovial fluid or tissue (Fig. 384-4). Individual crystals are very small and can be seen only by electron microscopy. Clumps of crystals may appear as 1- to 20-μm shiny intra- or extracellular nonbirefringent globules or aggregates that stain purplish with Wright's stain and bright red with alizarin red S. Absolute identification depends on electron microscopy with energy-dispersive elemental analysis, x-ray diffraction, infrared spectroscopy, or Raman microspectroscopy, but these techniques usually are not required in clinical diagnosis.

TREATMENT

Calcium Apatite Deposition Disease

Treatment of apatite arthritis or periarthritis is nonspecific. Acute attacks of bursitis or synovitis may be self-limiting, resolving in

A

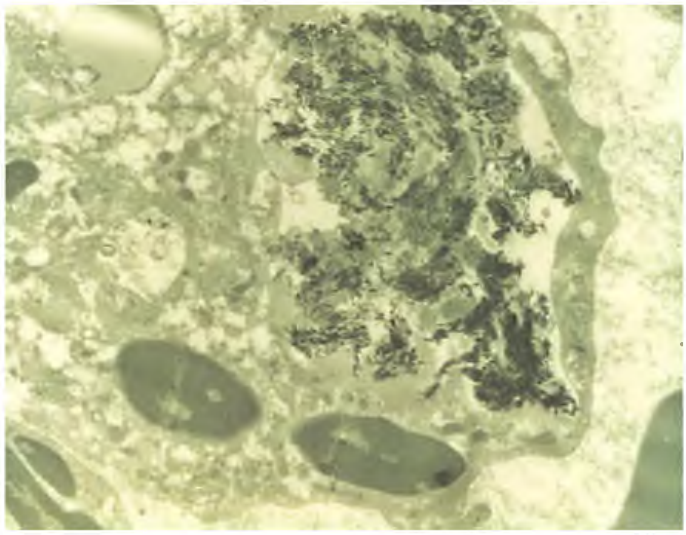

B

FIGURE 384-4 ***A.*** Radiograph showing calcification due to apatite crystals surrounding an eroded joint. ***B.*** An electron micrograph demonstrates dark needle-shaped apatite crystals within a vacuole of a synovial fluid mononuclear cell (30,000×).

days to several weeks. Aspiration of effusions and the use of either NSAIDs or oral colchicine for 2 weeks or intra- or periarticular injection of a depot glucocorticoid appear to shorten the duration and intensity of symptoms. Periarticular apatite deposits may be resorbed with resolution of attacks. Agents to lower serum phosphate levels may lead to resorption of deposits in renal failure patients receiving hemodialysis. In patients with underlying severe destructive articular changes, response to medical therapy is usually less rewarding.

CaOx DEPOSITION DISEASE

PATHOGENESIS

In chronic renal disease, CaOx deposits have long been recognized in visceral organs, blood vessels, bones, and cartilage and are now known to be one of the causes of arthritis in chronic renal failure. Thus far, reported patients have been dependent on long-term hemodialysis or peritoneal dialysis **(Chap. 323)**, and many had received ascorbic acid supplements. Ascorbic acid is metabolized to oxalate, which is inadequately cleared in uremia and by dialysis. Such supplements and foods high in oxalate content usually are avoided in dialysis programs because of the risk of enhancing hyperoxalosis and its sequelae.

CaOx aggregates can be found in bone, articular cartilage, synovium, and periarticular tissues. From these sites, crystals may be shed, causing acute synovitis. Persistent aggregates of CaOx can, like apatite and CPP crystals, stimulate synovial cell proliferation and enzyme release, resulting in progressive articular destruction. *Primary oxalosis* is a rare hereditary metabolic disorder **(Chap. 431)** that can lead to acute or chronic CaOx arthritis, periarthritis, and bone disease during later years of illness.

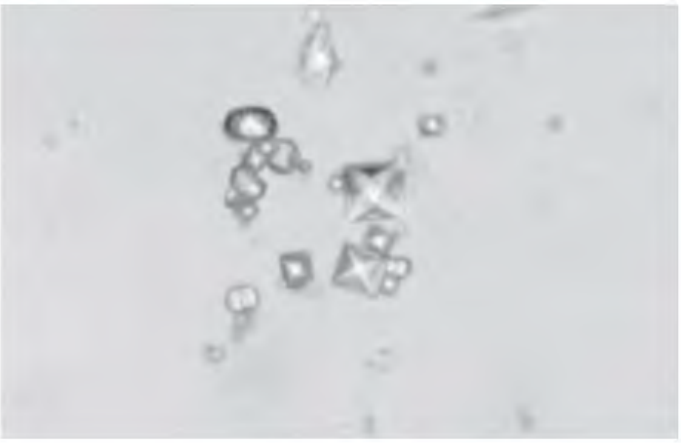

FIGURE 384-5 Bipyramidal and small polymorphic calcium oxalate crystals from synovial fluid are a classic finding in calcium oxalate arthropathy (ordinary light microscopy; 400×).

CLINICAL MANIFESTATIONS AND DIAGNOSIS

Clinical features of acute CaOx arthritis may not be distinguishable from those due to MSU, CPP, or apatite. Deposits have been documented in fingers, wrists, elbows, knees, ankles, and feet. Radiographs may reveal chondrocalcinosis or soft tissue calcifications. CaOx-induced synovial effusions are usually noninflammatory, with <2000 leukocytes/μL, or mildly inflammatory. Neutrophils or mononuclear cells can predominate. CaOx crystals have a variable shape and variable birefringence to polarized light. The most easily recognized forms are bipyramidal, have strong birefringence **(Fig. 384-5)**, and stain with alizarin red S.

TREATMENT

Calcium Oxalate Deposition Disease

Treatment of CaOx arthropathy with NSAIDs, colchicine, intraarticular glucocorticoids, and/or an increased frequency of dialysis has produced only slight improvement. In primary oxalosis, liver transplantation has induced a significant reduction in crystal deposits **(Chaps. 356 and 431)**.

Acknowledgment

This chapter includes content on purine and pyrimidine metabolism written by John N. Mecchella and Christopher M. Burns in previous editions of this textbook.

FURTHER READING

Choi HK et al: Pathogenesis of gout. Ann Intern Med 143:499, 2005.
Dalbeth N et al: Gout. Nat Rev Dis Primers 5:69, 2019.
Rosenthal AK, Ryan LM: Calcium pyrophosphate deposition disease. N Engl J Med 374:2575, 2016.