FURTHER READING

Aguilar C et al: Bone and joint disease in sickle cell disease. Hematol Oncol Clin North Am 19:929, 2005.

Botek G et al: Charcot neuroarthropathy: An often overlooked complication of diabetes. Cleve Clin J Med 77:593, 2010.

Dallos T et al: Idiopathic hand osteoarthritis vs haemochromatosis arthropathy: A clinical, functional and radiographic study. Rheumatology 52:910, 2013.

Guggenbuhl P et al: Miscellaneous non-inflammatory musculoskeletal conditions. Haemochromatosis: The bone and the joint. Best Pract Res Clin Rheumatol 25:649, 2011.

Kedar E, Gardner GC: Lipid-associated rheumatologic syndromes. Rheum Dis Clin North Am 39:481, 2013.

Killinger Z et al: Arthropathy in acromegaly. Rheum Dis Clin North Am 36:713, 2010.

Pineda C, Martínez-Lavín M: Hypertrophic osteoarthropathy: What a rheumatologist should know about this uncommon condition. Rheum Dis Clin North Am 39:383, 2013.

Stephan SR et al: Pigmented villonodular synovitis. A comprehensive review and proposed treatment algorithm. JBJS Rev 4:1, 2016.

Vanderhave KL et al: Musculoskeletal care of the hemophiliac patient. J Am Acad Orthop Surg 20:553, 2012.

387 Periarticular Disorders of the Extremities

Carol A. Langford

Periarticular disorders are common musculoskeletal abnormalities that can affect people of all ages. This chapter reviews some of the more frequently encountered periarticular disorders.

BURSITIS

Bursitis is inflammation of a bursa, which is a thin-walled sac lined with synovial tissue. Adults typically have over 150 bursae that function to facilitate movement of tendons and muscles over bony prominences. Excessive frictional forces from overuse, trauma, systemic disease (e.g., rheumatoid arthritis, gout), or infection may cause bursitis. Although any bursa has the ability to become inflamed, certain bursal structures are more prone to developing bursitis because of their location and the mechanical stresses they are subject to. *Subacromial bursitis* (subdeltoid bursitis) is the most common form of bursitis and often accompanies rotator cuff tendinitis. The subacromial bursa, which is contiguous with the subdeltoid bursa, is located between the undersurface of the acromion and the humeral head and is covered by the deltoid muscle. Patients most often experience pain in the anterolateral aspect of the shoulder. As it can develop in the setting of other shoulder disorders, directed examination and imaging are particularly important to rule these out. *Trochanteric bursitis* (also called *greater trochanteric pain syndrome*) is a tendinopathy of the gluteus medius and/or minimus muscles that occurs with or without inflammation of the bursa located around the insertion of the gluteus medius onto the greater trochanter of the femur. Patients experience pain over the lateral aspect of the hip and upper thigh and have tenderness over the posterior aspect of the greater trochanter, often most noticeable when lying on their side. External rotation and resisted abduction of the hip elicit pain, as will direct pressure applied to the bursa. *Olecranon bursitis* involves the posterior elbow, often presenting with visible swelling over the olecranon. In settings where this area becomes acutely inflamed with redness and/or warmth, infection or gout should be excluded by aspirating the bursa and performing a Gram stain and culture on the fluid as well as examining the fluid for urate crystals. *Achilles bursitis* (also called subcutaneous calcaneal bursitis) impacts the bursa located between the skin and the Achilles tendon and is most often caused by overuse and ill-fitting shoes. *Retrocalcaneal bursitis* impacts a deeper bursa that is located between the calcaneus and posterior surface of the Achilles tendon. This bursa facilitates sliding of the Achilles tendon over the calcaneus and can become inflamed as a result of repetitive movement, trauma, or in association with spondyloarthritis, rheumatoid arthritis, or gout. Patients experience pain at the back of the heel and swelling along the medial and/or lateral side of the tendon. *Ischial bursitis* affects the bursa separating the gluteus medius from the ischial tuberosity and typically occurs from prolonged sitting on hard surfaces. *Iliopsoas bursitis* affects the iliopsoas bursa, the largest bursa in the body, which lies between the anterior aspect of the hip joint and the iliopsoas muscle. Bursitis in this location is associated with overuse or an underlying systemic disease process. Patients experience pain over the area, made worse by hip extension and flexion, which must be differentiated from pain originating within the hip joint. *Anserine bursitis* is an inflammation of the bursa located over the medial side of the tibia just below the knee joint under the conjoint tendon of the sartorius, gracilis, and semitendinosus muscles. Pain can be elicited on climbing stairs and by direct pressure over the bursa about 5 cm below the medial knee joint line. *Prepatellar bursitis* occurs in the bursa situated between the patella and overlying skin and is caused by kneeling on hard surfaces. Gout or infection may also occur at this site. Bursitis is typically diagnosed by history and physical examination, but ultrasound may play a useful role in selected instances for diagnosis and directed guidance of glucocorticoid injection. Treatment of bursitis consists of prevention of aggravating factors, rest of the involved part, administration of a topical or systemic nonsteroidal anti-inflammatory drug (NSAID) where appropriate for an individual patient, or local glucocorticoid injection.

ROTATOR CUFF TENDINITIS AND IMPINGEMENT SYNDROME

Tendinitis of the rotator cuff (also called *impingement syndrome*) is the major cause of a painful shoulder. The rotator cuff consists of the tendons of the supraspinatus, infraspinatus, subscapularis, and teres minor muscles, and inserts on the humeral tuberosities. Of the tendons forming the rotator cuff, the supraspinatus tendon is the most often affected, because of its potential for impingement between the humeral head and the undersurface of the anterior third of the acromion and coracoacromial ligament above (Fig. 387-1). The tendon of the infraspinatus and that of the long head of the biceps are less commonly involved. Subacromial bursitis often accompanies this syndrome. Symptoms can appear without a triggering cause or after injury or

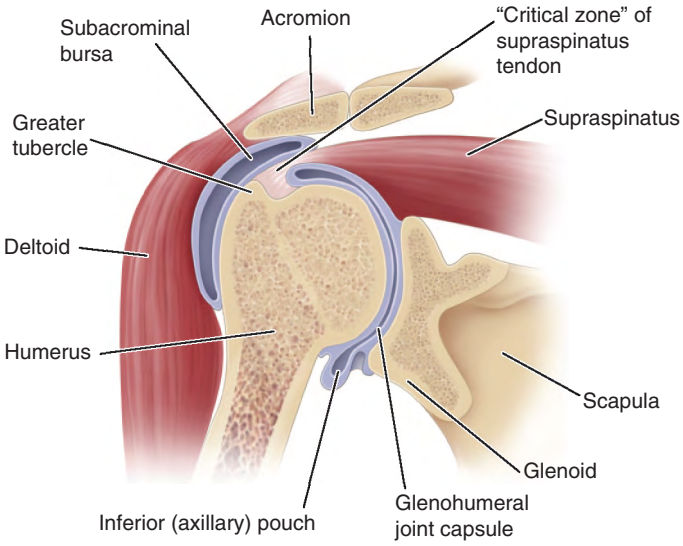

FIGURE 387-1 Coronal section of the shoulder illustrating the relationships of the glenohumeral joint, the joint capsule, the subacromial bursa, and the rotator cuff (supraspinatus tendon). *(Reproduced with permission from F Kozin, in WJ Koopman [ed]: Arthritis and Allied Conditions, 13th ed, Baltimore, Williams & Wilkins, 1997.)*

overuse, especially with occupations or sports that involve elevation of the arm with forward flexion such as baseball, tennis, or swimming. Work and home ergonomic issues have also increasingly been raised as contributing factors. Patients typically experience a dull aching in the shoulder, which may interfere with sleep. Severe pain occurs when the arm is actively abducted into an overhead position, with the arc between 60° and 120° being especially painful. Tenderness is present over the lateral aspect of the humeral head just below the acromion. NSAIDs, local glucocorticoid injection, and physical therapy may relieve symptoms. Surgical decompression of the subacromial space may be necessary in patients refractory to conservative treatment.

ROTATOR CUFF TEARS

Rotator cuff tears may be acute, subacute, or chronic. Acute tears can occur related to sports, falling on an outstretched arm, or lifting a heavy object. Subacute and chronic tears are more common and develop in middle-aged and older patients, where the cause of the tear is likely multifactorial. Osteoarthritis is a risk factor for rotator cuff tears. Symptoms are pain along with weakness of abduction and external rotation of the shoulder. There is no single examination finding that can diagnose a torn rotator cuff, although this can be suggested by a range of maneuvers that include a painful abduction arc above 90°, failure to control shoulder adduction (drop arm test), or weakness in external rotation. The diagnosis is established by ultrasound or magnetic resonance imaging (MRI). Multiple factors influence management including symptom duration, degree of the tear (partial or full thickness), level of pain and disability, functional status, severity of osteoarthritis if present, and individual patient characteristics. Surgical referral should be pursued in patients with acute or acute-on-chronic tears that are moderate to severe with functional loss. Surgery may also be indicated in patients who fail to respond to conservative measures.

CALCIFIC TENDINITIS

Calcific tendinitis is characterized by deposition of calcium salts, primarily hydroxyapatite, within a tendon. The shoulder is the main site of involvement with calcific deposits in or around the rotator cuff tendons, with the supraspinatus tendon being involved in 63% of patients. The condition usually develops after age 40. Although the mechanism through which calcification is initiated is unknown, the process is felt to go through different phases. It is not felt to be due to overuse or systemic disease, although links have been seen with diabetes and thyroid disorders and a genetic predisposition has been questioned. Calcification within the tendon may evoke acute inflammation, producing sudden and severe shoulder pain, but may also be asymptomatic. Diagnosis of calcific tendinitis can be made by radiograph or ultrasound. Most cases are self-limited and respond to conservative therapy with physical therapy and/or NSAIDs. For patients with refractory pain, ultrasound-guided percutaneous needle aspiration and lavage, extracorporeal shock wave therapy, or surgery has been used.

BICIPITAL TENDINITIS AND RUPTURE

Bicipital tendinitis is produced by friction on the tendon of the long head of the biceps as it passes through the bicipital groove. When the inflammation is acute, patients experience anterior shoulder pain that radiates down the biceps into the forearm. Abduction and external rotation of the arm are painful and limited with tenderness over the bicipital groove. Pain may be elicited along the course of the tendon by resisting supination of the forearm with the elbow at 90° (Yergason's test). Acute rupture of the tendon may occur with vigorous exercise of the arm and is often painful. In a healthy and active patient, it should be repaired surgically as soon as possible after the rupture occurs. Rupture of the tendon in an older person may be associated with little or no pain and is recognized by the presence of persistent swelling of the biceps produced by the retraction of the long head of the biceps. Surgery is usually not necessary in this setting.

DE QUERVAIN'S TENOSYNOVITIS

De Quervain's tenosynovitis is the result of inflammation involving the abductor pollicis longus and the extensor pollicis brevis as these tendons pass through a fibrous sheath at the radial styloid process. The usual cause is repetitive twisting of the wrist. It may also occur in pregnancy and in parents who hold their babies with the thumb outstretched. Patients experience pain on grasping or pinching with their thumb. Swelling and tenderness are often present over the radial styloid process. A positive Finkelstein test can be elicited by having the patient place the thumb in the palm, closing the fingers over it, and then ulnar deviating the wrist, which results in pain over the involved tendon sheath in the area of the radial styloid. Initial treatment consists of wrist splinting and NSAIDs. When severe or refractory, local glucocorticoid injections can be effective.

PATELLAR TENDINITIS

Patellar tendinitis involves the patellar tendon at its attachment to the lower pole of the patella. Patients may experience pain when jumping during sports, going up stairs, or doing deep knee squats. Tenderness is noted on examination over the lower pole of the patella. Treatment consists of rest, icing, and NSAIDs, followed by physical therapy.

DRUG-INDUCED TENDINOPATHIES

With the broadening range of pharmacologic agents, the potential for drug-induced tendinopathies has become increasingly recognized. The drug classes most associated with tendinopathies include quinolones, glucocorticoids, aromatase inhibitors, and statins. Although any tendon can be affected, the tendons of the lower extremities are most often impacted, particularly the Achilles tendon. The pathophysiologic mechanisms responsible for drug-induced tendinopathies remain unknown. Presenting features include pain and potentially swelling over the tendon, although some patients may first present with tendon rupture. Ultrasound and MRI can provide information on tendon structure and integrity in support of the diagnosis. When suspected, the potential agent should be withdrawn and not reintroduced where possible. Tendon ruptures may require surgery.

ILIOTIBIAL BAND SYNDROME

The iliotibial band is a thick connective tissue that runs from the ilium to the tibia. Iliotibial band syndrome most commonly presents with aching or burning pain where the band courses over the lateral femoral condyle of the knee; pain may also radiate up the thigh, toward the hip. Predisposing factors for iliotibial band syndrome include a varus alignment of the knee, distance running, poorly fitted shoes, or running on uneven terrain. Treatment consists of rest, NSAIDs, physical therapy, and addressing modifiable risk factors. Glucocorticoid injection into the area of tenderness can provide relief, but running must be avoided for at least 2 weeks after the injection. Surgical release of the iliotibial band has been helpful in rare patients for whom conservative treatment has failed.

ADHESIVE CAPSULITIS

Adhesive capsulitis ("frozen shoulder") is characterized by pain and restricted movement of the shoulder, usually in the absence of intrinsic shoulder disease. It most often develops in the setting of reduced arm mobility following bursitis or tendinitis of the shoulder, fractures, or recovery from surgery but can occur without an antecedent event. Adhesive capsulitis has been associated with systemic disorders such as diabetes mellitus, chronic pulmonary disease, myocardial infarction, and thyroid disease. Pathologically, the capsule of the shoulder is thickened, and a mild chronic inflammatory infiltrate and fibrosis may be present.

Adhesive capsulitis occurs more commonly in women over age 50. Pain and stiffness usually develop gradually but can rapidly progress. Night pain is often present in the affected shoulder and interferes with sleep. The shoulder is tender to palpation, and both active and passive movements are restricted. The diagnosis is based on physical examination showing a reduced range of motion in the shoulder that is not due to other causes. There are no diagnostic findings by plain radiograph, ultrasound, or MRI, but these can be used to rule out other conditions.

In most patients, the condition improves spontaneously 1–3 years after onset. While pain usually improves, many patients are left with

some limitation of shoulder motion. Early mobilization of the arm following a shoulder injury may prevent the development of this disorder. Physical therapy provides the foundation of treatment for adhesive capsulitis. Local glucocorticoid injection and NSAIDs may also provide relief of symptoms. Slow but forceful injection of contrast material into the joint may lyse adhesions and stretch the capsule, resulting in improvement of shoulder motion. Manipulation under anesthesia may be helpful in some patients.

LATERAL EPICONDYLITIS

Lateral epicondylitis, also known as tennis elbow, is a painful condition involving the soft tissue over the lateral aspect of the elbow. The pain originates at or near the site of attachment of the common extensors to the lateral epicondyle and may radiate into the forearm and dorsum of the wrist. The pain is usually linked to work or recreational activities that involve repeated motions of wrist extension and supination against resistance. Most patients with this disorder injure themselves in activities other than tennis, such as pulling weeds, carrying suitcases or briefcases, or using a screwdriver. The injury in tennis usually occurs when hitting a backhand with the elbow flexed. The pain can be reproduced by shaking hands or opening doors.

The treatment is usually rest with avoidance of activities that would aggravate the elbow along with an NSAID. Ultrasound, icing, and friction massage may also help relieve pain. When pain is severe, the elbow is placed in a sling or splinted at 90° of flexion. A one-time local glucocorticoid injection can be considered for severe, acute pain, but repeat injections should be avoided. After 4–6 weeks of rest, the patient should begin physical therapy to strengthen and increase flexibility of the extensor muscles. A forearm band placed 2.5–5.0 cm below the elbow may help to reduce tension on the extensor muscles at their attachment to the lateral epicondyle. The patient should be advised to restrict activities requiring forcible extension and supination of the wrist. The patient may continue to experience mild pain but, with care, can usually avoid the return of debilitating pain. In recalcitrant cases, ultrasound-guided needle tenotomy and injection of platelet-rich plasma have been used. Occasionally, surgical release of the extensor aponeurosis may be necessary.

MEDIAL EPICONDYLITIS

Medial epicondylitis is an overuse syndrome resulting in pain over the medial side of the elbow with radiation into the forearm. The cause of this syndrome is considered to be repetitive resisted motions of wrist flexion and pronation, which lead to microtears at the origin of the pronator teres and forearm flexors, particularly the flexor carpi radialis. This overuse syndrome is usually seen in patients aged >35 years and is much less common than lateral epicondylitis. It occurs most often in work-related repetitive activities and with recreational activities such as swinging a golf club or throwing a baseball. On physical examination, there is tenderness just distal to the medial epicondyle over the origin of the forearm flexors. Pain can be reproduced by resisting wrist flexion and pronation with the elbow extended. Radiographs are usually normal.

The initial treatment of medial epicondylitis is conservative, involving rest, NSAIDs, friction massage, ultrasound, and icing. Some patients may require splinting. For severe pain, a one-time local glucocorticoid injection can be considered. Patients should be instructed to rest for at least 4–6 weeks followed by physical therapy once the pain has subsided. In patients with chronic debilitating medial epicondylitis that remains unresponsive after at least a year of treatment, surgical release of the flexor muscle at its origin may be necessary and is often successful.

PLANTAR FASCIITIS

Plantar fasciitis is a common cause of foot pain in adults. The pain originates at or near the site of the plantar fascia attachment to the medial tuberosity of the calcaneus. Factors that increase the risk of developing plantar fasciitis include obesity, pes planus (flat foot or absence of the foot arch when standing), pes cavus (high-arched foot), limited dorsiflexion of the ankle, prolonged standing, walking on hard surfaces, and faulty shoes. In runners, excessive running and a change to a harder running surface may precipitate plantar fasciitis.

The diagnosis of plantar fasciitis can usually be made on the basis of history and physical examination alone. Patients experience severe pain with the first steps on arising in the morning or following inactivity during the day. The pain usually lessens with weight-bearing activity but then increases with continued activity. Pain is made worse on walking barefoot or going up stairs. On examination, tenderness is elicited on palpation over the inferior heel at the attachment site of the plantar fascia to the calcaneus. Imaging may be indicated when the diagnosis is not clear. Plain radiographs may show heel spurs, which are of little diagnostic significance. Ultrasonography in plantar fasciitis can demonstrate thickening of the fascia and diffuse hypoechogenicity, indicating edema at the attachment of the plantar fascia to the calcaneus. MRI is a sensitive method for detecting plantar fasciitis, but it is usually not required to establish the diagnosis.

Resolution of symptoms occurs within 12 months in >80% of patients with plantar fasciitis. Initial treatment consists of ice, heat, massage, stretching, and eliminating inciting activities. Orthotics provide medial arch support and can be effective. Some patients may benefit from foot strapping or taping or by wearing a night splint designed to keep the ankle in a neutral position. A short course of NSAIDs can be given to patients who do not have contraindications. Local glucocorticoid injections have also been shown to be efficacious but may carry an increased risk for plantar fascia rupture. Plantar fasciotomy is reserved for patients who have failed to improve after at least 6–12 months of conservative treatment.

FURTHER READING

Buchbinder R: Plantar fasciitis. N Engl J Med 350:2159, 2004.

Greis AC et al: Evaluation and nonsurgical management of rotator cuff calcific tendinopathy. Orthop Clin North Am 46:293, 2015.

Harrison AK, Flatow EL: Subacromial impingement syndrome. J Am Acad Orthop Surg 19:701, 2011.

Kirchgesner T et al: Drug-induced tendinopathy: From physiology to clinical applications. Joint Bone Spine 81:485, 2014.

Neviaser AS, Neviaser RJ: Adhesive capsulitis of the shoulder. J Am Acad Orthop Surg 19:536, 2011.

This page intentionally left blank