undergo chest CT. Diseases causing cough that may be missed on chest x-ray include tumors, early interstitial lung disease, bronchiectasis, and atypical mycobacterial pulmonary infection. On the other hand, patients with chronic cough who have normal findings on chest examination, lung function testing, oxygenation assessment, and chest CT can be reassured as to the absence of serious pulmonary pathology.

GLOBAL CONSIDERATIONS

Regular exposure to air pollution can cause chronic cough and throat clearing, as well as lower respiratory tract disease. Smoke from cooking and heating fuels in poorly ventilated homes; toxic exposures in work settings lacking implementation of occupational safety standards; and ambient chemicals and particulates in highly polluted outdoor air are all forms of air pollution causing cough. Limited therapeutic options are available; treatment focuses on improving environmental air quality (e.g., use of a stove chimney in the home), removal from the exposure, and use of an appropriate face mask.

In areas of the world where tuberculosis is endemic, chronic cough conjures the possibility of active pulmonary tuberculosis and mandates appropriate evaluation, including chest imaging and sputum analysis.

SYMPTOM-BASED TREATMENT OF COUGH

Empiric treatment of chronic idiopathic cough with inhaled corticosteroids, inhaled anticholinergic bronchodilators, and macrolide antibiotics has been tried without consistent success. Currently available cough suppressants are only modestly effective. Most potent are narcotic cough suppressants, such as codeine, hydrocodone, or morphine, which are thought to act in the "cough center" in the brainstem. The tendency of narcotic cough suppressants to cause drowsiness and constipation and their potential for addictive dependence limit their appeal for long-term use. Dextromethorphan is an over-the-counter, centrally acting cough suppressant with fewer side effects and less efficacy than the narcotic cough suppressants. Dextromethorphan is thought to have a different site of action than narcotic cough suppressants and can be used in combination with them if necessary. Benzonatate is thought to inhibit neural activity of sensory nerves in the cough-reflex pathway. It is generally free of side effects; however, its effectiveness in suppressing cough is variable and unpredictable. Inhaled lidocaine, an inhibitor of voltage-gated sodium channels, provides transient cough suppression, but because of associated oropharyngeal anesthesia, it poses an increased risk of aspiration.

Attempts to treat cough hypersensitivity syndrome have focused on inhibition of neural pathways. Small case series and randomized clinical trials have indicated benefit from off-label use of gabapentin, pregabalin, or amitriptyline. Recent studies suggest a role for behavioral modification using specialized speech therapy techniques, but widespread application of this modality is currently not practical. Novel cough suppressants without the limitations of currently available agents are greatly needed. Approaches that are being explored include the development of neurokinin-1 receptor antagonists, transient receptor protein vanilloid-1 (TRPV1) channel antagonists, P2X3 channel antagonists, and novel opioid and opioid-like receptor agonists.

Acknowledgment

Christopher H. Fanta contributed to this chapter in the 21st edition and some material from that chapter has been retained here.

FURTHER READING

Brightling CE et al: Eosinophilic bronchitis as an important cause of chronic cough. Am J Respir Crit Care Med 160:406, 1999.

Carroll TL (ed): *Chronic Cough*. San Diego, Plural Publishing, Inc., 2019.

Gibson P et al: Treatment of unexplained chronic cough: CHEST guideline and expert panel report. Chest 149:27, 2016.

Kahrilas PJ et al: Chronic cough due to gastroesophageal reflux in adults: CHEST Guideline and Expert Panel Report. Chest 150:1381, 2016.

Mazzone SB et al: Chronic cough and cough hypersensitivity: From mechanistic insights to novel antitussives. Lancet Respir Med 10:1113, 2022.

Morice AH et al: ERS guidelines on the diagnosis and treatment of chronic cough in adults and children. Eur Respir J 55:1901136, 2020.

Smith JA, Woodcock A: Chronic cough. N Engl J Med 375:1544, 2016.

41 Hemoptysis

Erin M. DeBiasi, Carolyn D'Ambrosio

Hemoptysis is the expectoration of blood originating from the lower respiratory tract. It can be confused initially with bleeding from the gastrointestinal tract (hematemesis) or nasal cavities (epistaxis). The amount of blood that is being expectorated (volume and frequency) is the most important information to gather as massive or life-threatening hemoptysis (variable definitions but commonly expectorating >150 mL in 24 h or a bleeding rate of ≥100 mL/h) requires emergent intervention. This chapter focuses on non-life-threatening hemoptysis, which is more common.

ANATOMY AND PHYSIOLOGY OF HEMOPTYSIS

Hemoptysis originates in the lower respiratory tract, anywhere from the glottis to the alveolus. The bleeding most commonly arises from the bronchi or medium-sized airways, but a thorough evaluation of the entire respiratory tree is important. The blood supply to the lungs is from both the pulmonary and bronchial circulations. The pulmonary circulation is a low-pressure system that is essential for gas exchange at the alveoli; in contrast, the bronchial circulation originates from the aorta and, thus, is a higher-pressure system. The bronchial arteries supply the airways and can neovascularize tumors, dilated airways in bronchiectasis, and cavitary lesions. Most hemoptysis originates from the bronchial circulation, the higher-pressure system, which can make it difficult to control.

ETIOLOGY

Infection, malignancy, and vascular disease are some of the common causes of hemoptysis, but the differential is quite broad. In the United States, the most common causes remain viral bronchitis, bronchiectasis, or malignancy. In other parts of the world, infections such as tuberculosis are the most common causes.

INFECTIONS

Although most small-volume hemoptysis cases are due to viral bronchitis, patients with chronic bronchitis are at risk for bacterial superinfection. *Streptococcus pneumoniae*, *Haemophilus influenzae*, and *Moraxella catarrhalis* are the more common bacteria involved, and these infections can increase airway inflammation that leads to bleeding. Similarly, patients with bronchiectasis, including those with cystic fibrosis, can have hemoptysis during exacerbations. Due to recurrent bacterial infection, bronchiectatic airways are dilated, inflamed, and highly vascular, supplied by the bronchial circulation. This can cause bronchiectasis to also be a significant cause of massive hemoptysis and subsequent death.

Tuberculosis used to be the most common cause of hemoptysis worldwide, but in industrialized countries, bronchitis and bronchiectasis are more common. In patients with tuberculosis, development of cavitary disease is frequently the source of bleeding, but rarer complications such as erosion of a pulmonary artery aneurysm into a preexisting cavity (i.e., Rasmussen's aneurysm) can also be the source.

Other infectious agents such as endemic fungi, *Nocardia*, and nontuberculous mycobacteria can present as cavitary lung disease complicated by hemoptysis. In addition, *Aspergillus* species can develop into mycetomas within preexisting cavities, with neovascularization to these inflamed spaces leading to bleeding. Pulmonary abscesses and necrotizing pneumonia can cause bleeding by devitalizing lung parenchyma. Common responsible organisms include *Staphylococcus aureus, Klebsiella pneumoniae*, and oral anaerobes.

Paragonimiasis can mimic tuberculosis and is another significant cause of hemoptysis seen globally; it is common in Southeast Asia and China, although cases have been reported in North America from raw

crayfish ingestion. It should be considered as a cause of hemoptysis in recent immigrants from endemic areas.

VASCULAR

Hemoptysis from a vascular cause can be associated with cardiac disease, pulmonary embolism, arteriovenous malformation, or diffuse alveolar hemorrhage (DAH). While the classic description of the sputum expectorated in pulmonary edema (from elevated left end-diastolic pressure) is "pink and frothy," a spectrum of hemoptysis including frank blood can be seen. This observation is particularly true now with the more widespread use of anticoagulants and antiplatelet medications.

Pulmonary embolism with parenchymal infarction can present with hemoptysis, but pulmonary emboli do not commonly cause hemoptysis. An ectatic vessel in an airway or a pulmonary arteriovenous malformation can be a source of bleeding. A rare vascular cause of hemoptysis is the rupture of an aortobronchial fistula; these fistulae arise in the setting of aortic pathology such as aneurysm or pseudoaneurysm and can cause small bleeding episodes that result in massive hemoptysis.

DAH causes significant bleeding into the lung parenchyma but, interestingly, is not often associated with hemoptysis. DAH typically presents with diffuse ground-glass opacities on chest imaging. A range of insults cause DAH, including immune-mediated capillaritis from diseases such as systemic lupus erythematosus, toxicity from cocaine and other inhalants, and stem cell transplantation. The so-called "pulmonary-renal" syndromes, including granulomatosis with polyangiitis and anti–glomerular basement membrane (anti-GBM) disease, may lead to both hemoptysis and hematuria (though one manifestation may be present without the other). A recently identified cause of hemoptysis and DAH is vaping-induced lung injury.

MALIGNANCY

Bronchogenic carcinoma of any histology is a common cause of hemoptysis (both massive and nonmassive). Hemoptysis can indicate airway involvement of the tumor and can be a presenting symptom of carcinoid tumors, vascular lesions that frequently arise in the proximal airways. Small-cell and squamous cell carcinomas are frequently central in nature and more likely to erode into major pulmonary vessels, resulting in massive hemoptysis. Pulmonary metastases from distant tumors (e.g., melanoma, sarcoma, adenocarcinomas of the breast and colon) can also cause bleeding. Kaposi's sarcoma, seen in advanced acquired immunodeficiency syndrome, is very vascular and can develop anywhere along the respiratory tract, from the bronchi to the oral cavity.

MECHANICAL AND OTHER CAUSES

In addition to infection, vascular disease, and malignancy, other insults to the pulmonary system can cause hemoptysis. Pulmonary endometriosis causes cyclical bleeding known as catamenial hemoptysis. Foreign body aspiration can lead to airway irritation and bleeding. Diagnostic and therapeutic procedures are also potential offenders: pulmonary vein stenosis can result from left atrial procedures, such as pulmonary vein isolation, and pulmonary artery catheters can lead to rupture of the pulmonary artery if the distal balloon is kept inflated. Finally, in the setting of thrombocytopenia, coagulopathy, anticoagulation, or antiplatelet therapy, even minor insults can cause hemoptysis.

EVALUATION AND MANAGEMENT

HISTORY

The initial history should be directed at assessing the pattern, severity, and quantity of hemoptysis. An approach to management of hemoptysis is outlined in Fig. 41-1. A patient's description of the sputum (e.g., flecks of blood, pink-tinged, frank blood or clot) is helpful if you cannot examine it. Quantification is often challenging for patients, so using references like cups (one U.S. cup is 236 mL) can be helpful. Life-threatening hemoptysis is defined by the presence of significantly abnormal gas exchange, hemodynamic compromise, or threat for airway obstruction. Patients rarely die of exsanguination but, rather, are at risk of death due to asphyxiation from blood filling the airways and airspaces. This can occur with blood loss of >400 mL within 24 h or >150 mL at one time. Fortunately, life-threatening hemoptysis only accounts for 5–15% of cases of hemoptysis.

Further history may help define the etiology of hemoptysis. Smoking history and/or unintentional weight loss may point to possible malignancy. Preceding fevers, cough, and/or sputum production may suggest infection. A history of prior diagnosed chronic lung conditions, especially cystic fibrosis or other chronic bronchiectatic diseases, is important to note. Screening for causes of pseudohemoptysis (i.e., other upper airway or gastrointestinal) is also helpful.

PHYSICAL EXAMINATION

Patients should initially be assessed for signs of life-threatening hemoptysis including hypoxemia, tachycardia, and hemodynamic instability. Examination should include possible sites of extrapulmonary bleeding such as the nasal and oral cavities. Auscultation of the lungs may suggest a laterality. Other relevant physical findings may suggest other etiologies of the hemoptysis and include clubbing, signs of a bleeding diathesis (e.g., skin or mucosal ecchymoses and petechiae), telangiectasias, or skin rash.

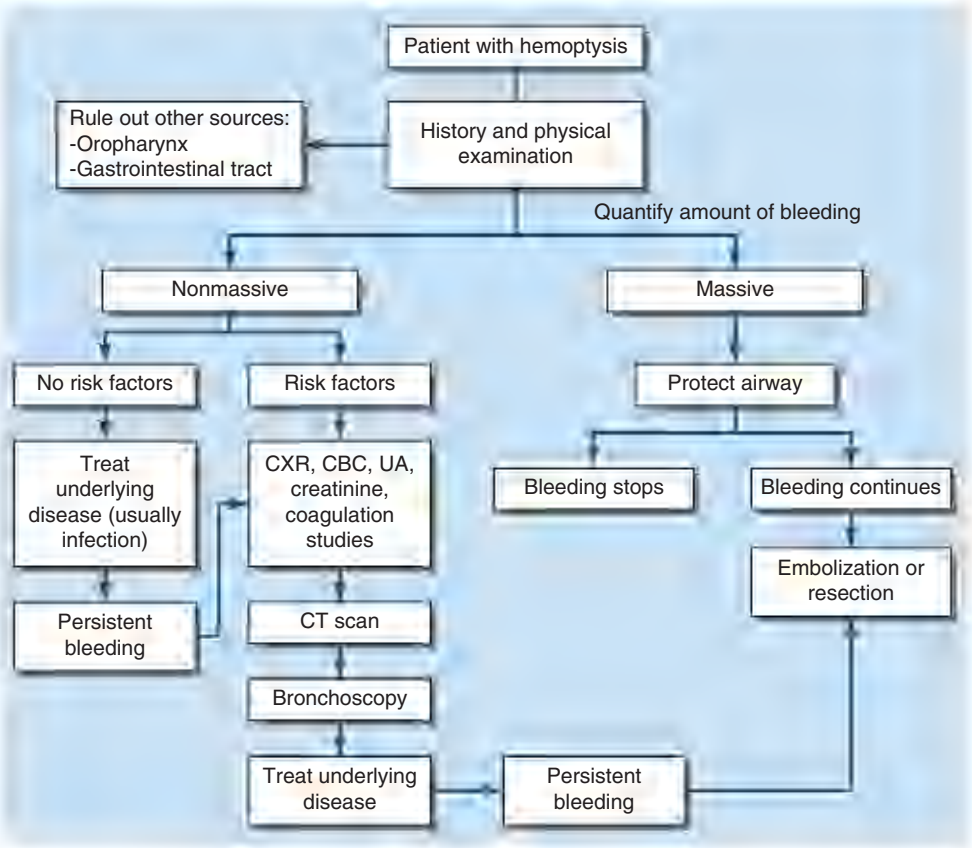

FIGURE 41-1 Approach to the management of hemoptysis. CBC, complete blood count; CT, computed tomography; CXR, chest x-ray; UA, urinalysis.

DIAGNOSTIC STUDIES

Laboratory studies for initial evaluation should include a complete blood count, coagulation studies, basic metabolic panel, and urinalysis (to evaluate for pulmonary-renal disease). The absence of anemia in life-threatening hemoptysis is not uncommon, as asphyxiation can occur without large blood volume loss. Infectious workup (including bacterial sputum culture, acid-fast bacillus culture, and respiratory viral panel) and serologic workup (including antinuclear antibody, antineutrophilic cytoplasmic antibody, and anti-GBM) can be obtained if indicated.

Imaging of the chest is essential. While a chest radiograph is often first obtained, aside from large masses, it often does not localize the site and can be normal. In most patients without risk factors for malignancy or other abnormalities in the initial evaluation and with a normal chest radiograph, treating for bronchitis and ensuring close follow-up is a reasonable strategy, with further diagnostic workup.

In contrast, patients with risk factors for malignancy (i.e., age >40, especially those with risk factors for malignancy or significant hemoptysis) should have a chest computed tomography (CT). A chest CT identifies the site and cause of hemoptysis in the majority of patients. A CT angiogram can be considered to identify a source for possible embolization if needed. A diagnostic bronchoscopy can be a complimentary study performed to evaluate for subtle mucosal lesions that are often missed on CT scans, perform interventions as per below, or localize the general location and laterality of bleeding. This is best performed during an acute episode of hemoptysis to increase the yield.

INTERVENTIONS

When the amount of hemoptysis is life-threatening, there are three simultaneous goals: first, protect the nonbleeding lung; second, locate the site of bleeding; and third, control the bleeding.

Protecting the airway and nonbleeding lung is paramount in the management of life-threatening hemoptysis because asphyxiation can happen quickly. If the side of bleeding is known, the patient should be positioned with the bleeding side down to use gravitational advantage to keep blood out of the nonbleeding lung. A strong cough reflex can often be highly effective at clearing clot from the airway, but intubation is sometimes necessary if the patient cannot protect their airway. Intubation with a large endotracheal tube (size 8.5) is preferred to allow for suctioning and interventions. If needed, this can be advanced into the mainstem airway of the nonbleeding lung for isolation. Double-lumen endotracheal tubes can also be used, but the lumen of each is often too small for suctioning and therapeutic interventions.

Imaging obtained during initial evaluation can indicate the source of the bleeding. Flexible bronchoscopy during active bleeding is most useful. Even if a bleeding lesion is not identified, flexible bronchoscopy can help identify a side and lobe. Finally, proceeding directly to CT angiography is also a reasonable strategy given that it has both diagnostic and therapeutic capabilities.

Controlling the bleeding during an episode of life-threatening hemoptysis can be accomplished in one of three ways: from the airway lumen, from the involved blood vessel, or by surgical resection of both airway and vessel involved. Any known bleeding diathesis should be corrected first. As above, bronchoscopic measures can often be diagnostic, but also therapeutic if the bleeding is from a central airway lesion. Initially, a flexible bronchoscope can be used to help stabilize a patient via suctioning clot and insertion of a balloon catheter or bronchial blocker to occlude the involved airway. Additionally, instillation of iced saline or epinephrine can help temporize bleeding. Tranexamic acid (TXA), an antifibrinolytic agent (500 mg/5 mL), can be instilled during bronchoscopy or administered via nebulizer. Rigid bronchoscopy, done by an interventional pulmonologist or thoracic surgeon, allows therapeutic interventions of bleeding airway lesions such as argon plasma coagulation and cautery, which can be definitive. However, because most life-threatening cases of hemoptysis arise from the bronchial circulation, bronchial artery embolization is the procedure of choice for control of the bleeding. It is generally successful in the short term, with >80% success rate at controlling bleeding immediately, although bleeding can recur if the underlying disease (e.g., a mycetoma) is not treated. Surgical resection has a high mortality rate (up to 15–40%) and should not be pursued unless initial measures have failed and bleeding is ongoing. Ideal candidates for surgery have localized disease but otherwise normal lung parenchyma.

Acknowledgment

Anna K. Brady and Patricia A. Kritek contributed to this chapter in the 20th edition and some material from that chapter has been retained here.

FURTHER READING

Bellam BL et al: Efficacy of tranexamic acid in haemoptysis: A randomized, controlled pilot study. Pulm Pharmacol Ther 40:80, 2016.

Davidson K, Shojaee S: Managing massive hemoptysis. Chest 157:77, 2020.

Flume PA et al: CF pulmonary guidelines. Pulmonary complications: Hemoptysis and pneumothorax. Am J Respir Crit Care Med 182:298, 2010.

Layden JE et al: Pulmonary illness related to e-cigarette use in Illinois and Wisconsin-final report. N Engl J Med 382:903, 2020.

Lim RK et al: Evaluating hemoptysis hospitalizations among patients with bronchiectasis in the United States: A population-based cohort study. BMC Pulm Med 21:392, 2021.

Mondoni M et al: Observational, multicentre study on the epidemiology of haemoptysis. Eur Resp J 51:1701813, 2018.

Mondoni M et al: Bronchoscopy to assess patients with hemoptysis: Which is the optimal timing? BMC Pulm Med 19:36, 2019.

42 Hypoxia and Cyanosis

Joseph Loscalzo

HYPOXIA

The fundamental purpose of the cardiorespiratory system is to deliver O_2 and nutrients to cells and to remove CO_2 and other metabolic products from them. Proper maintenance of this function depends not only on intact cardiovascular and respiratory systems, but also on an adequate number of red blood cells and hemoglobin, and a supply of inspired gas containing adequate O_2.

RESPONSES TO HYPOXIA

Decreased O_2 availability to cells typically results in an inhibition of oxidative phosphorylation and increased anaerobic glycolysis. This switch from aerobic to anaerobic metabolism, the Pasteur effect, reduces the yield of adenosine 5′-triphosphate (ATP) produced per mole of glucose. In severe hypoxia, when ATP production is inadequate to meet the energy requirements of ionic and osmotic equilibrium, cell membrane depolarization leads to uncontrolled Ca^{2+} influx and activation of Ca^{2+}-dependent phospholipases and proteases. These events, in turn, cause cell swelling, activation of apoptotic pathways, and, ultimately, cell death.

The adaptations to hypoxia are mediated, in part, by the upregulation of genes encoding a variety of proteins, including glycolytic enzymes, such as phosphoglycerate kinase and phosphofructokinase, as well as the glucose transporters Glut-1 and Glut-2; and by growth factors, such as vascular endothelial growth factor (VEGF) and erythropoietin, which enhance erythrocyte production. The hypoxia-induced increase in expression of these and other key proteins is largely governed by the hypoxia-sensitive transcription factor, hypoxia-inducible factor-1 (HIF-1).

During hypoxia, systemic arterioles dilate, at least in part, by opening of K_{ATP} channels in vascular smooth-muscle cells due to the hypoxia-induced reduction in ATP concentration. By contrast, in pulmonary