Section 1 Diagnosis of Neurologic Disorders

433 Approach to the Patient with Neurologic Disease

Daniel H. Lowenstein, S. Andrew Josephson, Stephen L. Hauser

Neurologic diseases are common and costly. According to estimates by the World Health Organization, neurologic disorders affect nearly one in three individuals and represent the leading cause of disability and the second leading cause of death worldwide (Fig. 433-1). These numbers have increased significantly over the past 30 years and are expected to double by 2050, due to multiple factors, including aging of the population, population growth, and a rising prevalence of metabolic risk conditions.

Because therapies now exist for many neurologic disorders, a skillful approach to diagnosis is essential. Errors commonly result from an over-reliance on costly neuroimaging procedures and laboratory tests, which, while useful, do not substitute for an adequate history and examination. The proper approach begins with the patient and focuses the clinical problem, first in anatomic and then in pathophysiologic terms; only then should a specific neurologic diagnosis be entertained. This method ensures that technology is judiciously applied, a correct diagnosis is established in an efficient manner, and treatment is promptly initiated.

THE NEUROLOGIC METHOD

DEFINE THE ANATOMY

The first priority is to identify the region of the nervous system that is likely to be responsible for the symptoms. Can the disorder be mapped to one specific location, is it multifocal, or is a diffuse process present? Are the symptoms restricted to the nervous system, or do they arise in the context of a systemic illness? Is the problem in the central nervous system (CNS), the peripheral nervous system (PNS), or both? In the CNS, is the cerebral cortex, basal ganglia, brainstem, cerebellum, or spinal cord responsible? Are the pain-sensitive meninges involved? In the PNS, could the disorder be located in peripheral nerves and, if

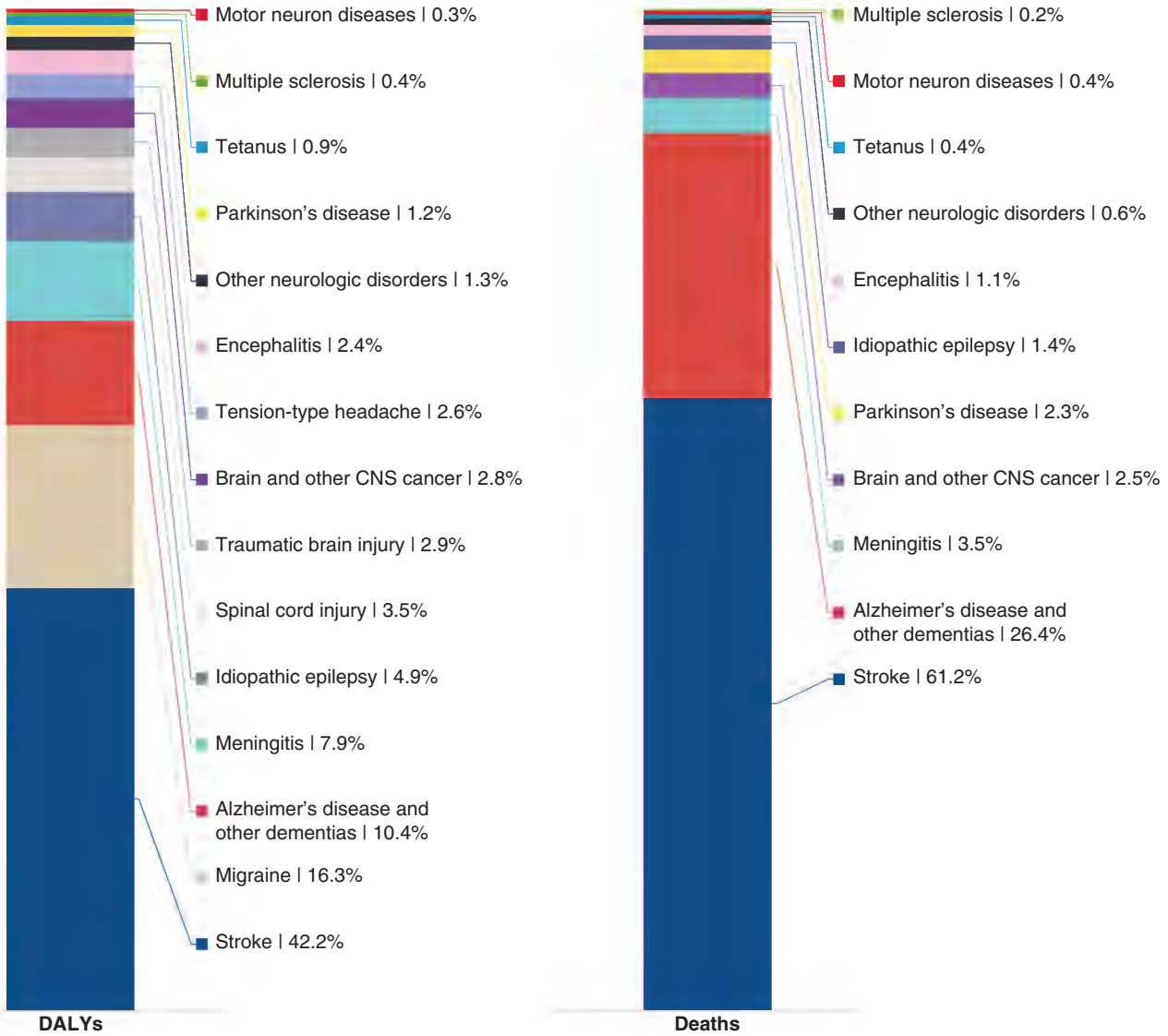

FIGURE 433-1 Proportional contributions to the overall global burden of neurologic disorders. Proportions (%) of disability-adjusted life-years (DALYs) and deaths. *(Based on data from GBD 2016 Neurology Collaborators: Lancet Neurol 18:459, 2019.)*

so, are motor or sensory nerves primarily affected, or is a lesion in the neuromuscular junction or muscle more likely?

The first clues to defining the anatomic area of involvement appear in the history, and the examination is then directed to confirm or rule out these impressions and to clarify uncertainties. A more detailed examination of a particular region of the CNS or PNS is often indicated. For example, the examination of a patient who presents with a history of ascending paresthesias and weakness should be directed toward deciding, among other things, if the lesion is in the spinal cord or peripheral nerves. Focal back pain, a spinal cord sensory level, and incontinence suggest a spinal cord origin, whereas a stocking-glove pattern of sensory loss suggests peripheral nerve disease; areflexia usually indicates peripheral neuropathy but may also be present, typically transiently, with acute spinal cord disorders.

Deciding "where the lesion is" accomplishes the task of limiting the possible etiologies to a manageable, finite number. In addition, this strategy safeguards against making serious errors. Symptoms of recurrent vertigo, diplopia, and nystagmus should not trigger "multiple sclerosis" as an answer (etiology) but "brainstem" or "pons" (location); then a diagnosis of brainstem arteriovenous malformation will not be missed for lack of consideration. Similarly, the combination of visual blurring and spastic ataxic paraparesis suggests possible optic nerve and spinal cord disease; multiple sclerosis (MS), CNS syphilis, and vitamin B_{12} deficiency are treatable disorders that can produce this syndrome. Once the question, "Where is the lesion?" is answered, then the question "What is the lesion?" can be addressed.

IDENTIFY THE PATHOPHYSIOLOGY

Clues to the pathophysiology of the disease process may also be present in the history. Primary neuronal (gray matter) disorders often present as early cognitive disturbances, movement disorders, or seizures, whereas disorders of the connecting pathways (white matter involvement) produce "long tract" motor, sensory, visual, and/or cerebellar manifestations. Progressive and symmetric symptoms often have a metabolic or degenerative origin; in such cases, lesions are usually not sharply circumscribed. Thus, a patient with paraparesis and a clear spinal cord sensory level is unlikely to have vitamin B_{12} deficiency as the explanation. A Lhermitte symptom (electric shock–like sensations evoked by neck flexion) is due to ectopic impulses that arise in white matter pathways and occurs with demyelination in the cervical spinal cord; among many possible causes, this symptom may indicate MS in a young adult or compressive cervical spondylosis in an older person. Symptoms that worsen after exposure to heat or exercise may indicate conduction block in demyelinated axons, as occurs in MS. A patient with recurrent episodes of diplopia and dysarthria associated with exercise or fatigue may have a disorder of neuromuscular transmission such as myasthenia gravis. Slowly advancing visual scotoma with luminous edges, termed *fortification spectra*, indicates spreading cortical depression, typically with migraine.

THE NEUROLOGIC HISTORY

Attention to the description of symptoms experienced by the patient and substantiated by family members and others often permits an accurate localization and determination of the probable cause, even before the neurologic examination is performed. The history also helps focus the neurologic examination that follows. Each complaint should be pursued as far as possible to identify the location of the lesion, the likely underlying pathophysiology, and potential etiologies. For example, a patient complains of weakness of the right arm. What are the associated features? Does the patient have difficulty with brushing hair or reaching upward (proximal) or fastening buttons or opening a plastic bottle (distal)? Negative associations may also be crucial. A right-handed patient with a right hemiparesis without a language deficit likely has a lesion (internal capsule, brainstem, or spinal cord) different from that of a patient with a right hemiparesis and aphasia (left hemisphere). Other pertinent features of the history include the following:

1. *Temporal course of the illness*. It is important to determine the precise time of appearance and rate of progression of the symptoms experienced by the patient. The rapid onset of a neurologic complaint, occurring within seconds or minutes, usually indicates a vascular event, a seizure, or migraine. The onset of sensory symptoms located in one extremity that spread over a few seconds to adjacent portions of that extremity and then to the other regions of the body suggests a seizure. A similar but slower temporal march of symptoms accompanied by headache, nausea, or visual disturbance suggests migraine. Less well-localized symptoms that are maximum at onset and persist for seconds, minutes, or much less commonly hours, point to the possibility of a transient ischemic attack (TIA). The presence of "positive" sensory symptoms (e.g., tingling or sensations that are difficult to describe) or involuntary motor movements suggests a seizure; in contrast, transient loss of function (negative symptoms) suggests a TIA. A stuttering onset where symptoms appear, stabilize, and then progress over hours or days also suggests cerebrovascular disease; an additional history of transient remission or regression indicates that the process is more likely due to ischemia rather than hemorrhage. A gradual evolution of symptoms over hours or days suggests a toxic, metabolic, infectious, or inflammatory process. Progressing symptoms associated with the systemic manifestations of fever, stiff neck, and altered level of consciousness imply an infectious process. Relapsing and remitting symptoms involving different levels of the nervous system suggest MS or other inflammatory processes. Slowly progressive symptoms without remissions are characteristic of neurodegenerative disorders, chronic infections, gradual intoxications, and neoplasms.
2. *Patients' descriptions of the complaint*. The same words often mean different things to different patients. "Dizziness" may imply impending syncope, a sense of disequilibrium, or true spinning vertigo. "Numbness" may mean a complete loss of feeling, a positive sensation such as tingling, or even weakness. "Blurred vision" may be used to describe unilateral visual loss, as in transient monocular blindness, or diplopia. The interpretation of the true meaning of the words used by patients to describe symptoms obviously becomes even more complex when there are differences in primary languages and cultures.
3. *Corroboration of the history by others*. It is almost always helpful to obtain additional information from family, friends, or other observers to corroborate or expand the patient's description. Memory loss, aphasia, loss of insight, intoxication, and other factors may impair the patient's capacity to communicate normally with the examiner or prevent openness about factors that have contributed to the illness. Episodes of loss of consciousness necessitate that details be sought from observers to ascertain precisely what has happened during the event.
4. *Family history*. Many neurologic disorders have an underlying genetic component. The presence of a Mendelian disorder, such as Huntington's disease or Charcot-Marie-Tooth neuropathy, is often obvious if family data are available. Clearly note if the family history has been fully ascertained or if some branches of the family could not be traced. More detailed questions about family history are often necessary in polygenic disorders such as MS, migraine, and many types of epilepsy. It is important to elicit family history about all illnesses, in addition to neurologic and psychiatric disorders. A familial propensity to hypertension or heart disease is relevant in a patient who presents with a stroke. Numerous inherited neurologic diseases are associated with multisystem manifestations that may provide clues to the correct diagnosis (e.g., neurofibromatosis, Wilson's disease, mitochondrial disorders).
5. *Medical illnesses*. Many neurologic diseases occur in the context of systemic disorders. Diabetes mellitus, hypertension, and abnormalities of blood lipids predispose to cerebrovascular disease. A solitary mass lesion in the brain may be an abscess in a patient with valvular heart disease, a primary hemorrhage in a patient with a coagulopathy, a lymphoma or toxoplasmosis in a patient with AIDS, or a metastasis in a patient with underlying cancer. Patients with malignancy may also present with a neurologic paraneoplastic syndrome **(Chap. 99)** or complications from chemotherapy, immunotherapy,

or radiotherapy. Marfan's syndrome and related collagen disorders predispose to dissection of the cranial arteries and aneurysmal subarachnoid hemorrhage; the latter may also occur with polycystic kidney disease and fibromuscular dysplasia. Various neurologic disorders occur with dysthyroid states or other endocrinopathies. It is especially important to look for the presence of systemic diseases in patients with peripheral neuropathy. Most patients with coma in a hospital setting have a metabolic, toxic, or infectious cause.

6. *Drug use and abuse and toxin exposure*. It is essential to inquire about the history of drug use, both prescribed and illicit. Sedatives, antidepressants, and other psychoactive medications are frequently associated with acute confusional states, especially in the elderly. Aminoglycoside antibiotics may exacerbate symptoms of weakness in patients with disorders of neuromuscular transmission, such as myasthenia gravis, and may cause dizziness secondary to ototoxicity. Vincristine and other antineoplastic drugs can cause peripheral neuropathy, immunosuppressive agents such as cyclosporine can produce encephalopathy, and immunotherapies with checkpoint inhibitors and chimeric antigen receptor (CAR) T cells are associated with various neurotoxicities including brain edema, inflammation, and demyelination **(Chap. 318)**. Excessive vitamin ingestion can lead to disease; examples include vitamin A and intracranial hypertension ("pseudotumor cerebri") or pyridoxine and peripheral neuropathy. Many patients are unaware that over-the-counter sleeping pills, cold preparations, and diet pills are actually drugs. Alcohol, the most prevalent neurotoxin, is often not recognized as such by patients, and other drugs of abuse such as cocaine, methamphetamine, and heroin can cause a wide range of neurologic abnormalities. A history of environmental or industrial exposure to neurotoxins may provide an essential clue; consultation with the patient's coworkers or employer may be required.
7. *Formulating an impression of the patient*. Use the opportunity while taking the history to form an impression of the patient. Is the information forthcoming, or does it take a circuitous course? Is there evidence of anxiety, depression, or hypochondriasis? Are there any clues to problems with language, memory, insight, comportment, or behavior? The neurologic assessment begins as soon as the patient comes into the room and the first introduction is made.

THE NEUROLOGIC EXAMINATION

The neurologic examination can be challenging and complex; it has many components and includes a number of skills that can be mastered only through repeated use of the same techniques on a large number of individuals with and without neurologic disease. Mastery of the complete neurologic examination is usually important only for physicians in neurology and associated specialties. However, knowledge of the basics of the examination, especially those components that are effective in screening for neurologic dysfunction, is essential for all clinicians, especially generalists.

There is no single, universally accepted sequence of the examination that must be followed, but most clinicians begin with assessment of mental status followed by the cranial nerves (CN), motor system, reflexes, sensory system, coordination, and gait. Whether the examination is basic or comprehensive, it is essential that it is performed in an orderly and systematic fashion to avoid errors and serious omissions. Thus, the best way to learn and gain expertise in the examination is to choose one's own approach and practice it frequently and do it in the same exact sequence each time. Essential tools for the examination should be accessible whenever the exam goes beyond screening, including a Snellen visual chart, portable ophthalmoscope, reflex hammer, a 128-Hz tuning fork, and disposable cotton wisps, tongue depressors, and pins.

The detailed description that follows describes the more commonly used parts of the neurologic examination, with a particular emphasis on the components that are considered most helpful for the assessment of common neurologic problems. Each section also includes a brief description of the minimal examination necessary to adequately screen for abnormalities in a patient who has no symptoms suggesting neurologic dysfunction. A screening examination done in this way can be completed in 3–5 min. *Video demonstrations of the neurologic screening examination (V6) and the detailed neurologic examination (V7) can be found in the Harrison's Video Collection included in this textbook*.

Several additional points about the examination are worth noting. First, in recording observations, it is important to describe what is found rather than to apply a poorly defined medical term (e.g., "patient groans to sternal rub" rather than "obtunded"). Second, subtle CNS abnormalities are best detected by carefully comparing a patient's performance on tasks that require simultaneous activation of both cerebral hemispheres (e.g., eliciting a pronator drift of an outstretched arm with the eyes closed; extinction on one side of bilaterally applied light touch, also with eyes closed; or decreased arm swing or a slight asymmetry when walking). Third, if the patient's complaint is brought on by some activity, reproduce the activity in the office. If the complaint is of dizziness when the head is turned in one direction, have the patient do this and also look for associated signs on examination (e.g., nystagmus or dysmetria). If pain or weakness occurs after walking two blocks, have the patient leave the office and walk this distance and immediately return, and repeat the relevant parts of the examination. Finally, the use of tests that are individually tailored to the patient's problem can be of value in assessing changes over time. Tests of walking a 7.5-m (25-ft) distance (normal, 5–6 s; note assistance, if any), repetitive finger or toe tapping (normal, 20–25 taps in 5 s), or handwriting are examples.

MENTAL STATUS EXAMINATION

- *The bare minimum: During the interview, look for difficulties with communication and determine whether the patient has recall and insight into recent and past events.*

The mental status examination is underway as soon as the physician begins observing and speaking with the patient. If the history raises any concern for abnormalities of higher cortical function or if cognitive problems are observed during the interview, then detailed testing of the mental status is indicated. The patient's ability to understand the language used for the examination, cultural background, educational experience, sensory or motor problems, or comorbid conditions must be factored into the applicability of the tests and interpretation of results.

The Mini-Mental State Examination (MMSE) is a standardized screening examination of cognitive function that is extremely easy to administer and takes <10 min to complete **(Chap. 31)**. Using age-adjusted values for defining normal performance, the test is ~85% sensitive and 85% specific for making the diagnosis of dementia that is moderate or severe, especially in educated patients. When there is sufficient time available in the outpatient setting, the MMSE is one of the best methods for documenting the current mental status of the patient, and this is especially useful as a baseline assessment to which future scores of the MMSE can be compared.

Individual elements of the mental status examination can be subdivided into level of consciousness, orientation, speech and language, memory, fund of information, insight and judgment, abstract thought, and calculations.

Level of consciousness is the patient's relative state of awareness of self and the environment, and ranges from fully awake to comatose. When the patient is not fully awake, the examiner should describe the responses to the minimum stimulus necessary to elicit a reaction, ranging from verbal commands to a brief, painful stimulus such as a squeeze of the trapezius muscle. Responses that are directed toward the stimulus and signify some degree of intact cerebral function (e.g., opening the eyes and looking at the examiner or reaching to push away a painful stimulus) must be distinguished from reflex responses of a spinal origin (e.g., triple flexion response—flexion at the ankle, knee, and hip in response to a painful stimulus to the foot).

Orientation is tested by asking the person to state their name, location, and time (day of the week and date); time is usually the first to be affected in a variety of conditions.

Speech is assessed by observing articulation, rate, rhythm, and prosody (i.e., the changes in pitch and accentuation of syllables and words).

Language is assessed by observing the content of the patient's verbal and written output, response to spoken commands, and ability to read. A typical testing sequence is to ask the patient to name successively more detailed components of clothing, a watch, or a pen; repeat the phrase "No ifs, ands, or buts"; follow a three-step, verbal command; write a sentence; and read and respond to a written command.

Memory should be analyzed according to three main time scales: (1) immediate memory is assessed by saying a list of three items and having the patient repeat the list immediately; (2) short-term memory is tested by asking the patient to recall the same three items 5 and 15 min later; and (3) long-term memory is evaluated by determining how well the patient is able to provide a coherent chronologic history of their illness or personal events.

Fund of information is assessed by asking questions about major historic or current events, with special attention to educational level and life experiences.

Abnormalities of *insight and judgment* are usually detected during the interview; a more detailed assessment can be elicited by asking the patient to describe how they would respond to situations having a variety of potential outcomes (e.g., "What would you do if you found a wallet on the sidewalk?").

Abstract thought can be tested by asking the patient to describe similarities between various objects or concepts (e.g., apple and orange, desk and chair, poetry and sculpture) or to list items having the same attributes (e.g., a list of four-legged animals).

Calculation ability is assessed by having the patient carry out a computation that is appropriate to the patient's age and education (e.g., serial subtraction of 7 from 100 or 3 from 20; or word problems involving simple arithmetic).

CRANIAL NERVE EXAMINATION

- *The bare minimum: Check the fundi, visual fields, pupil size and reactivity, extraocular movements, and facial movements.*

The CNs are best examined in numerical order, except for grouping together CN III, IV, and VI because of their similar function.

CN I (Olfactory) Testing is often omitted unless there is suspicion for inferior frontal lobe disease (e.g., meningioma). With eyes closed, ask the patient to sniff a mild stimulus such as toothpaste or coffee and identify the odorant.

CN II (Optic) Check visual acuity (with eyeglasses or contact lens correction) using a Snellen chart or similar tool. Test the visual fields by confrontation, i.e., by comparing the patient's visual fields to your own. As a screening test, it is usually sufficient to examine the visual fields of both eyes simultaneously; individual eye fields should be tested if there is any reason to suspect a problem of vision by the history or other elements of the examination, or if the screening test reveals an abnormality. Face the patient at a distance of ~0.6–1.0 m (2–3 ft) and place your hands at the periphery of your visual fields in the plane that is equidistant between you and the patient. Instruct the patient to look directly at the center of your face and to indicate when and where they see one of your fingers moving. Beginning with the two inferior quadrants and then the two superior quadrants, move your index finger of the right hand, left hand, or both hands simultaneously and observe whether the patient detects the movements. A single small-amplitude movement of the finger is sufficient for a normal response. Focal perimetry and tangent screen examinations should be used to map out visual field defects fully or to search for subtle abnormalities. Optic fundi should be examined with an ophthalmoscope, and the color, size, and degree of swelling or elevation of the optic disc noted, as well as the color and texture of the retina. The retinal vessels should be checked for size, regularity, arteriovenous nicking at crossing points, hemorrhage, and exudates.

CN III, IV, VI (Oculomotor, Trochlear, Abducens) Describe the size and shape of the pupils and reaction to light and accommodation (i.e., as the eyes converge while following your finger as it moves toward the bridge of the nose). To check extraocular movements, ask the patient to keep their head still while tracking the movement of the tip of your finger. Move the target slowly in the horizontal and vertical planes; observe any paresis, nystagmus, or abnormalities of smooth pursuit (saccades, oculomotor ataxia, etc.). If necessary, the relative position of the two eyes, both in primary and multidirectional gaze, can be assessed by comparing the reflections of a bright light off both pupils. However, in practice it is typically more useful to determine whether the patient describes diplopia in any direction of gaze; true diplopia should almost always resolve with one eye closed. Horizontal nystagmus is best assessed at 45° and not at extreme lateral gaze (which is uncomfortable for the patient); the target must often be held at the lateral position for at least a few seconds to detect an abnormality.

CN V (Trigeminal) Examine sensation within the three territories of the branches of the trigeminal nerve (ophthalmic, maxillary, and mandibular) on each side of the face. As with other parts of the sensory examination, testing of two sensory modalities derived from different anatomic pathways (e.g., light touch and temperature) is sufficient for a screening examination. Testing of other modalities, the corneal reflex, and the motor component of CN V (jaw clench—masseter muscle) is indicated when suggested by the history.

CN VII (Facial) Look for facial asymmetry at rest and with spontaneous movements. Test eyebrow elevation, forehead wrinkling, eye closure, smiling, and cheek puff. Look in particular for differences in the lower versus upper facial muscles; weakness of the lower two-thirds of the face with preservation of the upper third suggests an upper motor neuron lesion, whereas weakness of an entire side suggests a lower motor neuron lesion.

CN VIII (Vestibulocochlear) Check the patient's ability to hear a finger rub or whispered voice with each ear. Further testing for air versus mastoid bone conduction (Rinne) and lateralization of a 512-Hz tuning fork placed at the center of the forehead (Weber) should be done if an abnormality is detected by history or examination. Any suspected problem should be followed up with formal audiometry. **For further discussion of assessing vestibular nerve function in the setting of dizziness, coma, or hearing loss, see Chaps. 24, 30, and 36, respectively**.

CN IX, X (Glossopharyngeal, Vagus) Observe the position and symmetry of the palate and uvula at rest and with phonation ("aah"). The pharyngeal ("gag") reflex is evaluated by stimulating the posterior pharyngeal wall on each side with a sterile, blunt object (e.g., tongue blade), but the reflex may be absent in normal individuals.

CN XI (Spinal Accessory) Check shoulder shrug (trapezius muscle) and head rotation to each side (sternocleidomastoid) against resistance.

CN XII (Hypoglossal) Inspect the tongue for atrophy or fasciculations, position with protrusion, and strength when extended against the inner surface of the cheeks on each side.

MOTOR EXAMINATION

- *The bare minimum: Look for muscle atrophy and check extremity tone. Assess upper extremity strength by checking for pronator drift and strength of wrist or finger extensors. Assess lower extremity strength by checking strength of the toe extensors.*

The motor examination includes observations of muscle appearance, tone, and strength. Although gait is in part a test of motor function, it is usually evaluated separately at the end of the examination.

Appearance Inspect and palpate muscle groups under good light and with the patient in a comfortable and symmetric position. Check for muscle fasciculations, tenderness, and atrophy or hypertrophy. Involuntary movements may be present at rest (e.g., tics, myoclonus, choreoathetosis, pill-rolling tremor of Parkinson's disease), during maintained posture (essential tremor), or with voluntary movements (intention tremor of cerebellar disease or familial tremor).

Tone Muscle tone is tested by measuring the resistance to passive movement of a relaxed limb. Patients often have difficulty relaxing during this procedure, so it is useful to distract the patient to minimize active movements. In the upper limbs, tone is assessed by rapid pronation and supination of the forearm and flexion and extension at the wrist. In the lower limbs, while the patient is supine, the examiner's hands are placed behind the knees and rapidly raised; with normal tone, the ankles drag along the table surface for a variable distance before rising, whereas increased tone results in an immediate lift of the heel off the surface. Decreased tone is most commonly due to lower motor neuron or peripheral nerve disorders. Increased tone may be evident as spasticity (resistance determined by the angle and velocity of motion; corticospinal tract disease), rigidity (similar resistance in all angles of motion; extrapyramidal disease), or paratonia (fluctuating changes in resistance; frontal lobe pathways; or normal difficulty in relaxing). Cogwheel rigidity, in which passive motion elicits jerky interruptions in resistance, is seen in parkinsonism.

Strength Testing for pronator drift is an extremely useful method for screening upper limb weakness. The patient is asked to hold both arms fully extended and parallel to the ground with eyes closed. This position should be maintained for ~10 s; any flexion at the elbow or fingers or pronation of the forearm, especially if asymmetric, is a sign of potential weakness. Patients with shoulder pain or a limited range of motion may have an apparent pronator drift that is not due to true weakness. Muscle strength is further assessed by having the patient exert maximal effort for the particular muscle or muscle group being tested. It is important to isolate the muscles as much as possible, i.e., hold the limb so that only the muscles of interest are active. It is also helpful to palpate accessible muscles as they contract. Grading muscle strength and evaluating the patient's effort are an art that takes time and practice. Muscle strength is traditionally graded using the following scale:

0 = no movement
1 = flicker or trace of contraction but no associated movement at a joint
2 = movement with gravity eliminated
3 = movement against gravity but not against resistance
4– = movement against a mild degree of resistance
4 = movement against moderate resistance
4+ = movement against strong resistance
5 = full power

However, in many cases, it is more practical to use the following terms:

Paralysis = no movement
Severe weakness = movement with gravity eliminated
Moderate weakness = movement against gravity but not against mild resistance
Mild weakness = movement against moderate resistance
Full strength

Noting the pattern of weakness is as important as assessing the magnitude of weakness. Unilateral or bilateral weakness of the upper limb extensors and lower limb flexors ("pyramidal weakness") suggests a lesion of the pyramidal tract, bilateral proximal weakness suggests myopathy, and bilateral distal weakness suggests peripheral neuropathy.

REFLEX EXAMINATION

- *The bare minimum: Check the biceps, patellar, and Achilles reflexes.*

Muscle Stretch Reflexes Those that are typically assessed include the biceps (C5, C6), brachioradialis (C5, C6), triceps (C6, C7), and sometimes finger flexor (C8, T1) reflexes in the upper limbs and the patellar or quadriceps (L3, L4) and Achilles (S1, S2) reflexes in the lower limbs. The patient should be relaxed and the muscle positioned midway between full contraction and extension. Reflexes may be enhanced by asking the patient to voluntarily contract other, distant muscle groups (Jendrassik maneuver). For example, upper limb reflexes may be reinforced by voluntary teeth-clenching, and the Achilles reflex by hooking the flexed fingers of the two hands together and attempting to pull them apart. For each reflex tested, the two sides should be tested sequentially, and it is important to determine the smallest stimulus required to elicit a reflex rather than the maximum response. Reflexes are graded according to the following scale:

0 = absent
1 = present but diminished
2 = normoactive
3 = increased
4 = clonus

Cutaneous Reflexes The plantar reflex is elicited by stroking, with a noxious stimulus such as a tongue blade, the lateral surface of the sole of the foot beginning near the heel and moving across the ball of the foot to the great toe. The normal reflex consists of plantar flexion of the toes. With upper motor neuron lesions above the S1 level of the spinal cord, a paradoxical extension of the toe is observed, associated with fanning and extension of the other toes (termed an *extensor plantar response*, or *Babinski sign*). However, despite its popularity, the reliability and validity of the Babinski sign for identifying upper motor neuron weakness are limited—it is far more useful to rely on tests of tone, strength, stretch reflexes, and coordination. Superficial abdominal reflexes are elicited by gently stroking the abdominal surface near the umbilicus in a diagonal fashion with a sharp object (e.g., the wooden end of a cotton-tipped swab) and observing the movement of the umbilicus. Normally, the umbilicus will pull toward the stimulated quadrant. With upper motor neuron lesions, these reflexes are absent. They are most helpful when there is preservation of the upper (spinal cord level T9) but not lower (T12) abdominal reflexes, indicating a spinal lesion between T9 and T12, or when the response is asymmetric. Other useful cutaneous reflexes include the cremasteric (ipsilateral elevation of the testicle following stroking of the medial thigh; mediated by L1 and L2) and anal (contraction of the anal sphincter when the perianal skin is scratched; mediated by S2, S3, S4) reflexes. It is particularly important to test for these reflexes in any patient with suspected injury to the spinal cord or lumbosacral roots.

Primitive Reflexes With disease of the frontal lobe pathways, several primitive reflexes not normally present in the adult may appear. The suck response is elicited by lightly touching with a tongue blade the center of the lips, and the root response the corner of the lips; the patient will move the lips to suck or root in the direction of the stimulus. The grasp reflex is elicited by touching the palm between the thumb and index finger with the examiner's fingers; a positive response is a forced grasp of the examiner's hand. In many instances, stroking the back of the hand will lead to its release. The palmomental response is contraction of the mentalis muscle (chin) ipsilateral to a scratch stimulus diagonally applied to the palm.

SENSORY EXAMINATION

- *The bare minimum: Ask whether the patient can feel light touch and the temperature of a cool object in each distal extremity. Check double simultaneous stimulation using light touch on the hands. Perform the Romberg maneuver.*

Evaluating sensation is usually the most unreliable part of the examination because it is subjective and is difficult to quantify. In the compliant and discerning patient, the sensory examination can be extremely helpful for the precise localization of a lesion. With patients who are uncooperative or lack an understanding of the tests, it may be useless. The examination should be focused on the suspected lesion. For example, in spinal cord, spinal root, or peripheral nerve abnormalities, all major sensory modalities should be tested while looking for a pattern consistent with a spinal level and dermatomal or nerve distribution. In patients with lesions at or above the brainstem, screening the primary sensory modalities in the distal extremities along with tests of "cortical" sensation is usually sufficient.

The five primary sensory modalities—light touch, pain, temperature, vibration, and joint position—are tested in each limb. Light touch

is assessed by stimulating the skin with single, very gentle touches of the examiner's finger or a wisp of cotton. Pain is tested using a new pin, and temperature is assessed using a metal object (e.g., tuning fork) that has been immersed in cold and warm water. Vibration is tested using a 128-Hz tuning fork applied to the distal phalanx of the great toe or index finger just below the nail bed. By placing a finger on the opposite side of the joint being tested, the examiner compares the patient's threshold of vibration perception with their own. For joint position testing, the examiner grasps the digit or limb laterally and distal to the joint being assessed; small 1- to 2-mm excursions can usually be sensed. The Romberg maneuver is primarily a test of proprioception. The patient is asked to stand with the feet as close together as necessary to maintain balance while the eyes are open, and the eyes are then closed. A loss of balance with the eyes closed is an abnormal response.

"Cortical" sensation is mediated by the parietal lobes and represents an integration of the primary sensory modalities; testing cortical sensation is only meaningful when primary sensation is intact. Double simultaneous stimulation is especially useful as a screening test for cortical function; with the patient's eyes closed, the examiner lightly touches one or both hands and asks the patient to identify the stimuli. With a parietal lobe lesion, the patient may be unable to identify the stimulus on the contralateral side when both hands are touched. Other modalities relying on the parietal cortex include the discrimination of two closely placed stimuli as separate (two-point discrimination), identification of an object by touch and manipulation alone (stereognosis), and the identification of numbers or letters written on the skin surface (graphesthesia).

COORDINATION EXAMINATION

- *The bare minimum: Observe the patient at rest and during spontaneous movements. Test rapid alternating movements of the hands and feet and finger to nose.*

Coordination refers to the orchestration and fluidity of movements. Even simple acts require cooperation of agonist and antagonist muscles, maintenance of posture, and complex servomechanisms to control the rate and range of movements. Part of this integration relies on normal function of the cerebellar and basal ganglia systems. However, coordination also requires intact muscle strength and kinesthetic and proprioceptive information. Thus, if the examination has disclosed abnormalities of the motor or sensory systems, the patient's coordination should be assessed with these limitations in mind.

Rapid alternating movements in the upper limbs are tested separately on each side by having the patient make a fist, partially extend the index finger, and then tap the index finger on the distal thumb as quickly as possible. In the lower limb, the patient rapidly taps the foot against the floor or the examiner's hand. If these rapid alternating movements are imprecise or vary in amplitude or rhythm, a cerebellar lesion is suspected; if, however, they are slow compared with the other side, a lesion of the pyramidal tract is most likely. Finger-to-nose testing is primarily a test of cerebellar function; the patient is asked to touch their index finger repetitively to the nose and then to the examiner's outstretched finger, which moves with each repetition. A similar test in the lower extremity is to have the patient raise the leg and touch the examiner's finger with the great toe. Another coordination test in the lower limbs is the heel-knee-shin maneuver; in the supine position, the patient is asked to slide the heel of each foot from the knee down the shin of the other leg. For all these movements, the accuracy, speed, and rhythm are noted.

GAIT EXAMINATION

- *The bare minimum: Observe the patient while walking normally, on the heels and toes, and along a straight line.*

Watching the patient walk is the most important part of the neurologic examination. Normal gait requires that multiple systems—including strength, sensation, and coordination—function in a highly integrated fashion. Unexpected abnormalities may be detected that prompt the examiner to return in more detail to other aspects of the examination. The patient should be observed while walking and turning normally, walking on the heels, walking on the toes, and walking heel-to-toe along a straight line. The examination may reveal decreased arm swing on one side (corticospinal tract disease), a stooped posture and short-stepped gait (parkinsonism), a broad-based unstable gait (ataxia), scissoring (spasticity), or a high-stepped, slapping gait (posterior column or peripheral nerve disease), or the patient may appear to be stuck in place (apraxia with frontal lobe disease).

NEUROLOGIC DIAGNOSIS

The clinical data obtained from the history and examination are interpreted to arrive at an anatomic localization that best explains the clinical findings **(Table 433-1)**, to narrow the list of diagnostic possibilities, and to select the laboratory tests most likely to be informative. The laboratory assessment may include (1) serum electrolytes; complete blood count; and renal, hepatic, endocrine, and immune studies; (2) cerebrospinal fluid examination; (3) focused neuroimaging studies **(Chap. 434)**; or (4) electrophysiologic studies. The anatomic localization, mode of onset and course of illness, other medical data, and laboratory findings are then integrated to establish an etiologic diagnosis.

The neurologic examination may be normal even in patients with a serious neurologic disease, such as seizures, chronic meningitis, or a TIA. A comatose patient may arrive with no available history, and in such cases, the approach is as described in **Chap. 30**. In other patients, an inadequate history may be overcome by a succession of examinations from which the course of the illness can be inferred. In perplexing cases, it is useful to remember that uncommon presentations of common diseases are more likely than rare etiologies. Thus, even in

TABLE 433-1 Findings Helpful for Localizations within the Nervous System

	SIGNS
Cerebrum	Abnormal mental status or cognitive impairment Seizures Unilateral weakness[a] and sensory abnormalities including head and limbs Visual field abnormalities Movement abnormalities (e.g., diffuse incoordination, tremor, chorea)
Brainstem	Isolated cranial nerve abnormalities (single or multiple) "Crossed" weakness[a] and sensory abnormalities of head and limbs, e.g., weakness of right face and left arm and leg
Spinal cord	Back pain or tenderness Weakness[a] and sensory abnormalities sparing the head Mixed upper and lower motor neuron findings Sensory level Sphincter dysfunction
Spinal roots	Radiating limb pain Weakness[b] or sensory abnormalities following root distribution **(see Figs. 27-2 and 27-3)** Loss of reflexes
Peripheral nerve	Mid or distal limb pain Weakness[b] or sensory abnormalities following nerve distribution **(see Figs. 27-2 and 27-3)** "Stocking or glove" distribution of sensory loss Loss of reflexes
Neuromuscular junction	Bilateral weakness including face (ptosis, diplopia, dysphagia) and proximal limbs Increasing weakness with exertion Sparing of sensation
Muscle	Bilateral proximal or distal weakness Sparing of sensation

[a]Weakness along with other abnormalities having an "upper motor neuron" pattern, i.e., spasticity, weakness of extensors > flexors in the upper extremity and flexors > extensors in the lower extremity, and hyperreflexia. [b]Weakness along with other abnormalities having a "lower motor neuron" pattern, i.e., flaccidity and hyporeflexia.