SPECIAL ISSUES RELATED TO EPILEPSY IN THE ELDERLY

Epilepsy has a bimodal distribution according to age, with the highest incidence in the very young and in the elderly. The increased incidence in the elderly may be attributed to age- and aging-related epileptogenic factors. The most common cause is stroke, followed by neoplasm, and dementia, resulting in a preponderance of extratemporal epilepsy. Antiseizure medication selection requires careful consideration of medical and psychiatric comorbidities, side effect profiles, effects on mood and cognition, and drug-drug interactions.

FURTHER READING

Bui E: Women's issues in epilepsy. Continuum (Minneap Minn) 28:399, 2022.

Cornes SB, Shih T: Evaluation of the patient with spells. Continuum (Minneap Minn) 17:984, 2011.

Crepeau AZ, Sirven JI: Management of adult onset seizures. Mayo Clin Proc 92:306, 2017.

Ellis CA et al: Epilepsy genetics: Clinical impacts and biological insights. Lancet Neurol 19:93, 2020.

Fisher RS et al: Operational classification of seizure types by the International League Against Epilepsy: Position paper of the ILAE Commission for Classification and Terminology. Epilepsia 58:522, 2017.

Gavvala JR, Schuele SU: New-onset seizure in adults and adolescents: A review. JAMA 316:2657, 2016.

Jetté N et al: Surgical treatment for epilepsy: The potential gap between evidence and practice. Lancet Neurol 15:982, 2016.

Kanner AM: Management of psychiatric and neurological comorbidities in epilepsy. Nat Rev Neurol 12:106, 2016.

Krumholz A et al: Evidence-based guideline: Management of an unprovoked first seizure in adults: Report of the Guideline Development Subcommittee of the American Academy of Neurology and the American Epilepsy Society. Neurology 84:1705, 2015.

Kwan P, Brodie MJ: Early identification of refractory epilepsy. N Engl J Med 342:314, 2000.

Markert MS, Fisher RS: Neuromodulation: Science and practice in epilepsy: Vagus nerve simulation, thalamic deep brain stimulation, and responsive neurostimulation. Expert Rev Neurother 19:17, 2019.

Rao VR et al: Cues for seizure timing. Epilepsia 62:S15, 2021.

Sen A et al: Epilepsy in older people. Lancet 395:735, 2020.

437 Introduction to Cerebrovascular Diseases

Wade S. Smith, J. Claude Hemphill, III

Cerebrovascular diseases include some of the most common and devastating disorders: ischemic stroke and hemorrhagic stroke. Stroke is the second leading cause of death worldwide, with 7.1 million dying from stroke in 2020. Nearly 7 million Americans age 20 or older report having had a stroke, and the prevalence is estimated to rise by 3.4 million adults in the next decade, representing 4% of the entire adult population. Although mortality is increased from 6.2 million in 2010, the age standardized death rate has fallen by 15% in this decade, likely due to better prevention and treatment. However, overall disease burden will continue to climb as the population ages, and stroke is likely to remain the second most common disabling condition in individuals aged 50 or older worldwide.

A stroke, or cerebrovascular accident, is defined as an abrupt onset of a neurologic deficit that is attributable to a vascular cause. Thus, the definition of stroke is clinical, and laboratory studies including brain imaging are used to support the diagnosis. The clinical manifestations of stroke are highly variable because of the complex anatomy of the brain and its vasculature. *Cerebral ischemia* is caused by a reduction in blood flow that lasts longer than several seconds. Neurologic symptoms are manifest within seconds because neurons lack glycogen, so energy failure is rapid. If the cessation of flow lasts for more than a few minutes, *infarction* or death of brain tissue results. When blood flow is quickly restored, brain tissue can recover fully and the patient's symptoms are only transient: this is called a *transient ischemic attack* (TIA). The definition of TIA requires that all neurologic signs and symptoms resolve within 24 h without evidence of brain infarction on brain imaging. Stroke has occurred if the neurologic signs and symptoms last for >24 h or brain infarction is demonstrated. A generalized reduction in cerebral blood flow due to systemic hypotension (e.g., cardiac arrhythmia, sepsis, or hemorrhagic shock) usually produces syncope **(Chap. 23)**. If low cerebral blood flow persists for a longer duration, then infarction in the border zones between the major cerebral artery distributions may develop. In more severe instances as in cardiac arrest, *global hypoxia-ischemia* causes widespread brain injury; the constellation of cognitive sequelae that ensues is called *hypoxic-ischemic encephalopathy* **(Chap. 318)**. *Focal ischemia* or infarction, conversely, is usually caused by thrombosis of the cerebral vessels themselves or by emboli from a proximal arterial source or the heart **(Chap. 438)**. *Intracranial hemorrhage* is caused by bleeding directly into or around the brain; it produces neurologic symptoms by producing a mass effect on neural structures, from the toxic effects of blood itself, or by increasing intracranial pressure **(Chap. 439)**.

APPROACH TO THE PATIENT

Cerebrovascular Disease

Rapid evaluation is essential for use of acute treatments such as thrombolysis or thrombectomy. However, patients with acute stroke often do not seek medical assistance on their own because they may lose the appreciation that something is wrong (anosognosia) or lack the knowledge that acute treatment is beneficial; it is often a family member or a bystander who calls for help. Therefore, patients and their family members should be counseled to call emergency medical services immediately if they experience or witness the sudden onset of any of the following: loss of sensory and/or motor function on one side of the body (nearly 85% of ischemic stroke patients have hemiparesis); change in vision, gait, or ability to speak or understand; or a sudden, severe headache. The acronym FAST (*f*acial weakness, *a*rm weakness, *s*peech abnormality, and *t*ime) is simple and helpful to teach to the lay public about the common physical symptoms of stroke and to underscore that treatments are highly time sensitive.

Other causes of sudden-onset neurologic symptoms that may mimic stroke include seizure, intracranial tumor, migraine, and metabolic encephalopathy. An adequate history from an observer that no convulsive activity occurred at the onset usually excludes seizure **(Chap. 436)**, although ongoing complex partial seizures without tonic-clonic activity can on occasion mimic stroke. Tumors **(Chap. 95)** may present with acute neurologic symptoms due to hemorrhage, seizure, or hydrocephalus. Surprisingly, migraine **(Chap. 441)** can mimic stroke, even in patients without a significant migraine history. When migraine develops without head pain (*acephalgic migraine*), the diagnosis can be especially difficult. Patients without any prior history of migraine may develop acephalgic migraine even after age 65. A sensory disturbance is often prominent, and the sensory deficit, as well as any motor deficits, tends to migrate slowly across a limb, over minutes rather than seconds as with stroke. The diagnosis of migraine becomes more secure as the cortical disturbance begins to cross vascular boundaries or if classic visual symptoms are present such as scintillating scotomata. At times, it may be impossible to make the diagnosis of migraine until there have been multiple episodes with no residual symptoms or signs and no changes on brain magnetic resonance imaging (MRI). Metabolic encephalopathies typically produce fluctuating mental status changes without focal neurologic findings. However, in the setting of prior stroke or brain injury, a patient with

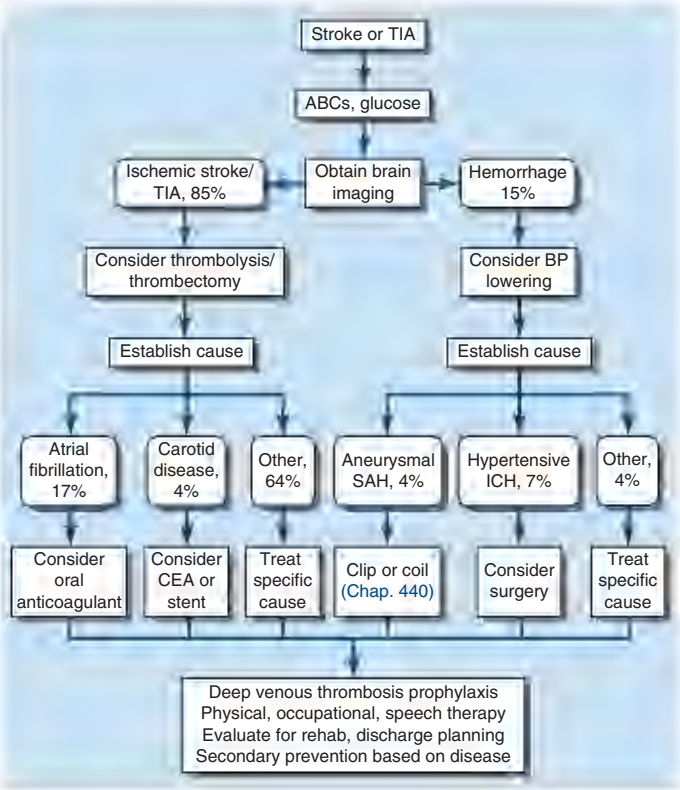

FIGURE 437-1 Medical management of stroke and TIA. *Rounded boxes* are diagnoses; *rectangles* are interventions. Numbers are percentages of stroke overall. ABCs, airway, breathing, circulation; BP, blood pressure; CEA, carotid endarterectomy; ICH, intracerebral hemorrhage; SAH, subarachnoid hemorrhage; TIA, transient ischemic attack.

fever or sepsis may manifest a recurrent hemiparesis, which clears rapidly when the infection is treated. The metabolic process serves to "unmask" a prior deficit and is termed "stroke recrudescence."

Once the diagnosis of stroke is made, a brain imaging study is necessary to determine if the cause of stroke is ischemia or hemorrhage **(Fig. 437-1)**. Computed tomography (CT) imaging of the brain is the standard imaging modality to detect the presence or absence of intracranial hemorrhage (see "Imaging Studies," below). If the stroke is ischemic, administration of recombinant tissue plasminogen activator (rtPA) or endovascular mechanical thrombectomy may be beneficial in restoring cerebral perfusion **(Chap. 438)**. Medical management to reduce the risk of complications becomes the next priority, followed by plans for secondary prevention. For ischemic stroke, several strategies can reduce the risk of subsequent stroke in all patients, while other strategies are effective for patients with specific causes of stroke such as cardiac embolus and carotid atherosclerosis. For hemorrhagic stroke, aneurysmal subarachnoid hemorrhage (SAH) and hypertensive intracerebral hemorrhage are two important causes. **The treatment and prevention of hypertensive intracerebral hemorrhage are discussed in Chap. 439. SAH is discussed in Chap. 440.**

STROKE SYNDROMES

A careful history and neurologic examination can often localize the region of brain dysfunction; if this region corresponds to an arterial distribution, the possible causes responsible for the syndrome can be narrowed. This is of particular importance when the patient presents with a TIA and a normal examination. For example, if a patient develops language loss and a right homonymous hemianopia, a search for causes of left middle cerebral emboli should be performed. A finding of an isolated stenosis of the right internal carotid artery in that patient, for example, suggests an asymptomatic carotid stenosis, and the search for other causes of stroke should continue. The following sections describe the clinical findings of cerebral ischemia associated with cerebral vascular territories depicted in **Figs. 437-2 through 437-11**. Stroke syndromes are divided into (1) large-vessel stroke within the anterior circulation, (2) large-vessel stroke within the posterior circulation, and (3) small-vessel disease of either vascular bed.

Stroke within the Anterior Circulation The internal carotid artery and its branches compose the anterior circulation of the brain. These vessels can be occluded by intrinsic disease of the vessel (e.g., atherosclerosis or dissection) or by embolic occlusion from a proximal source as discussed above. Occlusion of each major intracranial vessel has distinct clinical manifestations.

MIDDLE CEREBRAL ARTERY Occlusion of the proximal middle cerebral artery (MCA) or one of its major branches is most often due to an embolus (artery-to-artery, cardiac, or of unknown source) rather than intracranial atherothrombosis. Atherosclerosis of the proximal MCA may cause distal emboli to the middle cerebral territory or, less commonly, may produce low-flow TIAs. Collateral formation via leptomeningeal vessels often prevents MCA stenosis from becoming symptomatic.

The cortical branches of the MCA supply the lateral surface of the hemisphere except for (1) the frontal pole and a strip along the superomedial border of the frontal and parietal lobes supplied by the anterior cerebral artery (ACA) and (2) the lower temporal and occipital pole convolutions supplied by the posterior cerebral artery (PCA) (Figs. 437-2–437-5).

The proximal MCA (M1 segment) gives rise to penetrating branches (termed *lenticulostriate arteries*) that supply the putamen, outer globus pallidus, posterior limb of the internal capsule, adjacent corona radiata, and most of the caudate nucleus (Fig. 437-2). In the sylvian fissure, the MCA in most patients divides into *superior* and *inferior* divisions (M2 branches). Branches of the inferior division supply the inferior parietal and temporal cortex, and those from the superior division supply the frontal and superior parietal cortex (Fig. 437-3).

If the entire MCA is occluded at its origin (blocking both its penetrating and cortical branches) and the distal collaterals are limited, the clinical findings are contralateral hemiplegia, hemianesthesia, homonymous hemianopia, and a day or two of gaze preference to the ipsilateral side. Dysarthria is common because of facial weakness. When the dominant hemisphere is involved, global aphasia is present also, and when the nondominant hemisphere is affected, anosognosia, constructional apraxia, and neglect are found **(Chap. 32)**.

Complete MCA syndromes occur most often when an embolus occludes the stem of the artery. Cortical collateral blood flow and differing arterial configurations are probably responsible for the development of many partial syndromes. Partial syndromes may also be due to emboli that enter the proximal MCA without complete occlusion, occlude distal MCA branches, or fragment and move distally.

Partial syndromes due to embolic occlusion of a single branch include hand, or arm and hand, weakness alone (brachial syndrome) or facial weakness with nonfluent (Broca) aphasia **(Chap. 32)**, with or without arm weakness (frontal opercular syndrome). A combination of sensory disturbance, motor weakness, and nonfluent aphasia suggests that an embolus has occluded the proximal superior division and infarcted large portions of the frontal and parietal cortices (Fig. 437-3). If a fluent (Wernicke's) aphasia occurs without weakness, the inferior division of the MCA supplying the posterior part (temporal cortex) of the dominant hemisphere is probably involved. Jargon speech and an inability to comprehend written and spoken language are prominent features, often accompanied by a contralateral, homonymous superior quadrantanopia. Hemineglect or spatial agnosia without weakness indicates that the inferior division of the MCA in the nondominant hemisphere is involved.

Occlusion of a lenticulostriate vessel produces small-vessel (lacunar) stroke within the internal capsule (Fig. 437-2). This produces pure motor stroke or sensory-motor stroke contralateral to the lesion. Ischemia within the genu of the internal capsule causes primarily facial weakness followed by arm and then leg weakness as the ischemia moves posterior within the capsule. Alternatively, the contralateral hand may become ataxic, and dysarthria will be prominent (clumsy hand, dysarthria lacunar syndrome). Lacunar infarction affecting the globus pallidus and putamen often has few clinical signs, but parkinsonism and hemiballismus have been reported.

ANTERIOR CEREBRAL ARTERY The ACA is divided into two segments: the precommunal (A1) circle of Willis, or stem, which connects

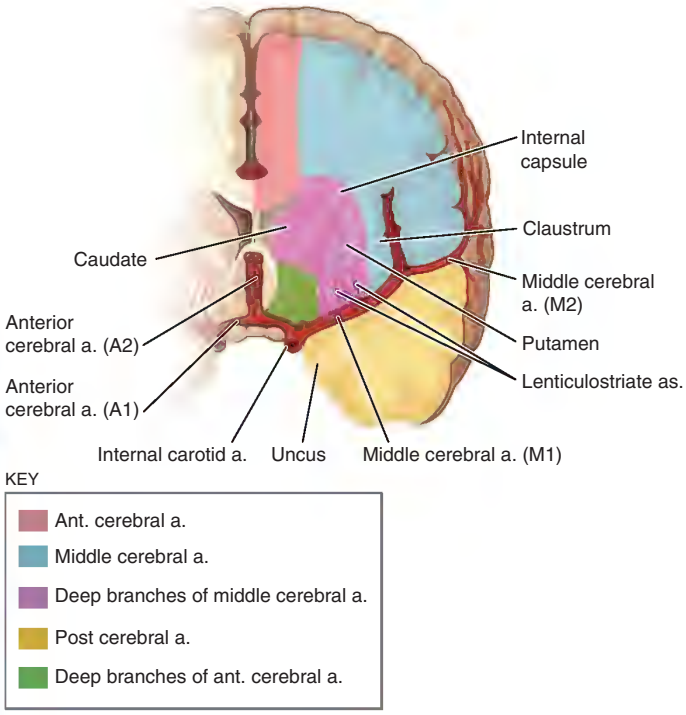

FIGURE 437-2 Diagram of a cerebral hemisphere in coronal section showing the territories of the major cerebral vessels that branch from the internal carotid arteries.

the internal carotid artery to the anterior communicating artery, and the postcommunal (A2) segment distal to the anterior communicating artery (Figs. 437-2 and 437-4). The A1 segment gives rise to several deep penetrating branches that supply the anterior limb of the internal capsule, the anterior perforate substance, amygdala, anterior hypothalamus, and the inferior part of the head of the caudate nucleus.

Occlusion of the proximal ACA is usually well tolerated because of collateral flow through the anterior communicating artery and collaterals through the MCA and PCA. Occlusion of a single A2 segment results in the contralateral symptoms noted in Fig. 437-4. If both A2 segments arise from a single anterior cerebral stem (contralateral A1 segment atresia), the occlusion may affect both hemispheres. Profound abulia (a delay in verbal and motor response) and bilateral pyramidal signs with paraparesis or quadriparesis and urinary incontinence result.

ANTERIOR CHOROIDAL ARTERY This artery arises from the internal carotid artery and supplies the posterior limb of the internal capsule and the white matter posterolateral to it, through which pass some of the geniculocalcarine fibers (Fig. 437-5). The complete syndrome of anterior choroidal artery occlusion consists of contralateral hemiplegia, hemianesthesia (hypesthesia), and homonymous hemianopia. However, because this territory is also supplied by penetrating vessels of the proximal MCA and the posterior communicating and posterior choroidal arteries, minimal deficits may occur, and patients frequently recover substantially. Anterior choroidal strokes are usually the result of in situ thrombosis of the vessel, and the vessel is particularly vulnerable to iatrogenic occlusion during surgical clipping of aneurysms arising from the internal carotid artery.

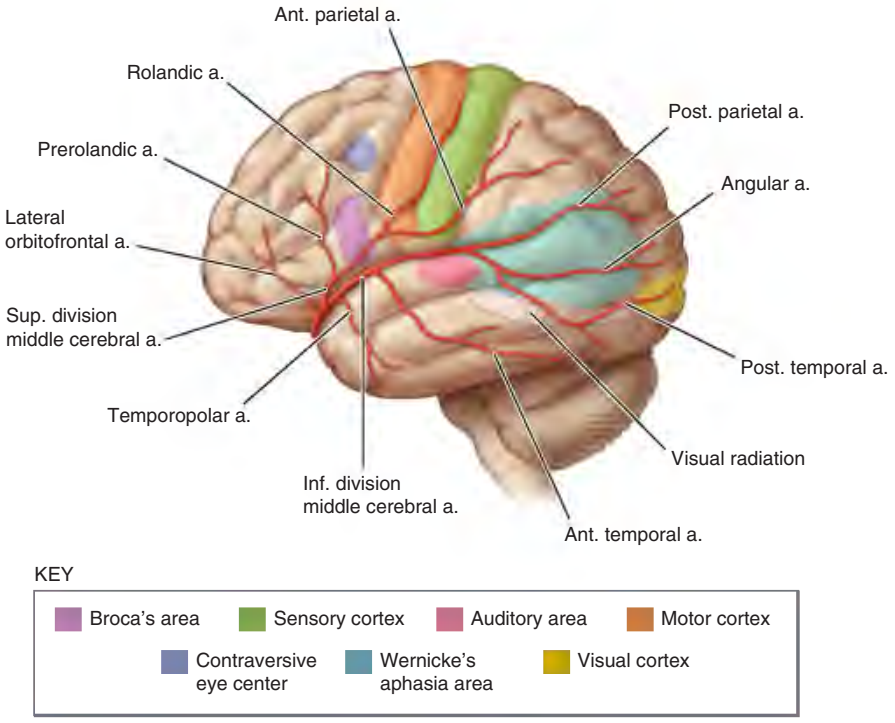

FIGURE 437-3 Diagram of a cerebral hemisphere, lateral aspect, showing the branches and distribution of the middle cerebral artery (MCA) and the principal regions of cerebral localization. Note the bifurcation of the MCA into a superior and inferior division.

Signs and symptoms: *Structures involved*

Paralysis of the contralateral face, arm, and leg; sensory impairment over the same area (pinprick, cotton touch, vibration, position, two-point discrimination, stereognosis, tactile localization, barognosis, cutaneographia): *Somatic motor area for face and arm and the fibers descending from the leg area to enter the corona radiata and corresponding somatic sensory system*

Motor aphasia: Motor speech area of the dominant hemisphere

Central aphasia, word deafness, anomia, jargon speech, sensory agraphia, acalculia, alexia, finger agnosia, right-left confusion (the last four comprise the Gerstmann syndrome): Central, suprasylvian speech area and parietooccipital cortex of the dominant hemisphere

Conduction aphasia: Central speech area (parietal operculum)

Apractagnosia of the nondominant hemisphere, anosognosia, hemiasomatognosia, unilateral neglect, agnosia for the left half of external space, dressing "apraxia," constructional "apraxia," distortion of visual coordinates, inaccurate localization in the half field, impaired ability to judge distance, upside-down reading, visual illusions (e.g., it may appear that another person walks through a table): *Nondominant parietal lobe (area corresponding to speech area in dominant hemisphere); loss of topographic memory is usually due to a nondominant lesion, occasionally to a dominant one*

Homonymous hemianopsia (or less frequently a superior quadrantanopsia due to isolated anterior temporal lobe infarction or inferior quadrantanopsia due to isolated parietal lobe infarction)

Paralysis of conjugate gaze to the opposite side: *Frontal contraversive eye field or projecting fibers.*

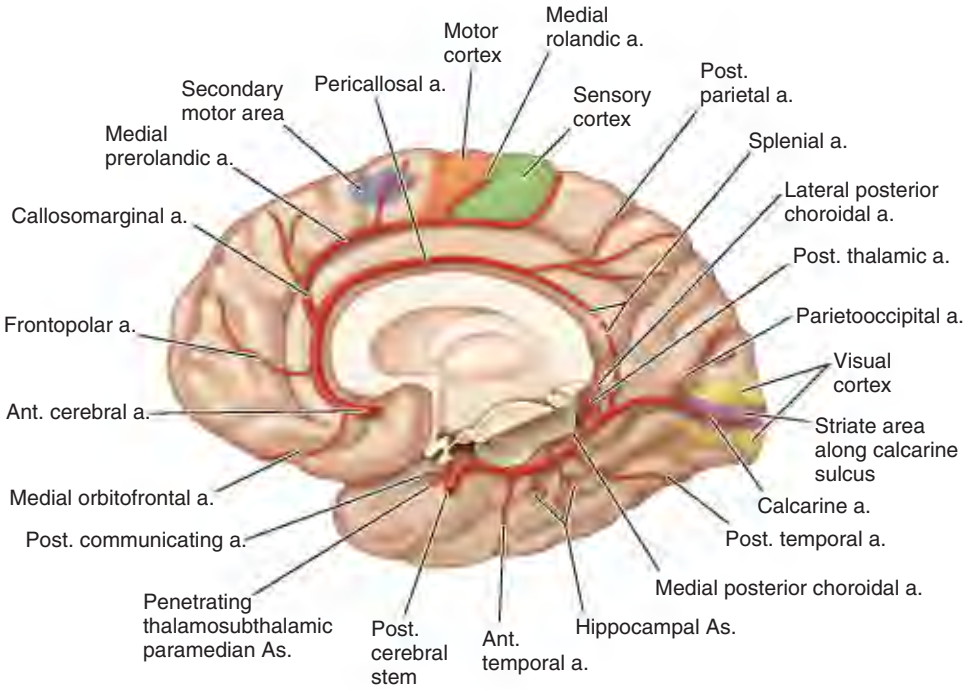

FIGURE 437-4 Diagram of a cerebral hemisphere, medial aspect, showing the branches and distribution of the anterior cerebral artery and the principal regions of cerebral localization.

Signs and symptoms: *Structures involved*
Paralysis of opposite foot and leg: *Motor leg area*
A lesser degree of paresis of opposite arm: *Arm area of cortex or fibers descending to corona radiata.*
Cortical sensory loss over toes, foot, and leg: *Sensory area for foot and leg*
Urinary incontinence: *Sensorimotor area in paracentral lobule*
Contralateral grasp reflex, sucking reflex, gegenhalten (paratonic rigidity): *Medial surface of the posterior frontal lobe; likely supplemental motor area*
Abulia (akinetic mutism), slowness, delay, intermittent interruption, lack of spontaneity, whispering, reflex distraction to sights and sounds: *Uncertain localization—probably cingulate gyrus and medial inferior portion of frontal, parietal, and temporal lobes*
Impairment of gait and stance (gait apraxia): *Frontal cortex near leg motor area*
Dyspraxia of left limbs, tactile aphasia in left limbs: *Corpus callosum*

INTERNAL CAROTID ARTERY The clinical picture of internal carotid occlusion varies depending on whether the cause of ischemia is propagated thrombus, embolism, or low flow. The cortex supplied by the MCA territory is affected most often. With a competent circle of Willis, occlusion may go unnoticed. If the thrombus propagates up the internal carotid artery into the MCA or embolizes it, symptoms are identical to proximal MCA occlusion (see above). Sometimes there is massive infarction of the entire deep white matter and cortical surface. When the origins of both the ACA and MCA are occluded at the top of the carotid artery, abulia or stupor occurs with hemiplegia, hemianesthesia, and aphasia or anosognosia. When the PCA arises from the internal carotid artery (a configuration called a *fetal PCA*), it may also become occluded and give rise to symptoms referable to its peripheral territory (Figs. 437-4 and 437-5).

In addition to supplying the ipsilateral brain, the internal carotid artery perfuses the optic nerve and retina via the ophthalmic artery. In ~25% of symptomatic internal carotid disease, recurrent transient monocular blindness (amaurosis fugax) warns of the lesion. Patients typically describe a horizontal shade that sweeps down or up across the field of vision. They may also complain that their vision was blurred in that eye or that the upper or lower half of vision disappeared. In most cases, these symptoms last only a few minutes. Rarely, ischemia or infarction of the ophthalmic artery or central retinal arteries occurs at the time of cerebral TIA or infarction.

A high-pitched prolonged carotid bruit fading into diastole is often associated with tightly stenotic lesions. As the stenosis grows tighter and flow distal to the stenosis becomes reduced, the bruit becomes fainter and may disappear when occlusion is imminent.

COMMON CAROTID ARTERY All symptoms and signs of internal carotid occlusion may also be present with occlusion of the common carotid artery. Jaw claudication may result from low flow in the external carotid branches. Bilateral common carotid artery occlusions at their origin may occur in Takayasu's arteritis **(Chap. 375)**.

Stroke within the Posterior Circulation The posterior circulation is composed of the paired vertebral arteries, the basilar artery, and the paired PCAs. The vertebral arteries join to form the basilar artery at the pontomedullary junction. The basilar artery divides into two PCAs in the interpeduncular fossa (Figs. 437-4–437-6). These major arteries give rise to long and short circumferential branches and to smaller deep penetrating branches that supply the cerebellum, medulla, pons, midbrain, subthalamus, thalamus, hippocampus, and medial temporal and occipital lobes. Occlusion of each vessel produces its own distinctive syndrome.

POSTERIOR CEREBRAL ARTERY In 75% of cases, both PCAs arise from the bifurcation of the basilar artery; in 20%, one has its origin from the ipsilateral internal carotid artery via the posterior communicating artery; in 5%, both originate from the respective ipsilateral internal carotid arteries (Figs. 437-4–437-6). The precommunal, or P1, segment of the true PCA is atretic in such cases.

PCA syndromes usually result from atheroma formation or emboli that lodge at the top of the basilar artery; posterior circulation disease may also be caused by dissection of either vertebral artery or fibromuscular dysplasia.

Two clinical syndromes are commonly observed with occlusion of the PCA: (1) *P1 syndrome*: midbrain, subthalamic, and thalamic signs, which are due to disease of the proximal P1 segment of the PCA or its penetrating branches (thalamogeniculate, Percheron, and posterior choroidal arteries); and (2) *P2 syndrome*: cortical temporal and occipital lobe signs, due to occlusion of the P2 segment distal to the junction of the PCA with the posterior communicating artery.

P1 SYNDROMES Infarction usually occurs in the ipsilateral subthalamus and medial thalamus and in the ipsilateral cerebral peduncle and midbrain (Figs. 437-5 and 437-11). A third nerve palsy with contralateral ataxia (Claude's syndrome) or with contralateral hemiplegia (Weber's syndrome) may result. The ataxia indicates involvement of

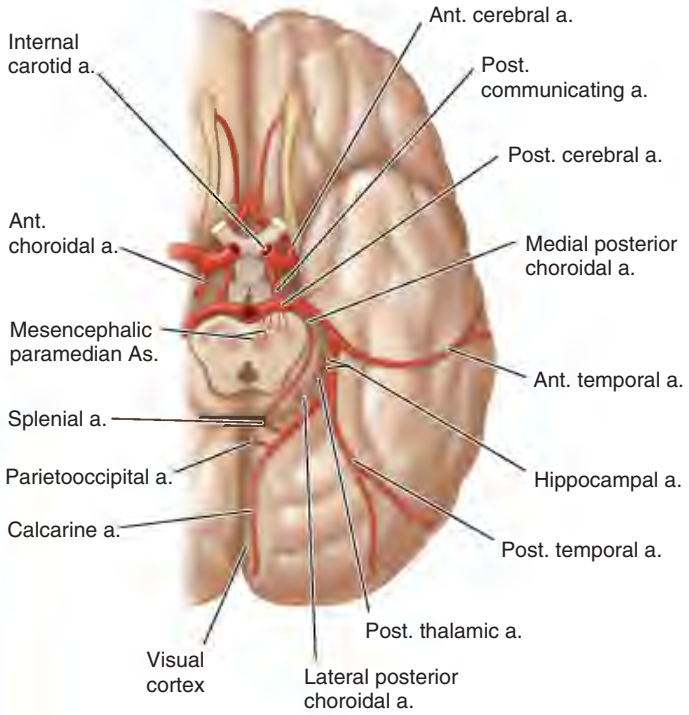

FIGURE 437-5 Inferior aspect of the brain with the branches and distribution of the posterior cerebral artery and the principal anatomic structures shown.

Signs and symptoms: *Structures involved*

Peripheral territory (see also Fig. 437-9). Homonymous hemianopia (often upper quadrantic): *Calcarine cortex or optic radiation nearby.* Bilateral homonymous hemianopia, cortical blindness, awareness or denial of blindness; tactile naming, achromatopia (color blindness), failure to see to-and-fro movements, inability to perceive objects not centrally located, apraxia of ocular movements, inability to count or enumerate objects, tendency to run into things that the patient sees and tries to avoid: *Bilateral occipital lobe with possibly the parietal lobe involved.* Verbal dyslexia without agraphia, color anomia: *Dominant calcarine lesion and posterior part of corpus callosum.* Memory defect: *Hippocampal lesion bilaterally or on the dominant side only.* Topographic disorientation and prosopagnosia: *Usually with lesions of nondominant, calcarine, and lingual gyrus.* Simultanagnosia, hemivisual neglect: *Dominant visual cortex, contralateral hemisphere.* Unformed visual hallucinations, peduncular hallucinosis, metamorphopsia, teleopsia, illusory visual spread, palinopsia, distortion of outlines, central photophobia: *Calcarine cortex.* Complex hallucinations: *Usually nondominant hemisphere.*

Central territory. Thalamic syndrome: sensory loss (all modalities), spontaneous pain and dysesthesias, choreoathetosis, intention tremor, spasms of hand, mild hemiparesis: *Posteroventral nucleus of thalamus; involvement of the adjacent subthalamus body or its afferent tracts.* Thalamoperforate syndrome: crossed cerebellar ataxia with ipsilateral third nerve palsy (Claude's syndrome): *Dentatothalamic tract and issuing third nerve.* Weber's syndrome: third nerve palsy and contralateral hemiplegia: *Third nerve and cerebral peduncle.* Contralateral hemiplegia: *Cerebral peduncle.* Paralysis or paresis of vertical eye movement, skew deviation, sluggish pupillary responses to light, slight miosis and ptosis (retraction nystagmus and "tucking" of the eyelids may be associated): *Supranuclear fibers to third nerve, interstitial nucleus of Cajal, nucleus of Darkschewitsch, and posterior commissure.* Contralateral rhythmic, ataxic action tremor; rhythmic postural or "holding" tremor (rubral tremor): *Dentatothalamic tract.*

the red nucleus or dentatorubrothalamic tract; the hemiplegia is localized to the cerebral peduncle (Fig. 437-11). If the subthalamic nucleus is involved, contralateral hemiballismus may occur. Occlusion of the artery of Percheron produces paresis of upward gaze and drowsiness and often abulia. Extensive infarction in the midbrain and subthalamus occurring with bilateral proximal PCA occlusion presents as coma, unreactive pupils, bilateral pyramidal signs, and decerebrate rigidity.

Occlusion of the penetrating branches of thalamic and thalamogeniculate arteries produces less extensive thalamic and thalamocapsular lacunar syndromes. The *thalamic Déjérine-Roussy syndrome* consists of contralateral hemisensory loss followed later by an agonizing, searing, or burning pain in the affected areas. It is persistent and responds poorly to analgesics. Anticonvulsants (carbamazepine or gabapentin) or tricyclic antidepressants may be beneficial.

P2 SYNDROMES (Figs. 437-4 and 437-5) Occlusion of the distal PCA causes infarction of the medial temporal and occipital lobes.

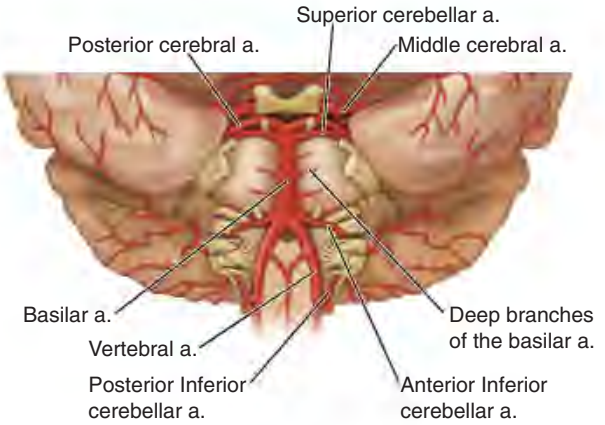

FIGURE 437-6 Diagram of the posterior circulation, showing the intracranial vertebral arteries forming the basilar artery that gives off the anterior inferior cerebellar, superior cerebellar, and posterior cerebral arteries. The posterior inferior cerebellar artery arises from each of the vertebral segments. The majority of brainstem blood flow arises from numerous deep branches of the basilar artery that penetrate directly into the brainstem.

Contralateral homonymous hemianopia without macula sparing is the usual manifestation. (MCA strokes often produce hemianopia but typically spare the macula as calcarine cortex is perfused by the P2 segment.) Occasionally, only the upper quadrant of visual field is involved or the macula vision is spared. If the visual association areas are spared and only the calcarine cortex is involved, the patient may be aware of visual defects. Medial temporal lobe and hippocampal involvement may cause an acute disturbance in memory, particularly if it occurs in the dominant hemisphere. The defect usually clears because memory has bilateral representation. If the dominant hemisphere is affected and the infarct extends to involve the splenium of the corpus callosum, the patient may demonstrate alexia without agraphia. Visual agnosia for faces, objects, mathematical symbols, and colors and anomia with paraphasic errors (amnestic aphasia) may also occur, even without callosal involvement. Occlusion of the PCA can produce *peduncular hallucinosis* (visual hallucinations of brightly colored scenes and objects).

Bilateral infarction in the distal PCAs produces cortical blindness (blindness with preserved pupillary light reaction). The patient is often unaware of the blindness or may even deny it (*Anton's syndrome*). Tiny islands of vision may persist, and the patient may report that vision fluctuates as images are captured in the preserved portions. Rarely, only peripheral vision is lost and central vision is spared, resulting in "gun-barrel" vision. Bilateral visual association area lesions may result in *Balint's syndrome*, a disorder of the orderly visual scanning of the environment **(Chap. 32)**, usually resulting from infarctions secondary to low flow in the "watershed" between the distal PCA and MCA territories, as occurs after cardiac arrest. Patients may experience persistence of a visual image for several minutes despite gazing at another scene (*palinopsia*) or an inability to synthesize the whole of an image (*asimultanagnosia*). Embolic occlusion of the top of the basilar artery can produce any or all the central or peripheral territory symptoms. The hallmark is the sudden onset of bilateral signs, including ptosis, pupillary asymmetry or lack of reaction to light, and somnolence. Patients will often have posturing and myoclonic jerking that simulates seizure. Interrogation of the noncontrast CT scan for a hyperdense basilar artery sign (indicating thrombus in the basilar artery) or CT angiography (CTA) establishes this diagnosis. Physicians should be suspicious of this rare but potentially treatable stroke syndrome in the setting of presumed new-onset seizure and cranial nerve deficits.

VERTEBRAL AND POSTERIOR INFERIOR CEREBELLAR ARTERIES The vertebral artery, which arises from the innominate artery on the right and the subclavian artery on the left, consists of four segments. The first (V1) extends from its origin to its entrance into the sixth or fifth transverse vertebral foramen. The second segment (V2) traverses the vertebral foramina from C6 to C2. The third (V3) passes through the transverse foramen and circles around the arch of the atlas to pierce the dura at the foramen magnum. The fourth (V4) segment courses

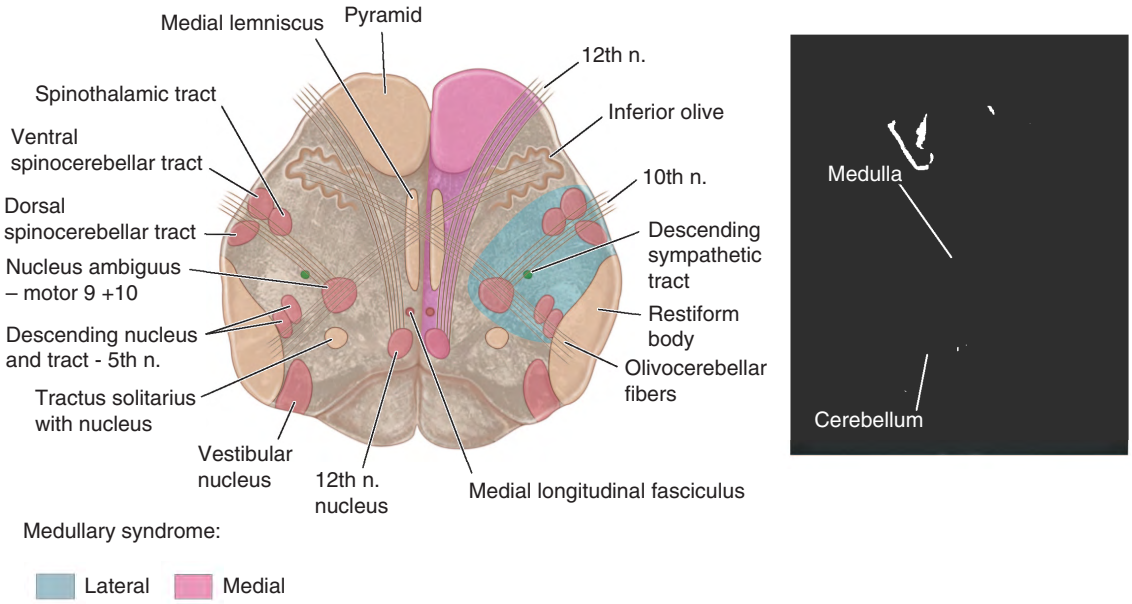

FIGURE 437-7 Axial section at the level of the medulla, depicted schematically on the left, with a corresponding magnetic resonance image on the right. Note that in Figs. 437-7 through 437-11, all drawings are oriented with the dorsal surface at the bottom, matching the orientation of the brainstem that is commonly seen in all modern neuroimaging studies. Approximate regions involved in medial and lateral medullary stroke syndromes are shown.

Signs and symptoms: *Structures involved*

1. Medial medullary syndrome (occlusion of vertebral artery or of branch of vertebral or lower basilar artery)

On side of lesion

Paralysis with atrophy of one-half half the tongue: *Ipsilateral twelfth nerve*

Paralysis of arm and leg, sparing face; impaired tactile and proprioceptive sense over one-half the body: *Contralateral pyramidal tract and medial lemniscus*

Pain, numbness, impaired sensation over one-half the face: *Descending tract and nucleus fifth nerve*

Ataxia of limbs, falling to side of lesion: *Uncertain—restiform body, cerebellar hemisphere, cerebellar fibers, spinocerebellar tract (?)*

Nystagmus, diplopia, oscillopsia, vertigo, nausea, vomiting: *Vestibular nucleus*

Horner's syndrome (miosis, ptosis, decreased sweating): *Descending sympathetic tract*

Dysphagia, hoarseness, paralysis of palate, paralysis of vocal cord, diminished gag reflex: *Issuing fibers ninth and tenth nerves*

Loss of taste: *Nucleus and tractus solitarius*

Numbness of ipsilateral arm, trunk, or leg: *Cuneate and gracile nuclei*

Weakness of lower face: *Genuflected upper motor neuron fibers to ipsilateral facial nucleus*

Impaired pain and thermal sense over half the body, sometimes face: *Spinothalamic tract*

5. Basilar artery syndrome (the syndrome of the lone vertebral artery is equivalent): A combination of the various brainstem syndromes plus those arising in the posterior cerebral artery distribution.

Bilateral long tract signs (sensory and motor; cerebellar and peripheral cranial nerve abnormalities): *Bilateral long tract; cerebellar and peripheral cranial nerves*

Paralysis or weakness of all extremities, plus all bulbar musculature: *Corticobulbar and corticospinal tracts bilaterally*

upward to join the other vertebral artery to form the basilar artery (Fig. 437-6); only the fourth segment gives rise to branches that supply the brainstem and cerebellum. The posterior inferior cerebellar artery (PICA) in its proximal segment supplies the lateral medulla and, in its distal branches, the inferior surface of the cerebellum.

Atherothrombotic lesions have a predilection for V1 and V4 segments of the vertebral artery. The first segment may become diseased at the origin of the vessel and may produce posterior circulation emboli; collateral flow from the contralateral vertebral artery or the ascending cervical, thyrocervical, or occipital arteries is usually sufficient to prevent low-flow TIAs or stroke. When one vertebral artery is atretic and an atherothrombotic lesion threatens the origin of the other, the collateral circulation, which may also include retrograde flow down the basilar artery, is often insufficient (Figs. 437-5 and 437-6). In this setting, low-flow TIAs may occur, consisting of syncope, vertigo, and alternating hemiplegia; this state also sets the stage for thrombosis. Disease of the distal fourth segment of the vertebral artery can promote thrombus formation manifest as embolism or with propagation as basilar artery thrombosis. Stenosis proximal to the origin of the PICA can threaten the lateral medulla and posterior inferior surface of the cerebellum.

If the subclavian artery is occluded proximal to the origin of the vertebral artery, there is a reversal in the direction of blood flow in the ipsilateral vertebral artery. Exercise of the ipsilateral arm may increase demand on vertebral flow, producing posterior circulation TIAs, or "subclavian steal."

Although atheromatous disease rarely narrows the second and third segments of the vertebral artery, this region is subject to dissection, fibromuscular dysplasia, and, rarely, encroachment by osteophytic spurs within the vertebral foramina.

Embolic occlusion or thrombosis of a V4 segment causes ischemia of the lateral medulla. The constellation of vertigo, numbness of the ipsilateral face and contralateral limbs, diplopia, hoarseness, dysarthria, dysphagia, and ipsilateral Horner's syndrome is called the *lateral medullary (or Wallenberg's) syndrome* (Fig. 437-7). Ipsilateral upper motor neuron facial weakness can also occur. Most cases result from ipsilateral vertebral artery occlusion; in the remainder, PICA occlusion is responsible. Occlusion of the medullary penetrating branches of the vertebral artery or PICA results in partial syndromes. *Hemiparesis is not a typical feature of vertebral artery occlusion; however, quadriparesis may result from occlusion of the anterior spinal artery.*

Rarely, a *medial medullary syndrome* occurs with infarction of the pyramid and contralateral hemiparesis of the arm and leg, sparing the face. If the medial lemniscus and emerging hypoglossal nerve fibers are involved, contralateral loss of joint position sense and ipsilateral tongue weakness occur.

Cerebellar infarction can lead to *respiratory arrest* due to brainstem herniation from cerebellar swelling, closure of the aqueduct of Silvius or fourth ventricle, followed by hydrocephalus and central herniation. This added downward displacement of the brainstem from hydrocephalus will exacerbate respiratory and hemodynamic instability. Drowsiness, Babinski signs, dysarthria, and bifacial weakness may be absent, or present only briefly, before respiratory arrest ensues. Gait unsteadiness, headache, dizziness, nausea, and vomiting may be the only early symptoms and signs and should arouse suspicion of this impending complication, which may require neurosurgical decompression, often with an excellent outcome. Separating these symptoms from those of

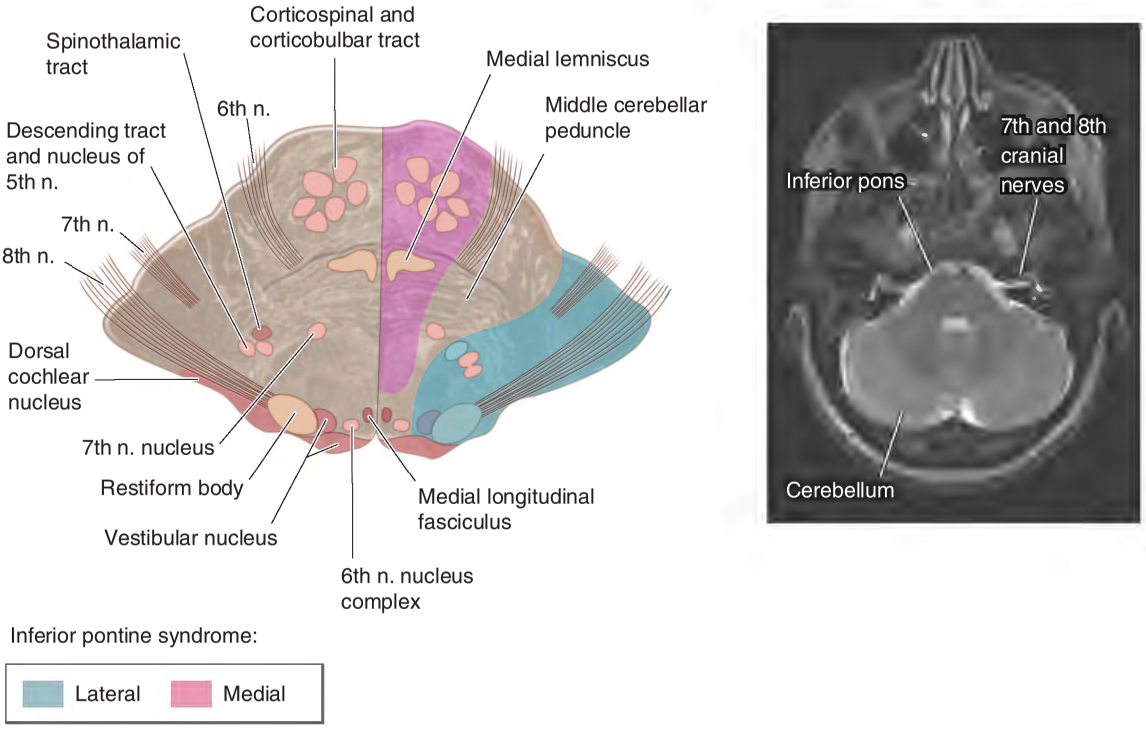

FIGURE 437-8 Axial section at the level of the inferior pons, depicted schematically on the left, with a corresponding magnetic resonance image on the right. Approximate regions involved in medial and lateral inferior pontine stroke syndromes are shown.

Signs and symptoms: *Structures involved*
Paralysis of conjugate gaze to side of lesion (preservation of convergence): *Center for conjugate lateral gaze*
Nystagmus: *Vestibular nucleus*
Ataxia of limbs and gait: Likely *middle cerebellar peduncle*
Diplopia on lateral gaze: *Abducens nerve*
Paralysis of face, arm, and leg: *Corticobulbar and corticospinal tract in lower pons*
Impaired tactile and proprioceptive sense over one-half of the body: *Medial lemniscus*
Horizontal and vertical nystagmus, vertigo, nausea, vomiting, oscillopsia: *Vestibular nerve or nucleus*
Facial paralysis: *Seventh nerve*
Paralysis of conjugate gaze to side of lesion: *Center for conjugate lateral gaze*
Deafness, tinnitus: *Auditory nerve or cochlear nucleus*
Ataxia: *Middle cerebellar peduncle and cerebellar hemisphere*
Impaired sensation over face: *Descending tract and nucleus fifth nerve*
Impaired pain and thermal sense over one-half the body (may include face): *Spinothalamic tract*

viral labyrinthitis can be a challenge, but headache, neck stiffness, and unilateral dysmetria favor stroke.

BASILAR ARTERY Branches of the basilar artery (Fig. 437-6) supply the base of the pons and superior cerebellum and fall into three groups: (1) paramedian, 7–10 in number, which supply a wedge of pons on either side of the midline; (2) short circumferential, 5–7 in number, that supply the lateral two-thirds of the pons and middle and superior cerebellar peduncles; and (3) bilateral long circumferential (superior cerebellar and anterior inferior cerebellar arteries), which course around the pons to supply the cerebellar hemispheres.

Atheromatous lesions can occur anywhere along the basilar trunk but are most frequent in the proximal basilar and distal vertebral segments. Typically, lesions occlude either the proximal basilar and one or both vertebral arteries. The clinical picture varies depending on the availability of retrograde collateral flow from the posterior communicating arteries. Rarely, dissection of a vertebral artery may involve the basilar artery and, depending on the location of true and false lumen, may produce multiple penetrating artery strokes.

Although atherothrombosis occasionally occludes the distal portion of the basilar artery, emboli from the heart or proximal vertebral or basilar segments are more commonly responsible for "top of the basilar" syndromes.

Because the brainstem contains many structures in close apposition, a diversity of clinical syndromes may emerge with ischemia, reflecting involvement of the corticospinal and corticobulbar tracts, ascending sensory tracts, and cranial nerve nuclei (Figs. 437-7 to 437-11).

The symptoms of transient ischemia or infarction in the territory of the basilar artery often do not indicate whether the basilar artery itself or one of its branches is diseased, yet this distinction has important implications for therapy. *The picture of complete basilar occlusion, however, is easy to recognize as a constellation of bilateral long tract signs (sensory and motor) with signs of cranial nerve and cerebellar dysfunction.* Patients may have spontaneous posturing movements that are myoclonic in nature and simulate seizure activity. These movements are brief, repetitive, and multifocal and often confused with status epilepticus. CT or magnetic resonance angiography can rapidly detect basilar thrombosis, and rapid treatment (thrombectomy) can be lifesaving. A "locked-in" state of preserved consciousness with quadriplegia and cranial nerve signs suggests complete pontine and lower midbrain infarction. The therapeutic goal is to identify *impending* basilar occlusion before devastating infarction occurs. A series of TIAs and a slowly progressive, fluctuating stroke are extremely significant, because they often herald an atherothrombotic occlusion of the distal vertebral or proximal basilar artery.

TIAs in the proximal basilar distribution may produce vertigo (often described by patients as "swimming," "swaying," "moving," "unsteadiness," or "light-headedness"). Other symptoms that warn of basilar thrombosis include diplopia, dysarthria, facial or circumoral numbness, and hemisensory symptoms. In general, symptoms of basilar branch TIAs affect one side of the brainstem, whereas symptoms of basilar artery TIAs usually affect both sides, although a "herald" hemiparesis has been emphasized as an initial symptom of basilar occlusion. Most often, TIAs, whether due to impending occlusion of the basilar artery or a basilar branch, are short lived (5–30 min) and repetitive, occurring several times a day. The pattern suggests intermittent reduction of flow. Although treatment with intravenous heparin or various

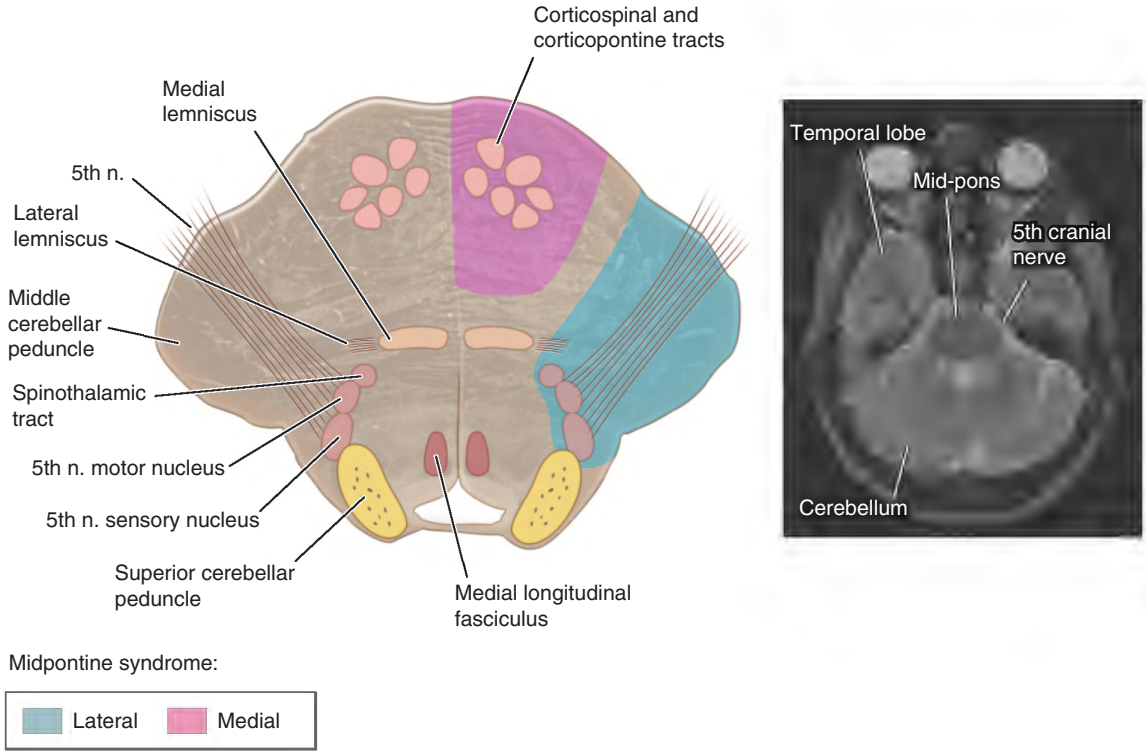

FIGURE 437-9 Axial section at the level of the midpons, depicted schematically on the left, with a corresponding magnetic resonance image on the right. Approximate regions involved in medial and lateral midpontine stroke syndromes are shown.

Signs and symptoms: *Structures involved*
Ataxia of limbs and gait (more prominent in bilateral involvement): *Pontine nuclei*
Paralysis of face, arm, and leg: *Corticobulbar and corticospinal tract*
Variable impaired touch and proprioception when lesion extends posteriorly: *Medial lemniscus*
Ataxia of limbs: *Middle cerebellar peduncle*
Paralysis of muscles of mastication: *Motor fibers or nucleus of fifth nerve*
Impaired sensation over side of face: *Sensory fibers or nucleus of fifth nerve*
Impaired pain and thermal sense on limbs and trunk: *Spinothalamic tract*

combinations of antiplatelet agents has been used to prevent clot propagation, there is no specific evidence to support any one approach, and endovascular intervention is also an option.

Atherothrombotic occlusion of the basilar artery with infarction usually causes *bilateral* brainstem signs. A gaze paresis or internuclear ophthalmoplegia associated with ipsilateral hemiparesis may be the only manifestation of bilateral brainstem ischemia. More often, unequivocal signs of bilateral pontine disease are present. Complete basilar thrombosis carries a high mortality.

Occlusion of a branch of the basilar artery usually causes *unilateral* symptoms and signs involving motor, sensory, and cranial nerves. If symptoms remain unilateral, concern over pending basilar occlusion should be reduced.

Occlusion of the superior cerebellar artery results in severe ipsilateral cerebellar ataxia, nausea and vomiting, dysarthria, and contralateral loss of pain and temperature sensation over the extremities, body, and face (spino- and trigeminothalamic tract). Partial deafness, ataxic tremor of the ipsilateral upper extremity, Horner's syndrome, and palatal myoclonus may occur rarely. Partial syndromes occur frequently (Fig. 437-10). With large strokes, swelling and mass effects may compress the midbrain or produce hydrocephalus; these symptoms may evolve rapidly. Neurosurgical intervention may be lifesaving in such cases.

Occlusion of the anterior inferior cerebellar artery produces variable degrees of infarction because the size of this artery and the territory it supplies vary inversely with those of the PICA. The principal symptoms include (1) ipsilateral deafness, facial weakness, vertigo, nausea and vomiting, nystagmus, tinnitus, cerebellar ataxia, Horner's syndrome, and paresis of conjugate lateral gaze; and (2) contralateral loss of pain and temperature sensation. An occlusion close to the origin of the artery may cause corticospinal tract signs (Fig. 437-8).

Occlusion of one of the short circumferential branches of the basilar artery affects the lateral two-thirds of the pons and middle or superior cerebellar peduncle, whereas occlusion of one of the paramedian branches affects a wedge-shaped area on either side of the medial pons (Figs. 437-8–437-10).

IMAGING STUDIES

See also Chap. 434.

CT Scans CT radiographic images identify or exclude hemorrhage as the cause of stroke, and they identify extraparenchymal hemorrhages, neoplasms, abscesses, and other conditions masquerading as stroke. Brain CT scans obtained in the first several hours after an infarction generally show no abnormality (Fig. 437-12*A*), and the infarct may not be seen reliably for 24–48 h. The decision to treat patients with IV plasminogen activators is based on the clinical diagnosis of stroke and a CT scan showing no hemorrhage. CT may fail to show small ischemic strokes in the posterior fossa because of bone artifact; small infarcts on the cortical surface may also be missed.

Contrast-enhanced CT scans add specificity by showing contrast enhancement of subacute infarcts and allow visualization of venous structures. Coupled with multidetector scanners, CT angiography can be performed with administration of IV iodinated contrast allowing visualization of the cervical and intracranial arteries, intracranial veins, and aortic arch in one imaging session. Carotid disease and intracranial vascular occlusions are readily identified with this method (see Fig. 438-2). After an IV bolus of contrast, deficits in brain perfusion produced by vascular occlusion can also be demonstrated (Fig. 437-12*D*) and used to predict the region of infarcted brain and the brain at risk of further infarction (i.e., the ischemic penumbra, see "Pathophysiology of Ischemic Stroke" in Chap. 438). CT imaging is also sensitive for detecting SAH (although by itself does not rule it out), and CTA can readily

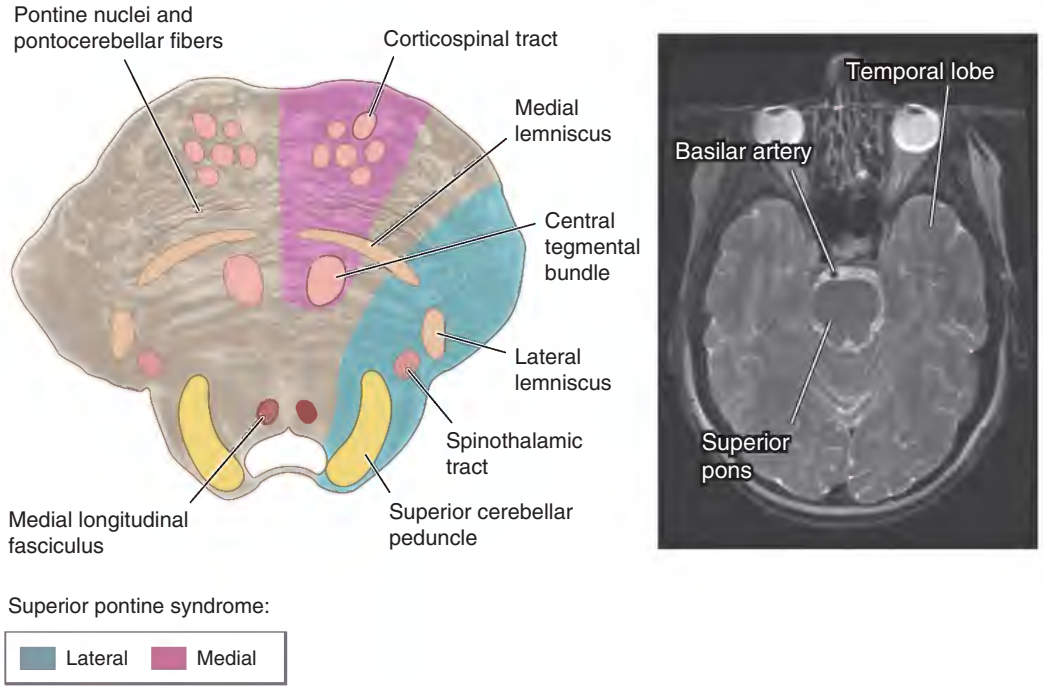

FIGURE 437-10 Axial section at the level of the superior pons, depicted schematically on the left, with a corresponding magnetic resonance image on the right. Approximate regions involved in medial and lateral superior pontine stroke syndromes are shown.

Signs and symptoms: *Structures involved*
Cerebellar ataxia (probably): *Superior and/or middle cerebellar peduncle*
Internuclear ophthalmoplegia: *Medial longitudinal fasciculus*
Myoclonic syndrome, palate, pharynx, vocal cords, respiratory apparatus, face, oculomotor apparatus, etc.: *Localization uncertain—central tegmental bundle, dentate projection, inferior olivary nucleus*
Paralysis of face, arm, and leg: *Corticobulbar and corticospinal tract*
Rarely touch, vibration, and position are affected: *Medial lemniscus*
Ataxia of limbs and gait, falling to side of lesion: *Middle and superior cerebellar peduncles, superior surface of cerebellum, dentate nucleus*
Dizziness, nausea, vomiting; horizontal nystagmus: *Vestibular nucleus*
Paresis of conjugate gaze (ipsilateral): *Pontine contralateral gaze*
Skew deviation: *Uncertain*
Miosis, ptosis, decreased sweating over face (Horner's syndrome): *Descending sympathetic fibers*
Tremor: Localization unclear—*Dentate nucleus, superior cerebellar peduncle*
Impaired pain and thermal sense on face, limbs, and trunk: *Spinothalamic tract*
Impaired touch, vibration, and position sense, more in leg than arm (there is a tendency to incongruity of pain and touch deficits): *Medial lemniscus (lateral portion)*

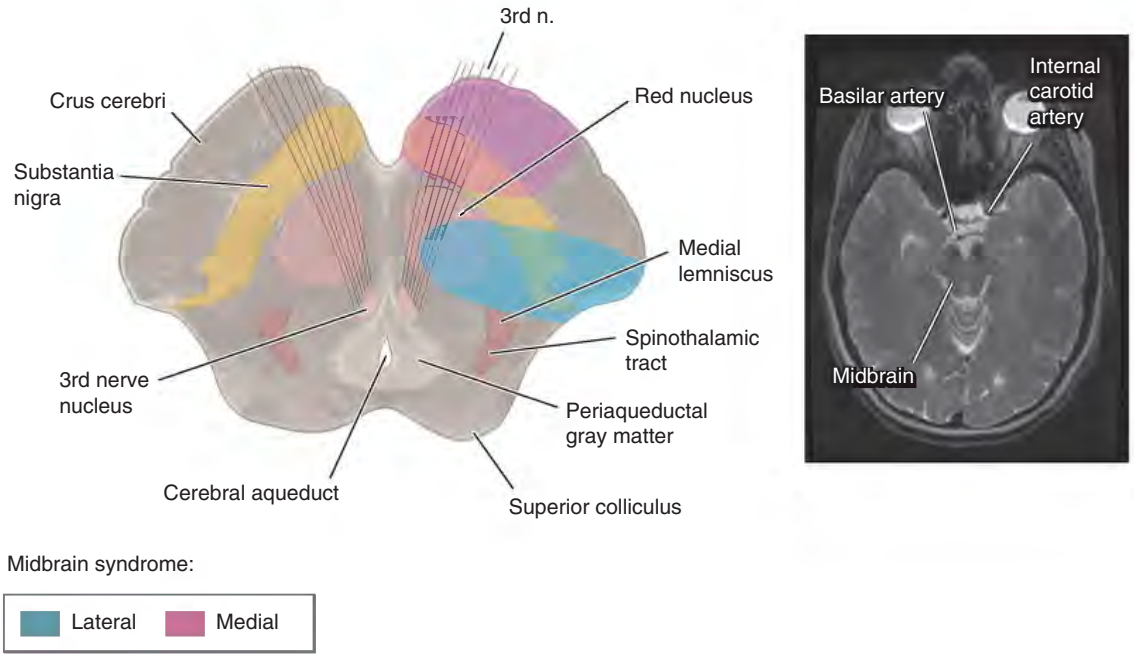

FIGURE 437-11 Axial section at the level of the midbrain, depicted schematically on the left, with a corresponding magnetic resonance image on the right. Approximate regions involved in medial and lateral midbrain stroke syndromes are shown.

Signs and symptoms: *Structures involved*
Eye "down and out" secondary to unopposed action of fourth and sixth cranial nerves, with dilated and unresponsive pupil: *Third nerve fibers*
Paralysis of face, arm, and leg: *Corticobulbar and corticospinal tract descending in crus cerebri*
Eye "down and out" secondary to unopposed action of fourth and sixth cranial nerves, with dilated and unresponsive pupil: *Third nerve fibers and/or third nerve nucleus*
Hemiataxia, hyperkinesias, tremor: *Red nucleus, dentatorubrothalamic pathway*

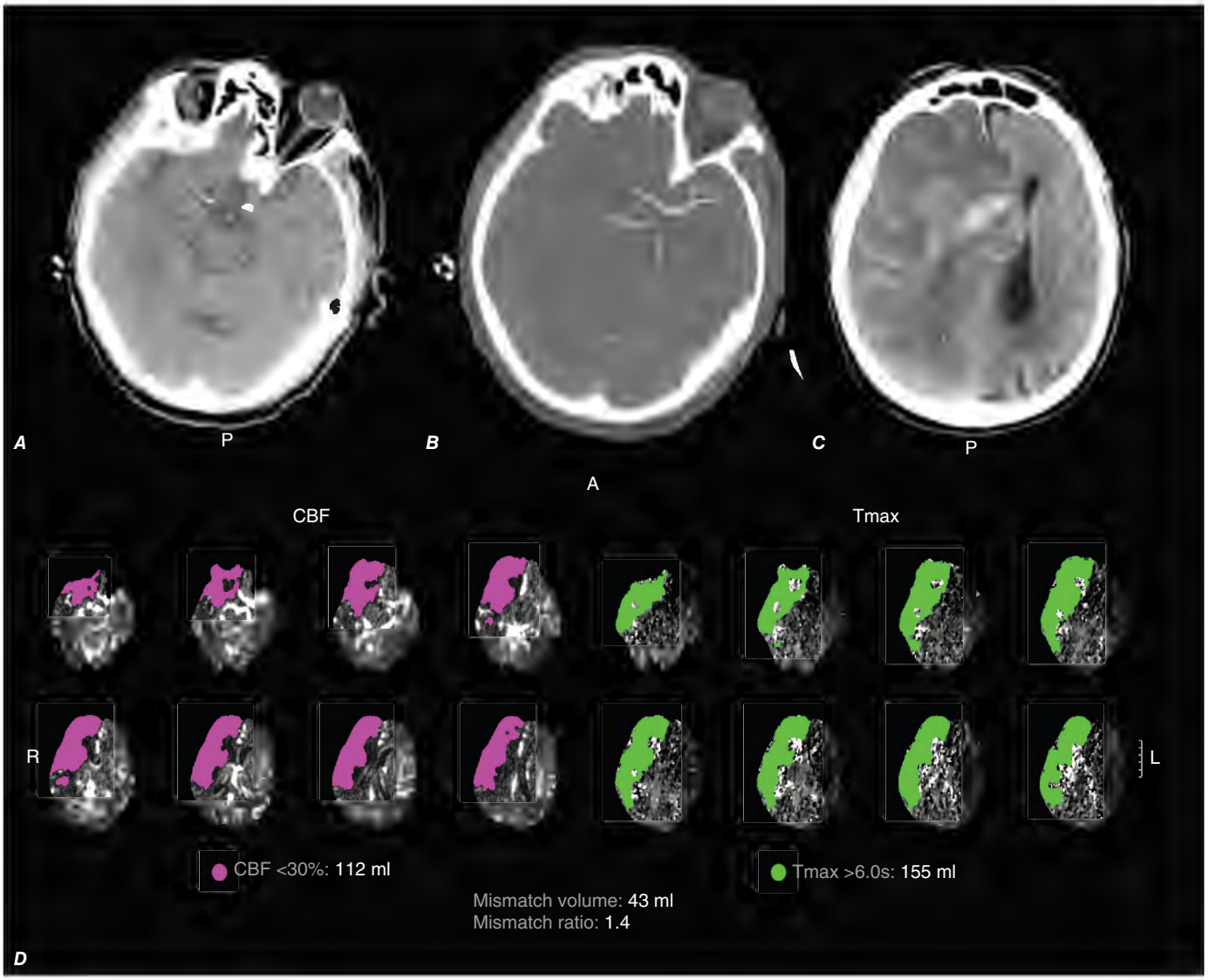

FIGURE 437-12 ***(A)*** Noncontrast head computed tomography (CT) image of an 83-year-old man with sudden onset left hemiplegia, left homonymous hemianopia, rightward gaze deviation and left hemineglect showing no clear brain infarction and hyperdensity within the right middle cerebral artery (MCA) suggestive of clot. ***(B)*** CT angiography performed at the same time as the CT showing absence of the right MCA and anterior cerebral artery (ACA) vessels consistent with occlusion of the bifurcation of the right intracranial internal carotid artery. ***(C)*** Follow-up head CT 1 day later showing extensive infarction of the right frontal lobe with brain herniation. ***(D)*** CT perfusion performed with studies shown in ***A*** and ***B***. This predicts a large core infarction (pink regions) despite attempts at revascularization with thrombectomy. CBF, cerebral blood flow.

identify intracranial aneurysms (Chap. 440). Because of its speed and wide availability, noncontrast head CT is the imaging modality of choice in patients with acute stroke (Fig. 437-1), and CTA and CT perfusion imaging may also be useful and convenient adjuncts.

MRI

MRI reliably documents the extent and location of infarction in all areas of the brain, including the posterior fossa and cortical surface. Diffusion-weighted imaging (DWI) identifies regions of brain infarction within minutes of the stroke onset (Fig. 437-13*A*, *B*), while fluid-attenuated inversion recovery (FLAIR) imaging reliably reveals areas of prior brain infarction from a few days to years later (Fig. 437-13*C*). CT is poorly sensitive to brain infarction in the posterior fossae compared to MRI DWI images (Fig. 437-13*D*, *E*). MRI also identifies intracranial hemorrhage and other abnormalities and, using special sequences, can be as sensitive as CT for detecting acute intracerebral hemorrhage. MRI scanners with magnets of higher field strength produce more reliable and precise images. Using IV administration of gadolinium contrast, magnetic resonance (MR) perfusion studies can be performed. Brain regions showing poor perfusion but no abnormality on diffusion provide, compared to CT, an equivalent measure of the ischemic penumbra. MR angiography is highly sensitive for stenosis of extracranial internal carotid arteries and of large intracranial vessels. With higher degrees of stenosis, MR angiography tends to overestimate the degree of stenosis when compared to conventional x-ray angiography. MRI with fat saturation is an imaging sequence used to visualize extra- or intracranial arterial dissection. This sensitive technique images clotted blood within the dissected vessel wall. Iron-sensitive imaging (ISI) is helpful to detect cerebral microbleeds that may be present in cerebral amyloid angiopathy and other hemorrhagic disorders.

MRI is more expensive and time consuming than CT and less readily available. Claustrophobia and the logistics of imaging acutely critically ill patients also limit its application. Most acute stroke protocols use CT because of these limitations. However, MRI is useful outside the acute period by more clearly defining the extent of tissue injury and discriminating new from old regions of brain infarction. MRI may have utility in patients with TIA, because it is also more likely to identify new infarction, which is a strong predictor of subsequent stroke.

Cerebral Angiography Conventional x-ray cerebral angiography is the gold standard for identifying and quantifying atherosclerotic stenoses of the cerebral arteries and for identifying and characterizing other pathologies, including aneurysms, vasospasm, intraluminal thrombi, fibromuscular dysplasia, arteriovenous fistulae, vasculitis, and collateral channels of blood flow. Conventional angiography carries risks of arterial damage, groin hemorrhage, embolic stroke, and

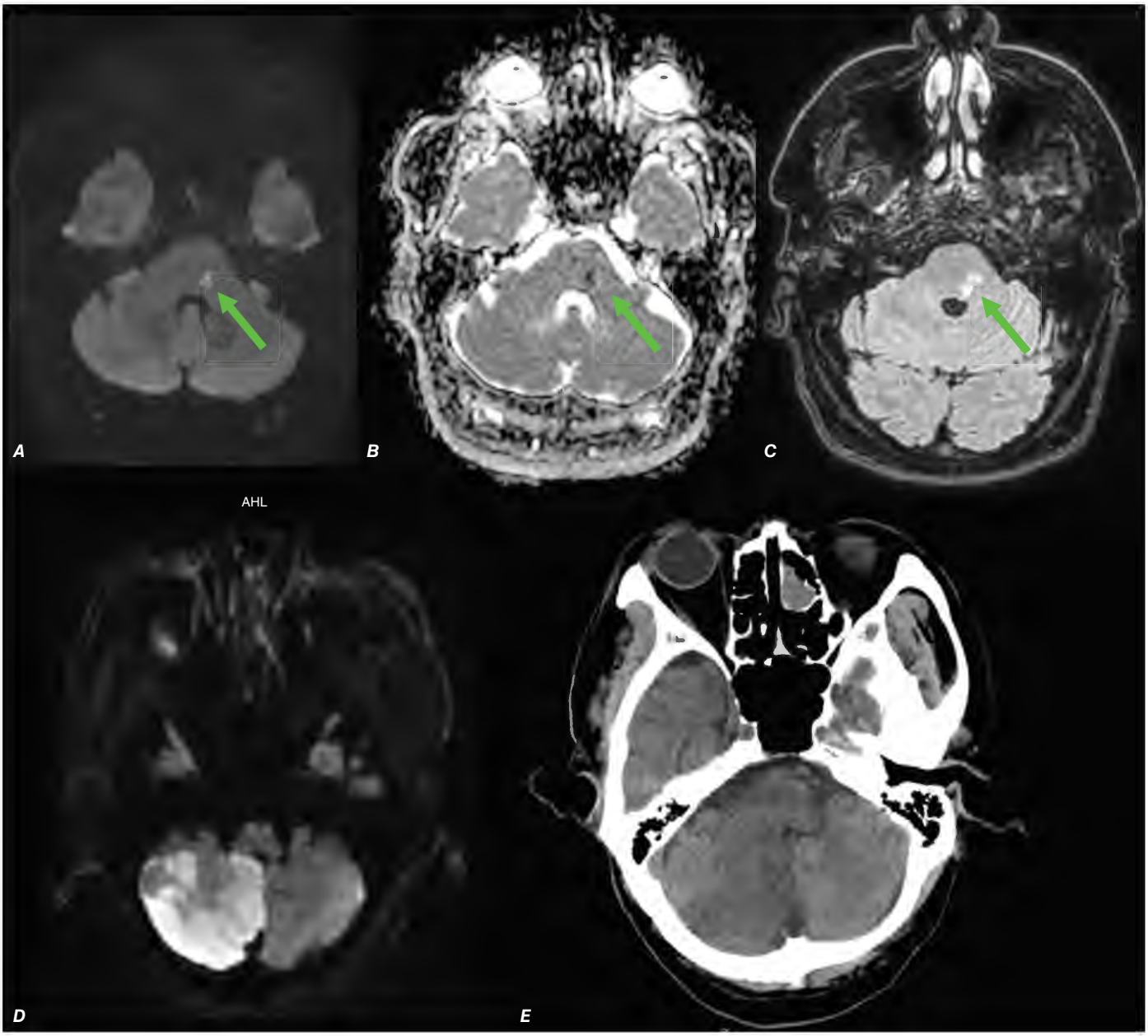

FIGURE 437-13 Examples of magnetic resonance imaging (MRI) imaging of acute ischemic infarcts. ***(A)*** Diffusion-weighted image (DWI) revealing bright region in the left pons (*arrow*), and ***(B)*** dark region on apparent diffusion coefficient (ADC) in the same region. Bright regions on DWI and corresponding dark regions on ADC are consistent with acute brain ischemia (within minutes to hours of stroke onset). (***C***) Same region of the brain 2 days later showing bright region in the infarcted tissue on fluid-attenuated inversion recovery (FLAIR) images. The DWI and ADC values will return to normal after 10–14 days while the FLAIR abnormality will persist long term. ***(D)*** DWI MRI and ***(E)*** computed tomography (CT) images of a patient with acute-onset vertigo. The DWI image shows an acute ischemic infarction of the right posterior inferior cerebellar artery territory within the cerebellum, whereas the CT scan is only subtly hypodense in the same region. MRI is superior to CT imaging for identifying ischemic infarction especially within the posterior fossa.

renal failure from contrast nephropathy, so it should be reserved for situations where less invasive means are inadequate. Acute stroke treatment with endovascular thrombectomy has proven effective in ischemic strokes caused by internal carotid terminus or MCA occlusions and is now part of routine clinical practice at centers that have this capability **(see Chap. 438)**.

Ultrasound Techniques Stenosis at the origin of the internal carotid artery can be identified and quantified reliably by ultrasonography that combines a B-mode ultrasound image with a Doppler ultrasound assessment of flow velocity ("duplex" ultrasound). Transcranial Doppler (TCD) assessment of MCA, ACA, and PCA flow and of vertebrobasilar flow is also useful. This latter technique can detect stenotic lesions in the large intracranial arteries because such lesions increase systolic flow velocity. TCD can also detect microemboli from otherwise asymptomatic carotid plaques. In many cases, MR angiography combined with carotid and transcranial ultrasound studies eliminates the need for conventional x-ray angiography in evaluating vascular stenosis. Alternatively, CTA of the entire head and neck can be performed during the initial imaging of acute stroke. Because this images the entire arterial system relevant to stroke, with the exception of the heart, much of the clinician's stroke workup can be completed with this single imaging study.

Radionuclide Perfusion Techniques Both xenon techniques (principally xenon-CT) and positron emission tomography (PET) can quantify cerebral blood flow. These tools are generally used for research **(Chap. 434)** but can be useful for determining the significance of arterial stenosis and planning for revascularization surgery. Single-photon emission computed tomography (SPECT) and CT or MR perfusion techniques report relative cerebral blood flow. As noted above, CT imaging is used as the initial imaging modality for acute stroke, and