and costs. Patients with high-risk endoscopic findings (e.g., varices, ulcers with active bleeding or a visible vessel) benefit from hemostatic therapy at endoscopy.

EVALUATION AND MANAGEMENT OF LGIB (FIG. 51-2)

Patients with hematochezia and hemodynamic instability should have upper endoscopy to rule out an upper GI source before evaluation of the lower GI tract.

Colonoscopy after an oral lavage solution is the procedure of choice in most patients admitted with LGIB. If ongoing hemodynamically significant hematochezia precludes bowel preparation and colonoscopy, computed tomography (CT) angiography is suggested. If extravasation is seen, angiography is performed, allowing treatment with transcatheter arterial embolization. If no extravasation is seen, colonoscopy is subsequently performed.

EVALUATION AND MANAGEMENT OF SMALL-INTESTINAL OR OBSCURE GIB

In patients with severe bleeding suspected to be from the small intestine, CT angiography or angiography is the initial test. For others, video capsule endoscopy is generally the next diagnostic test suggested, although repeat upper and lower endoscopy may be considered because second-look procedures in some observational studies identify a source in up to ~25% of cases (a push enteroscopy, usually performed with a pediatric colonoscope to inspect the entire duodenum and proximal jejunum, may be substituted for a repeat standard upper endoscopy). Systematic reviews report a diagnostic yield with capsule endoscopy of ~55%. Limitations of capsule endoscopy include the inability to fully visualize the small intestinal mucosa, sample tissue, or apply therapy.

If capsule endoscopy is positive, management is dictated by the finding. If capsule endoscopy is negative, clinically stable patients may be observed and treated with iron if iron deficiency is present. In those with further bleeding (e.g., need for transfusions), additional testing is performed. A second capsule endoscopy may be considered because some observational studies report it identifies a source in up to 50% or more of cases. CT enterography also may follow a negative capsule endoscopy, given its higher sensitivity for small-intestinal masses (CT enterography also may be used initially instead of video capsule in patients with concern for small bowel narrowing [e.g., stricture, prior surgery or radiation, Crohn's disease]).

"Deep" enteroscopy (double-balloon, single-balloon, or spiral enteroscopy) is commonly the next test after capsule endoscopy for clinically important GIB documented or suspected to be from the small intestine because it allows the endoscopist to examine, obtain specimens from, and provide therapy to much or all of the small intestine. Other imaging techniques sometimes used in evaluation of obscure GIB include CT angiography, angiography, ^{99m}Tc-labeled red-blood-cell scintigraphy, and ^{99m}Tc-pertechnetate scintigraphy for Meckel's diverticulum (especially in young patients). If all tests are unrevealing, intraoperative endoscopy is indicated in patients with severe recurrent or persistent bleeding requiring repeated transfusions.

POSITIVE FECAL OCCULT BLOOD TEST

Fecal occult blood testing is recommended only for colorectal cancer screening, beginning at age 45 years in average-risk adults. A positive test necessitates colonoscopy. If evaluation of the colon is negative, further workup is not recommended unless iron-deficiency anemia or GI symptoms are present.

FURTHER READING

Chen H et al: Thalidomide for recurrent bleeding due to small-intestinal angiodysplasia. N Engl J Med 389:1649, 2023.

Kaplan DE et al: AASLD practice guidance on risk stratification and management of portal hypertension and varices in cirrhosis. Hepatology 79:1180, 2024.

Karuppasamy K et al: ACR Appropriateness criteria® radiologic management of lower gastrointestinal tract bleeding: 2021 update. J Am Coll Radiol 18:S139, 2021.

Laine L et al: ACG clinical guideline: Upper gastrointestinal and ulcer bleeding. Am J Gastroenterol 116:899, 2021.

Lau JYW et al: Timing of endoscopy for acute upper gastrointestinal bleeding. N Engl J Med 382:1299, 2020.

Pennazio M et al: Small-bowel capsule endoscopy and device-assisted enteroscopy for diagnosis and treatment of small-bowel disorders: European Society of Gastrointestinal Endoscopy (ESGE) guideline—update 2022. Endoscopy 55:58, 2023.

Sengupta N et al: Management of patients with acute lower gastrointestinal bleeding: An updated ACG guideline. Am J Gastroenterol 118:208, 2023.

Villaneuva C et al: Transfusion strategies for acute upper gastrointestinal bleeding. N Engl J Med 368:11, 2013.

Ye Z et al: Gastrointestinal bleeding prophylaxis for critically ill patients: A clinical practice guideline. BMJ 368:16722, 2020.

52 Jaundice

Savio John, Daniel S. Pratt

Jaundice is a yellowish discoloration of body tissues resulting from the deposition of bilirubin. Tissue deposition of bilirubin occurs only in the presence of serum hyperbilirubinemia and is a sign of either liver disease or, less often, a hemolytic disorder or disorder of bilirubin metabolism. The degree of serum bilirubin elevation can be estimated by physical examination. Slight increases in serum bilirubin level are best detected by examining the sclerae for icterus. Sclerae have a particular affinity for bilirubin due to their high elastin content, and the presence of scleral icterus indicates a serum bilirubin level of at least 51 μmol/L (3 mg/dL). The ability to detect scleral icterus is made more difficult if the examining room has fluorescent lighting. If the examiner suspects scleral icterus, a second site to examine is underneath the tongue. As serum bilirubin levels rise, the skin will eventually become yellow in light-skinned patients and even green if the process is long-standing; the green color is produced by oxidation of bilirubin to biliverdin.

The differential diagnosis for yellowing of the skin is limited. In addition to jaundice, it includes carotenoderma; the use of drugs including quinacrine, sunitinib, and sorafenib; and excessive exposure to phenols. Carotenoderma, a yellow coloring of the skin, is associated with diabetes, hypothyroidism, and anorexia nervosa, but most commonly, it is caused by the ingestion of an excessive amount of vegetables and fruits such as carrots, leafy vegetables, squash, peaches, and oranges that contain carotene. In jaundice, the yellow coloration of the skin is uniformly distributed over the body, whereas in carotenoderma, the pigment is concentrated on the palms, soles, forehead, and nasolabial folds. Carotenoderma can be distinguished from jaundice by the sparing of the sclerae. Quinacrine causes a yellow discoloration of the skin in 4–37% of patients treated with it. It has also been reported with the use of the tyrosine kinase inhibitors sunitinib and sorafenib.

Another sensitive indicator of increased serum bilirubin is darkening of the urine, which is due to the renal excretion of conjugated bilirubin. Patients often describe their urine as tea- or cola-colored. Bilirubinuria indicates an elevation of the direct serum bilirubin fraction and, therefore, the presence of liver or biliary disease.

Serum bilirubin levels increase when an imbalance exists between bilirubin production and clearance. A logical evaluation of the patient who is jaundiced requires an understanding of bilirubin production and metabolism.

PRODUCTION AND METABOLISM OF BILIRUBIN

(See Chap. 349) Bilirubin, a tetrapyrrole pigment, is a breakdown product of heme (ferroprotoporphyrin IX). About 80–85% of the

4 mg/kg body weight of bilirubin produced each day is derived from the breakdown of hemoglobin in senescent red blood cells. The remainder comes from prematurely destroyed erythroid cells in bone marrow and from the turnover of hemoproteins such as myoglobin and cytochromes found in tissues throughout the body.

The formation of bilirubin occurs in reticuloendothelial cells, primarily in the spleen and liver. The first reaction, catalyzed by the microsomal enzyme heme oxygenase, oxidatively cleaves the α bridge of the porphyrin group and opens the heme ring. The end products of this reaction are biliverdin, carbon monoxide, and iron. The second reaction, catalyzed by the cytosolic enzyme biliverdin reductase, reduces the central methylene bridge of biliverdin and converts it to bilirubin. Bilirubin formed in the reticuloendothelial cells is virtually insoluble in water due to tight internal hydrogen bonding between the water-soluble moieties of bilirubin—that is, the bonding of the propionic acid carboxyl groups of one dipyrrolic half of the molecule with the imino and lactam groups of the opposite half. This configuration blocks solvent access to the polar residues of bilirubin and places the hydrophobic residues on the outside. To be transported in blood, bilirubin must be solubilized. Solubilization is accomplished by the reversible, noncovalent binding of bilirubin to albumin. Unconjugated bilirubin bound to albumin is transported to the liver. There, the bilirubin—but not the albumin—is taken up by hepatocytes via a process that at least partly involves carrier-mediated membrane transport. Remarkably, a full understanding of this process remains elusive as no specific bilirubin transporter has yet been identified **(Chap. 349, Fig. 349-1)**.

After entering the hepatocyte, unconjugated bilirubin is bound in the cytosol to several proteins including proteins in the glutathione-*S*-transferase superfamily. These proteins serve both to reduce efflux of bilirubin back into the serum and to present the bilirubin for conjugation. In the endoplasmic reticulum, bilirubin is made aqueous soluble by conjugation to glucuronic acid, a process that disrupts the hydrophobic internal hydrogen bonds and yields bilirubin monoglucuronide and diglucuronide. The conjugation of glucuronic acid to bilirubin is catalyzed by bilirubin uridine diphosphate-glucuronosyl transferase (UDPGT). The now-hydrophilic bilirubin conjugates diffuse from the endoplasmic reticulum to the canalicular membrane, where bilirubin monoglucuronide and diglucuronide are actively transported into canalicular bile by an energy-dependent mechanism involving the multidrug resistance–associated protein 2 (MRP2). A portion of bilirubin glucuronides is transported into the sinusoids and portal circulation by MRP3 and is subjected to reuptake into the hepatocyte by the sinusoidal organic anion transport protein 1B1 (OATP1B1) and OATP1B3. The conjugated bilirubin excreted into bile drains into the duodenum and passes unchanged through the proximal small bowel. Conjugated bilirubin is not reabsorbed by the intestinal mucosa due to its hydrophilicity and increased molecular size. When the conjugated bilirubin reaches the distal ileum and colon, it is hydrolyzed to unconjugated bilirubin by bacterial β-glucuronidases. The unconjugated bilirubin is reduced by normal gut bacteria to form a group of colorless tetrapyrroles called *urobilinogens* and other products, the nature and relative amounts of which depend on the bacterial flora. About 80–90% of these products are excreted in feces, either unchanged or oxidized to orange derivatives called *urobilins*. The remaining 10–20% of the urobilinogens undergo enterohepatic cycling. A small fraction (usually <3 mg/dL) escapes hepatic uptake, filters across the renal glomerulus, and is excreted in urine. Increased urinary excretion of urobilinogen can be due to increased bilirubin production, increased hepatic reabsorption of urobilinogen from the colon, or decreased hepatic clearance of urobilinogen.

MEASUREMENT OF SERUM BILIRUBIN

The terms *direct* and *indirect* bilirubin—that is, conjugated and unconjugated bilirubin, respectively—are based on the original van den Bergh reaction. This assay, or a variation of it, is still used in most clinical chemistry laboratories to determine the serum bilirubin level. In this assay, bilirubin is exposed to diazotized sulfanilic acid and splits into two relatively stable dipyrrylmethene azopigments that absorb maximally at 540 nm, allowing photometric analysis. The direct fraction is that which reacts with diazotized sulfanilic acid in the absence of an accelerator substance such as alcohol. The direct fraction provides an approximation of the conjugated bilirubin level in serum. The *total* serum bilirubin is the amount that reacts after the addition of alcohol to allow the release of unconjugated bilirubin from albumin binding sites. The indirect fraction is the difference between the total and the direct bilirubin levels and provides an estimate of the unconjugated bilirubin in serum. Unconjugated bilirubin also reacts with diazo reagents, albeit slowly, even when the accelerator is absent. Thus, the calculated indirect bilirubin may underestimate the true amount of unconjugated bilirubin in circulation.

With the van den Bergh method, the normal serum bilirubin concentration usually is between 17 and 26 μmol/L (1 and 1.5 mg/dL). Total serum bilirubin concentrations are between 3.4 and 15.4 μmol/L (0.2 and 0.9 mg/dL) in 95% of a normal population. Unconjugated hyperbilirubinemia is present when the direct fraction is <15% of the total serum bilirubin. The presence of even limited amounts of true conjugated bilirubin in serum suggests significant hepatobiliary pathology. As conjugated hyperbilirubinemia is always associated with bilirubinuria (except in the presence of delta bilirubin in prolonged cholestasis when jaundice is overt), detection of bilirubin in urine via dipstick test is extremely helpful to confirm the presence of conjugated hyperbilirubinemia in a patient with a mildly elevated direct fraction.

Other techniques, although less convenient to perform, have added considerably to our understanding of bilirubin metabolism. First, studies using these methods demonstrate that, in normal persons or those with Gilbert's syndrome, almost 100% of the serum bilirubin is unconjugated; <3% is monoconjugated bilirubin. Second, in jaundiced patients with hepatobiliary disease, the total serum bilirubin concentration measured by these more accurate methods is lower than the values found with diazo methods. This finding suggests that there are diazo-positive compounds distinct from bilirubin in the serum of patients with hepatobiliary disease. Third, these studies indicate that, in jaundiced patients with hepatobiliary disease, monoglucuronides of bilirubin predominate over diglucuronides. Fourth, part of the direct-reacting bilirubin fraction includes conjugated bilirubin that is covalently linked to albumin. This albumin-linked fraction of conjugated bilirubin (*delta fraction, delta bilirubin*, or *biliprotein*) represents an important fraction of total serum bilirubin in patients with cholestasis and hepatobiliary disorders. The delta bilirubin is formed in serum when hepatic excretion of bilirubin glucuronides is impaired and the glucuronides accumulate in serum. By virtue of its tight binding to albumin, the clearance rate of delta bilirubin from serum approximates the longer half-life of albumin (18–20 days) rather than the short half-life of bilirubin (about 4 h).

The prolonged half-life of albumin-bound conjugated bilirubin accounts for two previously unexplained enigmas in jaundiced patients with liver disease: (1) that some patients with conjugated hyperbilirubinemia do not exhibit bilirubinuria during the recovery phase of their disease because the delta bilirubin, although conjugated, is covalently bound to albumin and therefore not filtered by the renal glomeruli, and (2) that the elevated serum bilirubin level declines more slowly than expected in some patients who otherwise appear to be recovering satisfactorily. Late in the recovery phase of hepatobiliary disorders, all the conjugated bilirubin may be in the albumin-linked form.

MEASUREMENT OF URINE BILIRUBIN

Unconjugated bilirubin is always bound to albumin in the serum, is not filtered by the kidney, and is not found in the urine. Conjugated bilirubin is filtered at the glomerulus, and the majority is reabsorbed by the proximal tubules; a small fraction is excreted in the urine. Any bilirubin found in the urine is conjugated bilirubin. The presence of bilirubinuria on urine dipstick test (Ictotest) indicates an elevation of the conjugated bilirubin fraction that cannot be excreted from the liver and implies the presence of hepatobiliary disease. A false-negative result is possible in patients with prolonged cholestasis due to the predominance of delta bilirubin, which is covalently bound to albumin and therefore not filtered by the renal glomeruli.

APPROACH TO THE PATIENT

Jaundice

The goal of this chapter is not to provide an encyclopedic review of every condition that causes jaundice. Rather, the chapter is intended to offer a framework that helps a physician to evaluate the patient with jaundice in a logical way **(Fig. 52-1)**.

The initial step is to perform appropriate blood tests in order to determine whether the patient has an isolated elevation of serum bilirubin. If so, is the bilirubin elevation due to an increased unconjugated or conjugated fraction? If the hyperbilirubinemia is accompanied by other liver test abnormalities, is the disorder hepatocellular or cholestatic? If cholestatic, is the cause intra- or extrahepatic? These questions can all be answered with a thoughtful history, physical examination, and interpretation of appropriate laboratory and radiologic tests and procedures.

The bilirubin present in serum represents a balance between input from the production of bilirubin and hepatic/biliary removal of the pigment. Hyperbilirubinemia may result from (1) overproduction of bilirubin; (2) impaired uptake, conjugation, or excretion of bilirubin; or (3) regurgitation of unconjugated or conjugated bilirubin from damaged hepatocytes or bile ducts. An increase in unconjugated bilirubin in serum results from overproduction, impaired uptake, or conjugation of bilirubin. An increase in conjugated bilirubin is due to decreased excretion into the bile ductules or backward leakage of the pigment. The initial steps in evaluating the patient with jaundice are to determine (1) whether the hyperbilirubinemia is predominantly conjugated or unconjugated in nature and (2) whether other biochemical liver tests are abnormal. The thoughtful interpretation of limited data permits a rational evaluation of the patient (Fig. 52-1). The following discussion will focus solely on the evaluation of the adult patient with jaundice.

ISOLATED ELEVATION OF SERUM BILIRUBIN

Unconjugated Hyperbilirubinemia The differential diagnosis of isolated unconjugated hyperbilirubinemia is limited **(Table 52-1)**. The critical determination is whether the patient is suffering from a hemolytic process resulting in an overproduction of bilirubin (hemolytic disorders and ineffective erythropoiesis) or from impaired hepatic uptake/conjugation of bilirubin (drug effect or genetic disorders).

Hemolytic disorders that cause excessive heme production may be either inherited or acquired. Inherited disorders include

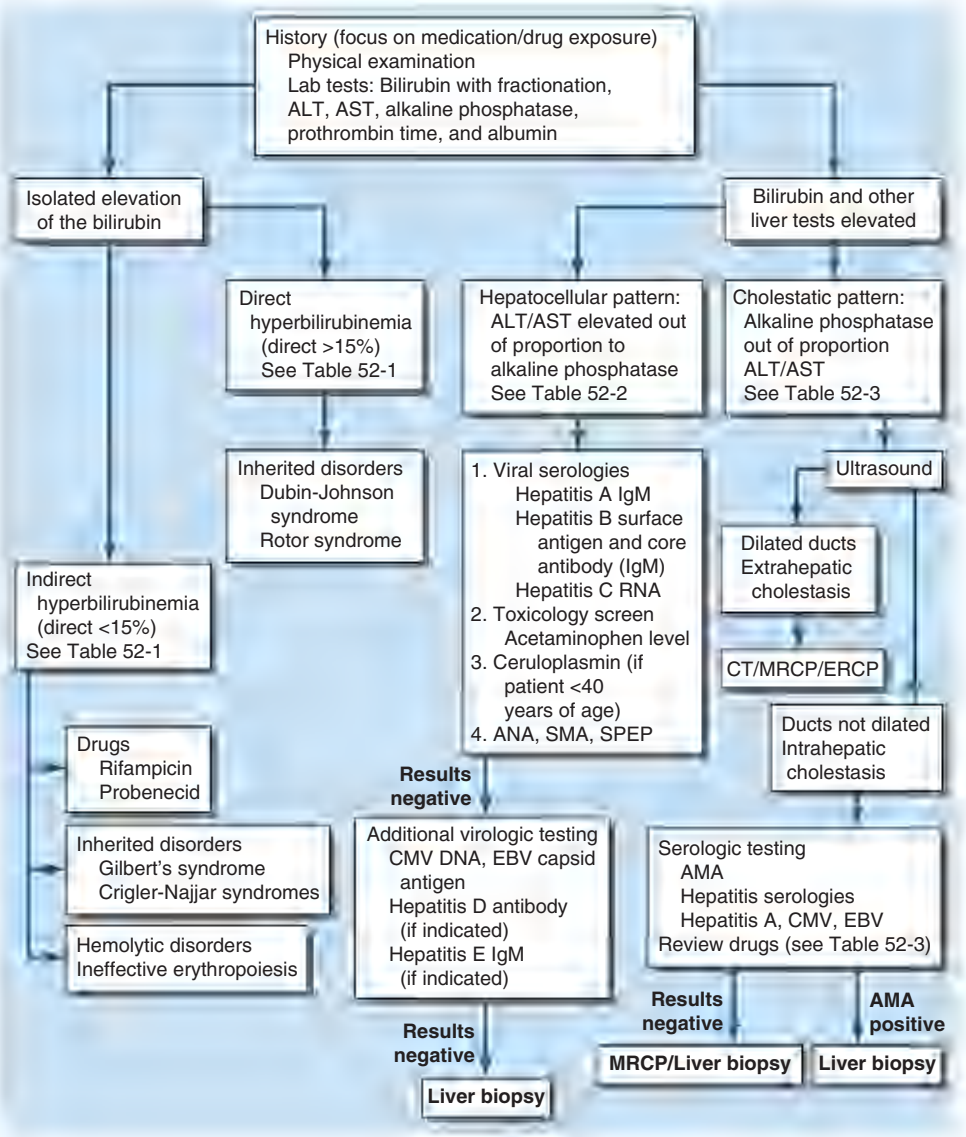

FIGURE 52-1 Evaluation of the patient with jaundice. ALT, alanine aminotransferase; AMA, antimitochondrial antibody; ANA, antinuclear antibody; AST, aspartate aminotransferase; CMV, cytomegalovirus; EBV, Epstein-Barr virus; ERCP, endoscopic retrograde cholangiopancreatography; LKM, liver-kidney microsomal antibody; MRCP, magnetic resonance cholangiopancreatography; SMA, smooth-muscle antibody; SPEP, serum protein electrophoresis.

TABLE 52-1 Causes of Isolated Hyperbilirubinemia

I. Indirect hyperbilirubinemia
- A. Hemolytic disorders
- B. Ineffective erythropoiesis
- C. Increased bilirubin production
  1. Massive blood transfusion
  2. Resorption of hematoma
- D. Drugs
  1. Rifampin
  2. Probenecid
  3. Atazanavir
  4. Antibiotics—cephalosporins and penicillins
- E. Inherited conditions
  1. Crigler-Najjar types I and II
  2. Gilbert's syndrome

II. Direct hyperbilirubinemia (inherited conditions)
- A. Dubin-Johnson syndrome
- B. Rotor syndrome

spherocytosis, sickle cell anemia, thalassemia, and deficiency of red cell enzymes such as pyruvate kinase and glucose-6-phosphate dehydrogenase. In these conditions, the serum bilirubin level rarely exceeds 86 μmol/L (5 mg/dL). Higher levels may occur when there is coexistent renal or hepatocellular dysfunction or in acute hemolysis, such as a sickle cell crisis. In evaluating jaundice in patients with chronic hemolysis, it is important to remember the high incidence of pigmented (calcium bilirubinate) gallstones found in these patients, which increases the likelihood of choledocholithiasis as an alternative explanation for hyperbilirubinemia.

Acquired hemolytic disorders include microangiopathic hemolytic anemia (e.g., hemolytic-uremic syndrome), paroxysmal nocturnal hemoglobinuria, spur cell anemia, immune hemolysis, and parasitic infections (e.g., malaria and babesiosis). Ineffective erythropoiesis occurs in cobalamin, folate, and iron deficiencies. Resorption of hematomas and massive blood transfusions both can result in increased hemoglobin release and overproduction of bilirubin.

In the absence of hemolysis, the physician should consider a problem with the hepatic uptake or conjugation of bilirubin. Certain drugs, including rifampin and probenecid, may cause unconjugated hyperbilirubinemia by diminishing hepatic uptake of bilirubin. Impaired bilirubin conjugation occurs in three genetic conditions: Crigler-Najjar syndrome types I and II and Gilbert's syndrome. *Crigler-Najjar type I* is an exceptionally rare condition found in neonates and characterized by severe jaundice (bilirubin >342 μmol/L [>20 mg/dL]) and neurologic impairment due to kernicterus, frequently leading to death in infancy or childhood. These patients have a complete absence of bilirubin UDPGT activity; are totally unable to conjugate bilirubin; and hence cannot excrete it.

Crigler-Najjar type II is somewhat more common than type I. Patients live into adulthood with serum bilirubin levels of 103–428 μmol/L (6–25 mg/dL). In these patients, mutations in the bilirubin *UDPGT* gene cause the reduction—typically ≤10%—of the enzyme's activity. Bilirubin UDPGT activity can be induced by the administration of phenobarbital, which can reduce serum bilirubin levels in these patients. Despite marked jaundice, these patients usually survive into adulthood, although they may be susceptible to kernicterus under the stress of concurrent illness or surgery.

Gilbert's syndrome is also marked by the impaired conjugation of bilirubin due to reduced bilirubin UDPGT activity (typically 10–35% of normal). Patients with Gilbert's syndrome have mild unconjugated hyperbilirubinemia, with serum levels almost always <103 μmol/L (6 mg/dL). The serum levels may fluctuate, and jaundice is often identified only during periods of stress, concurrent illness, alcohol use, or fasting. Unlike both Crigler-Najjar syndromes, Gilbert's syndrome is very common. The reported incidence is 3–7% of the population, with males predominating over females by a ratio of 1.5–7:1. The mildly elevated indirect serum hyperbilirubinemia seen in Gilbert's syndrome is generally of no clinical consequence and may actually have protective effects.

Conjugated Hyperbilirubinemia Elevated conjugated hyperbilirubinemia is found in two rare inherited conditions: *Dubin-Johnson syndrome* and *Rotor syndrome* (Table 52-1). Patients with either condition present with asymptomatic jaundice. The defect in Dubin-Johnson syndrome is the presence of mutations in the gene for MRP2. These patients have altered excretion of bilirubin into the bile ducts. Rotor syndrome is caused by a deficiency of the major hepatic drug reuptake transporters OATP1B1 and OATP1B3. Differentiating between these syndromes is possible but is clinically unnecessary due to their benign nature.

ELEVATION OF SERUM BILIRUBIN WITH OTHER LIVER TEST ABNORMALITIES

The remainder of this chapter will focus on the evaluation of patients with conjugated hyperbilirubinemia in the setting of other liver test abnormalities. This group of patients can be divided into those with a primary hepatocellular process and those with intra- or extrahepatic cholestasis. This distinction, which is based on the history and physical examination as well as the pattern of liver test abnormalities, guides the clinician's evaluation (Fig. 52-1).

History A complete medical history is perhaps the single most important part of the evaluation of the patient with unexplained jaundice. Important considerations include the use of or exposure to any chemical or medication, whether physician-prescribed, over-the-counter, complementary, or alternative medicines (e.g., herbal and vitamin preparations) or other drugs such as anabolic steroids. The patient should be carefully questioned about possible parenteral exposures, including transfusions, intravenous and intranasal drug use, tattooing, and sexual activity. Other important points include recent travel history; exposure to people with jaundice; exposure to possibly contaminated foods; occupational exposure to hepatotoxins; alcohol consumption; the duration of jaundice; and the presence of any accompanying signs and symptoms, such as arthralgias, myalgias, rash, anorexia, weight loss, abdominal pain, fever, pruritus, and changes in the urine and stool. While none of the latter manifestations is specific for any one condition, any of them can suggest a diagnosis. A history of arthralgias and myalgias predating jaundice suggests hepatitis, either viral or drug related. Jaundice associated with the sudden onset of severe right-upper-quadrant pain and shaking chills suggests choledocholithiasis and ascending cholangitis.

Physical Examination The general assessment should include evaluation of the patient's nutritional status. Temporal and proximal muscle wasting suggests long-standing disease such as pancreatic cancer or cirrhosis. Stigmata of chronic liver disease, including spider nevi, palmar erythema, gynecomastia, caput medusae, Dupuytren's contractures, parotid gland enlargement, and testicular atrophy, are commonly seen in advanced alcohol-related cirrhosis and occasionally in other types of cirrhosis. An enlarged left supraclavicular node (Virchow's node) or a periumbilical nodule (Sister Mary Joseph's nodule) suggests an abdominal malignancy. Jugular venous distention, a sign of right-sided heart failure, and/or a pulsatile liver suggest hepatic congestion. Right pleural effusion even in the absence of clinically apparent ascites may be seen in advanced cirrhosis.

The abdominal examination should focus on the size and consistency of the liver, on whether the spleen is palpable and hence enlarged, and on whether ascites is present. Patients with cirrhosis may have an enlarged left lobe of the liver, which is felt below the xiphoid, and an enlarged spleen. A grossly enlarged nodular liver

or an obvious abdominal mass suggests malignancy. An enlarged tender liver could signify viral or alcoholic hepatitis; an infiltrative process such as amyloidosis; or, less often, an acutely congested liver secondary to right-sided heart failure. Severe right-upper-quadrant tenderness with respiratory arrest on inspiration (Murphy's sign) suggests cholecystitis. Ascites in the presence of jaundice suggests either cirrhosis or malignancy with peritoneal spread.

Laboratory Tests A battery of tests are helpful in the initial evaluation of a patient with unexplained jaundice. These include total and direct serum bilirubin measurement; determination of serum aminotransferase, alkaline phosphatase, and albumin concentrations; and prothrombin time tests. Enzyme tests (alanine aminotransferase [ALT], aspartate aminotransferase [AST], and alkaline phosphatase [ALP]) are helpful in differentiating between a hepatocellular process and a cholestatic process (**Table 348-1**; Fig. 52-1)—a critical step in determining what additional workup is indicated. Patients with a hepatocellular process generally have a rise in the aminotransferases that is disproportionate to that in ALP, whereas patients with a cholestatic process have a rise in ALP that is disproportionate to that of the aminotransferases. The serum bilirubin can be prominently elevated in both hepatocellular and cholestatic conditions and therefore is not necessarily helpful in differentiating between the two.

In addition to enzyme tests, all jaundiced patients should have additional blood tests—specifically, an albumin level and a prothrombin time—to assess liver function. A low albumin level suggests a chronic process such as cirrhosis or cancer. A normal albumin level is suggestive of a more acute process such as viral hepatitis or choledocholithiasis. An elevated prothrombin time indicates either vitamin K deficiency due to prolonged jaundice and malabsorption of vitamin K or significant hepatocellular dysfunction. The failure of the prothrombin time to correct with parenteral administration of vitamin K indicates severe hepatocellular injury.

The results of the bilirubin, enzyme, albumin, and prothrombin time tests will usually indicate whether a jaundiced patient has a hepatocellular or a cholestatic disease and offer some indication of the duration and severity of the disease. The causes and evaluations of hepatocellular and cholestatic diseases are quite different.

Hepatocellular Conditions Hepatocellular diseases that can cause jaundice include viral hepatitis, drug or environmental toxicity, alcohol, and end-stage cirrhosis from any cause **(Table 52-2)**. Wilson's disease occurs primarily in young adults and usually between the ages of 3 and 55. Autoimmune hepatitis is typically seen in young to middle-aged women but may affect men and women of any age. Alcoholic hepatitis can be differentiated from viral and toxin-related hepatitis by the pattern of the aminotransferases: patients with alcoholic hepatitis typically have an AST-to-ALT ratio of at least 2:1, and the AST level rarely exceeds 300 U/L. Patients with acute viral hepatitis and toxin-related injury severe enough to produce jaundice typically have aminotransferase levels >500 U/L, with the ALT greater than or equal to the AST. While ALT and AST values <8 times normal may be seen in either hepatocellular or cholestatic liver disease, values 25 times normal or higher are seen primarily in acute hepatocellular diseases. Patients with jaundice from cirrhosis can have normal or only slightly elevated aminotransferase levels.

When the clinician determines that a patient has a hepatocellular disease, appropriate testing for acute viral hepatitis includes a hepatitis A IgM antibody assay, a hepatitis B surface antigen and core IgM antibody assay, a hepatitis C viral RNA test, and, depending on the circumstances, a hepatitis E IgM antibody assay. The hepatitis C antibody can take up to 6 weeks to become detectable, making it an unreliable test if acute hepatitis C is suspected. Studies for hepatitis D, Epstein-Barr virus (EBV), and cytomegalovirus (CMV) may also be indicated. Ceruloplasmin is the initial screening test for Wilson's disease. Testing for autoimmune hepatitis usually includes antinuclear antibody and anti–smooth muscle antibody assays and measurement of specific immunoglobulins.

Drug-induced hepatocellular injury can be classified as either predictable or unpredictable. Predictable drug reactions are dose-dependent and affect all patients who ingest a toxic dose of the drug in question. The classic example is acetaminophen hepatotoxicity. Unpredictable or idiosyncratic drug reactions are not dose-dependent and occur in a minority of patients. A great number of drugs can cause idiosyncratic hepatic injury. Environmental toxins are also an important cause of hepatocellular injury. Examples include industrial chemicals such as vinyl chloride, herbal preparations containing pyrrolizidine alkaloids (Jamaica bush tea) or kava, and the mushrooms *Amanita phalloides* and *A. verna*, which contain highly hepatotoxic amatoxins.

TABLE 52-2 Hepatocellular Conditions That May Produce Jaundice

Viral hepatitis
Hepatitis A, B, C, D, and E
Epstein-Barr virus
Cytomegalovirus
Herpes simplex virus
Alcoholic hepatitis
Chronic liver disease and cirrhosis
Drug toxicity
Predictable, dose-dependent (e.g., acetaminophen)
Unpredictable, idiosyncratic (e.g., isoniazid)
Environmental toxins
Vinyl chloride
Jamaica bush tea—pyrrolizidine alkaloids
Kava kava
Wild mushrooms—*Amanita phalloides, A. verna*
Wilson's disease
Autoimmune hepatitis

Cholestatic Conditions When the pattern of the liver tests suggests a cholestatic disorder, the first step is to determine whether it is intra- or extrahepatic cholestasis (Fig. 52-1). Distinguishing intrahepatic from extrahepatic cholestasis may be difficult. History, physical examination, and laboratory tests often are not helpful. The next appropriate test is an ultrasound. The ultrasound is inexpensive, does not expose the patient to ionizing radiation, and can detect dilation of the intra- and extrahepatic biliary tree with a high degree of sensitivity and specificity. The absence of biliary dilation suggests intrahepatic cholestasis, while its presence indicates extrahepatic cholestasis. False-negative results occur in patients with partial obstruction of the common bile duct or in patients with cirrhosis or primary sclerosing cholangitis (PSC), in which scarring prevents the intrahepatic ducts from dilating.

Although ultrasonography may indicate extrahepatic cholestasis, it rarely identifies the site or cause of obstruction. The distal common bile duct is a particularly difficult area to visualize by ultrasound because of overlying bowel gas. Appropriate next tests include computed tomography (CT), magnetic resonance cholangiopancreatography (MRCP), endoscopic retrograde cholangiopancreatography (ERCP), percutaneous transhepatic cholangiography (PTC), and endoscopic ultrasound (EUS). CT and MRCP are better than ultrasonography for assessing the head of the pancreas and for identifying choledocholithiasis in the distal common bile duct, particularly when the ducts are not dilated. ERCP is the "gold standard" for identifying choledocholithiasis. Beyond its diagnostic capabilities, ERCP allows therapeutic interventions, including the removal of common bile duct stones and the placement of stents. PTC can provide the same information as ERCP and also allows for intervention in patients in whom ERCP is unsuccessful due to

proximal biliary obstruction or altered gastrointestinal anatomy. MRCP has replaced ERCP as the initial diagnostic test in most cases. EUS displays sensitivity and specificity comparable to that of MRCP in the detection of bile duct obstruction and allows biopsy of suspected malignant lesions.

In patients with apparent *intrahepatic cholestasis*, the diagnosis is often made by serologic testing in combination with a liver biopsy. The list of possible causes of intrahepatic cholestasis is long and varied **(Table 52-3)**. A number of conditions that typically cause a hepatocellular pattern of injury can also present as a cholestatic variant. Both hepatitis B and C viruses can cause cholestatic hepatitis (fibrosing cholestatic hepatitis). This disease variant has been reported in patients who have undergone solid organ transplantation. The availability of direct-acting antiviral drugs has reduced the incidence of this condition. Hepatitis A and E, alcoholic hepatitis, and EBV or CMV infections may also present as cholestatic liver disease.

TABLE 52-3 Cholestatic Conditions That May Produce Jaundice

I. Intrahepatic
- A. Viral hepatitis
  1. Fibrosing cholestatic hepatitis—hepatitis B and C
  2. Hepatitis A, Epstein-Barr virus infection, cytomegalovirus infection
- B. Alcoholic hepatitis
- C. Drug toxicity
  1. Pure cholestasis—anabolic and contraceptive steroids
  2. Cholestatic hepatitis—chlorpromazine, erythromycin estolate
  3. Chronic cholestasis—chlorpromazine and prochlorperazine
- D. Primary biliary cholangitis
- E. Sclerosing cholangitis, primary and secondary
- F. Vanishing bile duct syndrome
  1. Chronic rejection of liver transplants
  2. Sarcoidosis
  3. Drugs
- G. Congestive hepatopathy and ischemic hepatitis
- H. Inherited conditions
  1. Progressive familial intrahepatic cholestasis
  2. Benign recurrent intrahepatic cholestasis
- I. Cholestasis of pregnancy
- J. Total parenteral nutrition
- K. Nonhepatobiliary sepsis
- L. Benign postoperative cholestasis
- M. Paraneoplastic syndrome
- N. Veno-occlusive disease
- O. Graft-versus-host disease
- P. Infiltrative disease
  1. Tuberculosis
  2. Lymphoma
  3. Amyloidosis
- Q. Infections
  1. Malaria
  2. Leptospirosis

II. Extrahepatic
- A. Malignant
  1. Cholangiocarcinoma
  2. Pancreatic cancer
  3. Gallbladder cancer
  4. Ampullary cancer
  5. Malignant involvement of the porta hepatis lymph nodes
- B. Benign
  1. Choledocholithiasis
  2. Postoperative biliary strictures
  3. Primary sclerosing cholangitis
  4. Chronic pancreatitis
  5. AIDS cholangiopathy
  6. Mirizzi's syndrome
  7. Parasitic disease (ascariasis)

Drugs may cause intrahepatic cholestasis that is usually reversible after discontinuation of the offending agent, although it may take many months for cholestasis to resolve. Drugs most commonly associated with cholestasis are the anabolic and contraceptive steroids. Cholestatic hepatitis has been reported with chlorpromazine, imipramine, tolbutamide, sulindac, cimetidine, and erythromycin estolate. It also occurs in patients taking trimethoprim; sulfamethoxazole; and penicillin-based antibiotics such as ampicillin, dicloxacillin, and clavulanic acid. Rarely, cholestasis may be chronic and associated with progressive fibrosis despite early discontinuation of the offending drug. Chronic cholestasis has been associated with chlorpromazine and prochlorperazine.

Primary biliary cholangitis is an autoimmune disease predominantly affecting women and characterized by progressive destruction of interlobular bile ducts. The diagnosis is made by the detection of antimitochondrial antibody, which is found in 95% of patients. *PSC* is characterized by the destruction and fibrosis of larger bile ducts. The diagnosis of PSC is made with cholangiography (MRCP), which demonstrates the pathognomonic segmental strictures. Approximately 75% of patients with PSC also have inflammatory bowel disease.

The *vanishing bile duct syndrome* and *adult bile ductopenia* are rare conditions in which a decreased number of bile ducts are seen in liver biopsy specimens. This histologic picture is also seen in patients who develop chronic rejection after liver transplantation and in those who develop graft-versus-host disease after bone marrow transplantation. Vanishing bile duct syndrome also occurs in rare cases of sarcoidosis, in patients taking certain drugs (including chlorpromazine), and idiopathically.

There are also familial forms of intrahepatic cholestasis. The familial intrahepatic cholestatic syndromes include *progressive familial intrahepatic cholestasis* (PFIC) *types 1–3* and *benign recurrent intrahepatic cholestasis* (BRIC) *types 1 and 2*. BRIC is characterized by episodic attacks of pruritus, cholestasis, and jaundice beginning at any age, which can be debilitating but do not lead to chronic liver disease. Serum bile acids are elevated during episodes, but serum γ-glutamyltransferase (γ-GT) activity is normal. PFIC disorders begin at childhood and are progressive in nature. All three types of PFIC are associated with progressive cholestasis, elevated levels of serum bile acids, and similar phenotypes but different genetic mutations. Only type 3 PFIC is associated with high levels of γ-GT. *Cholestasis of pregnancy* occurs in the second and third trimesters and resolves after delivery. Its cause remains unknown, but the condition is probably inherited, and cholestasis can be triggered by estrogen administration.

Other causes of intrahepatic cholestasis include total parenteral nutrition (TPN); nonhepatobiliary sepsis; benign postoperative cholestasis; and a paraneoplastic syndrome associated with a number of different malignancies, including Hodgkin's disease, medullary thyroid cancer, renal cell cancer, renal sarcoma, T-cell lymphoma, prostate cancer, and several gastrointestinal malignancies. In patients developing cholestasis in the intensive care unit, the major considerations should be sepsis, ischemic hepatitis ("shock liver"), and TPN-related jaundice. Jaundice occurring after bone marrow transplantation is most likely due to veno-occlusive disease (also called sinusoidal obstruction syndrome) or graft-versus-host disease. In addition to hemolysis, sickle cell disease may cause intrahepatic and extrahepatic cholestasis. Jaundice is a late finding in heart failure caused by hepatic congestion and hepatocellular hypoxia. Ischemic hepatitis is a distinct entity of acute hypoperfusion characterized by an acute and dramatic elevation in the serum aminotransferases followed by a gradual peak in serum bilirubin.

Jaundice with associated liver dysfunction can be seen in severe cases of *Plasmodium falciparum* malaria. The jaundice in these cases is due to a combination of indirect hyperbilirubinemia from hemolysis and both cholestatic and hepatocellular jaundice. Weil's disease, a severe presentation of leptospirosis, is marked by jaundice with renal failure, fever, headache, and muscle pain.

Causes of *extrahepatic cholestasis* can be split into malignant and benign (Table 52-3). Malignant causes include pancreatic, gallbladder, and ampullary cancers as well as cholangiocarcinoma. This last malignancy is most commonly associated with PSC and is exceptionally difficult to diagnose because its appearance is often identical to that of PSC. Pancreatic and gallbladder tumors as well as cholangiocarcinoma are rarely resectable at the time of diagnosis and have poor prognoses. Ampullary carcinoma has the highest surgical cure rate of all the tumors that present as painless jaundice. Hilar lymphadenopathy due to metastases from other cancers may cause obstruction of the extrahepatic biliary tree.

Choledocholithiasis is the most common cause of extrahepatic cholestasis. The clinical presentation can range from mild right-upper-quadrant discomfort with only minimal elevations of enzyme test values to ascending cholangitis with jaundice, sepsis, and circulatory collapse. PSC may occur with clinically important strictures limited to the extrahepatic biliary tree. IgG4-associated cholangitis is marked by stricturing of the biliary tree. It is critical that the clinician differentiate this condition from PSC as it is responsive to glucocorticoid therapy. In rare instances, chronic pancreatitis causes strictures of the distal common bile duct, where it passes through the head of the pancreas. AIDS cholangiopathy is a condition that is usually due to infection of the bile duct epithelium with CMV or cryptosporidia and has a cholangiographic appearance similar to that of PSC. The affected patients usually present with greatly elevated serum alkaline phosphatase levels (mean, 800 IU/L), but the bilirubin level is often near normal. These patients do not typically present with jaundice. Its incidence has dropped dramatically since the introduction of potent antiretrovirals in the 1990s.

GLOBAL CONSIDERATIONS

While extrahepatic biliary obstruction and drugs are common causes of new-onset jaundice in developed countries, infections remain the leading cause in developing countries. Liver involvement and jaundice are observed with numerous infections, particularly malaria, babesiosis, severe leptospirosis, infections due to *Mycobacterium tuberculosis* and the *Mycobacterium avium* complex, typhoid fever, infection with hepatitis viruses A–E, EBV, CMV, viral hemorrhagic fevers including Ebola virus, late phases of yellow fever, dengue fever, schistosomiasis, fascioliasis, clonorchiasis, opisthorchiasis, ascariasis, echinococcosis, hepatosplenic candidiasis, disseminated histoplasmosis, cryptococcosis, coccidioidomycosis, ehrlichiosis, chronic Q fever, yersiniosis, brucellosis, syphilis, and leprosy. Bacterial infections that do not necessarily involve the liver and bile ducts may also lead to jaundice, as in cholestasis of sepsis. The presence of fever or abdominal pain suggests concurrent infection, sepsis, or complications from gallstones. The development of encephalopathy and coagulopathy in a jaundiced patient with no preexisting liver disease signifies acute liver failure, which warrants urgent liver transplant evaluation.

FURTHER READING

Erlinger S et al: Inherited disorders of bilirubin transport and conjugation: New insights into molecular mechanisms and consequences. Gastroenterology 146:1625, 2014.

Wolkoff AW et al: Bilirubin metabolism and jaundice, in *Schiff's Diseases of the Liver*, 11th ed, Schiff ER et al (eds). Oxford, UK, John Wiley & Sons, Ltd, 2012, pp 120–150.

53 Abdominal Swelling and Ascites

Lawrence S. Friedman

ABDOMINAL SWELLING

Abdominal swelling is a manifestation of numerous diseases. Patients may complain of *bloating* or abdominal fullness and may note increasing abdominal girth on the basis of increased clothing or belt size. Abdominal discomfort is often reported, but pain is less frequent. When abdominal pain does accompany swelling, it is frequently the result of an intraabdominal infection, peritonitis, or pancreatitis. Patients with abdominal distention from *ascites* (fluid in the abdomen) may report the new onset of an inguinal or umbilical hernia. Dyspnea may result from pressure against the diaphragm and the inability to expand the lungs fully.

CAUSES

The causes of abdominal swelling can be remembered conveniently as the *six Fs*: flatus, fat, fluid, fetus, feces, or a "fatal growth" (often a neoplasm).

Flatus Abdominal swelling may be the result of increased intestinal gas. The normal small intestine contains ~200 mL of gas made up of nitrogen, oxygen, carbon dioxide, hydrogen, and methane. Nitrogen and oxygen are consumed (swallowed), whereas carbon dioxide, hydrogen, and methane are produced intraluminally by bacterial fermentation. Increased intestinal gas can occur in a number of conditions. *Aerophagia*, the swallowing of air, can result in increased amounts of oxygen and nitrogen in the small intestine and lead to abdominal swelling. Aerophagia typically results from gulping food; chewing gum; smoking; or as a response to anxiety, which can lead to repetitive belching. Celiac disease, or gluten-sensitive enteropathy, and gastroparesis may be associated with bloating and distention. In some cases, increased intestinal gas is the consequence of bacterial metabolism of excess fermentable substances such as lactose, fructose, and other fermentable oligosaccharides, disaccharides, monosaccharides, and polyols (FODMAPs), which can lead to production of hydrogen, carbon dioxide, or methane, as occurs also in small intestinal bacterial overgrowth or intestinal methanogen overgrowth. In some persons, particularly those with irritable bowel syndrome and bloating, the subjective sense of abdominal pressure is attributable to impaired intestinal transit of gas (rather than increased gas volume) or to visceral hypersensitivity. Abdominal *distention*—an objective increase in girth—may result from a lack of coordination between diaphragmatic contraction and anterior abdominal wall relaxation ("abdominophrenic dyssynergia"), a response in some cases to intraluminal bowel stimuli; dietary alterations, manipulation of the intestinal microbiota, or biofeedback may be effective therapy. Occasionally, increased lumbar lordosis accounts for apparent abdominal distention.

Fat Weight gain with an increase in abdominal fat can result in an increase in abdominal girth and can be perceived as abdominal swelling. Abdominal fat may be caused by an imbalance between caloric intake and energy expenditure associated with a poor diet and sedentary lifestyle; it also can be a manifestation of certain diseases, such as Cushing's syndrome. Excess abdominal fat has been associated with an increased risk of insulin resistance and cardiovascular disease.

Fluid The accumulation of fluid within the abdominal cavity (ascites) often results in abdominal distention and is discussed in detail below. Grade 1 ascites is detectable only by ultrasonography; grade 2 ascites is detectable by physical examination; and grade 3 ascites results in marked abdominal distention.

Fetus Pregnancy results in increased abdominal girth. Typically, an increase in abdominal size is first noted at 12–14 weeks of gestation,