reactivation is advised in the majority of patients with hematologic malignancies on active therapy. In patients with AML receiving induction or reinduction chemotherapy, prophylaxis with posaconazole should be included. Mold-active prophylaxis is also recommended in patients with significant GVHD. PJP prophylaxis is recommended for patients with severe T cell impairment (TMP-SMX is preferred). Examples include standard induction chemotherapy for acute lymphoblastic leukemia that involves systemic corticosteroids, prolonged corticosteroids (described above), use of purine analogues (e.g., cladribine-containing regimens), and GVHD. Pneumococcal prophylaxis (e.g., with penicillin) should be considered for persons with asplenia or chronic GVHD (described above).

VACCINATION

Patients with cancer should receive all recommended non-live vaccines based on their approved indications. Yearly recommendations regarding COVID-19 and influenza vaccines should be followed. Patients with solid tumors in general mount greater antibody titers than patients with hematologic malignancies, especially if they have received B cell–depleting agents (e.g., rituximab, BTK inhibitors). However, vaccination is still recommended for such patients with the rationale that they may derive some protective benefit even if suboptimal. We also stress vaccination of household members, caretakers, and other close contacts to prevent them from viral infection and transmission to the patient.

Live vaccines should not be given to immunocompromised persons. However, household members including children should receive age-appropriate vaccines, including live vaccines such as MMR and varicella. If the child develops a rash following MMR or varicella vaccination, contact with the cancer patient should be limited until the rash resolves.

FURTHER READING

Kamboj M et al: Vaccination of adults with cancer: ASCO guideline. J Clin Oncol 42:1699, 2024.

Lehrnbecher T et al: Guideline for the management of fever and neutropenia in pediatric patients with cancer and hematopoietic cell transplantation recipients: 2023 update. J Clin Oncol 41:1774, 2023.

Maertens J et al: Empiric vs preemptive antifungal strategy in high-risk neutropenic patients on fluconazole prophylaxis: A randomized trial of the European Organization for Research and Treatment of Cancer. Clin Infect Dis 76:674, 2023.

Martinez-Nadal G et al: Inappropriate empirical antibiotic treatment in high-risk neutropenic patients with bacteremia in the era of multidrug resistance. Clin Infect Dis 70:1068, 2020.

Maschmeyer G et al: Infectious complications of targeted drugs and biotherapies in acute leukemia. Clinical practice guidelines by the European Conference on Infections in Leukemia (ECIL), a joint venture of the European Group for Blood and Marrow Transplantation (EBMT), the European Organization for Research and Treatment of Cancer (EORTC), the International Immunocompromised Host Society (ICHS) and the European Leukemia Net (ELN). Leukemia 36: 1215, 2022.

Stern A et al: Early discontinuation of antibiotics for febrile neutropenia versus continuation until neutropenia resolution in people with cancer. Cochrane Database Syst Rev 1:CD012184, 2019.

Taplitz RA et al: Antimicrobial prophylaxis for adult patients with cancer-related immunosuppression: ASCO and IDSA clinical practice guideline update. J Clin Oncol 36:3043, 2018.

Zimmer AJ et al: Bloodstream infections in hematologic malignancy patients with fever and neutropenia: Are empirical antibiotic therapies in the United States still effective? Open Forum Infect Dis 9:ofac240, 2022.

WEBSITE

NCCN Guidelines. Prevention and Treatment of Cancer-Related Infections. Version 2.2023. *https://www.nccn.org/guidelines/guidelines-detail?category=3&id=1457*

80 Oncologic Emergencies

Rasim Gucalp, Janice P. Dutcher

Emergencies in patients with cancer may be classified into three groups: pressure or obstruction caused by a space-occupying lesion, metabolic or hormonal problems (paraneoplastic syndromes, **Chap. 98**), and treatment-related complications.

STRUCTURAL-OBSTRUCTIVE ONCOLOGIC EMERGENCIES

SUPERIOR VENA CAVA SYNDROME

Superior vena cava syndrome (SVCS) is the clinical manifestation of superior vena cava (SVC) obstruction, with severe reduction in venous return from the head, neck, and upper extremities. Malignant tumors, such as lung cancer, lymphoma, and metastatic tumors, are responsible for the majority of SVCS cases. With the expanding use of intravascular devices (e.g., permanent central venous access catheters, pacemaker/defibrillator leads), the prevalence of benign causes of SVCS is now increasing, accounting for at least 40% of cases. Lung cancer, particularly of small-cell and squamous cell histologies, accounts for ~85% of all cases of malignant origin. In young adults, malignant lymphoma is a leading cause of SVCS. Hodgkin's lymphoma involves the mediastinum more commonly than other lymphomas but rarely causes SVCS. When SVCS is noted in a young man with a mediastinal mass, the differential diagnosis is lymphoma versus primary mediastinal germ cell tumor. Metastatic cancers to the mediastinal lymph nodes, such as testicular and breast carcinomas, account for a small proportion of cases. Other causes include benign tumors, aortic aneurysm, thyromegaly, thrombosis, and fibrosing mediastinitis from prior irradiation, histoplasmosis, or Behçet's syndrome. SVCS as the initial manifestation of Behçet's syndrome may be due to inflammation of the SVC associated with thrombosis.

Patients with SVCS usually present with neck and facial swelling (especially around the eyes), dyspnea, and cough. Other symptoms include hoarseness, tongue swelling, headaches, nasal congestion, epistaxis, hemoptysis, dysphagia, pain, dizziness, syncope, and lethargy. Bending forward or lying down may aggravate the symptoms. The characteristic physical findings are dilated neck veins; an increased number of collateral veins covering the anterior chest wall; cyanosis; and edema of the face, arms, and chest. Facial swelling and plethora are typically exacerbated when the patient is supine. More severe cases include proptosis, glossal and laryngeal edema, and obtundation. The clinical picture is milder if the obstruction is located above the azygos vein. Symptoms are usually progressive, but in some cases, they may improve as collateral circulation develops.

Signs and symptoms of cerebral and/or laryngeal edema, though rare, are associated with a poorer prognosis and require urgent evaluation. Seizures are more likely related to brain metastases than to cerebral edema from venous occlusion. Patients with small-cell lung cancer and SVCS have a higher incidence of brain metastases than those without SVCS.

Cardiorespiratory symptoms at rest, particularly with positional changes, suggest significant airway and vascular obstruction and limited physiologic reserve. Cardiac arrest or respiratory failure can occur, particularly in patients receiving sedatives or undergoing general anesthesia.

Rarely, esophageal varices may develop, particularly in the setting of SVC syndrome due to hemodialysis catheter. These are "downhill" varices based on the direction of blood flow from cephalad to caudad (in contrast to "uphill" varices associated with caudad to cephalad flow from portal hypertension). Variceal bleeding may be a late complication of chronic SVCS.

SVC obstruction may lead to bilateral breast edema with bilateral enlarged breasts. Unilateral breast dilation may be seen as a consequence of axillary or subclavian vein blockage.

The diagnosis of SVCS is a clinical one. The most significant chest radiographic finding is widening of the superior mediastinum, most commonly on the right side. Pleural effusion occurs in only 25% of patients, often on the right side. The majority of these effusions are exudative and occasionally chylous. However, a normal chest radiograph is still compatible with the diagnosis if other characteristic findings are present. Computed tomography (CT) provides the most reliable view of the mediastinal anatomy. The diagnosis of SVCS requires diminished or absent opacification of central venous structures with prominent collateral venous circulation. The focal hepatic hotspot on CT scan ("hot quadrate") sign suggests SVC obstruction, and it is caused by portosystemic venous shunting between the SVC and portal vein within liver. Magnetic resonance imaging (MRI) is increasingly being used to diagnose SVC obstruction with a 100% sensitivity and specificity, but dyspneic SVCS patients may have difficulty remaining supine for the entire imaging process. Invasive procedures, including bronchoscopy, percutaneous needle biopsy, mediastinoscopy, and even thoracotomy, can be performed by a skilled clinician without any major risk of bleeding. Endobronchial or esophageal ultrasound-guided needle aspiration may establish the diagnosis safely. For patients with a known cancer, a detailed workup usually is not necessary, and appropriate treatment may be started after obtaining a CT scan of the thorax. For those with no history of malignancy, a detailed evaluation is essential to rule out benign causes and determine a specific diagnosis to direct the appropriate therapy.

TREATMENT

Superior Vena Cava Syndrome

The one potentially life-threatening complication of a superior mediastinal mass is tracheal obstruction. Upper airway obstruction demands emergent therapy. Diuretics with a low-salt diet, head elevation, and oxygen may produce temporary symptomatic relief. Glucocorticoids have a limited role except in the setting of mediastinal lymphoma masses.

Radiation therapy is the primary treatment for SVCS caused by non-small-cell lung cancer and other metastatic solid tumors. Chemotherapy is effective when the underlying cancer is small-cell carcinoma of the lung, lymphoma, or germ cell tumor. SVCS recurs in 10–30% of patients; it may be palliated with the use of intravascular self-expanding stents **(Fig. 80-1)**. Endovascular therapy is more frequently used first, to provide rapid relief of clinical symptoms with reduced complications. Early stenting may be necessary in patients with severe symptoms, particularly cerebral or laryngeal edema or postural hypotension; however, the prompt increase in venous return after stenting may precipitate heart failure and pulmonary edema. Other complications of stent placement include hematoma at the insertion site, SVC perforation, stent migration in the right ventricle, stent fracture, and pulmonary embolism. Surgery may play role in treatment of SVCS secondary to nonmalignant mediastinal fibrosis.

Clinical improvement occurs in most patients, although this improvement may be due to the development of adequate collateral circulation. The mortality associated with SVCS does not relate to caval obstruction but rather to the underlying cause.

SVCS AND CENTRAL VENOUS CATHETERS IN ADULTS

The use of long-term central venous catheters has become common practice in patients with cancer. Major vessel thrombosis may occur. In these cases, catheter removal should be combined with anticoagulation to prevent embolization. SVCS in this setting, if detected early, can be treated by fibrinolytic therapy without sacrificing the catheter. When managing patients with transvenous lead-related SVC syndrome, anticoagulation, local and systemic thrombolytic therapy, and surgical intervention can be effective therapy in select patients. Endovascular stenting has also been shown to be safe and promising, with minimal procedural or clinical complications. The role of anticoagulation after SVC stent placement is controversial.

A

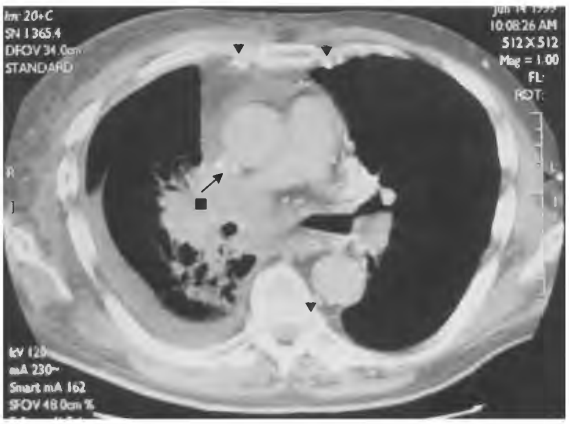

B

C

FIGURE 80-1 Superior vena cava syndrome (SVCS). ***A.*** Chest radiographs of a 59-year-old man with recurrent SVCS caused by non-small-cell lung cancer showing right paratracheal mass with right pleural effusion. ***B.*** Computed tomography of same patient demonstrating obstruction of the superior vena cava with thrombosis (*arrow*) by the lung cancer (*square*) and collaterals (*arrowheads*). ***C.*** Balloon angioplasty (*arrowhead*) with Wallstent (*arrow*) in same patient.

PERICARDIAL EFFUSION/TAMPONADE

Malignant pericardial disease is found at autopsy in 5–10% of patients with cancer, most frequently with lung cancer, breast cancer, leukemias, and lymphomas. Cardiac tamponade as the initial presentation of extrathoracic malignancy is rare. The origin is not malignancy in ~50% of cancer patients with symptomatic pericardial disease, but it can be related to irradiation; drug-induced pericarditis, including chemotherapeutic agents such as all-trans retinoic acid, arsenic trioxide, imatinib, and other abl kinase inhibitors; hypothyroidism; idiopathic pericarditis; infection; or autoimmune diseases. Pericardial disease has been associated with immune checkpoint inhibitors specifically in patients with advanced non-small-cell lung cancer. Two types of radiation pericarditis occur: an acute inflammatory, effusive pericarditis occurring within months of irradiation, which usually resolves spontaneously, and a chronic effusive pericarditis that may appear up to 20 years after radiation therapy and is accompanied by a thickened pericardium.

Most patients with pericardial metastasis are asymptomatic. However, the common symptoms are dyspnea, cough, chest pain, orthopnea, and weakness. Pleural effusion, sinus tachycardia, jugular venous distention, hepatomegaly, peripheral edema, and cyanosis are the most frequent physical findings. Relatively specific diagnostic findings, such as paradoxical pulse, diminished heart sounds, pulsus alternans (pulse waves alternating between those of greater and lesser amplitude with successive beats), and friction rub are less common than with nonmalignant pericardial disease. Chest radiographs and electrocardiogram (ECG) reveal abnormalities in 90% of patients, but half of these abnormalities are nonspecific. Echocardiography is the most helpful diagnostic test. Pericardial fluid may be serous, serosanguineous, or hemorrhagic, and cytologic examination of pericardial fluid is diagnostic in most patients. Measurements of tumor markers in the pericardial fluid are not helpful in the diagnosis of malignant pericardial fluid. Pericardioscopy with targeted pericardial and epicardial biopsy may differentiate neoplastic and benign pericardial disease. A combination of cytology, pericardial and epicardial biopsy, and guided pericardioscopy gives the best diagnostic yield. CT scan of chest may also reveal the presence of a concomitant thoracic neoplasm. Cancer patients with pericardial effusion containing malignant cells on cytology have a very poor survival.

TREATMENT

Pericardial Effusion/Tamponade

Pericardiocentesis with or without the introduction of sclerosing agents, the creation of a pericardial window, complete pericardial stripping, cardiac irradiation, and systemic chemotherapy are effective treatments. Acute pericardial tamponade with life-threatening hemodynamic instability requires immediate drainage of fluid. This can be quickly achieved by pericardiocentesis. The recurrence rate after percutaneous catheter drainage is ~20%. Sclerotherapy (pericardial instillation of bleomycin, mitomycin C, or tetracycline) may decrease recurrences. Alternatively, subxiphoid pericardiotomy can be performed in 45 min under local anesthesia. Thoracoscopic pericardial fenestration can be employed for benign causes; however, 60% of malignant pericardial effusions recur after this procedure. In a subset of patients, drainage of the pericardial effusion is paradoxically followed by worsening hemodynamic instability. This so-called "postoperative low cardiac output syndrome" occurs in up to 10% of patients undergoing surgical drainage and carries poor short-term survival.

INTESTINAL OBSTRUCTION

Intestinal obstruction and reobstruction are common problems in patients with advanced cancer, particularly colorectal or ovarian carcinoma. However, other cancers, such as lung or breast cancer and melanoma, can metastasize within the abdomen, leading to intestinal obstruction. Metastatic disease from colorectal, ovarian, pancreatic, gastric, and occasionally breast cancer can lead to peritoneal carcinomatosis, with infiltration of the omentum and peritoneal surface, thus limiting bowel motility. Typically, obstruction occurs at multiple sites in peritoneal carcinomatosis. Melanoma has a predilection to involve the small bowel; this involvement may be isolated, and resection may result in prolonged survival. Intestinal pseudoobstruction is caused by infiltration of the mesentery or bowel muscle by tumor, involvement of the celiac plexus, or paraneoplastic neuropathy in patients with small-cell lung cancer. Paraneoplastic neuropathy is associated with IgG antibodies reactive to neurons of the myenteric and submucosal plexuses of the jejunum and stomach. Ovarian cancer can lead to authentic luminal obstruction or to pseudoobstruction that results when circumferential invasion of a bowel segment arrests the forward progression of peristaltic contractions.

The onset of obstruction is usually insidious. Pain is the most common symptom and is usually colicky in nature. Pain can also be due to abdominal distention, tumor masses, or hepatomegaly. Vomiting can be intermittent or continuous. Patients with complete obstruction usually have constipation. Physical examination may reveal abdominal distention with tympany, ascites, visible peristalsis, high-pitched bowel sounds, and tumor masses. Erect plain abdominal films may reveal multiple air-fluid levels and dilation of the small or large bowel. Acute cecal dilation to >12–14 cm is considered a surgical emergency because of the high likelihood of rupture. CT scan is useful in defining the extent of disease and the exact nature of the obstruction and differentiating benign from malignant causes of obstruction in patients who have undergone surgery for malignancy. Malignant obstruction is suggested by a mass at the site of obstruction or prior surgery, adenopathy, or an abrupt transition zone and irregular bowel thickening at the obstruction site. Benign obstruction is more likely when CT shows mesenteric vascular changes, a large volume of ascites, or a smooth transition zone and smooth bowel thickening at the obstruction site. In challenging patients with obstructive symptoms, particularly low-grade small-bowel obstruction (SBO), CT enteroclysis often can help establish the diagnosis by providing distention of small-bowel loops. In this technique, water-soluble contrast is infused through a nasoenteric tube into the duodenum or proximal small bowel followed by CT images. The prognosis for the patient with cancer who develops intestinal obstruction is poor; median survival is 3–4 months. About 25–30% of patients are found to have intestinal obstruction due to causes other than cancer. Adhesions from previous operations are a common benign cause. Ileus induced by vinca alkaloids, narcotics, or other drugs is another reversible cause.

TREATMENT

Intestinal Obstruction

The management of intestinal obstruction in patients with advanced malignancy depends on the extent of the underlying malignancy, options for further antineoplastic therapy, estimated life expectancy, the functional status of the major organs, and the extent of the obstruction. The initial management should include surgical evaluation. Operation is not always successful and may lead to further complications with a substantial mortality rate (10–20%). Laparoscopy can diagnose and treat malignant bowel obstruction in some cases. Self-expanding metal stents placed in the gastric outlet, duodenum, proximal jejunum, colon, or rectum may palliate obstructive symptoms at those sites without major surgery. Patients known to have advanced intraabdominal malignancy should receive a prolonged course of conservative management, including nasogastric decompression. Percutaneous endoscopic or surgical gastrostomy tube placement is an option for palliation of nausea and vomiting, the so-called "venting gastrostomy." Treatment with antiemetics, antispasmodics, and analgesics may allow patients to remain outside the hospital. Octreotide may relieve obstructive symptoms through its inhibitory effect on gastrointestinal secretion. Glucocorticoids have anti-inflammatory effects and may help the resolution of bowel obstruction.

URINARY OBSTRUCTION

Urinary obstruction may occur in patients with prostatic or gynecologic malignancies, particularly cervical carcinoma; metastatic disease from other primary sites such as carcinomas of the breast, stomach, lung, colon, and pancreas; or lymphomas. Radiation therapy to pelvic tumors may cause fibrosis and subsequent ureteral obstruction. Bladder outlet obstruction is usually due to prostate and cervical cancers and may lead to bilateral hydronephrosis and renal failure.

Flank pain is the most common symptom. Persistent urinary tract infection, persistent proteinuria, or hematuria in patients with cancer should raise suspicion of ureteral obstruction. Total anuria and/or anuria alternating with polyuria may occur. A slow, continuous rise in the serum creatinine level necessitates immediate evaluation. Renal ultrasound is the safest and cheapest way to identify hydronephrosis. The function of an obstructed kidney can be evaluated by a nuclear scan. CT scan can reveal the point of obstruction and identify a retroperitoneal mass or adenopathy.

TREATMENT

Urinary Obstruction

Obstruction associated with flank pain, sepsis, or fistula formation is an indication for immediate palliative urinary diversion. Internal ureteral stents can be placed under local anesthesia. Percutaneous nephrostomy offers an alternative approach for drainage. The placement of a nephrostomy is associated with a significant rate of pyelonephritis. In the case of bladder outlet obstruction due to malignancy, a suprapubic cystostomy can be used for urinary drainage. An aggressive intervention with invasive approaches to improve the obstruction should be weighed against the likelihood of antitumor response, and the ability to reverse renal insufficiency should be evaluated.

MALIGNANT BILIARY OBSTRUCTION

This common clinical problem can be caused by a primary carcinoma arising in the pancreas, ampulla of Vater, bile duct, or liver or by metastatic disease to the periductal lymph nodes or liver parenchyma. The most common metastatic tumors causing biliary obstruction are gastric, colon, breast, and lung cancers. Jaundice, light-colored stools, dark urine, pruritus, and weight loss due to malabsorption are usual symptoms. Pain and secondary infection are uncommon in malignant biliary obstruction. Ultrasound, CT scan, magnetic resonance cholangiopancreatography (MRCP), or percutaneous transhepatic or endoscopic retrograde cholangiopancreatography (ERCP) will identify the site and nature of the biliary obstruction.

TREATMENT

Malignant Biliary Obstruction

Palliative intervention is indicated only in patients with disabling pruritus resistant to medical treatment, severe malabsorption, or infection. Stenting under radiographic control, surgical bypass, or radiation therapy with or without chemotherapy may alleviate the obstruction. The choice of therapy should be based on the site of obstruction (proximal vs distal), the type of tumor (sensitive to radiotherapy, chemotherapy, or neither), and the general condition of the patient. Stenting under radiographic or endoscopic control, surgical bypass, or radiation therapy with or without chemotherapy may alleviate the obstruction. Photodynamic therapy and radiofrequency ablation are promising endoscopic therapies for malignant biliary obstruction.

Endoscopic ultrasonography-guided biliary drainage is a safe and effective method of biliary drainage in patients with malignant biliary obstruction, particularly in patients whom standard ERCP failed.

SPINAL CORD COMPRESSION

Malignant spinal cord compression (MSCC) is defined as compression of the spinal cord and/or cauda equina by an extradural tumor mass. The minimum radiologic evidence for cord compression is indentation of the theca at the level of clinical features. Spinal cord compression (SCC) occurs in 5–10% of patients with cancer. Epidural tumor is the first manifestation of malignancy in ~10% of patients. The underlying cancer is usually identified during the initial evaluation; lung cancer is the most common cause of MSCC.

Metastatic tumor involves the vertebral column more often than any other part of the bony skeleton. Lung, breast, and prostate cancers are the most frequent offenders. Multiple myeloma also has a high incidence of spine involvement. Lymphomas, melanoma, renal cell cancer, and genitourinary cancers also cause cord compression. The thoracic spine is the most common site (70%), followed by the lumbosacral spine (20%) and the cervical spine (10%). Involvement of multiple sites is most frequent in patients with breast and prostate carcinoma. Cord injury develops when metastases to the vertebral body or pedicle enlarge and compress the underlying dura. Another cause of cord compression is direct extension of a paravertebral lesion through the intervertebral foramen. These cases usually involve a lymphoma, myeloma, or pediatric neoplasm. Parenchymal spinal cord metastasis due to hematogenous spread is rare. Intramedullary metastases can be seen in lung cancer, breast cancer, renal cancer, melanoma, and lymphoma, and are frequently associated with brain metastases and leptomeningeal disease.

Expanding extradural tumors induce injury through several mechanisms. Expanding extradural tumors induce mechanical injury to axons and myelin. Compression compromises blood flow, leading to ischemia and/or infarction.

The most common initial symptom in patients with SCC is localized back pain and tenderness due to involvement of vertebrae by tumor. Pain is usually present for days or months before other neurologic findings appear. It is exacerbated by movement and by coughing or sneezing. It can be differentiated from the pain of disk disease by the fact that it worsens when the patient is supine. Radicular pain is less common than localized back pain and usually develops later. Radicular pain in the cervical or lumbosacral areas may be unilateral or bilateral. Radicular pain from the thoracic roots is often bilateral and is described by patients as a feeling of tight, band-like constriction around the thorax and abdomen. Typical cervical radicular pain radiates down the arm; in the lumbar region, the radiation is down the legs. *Lhermitte's sign*, a tingling or electric sensation down the back and upper and lower limbs upon flexing or extending the neck, may be an early sign of cord compression. Loss of bowel or bladder control may be the presenting symptom but usually occurs late in the course. Occasionally, patients present with ataxia of gait without motor and sensory involvement due to involvement of the spinocerebellar tract.

On physical examination, pain induced by straight leg raising, neck flexion, or vertebral percussion may help to determine the level of cord compression. Patients develop numbness and paresthesias in the extremities or trunk. Loss of sensibility to pinprick is as common as loss of sensibility to vibration or position. The upper limit of the zone of sensory loss is often one or two vertebrae below the site of compression. Motor findings include weakness, spasticity, and abnormal muscle stretching. An extensor plantar reflex reflects significant compression. Deep tendon reflexes may be brisk. Motor and sensory loss usually precedes sphincter disturbance. Patients with autonomic dysfunction may present with decreased anal tonus, decreased perineal sensibility, and a distended bladder. The absence of the anal wink reflex or the bulbocavernosus reflex confirms cord involvement. Autonomic dysfunction is an unfavorable prognostic factor. Patients with progressive neurologic symptoms should have frequent neurologic examinations and rapid therapeutic intervention. Other illnesses that may mimic cord compression include osteoporotic vertebral collapse, disk disease, pyogenic abscess or vertebral tuberculosis, radiation myelopathy, neoplastic leptomeningitis, benign tumors, epidural hematoma, and spinal lipomatosis.

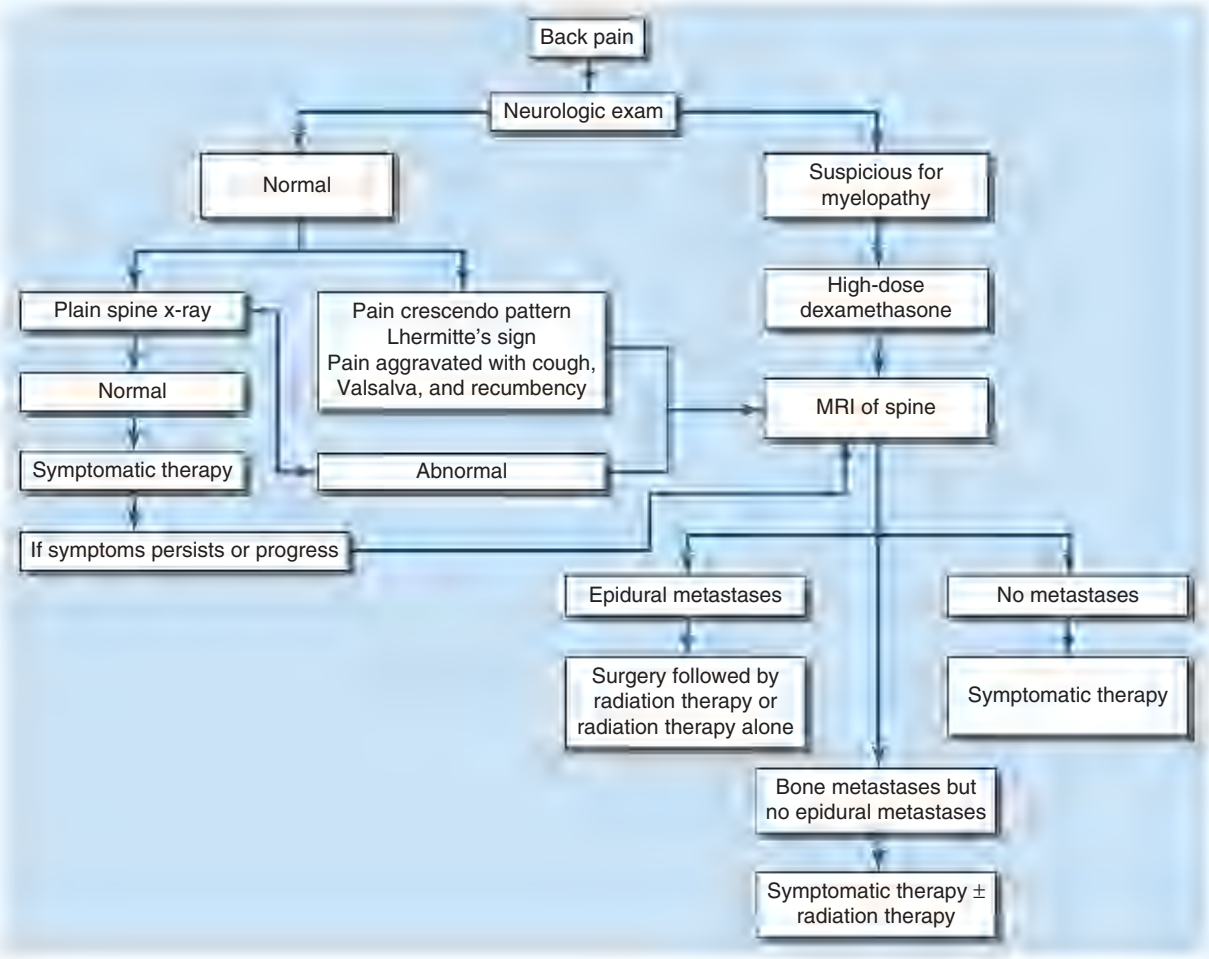

FIGURE 80-2 Management of cancer patients with back pain.

Cauda equina syndrome is characterized by low back pain; diminished sensation over the buttocks, posterior-superior thighs, and perineal area in a saddle distribution; rectal and bladder dysfunction; sexual impotence; absent bulbocavernous, patellar, and Achilles' reflexes; and variable amount of lower-extremity weakness. This reflects compression of nerve roots as they form the cauda equina after leaving the spinal cord. The majority of cauda equina tumors are primary tumors of glial or nerve sheath origin; metastases are very rare.

Patients with cancer who develop back pain should be evaluated for SCC as quickly as possible **(Fig. 80-2)**. Treatment is more often successful in patients who are ambulatory and still have sphincter control at the time treatment is initiated. Patients should have a neurologic examination and plain films of the spine. Those whose physical examination suggests cord compression should receive dexamethasone starting immediately and undergo MRI imaging.

Erosion of the pedicles (the "winking owl" sign) is the earliest radiologic finding of vertebral tumor in plain films; however, plain films are insensitive. Other radiographic changes include increased intrapedicular distance, vertebral destruction, lytic or sclerotic lesions, scalloped vertebral bodies, and vertebral body collapse. Vertebral collapse is not a reliable indicator of the presence of tumor; ~20% of cases of vertebral collapse, particularly those in older patients and postmenopausal women, are due not to cancer but to osteoporosis. Also, a normal appearance on plain films of the spine does not exclude the diagnosis of cancer. The role of bone scans in the detection of cord compression is not clear; this method is sensitive but less specific than spinal radiography.

The full-length image of the cord provided by MRI is the imaging procedure of choice. Multiple epidural metastases are noted in 25% of patients with cord compression, and their presence influences treatment plans. On T1-weighted images, good contrast is noted between the cord, cerebrospinal fluid (CSF), and extradural lesions. Owing to its sensitivity in demonstrating the replacement of bone marrow by tumor, MRI can show which parts of a vertebra are involved by tumor. MRI also visualizes intraspinal extradural masses compressing the cord. T2-weighted images are most useful for the demonstration of intramedullary pathology. Gadolinium-enhanced MRI can help to delineate intramedullary disease. MRI is as good as or better than myelography plus postmyelogram CT scan in detecting metastatic epidural disease with cord compression. Myelography should be reserved for patients who have poor MRIs or who cannot undergo MRI promptly. CT scan in conjunction with myelography enhances the detection of small areas of spinal destruction.

In patients with cord compression and an unknown primary tumor, a simple workup including chest radiography, mammography, measurement of prostate-specific antigen, and abdominal CT usually reveals the underlying malignancy.

TREATMENT

Spinal Cord Compression

The treatment of patients with SCC is aimed at relief of pain and restoration/preservation of neurologic function (Fig. 80-2). Management of MSCC requires a multidisciplinary approach.

Radiation therapy plus glucocorticoids is generally the initial treatment of choice for most patients with SCC. The management decision of SCC involves assessment of neurologic (N), oncologic (O), mechanical (M), and systemic factors (S). NOMS was

developed by Memorial Sloan Kettering Cancer Center (MSKCC) researchers to provide an algorithm for management of SCC. The neurologic assessment is based on the degree of epidural SCC, myelopathy, and/or functional radiculopathy. Oncologic assessment involves the radiosensitivity of the tumor type. In patients with radioresistant tumors, stereotactic body radiotherapy (SBRT) is the preferred approach if radiation is appropriate. Safe delivery of SBRT requires a 2- to 3-mm margin away from the spinal cord. Separation surgery followed by SBRT is necessary in patients with high-grade SCC due to radioresistant tumors. Separation surgery is the circumferential excision of epidural tumor to reconstitute the thecal sac and provide a 2-mm margin for safe delivery of an ablative radiation dose. In patients with mechanical instability or retropulsion of bone fragments into the spinal canal or cord, a surgical approach is the treatment of choice. Systemic factors that need to be considered are the extent of disease and medical comorbidities that determine the patient's ability to tolerate planned therapy. Chemotherapy may have a role in patients with chemosensitive tumors who have had prior radiotherapy to the same region and who are not candidates for surgery. Patients who previously received radiotherapy for MSCC with an in-field tumor progression can be treated with reirradiation with spine stereotactic radiosurgery (SRS) if they are not surgical candidates.

Patients with painful pathologic compression fractures without spinal instability may benefit from percutaneous vertebroplasty or kyphoplasty, the injection of acrylic cement into a collapsed vertebra to stabilize the fracture. Pain palliation is common, and local antitumor effects have been noted. Cement leakage may cause symptoms in ~10% of patients. Bisphosphonates and/or denosumab may be helpful in prevention of SCC in patients with bony involvement.

The histology of the tumor is an important determinant of both recovery and survival. Rapid onset and progression of signs and symptoms are poor prognostic features.

INCREASED INTRACRANIAL PRESSURE

About 25% of patients with cancer die with intracranial metastases. The cancers that most often metastasize to the brain are lung and breast cancers and melanoma. Brain metastases often occur in the presence of systemic disease, and they frequently cause major symptoms, disability, and early death. The initial presentation of brain metastases from a previously unknown primary cancer is common. Lung cancer is most commonly the primary malignancy. CT scans of the chest/abdomen and MRI of the brain as the initial diagnostic studies can identify a biopsy site in most patients.

The signs and symptoms of a metastatic brain tumor are similar to those of other intracranial expanding lesions: headache, nausea, vomiting, behavioral changes, seizures, and focal, progressive neurologic changes. Occasionally the onset is abrupt, resembling a stroke, with the sudden appearance of headache, nausea, vomiting, and neurologic deficits. This picture is usually due to hemorrhage into the metastasis. Melanoma, germ cell tumors, and renal cell cancers have a particularly high incidence of intracranial bleeding. The tumor mass and surrounding edema may cause obstruction of the circulation of CSF, with resulting hydrocephalus. Patients with increased intracranial pressure may have papilledema with visual disturbances and neck stiffness. As the mass enlarges, brain tissue may be displaced through the fixed cranial openings, producing various herniation syndromes.

MRI is superior to CT scan. Gadolinium-enhanced MRI is more sensitive than CT at revealing meningeal involvement and small lesions, particularly in the brainstem or cerebellum. The MRI of the brain shows brain metastases as multiple enhancing lesions of various sizes with surrounding areas of low-density edema.

Intracranial hypertension ("pseudotumor cerebri") secondary to tretinoin therapy for acute promyelocytic leukemia has been reported as another cause of intracranial pressure in the setting of a malignancy.

TREATMENT

Increased Intracranial Pressure

Dexamethasone is the best initial treatment for all symptomatic patients with brain metastases. The current success of immunotherapy approaches for primary and metastatic brain tumors may preclude or limit glucocorticoid use since it may decrease antitumor response. Bevacizumab should be considered in patients who are unable to wean completely off of steroids as well as those who have symptomatic brain edema and are on immunotherapy. Patients with a single brain metastasis and with controlled extracranial disease may be treated with surgical excision followed by SRS to the resection cavity. SRS is recommended in patients with a limited number of brain metastases (one to four) who have stable, systemic disease or reasonable systemic treatment options and in patients who have a small number of metastatic lesions in whom whole-brain radiation therapy has failed. The treatment of a larger number of intracranial metastases remains controversial. More patients now receive SRS because of cognitive dysfunction associated with whole-brain radiation. Some patients with increased intracranial pressure associated with hydrocephalus may benefit from shunt placement. If neurologic deterioration is not reversed with medical therapy, ventriculotomy to remove CSF or craniotomy to remove tumors or hematomas may be necessary.

Targeted agents and checkpoint inhibitors have significant activity in brain metastases from non-small-cell lung cancer, breast cancer, renal cancer, and melanoma.

NEOPLASTIC MENINGITIS

Tumor involving the leptomeninges is a complication of both primary central nervous system (CNS) tumors and tumors that metastasize to the CNS. The incidence is estimated at 3–8% of patients with cancer. Melanoma, breast and lung cancer, lymphoma (including AIDS-associated), and acute leukemia are the most common causes. The lobular or triple-negative subtypes of breast cancer, as well as tumors with expression of the mutant epidermal growth factor receptor (EGFR) or the anaplastic lymphoma kinase (ALK) rearrangement in non-small-cell lung cancer, are more likely to have CNS involvement including neoplastic meningitis and brain metastases. Synchronous intraparenchymal brain metastases are frequent in patients with neoplastic meningitis. Leptomeningeal seeding is frequent in patients undergoing resection of brain metastases or receiving stereotactic radiotherapy for brain metastases.

Patients typically present with multifocal neurologic signs and symptoms, including headache, gait abnormality, mental changes, nausea, vomiting, seizures, back or radicular pain, and limb weakness. Signs include cranial nerve palsies, extremity weakness, paresthesia, and decreased deep tendon reflexes.

Diagnosis is made by demonstrating malignant cells in the CSF; however, up to 40% of patients may have false-negative CSF cytology. An elevated CSF protein level is nearly always present. Patients with neurologic signs and symptoms consistent with neoplastic meningitis who have a negative CSF cytology should have the spinal tap repeated at least one more time for cytologic examination. MRI findings suggestive of neoplastic meningitis include leptomeningeal, subependymal, dural, or cranial nerve enhancement; superficial cerebral lesions; intradural nodules; and communicating hydrocephalus. Spinal cord imaging by MRI is a necessary component of the evaluation of nonleukemia neoplastic meningitis because ~20% of patients have cord abnormalities, including intradural enhancing nodules that are diagnostic for leptomeningeal involvement. Cauda equina lesions are common, but lesions may be seen anywhere in the spinal canal. Radiolabeled CSF flow studies are abnormal in up to 70% of patients with neoplastic meningitis; ventricular outlet obstruction, abnormal flow in the spinal canal, or impaired flow over the cerebral convexities may affect distribution of intrathecal chemotherapy, resulting in decreased efficacy or increased toxicity. Radiation therapy may correct CSF flow abnormalities before

use of intrathecal chemotherapy. Neoplastic meningitis can also lead to intracranial hypertension and hydrocephalus. Placement of a ventriculoperitoneal shunt may effectively palliate symptoms in these patients.

The development of neoplastic meningitis usually occurs in the setting of uncontrolled cancer outside the CNS; thus, prognosis is poor (median survival 10–12 weeks). However, treatment of the neoplastic meningitis may successfully alleviate symptoms and control the CNS spread.

TREATMENT

Neoplastic Meningitis

Chemotherapy provided by either intrathecal injection or systemic routes is used to control leptomeningeal disease throughout the entire neuroaxis. Intrathecal chemotherapy, usually methotrexate, cytarabine, or thiotepa, is delivered by lumbar puncture or by an intraventricular reservoir (Ommaya). Among solid tumors, breast cancer responds best to therapy. Focal radiotherapy may have a role in bulky disease and in symptomatic or obstructive lesions. Targeted therapy such as systemically administered EGFR tyrosine kinase inhibitors (TKIs) in non-small-cell lung cancer may lead to improvement in some patients with leptomeningeal spread. Patients with neoplastic meningitis from either acute leukemia or lymphoma may be cured of their CNS disease if the systemic disease can be eliminated.

SEIZURES

Seizures occurring in a patient with cancer can be caused by the tumor itself, by metabolic disturbances, by radiation injury, by cerebral infarctions, by chemotherapy-related encephalopathies, or by CNS infections. Metastatic disease to the CNS is the most common cause of seizures in patients with cancer. However, seizures occur more frequently in primary brain tumors than in metastatic brain lesions. Seizures are a presenting symptom of CNS metastasis in 6–29% of cases. Approximately 10% of patients with CNS metastasis eventually develop seizures. Tumors that affect the frontal, temporal, and parietal lobes are more commonly associated with seizures than are occipital lesions. Both early and late seizures are uncommon in patients with posterior fossa and sellar lesions. Seizures are common in patients with CNS metastases from melanoma and low-grade primary brain tumors. Very rarely, cytotoxic drugs such as etoposide, busulfan, ifosfamide, and chlorambucil cause seizures. Treatment with bispecific antibodies and chimeric antigen receptor (CAR) T cells may also cause CNS toxicity including seizures and encephalopathy. Another cause of seizures related to drug therapy is reversible posterior leukoencephalopathy syndrome (RPLS). Chemotherapy, targeted therapy, and immunotherapies have been associated with the development of RPLS. RPLS occurs in patients undergoing allogeneic bone marrow or solid-organ transplantation. RPLS is characterized by headache, altered consciousness, generalized seizures, visual disturbances, hypertension, and symmetric posterior cerebral white matter vasogenic edema on CT/MRI. Seizures may begin focally but are typically generalized.

TREATMENT

Seizures

Patients in whom seizures due to CNS metastases have been demonstrated should receive anticonvulsive treatment with levetiracetam, lacosamide, or lamotrigine. Prophylactic anticonvulsant therapy is not recommended. In postcraniotomy patients, prophylactic antiepileptic drugs should be withdrawn during the first 2 weeks after surgery. Most antiseizure medications including phenytoin induce cytochrome P450 (CYP450), which alters the metabolism of many antitumor agents, including irinotecan, taxanes, and etoposide, as well as molecular targeted agents, including imatinib, gefitinib, erlotinib, tipifarnib, sorafenib, sunitinib, temsirolimus, everolimus, and vemurafenib. Levetiracetam, lacosamide, and lamotrigine are anticonvulsant agents not metabolized by the hepatic CYP450 system and do not alter the metabolism of antitumor agents. Levetiracetam has become the preferred drug. Surgical resection and other antitumor treatments such as radiotherapy and chemotherapy may improve seizure control.

PULMONARY AND INTRACEREBRAL LEUKOSTASIS

Hyperleukocytosis and the leukostasis syndrome associated with it are potentially fatal complications of acute leukemia (particularly myeloid leukemia) that can occur when the peripheral blast cell count is >100,000/mL. The frequency of hyperleukocytosis is 5–13% in acute myeloid leukemia (AML) and 10–30% in acute lymphoid leukemia; however, leukostasis is rare in lymphoid leukemia. In AML, hyperleukocytosis is more commonly seen in myelomonocytic AML (Fab-M4 and M5), those with 11q13 abnormalities involving the *MLL* gene, and those with *FLT3* mutations. At such high blast cell counts, blood viscosity is increased, blood flow is slowed by aggregates of tumor cells, and the primitive myeloid leukemic cells are capable of invading through the endothelium and causing hemorrhage. Brain and lung are most commonly affected. Patients with brain leukostasis may experience stupor, headache, dizziness, tinnitus, visual disturbances, ataxia, confusion, coma, or sudden death. On examination, papilledema, retinal vein distension, retinal hemorrhages, and focal deficit may be present. Pulmonary leukostasis may present as respiratory distress and hypoxemia and progress to respiratory failure. Chest radiographs may be normal but usually show interstitial or alveolar infiltrates. Hyperleukocytosis rarely may cause acute leg ischemia, renal vein thrombosis, myocardial ischemia, bowel infraction, and priapism. Arterial blood gas results should be interpreted cautiously. Rapid consumption of plasma oxygen by the markedly increased number of white blood cells can cause spuriously low arterial oxygen tension. Pulse oximetry is the most accurate way of assessing oxygenation in patients with hyperleukocytosis. Hydroxyurea can rapidly reduce a high blast cell count while the diagnostic workup is in progress. After the diagnosis is established, the patient should start quickly with effective induction chemotherapy. Leukapheresis should be used in patients with symptoms of hyperleukocytosis. Patients with hyperleukocytosis are also at risk for disseminated intravascular coagulation and tumor lysis syndrome. The clinician should monitor the patient for these complications and take preventive and therapeutic actions during induction therapy. Intravascular volume depletion and unnecessary blood transfusions may increase blood viscosity and worsen the leukostasis syndrome. Leukostasis is very rarely a feature of the high white cell counts associated with chronic lymphoid or chronic myeloid leukemia.

When acute promyelocytic leukemia is treated with differentiating agents like tretinoin and arsenic trioxide, cerebral or pulmonary leukostasis may occur as tumor cells differentiate into mature neutrophils. This complication can be largely avoided by using cytotoxic chemotherapy together with the differentiating agents.

HEMOPTYSIS

Hemoptysis may be caused by nonmalignant conditions, but lung cancer accounts for a large proportion of cases. Up to 20% of patients with lung cancer have hemoptysis some time in their course. Endobronchial metastases from carcinoid tumors, breast cancer, colon cancer, kidney cancer, and melanoma may also cause hemoptysis. The volume of bleeding is often difficult to gauge. Massive hemoptysis is defined as >200–600 mL of blood produced in 24 h. However, any hemoptysis should be considered massive if it threatens life. When respiratory difficulty occurs, hemoptysis should be treated emergently. The first priorities are to maintain the airway, optimize oxygenation, and stabilize the hemodynamic status. If the bleeding side is known, the patient should be placed in a lateral decubitus position, with the bleeding side down to prevent aspiration into the unaffected lung and given supplemental oxygen. If large-volume bleeding continues or the airway is compromised, the patient should be intubated and undergo emergency bronchoscopy. If the site of bleeding is detected, either the patient undergoes a definitive surgical procedure or the lesion is treated with a neodymium:yttrium-aluminum-garnet (Nd:YAG) laser, argon plasma

coagulation, or electrocautery. In stable patients, multidetector CT angiography delineates bronchial and nonbronchial systemic arteries and identifies the source of bleeding and underlying pathology with high sensitivity. Massive hemoptysis usually originates from the high-pressure bronchial circulation. Bronchial artery embolization is considered a first-line definitive procedure for managing hemoptysis. Bronchial artery embolization may control brisk bleeding in 75–90% of patients, permitting the definitive surgical procedure to be done more safely if it is appropriate.

Embolization without definitive surgery is associated with rebleeding in 20–50% of patients. Recurrent hemoptysis usually responds to a second embolization procedure. A postembolization syndrome characterized by pleuritic pain, fever, dysphagia, and leukocytosis may occur; it lasts 5–7 days and resolves with symptomatic treatment. Bronchial or esophageal wall necrosis, myocardial infarction, and spinal cord infarction are rare complications. Surgery, as a salvage strategy, is indicated after failure of embolization and is associated with better survival when performed in a nonurgent setting.

Pulmonary hemorrhage with or without hemoptysis in hematologic malignancies is often associated with fungal infections, particularly *Aspergillus* spp. After granulocytopenia resolves, the lung infiltrates in aspergillosis may cavitate and cause massive hemoptysis. Thrombocytopenia and coagulation defects should be corrected, if possible. Surgical evaluation is recommended in patients with aspergillosis-related cavitary lesions. Antibodies to vascular endothelial growth factor (VEGF) including bevacizumab and ramucirumab that inhibit angiogenesis, have been associated with life-threatening hemoptysis in patients with non-small-cell lung cancer, particularly of squamous cell histology. Non-small-cell lung cancer patients with cavitary lesions or previous hemoptysis (≥2.5 mL) within the past 3 months have higher risk for pulmonary hemorrhage.

AIRWAY OBSTRUCTION

Airway obstruction refers to a blockage at the level of the mainstem bronchi or above. It may result either from intraluminal tumor growth or from extrinsic compression of the airway. The most common cause of malignant upper airway obstruction is invasion from an adjacent primary tumor, most commonly lung cancer, followed by esophageal, thyroid, and mediastinal malignancies including lymphomas. Extrathoracic primary tumors such as renal, colon, or breast cancer can cause airway obstruction through endobronchial and/or mediastinal lymph node metastases. Patients may present with dyspnea, hemoptysis, stridor, wheezing, intractable cough, postobstructive pneumonia, or hoarseness. Chest radiographs usually demonstrate obstructing lesions. CT scans reveal the extent of tumor. Cool, humidified oxygen, glucocorticoids, and ventilation with a mixture of helium and oxygen (Heliox) may provide temporary relief. If the obstruction is proximal to the larynx, a tracheostomy may be lifesaving. For more distal obstructions, particularly intrinsic lesions incompletely obstructing the airway, bronchoscopy with mechanical debulking and dilation or ablational treatments including laser treatment, photodynamic therapy, argon plasma coagulation, electrocautery, or stenting can produce immediate relief in most patients (Fig. 80-3). However, radiation therapy (either external-beam irradiation or brachytherapy) given together with glucocorticoids may also open the airway. Symptomatic extrinsic compression may be palliated by stenting. Patients with primary airway tumors such as squamous cell carcinoma, carcinoid tumor, adenocystic carcinoma, or non-small-cell lung cancer, if resectable, should have surgery.

FIGURE 80-3 Airway obstruction. *A.* Computed tomography scan of a 62-year-old man with tracheal obstruction caused by renal carcinoma showing paratracheal mass with tracheal invasion/obstruction (*arrow*). ***B.*** Chest x-ray of same patient after stent (*arrows*) placement.

METABOLIC EMERGENCIES

HYPERCALCEMIA

Hypercalcemia is the most common paraneoplastic syndrome. Its pathogenesis and management are discussed fully in Chaps. 98 and 422.

SYNDROME OF INAPPROPRIATE SECRETION OF ANTIDIURETIC HORMONE

Hyponatremia is a common electrolyte abnormality in cancer patients, and syndrome of inappropriate secretion of antidiuretic hormone (SIADH) is the most common cause among patients with cancer. SIADH is discussed fully in Chaps. 98 and 393.

LACTIC ACIDOSIS

Lactic acidosis is a rare and potentially fatal metabolic complication of cancer. Lactic acidosis associated with sepsis and circulatory failure is a common preterminal event in many malignancies. Lactic acidosis in the absence of hypoxemia may occur in patients with leukemia, lymphoma, or solid tumors. In some cases, hypoglycemia also is present. Extensive involvement of the liver by tumor is often present. In most cases, decreased metabolism and increased production by the tumor both contribute to lactate accumulation. Tumor cell overexpression of certain glycolytic enzymes and mitochondrial dysfunction can contribute to its increased lactate production. HIV-infected patients have an increased risk of aggressive lymphoma; lactic acidosis that occurs in such patients may be related either to the rapid growth of the tumor or from toxicity of nucleoside reverse transcriptase inhibitors. Symptoms of lactic acidosis include tachypnea, tachycardia, change of mental status, and hepatomegaly. The serum level of lactic acid may reach 10–20 mmol/L (90–180 mg/dL). Treatment is aimed at the underlying disease. Sodium bicarbonate should be added if acidosis is very severe or if hydrogen ion production is very rapid and uncontrolled. Other treatment options include renal replacement therapy, such as hemodialysis, and thiamine replacement. The prognosis is poor regardless of the treatment offered.

HYPOGLYCEMIA

Persistent hypoglycemia is occasionally associated with tumors other than pancreatic islet cell tumors. Usually these tumors are large;

tumors of mesenchymal origin, hepatomas, or adrenocortical tumors may cause hypoglycemia. Mesenchymal tumors are usually located in the retroperitoneum or thorax. Obtundation, confusion, and behavioral aberrations occur in the postabsorptive period and may precede the diagnosis of the tumor. These tumors often secrete incompletely processed insulin-like growth factor II (IGF-II), a hormone capable of activating insulin receptors and causing hypoglycemia. Tumors secreting incompletely processed big IGF-II are characterized by an increased IGF-II to IGF-I ratio, suppressed insulin and C-peptide level, and inappropriately low growth hormone and β-hydroxybutyrate concentrations. Rarely, hypoglycemia is due to insulin secretion by a non–islet cell carcinoma. The development of hepatic dysfunction from liver metastases and increased glucose consumption by the tumor can contribute to hypoglycemia. If the tumor cannot be resected, hypoglycemia symptoms may be relieved by the administration of glucose, glucocorticoids, recombinant growth hormone, or glucagon.

Hypoglycemia can be artifactual; hyperleukocytosis from leukemia, myeloproliferative diseases, leukemoid reactions, or colony-stimulating factor treatment can increase glucose consumption in the test tube after blood is drawn, leading to pseudohypoglycemia.

ADRENAL INSUFFICIENCY

In patients with cancer, adrenal insufficiency may go unrecognized because the symptoms, such as nausea, vomiting, anorexia, and orthostatic hypotension, are nonspecific and may be mistakenly attributed to progressive cancer or to therapy. Primary adrenal insufficiency may develop owing to replacement of both glands by metastases (lung, breast, colon, or kidney cancer; lymphoma), to removal of both glands, or to hemorrhagic necrosis in association with sepsis or anticoagulation. Impaired adrenal steroid synthesis occurs in patients being treated for cancer with mitotane, ketoconazole, or aminoglutethimide or undergoing rapid reduction in glucocorticoid therapy. Megestrol acetate, used to manage cancer and HIV-related cachexia, may suppress plasma levels of cortisol and adrenocorticotropic hormone (ACTH). Patients taking megestrol may develop adrenal insufficiency, and even those whose adrenal dysfunction is not symptomatic may have inadequate adrenal reserve if they become seriously ill. Paradoxically, some patients may develop Cushing's syndrome and/or hyperglycemia because of the glucocorticoid-like activity of megestrol acetate. Ipilimumab, an anti-CTLA-4 antibody used for treatment of malignant melanoma and other cancers, may cause autoimmunity including autoimmune-like enterocolitis, hypophysitis (leading to secondary adrenal insufficiency), hepatitis, and, rarely, primary adrenal insufficiency. Autoimmune hypophysitis may present with headache, visual field defects, and pituitary hormone deficiencies manifesting as hypopituitarism, adrenal insufficiency (including adrenal crisis), or hypothyroidism. Ipilimumab-associated hypophysitis symptoms occur at an average of 6–12 weeks after initiation of therapy. An MRI usually shows homogenous enhancement of pituitary gland. Early glucocorticoid treatment and hormone replacement are the initial treatment. The role of high-dose glucocorticoids in the treatment of hypophysitis is not clear. High-dose glucocorticoids may not improve the frequency of pituitary function recovery. Autoimmune adrenalitis can also be observed with anti-CTLA-4 antibody. Pituitary dysfunction is usually permanent, requiring long-term hormone replacement therapy. Other checkpoint inhibitors, such as monoclonal antibodies targeting programmed cell death 1 (PD-1), an inhibitory receptor expressed by T cells or one of its ligands (PD-L1), may cause hypophysitis infrequently (~1%). Autoimmune adrenalitis is more frequent with use of PD-1/PD-L1 than with CTLA-4 inhibitors, but incidence is low. Cranial irradiation for childhood brain tumors may affect the hypothalamus-pituitary-adrenal axis, resulting in secondary adrenal insufficiency. Rarely, metastatic replacement causes primary adrenal insufficiency as the first manifestation of an occult malignancy. Metastasis to the pituitary or hypothalamus is found at autopsy in up to 5% of patients with cancer, but associated secondary adrenal insufficiency is rare.

Acute adrenal insufficiency is potentially lethal. Treatment of suspected adrenal crisis is initiated after the sampling of serum cortisol and ACTH levels (Chap. 398).

TREATMENT-RELATED EMERGENCIES

TUMOR LYSIS SYNDROME

Tumor lysis syndrome (TLS) is characterized by hyperuricemia, hyperkalemia, hyperphosphatemia, and hypocalcemia and is caused by the destruction of a large number of rapidly proliferating neoplastic cells. Acidosis may also develop. Acute renal failure occurs frequently.

TLS is most often associated with the treatment of Burkitt's lymphoma, acute lymphoblastic leukemia, AML, and other rapidly proliferating lymphomas, but it also may be seen with chronic leukemias and, rarely, with solid tumors. This syndrome is increased in frequency in lymphoid neoplasms treated with venetoclax, a bcl-2 antagonist. TLS has been observed with administration of glucocorticoids, hormonal agents such as letrozole and tamoxifen, and monoclonal antibodies such as rituximab, obinutuzumab, ofatumumab, and gemtuzumab. TLS usually occurs during or shortly (1–5 days) after chemotherapy. Rarely, spontaneous necrosis of malignancies causes TLS.

Hyperuricemia may be present at the time of chemotherapy. Effective treatment kills malignant cells and leads to increased serum uric acid levels from the turnover of nucleic acids. Owing to the acidic local environment, uric acid can precipitate in the tubules, medulla, and collecting ducts of the kidney, leading to renal failure. Lactic acidosis and dehydration may contribute to the precipitation of uric acid in the renal tubules. The finding of uric acid crystals in the urine is strong evidence for uric acid nephropathy. The ratio of urinary uric acid to urinary creatinine is >1 in patients with acute hyperuricemic nephropathy and <1 in patients with renal failure due to other causes. Other events may lead to renal failure in TLS. Calcium phosphate also precipitates in the interstitium and renal microvasculature, leading to nephrocalcinosis. Both types of crystals are toxic to the tubular epithelium, inducing local active inflammatory and pro-oxidative responses. Soluble uric acid may induce hemodynamic changes, with decreased renal blood flow due to vasoconstriction and impaired autoregulation (crystal-independent pathway).

Hyperphosphatemia, which can be caused by the release of intracellular phosphate pools by tumor lysis, produces a reciprocal depression in serum calcium, which causes severe neuromuscular irritability and tetany. Deposition of calcium phosphate in the kidney and hyperphosphatemia may cause renal failure. Potassium is the principal intracellular cation, and massive destruction of malignant cells may lead to hyperkalemia. Hyperkalemia in patients with renal failure may rapidly become life threatening by causing ventricular arrhythmias and sudden death.

The likelihood that TLS will occur in patients with Burkitt's lymphoma is related to the tumor burden and renal function. Hyperuricemia and high serum levels of lactate dehydrogenase (LDH >1500 U/L), both of which correlate with total tumor burden, also correlate with the risk of TLS. In patients at risk for TLS, pretreatment evaluations should include a complete blood count, serum chemistry evaluation, and urinalysis. High leukocyte and platelet counts may artificially elevate potassium levels ("pseudohyperkalemia") due to lysis of these cells after the blood is drawn. In these cases, plasma potassium instead of serum potassium should be followed. In pseudohyperkalemia, no electrocardiographic abnormalities are present. In patients with abnormal baseline renal function, the kidneys and retroperitoneal area should be evaluated by sonography and/or CT to rule out obstructive uropathy. Urine output should be watched closely.

TREATMENT

Tumor Lysis Syndrome

Recognition of risk and prevention are the most important steps in the management of this syndrome **(Fig. 80-4)**. The standard preventive approach consists of allopurinol and aggressive hydration. Urinary alkalization with sodium bicarbonate is no longer recommended. It increases uric acid solubility, but a high pH decreases the solubility of xanthine, hypoxanthine, and calcium phosphate, potentially increasing the likelihood of intratubular crystallization. Intravenous allopurinol may be given in patients who cannot tolerate oral therapy. Febuxostat, a potent nonpurine selective xanthine

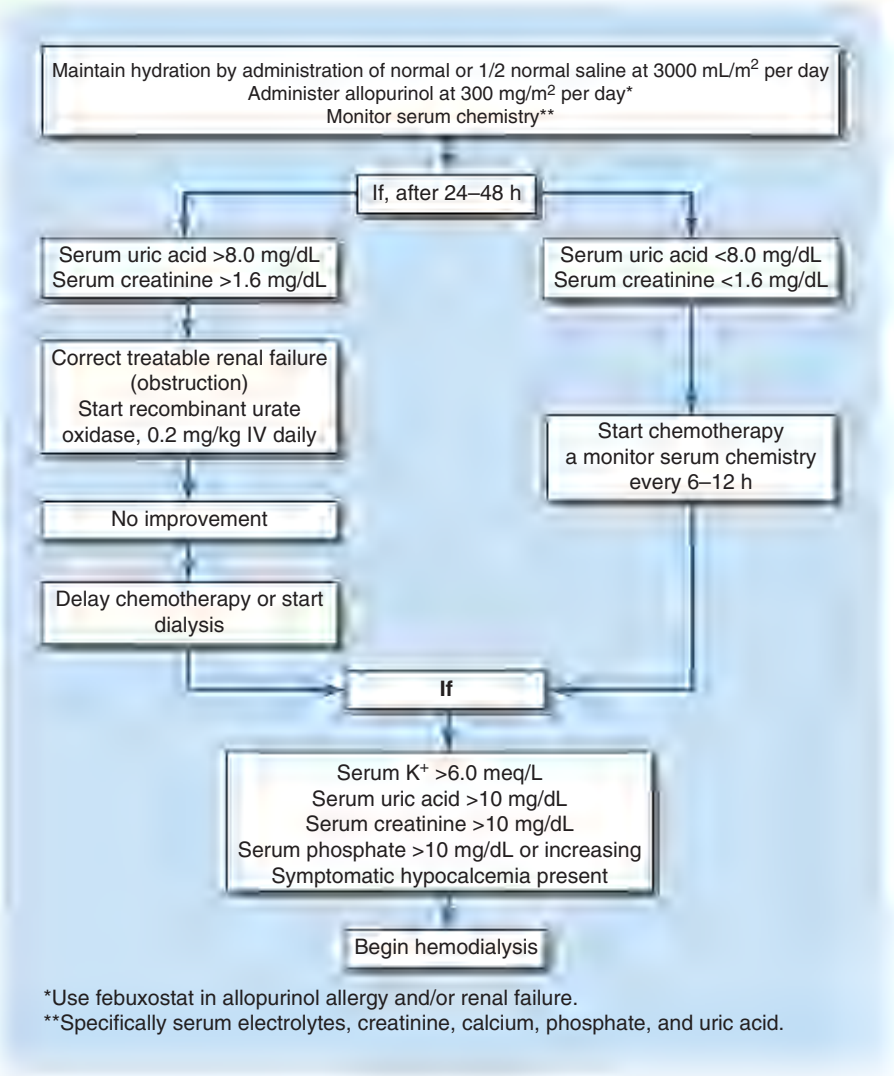

FIGURE 80-4 Management of patients at high risk for the tumor lysis syndrome.

oxidase inhibitor, is indicated for treatment of hyperuricemia. It results in fewer hypersensitivity reactions than allopurinol. Febuxostat does not require dosage adjustment in patients with mild to moderate renal impairment. Febuxostat achieved significantly superior serum uric acid control in comparison to allopurinol in patients with hematologic malignancies at intermediate to high TLS risk. In some cases, uric acid levels cannot be lowered sufficiently with the standard preventive approach. Rasburicase (recombinant urate oxidase) can be effective in these instances, particularly when renal failure is present. Urate oxidase is missing from primates and catalyzes the conversion of poorly soluble uric acid to readily soluble allantoin. Rasburicase acts rapidly, decreasing uric acid levels within hours; however, it may cause hypersensitivity reactions such as bronchospasm, hypoxemia, and hypotension. Rasburicase should also be administered to high-risk patients for TLS prophylaxis. Rasburicase is contraindicated in patients with glucose-6-phosphate dehydrogenase deficiency who are unable to break down hydrogen peroxide, an end product of the urate oxidase reaction. Rasburicase is known to cause ex vivo enzymatic degradation of uric acid in test tube at room temperature. This leads to spuriously low uric acid levels during laboratory monitoring of the patient with TLS. Samples must be cooled immediately to deactivate the urate oxidase. Despite aggressive prophylaxis, TLS and/or oliguric or anuric renal failure may occur. Renal replacement therapy is often necessary and should be considered early in the course. Hemodialysis is preferred. Hemofiltration offers a gradual, continuous method of removing cellular by-products and fluid.

HUMAN ANTIBODY INFUSION REACTIONS

The initial infusion of human or humanized antibodies (e.g., rituximab, gemtuzumab, trastuzumab, alemtuzumab, panitumumab, brentuximab vedotin, blinatumomab) is associated with fever, chills, nausea, asthenia, and headache in up to half of treated patients. Bronchospasm and hypotension occur in 1% of patients. Severe manifestations including pulmonary infiltrates, acute respiratory distress syndrome (ARDS), and cardiogenic shock occur rarely. Laboratory manifestations include elevated hepatic aminotransferase levels, thrombocytopenia, and prolongation of prothrombin time. The pathogenesis is thought to be activation of immune effector processes (cells and complement) and release of inflammatory cytokines, such as tumor necrosis factor α, interferon γ, interleukin (IL) 6, and IL-10 (cytokine release syndrome [CRS]). Although its origins are not completely understood, CRS is believed to be due to activation of a variety of cell types including neutrophils, monocytes/macrophages, natural killer cells, and T and B lymphocytes. Hemophagocytic lymphohistiocytosis (HLH)/macrophage activation syndrome (MAS) can develop as part of CRS and usually is a manifestation of severe CRS.

Severe CRS may require intensive support for ARDS and resistant hypotension. Emerging clinical experience at several institutions has concluded that tocilizumab is an effective treatment for severe or life-threatening CRS. Tocilizumab prevents IL-6 binding to both cell-associated and soluble IL-6 receptors and therefore inhibits both classical and trans-IL-6 signaling. Other cytokine-directed therapies, such as siltuximab, a chimeric anti-IL-6 monoclonal antibody, and anakinra, an IL-1 receptor antagonist, have been used.

Adoptive transfer of CAR-engineered T cells is a promising therapy for cancers. The most common acute toxicity of CAR T cells is CRS. CAR T cell–associated CRS may be associated with cardiac dysfunction and neurotoxicity. In all cases, MAS could happen with CRS. The management includes supportive care and tocilizumab.

HEMOLYTIC-UREMIC SYNDROME

Malignancy can induce hemolytic-uremic syndrome (HUS) through a wide variety of mechanisms, including systemic microvascular metastases, extensive bone marrow invasion, or secondary necrosis. HUS syndromes have been reported with metastatic gastric and ovarian cancers, leukemias, and lymphomas. HUS and, less commonly, thrombotic thrombocytopenic purpura (TTP) **(Chap. 329)** may rarely occur after treatment with antineoplastic drugs, including mitomycin, gemcitabine, cisplatin, bleomycin, and proteasome inhibitors, and with VEGF inhibitors. Mitomycin and gemcitabine are the most common offenders. Unlike mitomycin, there is no clear-cut relationship between the cumulative dose of gemcitabine and risk of HUS. It occurs most often in patients with gastric, lung, colorectal, pancreatic, and breast carcinoma. In one series, 35% of patients were without evident cancer at the time this syndrome appeared. Secondary HUS/TTP has also been reported as a rare but sometimes fatal complication of bone marrow transplantation.

HUS usually has its onset 4–8 weeks after the last dose of chemotherapy, but it is not rare to detect it several months later. HUS is characterized by microangiopathic hemolytic anemia, thrombocytopenia, and renal failure. Dyspnea, weakness, fatigue, oliguria, and purpura are also common initial symptoms and findings. Systemic hypertension and pulmonary edema frequently occur. Severe hypertension, pulmonary edema, and rapid worsening of hemolysis and renal function may occur after a blood or blood product transfusion. Cardiac findings include atrial arrhythmias, pericardial friction rub, and pericardial effusion. Raynaud's phenomenon is part of the syndrome in patients treated with bleomycin.

Laboratory findings include severe to moderate anemia associated with red blood cell fragmentation and numerous schistocytes on peripheral smear. Reticulocytosis, decreased plasma haptoglobin, and an LDH level document hemolysis. The serum bilirubin level is usually normal or slightly elevated. The Coombs test is negative. The white cell count is usually normal, and thrombocytopenia (<100,000/μL) is almost always present. Most patients have a normal coagulation profile, although some have mild elevations in thrombin time and in levels of fibrin degradation products. The serum creatinine level is elevated at presentation and shows a pattern of subacute worsening within weeks of the initial azotemia. The urinalysis reveals hematuria, proteinuria, and granular or hyaline casts, and circulating immune complexes may be present.

The basic pathologic lesion appears to be deposition of fibrin in the walls of capillaries and arterioles, and these deposits are similar to those seen in HUS due to other causes. These microvascular abnormalities involve mainly the kidneys and rarely occur in other organs. The pathogenesis of cancer treatment–related HUS is not completely understood, but probably the most important factor is endothelial damage. Primary forms of HUS/TTP are related to a decrease in processing of von Willebrand factor by a protease called ADAMTS13.

The case-fatality rate is high; most patients die within a few months. Optimal treatment for chemotherapy-induced HUS is debated. Immunocomplex removal through plasmapheresis, plasma exchange, immunoadsorption, or exchange transfusion, antiplatelet and anticoagulant therapies, and immunosuppression have all been employed with varying degrees of success.

The outcome with plasma exchange is generally poor, as in many other cases of secondary TTP. Rituximab is successfully used in patients with chemotherapy-induced HUS as well as in ADAMTS13-deficient TTP. Eculizumab, a complement inhibitor, is now considered first-line treatment of atypical HUS. Ravulizumab, a humanized monoclonal antibody that blocks terminal complement activation at C5 and is engineered from eculizumab, has an extended half-life and is approved by the U.S. Food and Drug Administration (FDA) for atypical HUS. Vaccination against *Neisseria meningitis* is mandatory before eculizumab and ravulizumab are administered.

NEUTROPENIA AND INFECTION

These remain the most common serious complications of cancer therapy. They are covered in detail in **Chap. 79**.

PULMONARY INFILTRATES

Patients with cancer may present with dyspnea associated with diffuse interstitial infiltrates on chest radiographs. Such infiltrates may be due to progression of the underlying malignancy, treatment-related toxicities, infection, and/or unrelated diseases. The cause may be multifactorial; however, most commonly, they occur as a consequence of treatment. Infiltration of the lung by malignancy has been described in patients with leukemia, lymphoma, and breast and other solid cancers. Pulmonary lymphatics may be involved diffusely by neoplasm (pulmonary lymphangitic carcinomatosis), resulting in a diffuse increase in interstitial markings on chest radiographs. The patient is often mildly dyspneic at the onset, but pulmonary failure develops over a period of weeks. In some patients, dyspnea precedes changes on the chest radiographs and is accompanied by a nonproductive cough. This syndrome is characteristic of solid tumors. In patients with leukemia, diffuse microscopic neoplastic peribronchial and peribronchiolar infiltration is frequent but may be asymptomatic. However, some patients present with diffuse interstitial infiltrates, an alveolar capillary block syndrome, and respiratory distress. Thickening of bronchovascular bundles and prominence of peripheral arteries are CT findings suggestive of leukemic infiltration. In these situations, glucocorticoids can provide symptomatic relief, but specific chemotherapy should always be started promptly.

Several cytotoxic agents, such as bleomycin, methotrexate, busulfan, nitrosoureas, gemcitabine, mitomycin, vinorelbine, docetaxel, paclitaxel, fludarabine, pentostatin, and ifosfamide, may cause pulmonary damage. The most frequent presentations are interstitial pneumonitis, alveolitis, and pulmonary fibrosis. Some cytotoxic agents, including methotrexate and procarbazine, may cause an acute hypersensitivity reaction. Cytosine arabinoside has been associated with noncardiogenic pulmonary edema. Administration of multiple cytotoxic drugs, as well as radiotherapy and preexisting lung disease, may potentiate the pulmonary toxicity. Supplemental oxygen may potentiate the effects of drugs and radiation injury. Patients should always be managed with the lowest FIO_2 that is sufficient to maintain hemoglobin saturation.

The onset of symptoms may be insidious, with symptoms including dyspnea, nonproductive cough, and tachycardia. Patients may have bibasilar crepitant rales, end-inspiratory crackles, fever, and cyanosis. The chest radiograph generally shows an interstitial and sometimes an intraalveolar pattern that is strongest at the lung bases and may be symmetric. A small effusion may occur. Hypoxemia with decreased carbon monoxide diffusing capacity is always present. Glucocorticoids may be helpful in patients in whom pulmonary toxicity is related to radiation therapy or to chemotherapy. Treatment is otherwise supportive.

Molecular targeted agents, imatinib, erlotinib, and gefitinib are potent inhibitors of tyrosine kinases. These drugs may cause interstitial lung disease (ILD). In the case of gefitinib, preexisting fibrosis, poor performance status, and prior thoracic irradiation are independent risk factors; this complication has a high fatality rate. In Japan, incidence of ILD associated with gefitinib was ~4.5% compared to 0.5% in the United States. Osimertinib may cause transient pulmonary opacities (TPOs). TPOs are characterized asymptomatic and localized ground-glass opacities (GGO) with or without nodular consolidation on CT. TPOs typically resolve during continued osimertinib therapy. Temsirolimus and everolimus, both esters of rapamycin (sirolimus), are agents that block the effects of mammalian target of rapamycin (mTOR), an enzyme that has an important role in regulating the synthesis of proteins that control cell division. These agents may cause GGO in the lung with or without diffuse interstitial disease and lung parenchymal consolidation. Patients may be asymptomatic with only radiologic findings or may be symptomatic. Symptoms include cough, dyspnea, and/or hypoxemia, and sometimes patients present

with systemic symptoms such as fever and fatigue. The incidence of everolimus-induced ILD also appears to be higher in Japanese patients. HER2-targeting ADC trastuzumab-deruxtecan carries a known risk of ILD with fatality. Treatment includes dose reduction or withdrawal and, in some cases, the addition of glucocorticoids.

The FDA-approved immune checkpoint inhibitors (ICIs) of the PD-1 and PD-L1 pathway, including nivolumab, pembrolizumab, durvalumab, avelumab, atezolizumab, and cemiplimab, enhance antitumor activity by blocking negative regulators of T-cell function. Immune-mediated pneumonitis is rare (10%) but may be a life-threatening complication of these drugs. Pneumonitis symptoms include cough, shortness of breath, dyspnea, and fever, and often involve only asymptomatic radiographic changes. Pneumonitis shows ground-glass patchy lesions and/or disseminated nodular infiltrates, predominantly in the lower lobes. Identifying the exact cause of a pneumonitis in a patient treated with ICIs could be challenging during the current COVID-19 outbreak **(Fig. 80-5*A*)**. Chest CT manifestations of COVID-19 include an imaging pattern of pure GGO, consolidation, nodules, fibrous stripes, and mixed patterns, with the distribution slightly predominant in the lower lobe and peripheral areas of the lung. Treatment of immune-mediated pneumonitis includes temporary or permanent withdrawal of drug and the addition of high-dose glucocorticoids **(Fig. 80-5*B*)**.

Radiation pneumonitis and/or fibrosis are relatively frequent side effects of thoracic radiation therapy. It may be acute or chronic. Radiation-induced lung toxicity is a function of the irradiated lung volume, dose per fraction, and radiation dose. The larger the irradiated lung field, the higher is the risk for radiation pneumonitis. The use of concurrent chemoradiation, particularly regimens including paclitaxel, increases pulmonary toxicity. Radiation pneumonitis usually develops 2–6 months after completion of radiotherapy. The clinical syndrome, which varies in severity, consists of dyspnea, cough with scanty sputum, low-grade fever, and an initial hazy infiltrate on chest radiographs. The infiltrate and tissue damage usually are confined to the radiation field. The CT scan may show GGOs, consolidation, fibrosis, atelectatic cicatrization, pleural volume loss, or pleural thickening. The patients subsequently may develop a patchy alveolar infiltrate and air bronchograms, which may progress to acute respiratory failure that is sometimes fatal. A lung biopsy may be necessary to make the diagnosis. Asymptomatic infiltrates found incidentally after radiation therapy need not be treated. However, prednisone should be administered to patients with fever or other symptoms. The dosage should be tapered slowly after the resolution of radiation pneumonitis, because abrupt withdrawal of glucocorticoids may cause an exacerbation of pneumonia. Delayed radiation fibrosis may occur years after radiation therapy and is signaled by dyspnea on exertion. Often it is mild, but it can progress to chronic respiratory failure. Therapy is supportive.

Classic radiation pneumonitis that leads to pulmonary fibrosis is due to radiation-induced production of local cytokines such as platelet-derived growth factor β, tumor necrosis factor, interleukins, and transforming growth factor β in the radiation field.

SBRT is a radiotherapy treatment method that has been applied to the treatment of stage I lung cancers in medically inoperable patients. SBRT accurately delivers a high dose of irradiation in one or few treatment fractions to an image-defined lung mass. Most of the acute changes after SBRT occur later than 3 months after treatment, and the shape of the SBRT-induced injury conforms more tightly to the tumor.

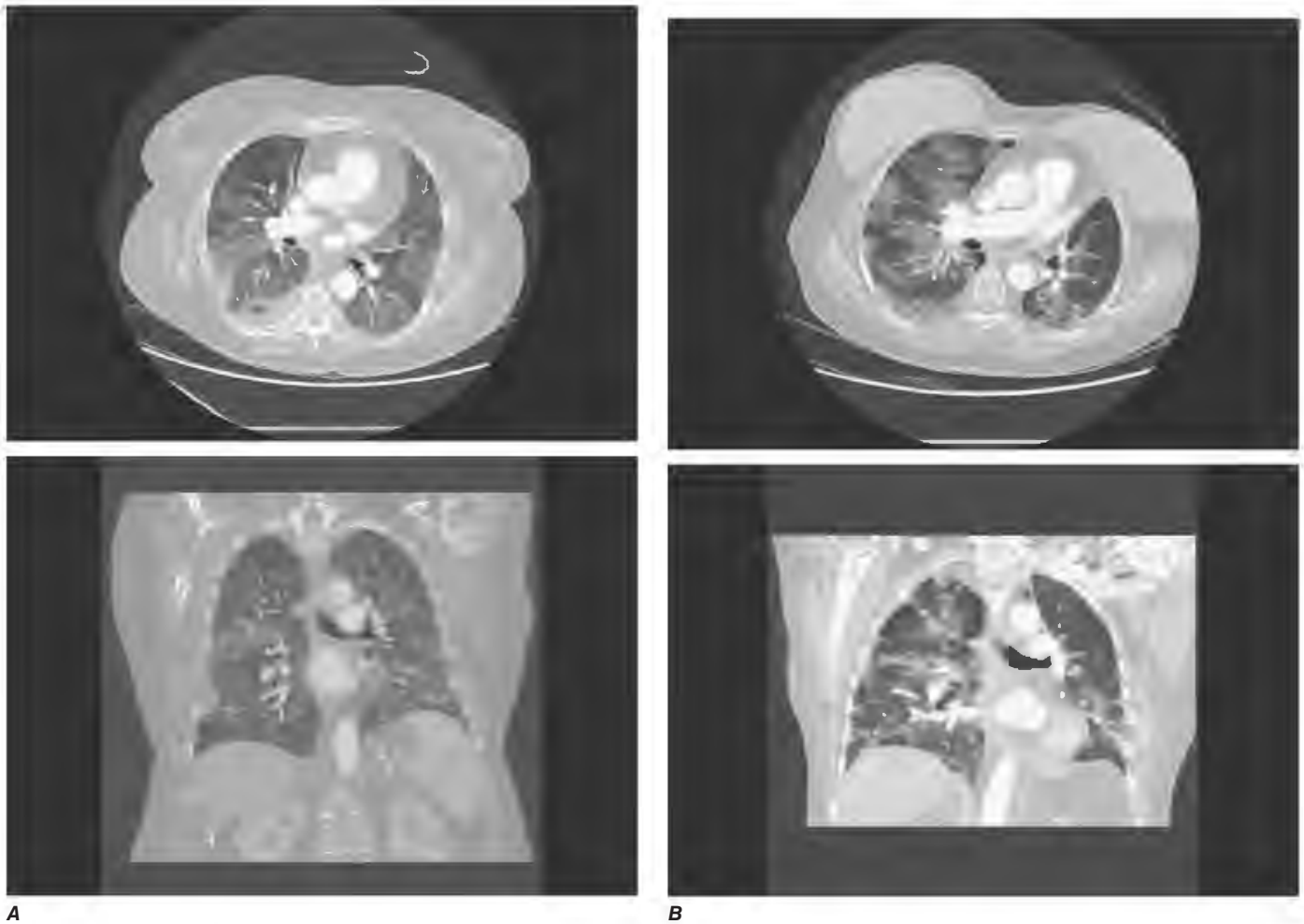

FIGURE 80-5 ***A.*** Computed tomography scan of a 63-year-old female with metastatic adenocarcinoma on nivolumab with immune check point inhibitor pneumonia showing interlobular septal thickening and diffuse ground-glass opacity to nivolumab. ***B.*** Computed tomography scan of a 68-year-old female with resected adenocarcinoma of lung and COVID-19 pneumonia showing peripheral and basilar predominant patchy ground-glass and consolidative opacity consistent with multifocal COVID pneumonia.

Pneumonia is a common problem in patients undergoing treatment for cancer (Chap 79). In patients with pulmonary infiltrates who are afebrile, heart failure and multiple pulmonary emboli are in the differential diagnosis.

NEUTROPENIC ENTEROCOLITIS

Neutropenic enterocolitis (typhlitis) is the inflammation and necrosis of the cecum and surrounding tissues that may complicate the treatment of acute leukemia. Nevertheless, it may involve any segment of the gastrointestinal tract including small intestine, appendix, and colon. This complication has also been seen in patients with other forms of cancer treated with taxanes, 5-fluorouracil, irinotecan, vinorelbine, cisplatin, carboplatin, sacituzumab govitecan, and high-dose chemotherapy (Fig. 80-6). It also has been reported in patients with AIDS, aplastic anemia, cyclic neutropenia, idiosyncratic drug reactions involving antibiotics, and immunosuppressive therapies. The patient develops right lower quadrant abdominal pain, often with rebound tenderness and a tense, distended abdomen, in a setting of fever and neutropenia. Watery diarrhea (often containing sloughed mucosa) and bacteremia are common, and bleeding may occur. Plain abdominal films are generally of little value in the diagnosis; CT scan may show marked bowel wall thickening, particularly in the cecum, with bowel wall edema, mesenteric stranding, and ascites, and may help to differentiate neutropenic colitis from other abdominal disorders such as appendicitis, diverticulitis, and *Clostridium difficile*–associated colitis in this high-risk population. Patients with bowel wall thickness >10 mm on ultrasonogram have higher mortality rates. However, bowel wall thickening is significantly more prominent in patients with *C. difficile* colitis. Pneumatosis intestinalis is a more specific finding, seen only in those with neutropenic enterocolitis and ischemia. The combined involvement of the small and large bowel suggests a diagnosis of neutropenic enterocolitis. Rapid institution of broad-spectrum antibiotics, bowel rest, and nasogastric suction may reverse the process. Use of myeloid growth factors improved outcome significantly. Surgical intervention is reserved for severe cases of neutropenic enterocolitis with evidence of perforation, peritonitis, gangrenous bowel, or gastrointestinal hemorrhage despite correction of any coagulopathy.

C. difficile colitis is increasing in incidence. Newer strains of *C. difficile* produce ~20 times more of toxins A and B compared to previously studied strains. *C. difficile* risk is also increased with chemotherapy. Antibiotic coverage for *C. difficile* should be added if pseudomembranous colitis cannot be excluded.

A

B

FIGURE 80-6 Abdominal computed tomography (CT) scans of a 72-year-old woman with neutropenic enterocolitis secondary to chemotherapy. *A.* Air in inferior mesenteric vein (*arrow*) and bowel wall with pneumatosis intestinalis. ***B.*** CT scan of upper abdomen demonstrating air in portal vein (*arrows*).

HEMORRHAGIC CYSTITIS

Hemorrhagic cystitis is characterized by diffuse bladder mucosal bleeding that develops secondary to chemotherapy (mostly cyclophosphamide or ifosfamide), radiation therapy, bone marrow transplantation (BMT), and/or opportunistic infections. Both cyclophosphamide and ifosfamide are metabolized to acrolein, which is a strong chemical irritant that is excreted in the urine. Prolonged contact or high concentrations may lead to bladder irritation and hemorrhage. Symptoms include gross hematuria, frequency, dysuria, burning, urgency, incontinence, and nocturia. The best management is prevention. Maintaining a high rate of urine flow minimizes exposure. In addition, 2-mercaptoethanesulfonate (mesna) detoxifies the metabolites and can be coadministered with the instigating drugs. Mesna usually is given three times on the day of ifosfamide administration in doses that are each 20% of the total ifosfamide dose. If hemorrhagic cystitis develops, the maintenance of a high urine flow may be sufficient supportive care. If conservative management is not effective, irrigation of the bladder with alum or formalin solution may stop the bleeding in most cases. *N*-Acetylcysteine may also be an effective irrigant. Prostaglandin (carboprost) can inhibit the process. In extreme cases, ligation of the hypogastric arteries, urinary diversion, or cystectomy may be necessary.

In the BMT setting, early-onset hemorrhagic cystitis is related to drugs in the treatment regimen (e.g., cyclophosphamide), and late-onset hemorrhagic cystitis is usually due to the polyoma virus BKV or adenovirus type 11. BKV load in urine alone or in combination with acute graft-versus-host disease correlates with development of hemorrhagic cystitis. Viral causes are usually detected by polymerase chain reaction (PCR)–based diagnostic tests. Treatment of viral hemorrhagic cystitis is largely supportive, with reduction in doses of immunosuppressive agents, if possible. No antiviral therapy is approved, although cidofovir was reported to be effective in a small series. Hyperbaric oxygen therapy has been used successfully in patients with BKV-associated and cyclophosphamide-induced hemorrhagic cystitis during hematopoietic stem cell transplantation, as well as in hemorrhagic radiation cystitis that occurs in up to 5% of patients after pelvic radiation.

HYPERSENSITIVITY REACTIONS TO ANTINEOPLASTIC DRUGS

Many antineoplastic drugs may cause hypersensitivity reaction. These reactions are unpredictable and potentially life threatening. Most reactions occur during or within hours of parenteral drug administration. Taxanes, platinum compounds, asparaginase, etoposide, procarbazine, and biologic agents, including rituximab, bevacizumab, trastuzumab, gemtuzumab, cetuximab, and alemtuzumab, are more commonly associated with acute hypersensitivity reactions than are other agents. Hypersensitivity reactions to some drugs, such as taxanes, occur during the first or second dose administered. Hypersensitivity to platinum compounds occurs after prolonged exposure. Skin testing may identify patients with high risk for hypersensitivity after carboplatin exposure.

Premedication with histamine H_1 and H_2 receptor antagonists and glucocorticoids reduces the incidence of hypersensitivity reaction to taxanes, particularly paclitaxel. Despite premedication, hypersensitivity reactions may still occur. In these cases, rapid desensitization in the intensive care unit setting or re-treatment may be attempted with care, but the use of alternative agents may be required. Skin testing is used to assess the involvement of IgE in the reaction. Tryptase levels measured at the time of the reaction help to explain the mechanism of the reaction and its severity. Increased tryptase levels indicate underlying mast cell activation. Candidate patients for desensitization include those who have mild to severe hypersensitivity type I, with mast cell–mediated and IgE-dependent reactions occurring during a chemotherapy infusion or shortly thereafter.

FURTHER READING

Azizi AH et al: Superior vena cava syndrome. JACC Cardiovasc Interv 13:2896, 2020.

Castells M et al: Hypersensitivity to antineoplastic agents: Mechanisms and treatment with rapid desensitization. Cancer Immunol Immunother 61:1575, 2012.

Castinetti F et al: Endocrine side-effects of new anticancer therapies: Overall monitoring and conclusions. Ann Endocrinol (Paris) 79:591, 2018.

Conte P et al: Drug-induced interstitial lung disease during cancer therapies: Expert opinion on diagnosis and treatment. ESMO Open 7:1, 2022.

Durani U, Hogan WJ: Emergencies in haematology: Tumour lysis syndrome. Br J Haematol 188:494, 2020.

Fajgenbaum DC, June CH: Cytokine storm. N Engl J Med 383:2255, 2020.

Gonzalez Castro LN, Milligan TA: Seizures in patients with cancer. Cancer 126:1379, 2020.

Lawton AJ et al: Assessment and management of patients with metastatic spinal cord compression: A multidisciplinary review. J Clin Oncol 37:61, 2019.

Paik WH, Park DH: Endoscopic management of malignant biliary obstruction. Gastrointest Endosc Clin N Am 34:127, 2024

Schusler R, Meyerson SL: Pericardial disease associated with malignancy. Curr Cardiol Rep 20:92, 2018.

Thomas MR, Scully M: How I treat microangiopathic hemolytic anemia in patients with cancer. Blood 137:1310, 2021.

Vogelbaum MA et al: Treatment for brain metastases: ASCO-SNO-ASTRO Guideline. J Clin Oncol 4:492, 2022.

81 Cancer of the Skin

Brendan D. Curti, John T. Vetto, Sancy A. Leachman

MELANOMA

Pigmented lesions are among the most common findings on skin examination. The challenge for the physician is to distinguish benign lesions from cutaneous melanomas and nonmelanoma skin cancers (NMSCs), both of which are increasing in frequency. Melanoma accounts for over half of the deaths resulting from skin cancer, although recent advances in immunotherapy and targeted therapy used in the neoadjuvant, adjuvant, and advanced disease settings have significantly improved survival. Genomic analysis of melanoma has improved our understanding of prognosis, and informed treatment and surveillance strategies beyond traditional surgical staging. Melanoma is an aggressive malignancy of melanocytes, pigment-producing cells that originate from the neural crest and migrate to the skin, meninges, mucous membranes, upper esophagus, and eyes. Melanocytes in each of these locations have the potential for malignant transformation, but most melanomas arise in the skin, facilitating detection when complete surgical excision can lead to cure. Cutaneous melanoma occurs in people of all ages and all colors. Noncutaneous melanomas have a different biology and a lower probability of response to the immunotherapy agents that have transformed the care of cutaneous melanoma. Examples of malignant melanoma of the skin, mucosa, eye, and nail are shown in **Fig. 81-1**.

RISK FACTORS AND EPIDEMIOLOGY

The epidemiologic patterns seen in melanoma reflect the genetic and biologic features of melanocytes and their response to environmental ultraviolet radiation (UVR). Clinical features that confer an increased risk for melanoma include: (1) vulnerability to sun damage (light/red coloration of skin, hair, or eyes; photodamaged skin; history of exposure to natural or artificial UVR; prior history of skin cancers of any type); (2) abnormal growth of melanocytes (increased absolute number of nevi, increased size of nevi, or atypical features of moles such as multiple colors, speckles, or shapes); and (3) immunosuppression (innate, functional, or drug-induced). **Table 81-1** summarizes melanoma risk factors and the relative risk associated with these factors.

The incidence and mortality rates are strongly influenced by ethnic, geographic, and environmental factors. For instance, the incidence of melanoma is 1/100,000 per year in populations with high skin eumelanin (a brown-black pigment that absorbs ultraviolet [UV] photons efficiently as they enter the epidermis) and up to 27/100,000 per year in populations with low skin eumelanin. Men are affected slightly more than women (1.4:1), and the median age at diagnosis is 66. Melanoma is one several cancer types with increasing incidence in the United States and is now the fifth leading cancer in men (59,170 new cases in 2024; probability 1:28) and the sixth leading cancer in women (41,460 new cases in 2024; probability 1:41). Although these rankings are based on the total number of new invasive melanoma cases in 2024, estimated at 100,640, an additional 99,700 cases of melanoma in situ (MIS) occurred in 2024.

Mortality rates begin to rise at age 55, with the greatest mortality in men age >65 years. In contrast to the increasing incidence, the mortality rates for melanoma are decreasing, though this trend appears less dramatic outside of the United States. The most likely reason for the decreased mortality is the influence of immunotherapy and targeted therapy on melanoma-specific survival. After U.S. Food and Drug Administration (FDA) approval of ipilimumab and vemurafenib in 2011, the 1-year relative survival rate increased from 42% (2008–2010) to 55% (2013–2015). The mortality rate from 2013 to 2017 dropped annually by 7% in those aged 20–64 years old and dropped 5–6% per year for individuals aged ≥65 years.

GLOBAL CONSIDERATIONS

The incidence of both nonmelanoma and melanoma skin cancers around the world has been increasing. Every year, between 2 and 3 million people develop NMSC, and in 2020, there were 324,635 cases of melanoma. A disproportionate number of cases and deaths occur in North America, Europe, Australia, and New Zealand. The highly variable melanoma incidence rates in different populations are due to the interplay between risk factors, including host genetics and environmental factors, which distribute risk unevenly across these populations and account for the absolute risk in different ethnic groups and geographic areas.

Dark-skinned populations (such as those of India and Puerto Rico), blacks, and East Asians also develop melanoma but at rates 10–20 times lower than those in whites. Cutaneous melanomas in dark-skinned populations are more often diagnosed at a higher stage, and patients tend to have worse outcomes. Surveillance, Epidemiology, and End Results (SEER) data (2016–2020) reveal that whites have the highest incidence of melanoma at 37.9 (men) and 25.2 (women) per 100,000 and that the incidence drops substantially in Hispanics (4.5 [men] and 4.3 [women] per 100,000), Native Americans (8.7 [men] and 7.8 [women] per 100,000), Asians/Pacific Islanders (1.3 [men] and 1.1 [women] per 100,000), and blacks (1 [men] and 0.9 [women] per 100,000). In nonwhite (Asian and dark-skinned) populations, the