National Comprehensive Cancer Network®

NCCN Clinical Practice Guidelines in Oncology (NCCN Guidelines®)

Central Nervous System Cancers

Version 3.2025 — December 5, 2025

NCCN.org

NCCN recognizes the importance of clinical trials and encourages participation when applicable and available. Trials should be designed to maximize inclusiveness and broad representative enrollment.

NCCN Guidelines for Patients® available at www.nccn.org/patients

Version 3.2025, 12/05/25 © 2025 National Comprehensive Cancer Network® (NCCN®), All rights reserved. NCCN Guidelines® and this illustration may not be reproduced in any form without the express written permission of NCCN.

PLEASE NOTE that use of this NCCN Content is governed by the End-User License Agreement, and you MAY NOT distribute this Content or use it with any artificial intelligence model or tool.
Printed by A. S. M. FAZLUL KARIM CHOWDHURY on 4/20/2026 3:06:38 AM. Copyright © 2026 National Comprehensive Cancer Network, Inc. All Rights Reserved.

***Louis Burt Nabors, MD/Chair** Ψ
O'Neal Comprehensive Cancer Center at UAB

***Jana Portnow, MD/Vice-Chair † Ψ**
City of Hope National Medical Center

Joachim Baehring, MD Ψ
Yale Cancer Center/Smilow Cancer Hospital

Ankush Bhatia, MD Ψ
University of Wisconsin
Carbone Cancer Center

Orin Bloch, MD Ψ ¶
UC Davis Comprehensive Cancer Center

Steven Brem, MD ¶
Abramson Cancer Center
at the University of Pennsylvania

Nicholas Butowski, MD Ψ **†**
UCSF Helen Diller Family
Comprehensive Cancer Center

Donald M. Cannon, MD §
Huntsman Cancer Institute
at the University of Utah

Samuel T. Chao, MD §
Case Comprehensive Cancer Center/
University Hospitals Seidman Cancer Center and
Cleveland Clinic Taussig Cancer Institute

Milan G. Chheda, MD Ψ
Siteman Cancer Center at Barnes-
Jewish Hospital and Washington
University School of Medicine

Andrew J. Fabiano, MD, MBA ¶
Roswell Park Comprehensive Cancer Center

Kristyn Galbraith, MD ≠
Fred Hutchinson Cancer Center

Pierre Giglio, MD Ψ
The Ohio State University Comprehensive
Cancer Center - James Cancer Hospital
and Solove Research Institute

Patrick T. Grogan, MD, PhD † Ψ
Moffitt Cancer Center

Jona Hattangadi-Gluth, MD §
UC San Diego Moores Cancer Center

Thomas J. Kaley, MD Ψ
Memorial Sloan Kettering Cancer Center

Michelle M. Kim, MD §
University of Michigan Rogel Cancer Center

Stephen T. Magill, MD, PhD Ψ **¶**
Robert H. Lurie Comprehensive Cancer Center of
Northwestern University

Ryan Merrell, MD Ψ
Vanderbilt-Ingram Cancer Center

Maciej M. Mrugala, MD, PhD, MPH Ψ
Mayo Clinic Comprehensive Cancer Center

Seema Nagpal, MD † Ψ
Stanford Cancer Institute

Lucien A. Nedzi, MD §
St. Jude Children's Research Hospital/
The University of Tennessee
Health Science Center

Kathryn Nevel, MD Ψ
Indiana University Melvin and Bren Simon
Comprehensive Cancer Center

Douglas E. Ney, MD Ψ
University of Colorado Cancer Center

Phioanh L. Nghiemphu, MD †
UCLA Jonsson Comprehensive Cancer Center

Ian Parney, MD, PhD Ψ **¶**
Mayo Clinic Comprehensive Cancer Center

Toral R. Patel, MD ¶
UT Southwestern Simmons
Comprehensive Cancer Center

Katherine B. Peters, MD, PhD Ψ
Duke Cancer Institute

Marco C. Pinho, MD ф
UT Southwestern Simmons
Comprehensive Cancer Center

Scott Plotkin, MD, PhD Ψ
Dana-Farber/Brigham and Women's Cancer
Center|Mass General Cancer Center

Vinay K. Puduvalli, MD Ψ
The University of Texas
MD Anderson Cancer Center

Solmaz Shaebjam, MD †
Johns Hopkins Kimmel Cancer Center

Nicole Shonka, MD † Ψ
Fred and Pamela Buffet Cancer Center

Lauren Singer, MD Ψ
The UChicago Medicine
Comprehensive Cancer Center

Lode J. Swinnen, MBChB ‡ † Ψ
Johns Hopkins Kimmel Cancer Center

Stephanie E. Weiss, MD §
Fox Chase Cancer Center

Nicole E. Willmarth, PhD ¥
American Brain Tumor Association

NCCN
Mary Anne Bergman
Swathi Ramakrishnan, PhD

NCCN Guidelines Panel Disclosures

ф Diagnostic/Interventional radiology
‡ Hematology/Hematology oncology
† Medical oncology
Ψ Neurology/Neuro-oncology
≠ Pathology
¥ Patient advocacy
§ Radiation/Radiation oncology
¶ Surgery/Surgical oncology
* Discussion Section Writing Committee

Version 3.2025, 12/05/25 © 2025 National Comprehensive Cancer Network® (NCCN®), All rights reserved. NCCN Guidelines® and this illustration may not be reproduced in any form without the express written permission of NCCN.

PLEASE NOTE that use of this NCCN Content is governed by the End-User License Agreement, and you MAY NOT distribute this Content or use it with any artificial intelligence model or tool.
Printed by A. S. M. FAZLUL KARIM CHOWDHURY on 4/20/2026 3:06:38 AM. Copyright © 2026 National Comprehensive Cancer Network, Inc. All Rights Reserved.

NCCN Guidelines Version 3.2025
Central Nervous System Cancers

NCCN Central Nervous System Cancers Panel Members

Summary of the Guidelines Updates

Adult Glioma:
- Circumscribed Glioma (GLIO-1)
- Oligodendroglioma (*IDH*-mutant, 1p19q codeleted) (GLIO-2)
- *IDH*-Mutant Astrocytoma (GLIO-4)
- Recurrent or Progressive Circumscribed Glioma (GLIO-7)
- Recurrent Oligodendroglioma and Astrocytoma (WHO Grade 2) (GLIO-8)
- High Grade (GLIO-9)
- Glioblastoma (GLIO-10)
- High-Grade Glioma: Other (GLIO-12)
- Recurrent or Progressive Disease (WHO Grades 3 & 4) (GLIO-13)
- Adult Glioma Systemic Therapy Options (GLIO-A)

Adult Intracranial and Spinal Ependymoma (Excluding Subependymoma) (EPEN-1)
- Systemic Therapy (EPEN-A)

Adult Medulloblastoma (AMED-1)
- Systemic Therapy (AMED-A)

Primary CNS Lymphoma (PCNS-1)
- Systemic Therapy (PCNS-A)

Primary Spinal Cord Tumors (PSCT-1)
- Systemic Therapy (PSCT-A)

Meningiomas (MENI-1)
- Systemic Therapy (MENI-A)

Limited Brain Metastases (LTD-1)
Extensive Brain Metastases (MU-1)
- Brain Metastases: Systemic Therapy (BRAIN METS-A)

Leptomeningeal Metastases (LEPT-1)
- Systemic Therapy (LEPT-A)

Metastatic Spine Tumors (SPINE-1)

Principles of:
- Brain and Spine Tumor Imaging (BRAIN-A)
- Surgery (BRAIN-B)
- Radiation Therapy for Brain and Spinal Cord (BRAIN-C)
- Brain and Spine Tumor Management (BRAIN-D)
- Brain Tumor Pathology (BRAIN-E)
- Cancer Risk Assessment and Counseling (BRAIN-F)
- Abbreviations (ABBR-1)

Find an NCCN Member Institution: https://www.nccn.org/home/member-institutions.

NCCN Categories of Evidence and Consensus: All recommendations are category 2A unless otherwise indicated.

See NCCN Categories of Evidence and Consensus.

NCCN Categories of Preference: All recommendations are considered appropriate.

See NCCN Categories of Preference.

The NCCN Guidelines® are a statement of evidence and consensus of the authors regarding their views of currently accepted approaches to treatment. Any clinician seeking to apply or consult the NCCN Guidelines is expected to use independent medical judgment in the context of individual clinical circumstances to determine any patient's care or treatment. The National Comprehensive Cancer Network® (NCCN®) makes no representations or warranties of any kind regarding their content, use or application and disclaims any responsibility for their application or use in any way. The NCCN Guidelines are copyrighted by National Comprehensive Cancer Network®. All rights reserved. The NCCN Guidelines and the illustrations herein may not be reproduced in any form without the express written permission of NCCN. ©2025.

PLEASE NOTE that use of this NCCN Content is governed by the End-User License Agreement, and you MAY NOT distribute this Content or use it with any artificial intelligence model or tool.
Printed by A. S. M. FAZLUL KARIM CHOWDHURY on 4/20/2026 3:06:38 AM. Copyright © 2026 National Comprehensive Cancer Network, Inc. All Rights Reserved.

Updates in Version 3.2025 of the NCCN Guidelines for Central Nervous System Cancers from Version 2.2025 include:

PSCT-A
- Selumetinib (category 1) added as a Useful in certain circumstances treatment option and mirdametinib updated as a treatment option for (patients with neurofibromatosis type 1 [NF1] who have symptomatic plexiform neurofibromas [PN] not amenable to complete resection)
  - Reference: Chen AP, Coyne GO, Wolters PL, et al. Efficacy and safety of selumetinib in adults with neurofibromatosis type 1 and symptomatic, inoperable plexiform neurofibromas (KOMET): a multicentre, international, randomised, placebo-controlled, parallel, double-blind, phase 3 study. The Lancet. 2025; 405(10496):2217-2230.
- Long-term follow-up added to reference 3 for mirdametinib: Hirbe AC, Moertel CL, Shuhaiber HH, et al. Update from the long-term follow-up (LTFU) Phase of ReNeu: A pivotal phase 2b trial of mirdametinib in children and adults with neurofibromatosis type 1 (NF1)-associated symptomatic plexiform neurofibroma (PN). Presented at the 2025 Children's Tumor Foundation NF Conference, June 21-24, 2025, Washington, DC.

BRAIN METS-A
- Following footnote added to all instances of pembrolizumab: *Pembrolizumab and berahyaluronidase alfa-pmph subcutaneous injection may be substituted for IV pembrolizumab. Pembrolizumab and berahyaluronidase alfa-pmph has different dosing and administration instructions compared to IV pembrolizumab.*

Updates in Version 2.2025 of the NCCN Guidelines for Central Nervous System Cancers from Version 1.2025 include:

GLIO-A 6
- Dordaviprone added as a Useful in certain circumstances treatment option for recurrent or progressive disease high-grade glioma harboring an H3K27M mutation.
  - Reference: Arrillaga-Romany I, Gardner SL, Odia Y, et al. ONC201 (dordaviprone) in recurrent H3K27M-Mutant diffuse midline glioma. J Clin Oncol. 2024;42:1542-1552.

Updates in Version 1.2025 of the NCCN Guidelines for Central Nervous System Cancers from Version 5.2024 include:

Global
- Follow-up throughout the GLIO section refers the reader to Principles of Brain and Spine Tumor Imaging BRAIN-A.
- New footnote throughout the systemic therapy section: *An FDA-approved biosimilar is an appropriate substitute for any recommended systemic biologic therapy in the NCCN Guidelines*.
- References have been updated throughout the guidelines.

GLIO-1

Pathology
- WHO grade 2, bullet 2 deleted glioneuronal tumors.
- Added WHO grade 3.
- If *IDH*-mutant astrocytoma, *for grade 4, see GLIO-6.*

Adjuvant Treatment
- Sub-sub-bullet 3, modified: Consider BRAF and MEK inhibitors if *BRAF alterations.* ~~V600E-activating mutation~~

Footnotes
- b, modified: Principles of ~~Brain and Spine Tumor~~ Surgery (BRAIN-B).
- e, new: The Panel strongly recommends multidisciplinary discussion of patients with newly diagnosed or recurrent or progressive gliomas (any grade) or referring such patients to a brain tumor center for a consultation. Similarly, if treatment with an IDH inhibitor is being considered for a patient with newly diagnosed oligodendroglioma or astrocytoma, the Panel strongly recommends multidisciplinary discussion or referral to a brain tumor center for consultation. (Also for GLIO-2A, GLIO-3, GLIO-4A, GLIO 5A, GLIO-6, GLIO-8, GLIO-9).

Continued

Version 3.2025, 12/05/25 © 2025 National Comprehensive Cancer Network® (NCCN®), All rights reserved. NCCN Guidelines® and this illustration may not be reproduced in any form without the express written permission of NCCN.

PLEASE NOTE that use of this NCCN Content is governed by the End-User License Agreement, and you MAY NOT distribute this Content or use it with any artificial intelligence model or tool.
Printed by A. S. M. FAZLUL KARIM CHOWDHURY on 4/20/2026 3:06:38 AM. Copyright © 2026 National Comprehensive Cancer Network, Inc. All Rights Reserved.

Updates in Version 1.2025 of the NCCN Guidelines for Central Nervous System Cancers from Version 5.2024 include:

GLIO-2
Adjuvant Treatment
Good PS (KPS ≥60)
- No residual*/measurable disease or,*
  - *IDH inhibitor or,*
  - *Consider clinical trial*
- Residual*/measurable disease* or recurrent tumor after resection or biopsy ~~and~~ *when* upfront treatment with RT and chemotherapy is not preferred.
  - *Consider clinical trial.*

Poor PS (KPS <60)
- IDH inhibitor (moved up from the 2nd bullet).

Consider clinical trial.

GLIO-2A
Footnotes
- Deleted: Principles of Brain and Spine Tumor Imaging (BRAIN-A). (Also for GLIO-4A, GLIO-5A).
- l, new: Patients with newly diagnosed grade 2 oligodendroglioma who have undergone gross total resection of tumor might remain progression free for many years; therefore, initially observing these patients is reasonable. Byeon Y, et al. Discov Oncol 2024;15:268.
- m, modified to include the following sentence: Overall survival data from this study are not yet available. Ivosidenib is an IDH1 inhibitor and is a reasonable alternative if a patient cannot tolerate vorasidenib. Byeon Y, et al. Discov Oncol 2024;15:268. (Also for GLIO-4A).
- n, new: Newly diagnosed patients with oligodendroglioma/astrocytoma (WHO grade 2 or 3) who did not have residual disease were excluded from participation in the phase 3 INDIGO study of vorasidenib versus placebo. Therefore, it remains unknown if this subset of patients would benefit from immediate treatment with an IDH inhibitor. The safety of long-term treatment with IDH inhibitors is unknown. The Panel recommends discussing the possible risks and benefits of starting treatment right away with an IDH inhibitor with these patients. (Also for GLIO-4A).
- Deleted: Ivosidenib is an IDH1 inhibitor and is a reasonable alternative if a patient with IDH1-mutated grade 2 oligodendroglioma cannot tolerate vorasidenib. (Byeon et al., Oligodendroglioma in adult patients: a single-institution experience. Discover Oncology 2024; 15:268). (Also for GLIO-4A).
- p, new: If a patient has a KPS <60 due to neurologic deficits from the brain tumor, then RT + temozolomide would be the preferred treatment. However, if a patient has a KPS <60 for other reasons, such as medical comorbidities, then treatment with an IDH inhibitor would be reasonable since it may be tolerated better than radiation and/or cytotoxic chemotherapy.(Also for GLIO-3, GLIO-4A, GLIO-5A).

GLIO-3
Adjuvant Treatment
Good PS (KPS ≥60)
- Added: IDH inhibitor (category 2B).

Poor PS (KPS <60)
- Added: Consider clinical trial.
- Added: IDH inhibitor (category 2B).

Footnotes
- s, new: Some Panel members felt that given the relatively slow growth rate of oligodendrogliomas, in certain circumstances it would be reasonable to first try treatment with an IDH inhibitor. However, other Panel members expressed concern about possible undertreatment of these patients by postponing the start of radiation and cytotoxic chemotherapy, which have been shown to improve survival in newly diagnosed grade 3 oligodendroglioma patients (van den Bent MJ, et al. J clin Oncol 2013;31:344-350; Cairncross G, et al. J Clin Oncol 2013;31:337-343).Newly diagnosed grade 3 oligodendroglioma patients who start treatment with an IDH inhibitor should be followed closely with brain MRIs. See Principles of Brain and Spine Tumor Management (BRAIN-D).

Version 3.2025, 12/05/25 © 2025 National Comprehensive Cancer Network® (NCCN®), All rights reserved. NCCN Guidelines® and this illustration may not be reproduced in any form without the express written permission of NCCN.

PLEASE NOTE that use of this NCCN Content is governed by the End-User License Agreement, and you MAY NOT distribute this Content or use it with any artificial intelligence model or tool.
Printed by A. S. M. FAZLUL KARIM CHOWDHURY on 4/20/2026 3:06:38 AM. Copyright © 2026 National Comprehensive Cancer Network, Inc. All Rights Reserved.

Updates in Version 1.2025 of the NCCN Guidelines for Central Nervous System Cancers from Version 5.2024 include:

GLIO-4
Adjuvant treatment
Good PS (KPS ≥60)
- No *residual*/measurable disease or,
  - *IDH inhibitor* or,
  - *Consider clinical trial.*
- Residual*/measurable disease* or recurrent tumor after resection or biopsy when upfront treatment with RT and chemotherapy is not preferred.
  - *IDH inhibitor* or,
  - *Consider clinical trial.*

Poor PS (KPS<60)
- *Consider clinical trial.*

GLIO-4A
Footnotes
- t, new: Grade 2 astrocytomas are relatively slow growing and may not require further treatment for several years. Therefore, initial observation after gross total resection is reasonable.
- u, new: The Panel acknowledges that compared to grade 2 oligodendrogliomas, grade 2 astrocytomas typically progress faster. Therefore, delaying the need for radiation and cytotoxic chemotherapy by starting treatment with an IDH inhibitor in a grade 2 astrocytoma patient who has undergone gross total resection of tumor may also be a reasonable approach.

GLIO-5
- Deleted, WHO grade 4.
- Grade 3, modified:
  - Good PS, KPS ≥60, added: IDH inhibitor (category 2B).
  - Poor PS, KPS <60, added: IDH inhibitor (category 2B).

GLIO-5A
Footnotes
- Deleted: Treatment of grade 4 disease is extrapolated from interim analyses of data from the CATNON study. Final results of CATNON are not yet available.
- v, new: Strict histopathologic criteria do not currently exist for definitively diagnosing a WHO grade 2 versus a WHO grade 3 *IDH*-mutated astrocytoma. Therefore, some Panel members felt that it may be reasonable to try treating patients with newly diagnosed *IDH*-mutated grade 3 astrocytoma up front with an IDH inhibitor in certain circumstances. This includes, but is not limited to, if the enhancing portion of the tumor has been resected, and all the remaining tumor is non-enhancing, probable grade 2 tumor. Other Panel members disagreed with this approach due to possibly undertreating a patient by postponing the start of radiation and cytotoxic chemotherapy, which have been shown to improve survival (van den Bent MJ, et al. Lancet Oncol 2021;22:813-823).

GLIO-6
- Added, WHO grade 4.

GLIO-7
Footnotes
- z: modified, *See* Principles of Brain and Spine Tumor Imaging (BRAIN-A) *for imaging recommendations to assess disease recurrence/progression*. (Also for GLIO-8).

Continued

Version 3.2025, 12/05/25 © 2025 National Comprehensive Cancer Network® (NCCN®), All rights reserved. NCCN Guidelines® and this illustration may not be reproduced in any form without the express written permission of NCCN.

PLEASE NOTE that use of this NCCN Content is governed by the End-User License Agreement, and you MAY NOT distribute this Content or use it with any artificial intelligence model or tool.
Printed by A. S. M. FAZLUL KARIM CHOWDHURY on 4/20/2026 3:06:38 AM. Copyright © 2026 National Comprehensive Cancer Network, Inc. All Rights Reserved.

Updates in Version 1.2025 of the NCCN Guidelines for Central Nervous System Cancers from Version 5.2024 include:

GLIO-A (1 of 9)
Circumscribed Glioma
Recurrent or Progressive Disease
Useful in Certain Circumstances
- Modified, *BRAF alterations* ~~V600E activation mutation~~
  - *BRAF fusion or rearrangement, or BRAF V600 mutation* ~~MEK inhibitors~~
    - ◊ New: Tovorafenib category 2A recommendation.
- MEK inhibitor
  - ◊ New: Trametinib (for *BRAF* only) category 2A recommendation.

GLIO-A (2 of 9)
Oligodendroglioma (IDH-Mutant, 1p19q-Codeleted)
- Modified: *No residual/*measurable *disease or* adjuvant treatment after surgery/biopsy ~~and~~ *when* treatment with RT and chemotherapy is not preferred, WHO grade 2, KPS ≥60.

Preferred
- Modified: Vorasidenib ~~(if residual disease is present)~~ (category 1 *for residual/measurable disease after surgery/biopsy) for IDH1 or IDH2 mutations.*

Useful in Certain Circumstances
- Modified: Ivosidenib for *IDH1* mutation *(if unable to tolerate vorasidenib).*

Adjuvant Treatment WHO grade 3, KPS ≥60.
Useful in Certain Circumstances
- New:
  - Ivosidenib for *IDH1* mutation (if unable to tolerate vorasidenib) (category 2B) *recommendation (Also for GLIO-A 4).*
  - Vorasidenib for *IDH1* or *IDH2* mutations (category 2B) recommendation *(Also for GLIO-A 4).*
- Modified: Adjuvant Treatment, KPS <60 ~~WHO grade 3.~~

Other Recommended
- New:
  - *Ivosidenib for IDH1 mutation (if unable to tolerate vorasidenib) (category 2B for WHO grade 3).*
  - *Vorasidenib for IDH1 or IDH2 mutations (category 2B for WHO grade 3).*

Useful in Certain Circumstances
- Deleted:
  - Ivosidenib for *IDH1* mutant grade 2.
  - Vorasidenib for *IDH1* or *IDH2* mutations and grade 2.

Recurrent or Progressive Disease after RT + chemotherapy WHO grade 2, KPS ≥60.
Preferred
- Bullet 4, modified: Ivosidenib for *IDH1* mutation *(if unable to tolerate vorasidenib) (Also for recurrent or progressive disease, WHO grade 3, KPS* ≥60, GLIO-4).

Recurrent or Progressive Disease, WHO grade 3, KPS ≥60.
Preferred
- Deleted: Category 2B for Vorasidenib for *IDH1* or *IDH2* mutations.
- New: Ivosidenib for *IDH1* mutation (if unable to tolerate vorasidenib).

Useful in Certain Circumstances
- Deleted: Ivosidenib for *IDH1* mutation.

Continued

Version 3.2025, 12/05/25 © 2025 National Comprehensive Cancer Network® (NCCN®), All rights reserved. NCCN Guidelines® and this illustration may not be reproduced in any form without the express written permission of NCCN.

PLEASE NOTE that use of this NCCN Content is governed by the End-User License Agreement, and you MAY NOT distribute this Content or use it with any artificial intelligence model or tool.
Printed by A. S. M. FAZLUL KARIM CHOWDHURY on 4/20/2026 3:06:38 AM. Copyright © 2026 National Comprehensive Cancer Network, Inc. All Rights Reserved.

Updates in Version 1.2025 of the NCCN Guidelines for Central Nervous System Cancers from Version 5.2024 include:

GLIO-A (3 of 9)
Footnotes
- g, modified: Vorasidenib is a dual inhibitor of *IDH1* and *IDH2* mutations. In a phase 3 study of vorasidenib versus placebo (Mellinghoff IK, et al. N Engl J Med 2023;389:589-601) in patients with residual or recurrent grade 2 IDH-mutant glioma (after surgery and no prior treatment), vorasidenib improved median PFS (27.7 months vs. 11.1 months), compared to placebo. *Vorasidenib has the most safety data in patients with newly diagnosed grade 2 IDH-mutant gliomas*. (Also for GLIO-A 5).
- h, new: Newly diagnosed patients with oligodendroglioma/astrocytoma (WHO grade 2 or 3) who did not have residual disease were excluded from participation in the phase 3 INDIGO study of vorasidenib versus placebo. Therefore, it remains unknown if this subset of patients would benefit from immediate treatment with an IDH inhibitor. The safety of long-term treatment with IDH inhibitors is unknown. The Panel recommends discussing the possible risks and benefits of starting treatment right away with an IDH inhibitor with these patients. (Also for GLIO-A 5).

GLIO-A (4 of 9)
IDH-Mutant Astrocytoma
- Modified: *No residual/*measurable *disease or* adjuvant treatment after surgery/biopsy ~~and~~ *when* treatment with RT and chemotherapy is not preferred, WHO grade 2, KPS ≥60.

Preferred
- Modified: Vorasidenib (category 1 for residual/measurable disease after surgery/biopsy) for *IDH1* or *IDH2* mutations.

Useful in Certain Circumstances
- Ivosidenib *for IDH1 mutation (if unable to tolerate vorasidenib).*

Adjuvant Treatment KPS <60
Useful in Certain Circumstances
- Modified, bullet 1: Ivosidenib *for IDH1 mutation (if unable to tolerate vorasidenib) (category 2B for grade 3).*
- Modified, bullet 2: Vorasidenib for *IDH1* or *IDH2* mutations *(category 2B for grade 3).*

Recurrent or Progressive Disease, WHO grade 3 or 4, KPS ≥60.
Preferred
- New, bullet 5: Ivosidenib for *IDH1* mutation (if unable to tolerate vorasidenib) (category 2B).

Useful in Certain Circumstances
- Moved: Ivosidenib for *IDH1* mutation (category 2B) to preferred above vorasidenib.

GLIO-A (6 of 9)
Glioblastoma
Recurrent or Progressive Disease
Preferred
- Deleted: Regorafenib.

Useful in Certain Circumstance
- New: *FGFR* alterations
  - Erdafitinib (category 2B) recommendation.
- Modified: *BRAF alterations*

Continued
UPDATES

Version 3.2025, 12/05/25 © 2025 National Comprehensive Cancer Network® (NCCN®), All rights reserved. NCCN Guidelines® and this illustration may not be reproduced in any form without the express written permission of NCCN.

PLEASE NOTE that use of this NCCN Content is governed by the End-User License Agreement, and you MAY NOT distribute this Content or use it with any artificial intelligence model or tool.
Printed by A. S. M. FAZLUL KARIM CHOWDHURY on 4/20/2026 3:06:38 AM. Copyright © 2026 National Comprehensive Cancer Network, Inc. All Rights Reserved.

Updates in Version 1.2025 of the NCCN Guidelines for Central Nervous System Cancers from Version 5.2024 include:

EPEN-2
Footnotes
- h, modified: Lumbar puncture is indicated when there is clinical concern for meningeal dissemination. Lumbar puncture should be done after MRI of spine is performed to avoid a false-positive imaging result. Lumbar puncture for ~~prompt~~ CSF ~~analysis~~ should be delayed at least 2 weeks after surgery to avoid possible false-positive cytology. Lumbar puncture may be contraindicated (eg, posterior fossa mass). *When available, CSF-tumor-derived DNA (tDNA) testing can be considered with CSF cytology to increase sensitivity of tumor cell detection and assessment of residual disease after surgery.* (Also for EPEN-3, EPEN-4, AMED-2, AMED-3).

EPEN-3
- Column 3, 3rd row, deleted cytology positive.

Footnotes
- m, modified: RT has been associated with improved disease control (Weber D, et al. Neuro Oncol 2015;17:588-595). ~~Given the different therapies available at recurrence, potential for salvage therapy~~ Close observation may be clinically appropriate in some cases (Kotecha R, et al. J Neurosurg Spine 2020;1:392-397).

PCNS-1
- Column 2, Bullet 1: Hold initiation of steroids, if possible, prior to diagnostic procedure. (Moved to first bullet from fourth).
- Column 3, new: Primary vitreoretinal lymphoma/primary CNS Lymphoma ocular variant.

Footnote
- f, modified: ~~Brain biopsy is recommended as the primary procedure to obtain diagnosis.~~ CSF analysis should include flow cytometry, CSF cytology, cell count, and possibly gene rearrangements, specifically the *IGH* heavy chain rearrangement, and CSF-tDNA. Polymerase chain reaction (PCR) of *MYD88* in the CSF is helpful. (Also for PCNS-2A).

PCNS-2
- This page has been significantly updated.

Footnote
- i, modified: CRu refers to no enhancement, any steroids, normal eye examination and negative CSF, or minimal contrast abnormality, any steroids, minor retinal pigment epithelium, and negative CSF ~~(Abrey LE, et al. J Clin Oncol 2005;23:5034-5043)~~. (Also for PCNS-3).
- k, modified: CSF analysis should include flow cytometry, CSF cytology, and *cell count*, and may consider gene rearrangements *and CSF-tDNA.*

PCNS-3
Footnote
- Deleted: A low KPS should not be a reason to withhold systemic therapy. KPS may improve dramatically after treatment.

PCNS-A
Primary CNS Lymphoma
Induction therapy
Useful in Certain Circumstances
- Bullet 2, first sub-bullet deleted: high-dose.

Relapsed or Refractory Disease
Useful in Certain Circumstances
- New: Zanubrutinib ± high-dose cytarabine (only at first recurrence; consider age and PS) Category 2A recommendation.

Continued

Version 3.2025, 12/05/25 © 2025 National Comprehensive Cancer Network® (NCCN®), All rights reserved. NCCN Guidelines® and this illustration may not be reproduced in any form without the express written permission of NCCN.

PLEASE NOTE that use of this NCCN Content is governed by the End-User License Agreement, and you MAY NOT distribute this Content or use it with any artificial intelligence model or tool.
Printed by A. S. M. FAZLUL KARIM CHOWDHURY on 4/20/2026 3:06:38 AM. Copyright © 2026 National Comprehensive Cancer Network, Inc. All Rights Reserved.

Updates in Version 1.2025 of the NCCN Guidelines for Central Nervous System Cancers from Version 5.2024 include:

MENI-1
Footnote
- a, modified: Multidisciplinary input for treatment planning if feasible. ~~See NCCN Guidelines for Genetic/Familial High-Risk Assessment: Breast, Ovarian, Pancreatic and Prostate~~.

MENI-2
Follow-Up
- New: Principles of Brain and Spine Tumor Imaging (BRAIN-A).
- Deleted: WHO grades 1, 2, and 3.

Footnote
- Deleted: Within the first 3 months after completion of RT and concomitant temozolomide, diagnosis of recurrence can be indistinguishable from pseudoprogression on neuroimaging.

LTD-1
Footnote
- Deleted: For secondary CNS lymphoma, treatment may include systemic treatment, WBRT or focal RT, or a combination.

LTD-2
Clinical Presentation
- Top and bottom pathways, flipped.

Treatment
- Top pathway, new: Surgical resection for management of mass effect or symptoms followed by SRS (BRAIN-C) to the surgical bed and other brain metastases or Systemic therapy in select patients.
  - Deleted: WBRT without HA ± memantine.
- Bottom pathway, modified: SRS ~~in select patients.~~

Footnote
- j, modified: SRS is preferred ~~when safe, especially~~ for low tumor volume ~~to both the resection cavity and any other non-resected brain metastases~~ *and when safe and feasible. For disease volume or distribution not feasible for SRS, consider HA-WBRT. Ideally, cognitive sparing radiotherapy should be employed in these settings.* ~~WBRT is generally not recommended but may be appropriate in some rare clinical circumstances.~~

LTD-3
Recurrence
- Modified, column 2, top pathway: Recurrent disease *after radiation*; local site.
- Deleted: Previous surgery only.
  - Previous WBRT or Prior SRS.
- Modified, column 2, bottom pathway: Recurrent disease *after radiation*; distant brain ± local recurrence.

Treatment
- Deleted, top pathway: Single-dose or fractionated stereotactic RT (SRT).
- Added, top and bottom pathway: SRS.
- Deleted, Row 2: Surgery followed by SRS or RT to the surgical bed or Single-dose (category 2B) or fractionated SRT or Consider systemic therapy.

LTD-3A
Footnotes
- i, 2nd sentence, new: *See* LTD-3 *for reirradiation doses for brain metastases.*

Continued

Version 3.2025, 12/05/25 © 2025 National Comprehensive Cancer Network® (NCCN®), All rights reserved. NCCN Guidelines® and this illustration may not be reproduced in any form without the express written permission of NCCN.

PLEASE NOTE that use of this NCCN Content is governed by the End-User License Agreement, and you MAY NOT distribute this Content or use it with any artificial intelligence model or tool.
Printed by A. S. M. FAZLUL KARIM CHOWDHURY on 4/20/2026 3:06:38 AM. Copyright © 2026 National Comprehensive Cancer Network, Inc. All Rights Reserved.

Updates in Version 1.2025 of the NCCN Guidelines for Central Nervous System Cancers from Version 5.2024 include:

LTD-3A, continued

Footnotes

- n, 2nd sentence, modified:Consider advanced MRI imaging, *including perfusion or spectroscopy*, multidisciplinary input, or observation with early repeat imaging.
- r, new: In certain cases, retreatment with radiation, (eg, WBRT or SRS) is possible. If patient cannot be treated with repeat radiation, other possible options include laser thermal ablation or palliative/best supportive care.

LTD-4

- Deleted: Revisions to LTD-4 have been incorporated into LTD-3 and this page has been deleted.

BRAIN-METS-A,1

Breast Cancer/HER2 positive

Preferred

- Modified: Tucatinib + trastuzumab + capecitabine (category 1) if previously treated with ≥*1* ~~or more anti-HER2–based~~ regimen~~s.~~
- Moved: Fam-trastuzumab deruxtecan-nxki from "Other Recommended" to Preferred.
  - Modified to include: *if previously treated with ≥1 regimen.*

Other Recommended Regimen

- New: Neratinib and T-DM1, (category 2A) recommendation.

Breast Cancer/HER2 low

Useful in Certain Circumstances

- Modified: *Fam-trastuzumab deruxtecan-nxki (may also be used in patients with breast cancer that is HER2* immunohistochemistry [*IHC*] *1+ or 2+/*in situ hybridization [*ISH*] negative). (Category 2A) recommendation.

Non-Small Cell Lung Cancer (NSCLC)

EGFR-sensitizing mutation positive/Preferred

- New:
  - Amivantamab-vmjw + lazertinib (for exon 19 deletion or L858R), preferred, (category 2A) recommendation.
  - Amivantamab-vmjw + carboplatin + pemetrexed (for exon 19 deletion or L858R), preferred, (category 2A) recommendation.

EGFR-sensitizing mutation positive/Other Recommended

- Modified: Osimertinib *plus platinum-pemetrexed (cisplatin or carboplatin) (category 1),* Other Recommended Recommendation.

ROS1 positive

- New: Repotrectinib (category 2A) recommendation.

Small Cell Lung Cancer (SCLC)

- New: Tarlatamab-dlle (category 2A recommendation).

LEPT-1

Footnotes

- c, new: Lumbar puncture should be done after MRI of spine is performed to avoid a false-positive imaging result.
- e, modified: ~~CSF analysis should include: a cell count, differential, glucose, and protein. For solid malignancies, order cytopathology. When available, assessment of circulating tumor DNA (ctDNA) or circulating tumor cells (CTCs) increases sensitivity of tumor cell detection and assessment of response to treatment. For hematologic malignancies, use flow cytometry~~. *When available, assessment of CSF-tDNA increases sensitivity of tumor cell detection and assessment of response to treatment.*
- f, new:Opening pressure should be recorded and consideration should be made of palliative CSF diversion for symptomatic benefit or hydrocephalus.

Continued

Version 3.2025, 12/05/25 © 2025 National Comprehensive Cancer Network® (NCCN®), All rights reserved. NCCN Guidelines® and this illustration may not be reproduced in any form without the express written permission of NCCN.

PLEASE NOTE that use of this NCCN Content is governed by the End-User License Agreement, and you MAY NOT distribute this Content or use it with any artificial intelligence model or tool.
Printed by A. S. M. FAZLUL KARIM CHOWDHURY on 4/20/2026 3:06:38 AM. Copyright © 2026 National Comprehensive Cancer Network, Inc. All Rights Reserved.

Updates in Version 1.2025 of the NCCN Guidelines for Central Nervous System Cancers from Version 5.2024 include:

LEPT-3
• Middle pathway, new bullet: Principles of Brain and Spine Imaging (BRAIN-A).
Footnote
• Deleted: Within the first 3 months after completion of RT and concomitant temozolomide, diagnosis of recurrence can be indistinguishable from pseudoprogression on neuroimaging.
LEPT-A
Treatment
Breast cancer/Preferred
• New:
▸ Fam-trastuzumab deruxtecan-nxki, (category 2A) recommendation.
Non-Small Cell Lung Cancer/Other Recommended
• New:
• Osimertinib *EGFR* mutation positive (double dose), (category 2A) recommendation.
Melanoma/Useful in Certain Circumstances
• Modified:
▸ IT *and intravenous (IV)* nivolumab (category 2B).
SPINE-2
Footnotes
• e, modified: Principles of Radiation Therapy for Brain and Spinal Cord (BRAIN-C). ~~Ablative doses of RT yield significantly higher rates of pain improvement and disease control (Sahgal A, et al. Lancet Oncol 2021;22:1023-1033 and Palma DA, et al. J Clin Oncol 2020;38:2830-2838)~~. (Also for SPINE-3).
• j, modified: Consider alternative diagnosis of leptomeningeal disease (LEPT-1). *Questions of spine stability should be determined in consultation with a spinal surgeon.*
BRAIN-A
Principles of Brain and Spine Tumor Imaging
• This section has been significantly updated.
BRAIN-B
Principles Surgery
• Title modified: Principles of ~~Brain and Spine Tumor~~ Surgery.
• This section is divided into 2 sections: Brain Surgery and Spine Surgery.
• Modified: Brain surgery:
▸ Tissue: Bullet 4, sentence 2: ~~Postoperative spine MRI should be delayed by at least 2–3 weeks to avoid post-surgical artifacts~~. *Staging spine MRI, when appropriate, should be obtained either pre-op, or* delayed by at least 2–3 weeks to avoid post-surgical artifacts.
• New: Spine surgery: This is a new section in the guidelines.
BRAIN-C,1
Principles of Radiation Therapy for Brain and Spinal Cord
• RT Dosing: Bullet 4, modified: In *patients with poor PS* or older patients, a hypofractionated...

Continued

Version 3.2025, 12/05/25 © 2025 National Comprehensive Cancer Network® (NCCN®), All rights reserved. NCCN Guidelines® and this illustration may not be reproduced in any form without the express written permission of NCCN.

PLEASE NOTE that use of this NCCN Content is governed by the End-User License Agreement, and you MAY NOT distribute this Content or use it with any artificial intelligence model or tool.
Printed by A. S. M. FAZLUL KARIM CHOWDHURY on 4/20/2026 3:06:38 AM. Copyright © 2026 National Comprehensive Cancer Network, Inc. All Rights Reserved.

Updates in Version 1.2025 of the NCCN Guidelines for Central Nervous System Cancers from Version 5.2024 include:

BRAIN-C, 2
Reirradiation for Brain Metastases: New section.

BRAIN-C, 4
Principles of Radiation Therapy for Brain and Spinal Cord
Primary CNS Lymphoma
- Modified: WBRT is typically *used as consolidation following high-dose methotrexate (*HDMTX*)-based induction therapy in* ~~withheld in~~ the primary setting ~~in~~ *for* patients *who are ineligible for autologous hematopoietic cell transplant (HCT) or is used in the palliative setting.* ~~treated with systemic therapy~~.
  - *Adjuvant RT: Can be tailored or given for patients who are ineligible for consolidation autologous HCT*
  - *Definitive: Primary RT should be first-line therapy after progression on* HDMTX based ~~on~~ upfront treatment. ~~Following progression for primary salvage~~*, Cranial radiation to 20–24 Gy followed by boost to radiographically visible T1/T2 disease to 40–50 Gy is recommended. Primary RT should also be considered in patients who are ineligible for MTX-based primary therapy.*

Secondary CNS Lymphoma
- RT Dosing:
  - Sub, sub-bullet, new: For patients with KPS ≥70 and no extracranial disease, then cranial radiation can be given to 20–24 Gy followed by boost to radiographically visible T1/T2 disease to 40 Gy. If poor KPS (<70) or extracranial disease, then RT can be limited to either cranial RT alone to 20–24 Gy or focal involved-site RT (ISRT) to gross disease to 24–30 Gy.
  - 3rd sub-bullet, modified: *Palliative: Primary RT should be first-line after progression on* HDMTX-based upfront treatment.

BRAIN-C,5
Meningiomas
General Treatment Information
- New: Sensitive and specific imaging modalities for radiation treatment planning in meningioma can be helpful, including MR perfusion and PET imaging (eg, Ga-68 DOTATATE PET-MRI and/or CT).

WHO Grade 3 Meningiomas
General Treatment Information
- Modified, 1st sub-sub-bullet: Treat as malignant tumors with treatment directed to gross tumor (if present), surgical bed, and a margin (*1*–2~~–3~~ cm, *depending on distribution of disease and histopathology)*.

BRAIN-C,7
Metastatic Spine Tumors
RT Dosing
- Modified, 4th sub-sub-bullet: When lower biologically effective dose (BED) *with alpha/beta ratio of 2 for spinal cord* regimens....
- Modified, 5th sub-sub-bullet, last sentence: *For radiation-associated edema and treatment-related necrosis, please see* BRAIN-D, 2 of 7.

BRAIN-D,2
Principles of Brain and Spine Tumor Management
- Modified, sub title: ~~Mass Effect~~, Brain Edema *and Treatment-Associated Necrosis/Radionecrosis*
- 1st sub-bullet, modified: Corticosteroids ~~or~~ *and* confirmatory diagnostic study.
- 2nd sub-sub-bullet, modified: Consider bevacizumab ~~for 2-3 doses~~ *if symptoms do not resolve with corticosteroids or patient is unable to tolerate corticosteroids.*
- 4th sub-sub-bullet, new: Consider hyperbaric oxygen treatment in select cases that are unresponsive to corticosteroids.

If asymptomatic:
- 1st sub-bullet, modified: Follow *with* serial MR *and neurologic exam* every 2–3 months.

Continued

Version 3.2025, 12/05/25 © 2025 National Comprehensive Cancer Network® (NCCN®), All rights reserved. NCCN Guidelines® and this illustration may not be reproduced in any form without the express written permission of NCCN.

PLEASE NOTE that use of this NCCN Content is governed by the End-User License Agreement, and you MAY NOT distribute this Content or use it with any artificial intelligence model or tool.
Printed by A. S. M. FAZLUL KARIM CHOWDHURY on 4/20/2026 3:06:38 AM. Copyright © 2026 National Comprehensive Cancer Network, Inc. All Rights Reserved.

Updates in Version 1.2025 of the NCCN Guidelines for Central Nervous System Cancers from Version 5.2024 include:

BRAIN-D,4
Principles of Brain and Spine Tumor Management
- Venous Thromboembolism (VTE), new: Treatment with direct oral anticoagulants is recommended for VTE prophylaxis in patients with adult-type diffuse gliomas who are deemed to be at high risk of VTE.

BRAIN-E, 4
Principles of Brain Tumor Pathology: Molecular Markers
ATRX Mutation
- Diagnostic value, modified: ~~A lack of ATRX immunostaining in glioblastoma should trigger IDH1/2 sequencing if IDH1 R132H immunostaining is negative, due to the frequent co-occurrence of ATRX and IDH mutations~~. *Since the ATRX immunostain can be false-negative due to thermal artifact, always interpret ATRX immunostaining using admixed nonneoplastic cells as positive controls (eg, endothelial cells, neurons, inflammatory cells).*

BRAIN-E, 6
Medulloblastoma Molecular Subtyping
- Bullet 3, Detection, modified: ~~Nuclear immunoreactivity for beta-catenin is a very useful way to identify WNT medulloblastomas, in conjunction with CTNNB1 sequencing and chromosome 6 FISH.~~ *However, nuclear staining for beta-catenin in WNT-medulloblastomas can be very focal and might be misinterpreted as negative or equivocal.*

Version 3.2025, 12/05/25 © 2025 National Comprehensive Cancer Network® (NCCN®), All rights reserved. NCCN Guidelines® and this illustration may not be reproduced in any form without the express written permission of NCCN.

PLEASE NOTE that use of this NCCN Content is governed by the End-User License Agreement, and you MAY NOT distribute this Content or use it with any artificial intelligence model or tool.
Printed by A. S. M. FAZLUL KARIM CHOWDHURY on 4/20/2026 3:06:38 AM. Copyright © 2026 National Comprehensive Cancer Network, Inc. All Rights Reserved.

NCCN Guidelines Version 3.2025
Adult Glioma: Circumscribed Glioma

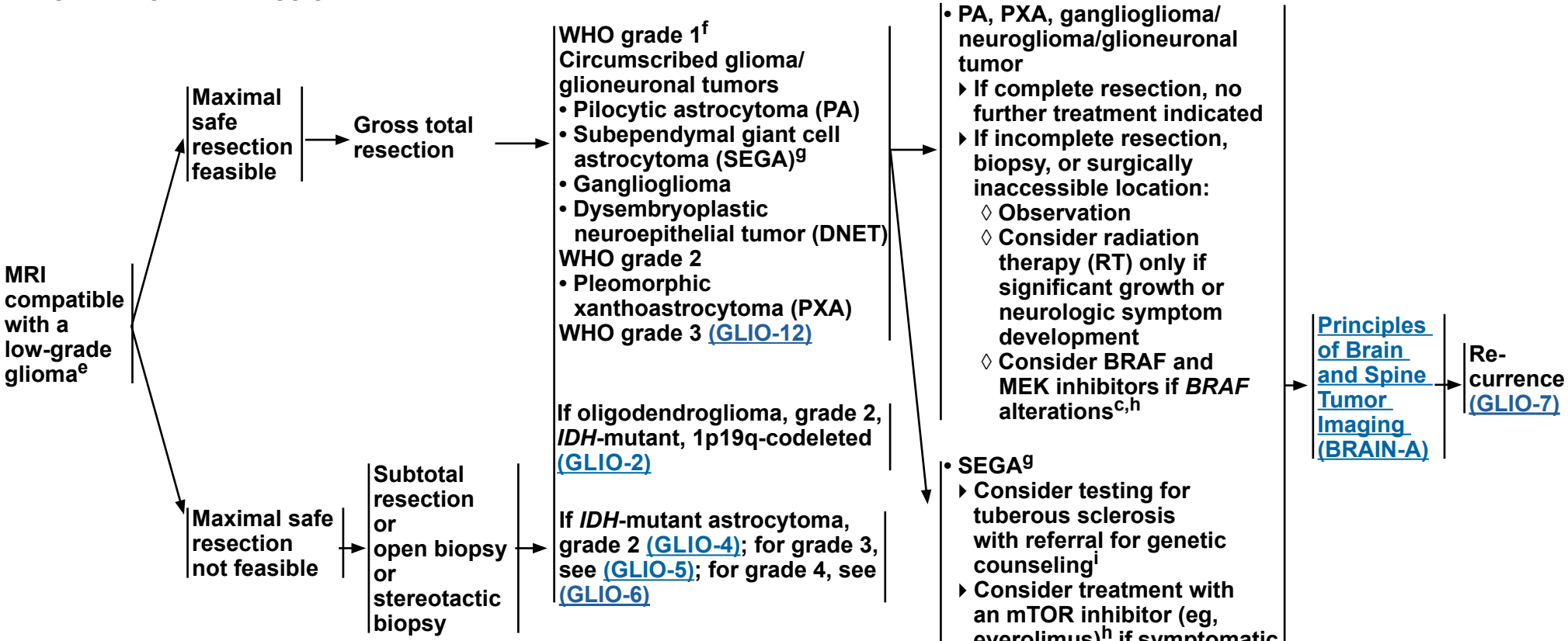

[a] Principles of Brain and Spine Tumor Imaging (BRAIN-A).
[b] Principles of Surgery (BRAIN-B).
[c] For recommended molecular diagnostics, see Principles of Brain Tumor Pathology (BRAIN-E).
[d] Postoperative brain MRI within 48 hours after surgery.
[e] The Panel strongly recommends multidisciplinary discussion of patients with newly diagnosed or recurrent or progressive gliomas (any grade) or referring such patients to a brain tumor center for a consultation. Similarly, if treatment with an IDH inhibitor is being considered for a patient with newly diagnosed oligodendroglioma or astrocytoma, the Panel strongly recommends multidisciplinary discussion or referral to a brain tumor center for consultation. See Principles of Brain and Spine Tumor Management (BRAIN-D).
[f] WHO grade 1 tumors with concurrent *H3* and *BRAF* alterations may behave more aggressively. See Principles of Brain Tumor Pathology (BRAIN-E).
[g] The need to treat SEGAs or other findings in the appropriate tuberous sclerosis patient population should be determined by the patient's symptoms and/or change on serial radiologic studies. Referral to medical genetics/brain tumor center is recommended.
[h] Systemic Therapy Options (GLIO-A).
[i] Principles of Cancer Risk Assessment and Counseling (BRAIN-F).

Note: All recommendations are category 2A unless otherwise indicated.

Version 3.2025, 12/05/25 © 2025 National Comprehensive Cancer Network® (NCCN®), All rights reserved. NCCN Guidelines® and this illustration may not be reproduced in any form without the express written permission of NCCN.

PLEASE NOTE that use of this NCCN Content is governed by the End-User License Agreement, and you MAY NOT distribute this Content or use it with any artificial intelligence model or tool.
Printed by: A. S. MUNAZLI | Karnov Group Sweden | 12/20/2025 | Licensee No. 1 | Copyright © 2025 National Comprehensive Cancer Network, Inc. All Rights Reserved.

Adult Glioma: Oligodendroglioma (*IDH*-mutant, 1p19q codeleted)

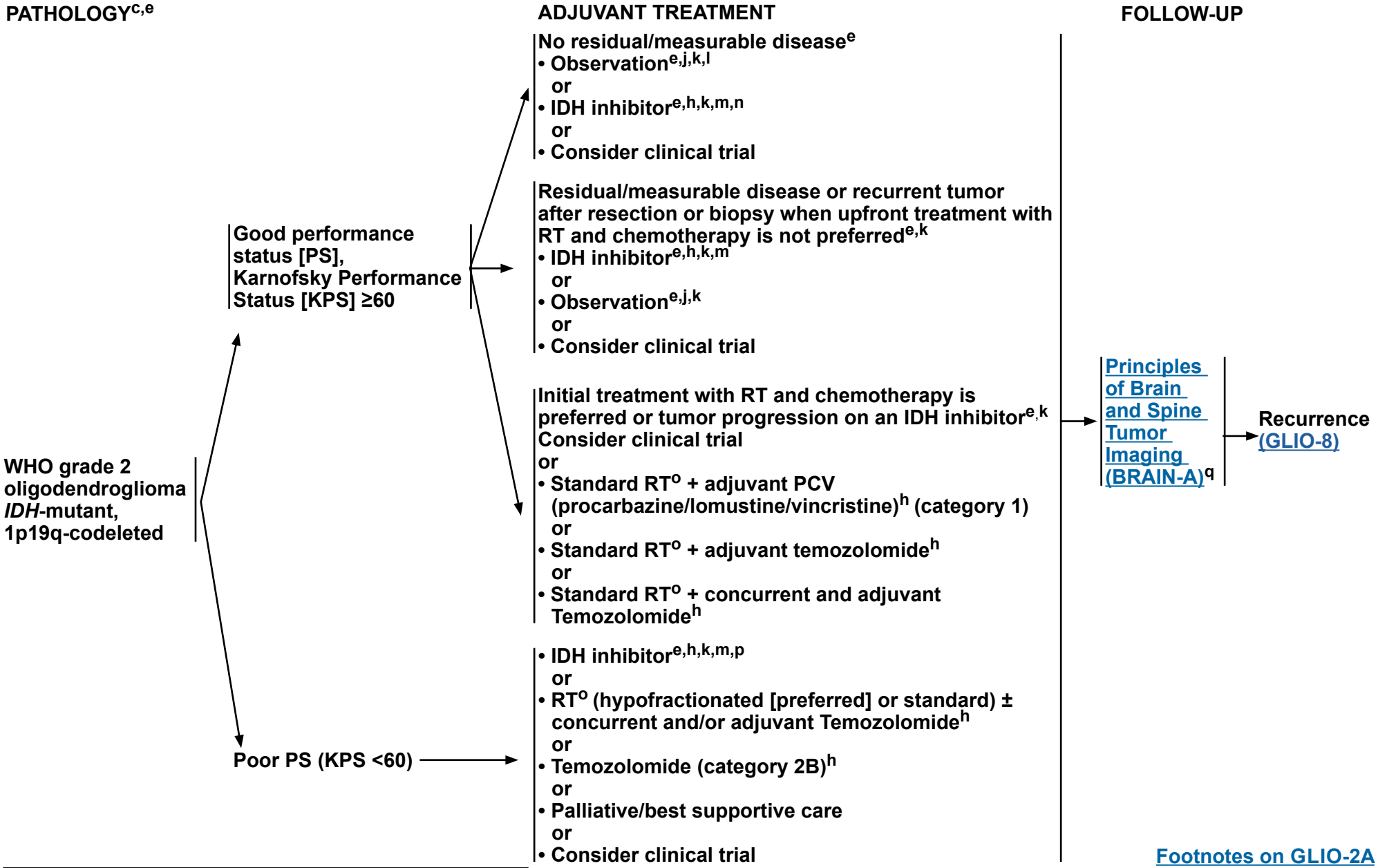

Note: All recommendations are category 2A unless otherwise indicated.

Footnotes on GLIO-2A

Version 3.2025, 12/05/25 © 2025 National Comprehensive Cancer Network® (NCCN®), All rights reserved. NCCN Guidelines® and this illustration may not be reproduced in any form without the express written permission of NCCN.

PLEASE NOTE that use of this NCCN Content is governed by the End-User License Agreement, and you MAY NOT distribute this Content or use it with any artificial intelligence model or tool.
Printed by: A. S. MUNOZLUNA on Nov 20, 2025 Expires: 12/30/2027 Account: 0 Copyright © 2025 National Comprehensive Cancer Network, Inc. All Rights Reserved.

FOOTNOTES

[c] For recommended molecular diagnostics, see Principles of Brain Tumor Pathology (BRAIN-E).

[e] The Panel strongly recommends multidisciplinary discussion of patients with newly diagnosed or recurrent or progressive gliomas (any grade) or referring such patients to a brain tumor center for a consultation. Similarly, if treatment with an IDH inhibitor is being considered for a patient with newly diagnosed oligodendroglioma or astrocytoma, the Panel strongly recommends multidisciplinary discussion or referral to a brain tumor center for consultation. See Principles of Brain and Spine Tumor Management (BRAIN-D).

[h] Systemic Therapy Options (GLIO-A).

[j] Regular follow-up is essential for patients receiving observation alone after resection.

[k] The results of RTOG 9802 showed that there was a significant improvement in median overall survival in patients with high-risk low-grade glioma treated with RT followed by PCV x 6 cycles compared with RT alone after a tissue diagnosis was made. However, this important study did not address whether all of these patients should be treated right away. Observation after diagnosis or treatment with an IDH inhibitor may be reasonable options for a patient with low-grade glioma who is neurologically asymptomatic or stable. Close monitoring with brain MRIs is important.

[l] Patients with newly diagnosed grade 2 oligodendroglioma who have undergone gross total resection of tumor might remain progression free for many years; therefore, initially observing these patients is reasonable. Byeon Y, et al. Discov Oncol 2024;15:268.

[m] Vorasidenib is a dual inhibitor of *IDH1* and *IDH2* mutations. In a phase 3 study of vorasidenib versus placebo (Mellinghoff IK, et al. N Engl J Med 2023;389:589-601) in patients with residual or recurrent grade 2 IDH-mutant glioma (after surgery and no prior treatment), vorasidenib improved median progression-free survival (PFS; 27.7 months vs. 11.1 months) compared to placebo. Overall survival data from this study are not yet available. Ivosidenib is an IDH1 inhibitor and is a reasonable alternative if a patient cannot tolerate vorasidenib. Byeon Y, et al. Discov Oncol 2024;15:268.

[n] Newly diagnosed patients with oligodendroglioma/astrocytoma (WHO grade 2 or 3) who did not have residual disease were excluded from participation in the phase 3 INDIGO study of vorasidenib versus placebo. Therefore, it remains unknown if this subset of patients would benefit from immediate treatment with an IDH inhibitor. The safety of long-term treatment with IDH inhibitors is unknown. The Panel recommends discussing the possible risks and benefits of starting treatment right away with an IDH inhibitor with these patients.

[o] Principles of Radiation Therapy for Brain and Spinal Cord (BRAIN-C).

[p] If a patient has a KPS <60 due to neurologic deficits from the brain tumor, then RT + temozolomide would be the preferred treatment. However, if a patient has a KPS <60 for other reasons, such as medical comorbidities, then treatment with an IDH inhibitor would be reasonable since it may be tolerated better than radiation and/or cytotoxic chemotherapy.

[q] Within the first 3 months after completion of RT and concomitant temozolomide, diagnosis of recurrence can be indistinguishable from pseudoprogression on neuroimaging.

Note: All recommendations are category 2A unless otherwise indicated.

Version 3.2025, 12/05/25 © 2025 National Comprehensive Cancer Network® (NCCN®), All rights reserved. NCCN Guidelines® and this illustration may not be reproduced in any form without the express written permission of NCCN.

PLEASE NOTE that use of this NCCN Content is governed by the End-User License Agreement, and you MAY NOT distribute this Content or use it with any artificial intelligence model or tool.
Printed by: A. S. MUNZLINGER, January 20, 2026 Expires: 01/30/2026 Copyright © 2026 National Comprehensive Cancer Network, Inc. All Rights Reserved.

NCCN Guidelines Version 3.2025
Adult Glioma: Oligodendroglioma (*IDH*-mutant, 1p19q codeleted)

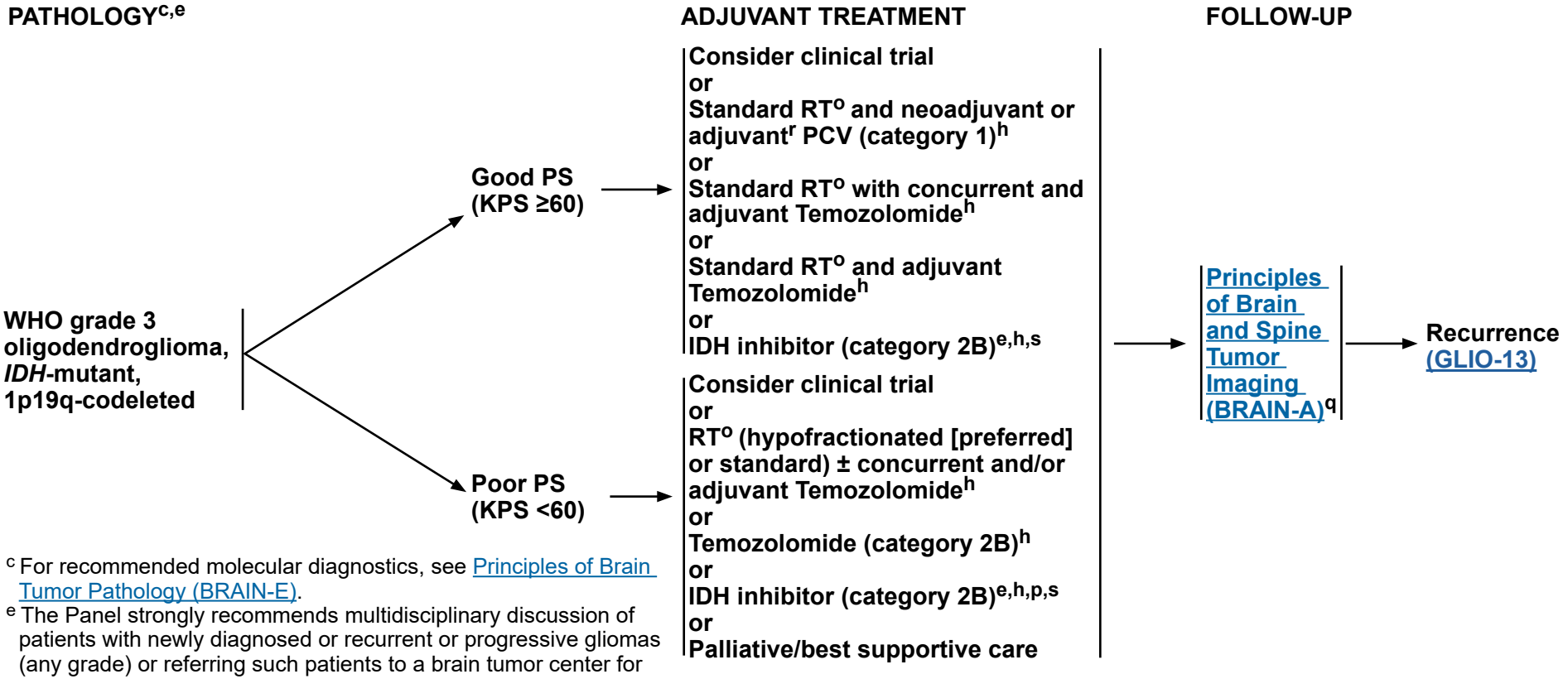

[c] For recommended molecular diagnostics, see Principles of Brain Tumor Pathology (BRAIN-E).

[e] The Panel strongly recommends multidisciplinary discussion of patients with newly diagnosed or recurrent or progressive gliomas (any grade) or referring such patients to a brain tumor center for a consultation. Similarly, if treatment with an IDH inhibitor is being considered for a patient with newly diagnosed oligodendroglioma or astrocytoma, the Panel strongly recommends multidisciplinary discussion or referral to a brain tumor center for consultation. See Principles of Brain and Spine Tumor Management (BRAIN-D).

[h] Systemic Therapy Options (GLIO-A).

[o] Principles of Radiation Therapy for Brain and Spinal Cord (BRAIN-C).

[p] If a patient has a KPS <60 due to neurologic deficits from the brain tumor, then RT + temozolomide would be the preferred treatment. However, if a patient has a KPS <60 for other reasons, such as medical comorbidities, then treatment with an IDH inhibitor would be reasonable since it may be tolerated better than radiation and/or cytotoxic chemotherapy.

[q] Within the first 3 months after completion of RT and concomitant temozolomide, diagnosis of recurrence can be indistinguishable from pseudoprogression on neuroimaging.

[r] The Panel recommends that PCV be administered after RT (as per EORTC 26951) since the intensive PCV regimen given prior to RT (RTOG 9402) was not tolerated as well.

[s] Some Panel members felt that given the relatively slow growth rate of oligodendrogliomas, in certain circumstances it would be reasonable to first try treatment with an IDH inhibitor. However, other Panel members expressed concern about possible undertreatment of these patients by postponing the start of radiation and cytotoxic chemotherapy, which have been shown to improve survival in newly diagnosed grade 3 oligodendroglioma patients (van den Bent MJ, et al. J clin Oncol 2013;31:344-350; Cairncross G, et al. J Clin Oncol 2013;31:337-343). Newly diagnosed grade 3 oligodendroglioma patients who start treatment with an IDH inhibitor should be followed closely with brain MRIs. See Principles of Brain and Spine Tumor Management (BRAIN-D).

Note: All recommendations are category 2A unless otherwise indicated.

Version 3.2025, 12/05/25 © 2025 National Comprehensive Cancer Network® (NCCN®), All rights reserved. NCCN Guidelines® and this illustration may not be reproduced in any form without the express written permission of NCCN.

PLEASE NOTE that use of this NCCN Content is governed by the End-User License Agreement, and you MAY NOT distribute this Content or use it with any artificial intelligence model or tool.
Printed by A. S. M. FAZLUL KARIM CHOWDHURY on 4/20/2026 3:06:38 AM. Copyright © 2026 National Comprehensive Cancer Network, Inc. All Rights Reserved.

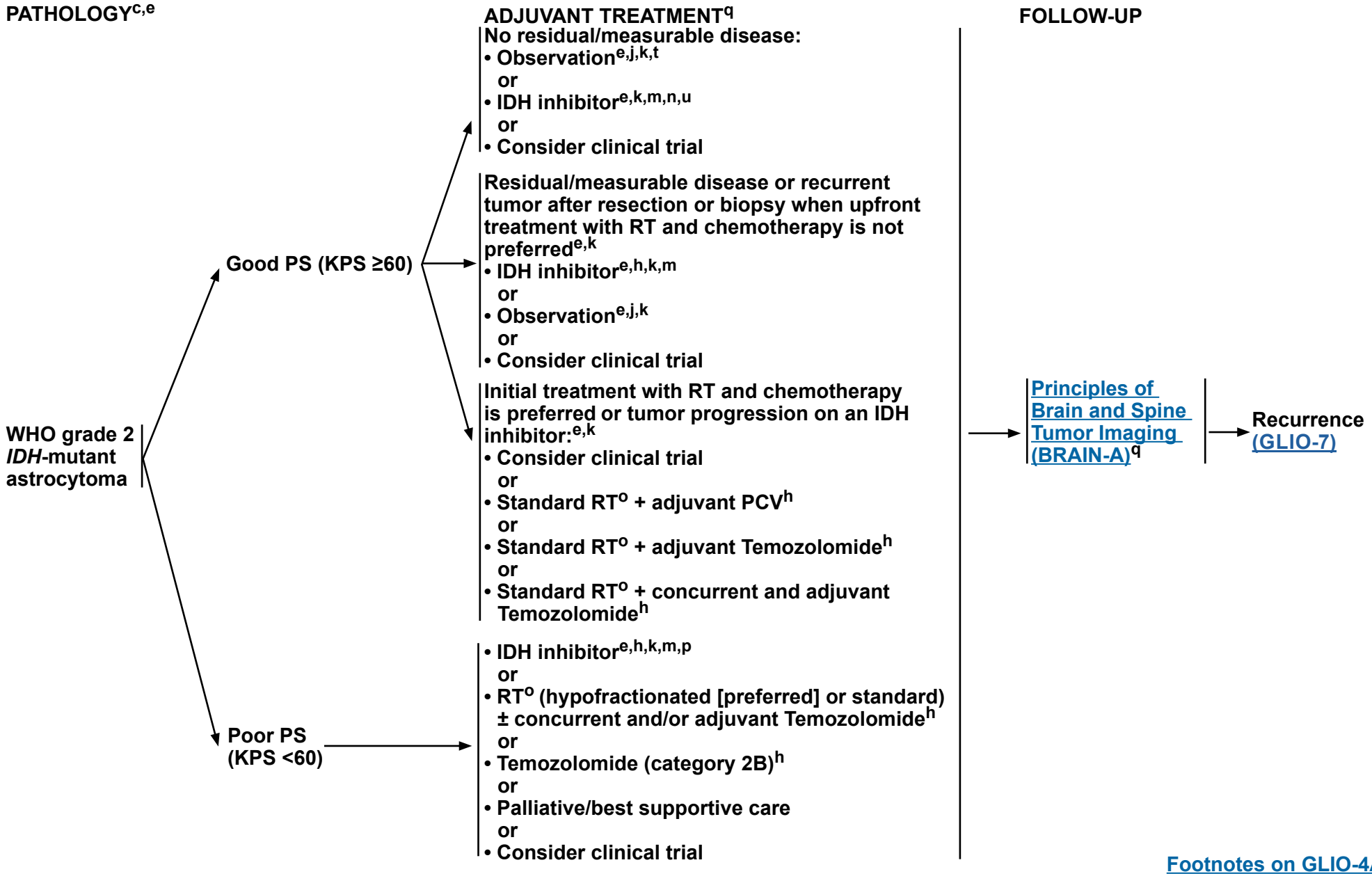

Footnotes on GLIO-4A

Note: All recommendations are category 2A unless otherwise indicated.

Version 3.2025, 12/05/25 © 2025 National Comprehensive Cancer Network® (NCCN®), All rights reserved. NCCN Guidelines® and this illustration may not be reproduced in any form without the express written permission of NCCN.

PLEASE NOTE that use of this NCCN Content is governed by the End-User License Agreement, and you MAY NOT distribute this Content or use it with any artificial intelligence model or tool.
Printed by A. S. M. FAZLUL KARIM CHOWDHURY on 4/20/2026 3:06:38 AM. Copyright © 2026 National Comprehensive Cancer Network, Inc. All Rights Reserved.

FOOTNOTES

[c] For recommended molecular diagnostics, see Principles of Brain Tumor Pathology (BRAIN-E).

[e] The Panel strongly recommends multidisciplinary discussion of patients with newly diagnosed or recurrent or progressive gliomas (any grade) or referring such patients to a brain tumor center for a consultation. Similarly, if treatment with an IDH inhibitor is being considered for a patient with newly diagnosed oligodendroglioma or astrocytoma, the Panel strongly recommends multidisciplinary discussion or referral to a brain tumor center for consultation. See Principles of Brain and Spine Tumor Management (BRAIN-D).

[h] Systemic Therapy Options (GLIO-A).

[j] Regular follow-up is essential for patients receiving observation alone after resection.

[k] The results of RTOG 9802 showed that there was a significant improvement in median overall survival in patients with high-risk low-grade glioma treated with RT followed by PCV x 6 cycles compared with RT alone after a tissue diagnosis was made. However, this important study did not address whether all of these patients should be treated right away. Observation after diagnosis or treatment with an IDH inhibitor may be reasonable options for a patient with low-grade glioma who is neurologically asymptomatic or stable. Close monitoring with brain MRIs is important.

[m] Vorasidenib is a dual inhibitor of *IDH1* and *IDH2* mutations. In a phase 3 study of vorasidenib versus placebo (Mellinghoff IK, et al. N Engl J Med 2023;389:589-601) in patients with residual or recurrent grade 2 IDH-mutant glioma (after surgery and no prior treatment), vorasidenib improved median PFS (27.7 months vs. 11.1 months) compared to placebo. Overall survival data from this study are not yet available. Ivosidenib is an IDH1 inhibitor and is a reasonable alternative if a patient cannot tolerate vorasidenib. Byeon Y, et al. Discov Oncol 2024;15:268.

[n] Newly diagnosed patients with oligodendroglioma/astrocytoma (WHO grade 2 or 3) who did not have residual disease were excluded from participation in the phase 3 INDIGO study of vorasidenib versus placebo. Therefore, it remains unknown if this subset of patients would benefit from immediate treatment with an IDH inhibitor. The safety of long-term treatment with IDH inhibitors is unknown. The Panel recommends discussing the possible risks and benefits of starting treatment right away with an IDH inhibitor with these patients.

[o] Principles of Radiation Therapy for Brain and Spinal Cord (BRAIN-C).

[p] If a patient has a KPS <60 due to neurologic deficits from the brain tumor, then RT + temozolomide would be the preferred treatment. However, if a patient has a KPS <60 for other reasons, such as medical comorbidities, then treatment with an IDH inhibitor would be reasonable since it may be tolerated better than radiation and/or cytotoxic chemotherapy.

[q] Within the first 3 months after completion of RT and concomitant temozolomide, diagnosis of recurrence can be indistinguishable from pseudoprogression on neuroimaging.

[t] Grade 2 astrocytomas are relatively slow growing and may not require further treatment for several years. Therefore, initial observation after gross total resection is reasonable.

[u] The Panel acknowledges that compared to grade 2 oligodendrogliomas, grade 2 astrocytomas typically progress faster. Therefore, delaying the need for radiation and cytotoxic chemotherapy by starting treatment with an IDH inhibitor in a grade 2 astrocytoma patient who has undergone gross total resection of tumor may also be a reasonable approach.

Note: All recommendations are category 2A unless otherwise indicated.

Version 3.2025, 12/05/25 © 2025 National Comprehensive Cancer Network® (NCCN®), All rights reserved. NCCN Guidelines® and this illustration may not be reproduced in any form without the express written permission of NCCN.

PLEASE NOTE that use of this NCCN Content is governed by the End-User License Agreement, and you MAY NOT distribute this Content or use it with any artificial intelligence model or tool.
Printed by A. S. M. FAZLUL KARIM CHOWDHURY on 4/20/2026 3:06:38 AM. Copyright © 2026 National Comprehensive Cancer Network, Inc. All Rights Reserved.

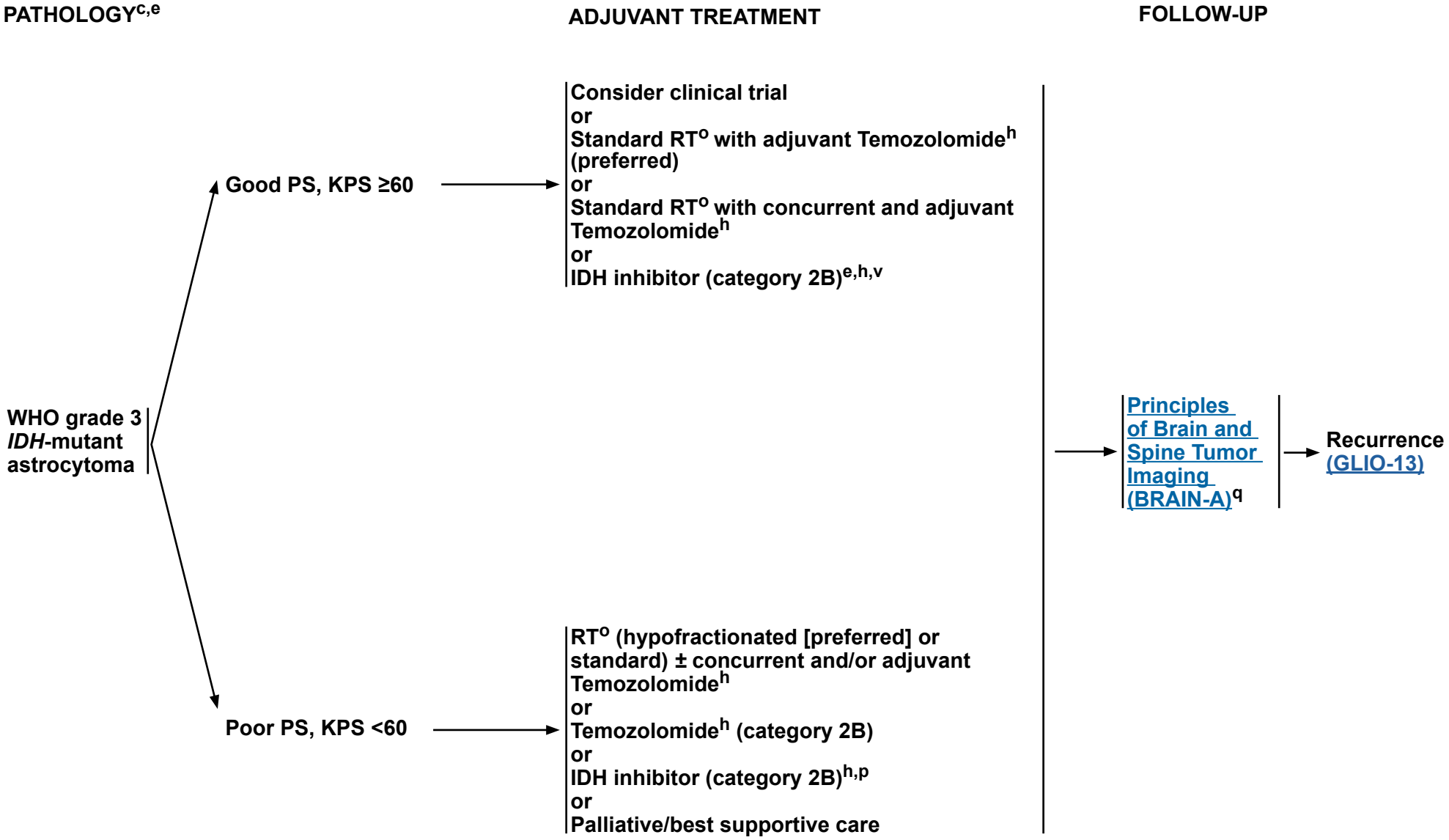

Footnotes on GLIO-5A

Note: All recommendations are category 2A unless otherwise indicated.

Version 3.2025, 12/05/25 © 2025 National Comprehensive Cancer Network® (NCCN®), All rights reserved. NCCN Guidelines® and this illustration may not be reproduced in any form without the express written permission of NCCN.

PLEASE NOTE that use of this NCCN Content is governed by the End-User License Agreement, and you MAY NOT distribute this Content or use it with any artificial intelligence model or tool.
Printed by A. S. M. FAZLUL KARIM CHOWDHURY on 4/20/2026 3:06:38 AM. Copyright © 2026 National Comprehensive Cancer Network, Inc. All Rights Reserved.

FOOTNOTES

[c] For recommended molecular diagnostics, see Principles of Brain Tumor Pathology (BRAIN-E).

[e] The Panel strongly recommends multidisciplinary discussion of patients with newly diagnosed or recurrent or progressive gliomas (any grade) or referring such patients to a brain tumor center for a consultation. Similarly, if treatment with an IDH inhibitor is being considered for a patient with newly diagnosed oligodendroglioma or astrocytoma, the Panel strongly recommends multidisciplinary discussion or referral to a brain tumor center for consultation. See Principles of Brain and Spine Tumor Management (BRAIN-D).

[h] Systemic Therapy Options (GLIO-A).

[o] Principles of Radiation Therapy for Brain and Spinal Cord (BRAIN-C).

[p] If a patient has a KPS <60 due to neurologic deficits from the brain tumor, then RT + temozolomide would be the preferred treatment. However, if a patient has a KPS <60 for other reasons, such as medical comorbidities, then treatment with an IDH inhibitor would be reasonable since it may be tolerated better than radiation and/or cytotoxic chemotherapy.

[q] Within the first 3 months after completion of RT and concomitant temozolomide, diagnosis of recurrence can be indistinguishable from pseudoprogression on neuroimaging.

[v] Strict histopathologic criteria do not currently exist for definitively diagnosing a WHO grade 2 versus a WHO grade 3 *IDH*-mutated astrocytoma. Therefore, some Panel members felt that it may be reasonable to try treating patients with newly diagnosed *IDH*-mutated grade 3 astrocytoma up front with an IDH inhibitor in certain circumstances. This includes, but is not limited to, if the enhancing portion of the tumor has been resected, and all the remaining tumor is non-enhancing, probable grade 2 tumor. Other Panel members disagreed with this approach due to possibly undertreating a patient by postponing the start of radiation and cytotoxic chemotherapy, which have been shown to improve survival (van den Bent MJ, et al. Lancet Oncol 2021;22:813-823).

Note: All recommendations are category 2A unless otherwise indicated.

Version 3.2025, 12/05/25 © 2025 National Comprehensive Cancer Network® (NCCN®), All rights reserved. NCCN Guidelines® and this illustration may not be reproduced in any form without the express written permission of NCCN.

PLEASE NOTE that use of this NCCN Content is governed by the End-User License Agreement, and you MAY NOT distribute this Content or use it with any artificial intelligence model or tool.
Printed by A. S. M. FAZLUL KARIM CHOWDHURY on 4/20/2026 3:06:38 AM. Copyright © 2026 National Comprehensive Cancer Network, Inc. All Rights Reserved.

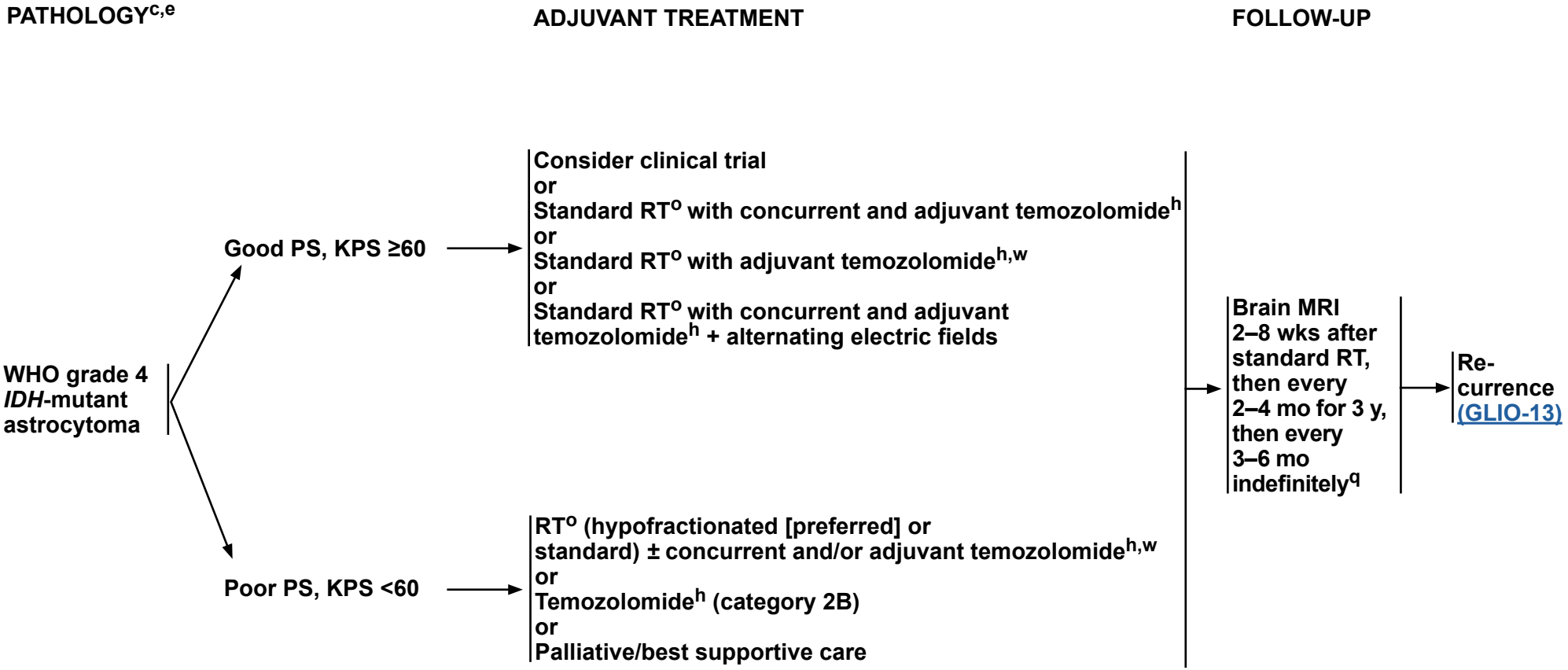

[c] For recommended molecular diagnostics, see Principles of Brain Tumor Pathology (BRAIN-E).
[e] The Panel strongly recommends multidisciplinary discussion of patients with newly diagnosed or recurrent or progressive gliomas (any grade) or referring such patients to a brain tumor center for a consultation. Similarly, if treatment with an IDH inhibitor is being considered for a patient with newly diagnosed oligodendroglioma or astrocytoma, the Panel strongly recommends multidisciplinary discussion or referral to a brain tumor center for consultation. See Principles of Brain and Spine Tumor Management (BRAIN-D).
[h] Systemic Therapy Options (GLIO-A).
[o] Principles of Radiation Therapy for Brain and Spinal Cord (BRAIN-C).
[q] Within the first 3 months after completion of RT and concomitant temozolomide, diagnosis of recurrence can be indistinguishable from pseudoprogression on neuroimaging.
[w] Treatment of grade 4 disease is extrapolated from interim analyses of data from the CATNON study. Final results of CATNON are not yet available.

Note: All recommendations are category 2A unless otherwise indicated.

Version 3.2025, 12/05/25 © 2025 National Comprehensive Cancer Network® (NCCN®), All rights reserved. NCCN Guidelines® and this illustration may not be reproduced in any form without the express written permission of NCCN.

PLEASE NOTE that use of this NCCN Content is governed by the End-User License Agreement, and you MAY NOT distribute this Content or use it with any artificial intelligence model or tool.
Printed by: A. S. Mohammed Zubair Khan on 2026-01-20 07:00 EST. Copyright © 2025 National Comprehensive Cancer Network, Inc. All Rights Reserved.

Adult Glioma: Recurrent or Progressive Circumscribed Glioma

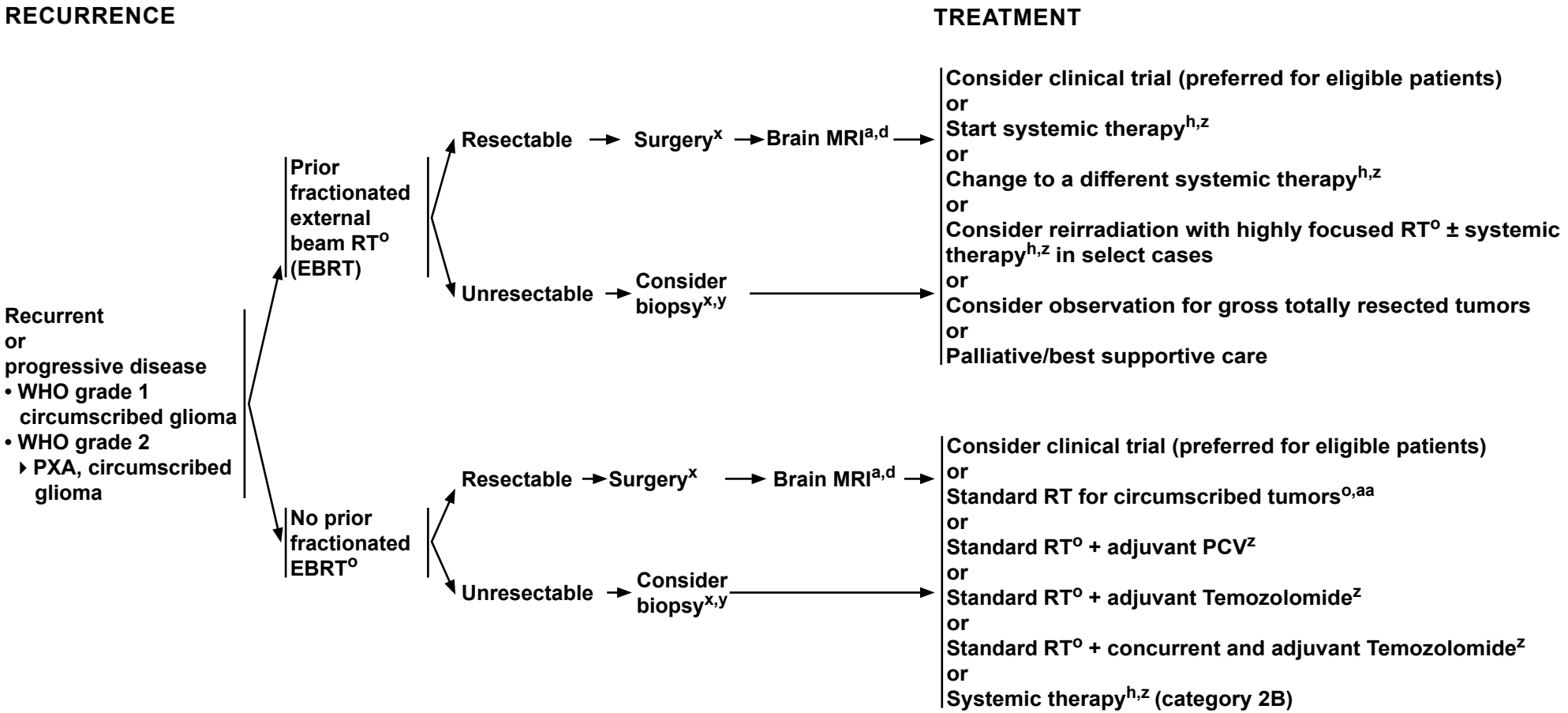

[a] Principles of Brain and Spine Tumor Imaging (BRAIN-A).
[d] Postoperative brain MRI within 48 hours after surgery.
[h] Systemic Therapy Options (GLIO-A).
[o] Principles of Radiation Therapy for Brain and Spinal Cord (BRAIN-C).
[x] If radiographically the tumor appears to be a high-grade glioma, see GLIO-8.
[y] Recurrence on neuroimaging can be confounded by treatment effects. To confirm tumor recurrence and assess for possible transformation of tumor to higher grade, strongly consider tumor tissue sampling (biopsy at minimum) if there is a high index of suspicion of recurrence. For treatment of patients with transformation to high-grade disease, see GLIO-9.
[z] See Principles of Brain and Spine Tumor Imaging (BRAIN-A) for imaging recommendations to assess disease recurrence/progression.
[aa] RT alone is not encouraged, but may be appropriate for select cases (eg, poor PS).

Note: All recommendations are category 2A unless otherwise indicated.

Version 3.2025, 12/05/25 © 2025 National Comprehensive Cancer Network® (NCCN®), All rights reserved. NCCN Guidelines® and this illustration may not be reproduced in any form without the express written permission of NCCN.

PLEASE NOTE that use of this NCCN Content is governed by the End-User License Agreement, and you MAY NOT distribute this Content or use it with any artificial intelligence model or tool.
Printed by: A. S. MUNAZLI | Jan 30, 2026 | Subscription expires on 12/30/2027 | Account ID: [illegible] | Copyright © 2026 National Comprehensive Cancer Network, Inc. All Rights Reserved.

Adult Glioma: Recurrent Oligodendroglioma and Astrocytoma (WHO Grade 2)

RECURRENCE[j]

TREATMENT

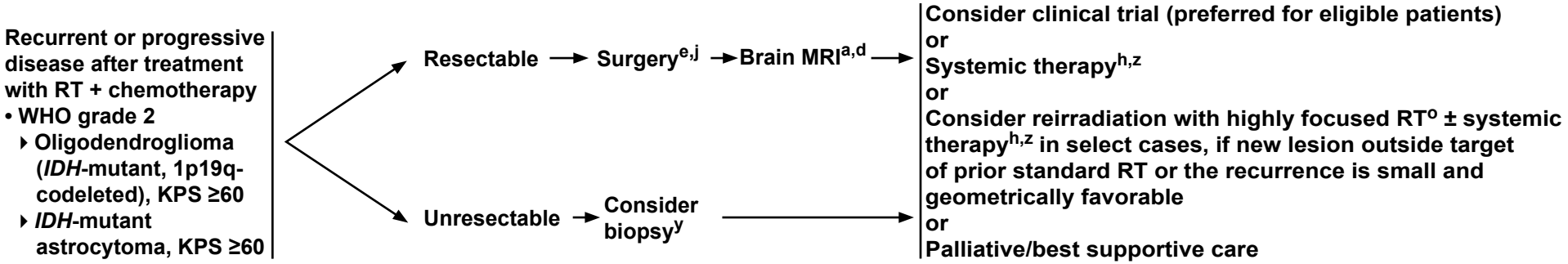

[a] Principles of Brain and Spine Tumor Imaging (BRAIN-A).
[d] Postoperative brain MRI within 48 hours after surgery.
[e] The Panel strongly recommends multidisciplinary discussion of patients with newly diagnosed or recurrent or progressive gliomas (any grade) or referring such patients to a brain tumor center for a consultation. Similarly, if treatment with an IDH inhibitor is being considered for a patient with newly diagnosed oligodendroglioma or astrocytoma, the Panel strongly recommends multidisciplinary discussion or referral to a brain tumor center for consultation. See Principles of Brain and Spine Tumor Management (BRAIN-D).
[h] Systemic Therapy Options (GLIO-A).
[j] Regular follow-up is essential for patients receiving observation alone after resection.
[o] Principles of Radiation Therapy for Brain and Spinal Cord (BRAIN-C).
[y] Recurrence on neuroimaging can be confounded by treatment effects. To confirm tumor recurrence and assess for possible transformation of tumor to higher grade, strongly consider tumor tissue sampling (biopsy at minimum) if there is a high index of suspicion of recurrence. For treatment of patients with transformation to high-grade disease, see GLIO-9.
[z] See Principles of Brain and Spine Tumor Imaging (BRAIN-A) for imaging recommendations to assess disease recurrence/progression.

Note: All recommendations are category 2A unless otherwise indicated.

Version 3.2025, 12/05/25 © 2025 National Comprehensive Cancer Network® (NCCN®), All rights reserved. NCCN Guidelines® and this illustration may not be reproduced in any form without the express written permission of NCCN.

PLEASE NOTE that use of this NCCN Content is governed by the End-User License Agreement, and you MAY NOT distribute this Content or use it with any artificial intelligence model or tool.
Printed by A. S. M. FAZLUL KARIM CHOWDHURY on 4/20/2026 3:06:38 AM. Copyright © 2026 National Comprehensive Cancer Network, Inc. All Rights Reserved.

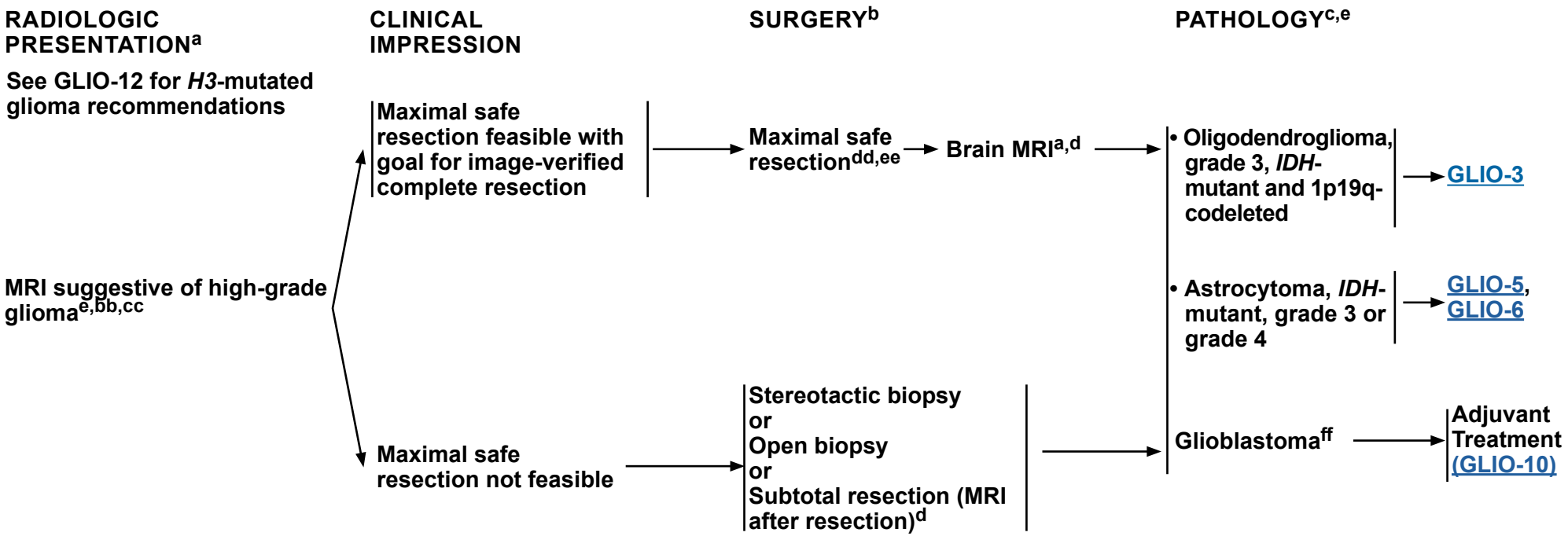

[a] Principles of Brain and Spine Tumor Imaging (BRAIN-A).
[b] Principles of Surgery (BRAIN-B).
[c] For recommended molecular diagnostics, see Principles of Brain Tumor Pathology (BRAIN-E).
[d] Postoperative brain MRI within 48 hours after surgery.
[e] The Panel strongly recommends multidisciplinary discussion of patients with newly diagnosed or recurrent or progressive gliomas (any grade) or referring such patients to a brain tumor center for a consultation. Similarly, if treatment with an IDH inhibitor is being considered for a patient with newly diagnosed oligodendroglioma or astrocytoma, the Panel strongly recommends multidisciplinary discussion or referral to a brain tumor center for consultation. See Principles of Brain and Spine Tumor Management (BRAIN-D).
[bb] This pathway includes the classification of grade 3 astrocytoma, *IDH*-mutant; grade 3 oligodendroglioma, *IDH*-mutant and 1p/19q-codeleted; and other rare grade 3 gliomas.
[cc] Biopsy prior to administration of steroids if MRI compatible with CNS lymphoma.
[dd] If frozen section diagnosis supports high-grade glioma.
[ee] Consider carmustine (BCNU) wafer implant during maximal safe resection (category 2B). Treatment with carmustine wafer may impact enrollment in adjuvant clinical trials.
[ff] This pathway also includes gliosarcoma.

Note: All recommendations are category 2A unless otherwise indicated.

Version 3.2025, 12/05/25 © 2025 National Comprehensive Cancer Network® (NCCN®), All rights reserved. NCCN Guidelines® and this illustration may not be reproduced in any form without the express written permission of NCCN.

PLEASE NOTE that use of this NCCN Content is governed by the End-User License Agreement, and you MAY NOT distribute this Content or use it with any artificial intelligence model or tool.
Printed by A. S. M. FAZLUL KARIM CHOWDHURY on 4/20/2026 3:06:38 AM. Copyright © 2026 National Comprehensive Cancer Network, Inc. All Rights Reserved.

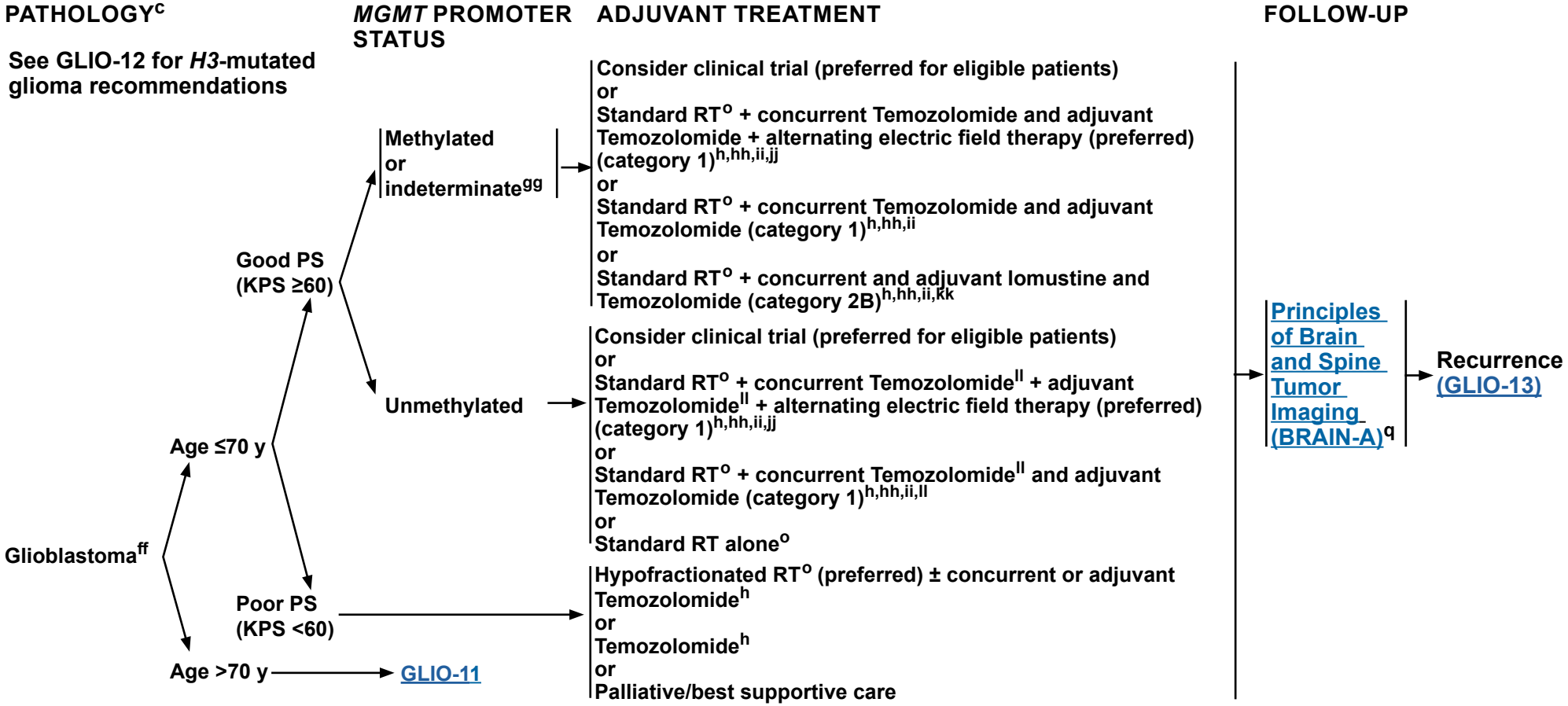

[c] For recommended molecular diagnostics, see Principles of Brain Tumor Pathology (BRAIN-E).
[h] Systemic Therapy Options (GLIO-A).
[o] Principles of Radiation Therapy for Brain and Spinal Cord (BRAIN-C).
[q] Within the first 3 months after completion of RT and concomitant temozolomide, diagnosis of recurrence can be indistinguishable from pseudoprogression on neuroimaging.
[ff] This pathway also includes gliosarcoma.
[gg] Consider pyrosequencing if not done (Mansouri A, et al. Neuro Oncol 2019;21:167-178).
[hh] Combination of modalities may lead to increased toxicity or radiographic changes.
[ii] There are no clear data that treatment with temozolomide beyond 6 months is beneficial, even in patients with *MGMT*-methylated disease.
[jj] Alternating electric field therapy is only an option for patients with supratentorial disease.
[kk] Moderate to significant myelosuppression was observed, but the toxicity profile for this regimen is not yet fully defined.
[ll] Clinical benefit from temozolomide is likely to be lower in patients whose tumors lack *MGMT* promoter methylation.

Note: All recommendations are category 2A unless otherwise indicated.

Version 3.2025, 12/05/25 © 2025 National Comprehensive Cancer Network® (NCCN®), All rights reserved. NCCN Guidelines® and this illustration may not be reproduced in any form without the express written permission of NCCN.

PLEASE NOTE that use of this NCCN Content is governed by the End-User License Agreement, and you MAY NOT distribute this Content or use it with any artificial intelligence model or tool.
Printed by A. S. M. FAZLUL KARIM CHOWDHURY on 4/20/2026 3:06:38 AM. Copyright © 2026 National Comprehensive Cancer Network, Inc. All Rights Reserved.

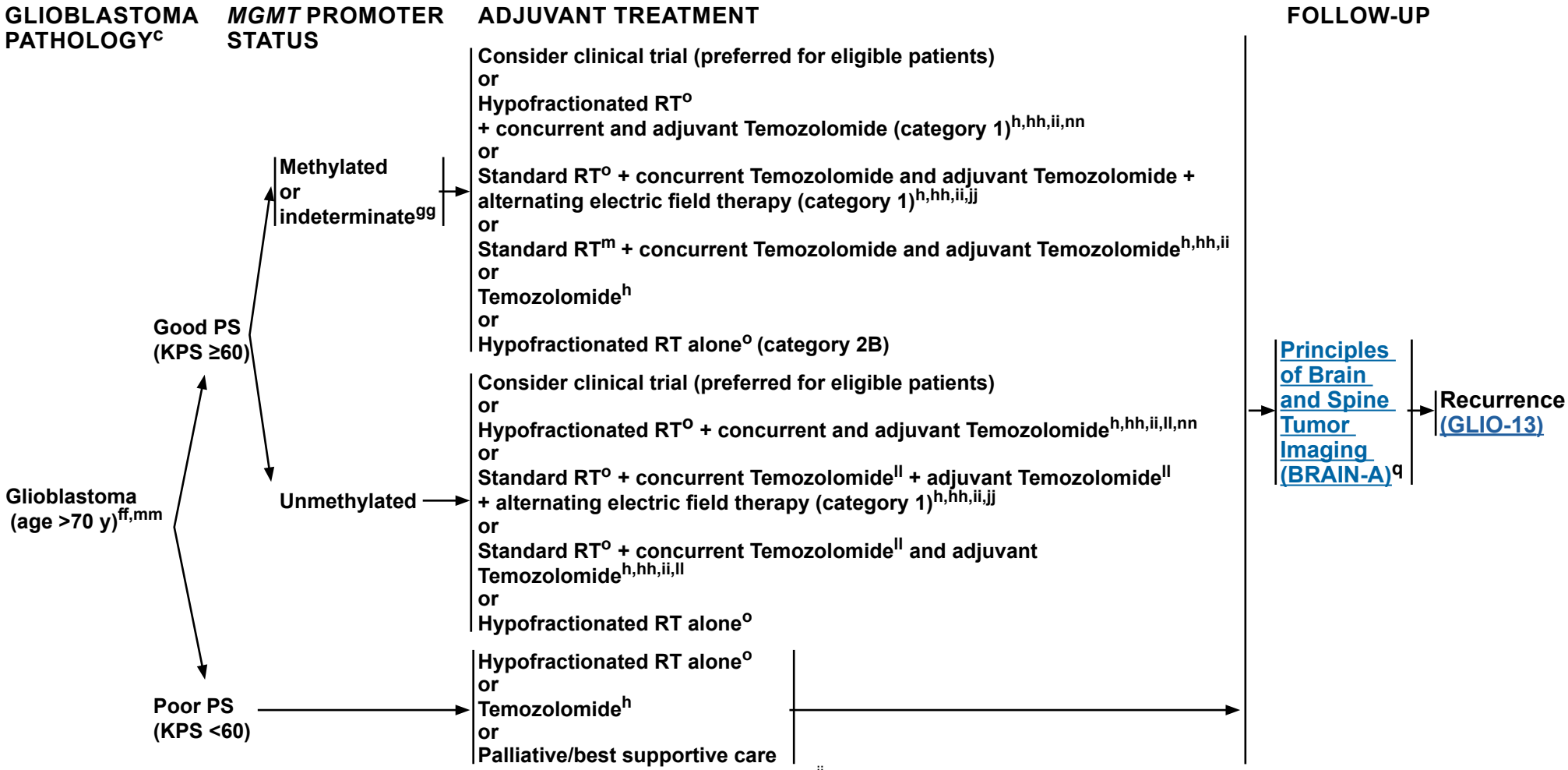

[c] For recommended molecular diagnostics, see Principles of Brain Tumor Pathology (BRAIN-E).
[h] Systemic Therapy Options (GLIO-A).
[o] Principles of Radiation Therapy for Brain and Spinal Cord (BRAIN-C).
[q] Within the first 3 months after completion of RT and concomitant temozolomide, diagnosis of recurrence can be indistinguishable from pseudoprogression on neuroimaging.
[ff] This pathway also includes gliosarcoma.
[gg] Consider pyrosequencing if not done (Mansouri A, et al. Neuro Oncol 2019;21:167-178).
[hh] Combination of modalities may lead to increased toxicity or radiographic changes.
[ii] There are no clear data that treatment with temozolomide beyond 6 months is beneficial, even in patients with *MGMT*-methylated disease.
[jj] Alternating electric field therapy is only an option for patients with supratentorial disease.
[ll] Clinical benefit from temozolomide is likely to be lower in patients whose tumors lack *MGMT* promoter methylation.
[mm] NCCN Guidelines for Older Adult Oncology.
[nn] Hypofractionated RT and temozolomide have not been formally compared with standard RT and temozolomide in patients aged >70 y.

Note: All recommendations are category 2A unless otherwise indicated.

Version 3.2025, 12/05/25 © 2025 National Comprehensive Cancer Network® (NCCN®), All rights reserved. NCCN Guidelines® and this illustration may not be reproduced in any form without the express written permission of NCCN.

PLEASE NOTE that use of this NCCN Content is governed by the End-User License Agreement, and you MAY NOT distribute this Content or use it with any artificial intelligence model or tool.
Printed by A. S. M. FAZLUL KARIM CHOWDHURY on 4/20/2026 3:06:38 AM. Copyright © 2026 National Comprehensive Cancer Network, Inc. All Rights Reserved.

PATHOLOGY[c] | ***MGMT* PROMOTER STATUS** | **ADJUVANT TREATMENT** | **FOLLOW-UP**

The treatment recommendations on this page are general high-grade glioma options. Tumor *MGMT* status and next-generation sequencing (NGS) should be performed to possibly expand therapeutic options.

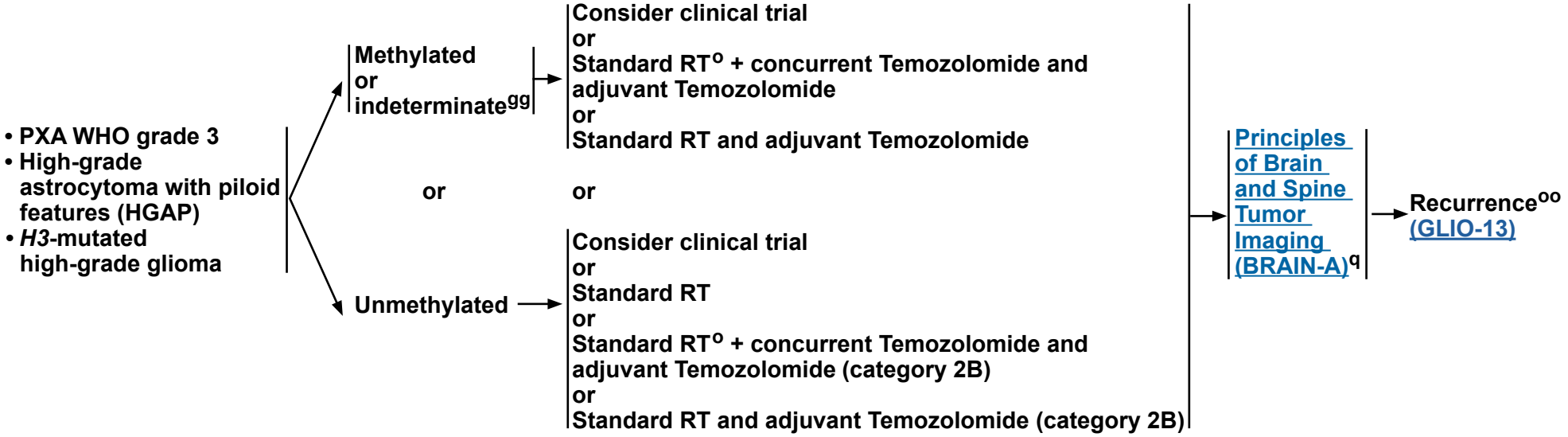

[c] For recommended molecular diagnostics, see Principles of Brain Tumor Pathology (BRAIN-E).
[o] Principles of Radiation Therapy for Brain and Spinal Cord (BRAIN-C).
[q] Within the first 3 months after completion of RT and concomitant temozolomide, diagnosis of recurrence can be indistinguishable from pseudoprogression on neuroimaging.
[gg] Consider pyrosequencing if not done (Mansouri A, et al. Neuro Oncol 2019;21:167-178).
[oo] Systemic therapy options for the more common recurrent high-grade gliomas (glioblastoma, grade 3 oligodendroglioma, and grade 3 or 4 astrocytoma) also apply to these other high-grade gliomas. See GLIO-A 6 of 9.

Note: All recommendations are category 2A unless otherwise indicated.

Version 3.2025, 12/05/25 © 2025 National Comprehensive Cancer Network® (NCCN®), All rights reserved. NCCN Guidelines® and this illustration may not be reproduced in any form without the express written permission of NCCN.

PLEASE NOTE that use of this NCCN Content is governed by the End-User License Agreement, and you MAY NOT distribute this Content or use it with any artificial intelligence model or tool.
Printed by: A. S. MUNAZLI | Karbon 2 Node Europe | 12/20/2025 | Copyright © 2025 National Comprehensive Cancer Network, Inc. All Rights Reserved.

Adult Glioma: Recurrent or Progressive Disease (WHO Grades 3 & 4)

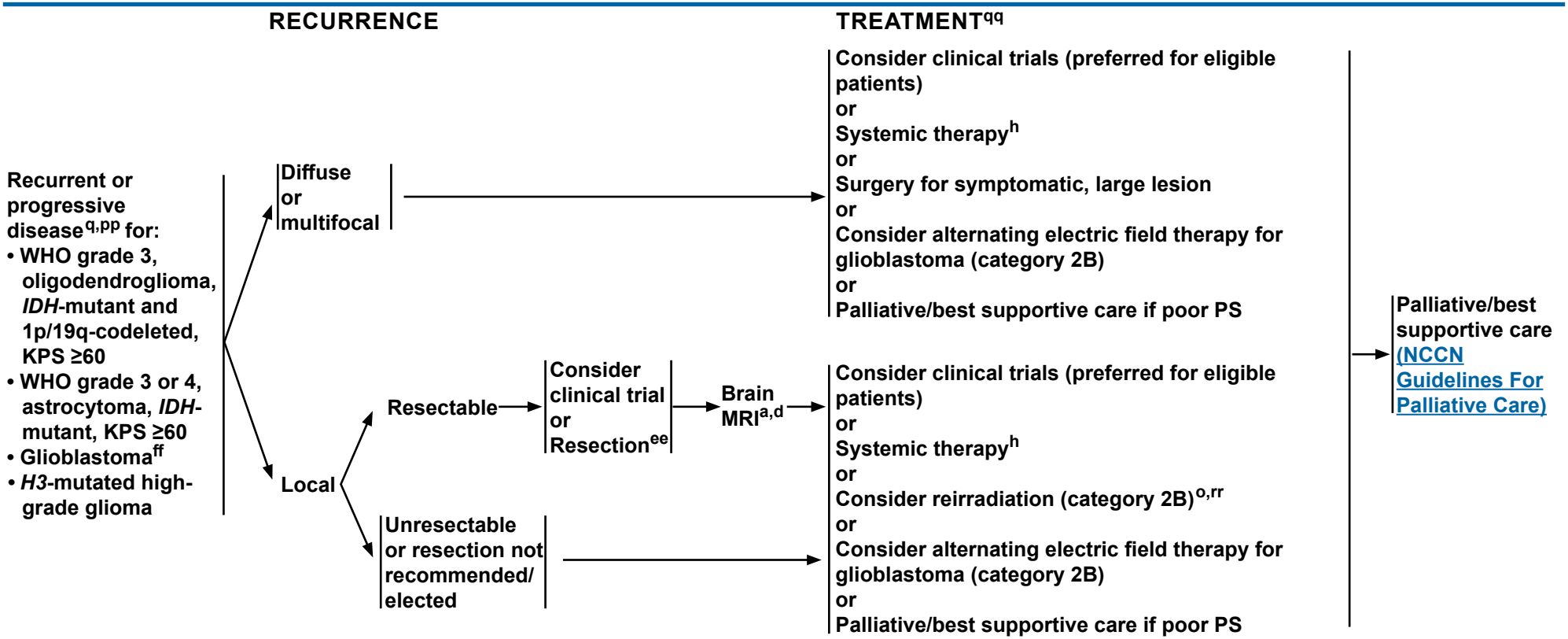

[a] Principles of Brain and Spine Tumor Imaging (BRAIN-A).
[d] Postoperative brain MRI within 48 hours after surgery.
[h] Systemic Therapy Options (GLIO-A).
[o] Principles of Radiation Therapy for Brain and Spinal Cord (BRAIN-C).
[q] Within the first 3 months after completion of RT and concomitant temozolomide, diagnosis of recurrence can be indistinguishable from pseudoprogression on neuroimaging.
[ee] Consider carmustine (BCNU) wafer implant during maximal safe resection (category 2B). Treatment with carmustine wafer may impact enrollment in adjuvant clinical trials.
[ff] This pathway also includes gliosarcoma.
[qq] The efficacy of standard-of-care treatment for recurrent glioblastoma is suboptimal, so for eligible patients consideration of clinical trials is highly encouraged. Prior treatment may impact enrollment in clinical trials.
[pp] Consider biopsy, magnetic resonance (MR) spectroscopy, MR perfusion, brain PET/CT, or brain PET/MRI, or re-image to follow changes that may be due to progression versus radionecrosis.
[rr] Especially if long interval since prior RT and/or if there was a good response to prior RT (RTOG 1205; Tsien CI, et al. J Clin Oncol 2023;41:1285-1295).

Note: All recommendations are category 2A unless otherwise indicated.

Version 3.2025, 12/05/25 © 2025 National Comprehensive Cancer Network® (NCCN®), All rights reserved. NCCN Guidelines® and this illustration may not be reproduced in any form without the express written permission of NCCN.

PLEASE NOTE that use of this NCCN Content is governed by the End-User License Agreement, and you MAY NOT distribute this Content or use it with any artificial intelligence model or tool.
Printed by A. S. M. FAZLUL KARIM CHOWDHURY on 4/20/2026 3:06:38 AM. Copyright © 2026 National Comprehensive Cancer Network, Inc. All Rights Reserved.

CIRCUMSCRIBED GLIOMA: SYSTEMIC THERAPY OPTIONS[a]

	Preferred	Other Recommended	Useful in Certain Circumstances
Adjuvant Treatment			• PA, circumscribed ganglioglioma/neuroglioma/glioneuronal tumor, PXA (grade 2) with *BRAF* V600E activation mutation ▸ BRAF/MEK inhibitors: ◊ Dabrafenib/trametinib[4,5] ◊ Vemurafenib/cobimetinib[6,7] • SEGA ▸ mTOR inhibitor (eg, everolimus)[8,9]
Recurrent[b] or Progressive Disease		• RT + adjuvant PCV[c,d] • RT + adjuvant Temozolomide[d] • RT + concurrent and adjuvant Temozolomide[d] • Temozolomide[e,1,2] • Lomustine or carmustine • PCV[c,3]	• *NTRK* gene fusion tumors ▸ Larotrectinib[10] ▸ Entrectinib[11] ▸ Repotrectinib (category 2B)[12] • *BRAF* alterations ▸ *BRAF* fusion or rearrangement, or *BRAF* V600 mutation: ◊ Tovorafenib[13] ▸ *BRAF* V600E activation mutation ◊ BRAF/MEK inhibitors: – Dabrafenib/trametinib[4,5] – Vemurafenib/cobimetinib[6,7] • *BRAF* fusion or *BRAF* V600E activating mutation or in *NF1*-mutated glioma ▸ MEK inhibitor ◊ Selumetinib[14] ◊ Trametinib[15](for *BRAF* only) • PAs ▸ Cisplatin/etoposide[16] ▸ Carboplatin[17] ▸ Carboplatin + vincristine (category 2B)[18] ▸ Thioguanine + PCV[c] (category 2B)[18,19]

[a] An FDA-approved biosimilar is an appropriate substitute for any recommended systemic biologic therapy in the NCCN Guidelines.
[b] There are multiple reasonable options, but there is no uniformly recommended option at this time for recurrent disease.
[c] When PCV is recommended, carmustine may be substituted for lomustine.
[d] If no prior RT; or if prior RT, consider with highly focused RT in select cases, if new lesion outside target of prior RT or the recurrence is small and geometrically favorable.
[e] For patients not previously treated.

Continued

Note: All recommendations are category 2A unless otherwise indicated.

Version 3.2025, 12/05/25 © 2025 National Comprehensive Cancer Network® (NCCN®), All rights reserved. NCCN Guidelines® and this illustration may not be reproduced in any form without the express written permission of NCCN.

PLEASE NOTE that use of this NCCN Content is governed by the End-User License Agreement, and you MAY NOT distribute this Content or use it with any artificial intelligence model or tool.
Printed by A. S. M. FAZLUL KARIM CHOWDHURY on 4/20/2026 3:06:38 AM. Copyright © 2026 National Comprehensive Cancer Network, Inc. All Rights Reserved.

OLIGODENDROGLIOMA (*IDH*-MUTANT, 1p19q-CODELETED): SYSTEMIC THERAPY OPTIONS[a]

	Preferred	Other Recommended	Useful in Certain Circumstances
No residual/measurable disease or adjuvant treatment after surgery/biopsy when treatment with RT and chemotherapy is not preferred, WHO grade 2, KPS ≥60	• Vorasidenib[g,h] (category 1 for residual/measurable disease after surgery/biopsy) for *IDH1* or *IDH2* mutations		• Ivosidenib for *IDH1* mutation[24] (if unable to tolerate vorasidenib)
Adjuvant Treatment after surgery/biopsy, if initial treatment with RT and chemotherapy is preferred or after progression on IDH inhibitor WHO grade 2, KPS ≥60	• Standard RT + adjuvant PCV (category 1)[c,20,21]	• Standard RT + adjuvant Temozolomide[32,33] • Standard RT + concurrent and adjuvant Temozolomide[32,33]	• Temozolomide[m,32] • PCV[c,m]
Adjuvant Treatment WHO grade 3, KPS ≥60	• Standard RT + adjuvant PCV (category 1)[c,i,22] • Standard RT + neoadjuvant PCV (category 1)[c,i,23]	• Standard RT + concurrent and adjuvant Temozolomide[34] • Standard RT + adjuvant Temozolomide[35,36]	• Ivosidenib for *IDH1* mutation (if unable to tolerate vorasidenib) (category 2B) • Vorasidenib for *IDH1* or *IDH2* mutations (category 2B)
Adjuvant Treatment, KPS <60		• RT + concurrent and/or adjuvant Temozolomide[k] • Temozolomide (category 2B)[37] • Ivosidenib for *IDH1* mutation (if unable to tolerate vorasidenib) (category 2B for WHO grade 3) • Vorasidenib for *IDH1* or *IDH2* mutations (category 2B for WHO grade 3)[g]	
Recurrent[b] or Progressive Disease after RT + chemotherapy WHO grade 2, KPS ≥60	• Temozolomide[e,1,2] • Lomustine or carmustine • PCV[c,3] • Ivosidenib for *IDH1* mutation[24] (if unable to tolerate vorasidenib) • Vorasidenib for *IDH1* or *IDH2* mutations[g]		
Recurrent[f] or Progressive Disease, WHO grade 3, KPS ≥60	• Temozolomide[1,2,25,26] • Lomustine or carmustine[27] • PCV[c,28] • Bevacizumab[j,29-31] • Ivosidenib for *IDH1* mutation[24] (if unable to tolerate vorasidenib) • Vorasidenib for *IDH1* or *IDH2* mutations[g]	• Systemic therapy[l] + bevacizumab[j] ▸ Carmustine or lomustine + bevacizumab[j,38] ▸ Temozolomide + bevacizumab[j,39]	• If disease progression on or intolerance to the preferred or other recommended regimens ▸ Etoposide[40,41] (category 2B) ▸ Carboplatin (category 3)[42-44] ▸ Cisplatin (category 3)[43]

Note: All recommendations are category 2A unless otherwise indicated.

Continued

Version 3.2025, 12/05/25 © 2025 National Comprehensive Cancer Network® (NCCN®), All rights reserved. NCCN Guidelines® and this illustration may not be reproduced in any form without the express written permission of NCCN.

PLEASE NOTE that use of this NCCN Content is governed by the End-User License Agreement, and you MAY NOT distribute this Content or use it with any artificial intelligence model or tool.
Printed by A. S. M. FAZLUL KARIM CHOWDHURY on 4/20/2026 3:06:38 AM. Copyright © 2026 National Comprehensive Cancer Network, Inc. All Rights Reserved.

FOOTNOTES

[a] An FDA-approved biosimilar is an appropriate substitute for any recommended systemic biologic therapy in the NCCN Guidelines.
[b] There are multiple reasonable options, but there is no uniformly recommended option at this time for recurrent disease.
[c] When PCV is recommended, carmustine may be substituted for lomustine.
[e] For patients not previously treated.
[f] Strongly suggest consideration of clinical trials prior to treating recurrent disease with standard systemic therapy, as additional therapies may eliminate the majority of clinical trial options.
[g] Vorasidenib is a dual inhibitor of *IDH1* and *IDH2* mutations. In a phase 3 study of vorasidenib versus placebo (Mellinghoff IK, et al. N Engl J Med 2023;389:589-601) in patients with residual or recurrent grade 2 *IDH*-mutant glioma (after surgery and no prior treatment), vorasidenib improved median PFS (27.7 months vs. 11.1 months), compared to placebo. Vorasidenib has the most safety data in patients with newly diagnosed grade 2 *IDH*-mutant gliomas.
[h] Newly diagnosed patients with oligodendroglioma/astrocytoma (WHO grade 2 or 3) who did not have residual disease were excluded from participation in the phase 3 INDIGO study of vorasidenib versus placebo. Therefore, it remains unknown if this subset of patients would benefit from immediate treatment with an IDH inhibitor. The safety of long-term treatment with IDH inhibitors is unknown. The Panel recommends discussing the possible risks and benefits of starting treatment right away with an IDH inhibitor with these patients.
[i] The Panel recommends that PCV be administered after RT (as per EORTC 26951) since the intensive PCV regimen given prior to RT (RTOG 9402) was not tolerated as well.
[j] Patients who have evidence of radiographic progression may benefit from continuation of bevacizumab to prevent rapid neurologic deterioration.
[k] Hypofractionated RT preferred.
[l] Bevacizumab + systemic therapy can be considered if disease progression on bevacizumab monotherapy and it is desirable to continue the steroid-sparing effects of bevacizumab.
[m] In rare circumstances, treating a patient with systemic therapy without RT may be considered.

Continued

Note: All recommendations are category 2A unless otherwise indicated.

Version 3.2025, 12/05/25 © 2025 National Comprehensive Cancer Network® (NCCN®), All rights reserved. NCCN Guidelines® and this illustration may not be reproduced in any form without the express written permission of NCCN.

PLEASE NOTE that use of this NCCN Content is governed by the End-User License Agreement, and you MAY NOT distribute this Content or use it with any artificial intelligence model or tool.
Printed by A. S. M. FAZLUL KARIM CHOWDHURY on 4/20/2026 3:06:38 AM. Copyright © 2026 National Comprehensive Cancer Network, Inc. All Rights Reserved.

IDH-MUTANT ASTROCYTOMA: SYSTEMIC THERAPY OPTIONS[a]

	Preferred	Other Recommended	Useful in Certain Circumstances
No residual/measurable disease or adjuvant treatment after surgery/ biopsy when treatment with RT and chemotherapy is not preferred, WHO grade 2, KPS ≥60	• Vorasidenib[g,h] (category 1 for residual/ measurable disease after surgery/biopsy) for *IDH1* or *IDH2* mutations		• Ivosidenib for *IDH1* mutation (if unable to tolerate vorasidenib)
Adjuvant Treatment after surgery/ biopsy, if initial treatment with RT and chemotherapy is preferred or after progression on IDH inhibitor, WHO grade 2, KPS ≥60	• Standard RT + adjuvant PCV[c,20,21]	• Standard RT + adjuvant Temozolomide[32,33] • Standard RT + concurrent and adjuvant Temozolomide[32,33]	• Temozolomide[m,32] • PCV[c,m]
Adjuvant Treatment, WHO grade 3, KPS ≥60	• Standard RT + adjuvant Temozolomide[45] • Standard RT + concurrent and adjuvant Temozolomide[45-46]		• Ivosidenib for *IDH1* mutation (if unable to tolerate vorasidenib) (category 2B) • Vorasidenib (category 2B) for *IDH1* or *IDH2* mutations
Adjuvant Treatment, WHO grade 4, KPS ≥60	• Standard RT + adjuvant Temozolomide[45] • Standard RT + concurrent and adjuvant Temozolomide ± alternating electric field therapy		
Adjuvant Treatment, KPS <60		• RT + concurrent and/or adjuvant Temozolomide[k] • Temozolomide (category 2B)[37]	• Ivosidenib for *IDH1* mutation (if unable to tolerate vorasidenib) (category 2B for grade 3) • Vorasidenib for *IDH1* or *IDH2* mutations (category 2B for grade 3)[g]
Recurrent[b] or Progressive Disease after RT + chemotherapy, WHO grade 2, KPS ≥60	• Temozolomide[e,1,2] • Lomustine or carmustine • PCV[c,3] • Ivosidenib for *IDH1* mutation[24] (if unable to tolerate vorasidenib) • Vorasidenib for *IDH1* or *IDH2* mutations		
Recurrent[f] or Progressive Disease, WHO grade 3 or 4, KPS ≥60	• Temozolomide[1,2,25,26] • Lomustine or carmustine[27] • PCV[c,28] • Bevacizumab[j,29-31] • Ivosidenib for *IDH1* mutation (if unable to tolerate vorasidenib) (category 2B)[24] • Vorasidenib for *IDH1* or *IDH2* mutations (category 2B)[g]	• Systemic therapy[l] + bevacizumab[j] ▸ Carmustine or lomustine + bevacizumab[j,38] ▸ Temozolomide + bevacizumab[j,39]	• If disease progression on or intolerance to the preferred or other recommended regimens ▸ Etoposide[40,41] (category 2B) ▸ Carboplatin (category 3)[42-44] ▸ Cisplatin (category 3)[43]

Note: All recommendations are category 2A unless otherwise indicated.

Continued

Version 3.2025, 12/05/25 © 2025 National Comprehensive Cancer Network® (NCCN®), All rights reserved. NCCN Guidelines® and this illustration may not be reproduced in any form without the express written permission of NCCN.

PLEASE NOTE that use of this NCCN Content is governed by the End-User License Agreement, and you MAY NOT distribute this Content or use it with any artificial intelligence model or tool.
Printed by A. S. M. FAZLUL KARIM CHOWDHURY on 4/20/2026 3:06:38 AM. Copyright © 2026 National Comprehensive Cancer Network, Inc. All Rights Reserved.

FOOTNOTES

[a] An FDA-approved biosimilar is an appropriate substitute for any recommended systemic biologic therapy in the NCCN Guidelines.
[b] There are multiple reasonable options, but there is no uniformly recommended option at this time for recurrent disease.
[c] When PCV is recommended, carmustine may be substituted for lomustine.
[e] For patients not previously treated.
[f] Strongly suggest consideration of clinical trials prior to treating recurrent disease with standard systemic therapy, as additional therapies may eliminate the majority of clinical trial options.
[g] Vorasidenib is a dual inhibitor of *IDH1* and *IDH2* mutations. In a phase 3 study of vorasidenib versus placebo (Mellinghoff IK, et al. N Engl J Med 2023;389:589-601) in patients with residual or recurrent grade 2 *IDH*-mutant glioma (after surgery and no prior treatment), vorasidenib improved median PFS (27.7 months vs. 11.1 months), compared to placebo. Vorasidenib has the most safety data in patients with newly diagnosed grade 2 *IDH*-mutant gliomas.
[h] Newly diagnosed patients with oligodendroglioma/astrocytoma (WHO grade 2 or 3) who did not have residual disease were excluded from participation in the phase 3 INDIGO study of vorasidenib versus placebo. Therefore, it remains unknown if this subset of patients would benefit from immediate treatment with an IDH inhibitor. The safety of long-term treatment with IDH inhibitors is unknown. The Panel recommends discussing the possible risks and benefits of starting treatment right away with an IDH inhibitor with these patients.
[j] Patients who have evidence of radiographic progression may benefit from continuation of bevacizumab to prevent rapid neurologic deterioration.
[k] Hypofractionated RT preferred.
[l] Bevacizumab + systemic therapy can be considered if disease progression on bevacizumab monotherapy and it is desirable to continue the steroid-sparing effects of bevacizumab.
[m] In rare circumstances, treating a patient with systemic therapy without RT may be considered.

Continued

Note: All recommendations are category 2A unless otherwise indicated.

Version 3.2025, 12/05/25 © 2025 National Comprehensive Cancer Network® (NCCN®), All rights reserved. NCCN Guidelines® and this illustration may not be reproduced in any form without the express written permission of NCCN.

PLEASE NOTE that use of this NCCN Content is governed by the End-User License Agreement, and you MAY NOT distribute this Content or use it with any artificial intelligence model or tool.
Printed by A. S. M. FAZLUL KARIM CHOWDHURY on 4/20/2026 3:06:38 AM. Copyright © 2026 National Comprehensive Cancer Network, Inc. All Rights Reserved.

GLIOBLASTOMA: SYSTEMIC THERAPY OPTIONS[a,n]

	Preferred	Other Recommended	Useful in Certain Circumstances
Adjuvant Treatment, KPS ≥60	• RT + concurrent and adjuvant Temozolomide[47,48] ± tumor treating fields (TTF)[p,49]		• Temozolomide (for patients with *MGMT* promoter-methylated or indeterminate tumors and age >70 years)[47,65] • Standard RT + concurrent and adjuvant lomustine and Temozolomide (for patients with *MGMT* promoter-methylated or indeterminate tumors and age ≤70 years) (category 2B)[q,66]
Adjuvant Treatment, KPS <60			• Hypofractionated RT + concurrent or adjuvant Temozolomide (for patients aged ≤70 years)[k,67] • Temozolomide (for patients with *MGMT* promoter-methylated tumors)[65]
Recurrent or Progressive Disease[f,l,o]	• Bevacizumab[j,50-53] • Temozolomide[2,27,54,55] • Lomustine or carmustine[56-59] • PCV[c,60,61]	• Systemic therapy[l] + bevacizumab[j] ▸ Carmustine or lomustine + bevacizumab[j,62] ▸ Temozolomide + bevacizumab[j,63,64]	• If disease progression or intolerance to the preferred or other recommended regimens ▸ Etoposide (category 2B)[40] ▸ Platinum-based regimens[r,42-44] (category 3) • *NTRK* gene fusion tumors ▸ Larotrectinib[10] ▸ Entrectinib[11] ▸ Repotrectinib (category 2B)[12] • *FGFR* alterations ▸ Erdafitinib (category 2B)[68,69] • *BRAF* alterations ▸ *BRAF* V600E activation mutation ◊ BRAF/MEK inhibitors: – Dabrafenib/trametinib[4,5] – Vemurafenib/cobimetinib[6,7] • H3K27M mutation ▸ Dordaviprone[70]

Note: All recommendations are category 2A unless otherwise indicated.

Continued

Version 3.2025, 12/05/25 © 2025 National Comprehensive Cancer Network® (NCCN®), All rights reserved. NCCN Guidelines® and this illustration may not be reproduced in any form without the express written permission of NCCN.

PLEASE NOTE that use of this NCCN Content is governed by the End-User License Agreement, and you MAY NOT distribute this Content or use it with any artificial intelligence model or tool.
Printed by A. S. M. FAZLUL KARIM CHOWDHURY on 4/20/2026 3:06:38 AM. Copyright © 2026 National Comprehensive Cancer Network, Inc. All Rights Reserved.

FOOTNOTES

[a] An FDA-approved biosimilar is an appropriate substitute for any recommended systemic biologic therapy in the NCCN Guidelines.
[c] When PCV is recommended, carmustine may be substituted for lomustine.
[f] Strongly suggest consideration of clinical trials prior to treating recurrent disease with standard systemic therapy, as additional therapies may eliminate the majority of clinical trial options.
[j] Patients who have evidence of radiographic progression may benefit from continuation of bevacizumab to prevent rapid neurologic deterioration.
[k] Hypofractionated RT preferred.
[l] Bevacizumab + systemic therapy can be considered if disease progression on bevacizumab monotherapy and it is desirable to continue the steroid-sparing effects of bevacizumab.
[n] There are no identified targeted agents with demonstrated efficacy in glioblastoma. However, the Panel encourages molecular testing of tumor because if a driver mutation is detected, it may be reasonable to treat with a targeted therapy on a compassionate use basis and/or the patient may have more treatment options in the context of a clinical trial. Molecular testing also has a valuable role in improving diagnostic accuracy and prognostic stratification that may inform treatment selection.
[o] Systemic therapy options also apply for *H3*-mutated high-grade glioma. Crowell C, et al. Neurooncol Adv 2022;4:1-10 and Gojo J, et al. Front Oncol 2020;9:1436.
[p] Alternating electric field therapy is only an option for patients with supratentorial disease.
[q] Moderate to significant myelosuppression was observed, but the toxicity profile for this regimen is not yet fully defined.
[r] Platinum-based regimens include cisplatin or carboplatin.

Continued

Note: All recommendations are category 2A unless otherwise indicated.

Version 3.2025, 12/05/25 © 2025 National Comprehensive Cancer Network® (NCCN®), All rights reserved. NCCN Guidelines® and this illustration may not be reproduced in any form without the express written permission of NCCN.

PLEASE NOTE that use of this NCCN Content is governed by the End-User License Agreement, and you MAY NOT distribute this Content or use it with any artificial intelligence model or tool.
Printed by A. S. M. FAZLUL KARIM CHOWDHURY on 4/20/2026 3:06:38 AM. Copyright © 2026 National Comprehensive Cancer Network, Inc. All Rights Reserved.

REFERENCES

[1] Nicholson HS, Kretschmar CS, Krailo M, et al. Phase 2 study of temozolomide in children and adolescents with recurrent central nervous system tumors: a report from the Children's Oncology Group. Cancer 2007;110:1542-1550.
[2] Perry JR, Rizek P, Cashman R, et al. temozolomide rechallenge in recurrent malignant glioma by using a continuous temozolomide schedule: the "rescue" approach. Cancer 2008;113:2152-2157.
[3] Triebels VH, Taphoorn MJ, Brandes AA, et al. Salvage PCV systemic therapy for temozolomide-resistant oligodendrogliomas. Neurology 2004;63:904-906.
[4] Brown NF, Carter T, Kitchen N, Mulholland P. Dabrafenib and trametinib in BRAFV600E mutated glioma. CNS Oncol 2017;6:291-296.
[5] Marks AM, Bindra RS, DiLuna ML, et al. Response to the BRAF/MEK inhibitors dabrafenib/trametinib in an adolescent with a BRAF V600E mutated anaplastic ganglioglioma intolerant to vemurafenib. Pediatr Blood Cancer 2018;65:e26969.
[6] Hyman DM, Puzanov I, Subbiah V, et al. Vemurafenib in multiple nonmelanoma cancers with BRAF V600 mutations. N Engl J Med 2015;373:726-736.
[7] Kaley T, Touat M, Subbiah V, et al. BRAF inhibition in BRAF(V600)-mutant gliomas: results from the VE-BASKET Study. J Clin Oncol 2018;36:3477-3484.
[8] Franz DN, Belousova E, Sparagana S, et al. Everolimus for subependymal giant cell astrocytoma in patients with tuberous sclerosis complex: 2-year open-label extension of the randomised EXIST-1 study. Lancet Oncol 2014;15:1513-1520.
[9] Franz DN, Belousova E, Sparagana S, et al. Efficacy and safety of everolimus for subependymal giant cell astrocytomas associated with tuberous sclerosis complex (EXIST-1): a multicentre, randomised, placebo-controlled phase 3 trial. Lancet 2013;381:125-132.
[10] Hong DS, DuBois SG, Kummar S, et al. Larotrectinib in patients with TRK fusion-positive solid tumours: a pooled analysis of three phase 1/2 clinical trials. Lancet Oncol 2020;21:531-540.
[11] Doebele RC, Drilon A, Paz-Ares L, et al. Entrectinib in patients with advanced or metastatic NTRK fusion-positive solid tumours: integrated analysis of three phase 1-2 trials. Lancet Oncol 2020;21:271-282.
[12] Solomon BJ, Drilon A, Lin JJ, et al. 1372P Repotrectinib in patients (pts) with NTRK fusion-positive (NTRK+) advanced solid tumors, including NSCLC: update from the phase I/II TRIDENT-1 trial. Ann Oncol 2023;34(Suppl):S787-S788.
[13] Kilburn LB, Khuong-Quang D-A, Hansford JR, et al. The type II RAF inhibitor tovorafenib in relapsed/refractory pediatric low-grade glioma: the phase 2 FIREFLY-1 trial. Nat Med 2024;30:207-217.
[14] Fangusaro J, Onar-Thomas A, Poussaint TY, et al. Selumetinib in paediatric patients with BRAF-aberrant or neurofibromatosis type 1-associated recurrent, refractory, or progressive low-grade glioma: a multicentre, phase 2 trial [article and supplementary appendix]. Lancet Oncol 2019;20:1011-1022.
[15] Bouffet E, Geoerger B, Moertel C, et al. Efficacy and safety of trametinib monotherapy or in combination with dabrafenib in pediatric *BRAF* V600-mutant low-grade Glioma. J Clin Oncol 2023;41:664-674.
[16] Massimino M, Spreafico F, Riva D, et al. A lower-dose, lower-toxicity cisplatin-etoposide regimen for childhood progressive low-grade glioma. J Neurooncol 2010;100:65-71.
[17] Moghrabi A, Friedman HS, Ashley DM, et al. Phase II study of carboplatin (CBDCA) in progressive low-grade gliomas. Neurosurg Focus 1998;4:e3.
[18] Ater JL, Zhou T, Holmes E, et al. Randomized study of two chemotherapy regimens for treatment of low-grade glioma in young children: A report from the children's Oncology Group. J Clin Oncol 2012;30:2641-2647.
[19] Mishra KK, Squire S, Lamborn K, et al. Phase II TPDCV protocol for pediatric low-grade hypothalamic/chiasmatic gliomas: 15-year update. J Neurooncol 2010;100:121-127.
[20] Buckner JC, Shaw EG, Pugh SL, et al. Radiation plus procarbazine, CCNU, and vincristine in low-grade glioma. N Engl J Med 2016;374:1344-1355.

Note: All recommendations are category 2A unless otherwise indicated.

Version 3.2025, 12/05/25 © 2025 National Comprehensive Cancer Network® (NCCN®), All rights reserved. NCCN Guidelines® and this illustration may not be reproduced in any form without the express written permission of NCCN.

PLEASE NOTE that use of this NCCN Content is governed by the End-User License Agreement, and you MAY NOT distribute this Content or use it with any artificial intelligence model or tool.
Printed by A. S. M. FAZLUL KARIM CHOWDHURY on 4/20/2026 3:06:38 AM. Copyright © 2026 National Comprehensive Cancer Network, Inc. All Rights Reserved.

REFERENCES

[21] Shaw EG, Wang M, Coons SW, et al. Randomized trial of radiation therapy plus procarbazine, lomustine, and vincristine systemic therapy for supratentorial adult low-grade glioma: initial results of RTOG 9802. J Clin Oncol 2012;30:3065-3070.
[22] van den Bent MJ, Brandes AA, Taphoorn MJ, et al. Adjuvant procarbazine, lomustine, and vincristine systemic therapy in newly diagnosed anaplastic oligodendroglioma: long-term follow-up of EORTC brain tumor group study 26951. J Clin Oncol 2013;31:344-350.
[23] Cairncross G, Wang M, Shaw E, et al. Phase III trial of chemoradiotherapy for anaplastic oligodendroglioma: long-term results of RTOG 9402. J Clin Oncol 2013;31:337-343.
[24] Mellinghoff IK, Ellingson BM, Touat M, et al. Ivosidenib in isocitrate dehydrogenase 1-mutated advanced glioma. J Clin Oncol 2020;38:3398-3406.
[25] Yung WK, Prados MD, Yaya-Tur R, et al. Multicenter phase II trial of temozolomide in patients with anaplastic astrocytoma or anaplastic oligoastrocytoma at first relapse. Temodal Brain Tumor Group. J Clin Oncol 1999;17:2762-2771.
[26] Perry JR, Belanger K, Mason WP, et al. Phase II trial of continuous dose-intense temozolomide in recurrent malignant glioma: RESCUE study. J Clin Oncol 2010;28:2051-2057.
[27] Prados M, Rodriguez L, Chamberlain M, et al. Treatment of recurrent gliomas with 1,3-bis (2-chloroethyl)-1-nitrosourea and alpha-difluoromethylornithine. Neurosurgery 1989;24:806-809.
[28] Soffietti R, Ruda R, Bradac GB, Schiffer D. PCV systemic therapy for recurrent oligodendrogliomas and oligoastrocytomas. Neurosurgery 1998;43:1066-1073.
[29] Norden AD, Young GS, Setayesh K, et al. Bevacizumab for recurrent malignant gliomas: efficacy, toxicity, and patterns of recurrence. Neurology 2008;70:779-787.
[30] Chamberlain MC, Johnston S. Bevacizumab for recurrent alkylator-refractory anaplastic oligodendroglioma. Cancer 2009;115:1734-1743.
[31] Chamberlain MC, Johnston S. Salvage systemic therapy with bevacizumab for recurrent alkylator-refractory anaplastic astrocytoma. J Neurooncol 2009;91:359-367.
[32] Pouratian N, Gasco J, Sherman JH, et al. Toxicity and efficacy of protracted low dose temozolomide for the treatment of low grade gliomas. J Neurooncol 2007;82:281-288.
[33] Fisher BJ, Hu C, Macdonald DR, et al. Phase 2 study of temozolomide-based chemoradiation therapy for high-risk low-grade gliomas: preliminary results of Radiation Therapy Oncology Group 0424. Int J Radiat Oncol Biol Phys 2015;91:497-504.
[34] Jaeckle K, Ballman K, van den Bent M, et al. CODEL: phase III study of RT, RT + temozolomide, or temozolomide for newly-diagnosed 1p/19q codeleted oligodendroglioma. Analysis from the initial study design. Neuro Oncol 2021;23:457-467.
[35] Panageas KS, Iwamoto FM, Cloughesy TF, et al. Initial treatment patterns over time for anaplastic oligodendroglial tumors. Neuro Oncol 2012;14:761-767.
[36] Shin JY, Diaz AZ. Utilization and impact of adjuvant therapy in anaplastic oligodendroglioma: an analysis on 1692 patients. J Neurooncol 2016;129:567-575.
[37] Ducray F, del Rio MS, Carpentier C, et al. Up-front temozolomide in elderly patients with anaplastic oligodendroglioma and oligoastrocytoma. J Neurooncol 2011;101:457-462.
[38] Vaccaro V, Fabi A, Vidiri A, et al. Activity and safety of bevacizumab plus fotemustine for recurrent malignant gliomas. Biomed Res Int 2014;2014:351252.
[39] Liu Y, Feng F, Ji P, et al. Improvement of health related quality of life in patients with recurrent glioma treated with bevacizumab plus daily temozolomide as the salvage therapy. Clin Neurol Neurosurg 2018;169:64-70.
[40] Fulton D, Urtasun R, Forsyth P. Phase II study of prolonged oral therapy with etoposide (VP16) for patients with recurrent malignant glioma. J Neurooncol 1996;27:149-155.
[41] Leonard A, Wolff JE. Etoposide improves survival in high-grade glioma: a meta-analysis. Anticancer Res 2013;33:3307-3315.
[42] Murray LJ, Bridgewater CH, Levy D. Carboplatin chemotherapy in patients with recurrent high-grade glioma. Clin Oncol (R Coll Radiol) 2011;23:55-61.
[43] Roci E, Cakani B, Brace G, et al. Platinum-based chemotherapy in recurrent high-grade glioma patients: retrospective study. Med Arch 2014;68:140-143.
[44] Soffietti R, Nobile M, Ruda R, et al. Second-line treatment with carboplatin for recurrent or progressive oligodendroglial tumors after PCV (procarbazine, lomustine, and vincristine) chemotherapy: a phase II study. Cancer 2004;100:807-813.
[45] van den Bent MJ, Tesileanu CMS, Wick W, et al. Adjuvant and concurrent temozolomide for 1p/19q non-co-deleted anaplastic glioma (CATNON; EORTC study 26053-22054): second interim analysis of a randomised, open-label, phase 3 study. Lancet Oncol 2021;22:813-823.
[46] Brandes AA, Nicolardi L, Tosoni A, et al. Survival following adjuvant PCV or temozolomide for anaplastic astrocytoma. Neuro Oncol 2006;8:253-260.

Continued

Note: All recommendations are category 2A unless otherwise indicated.

Version 3.2025, 12/05/25 © 2025 National Comprehensive Cancer Network® (NCCN®), All rights reserved. NCCN Guidelines® and this illustration may not be reproduced in any form without the express written permission of NCCN.

PLEASE NOTE that use of this NCCN Content is governed by the End-User License Agreement, and you MAY NOT distribute this Content or use it with any artificial intelligence model or tool.
Printed by A. S. M. FAZLUL KARIM CHOWDHURY on 4/20/2026 3:06:38 AM. Copyright © 2026 National Comprehensive Cancer Network, Inc. All Rights Reserved.

REFERENCES

[47] Stupp R, Mason WP, van den Bent MJ, et al. Radiotherapy plus concomitant and adjuvant temozolomide for glioblastoma. N Engl J Med 2005;352:987-996.
[48] Stupp R, Hegi ME, Mason WP, et al. Effects of radiotherapy with concomitant and adjuvant temozolomide versus radiotherapy alone on survival in glioblastoma in a randomised phase III study: 5-year analysis of the EORTC-NCIC trial. Lancet Oncol 2009;10:459-466.
[49] Stupp R, Taillibert S, Kanner A, et al. Effect of tumor-treating fields plus maintenance temozolomide vs maintenance temozolomide alone on survival in patients with glioblastoma: a randomized clinical trial. JAMA 2017;318:2306-2316.
[50] Cloughesy T, Prados MD, Mikkelsen T. A phase 2 randomized non-comparative clinical trial of the effect of bevacizumab alone or in combination with irinotecan on 6-month progression free survival in recurrent refractory glioblastoma [abstract]. J Clin Oncol 2008;26(Supp):Abstract 2010b.
[51] Friedman HS, Prados MD, Wen PY, et al. Bevacizumab alone and in combination with irinotecan in recurrent glioblastoma. J Clin Oncol 2009;27:4733-4740.
[52] Kreisl TN, Kim L, Moore K, et al. Phase II trial of single-agent bevacizumab followed by bevacizumab plus irinotecan at tumor progression in recurrent glioblastoma. J Clin Oncol 2009;27:740-745.
[53] Vredenburgh JJ, Desjardins A, Herndon JE, 2nd, et al. Phase II trial of bevacizumab and irinotecan in recurrent malignant glioma. Clin Cancer Res 2007;13:1253-1259.
[54] Yung WK, Albright RE, Olson J, et al. A phase II study of temozolomide vs. procarbazine in patients with glioblastoma multiforme at first relapse. Br J Cancer 2000;83:588-593.
[55] Weller M, Tabatabai G, Kastner B, et al. MGMT promoter methylation is a strong prognostic biomarker for benefit from dose-intensified temozolomide rechallenge in progressive glioblastoma: the DIRECTOR trial. Clin Cancer Res 2015;21:2057-2064.
[56] Wick W, Puduvalli VK, Chamberlain MC, et al. Phase III study of enzastaurin compared with lomustine in the treatment of recurrent intracranial glioblastoma. J Clin Oncol 2010;28:1168-1174.
[57] Brandes AA, Tosoni A, Amista P, et al. How effective is BCNU in recurrent glioblastoma in the modern era? A phase II trial. Neurology 2004;63:1281-1284.
[58] Reithmeier T, Graf E, Piroth T, et al. BCNU for recurrent glioblastoma multiforme: efficacy, toxicity and prognostic factors. BMC Cancer 2010;10:30.
[59] Taal W, Oosterkamp HM, Walenkamp AM, et al. Single-agent bevacizumab or lomustine versus a combination of bevacizumab plus lomustine in patients with recurrent glioblastoma (BELOB trial): a randomised controlled phase 2 trial. Lancet Oncol 2014;15:943-953.
[60] Carvalho BF, Fernandes AC, Almeida DS, et al. Second-line chemotherapy in recurrent glioblastoma: a 2-cohort study. Oncol Res Treat 2015;38:348-354.
[61] Schmidt F, Fischer J, Herrlinger U, et al. PCV chemotherapy for recurrent glioblastoma. Neurology 2006;66:587-589.
[62] Wick W, Gorlia T, Bendszus M, et al. Lomustine and bevacizumab in progressive glioblastoma. N Engl J Med 2017;377:1954-1963.
[63] Badruddoja MA, Pazzi M, Sanan A, et al. Phase II study of bi-weekly temozolomide plus bevacizumab for adult patients with recurrent glioblastoma. Cancer Chemother Pharmacol 2017;80:715-721.
[64] Desjardins A, Reardon DA, Coan A, et al. Bevacizumab and daily temozolomide for recurrent glioblastoma. Cancer 2012;118:1302-1312.
[65] Malmstrom A, Gronberg BH, Marosi C, et al. Temozolomide versus standard 6-week radiotherapy versus hypofractionated radiotherapy in patients older than 60 years with glioblastoma: the Nordic randomised, phase 3 trial. Lancet Oncol 2012;13:916-926.
[66] Herrlinger U, Tzaridis T, Mack F, et al. Lomustine-temozolomide combination therapy versus standard temozolomide therapy in patients with newly diagnosed glioblastoma with methylated MGMT promoter (CeTeG/ NOA-09): a randomised, open-label, phase 3 trial. Lancet 2019;393:678-688.
[67] Muni R, Minniti G, Lanzetta G, et al. Short-term radiotherapy followed by adjuvant chemotherapy in poor-prognosis patients with glioblastoma. Tumori 2010;96:60-64.
[68] Pant S, Schuler M, Iyer G, et al. Erdafitinib in patients with advanced solid tumors with FGRF alterations (RAGNAR): an international, single-arm, phase 2 study. Lancet Oncol 2023;24:925-935.
[69] Gong J, Mita AC, Wei Z, et al. Phase II study of erdafitinib in patients with tumors with fibroblast growth factor receptor mutations or fusions: Results from the NCI-MATCH ECOG-ACRIN trial (EAY 131) subprotocol K2. JCO Precis Oncol 2024;8:e2300407.
[70] Arrillaga-Romany I, Gardner SL, Odia Y, et al. ONC201 (dordaviprone) in recurrent H3K27M-Mutant diffuse midline glioma. J Clin Oncol. 2024;42:1542-1552.

Note: All recommendations are category 2A unless otherwise indicated.

Version 3.2025, 12/05/25 © 2025 National Comprehensive Cancer Network® (NCCN®), All rights reserved. NCCN Guidelines® and this illustration may not be reproduced in any form without the express written permission of NCCN.

PLEASE NOTE that use of this NCCN Content is governed by the End-User License Agreement, and you MAY NOT distribute this Content or use it with any artificial intelligence model or tool.
Printed by: A. S. MUNAZLI | Janssen Global Services, LLC | 12/30/2025 | Licensee ID: 9 | Copyright © 2025 National Comprehensive Cancer Network, Inc. All Rights Reserved.

NCCN Guidelines Version 3.2025
Adult Intracranial and Spinal Ependymoma (Excluding Subependymoma)

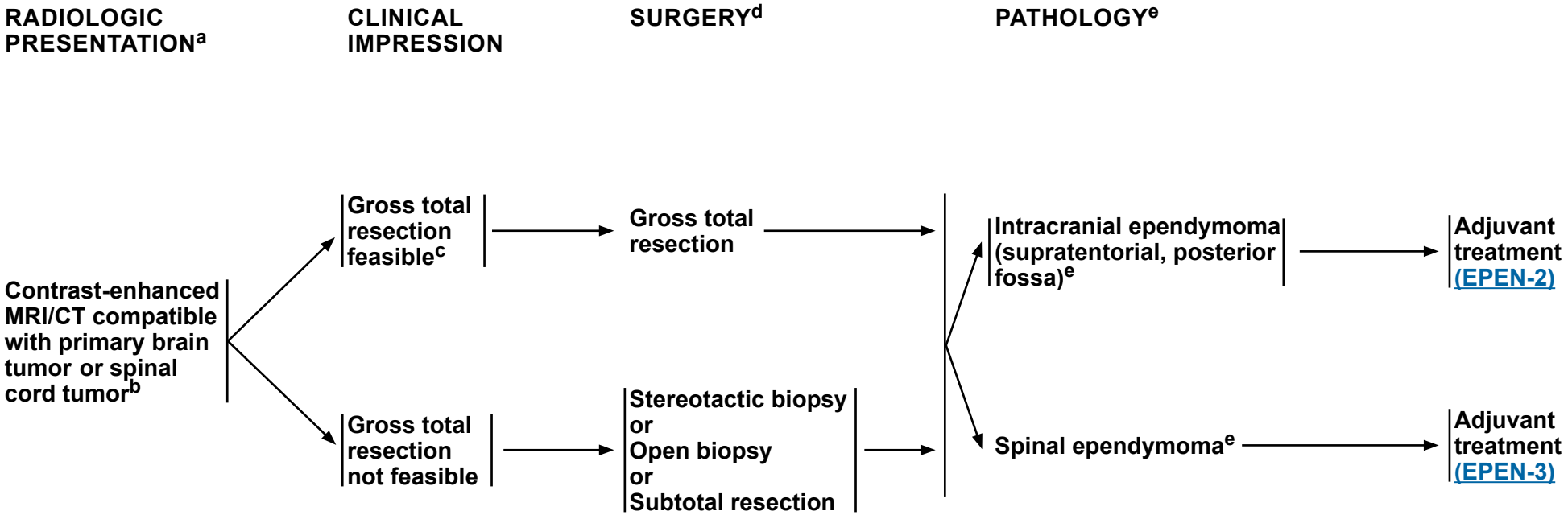

[a] Principles of Brain and Spine Tumor Imaging (BRAIN-A).
[b] Based on multidisciplinary review for treatment planning, once pathology is available. See Principles of Brain and Spine Tumor Management (BRAIN-D).
[c] If image-confirmed gross total resection not achieved, consider multidisciplinary review and reresection.
[d] Principles of Surgery (BRAIN-B).
[e] Principles of Brain Tumor Pathology (BRAIN-E).

Note: All recommendations are category 2A unless otherwise indicated.

Version 3.2025, 12/05/25 © 2025 National Comprehensive Cancer Network® (NCCN®), All rights reserved. NCCN Guidelines® and this illustration may not be reproduced in any form without the express written permission of NCCN.

PLEASE NOTE that use of this NCCN Content is governed by the End-User License Agreement, and you MAY NOT distribute this Content or use it with any artificial intelligence model or tool.
Printed by: A. S. MUNAZLI | Karbon 2025 | Expires: 12/30/2027 | Account: 1 | Copyright © 2025 National Comprehensive Cancer Network, Inc. All Rights Reserved.

INTRACRANIAL EPENDYMOMA

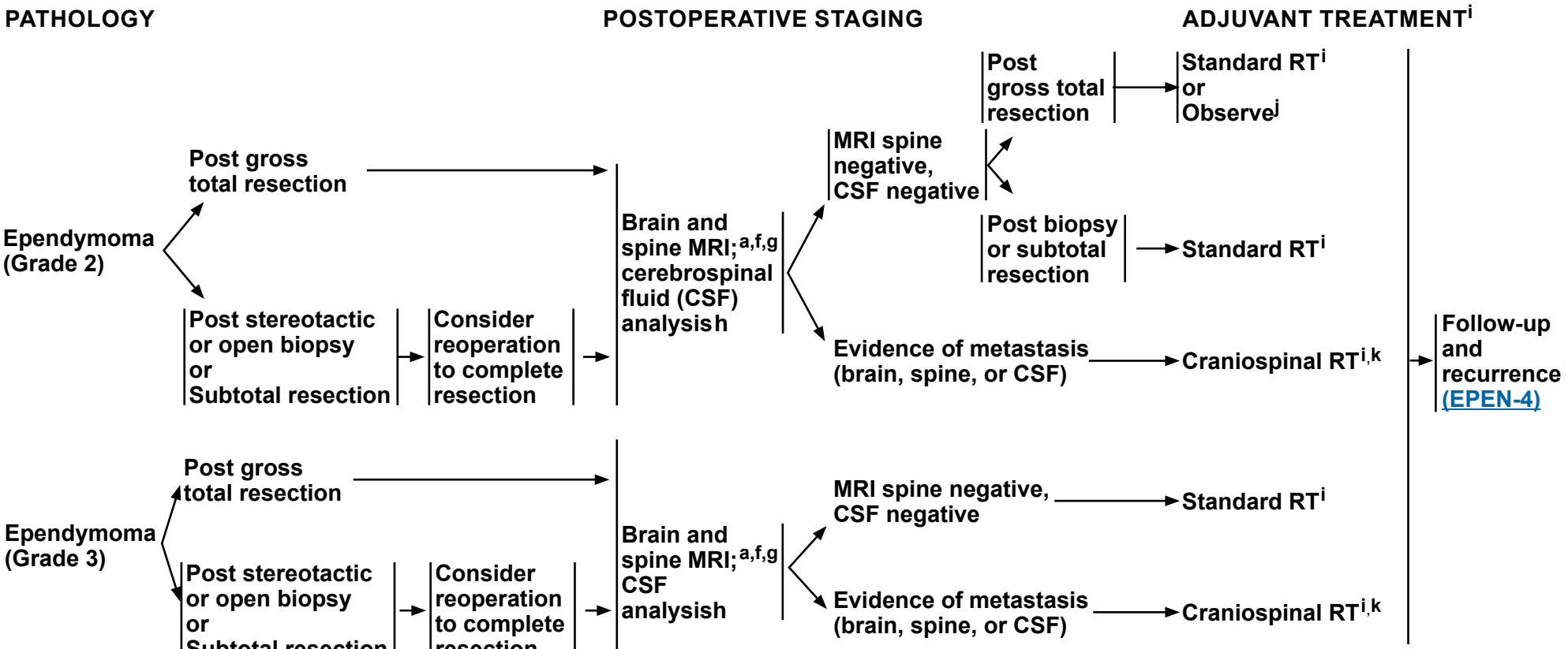

[h] Lumbar puncture is indicated when there is clinical concern for meningeal dissemination. Lumbar puncture should be done after MRI of spine is performed to avoid a false-positive imaging result. Lumbar puncture for CSF should be delayed at least 2 weeks after surgery to avoid possible false-positive cytology. Lumbar puncture may be contraindicated (eg, posterior fossa mass). When available, CSF-tumor-derived DNA (tDNA) testing can be considered with CSF cytology to increase sensitivity of tumor cell detection and assessment of residual disease after surgery.

[a] Principles of Brain and Spine Tumor Imaging (BRAIN-A).
[f] Postoperative brain MRI within 48 hours after surgery.
[g] If not done preoperatively, spine MRI should be delayed by at least 2–3 weeks post surgery to avoid post-surgical artifacts.
[i] Principles Radiation Therapy for Brain and Spinal Cord (BRAIN-C).
[j] Data supporting observation alone are based on retrospective studies.
[k] Consider proton therapy or intensity-modulated RT (IMRT) if available to reduce toxicity (Barney CL, et al. Neuro Oncol 2014;16:303-309).

Note: All recommendations are category 2A unless otherwise indicated.

Version 3.2025, 12/05/25 © 2025 National Comprehensive Cancer Network® (NCCN®), All rights reserved. NCCN Guidelines® and this illustration may not be reproduced in any form without the express written permission of NCCN.

PLEASE NOTE that use of this NCCN Content is governed by the End-User License Agreement, and you MAY NOT distribute this Content or use it with any artificial intelligence model or tool.
Printed by: A. S. MUNZLINGER | Karon Cancer Center | 12/30/2025 | Account: 1 | Copyright © 2025 National Comprehensive Cancer Network, Inc. All Rights Reserved.

SPINAL EPENDYMOMA

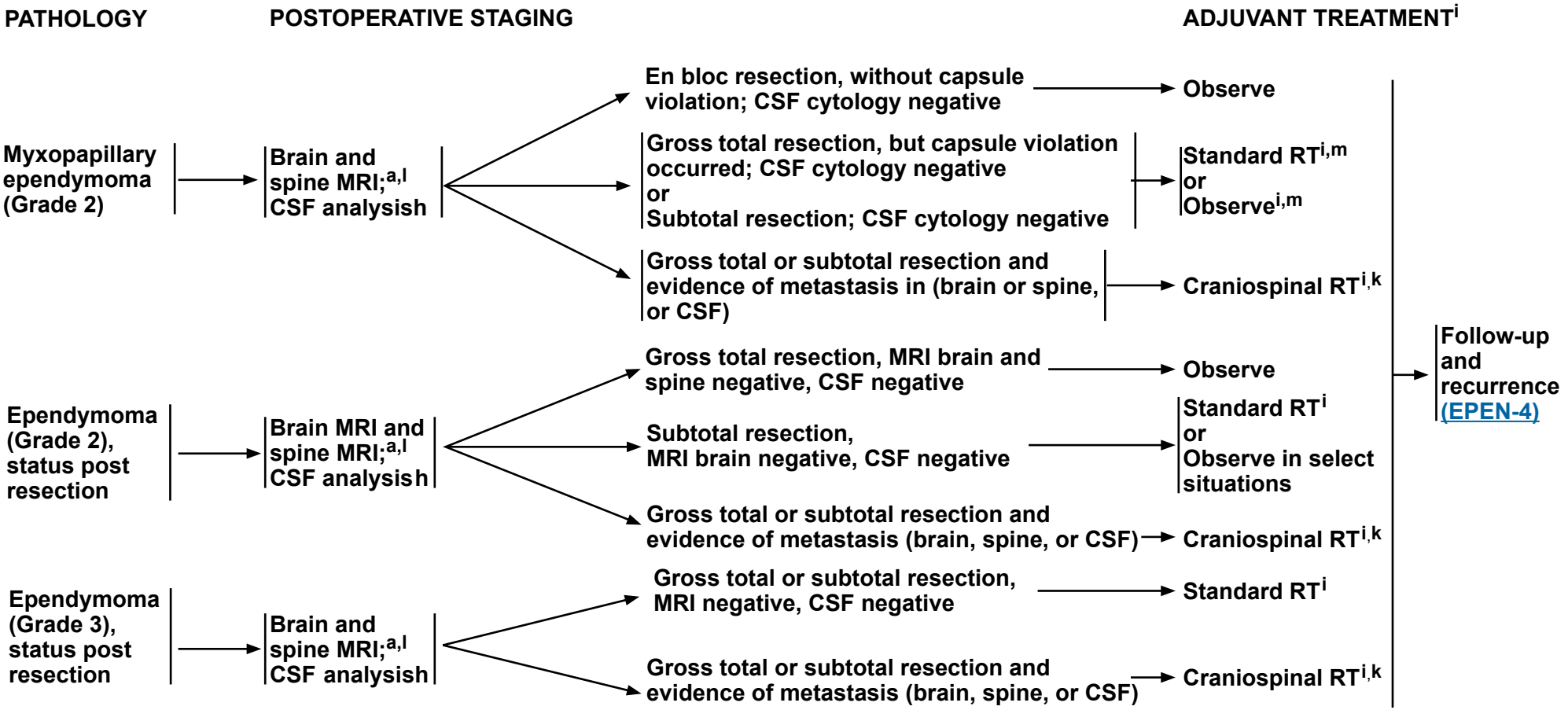

[a] Principles of Brain and Spine Tumor Imaging (BRAIN-A).

[h] Lumbar puncture is indicated when there is clinical concern for meningeal dissemination. Lumbar puncture should be done after MRI of spine is performed to avoid a false-positive imaging result. Lumbar puncture for CSF should be delayed at least 2 weeks after surgery to avoid possible false-positive cytology. Lumbar puncture may be contraindicated (eg, posterior fossa mass). When available, CSF-tDNA testing can be considered with CSF cytology to increase sensitivity of tumor cell detection and assessment of residual disease after surgery.

[i] Principles of Radiation Therapy for Brain and Spinal Cord (BRAIN-C).

[k] Consider proton therapy or IMRT if available to reduce toxicity (Barney CL, et al. Neuro Oncol 2014;16:303-309).

[l] If not done preoperatively, spine MRI should be performed 48 hours post surgery.

[m] RT has been associated with improved disease control (Weber D, et al. Neuro Oncol 2015;17:588-595). Close observation may be clinically appropriate in some cases (Kotecha R, et al. J Neurosurg Spine 2020;1:392-397).

Note: All recommendations are category 2A unless otherwise indicated.

Version 3.2025, 12/05/25 © 2025 National Comprehensive Cancer Network® (NCCN®), All rights reserved. NCCN Guidelines® and this illustration may not be reproduced in any form without the express written permission of NCCN.

PLEASE NOTE that use of this NCCN Content is governed by the End-User License Agreement, and you MAY NOT distribute this Content or use it with any artificial intelligence model or tool.
Printed by: A. S. MUNAZLI | Karbon 2025 | Expires: 12/30/2027 | Copyright © 2025 National Comprehensive Cancer Network, Inc. All Rights Reserved.

NCCN Guidelines Version 3.2025
Adult Intracranial and Spinal Ependymoma (Excluding Subependymoma)

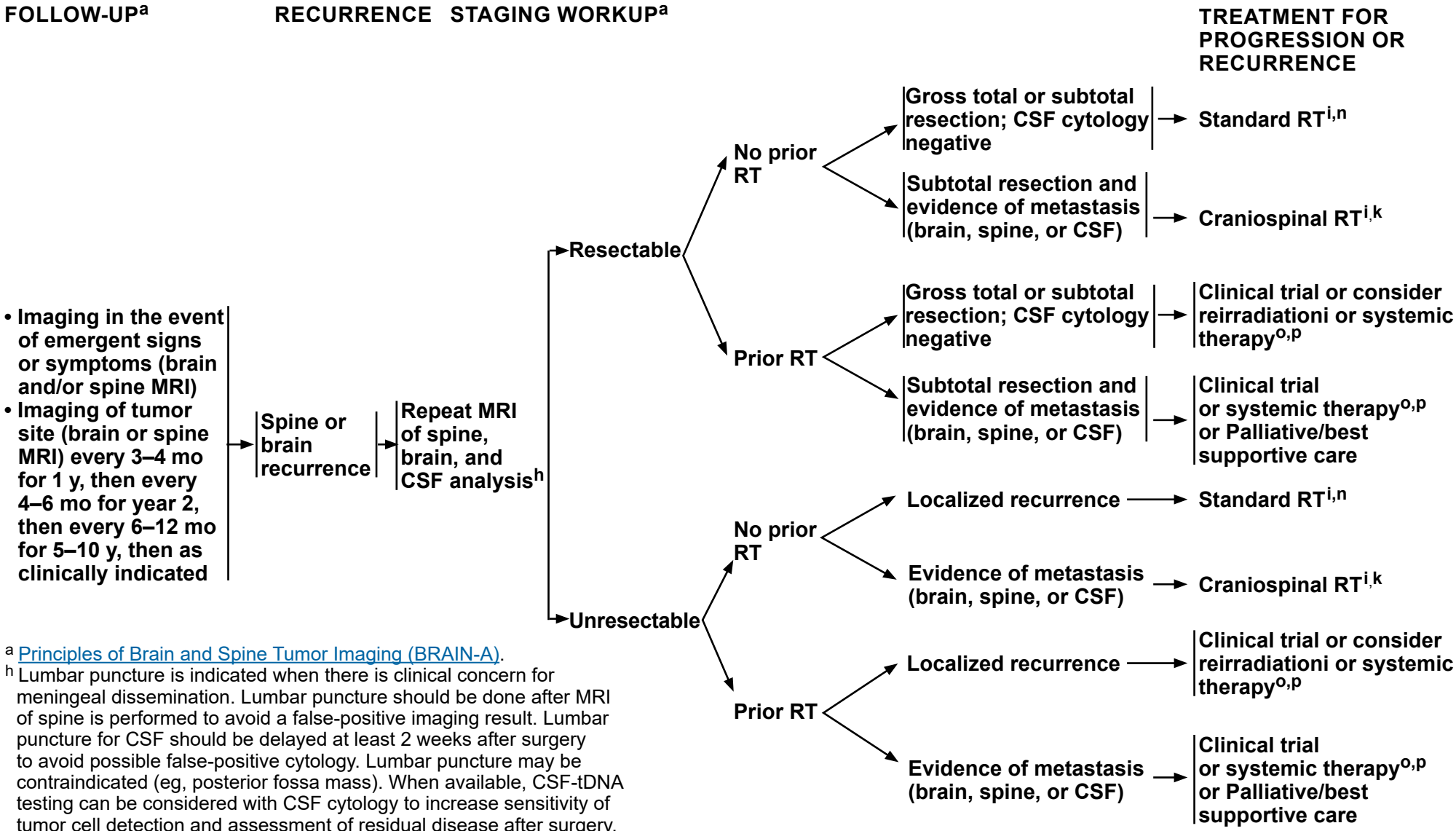

[a] Principles of Brain and Spine Tumor Imaging (BRAIN-A).
[h] Lumbar puncture is indicated when there is clinical concern for meningeal dissemination. Lumbar puncture should be done after MRI of spine is performed to avoid a false-positive imaging result. Lumbar puncture for CSF should be delayed at least 2 weeks after surgery to avoid possible false-positive cytology. Lumbar puncture may be contraindicated (eg, posterior fossa mass). When available, CSF-tDNA testing can be considered with CSF cytology to increase sensitivity of tumor cell detection and assessment of residual disease after surgery.
[i] Principles of Radiation Therapy for Brain and Spinal Cord (BRAIN-C).
[k] Consider proton therapy or IMRT if available to reduce toxicity (Barney CL, et al. Neuro Oncol 2014;16:303-309).
[n] Consider SRS if geometrically favorable.
[o] Systemic therapy should be reserved for patients who are refractory to surgery or radiation.
[p] Adult Intracranial and Spinal Ependymoma Systemic Therapy (EPEN-A).

Note: All recommendations are category 2A unless otherwise indicated.

Version 3.2025, 12/05/25 © 2025 National Comprehensive Cancer Network® (NCCN®), All rights reserved. NCCN Guidelines® and this illustration may not be reproduced in any form without the express written permission of NCCN.

PLEASE NOTE that use of this NCCN Content is governed by the End-User License Agreement, and you MAY NOT distribute this Content or use it with any artificial intelligence model or tool.
Printed by: A. S. MUNAZLI | Karbala Cancer Center | 12/20/2025 | Account No. | Copyright © 2025 National Comprehensive Cancer Network, Inc. All Rights Reserved.

ADULT INTRACRANIAL AND SPINAL EPENDYMOMA (EXCLUDING SUBEPENDYMOMA): SYSTEMIC THERAPY[a]

	Preferred	Other Recommended	Useful in Certain Circumstances
Recurrence Therapy	• None	• Platinum-based regimens:[b] Single agent or combination[1,2] • Etoposide[3,4] • Lomustine or carmustine[1] • Bevacizumab[a,c,5] • Temozolomide[6] • Lapatinib + Temozolomide (category 2B)[7]	• None

FOOTNOTES

[a] An FDA-approved biosimilar is an appropriate substitute for any recommended systemic biologic therapy in the NCCN Guidelines.
[b] Platinum-based regimens include cisplatin or carboplatin.
[c] Patients who have evidence of radiographic progression may benefit from continuation of bevacizumab to prevent rapid neurologic deterioration.

REFERENCES

[1] Gornet MK, Buckner JC, Marks RS, et al. Chemotherapy for advanced CNS ependymoma. J Neurooncol 1999;45:61-67.
[2] Brandes AA, Cavallo G, Reni M, et al. A multicenter retrospective study of chemotherapy for recurrent intracranial ependymal tumors in adults by the Gruppo Italiano Cooperativo di Neuro-Oncologia. Cancer 2005;104:143-148.
[3] Chamberlain MC. Recurrent intracranial ependymoma in children: salvage therapy with oral etoposide. Pediatr Neurol 2001;24:117-121.
[4] Sandri A, Massimino M, Mastrodicasa L, et al. Treatment with oral etoposide for childhood recurrent ependymomas. J Pediatr Hematol Oncol 2005;27:486-490.
[5] Green RM, Cloughesy TF, Stupp R, et al. Bevacizumab for recurrent ependymoma. Neurology 2009;73:1677-1680.
[6] Ruda R, Bosa C, Magistrello M, et al. Temozolomide as salvage treatment for recurrent intracranial ependymomas of the adult: a retrospective study. Neuro Oncol 2016;18:261-268.
[7] Gilbert MR, Yuan Y, Wu J, et al. A phase II study of dose-dense temozolomide and lapatinib for recurrent low-grade and anaplastic supratentorial, infratentorial, and spinal cord ependymoma. Neuro Oncol 2021;23:468-477.

Note: All recommendations are category 2A unless otherwise indicated.

Version 3.2025, 12/05/25 © 2025 National Comprehensive Cancer Network® (NCCN®), All rights reserved. NCCN Guidelines® and this illustration may not be reproduced in any form without the express written permission of NCCN.

PLEASE NOTE that use of this NCCN Content is governed by the End-User License Agreement, and you MAY NOT distribute this Content or use it with any artificial intelligence model or tool.
Printed by A. S. M. FAZLUL KARIM CHOWDHURY on 4/20/2026 3:06:38 AM. Copyright © 2026 National Comprehensive Cancer Network, Inc. All Rights Reserved.

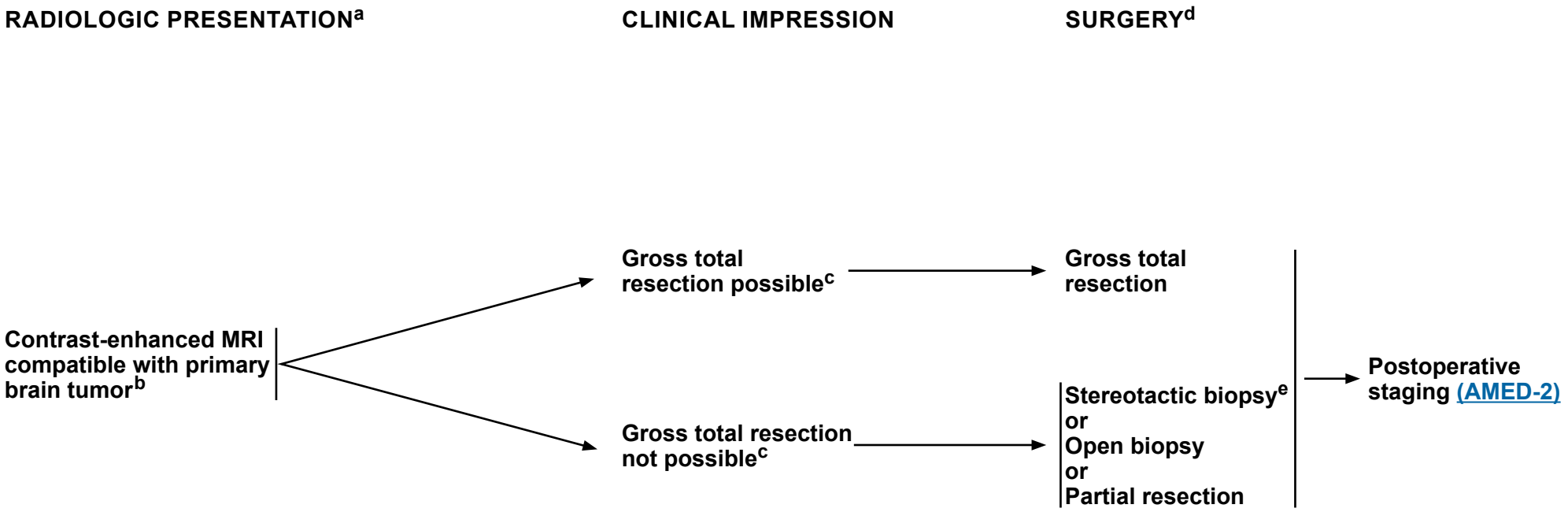

[a] Principles of Brain and Spine Tumor Imaging (BRAIN-A).
[b] Based on multidisciplinary review for treatment planning, once pathology is available. See Principles of Brain and Spine Tumor Management (BRAIN-D).
[c] Placement of ventriculoperitoneal (VP) shunt for management of hydrocephalus is acceptable if needed.
[d] Principles of Surgery (BRAIN-B).
[e] Strongly recommend referring patient to a brain tumor center to be evaluated for possible further, more complete surgical resection.

Note: All recommendations are category 2A unless otherwise indicated.

Version 3.2025, 12/05/25 © 2025 National Comprehensive Cancer Network® (NCCN®), All rights reserved. NCCN Guidelines® and this illustration may not be reproduced in any form without the express written permission of NCCN.

PLEASE NOTE that use of this NCCN Content is governed by the End-User License Agreement, and you MAY NOT distribute this Content or use it with any artificial intelligence model or tool.
Printed by A. S. M. FAZLUL KARIM CHOWDHURY on 4/20/2026 3:06:38 AM. Copyright © 2026 National Comprehensive Cancer Network, Inc. All Rights Reserved.

POSTOPERATIVE STAGING

ADJUVANT TREATMENT[l]

Brain[f] and spine MRI[a,g] and CSF,[h,i] and molecular analysisj

Standard risk for recurrence:[k]
- **No evidence of metastasis (brain, spine, CSF, extraneural)**
- **Small-volume residual disease (contrast volume <1.5 cm²)**
- **Classic or desmoplastic histology**

→ **Consider clinical trial**
or
Standard-dose craniospinal radiation[m,n]
or
Reduced-dose craniospinal RT[m,n] with systemic therapyo followed by post-radiation systemic therapy[o,p]

High risk for recurrence:[k]
Unresectable tumor or residual tumor >1.5 cm²
or
Disseminated disease within or outside of the neuroaxis
or
Large cell medulloblastoma

→ **Craniospinal radiation[m,n] with systemic therapy followed by post-radiation systemic therapy[q]**

→ **Follow-up (AMED-3)**

[a] Principles of Brain and Spine Tumor Imaging (BRAIN-A).
[f] Postoperative brain MRI within 48 hours after surgery.
[g] Spine MRI should be delayed by at least 2–3 weeks post surgery to avoid post-surgical artifacts.
[h] Lumbar puncture should be done after spine MRI. Lumbar puncture for CSF should be delayed at least 2 weeks after surgery to avoid possible false-positive cytology. When available, CSF-tDNA testing can be considered with CSF cytology to increase sensitivity of tumor cell detection and assessment of residual disease after surgery.
[i] Bone scan; CT with contrast of chest, abdomen, and pelvis or whole body PET/CT; and bone marrow biopsy only if clinically indicated.
[j] Molecular profiling to identify clinically relevant subtypes is recommended to encourage opportunities for clinical trial involvement. See Principles of Brain Tumor Pathology (BRAIN-E).
[k] See the modified Chang system for staging medulloblastoma. [Chang CH, et al. Radiology 1969;93:1351-1359 and Cohen ME, Duffner PK (Eds). Brain tumors in children, 2nd ed, McGraw-Hill, New York, 1994, p.187.]
[l] Since adult medulloblastoma is a rare adult central nervous system (CNS) malignancy, patients should be considered for referral to specialized brain tumor centers. We strongly recommend consideration of specialized surgical evaluation given the impact of resection on survival, reproductive endocrine and fertility evaluation, stem cell collection, role of early neuro-rehabilitation, and avoiding delay in adjuvant treatment initiation. Patients with a rare CNS tumor should be considered for registration in national registries of rare tumors. See https://clinicaltrials.gov/ct2/show/NCT02851706.
[m] Principles of Radiation Therapy for Brain and Spinal Cord (BRAIN-C).
[n] Consider proton therapy if available to reduce toxicity.
[o] Omission of vincristine during the radiotherapy phase of therapy or dose modification may be required for adults because they do not tolerate this regimen as well. Data supporting vincristine's use have been found in pediatric trials only. Patients should be closely monitored for neurologic toxicity with periodic exams (Packer RJ, et al. J Clin Oncol 2006;24:4202-4208).
[p] Adult Medulloblastoma Systemic Therapy (AMED-A).
[q] Consider collecting stem cells before craniospinal radiation.

Note: All recommendations are category 2A unless otherwise indicated.

Version 3.2025, 12/05/25 © 2025 National Comprehensive Cancer Network® (NCCN®), All rights reserved. NCCN Guidelines® and this illustration may not be reproduced in any form without the express written permission of NCCN.

PLEASE NOTE that use of this NCCN Content is governed by the End-User License Agreement, and you MAY NOT distribute this Content or use it with any artificial intelligence model or tool.
Printed by A. S. M. FAZLUL KARIM CHOWDHURY on 4/20/2026 3:06:38 AM. Copyright © 2026 National Comprehensive Cancer Network, Inc. All Rights Reserved.

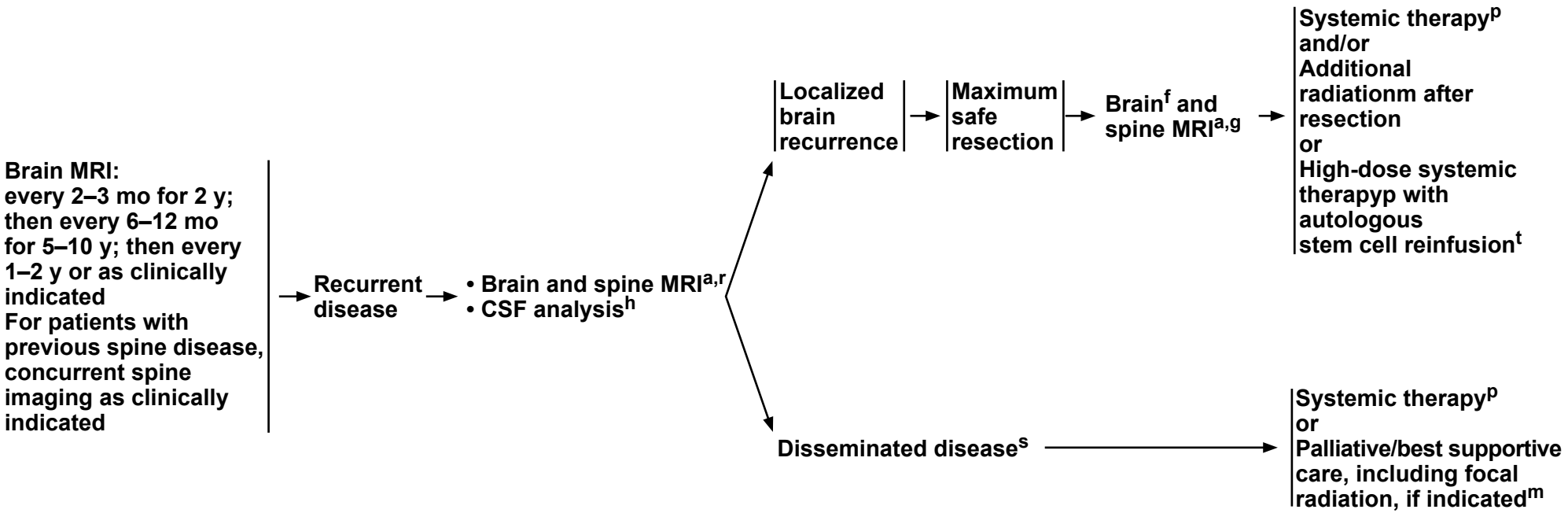

[a] Principles of Brain and Spine Tumor Imaging (BRAIN-A).
[f] Postoperative brain MRI within 48 hours after surgery.
[g] Spine MRI should be delayed by at least 2–3 weeks post surgery to avoid post-surgical artifacts.
[h] Lumbar puncture should be done after spine MRI. Lumbar puncture for CSF should be delayed at least 2 weeks after surgery to avoid possible false-positive cytology. When available, CSF-tDNA testing can be considered with CSF cytology to increase sensitivity of tumor cell detection and assessment of residual disease after surgery.
[m] Principles of Radiation Therapy for Brain and Spinal Cord (BRAIN-C).
[p] Adult Medulloblastoma Systemic Therapy (AMED-A).
[r] As clinically indicated, consider bone scan; contrast-enhanced CT scans of chest, abdomen, and pelvis; and/or bone marrow biopsy.
[s] Consider resection for palliation of symptoms where indicated.
[t] Only if the patient is without evidence of disease after surgery or conventional dose re-induction systemic therapy.

Note: All recommendations are category 2A unless otherwise indicated.

Version 3.2025, 12/05/25 © 2025 National Comprehensive Cancer Network® (NCCN®), All rights reserved. NCCN Guidelines® and this illustration may not be reproduced in any form without the express written permission of NCCN.

PLEASE NOTE that use of this NCCN Content is governed by the End-User License Agreement, and you MAY NOT distribute this Content or use it with any artificial intelligence model or tool.
Printed by A. S. M. FAZLUL KARIM CHOWDHURY on 4/20/2026 3:06:38 AM. Copyright © 2026 National Comprehensive Cancer Network, Inc. All Rights Reserved.

ADULT MEDULLOBLASTOMA: SYSTEMIC THERAPY[a]

	Preferred	Other Recommended	Useful in Certain Circumstances
Regimens Following Weekly Vincristine[b] During Craniospinal RT	• Cisplatin, cyclophosphamide, and vincristine[b,1] • Cisplatin, lomustine, and vincristine[b,1]	• None	• None
Recurrence Therapy	• None	• No prior systemic therapy ▸ High-dose cyclophosphamide ± etoposide[4] ▸ Carboplatin, etoposide, and cyclophosphamide[2,3] ▸ Cisplatin, etoposide, and cyclophosphamide[2] • Prior systemic therapy ▸ High-dose cyclophosphamide ± etoposide[4] ▸ Oral etoposide[5,6] ▸ Temozolomide[7,8] • Temozolomide/irinotecan/bevacizumab[9,10]	• Consider high-dose systemic therapy with autologous stem cell reinfusion[11] in patients who achieve a complete response (CR) with conventional doses of systemic therapy or have no residual disease after re-resection • Vismodegib (for mutations in the sonic hedgehog [SHH] pathway and if prior systemic therapy)[12]

FOOTNOTES

[a] An FDA-approved biosimilar is an appropriate substitute for any recommended systemic biologic therapy in the NCCN Guidelines.
[b] Omission of vincristine during the radiotherapy phase of therapy or dose modification may be required for adults because they do not tolerate this regimen as well. Data supporting vincristine's use have been found in pediatric trials only. Patients should be monitored closely for neurologic toxicity with periodic exams.

REFERENCES

1 Packer RJ, Gajjar A, Vezina G, et al. Phase III study of craniospinal radiation therapy followed by adjuvant chemotherapy for newly diagnosed average-risk medulloblastoma. J Clin Oncol 2006;24:4202-4208.
2 Brandes AA, Ermani M, Amista P, et al. The treatment of adults with medulloblastoma: A prospective study. Int J Radiat Oncol Biol Phys 2003;57:755-761.
3 Franceschi E, Cavallo G, Scopece L, et al. Phase II trial of carboplatin and etoposide for patients with recurrent high-grade glioma. Br J Cancer 2004;91:1038-1044.
4 Gururangan S, Krauser J, Watral MA, et al. Efficacy of high-dose chemotherapy or standard salvage therapy in patients with recurrent medulloblastoma. Neuro Oncol 2008;10:745-751.
5 Ashley DM, Meier L, Kerby T, et al. Response of recurrent medulloblastoma to low-dose oral etoposide. J Clin Oncol 1996;14:1922-1927.
6 Chamberlain MC, Kormanik PA. Chronic oral VP-16 for recurrent medulloblastoma. Pediatr Neurol 1997;17:230-234.
7 Nicholson HS, Kretschmar CS, Krailo M, et al. Phase 2 study of temozolomide in children and adolescents with recurrent central nervous system tumors: a report from the Children's Oncology Group. Cancer 2007;110:1542-1550.
8 Wang CH, Hsu TR, Wong TT, Chang KP. Efficacy of temozolomide for recurrent embryonal brain tumors in children. Childs Nerv Syst 2009;25:535-541.
9 Levy AS, Krailo M, Chi S, et al. Temozolomide with irinotecan versus temozolomide, irinotecan plus bevacizumab for recurrent medulloblastoma of childhood: Report of a COG randomized Phase II screening trial. Pediatr Blood Cancer 2021;68:e29031.
10 Yamauchi T, Kitai R, Arai H, et al. Bevacizumab, irinotecan, and temozolomide with re-irradiation in adult recurrent medulloblastoma: A first case report. Interdisciplinary Neurosurgery: Advanced Techniques and Case Management 2021;25:101249.
11 Dunkel IJ, Gardner SL, Garvin JH Jr, et al. High-dose carboplatin, thiotepa, and etoposide with autologous stem cell rescue for patients with previously irradiated recurrent medulloblastoma. Neuro Oncol 2010;12:297-303.
12 Robinson GW, Orr BA, Wu G, et al. Vismodegib exerts targeted efficacy against recurrent sonic hedgehog-subgroup medulloblastoma: results from phase II Pediatric Brain Tumor Consortium Studies PBTC-025B and PBTC-032. J Clin Oncol 2015;33:2646-2654.

Note: All recommendations are category 2A unless otherwise indicated.

Version 3.2025, 12/05/25 © 2025 National Comprehensive Cancer Network® (NCCN®), All rights reserved. NCCN Guidelines® and this illustration may not be reproduced in any form without the express written permission of NCCN.

PLEASE NOTE that use of this NCCN Content is governed by the End-User License Agreement, and you MAY NOT distribute this Content or use it with any artificial intelligence model or tool.
Printed by A. S. M. FAZLUL KARIM CHOWDHURY on 4/20/2026 3:06:38 AM. Copyright © 2026 National Comprehensive Cancer Network, Inc. All Rights Reserved.

DIAGNOSIS BY TISSUE EVALUATION[a]

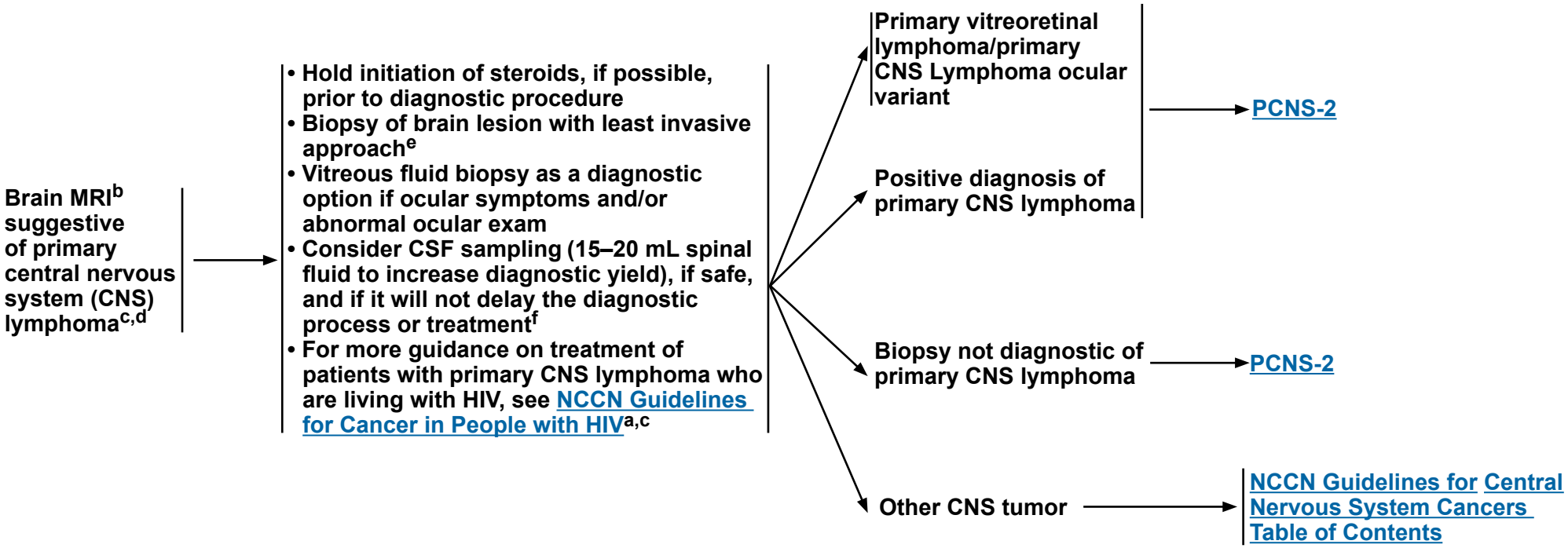

[a] For additional guidance on disease management of transplant recipients with primary CNS lymphoma, see NCCN Guidelines for B-Cell Lymphomas, Diffuse Large B-Cell Lymphoma.
[b] Principles of Brain and Spine Tumor Imaging (BRAIN-A).
[c] If patient is HIV positive, antiretroviral (ARV) therapy should be part of their treatment. ARVs can be administered safely with systemic therapy, but consultation with an HIV specialist or pharmacist is important to optimize compatibility. See NCCN Guidelines for Cancer in People with HIV.
[d] Includes primary CNS lymphoma of the brain, spine, CSF, and leptomeninges. For lymphoma with primary tumor outside the CNS or involving only the eye, see NCCN Guidelines for B-Cell Lymphomas, Diffuse Large B-Cell Lymphoma.
[e] If stereotactic biopsy is not available refer to a specialized center.
[f] CSF analysis should include flow cytometry, CSF cytology, cell count, and possibly gene rearrangements, specifically the *IGH* heavy chain rearrangement, and CSF-tDNA. Polymerase chain reaction (PCR) of *MYD88* in the CSF is helpful.

Note: All recommendations are category 2A unless otherwise indicated.

Version 3.2025, 12/05/25 © 2025 National Comprehensive Cancer Network® (NCCN®), All rights reserved. NCCN Guidelines® and this illustration may not be reproduced in any form without the express written permission of NCCN.

PLEASE NOTE that use of this NCCN Content is governed by the End-User License Agreement, and you MAY NOT distribute this Content or use it with any artificial intelligence model or tool.
Printed by A. S. M. FAZLUL KARIM CHOWDHURY on 4/20/2026 3:06:38 AM. Copyright © 2026 National Comprehensive Cancer Network, Inc. All Rights Reserved.

EXTENT OF DISEASE | **EVALUATION[i]** | **INDUCTION THERAPY[c,n]**

Positive diagnosis of primary CNS lymphoma[g,h] →

- Full ophthalmologic exam including slit lamp eye exam
- Lumbar puncture if safe[j,k,l]
- Spine MRI,[b] if clinically indicated
- Lactate dehydrogenase (LDH) test
- HIV status[c]
- Complete blood count (CBC), comprehensive metabolic panel
- Whole body PET/CT scan or contrast-enhanced chest/abdomen/pelvis CT
- Bone marrow biopsy if clinical suspicion of bone marrow involvement (category 2B)
- Consider testicular ultrasound for patients >60 y[m] (category 2B)
- Initiate steroids as clinically indicated

→ **Consider clinical trial**
or
High-dose methotrexate-based regimen[o,p,q] or other systemic therapy regimen if patient is unsuitable for or intolerant to high-dose methotrexate
- If eye exam shows vitreoretinal involvement and disease is not responding to systemic therapy, consider ocular RT[r] or refer to an experienced provider or ophthalmologist experienced in intraocular therapy[q] (category 2B)

or

Whole brain RT (WBRT)[r] if patient is not a candidate for systemic therapy
- If eye exam shows vitreoretinal involvement, refer to an experienced provider or ophthalmologist for intraocular therapy[q] or consider ocular RT
- If CSF positive or spinal MRI positive, consider intra-CSF systemic therapy[q] + focal spinal RT

→ PCNS-3

Biopsy not diagnostic of primary CNS lymphoma

- **Prior steroids** → **Discontinue steroids, and rebiopsy or repeat CSF evaluation when disease progresses**
- **No prior steroids** → **Workup for other CNS diagnosis or rebiopsy or repeat CSF evaluation**

Primary vitreoretinal lymphoma/PCNSL ocular variant (without other CNS involvement) → **Evaluation criteria is same as positive diagnosis of primary CNS lymphoma (see above)** →

Consider clinical trial
or
Multidisciplinary discussion with ophthalmologist, hematologist/oncologist/neuro-oncologist, and radiation oncologist for consideration of:
- Intraocular therapy[q] by experienced provider or ophthalmologist followed by consideration of close observation with deferred systemic therapy
- Ocular RT by experienced provider followed by consideration of close observation with deferred systemic therapy
- Systemic therapy[q]

→ PCNS-3

Note: All recommendations are category 2A unless otherwise indicated.

Footnotes on PCNS-2A
Consolidation Therapy(PCNS-3)

Version 3.2025, 12/05/25 © 2025 National Comprehensive Cancer Network® (NCCN®), All rights reserved. NCCN Guidelines® and this illustration may not be reproduced in any form without the express written permission of NCCN.

PLEASE NOTE that use of this NCCN Content is governed by the End-User License Agreement, and you MAY NOT distribute this Content or use it with any artificial intelligence model or tool.
Printed by A. S. M. FAZLUL KARIM CHOWDHURY on 4/20/2026 3:06:38 AM. Copyright © 2026 National Comprehensive Cancer Network, Inc. All Rights Reserved.

FOOTNOTES

[b] Principles of Brain and Spine Tumor Imaging (BRAIN-A).
[c] If patient is HIV positive, ARV therapy should be part of their treatment. ARVs can be administered safely with systemic therapy but consultation with an HIV specialist or pharmacist is important to optimize compatibility. See NCCN Guidelines for Cancer in People with HIV.
[g] May institute primary therapy and workup simultaneously.
[h] Includes primary CNS lymphoma of the brain, spine, CSF, and leptomeninges.
[i] CRu refers to no enhancement, any steroids, normal eye examination and negative CSF, or minimal contrast abnormality, any steroids, minor retinal pigment epithelium, and negative CSF.
[j] CSF analysis should include flow cytometry, CSF cytology, cell count, and possibly gene rearrangements, specifically the IGH heavy chain rearrangement, and CSF-tDNA. PCR of MYD88 in the CSF is helpful.
[k] CSF analysis should include flow cytometry, CSF cytology, and cell count, and may consider gene rearrangements and CSF-tDNA.
[l] Caution is indicated in patients who are anticoagulated, thrombocytopenic, or who have a bulky intracranial mass.
[m] Recommend regular testicular exams. If PET/CT scan is negative, then there is no need for testicular ultrasound.
[n] A low KPS should not be a reason to withhold systemic therapy. KPS may improve dramatically after treatment.
[o] If CSF positive or spinal MRI positive, consider alternative systemic therapy regimens and/or intra-CSF systemic therapy (category 2B), especially for patients who cannot tolerate systemic methotrexate ≥3.5 g/m^2.
[p] Dose adjusted for glomerular filtration rate (GFR) if dosing at 8 g/m^2.
[q] Primary CNS Lymphoma Systemic Therapy (PCNS-A).
[r] Principles of Radiation Therapy for Brain and Spinal Cord (BRAIN-C).

Note: All recommendations are category 2A unless otherwise indicated.

Version 3.2025, 12/05/25 © 2025 National Comprehensive Cancer Network® (NCCN®), All rights reserved. NCCN Guidelines® and this illustration may not be reproduced in any form without the express written permission of NCCN.

PLEASE NOTE that use of this NCCN Content is governed by the End-User License Agreement, and you MAY NOT distribute this Content or use it with any artificial intelligence model or tool.
Printed by A. S. M. FAZLUL KARIM CHOWDHURY on 4/20/2026 3:06:38 AM. Copyright © 2026 National Comprehensive Cancer Network, Inc. All Rights Reserved.

CONSOLIDATION THERAPY[c,t]

If CR or CR, unconfirmed (CRu)[i] consider:
High-dose systemic therapy with stem cell rescue[q]
or
High-dose cytarabine ± etoposide[q]
or
Low-dose WBRT[r,s]
or
Temozolomide (after WBRT)
or
Continue monthly high-dose methotrexate/rituximab-based regimen for up to 1 y
If residual disease, consider:
High-dose cytarabine ± etoposide[q]
or
Temozolomide (after WBRT)
or
WBRT[r]
or
Best supportive care

→ **Follow-up (PCNS-4)**

[c] If patient is HIV positive, ARV therapy should be part of their treatment. ARVs can be administered safely with systemic therapy but consultation with an HIV specialist or pharmacist is important to optimize compatibility. See NCCN Guidelines for Cancer in People with HIV.
[i] CRu refers to no enhancement, any steroids, normal eye examination and negative CSF, or minimal contrast abnormality, any steroids, minor retinal pigment epithelium, and negative CSF.
[q] Primary CNS Lymphoma Systemic Therapy (PCNS-A).
[r] Principles of Radiation Therapy for Brain and Spinal Cord (BRAIN-C).
[s] WBRT may increase neurotoxicity, especially in patients >60 years.
[t] Due to a lack of strong evidence, it is not clear if consolidation is needed and which consolidation regimen provides the most benefit.

Note: All recommendations are category 2A unless otherwise indicated.

Version 3.2025, 12/05/25 © 2025 National Comprehensive Cancer Network® (NCCN®), All rights reserved. NCCN Guidelines® and this illustration may not be reproduced in any form without the express written permission of NCCN.

PLEASE NOTE that use of this NCCN Content is governed by the End-User License Agreement, and you MAY NOT distribute this Content or use it with any artificial intelligence model or tool.
Printed by A. S. M. FAZLUL KARIM CHOWDHURY on 4/20/2026 3:06:38 AM. Copyright © 2026 National Comprehensive Cancer Network, Inc. All Rights Reserved.

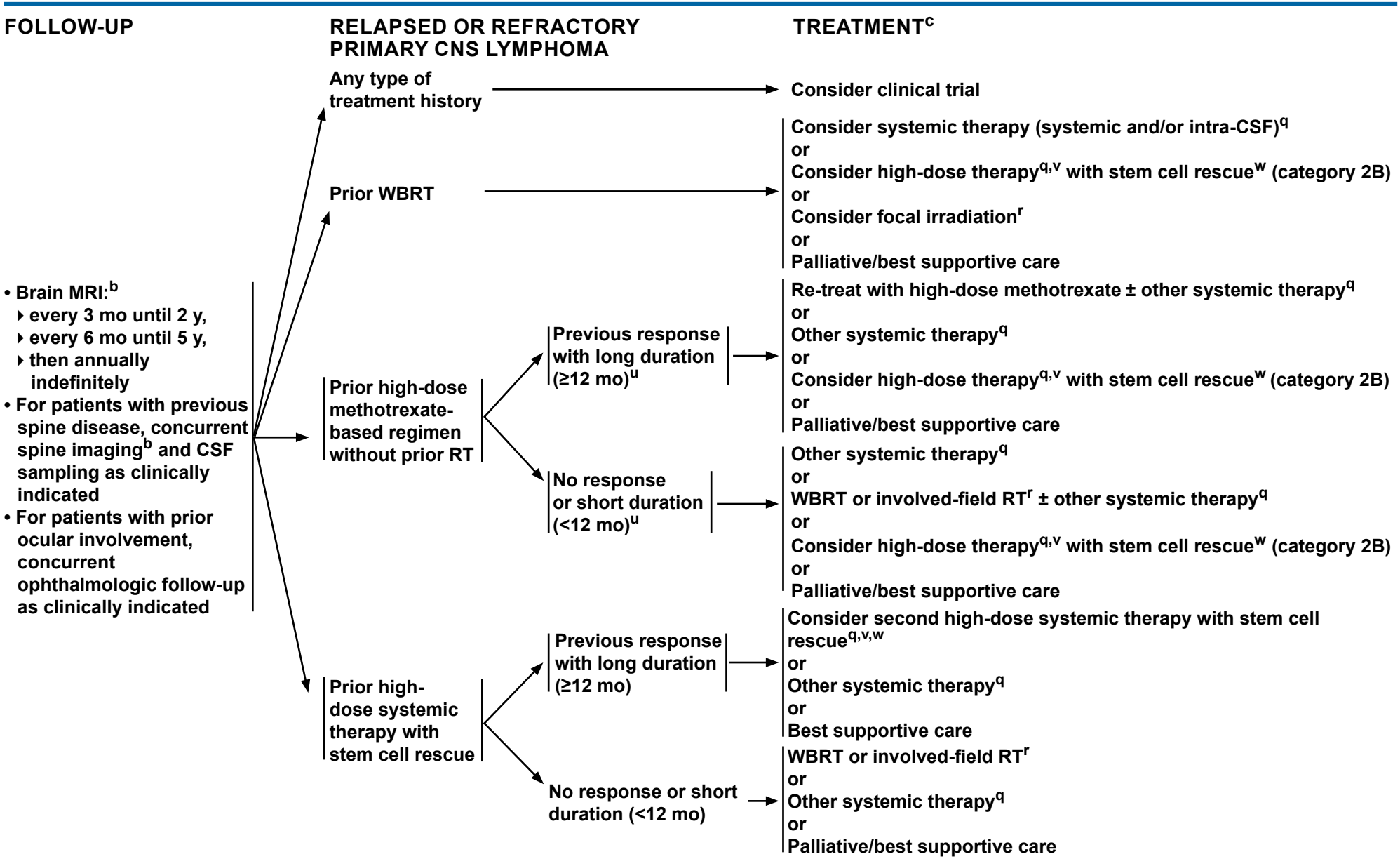

Footnotes on PCNS-4A

Note: All recommendations are category 2A unless otherwise indicated.

Version 3.2025, 12/05/25 © 2025 National Comprehensive Cancer Network® (NCCN®), All rights reserved. NCCN Guidelines® and this illustration may not be reproduced in any form without the express written permission of NCCN.

PLEASE NOTE that use of this NCCN Content is governed by the End-User License Agreement, and you MAY NOT distribute this Content or use it with any artificial intelligence model or tool.
Printed by A. S. M. FAZLUL KARIM CHOWDHURY on 4/20/2026 3:06:38 AM. Copyright © 2026 National Comprehensive Cancer Network, Inc. All Rights Reserved.

FOOTNOTES

[b] Principles of Brain and Spine Tumor Imaging (BRAIN-A).
[c] If patient is HIV positive, ARV therapy should be part of their treatment. ARVs can be administered safely with systemic therapy but consultation with an HIV specialist or pharmacist is important to optimize compatibility. See NCCN Guidelines for Cancer in People with HIV.
[q] Primary CNS Lymphoma Systemic Therapy (PCNS-A).
[r] Principles of Radiation Therapy for Brain and Spinal Cord (BRAIN-C).
[u] This is a consensus opinion. There are no specific data to define length of time before development of recurrence that would indicate if retreatment with methotrexate should be attempted.
[v] The risk of neurotoxicity should be considered before administrating high-dose therapy to a patient with prior WBRT.
[w] If the recurrent disease goes into complete remission with reinduction systemic therapy.

Note: All recommendations are category 2A unless otherwise indicated.

Version 3.2025, 12/05/25 © 2025 National Comprehensive Cancer Network® (NCCN®), All rights reserved. NCCN Guidelines® and this illustration may not be reproduced in any form without the express written permission of NCCN.

PLEASE NOTE that use of this NCCN Content is governed by the End-User License Agreement, and you MAY NOT distribute this Content or use it with any artificial intelligence model or tool.
Printed by A. S. M. FAZLUL KARIM CHOWDHURY on 4/20/2026 3:06:38 AM. Copyright © 2026 National Comprehensive Cancer Network, Inc. All Rights Reserved.

PRIMARY CNS LYMPHOMA: SYSTEMIC THERAPY[a]

	Preferred	Other Recommended	Useful in Certain Circumstances
Induction Therapy	• Systemic therapy ▸ High-dose methotrexate 8 g/m^2 combined with the following:[b,1] ◊ Rituximab[c,2-5] ◊ Rituximab and Temozolomide[c,6] ▸ High-dose methotrexate 3.5 g/m^2 combined with the following, and consider WBRT:[b,d] ◊ Vincristine, procarbazine, and rituximab (R-MPV)[c,7-10] ◊ Temozolomide + rituximab[c,11]	• High-dose methotrexate/cytarabine/thiotepa/rituximab[c,e,f,15]	• Intra-CSF therapy ▸ If CSF positive or spinal MRI positive ◊ Methotrexate ◊ Cytarabine[30] ◊ Rituximab[c,31] • Intraocular therapy[32] ▸ Methotrexate • Patient is unsuitable for or intolerant to high-dose methotrexate ▸ See Other Recommended for Relapsed or Refractory Disease
Consolidation Therapy	• High-dose systemic therapy with stem cell rescue ▸ Cytarabine + thiotepa followed by carmustine + thiotepa[12,13] ▸ Thiotepa, busulfan, and cyclophosphamide[14] • High-dose cytarabine + etoposide[6] • High-dose cytarabine[7-9]	• None	• Monthly maintenance: ▸ High-dose methotrexate (3.5 g/m^2 to 8 g/m^2) ± rituximab[4] ▸ Rituximab • Temozolomide (after WBRT)[11]
Relapsed or Refractory Disease	• None	• Retreat with high-dose methotrexate[b,g,1] ▸ With or without rituximab[c] ▸ With rituximab[c] and ibrutinib[h,16] • Ibrutinib[h,16,17] • Temozolomide[18] • Rituximab ± Temozolomide[19-22] • Lenalidomide ± rituximab[c,23] • High-dose cytarabine[24] • Pemetrexed[25,26] • Pomalidomide[27] • Rituximab, methotrexate, carmustine, etoposide and prednisone (R-MBVP)[28,29]	• Consider high-dose systemic therapy with autologous stem cell reinfusion in eligible patients[12,33,34] ▸ Zanubrutinib ± high-dose cytarabine (only at first recurrence; consider age and PS) ▸ High-dose methotrexate followed by cytarabine + thiotepa followed by carmustine + thiotepa[14] ▸ High-dose cytarabine + etoposide, followed by thiotepa + busulfan + cyclophosphamide[33] ▸ High-dose cytarabine + rituximab + thiotepa followed by thiotepa + rituximab + carmustine[34] • For intra-CSF therapy, see Induction Therapy above

Footnotes on PCNS-A 2 of 3

Note: All recommendations are category 2A unless otherwise indicated.

Version 3.2025, 12/05/25 © 2025 National Comprehensive Cancer Network® (NCCN®), All rights reserved. NCCN Guidelines® and this illustration may not be reproduced in any form without the express written permission of NCCN.

PLEASE NOTE that use of this NCCN Content is governed by the End-User License Agreement, and you MAY NOT distribute this Content or use it with any artificial intelligence model or tool.
Printed by A. S. M. FAZLUL KARIM CHOWDHURY on 4/20/2026 3:06:38 AM. Copyright © 2026 National Comprehensive Cancer Network, Inc. All Rights Reserved.

PRIMARY CNS LYMPHOMA: SYSTEMIC THERAPY

FOOTNOTES

[a] An FDA-approved biosimilar is an appropriate substitute for any recommended systemic biologic therapy in the NCCN Guidelines.
[b] Consider glucarpidase (carboxypeptidase G2) for prolonged methotrexate clearance due to methotrexate-induced renal toxicity. Ramsey LB, Balis FM, O'Brien MM, et al. Consensus guideline for use of glucarpidase in patients with high-dose methotrexate induced acute kidney injury and delayed methotrexate clearance. Oncologist 2018;23:52-61.
[c] Hepatitis B testing is indicated because of the risk of reactivation with immunotherapy + systemic therapy. Tests include hepatitis B surface antigen and core antibody for a patient with no risk factors. For patients with risk factors or previous history of hepatitis B, add e-antigen. If positive, check viral load and consult with gastroenterologist. The NCCN Guidelines for B-Cell Lymphomas (NHODG-B, 2 of 5) also have information about hepatitis B virus (HBV) testing for patients considering rituximab.
[d] Other combinations with methotrexate may be used.
[e] There are concerns about WBRT being used in the trials that evaluated these regimens, especially for patients >65 years of age.
[f] This regimen is associated with significant myeloid toxicity.
[g] This is a consensus opinion. There are no specific data to define length of time before development of recurrence that would indicate if retreatment with methotrexate should be attempted.
[h] Ibrutinib is associated with risk of *Aspergillus* infection.

REFERENCES

[1] Batchelor T, Carson K, O'Neill A, et al. Treatment of primary CNS lymphoma with methotrexate and deferred radiotherapy: a report of NABTT 96-07. J Clin Oncol 2003;21:1044-1049.
[2] Chamberlain MC, Johnston SK. High-dose methotrexate and rituximab with deferred radiotherapy for newly diagnosed primary B-cell CNS lymphoma. Neuro Oncol 2010;12:736-744.
[3] Gregory G, Arumugaswamy A, Leung T, et al. Rituximab is associated with improved survival for aggressive B cell CNS lymphoma. Neuro Oncol 2013;15:1068-1073.
[4] Holdhoff M, Ambady P, Abdelaziz A, et al. High-dose methotrexate with or without rituximab in newly diagnosed primary CNS lymphoma. Neurology 2014;83:235-239.
[5] Ly KI, Crew LL, Graham CA, Mrugala MM. Primary central nervous system lymphoma treated with high-dose methotrexate and rituximab: A single-institution experience. Oncol Lett 2016;11:3471-3476.
[6] Rubenstein JL, Hsi ED, Johnson JL, et al. Intensive chemotherapy and immunotherapy in patients with newly diagnosed primary CNS lymphoma: CALGB 50202 (Alliance 50202). J Clin Oncol 2013;31:3061-3068.
[7] DeAngelis LM, Seiferheld W, Schold SC, et al. Combination chemotherapy and radiotherapy for primary central nervous system lymphoma: Radiation Therapy Oncology Group Study 93-10. J Clin Oncol 2002;20:4643-4648.
[8] Shah GD, Yahalom J, Correa DD, et al. Combined immunochemotherapy with reduced whole-brain radiotherapy for newly diagnosed primary CNS lymphoma. J Clin Oncol 2007;25:4730-4735.
[9] Gavrilovic IT, Hormigo A, Yahalom J, et al. Long-term follow-up of high-dose methotrexate-based therapy with and without whole brain irradiation for newly diagnosed primary CNS lymphoma. J Clin Oncol 2006;24:4570-4574.
[10] Omuro A, Correa DD, DeAngelis LM, et al. R-MPV followed by high-dose chemotherapy with TBC and autologous stem-cell transplant for newly diagnosed primary CNS lymphoma. Blood 2015;125:1403-1410.
[11] Glass J, Won M, Schultz CJ, et al. Phase I and II study of induction chemotherapy with methotrexate, rituximab, and temozolomide, followed by whole-brain radiotherapy and postirradiation temozolomide for primary CNS lymphoma: NRG Oncology RTOG 0227. J Clin Oncol 2016;34:1620-1625.

Note: All recommendations are category 2A unless otherwise indicated.

Version 3.2025, 12/05/25 © 2025 National Comprehensive Cancer Network® (NCCN®), All rights reserved. NCCN Guidelines® and this illustration may not be reproduced in any form without the express written permission of NCCN.

PLEASE NOTE that use of this NCCN Content is governed by the End-User License Agreement, and you MAY NOT distribute this Content or use it with any artificial intelligence model or tool.
Printed by A. S. M. FAZLUL KARIM CHOWDHURY on 4/20/2026 3:06:38 AM. Copyright © 2026 National Comprehensive Cancer Network, Inc. All Rights Reserved.

PRIMARY CNS LYMPHOMA: SYSTEMIC THERAPY

REFERENCES (CONTINUED)

[12] Illerhaus G, Muller F, Feuerhake F, et al. High-dose chemotherapy and autologous stem-cell transplantation without consolidating radiotherapy as first-line treatment for primary lymphoma of the central nervous system. Haematologica 2008;93:147-148.
[13] Kasenda B, Schorb E, Fritsch K, et al. Prognosis after high-dose chemotherapy followed by autologous stem-cell transplantation as first-line treatment in primary CNS lymphoma--a long-term follow-up study. Ann Oncol 2012;23:2670-2675.
[14] DeFilipp Z, Li S, El-Jawahri A, et al. High-dose chemotherapy with thiotepa, busulfan, and cyclophosphamide and autologous stem cell transplantation for patients with primary central nervous system lymphoma in first complete remission. Cancer 2017;123:3073-3079.
[15] Ferreri AJM, Cwynarski K, Pulczynski E, et al. Chemoimmunotherapy with methotrexate, cytarabine, thiotepa, and rituximab (MATRix regimen) in patients with primary CNS lymphoma: results of the first randomisation of the International Extranodal Lymphoma Study Group-32 (IELSG32) phase 2 trial Lancet Haematol 2016;3:e217-e227.
[16] Grommes C, Tang SS, Wolfe J, et al. Phase 1b trial of an ibrutinib-based combination therapy in recurrent/refractory CNS lymphoma. Blood 2019;133:436-445.
[17] Grommes C, Pastore A, Palaskas N, et al. Ibrutinib unmasks critical role of bruton tyrosine kinase in primary CNS lymphoma. Cancer Discov 2017;7:1018-1029.
[18] Makino K, Nakamura H, Hide T, Kuratsu J. Salvage treatment with temozolomide in refractory or relapsed primary central nervous system lymphoma and assessment of the MGMT status. J Neurooncol 2012;106:155-160.
[19] Enting RH, Demopoulos A, DeAngelis LM, Abrey LE. Salvage therapy for primary CNS lymphoma with a combination of rituximab and temozolomide. Neurology 2004;63:901-903.
[20] Batchelor TT, Grossman SA, Mikkelsen T, et al. Rituximab monotherapy for patients with recurrent primary CNS lymphoma. Neurology 2011;76:929-930.
[21] Nayak L, Abrey LE, Drappatz J, et al. Multicenter phase II study of rituximab and temozolomide in recurrent primary central nervous system lymphoma. Leuk Lymphoma 2013;54:58-61.
[22] Rubenstein JL, Fridlyand J, Abrey L, et al. Phase I study of intraventricular administration of rituximab in patients with recurrent CNS and intraocular lymphoma. J Clin Oncol 2007;25:1350-1356.
[23] Rubenstein JL, Geng H, Fraser EJ, et al. Phase 1 investigation of lenalidomide/rituximab plus outcomes of lenalidomide maintenance in relapsed CNS lymphoma. Blood Adv 2018;2:1595-1607.
[24] DeAngelis LM, Kreis W, Chan K, et al. Pharmacokinetics of ara-C and ara-U in plasma and CSF after high-dose administration of cytosine arabinoside. Cancer Chemother Pharmacol 1992;29:173-177.
[25] Raizer JJ, Rademaker A, Evens AM, et al. Pemetrexed in the treatment of relapsed/refractory primary central nervous system lymphoma. Cancer 2012;118:3743-3748.
[26] Dietrich J, Versmee L, Drappatz J, et al. Pemetrexed in recurrent or progressive central nervous system lymphoma: A phase I multicenter clinical trial. Oncologist 2020;25:747-e1273.
[27] Tun HW, Johnston PB, DeAngelis LM, et al. Phase 1 study of pomalidomide and dexamethasone for relapsed/refractory primary CNS or vitreoretinal lymphoma. Blood 2018;132:2240-2248.
[28] Reiss SN, Yerram P, Modelevsky L, Grommes C. Rituximab, methotrexate, carmustine, etoposide, and prednisone (RMBVP) for the treatment of relapsed/refractory primary central nervous system lymphoma: a retrospective single-center study. Leuk Lymphoma 2022;63:627-632.
[29] Bromberg JEC, Issa S, Bakunina K, et al. Rituximab in patients with primary CNS lymphoma (HOVON 105/ALLG NHL 24): a randomised, open-label, phase 3 intergroup study. Lancet Oncol 2019;20:216-228.
[30] Glantz MJ, LaFollette S, Jaeckle KA, et al. Randomized trial of a slow-release versus a standard formulation of cytarabine for the intrathecal treatment of lymphomatous meningitis. J Clin Oncol 1999;17:3110-3116.
[31] Schulz H, Pels H, Schmidt-Wolf I, et al. Intraventricular treatment of relapsed central nervous system lymphoma with the anti-CD20 antibody rituximab. Haematologica 2004;89:753-754.
[32] Pulido JS, Johnston PB, Nowakowski GS, et al. The diagnosis and treatment of primary vitreoretinal lymphoma: a review. Int J Retin Vitr 2018;4:18.
[33] Soussain C, Hoang-Xuan K, Taillandier L, et al. Intensive chemotherapy followed by hematopoietic stem-cell rescue for refractory and recurrent primary CNS and intraocular lymphoma: Societe Francaise de Greffe de Moelle Osseuse-Therapie Cellulaire. J Clin Oncol 2008;26:2512-2518.
[34] Kasenda B, Ihorst G, Schroers R, et al. High-dose chemotherapy with autologous haematopoietic stem cell support for relapsed or refractory primary CNS lymphoma: a prospective multicentre trial by the German Cooperative PCNSL study group. Leukemia 2017;31:2623-2629.

Note: All recommendations are category 2A unless otherwise indicated.

Version 3.2025, 12/05/25 © 2025 National Comprehensive Cancer Network® (NCCN®), All rights reserved. NCCN Guidelines® and this illustration may not be reproduced in any form without the express written permission of NCCN.

PLEASE NOTE that use of this NCCN Content is governed by the End-User License Agreement, and you MAY NOT distribute this Content or use it with any artificial intelligence model or tool.
Printed by A. S. M. FAZLUL KARIM CHOWDHURY on 4/20/2026 3:06:38 AM. Copyright © 2026 National Comprehensive Cancer Network, Inc. All Rights Reserved.

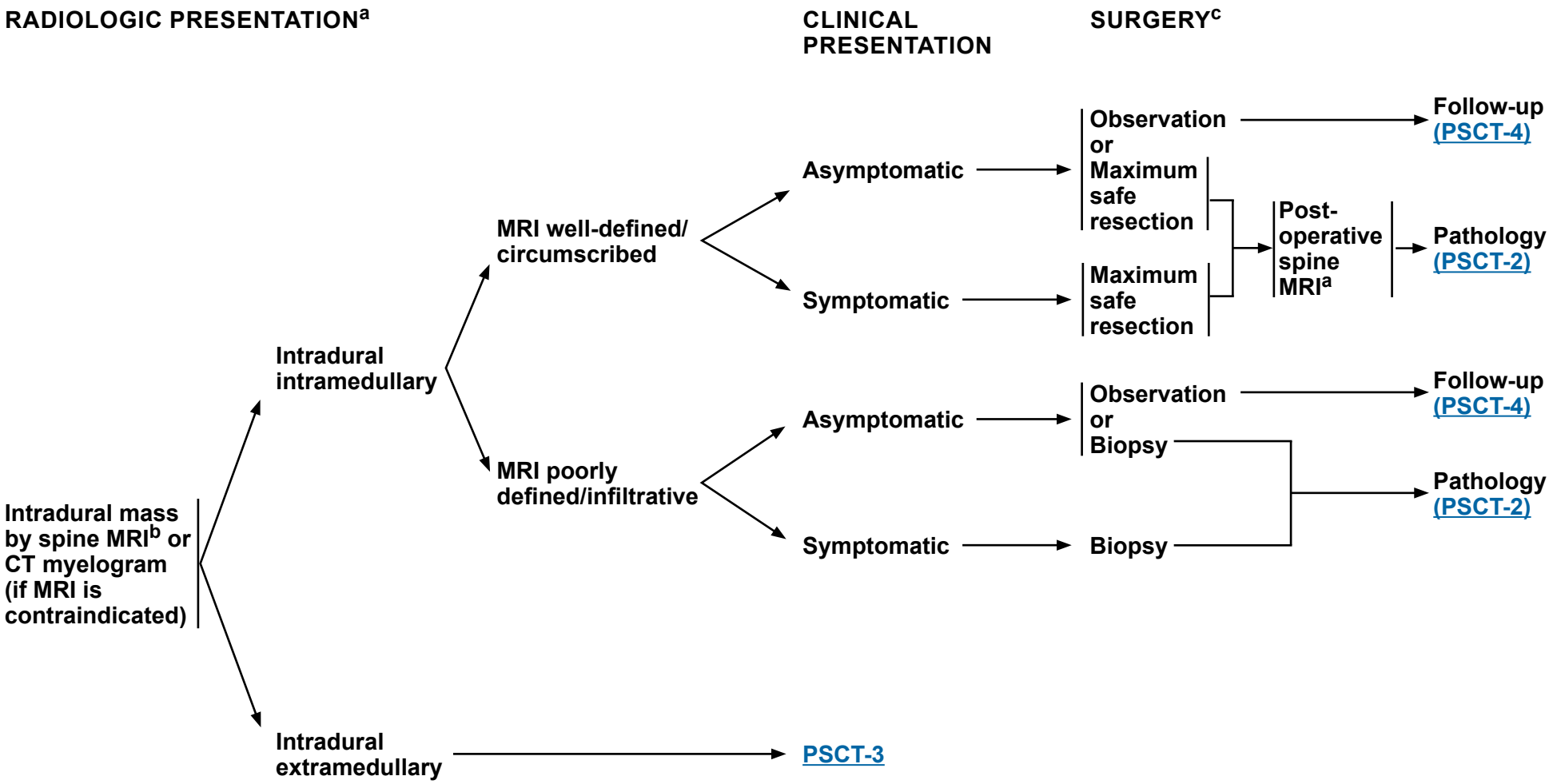

[a] Principles of Brain and Spine Tumor Imaging (BRAIN-A).
[b] Based on multidisciplinary review for treatment planning, once pathology is available. See Brain and Spine Tumor Management (BRAIN-D).
[c] Principles of Surgery (BRAIN-B).

Note: All recommendations are category 2A unless otherwise indicated.

Version 3.2025, 12/05/25 © 2025 National Comprehensive Cancer Network® (NCCN®), All rights reserved. NCCN Guidelines® and this illustration may not be reproduced in any form without the express written permission of NCCN.

PLEASE NOTE that use of this NCCN Content is governed by the End-User License Agreement, and you MAY NOT distribute this Content or use it with any artificial intelligence model or tool.
Printed by A. S. M. FAZLUL KARIM CHOWDHURY on 4/20/2026 3:06:38 AM. Copyright © 2026 National Comprehensive Cancer Network, Inc. All Rights Reserved.

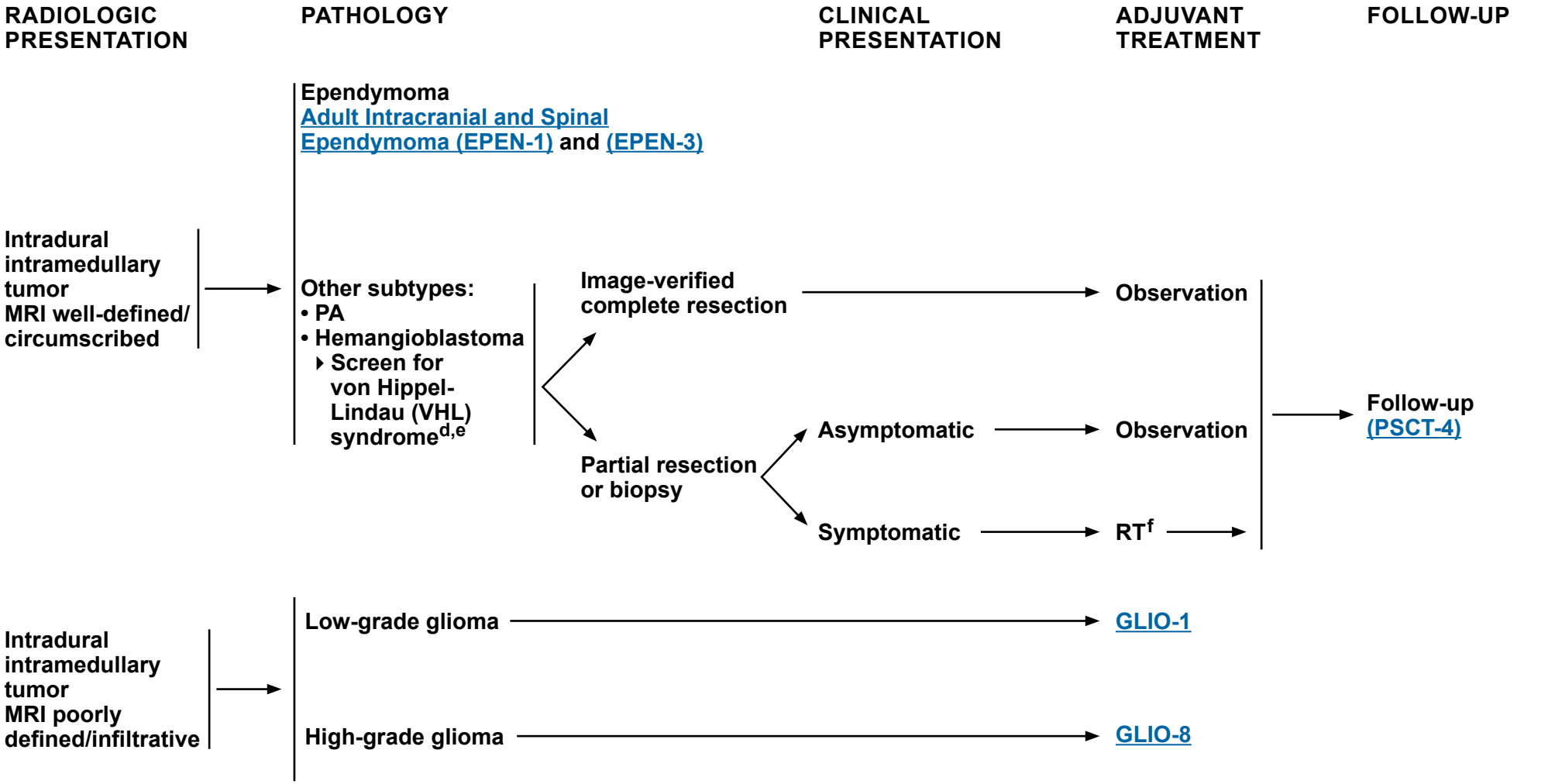

[d] Belzutifan has been FDA-approved for the treatment of VHL-associated CNS hemangioblastomas not requiring immediate surgery.
[e] Principles of Cancer Risk Assessment and Counseling (BRAIN-F).
[f] Principles of Radiation Therapy for Brain and Spinal Cord (BRAIN-C).

Note: All recommendations are category 2A unless otherwise indicated.

Version 3.2025, 12/05/25 © 2025 National Comprehensive Cancer Network® (NCCN®), All rights reserved. NCCN Guidelines® and this illustration may not be reproduced in any form without the express written permission of NCCN.

PLEASE NOTE that use of this NCCN Content is governed by the End-User License Agreement, and you MAY NOT distribute this Content or use it with any artificial intelligence model or tool.
Printed by A. S. M. FAZLUL KARIM CHOWDHURY on 4/20/2026 3:06:38 AM. Copyright © 2026 National Comprehensive Cancer Network, Inc. All Rights Reserved.

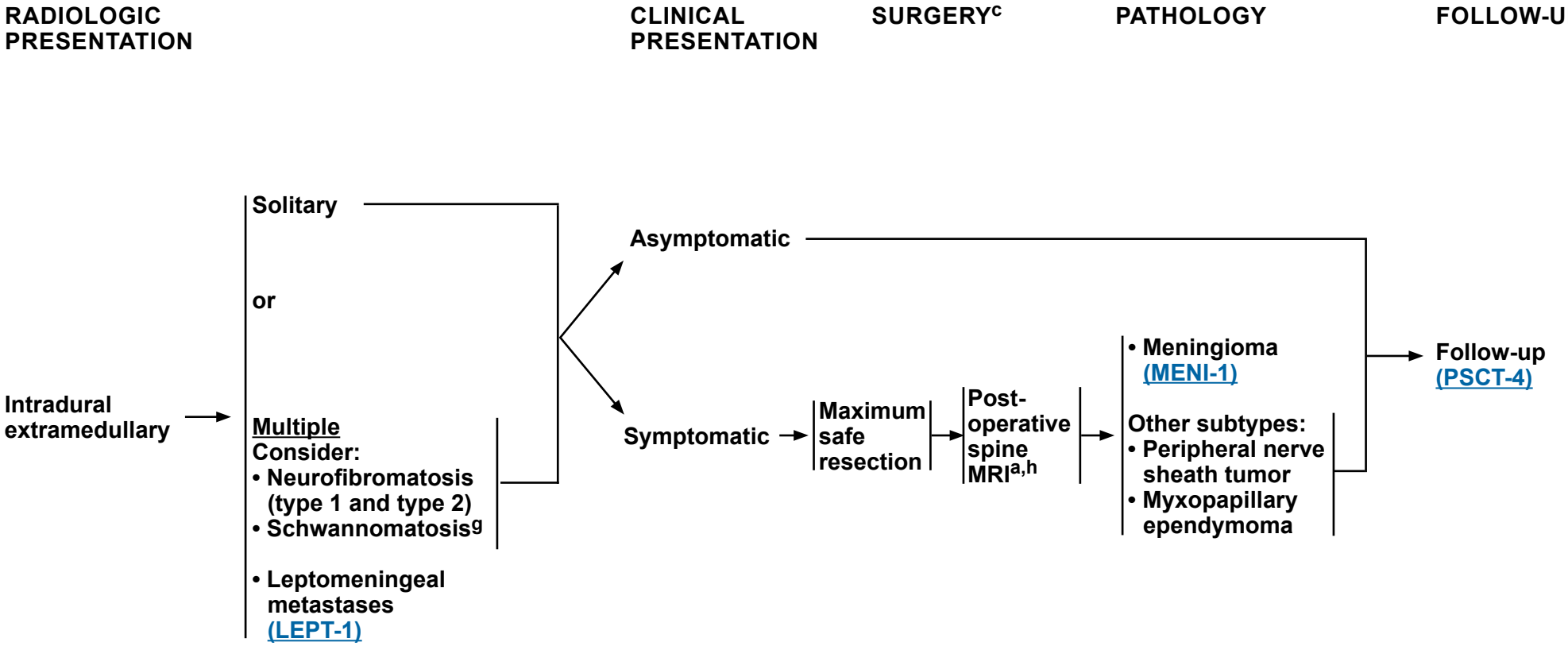

[a] Principles of Brain and Spine Tumor Imaging (BRAIN-A).
[c] Principles of Surgery (BRAIN-B).
[g] For neurofibromatosis type 2 (NF2) vestibular schwannomas with hearing loss, see BRAIN-D 4 of 7.
[h] Spine MRI should be delayed by at least 2–3 weeks post surgery to avoid post-surgical artifacts.

Note: All recommendations are category 2A unless otherwise indicated.

Version 3.2025, 12/05/25 © 2025 National Comprehensive Cancer Network® (NCCN®), All rights reserved. NCCN Guidelines® and this illustration may not be reproduced in any form without the express written permission of NCCN.

PLEASE NOTE that use of this NCCN Content is governed by the End-User License Agreement, and you MAY NOT distribute this Content or use it with any artificial intelligence model or tool.
Printed by A. S. M. FAZLUL KARIM CHOWDHURY on 4/20/2026 3:06:38 AM. Copyright © 2026 National Comprehensive Cancer Network, Inc. All Rights Reserved.

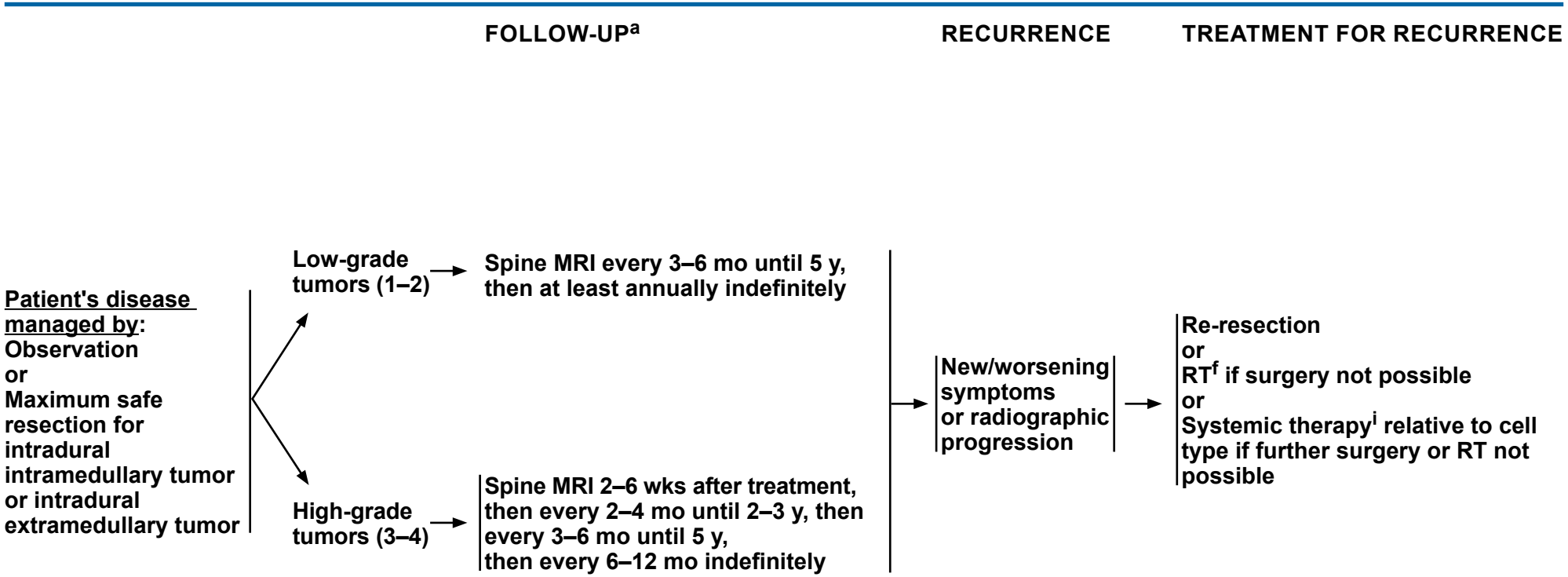

[a] Principles of Brain and Spine Tumor Imaging (BRAIN-A).
[f] Principles of Radiation Therapy for Brain and Spinal Cord (BRAIN-C).
[i] See Primary Spinal Cord Tumor Systemic Therapy (PSCT-A) and systemic therapy pages for other CNS tumor types in these Guidelines for options according to disease histology.

Note: All recommendations are category 2A unless otherwise indicated.

Version 3.2025, 12/05/25 © 2025 National Comprehensive Cancer Network® (NCCN®), All rights reserved. NCCN Guidelines® and this illustration may not be reproduced in any form without the express written permission of NCCN.

PLEASE NOTE that use of this NCCN Content is governed by the End-User License Agreement, and you MAY NOT distribute this Content or use it with any artificial intelligence model or tool.
Printed by A. S. M. FAZLUL KARIM CHOWDHURY on 4/20/2026 3:06:38 AM. Copyright © 2026 National Comprehensive Cancer Network, Inc. All Rights Reserved.

PRIMARY SPINAL CORD TUMORS: SYSTEMIC THERAPY[a]

MISCELLANEOUS CNS TUMORS

Preferred	Other Recommended	Useful in Certain Circumstances
• None	• Bevacizumab[1] (neurofibromatosis type 2 [NF2] vestibular schwannomas with hearing loss); see BRAIN-D 4 of 7	• Belzutifan[b,2] (VHL-associated CNS hemangioblastomas not requiring immediate surgery or those for whom surgery is contraindicated due to location or prior surgeries or comorbidities, growing or symptomatic) • Mirdametinib[3] or selumetinib[4] (category 1) (patients with neurofibromatosis type 1 [NF1] who have symptomatic plexiform neurofibromas [PN] not amenable to complete resection)

FOOTNOTES

[a] An FDA-approved biosimilar is an appropriate substitute for any recommended systemic biologic therapy in the NCCN Guidelines.
[b] Belzutifan has been FDA-approved for the treatment of VHL-associated CNS hemangioblastomas not requiring immediate surgery.

REFERENCES

[1] Plotkin SR, Duda DG, Muzikansky A, et al. Multicenter, prospective, phase II and biomarker study of high-dose bevacizumab as induction therapy in patients with neurofibromatosis type 2 and progressive vestibular Schwannoma. J Clin Oncol 2019;37:3446-3454.
[2] Srinivasan R, Donskov F, Iliopoulos O, et al. Phase 2 study of belzutifan (MK-6482), an oral hypoxia-inducible factor 2α (HIF-2α) inhibitor, for von Hippel-Lindau (VHL) disease-associated clear cell renal cell carcinoma [abstract]. J Clin Oncol 2021;39(Suppl):Abstract 4555. Presented at: American Society of Clinical Oncology (ASCO) Virtual Meeting; June 4-8, 2021.
[3] Moertel CL, Hirbe AC, Shuhaiber HH, et al. ReNeu: A pivotal, phase IIb trial of mirdametinib in adults and children with symptomatic neurofibromatosis type 1-associated plexiform neurofibroma. J Clin Oncol 2025;43:716-729, (Hirbe AC, Moertel CL, Shuhaiber HH, et al. Update from the long-term follow-up (LTFU) Phase of ReNeu: A pivotal phase 2b trial of mirdametinib in children and adults with neurofibromatosis type 1 (NF1)-associated symptomatic plexiform neurofibroma (PN). Presented at the 2025 Children's Tumor Foundation NF Conference, June 21-24, 2025, Washington, DC.
[4] Chen AP, Coyne GO, Wolters PL, et al. Efficacy and safety of selumetinib in adults with neurofibromatosis type 1 and symptomatic, inoperable plexiform neurofibromas (KOMET): a multicentre, international, randomised, placebo-controlled, parallel, double-blind, phase 3 study. The Lancet. 2025; 405(10496):2217-2230.

Note: All recommendations are category 2A unless otherwise indicated.

Version 3.2025, 12/05/25 © 2025 National Comprehensive Cancer Network® (NCCN®), All rights reserved. NCCN Guidelines® and this illustration may not be reproduced in any form without the express written permission of NCCN.

PLEASE NOTE that use of this NCCN Content is governed by the End-User License Agreement, and you MAY NOT distribute this Content or use it with any artificial intelligence model or tool.
Printed by A. S. M. FAZLUL KARIM CHOWDHURY on 4/20/2026 3:06:38 AM. Copyright © 2026 National Comprehensive Cancer Network, Inc. All Rights Reserved.

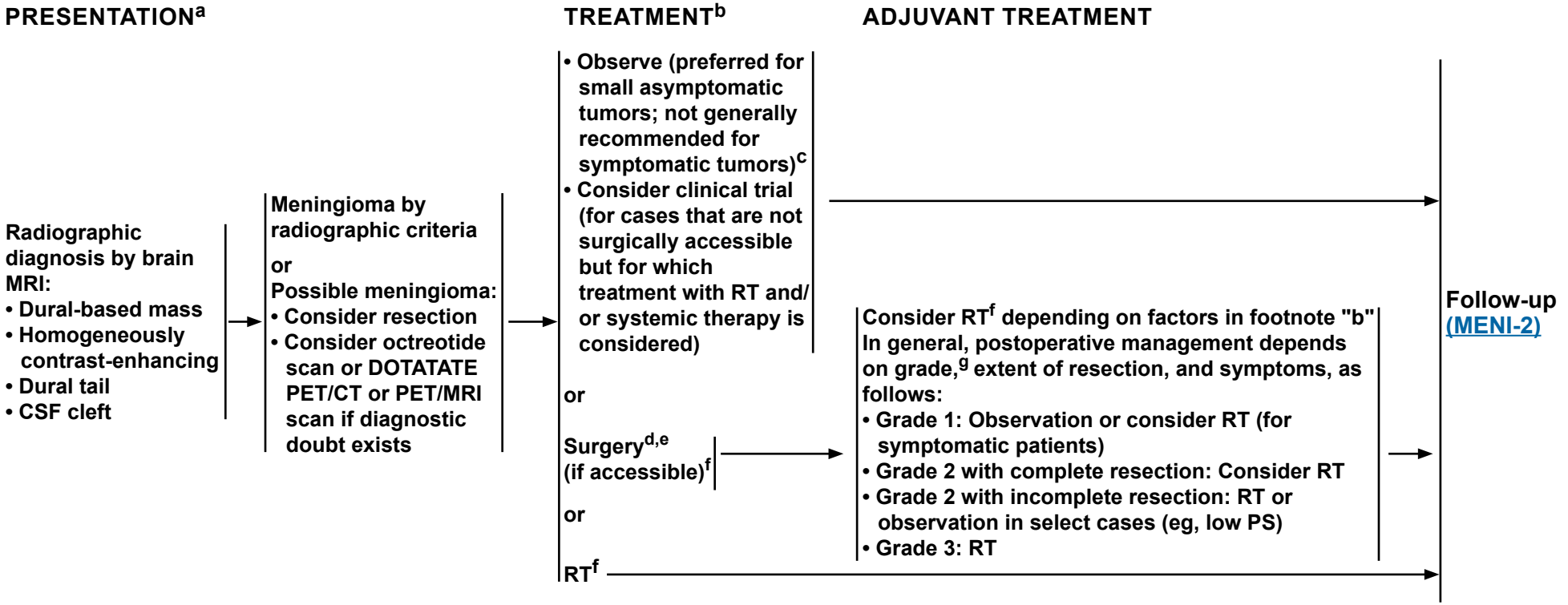

[a] Multidisciplinary input for treatment planning if feasible.

[b] Treatment selection should be based on assessment of a variety of inter-related factors, including patient features (eg, age, performance score, comorbidities, treatment preferences), tumor features (eg, size, grade, growth rate, location [proximity to critical structures], potential for causing neurologic consequences if untreated, presence and severity of symptoms), and treatment-related factors (eg, potential for neurologic consequences from surgery/RT, likelihood of complete resection and/or complete irradiation with SRS, treatability of tumor if it progresses, available surgical or radiation oncology expertise and resources). The decision to administer RT after surgery also depends on the extent of resection achieved. Multidisciplinary input for treatment planning is recommended.

[c] For asymptomatic meningiomas, observation is preferred for small tumors, with a suggested cutoff of ≤3 cm. Active treatment with surgery and/or RT is recommended in patients with one or more tumor- and/or treatment-related risk factors, such as proximity to the optic nerve.

[d] Postoperative brain MRI within 48 hours after surgery.

[e] Principles of Brain and Spine Tumor Imaging (BRAIN-A).

[f] Principles of Radiation Therapy for Brain and Spinal Cord (BRAIN-C).

[g] WHO grade 1 = Benign meningioma; WHO grade 2 = Atypical meningioma; WHO grade 3 = Malignant (anaplastic) meningioma.

Note: All recommendations are category 2A unless otherwise indicated.

Version 3.2025, 12/05/25 © 2025 National Comprehensive Cancer Network® (NCCN®), All rights reserved. NCCN Guidelines® and this illustration may not be reproduced in any form without the express written permission of NCCN.

PLEASE NOTE that use of this NCCN Content is governed by the End-User License Agreement, and you MAY NOT distribute this Content or use it with any artificial intelligence model or tool.
Printed by A. S. M. FAZLUL KARIM CHOWDHURY on 4/20/2026 3:06:38 AM. Copyright © 2026 National Comprehensive Cancer Network, Inc. All Rights Reserved.

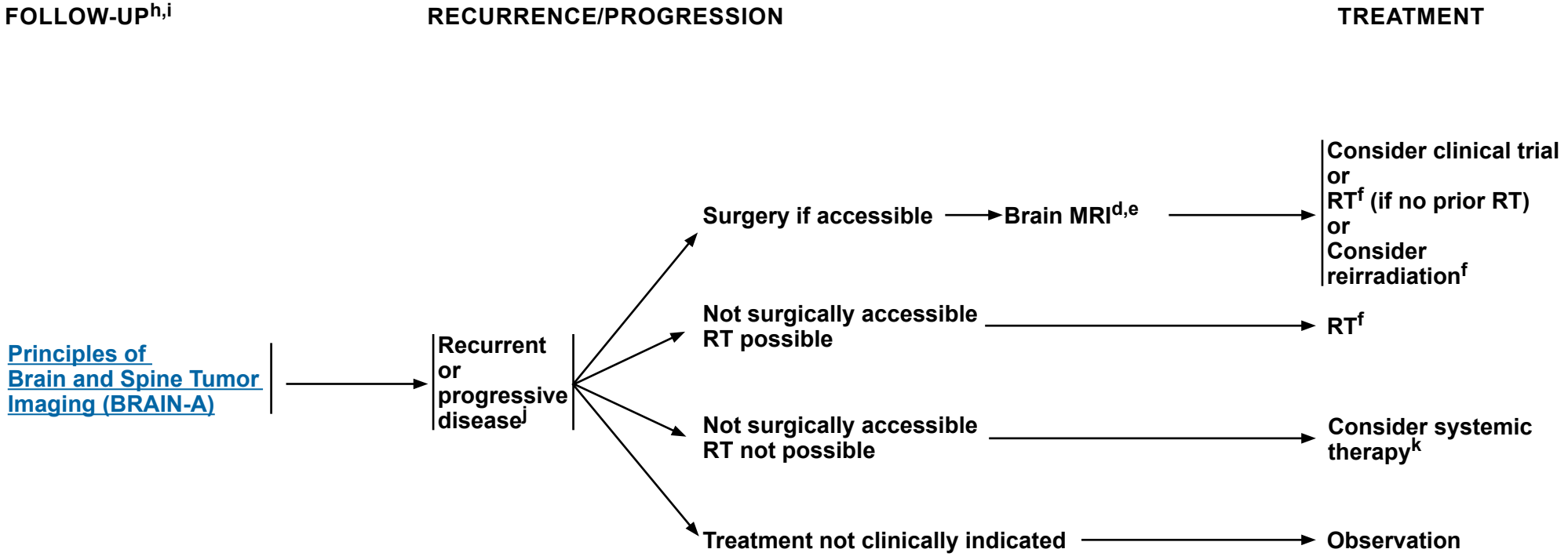

[d] Postoperative brain MRI within 48 hours after surgery.
[e] Principles of Brain and Spine Tumor Imaging (BRAIN-A).
[f] Principles of Radiation Therapy for Brain and Spinal Cord (BRAIN-C).
[h] Consider less frequent follow-up after 5–10 years.
[i] More frequent imaging may be required for meningiomas that are treated for recurrence or with systemic therapy.
[j] Consider use of additional imaging (octreotide scan or DOTATATE PET/CT or PET/MRI scan).
[k] Meningiomas Systemic Therapy (MENI-A).

Note: All recommendations are category 2A unless otherwise indicated.

Version 3.2025, 12/05/25 © 2025 National Comprehensive Cancer Network® (NCCN®), All rights reserved. NCCN Guidelines® and this illustration may not be reproduced in any form without the express written permission of NCCN.

PLEASE NOTE that use of this NCCN Content is governed by the End-User License Agreement, and you MAY NOT distribute this Content or use it with any artificial intelligence model or tool.
Printed by A. S. M. FAZLUL KARIM CHOWDHURY on 4/20/2026 3:06:38 AM. Copyright © 2026 National Comprehensive Cancer Network, Inc. All Rights Reserved.

MENINGIOMAS: SYSTEMIC THERAPY[a]

Preferred	Other Recommended	Useful in Certain Circumstances
• None	• Sunitinib (category 2B)[1] • Bevacizumab[b,2,3,4] • Bevacizumab[b] + everolimus (category 2B)[5]	• Somatostatin analogue (category 2B)[6] • Somatostatin analogue + everolimus[7]

FOOTNOTES

[a] An FDA-approved biosimilar is an appropriate substitute for any recommended systemic biologic therapy in the NCCN Guidelines.
[b] Patients who have evidence of radiographic progression may benefit from continuation of bevacizumab to prevent rapid neurologic deterioration.

REFERENCES

[1] Kaley TJ, Wen P, Schiff D, et al. Phase II trial of sunitinib for recurrent and progressive atypical and anaplastic meningioma. Neuro Oncol 2015;17:116-121.
[2] Lou E, Sumrall AL, Turner S, et al. Bevacizumab therapy for adults with recurrent/progressive meningioma: a retrospective series. J Neurooncol 2012;109:63-70.
[3] Nayak L, Iwamoto FM, Rudnick JD, et al. Atypical and anaplastic meningiomas treated with bevacizumab. J Neurooncol 2012;109:187-193.
[4] Kumthekar P, Grimm SA, Aleman RT, et al. A multi-institutional phase II trial of bevacizumab for recurrent and refractory meningioma. Neurooncol Adv 2022;4:vdac123.
[5] Shih KC, Chowdhary S, Rosenblatt P, et al. A phase II trial of bevacizumab and everolimus as treatment for patients with refractory, progressive intracranial meningioma. J Neurooncol 2016;129:281-288.
[6] Chamberlain MC, Glantz MJ, Fadul CE. Recurrent meningioma: salvage therapy with long-acting somatostatin analogue. Neurology 2007;69:969-973.
[7] Graillon T, Sanson M, Campello C, et al. Everolimus and octreotide for patients with recurrent meningioma: Results from the phase II CEVOREM trial. Clin Cancer Res. 2020;26:552-557.

Note: All recommendations are category 2A unless otherwise indicated.

Version 3.2025, 12/05/25 © 2025 National Comprehensive Cancer Network® (NCCN®), All rights reserved. NCCN Guidelines® and this illustration may not be reproduced in any form without the express written permission of NCCN.

PLEASE NOTE that use of this NCCN Content is governed by the End-User License Agreement, and you MAY NOT distribute this Content or use it with any artificial intelligence model or tool.
Printed by A. S. M. FAZLUL KARIM CHOWDHURY on 4/20/2026 3:06:38 AM. Copyright © 2026 National Comprehensive Cancer Network, Inc. All Rights Reserved.

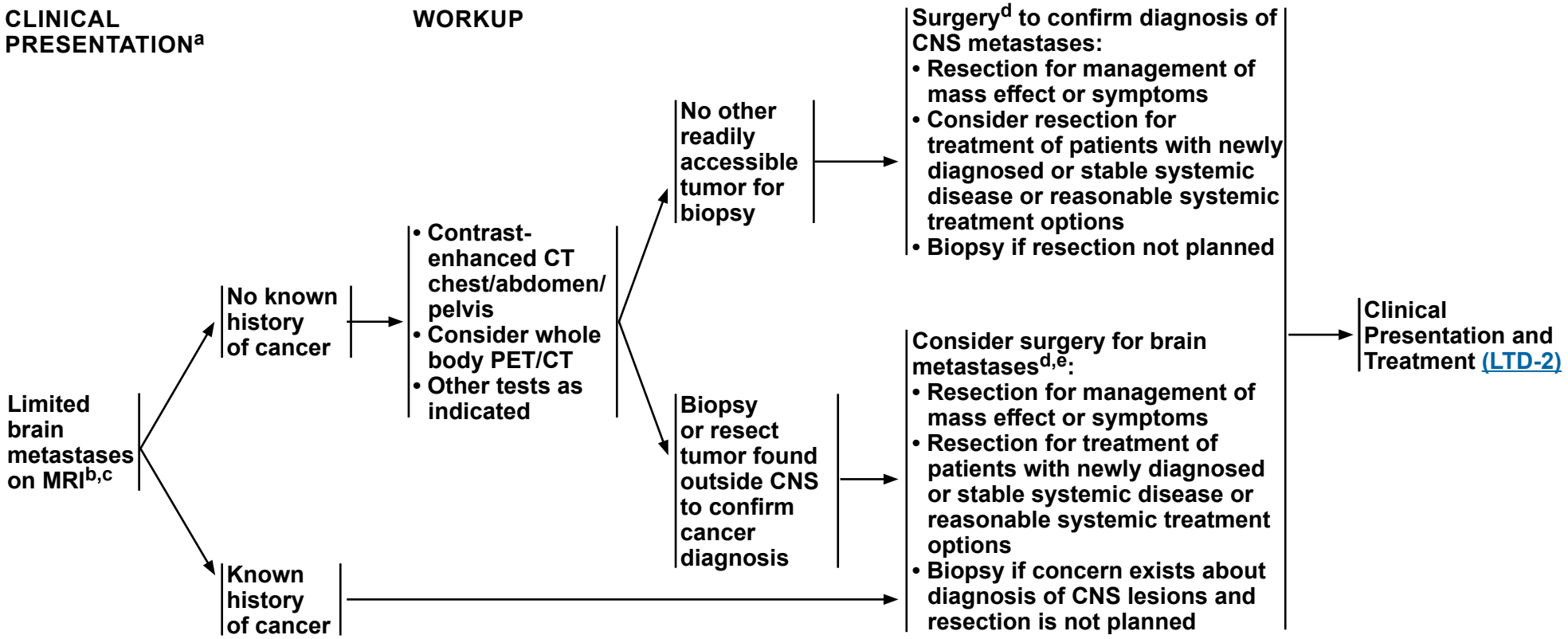

[a] Principles of Brain and Spine Tumor Imaging (BRAIN-A).
[b] Based on multidisciplinary review for treatment planning, once pathology is available. See Principles of Brain and Spine Tumor Management (BRAIN-D).
[c] "Limited" brain metastases defines a group of patients for whom SRS is equally effective and offers significant cognitive protection compared with WBRT. The definition of "limited" brain metastases in terms of number of metastases or total intracranial disease volume is evolving and may depend on the specific clinical situation (Yamamoto M, et al. Lancet Oncol 2014;15:387-395).
[d] Principles of Surgery (BRAIN-B).
[e] The decision to resect a tumor may depend on the need to establish histologic diagnosis, the size of the lesion, its location, and institutional expertise. For example, smaller (<2 cm), deep, asymptomatic lesions may be considered for treatment with SRS versus larger (>2 cm), symptomatic lesions that may be more appropriate for surgery (Ewend MG, et al. J Natl Compr Cancer Netw 2008;6:505-513).

Note: All recommendations are category 2A unless otherwise indicated.

Version 3.2025, 12/05/25 © 2025 National Comprehensive Cancer Network® (NCCN®), All rights reserved. NCCN Guidelines® and this illustration may not be reproduced in any form without the express written permission of NCCN.

PLEASE NOTE that use of this NCCN Content is governed by the End-User License Agreement, and you MAY NOT distribute this Content or use it with any artificial intelligence model or tool.
Printed by A. S. M. FAZLUL KARIM CHOWDHURY on 4/20/2026 3:06:38 AM. Copyright © 2026 National Comprehensive Cancer Network, Inc. All Rights Reserved.

CLINICAL PRESENTATION | **TREATMENT[g,h]**

Newly diagnosed or stable systemic disease or Reasonable systemic treatment options exist[f,h] →

Stereotactic radiosurgery (SRS) (preferred)[i,j]
or
Surgical resection for management of mass effect or symptoms followed by SRS (BRAIN-C) to the surgical bed and other brain metastases
or
Systemic therapy in select patients[f,g,h]
or
Hippocampal avoidance with WBRT (HA-WBRT)[i,k,l] + memantine

Disseminated systemic disease with poor systemic treatment options[f] →

HA-WBRT[g,i] + memantine[l]
or
SRS[i]
or
WBRT[i] without HA ± memantine
or
Consider palliative/best supportive care

→ **Follow-up and Recurrence (LTD-3)**

[f] For secondary CNS lymphoma, treatment may include systemic treatment, WBRT or focal RT, or a combination.
[g] If an active agent exists (eg, cytotoxic, targeted, immune modulating), trial of systemic therapy with good CNS penetration may be considered in select patients (eg, for patients with small asymptomatic brain metastases from melanoma or *ALK* rearrangement-positive non-small cell lung cancer [NSCLC] or *EGFR*-mutated NSCLC); it is reasonable to hold on treating with radiation to see if systemic therapy can control the brain metastases. Consultation with a radiation oncologist and close MRI surveillance is strongly recommended. There are no data from prospective clinical trials comparing the two strategies to assess what the impact of delayed radiation would be in terms of survival or in delay of neurologic deficit development.
[h] Brain Metastases: Systemic Therapy (BRAIN METS-A).
[i] Principles of Radiation Therapy for Brain and Spinal Cord (BRAIN-C). See LTD-3 for reirradiation doses for brain metastases.
[j] SRS is preferred for low tumor volume and when safe and feasible. For disease volume or distribution not feasible for SRS, consider HA-WBRT. Ideally, cognitive sparing radiotherapy should be employed in these settings.
[k] For brain metastases not managed with resection, SRS + WBRT is generally not recommended, as the addition of WBRT to SRS does not improve survival and can be associated with greater cognitive decline and poorer quality of life (QOL) (Brown PD, et al. JAMA 2016;316:401-409). However, the combination of SRS and WBRT may be appropriate in carefully selected clinical circumstances (eg, WBRT is already being offered for extensive brain metastases and an SRS boost is considered for a large lesion or radioresistant histology for the goal of improving local control) (Andrews DW, et al. Lancet 2004;363:1665-1672).
[l] Brain metastases not within 5 mm of the hippocampi; life expectancy of at least 4 months. In patients without brain metastases within 5 mm of the hippocampi, HA-WBRT + memantine was superior to WBRT + memantine in terms of cognitive preservation and patient-reported QOL (Brown PD, et al. J Clin Oncol 2020;38:1019-1029 and Brown PD, et al. Neuro Oncol 2013;15:1429-1437).

Note: All recommendations are category 2A unless otherwise indicated.

Version 3.2025, 12/05/25 © 2025 National Comprehensive Cancer Network® (NCCN®), All rights reserved. NCCN Guidelines® and this illustration may not be reproduced in any form without the express written permission of NCCN.

PLEASE NOTE that use of this NCCN Content is governed by the End-User License Agreement, and you MAY NOT distribute this Content or use it with any artificial intelligence model or tool.
Printed by A. S. M. FAZLUL KARIM CHOWDHURY on 4/20/2026 3:06:38 AM. Copyright © 2026 National Comprehensive Cancer Network, Inc. All Rights Reserved.

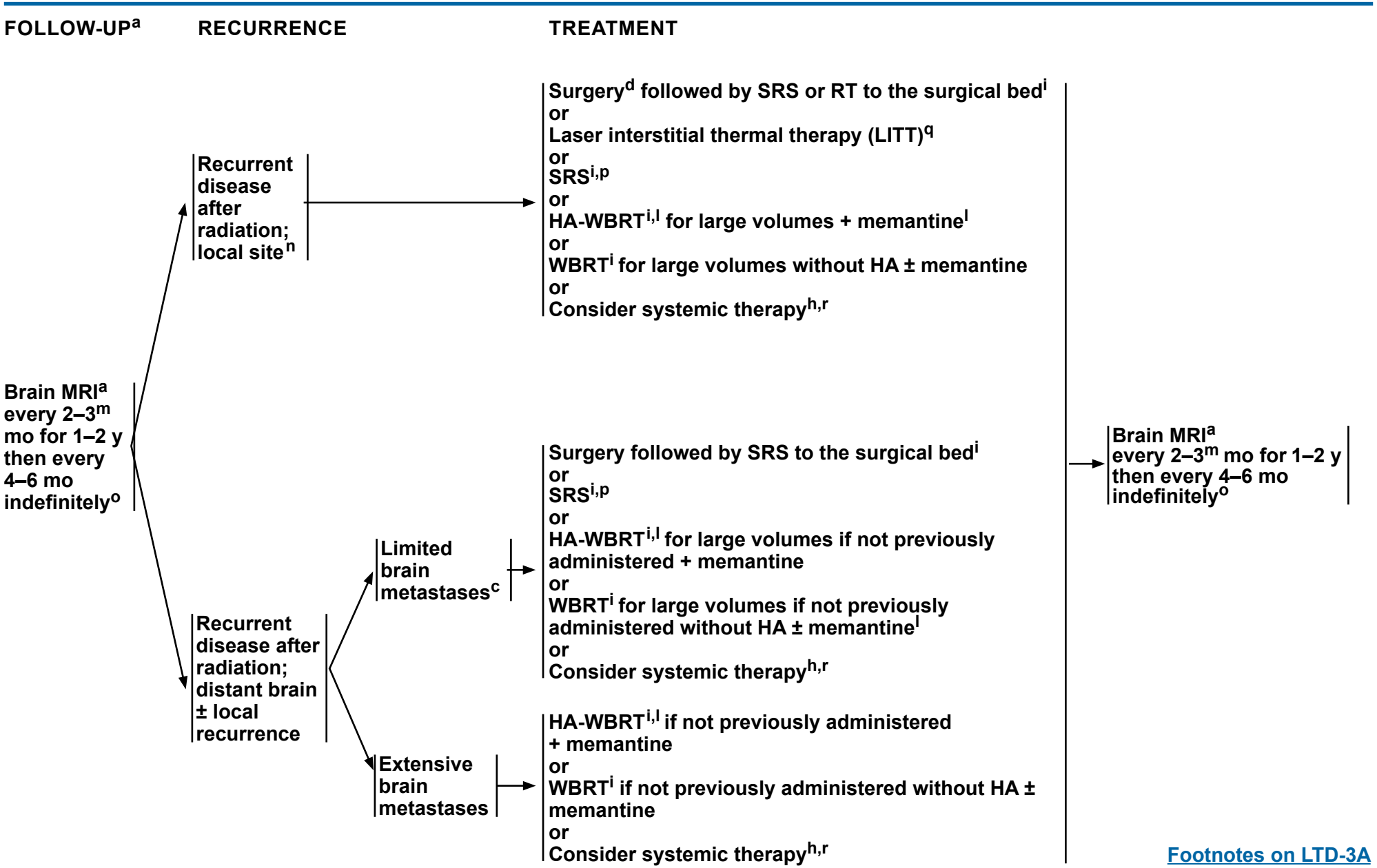

Footnotes on LTD-3A

Note: All recommendations are category 2A unless otherwise indicated.

Version 3.2025, 12/05/25 © 2025 National Comprehensive Cancer Network® (NCCN®), All rights reserved. NCCN Guidelines® and this illustration may not be reproduced in any form without the express written permission of NCCN.

PLEASE NOTE that use of this NCCN Content is governed by the End-User License Agreement, and you MAY NOT distribute this Content or use it with any artificial intelligence model or tool.
Printed by A. S. M. FAZLUL KARIM CHOWDHURY on 4/20/2026 3:06:38 AM. Copyright © 2026 National Comprehensive Cancer Network, Inc. All Rights Reserved.

FOOTNOTES

[a] Principles of Brain and Spine Tumor Imaging (BRAIN-A).
[c] "Limited" brain metastases defines a group of patients for whom SRS is equally effective and offers significant cognitive protection compared with WBRT. The definition of "limited" brain metastases in terms of number of metastases or total intracranial disease volume is evolving and may depend on the specific clinical situation (Yamamoto M, et al. Lancet Oncol 2014;15:387-395).
[d] Principles of Surgery (BRAIN-B).
[h] Brain Metastases: Systemic Therapy (BRAIN METS-A).
[i] Principles of Radiation Therapy for Brain and Spinal Cord (BRAIN-C). See LTD-3 for reirradiation doses for brain metastases.
[l] Brain metastases not within 5 mm of the hippocampi; life expectancy of at least 4 months. In patients without brain metastases within 5 mm of the hippocampi, HA-WBRT + memantine was superior to WBRT + memantine in terms of cognitive preservation and patient-reported QOL (Brown PD, et al. J Clin Oncol 2020;38:1019-1029 and Brown PD, et al. Neuro Oncol 2013;15:1429-1437).
[m] MRI every 2 months (instead of 3 months) for those patients treated with SRS alone.
[n] After SRS, imaging changes may reflect treatment changes or tumor progression. Consider advanced MRI imaging, including perfusion or spectroscopy, multidisciplinary input, or observation with early repeat imaging. When diagnosis remains unclear, consider tissue sampling.
[o] Imaging to evaluate emergent signs/symptoms is appropriate at any time.
[p] If patient had previous SRS with a good response >6 months, then reconsider SRS if imaging supports active tumor and not necrosis.
[q] This option is for patients who are not considered surgical candidates (Ahluwalia M, et al. J Neurosurg 2018;130:804-811 and Hernandez RN, et al. Neurosurgery 2019;85:84-90).
[r] In certain cases, retreatment with radiation, (eg, WBRT or SRS) is possible. If patient cannot be treated with repeat radiation, other possible options include laser thermal ablation, or palliative/best supportive care.

Note: All recommendations are category 2A unless otherwise indicated.

Version 3.2025, 12/05/25 © 2025 National Comprehensive Cancer Network® (NCCN®), All rights reserved. NCCN Guidelines® and this illustration may not be reproduced in any form without the express written permission of NCCN.

PLEASE NOTE that use of this NCCN Content is governed by the End-User License Agreement, and you MAY NOT distribute this Content or use it with any artificial intelligence model or tool.
Printed by A. S. M. FAZLUL KARIM CHOWDHURY on 4/20/2026 3:06:38 AM. Copyright © 2026 National Comprehensive Cancer Network, Inc. All Rights Reserved.

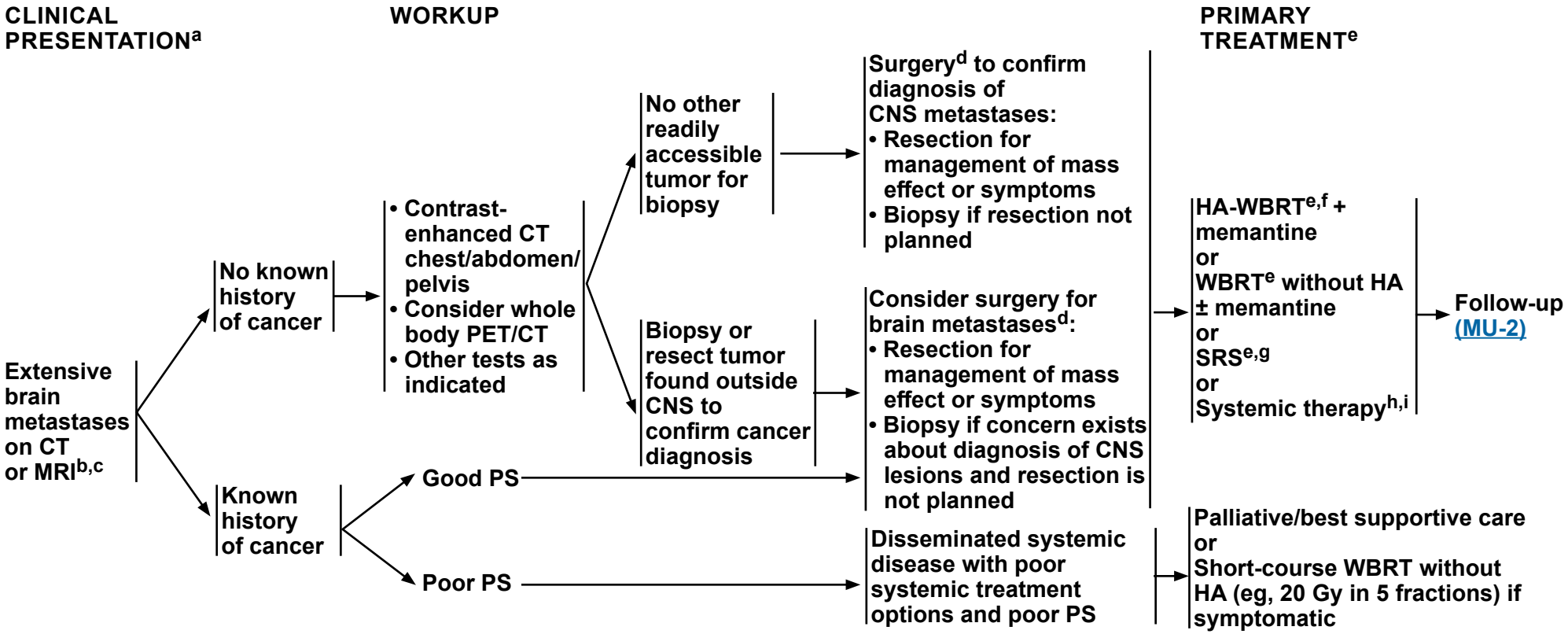

[a] Principles of Brain and Spine Tumor Imaging (BRAIN-A).
[b] Based on multidisciplinary review for treatment planning, once pathology is available. See Principles of Brain and Spine Tumor Management (BRAIN-D).
[c] Includes all cases that do not fit the definition of "limited brain metastases" on LTD-1.
[d] Principles of Surgery (BRAIN-B).
[e] Principles of Radiation Therapy for Brain and Spinal Cord (BRAIN-C).
[f] Brain metastases not within 5 mm of the hippocampi; KPS ≥70; life expectancy of at least 4 months; no leptomeningeal disease. In patients without brain metastases within 5 mm of the hippocampi, HA-WBRT + memantine was superior to WBRT + memantine in terms of cognitive preservation and patient-reported QOL (Brown PD, et al. J Clin Oncol 2020;38:1019-1029 and Brown PD, et al. Neuro Oncol 2013;15:1429-1437).
[g] SRS can be considered for patients with good performance and low overall tumor volume and/or radioresistant tumors such as melanoma (Yamamoto M, et al. Lancet Oncol 2014;15:387-395).
[h] If an active agent exists (eg, cytotoxic, targeted, immune modulating), trial of systemic therapy with good CNS penetration may be considered in select patients (eg, for patients with small asymptomatic brain metastases from melanoma or *ALK* rearrangement-positive NSCLC or *EGFR*-mutated NSCLC); it is reasonable to hold on treating with radiation to see if systemic therapy can control the brain metastases. Consultation with a radiation oncologist and close MRI surveillance is strongly recommended. There are no data from prospective clinical trials comparing the two strategies to assess what the impact of delayed radiation would be in terms of survival or in delay of neurologic deficit development.
[i] Brain Metastases: Systemic Therapy (BRAIN METS-A).

Note: All recommendations are category 2A unless otherwise indicated.

Version 3.2025, 12/05/25 © 2025 National Comprehensive Cancer Network® (NCCN®), All rights reserved. NCCN Guidelines® and this illustration may not be reproduced in any form without the express written permission of NCCN.

PLEASE NOTE that use of this NCCN Content is governed by the End-User License Agreement, and you MAY NOT distribute this Content or use it with any artificial intelligence model or tool.
Printed by A. S. M. FAZLUL KARIM CHOWDHURY on 4/20/2026 3:06:38 AM. Copyright © 2026 National Comprehensive Cancer Network, Inc. All Rights Reserved.

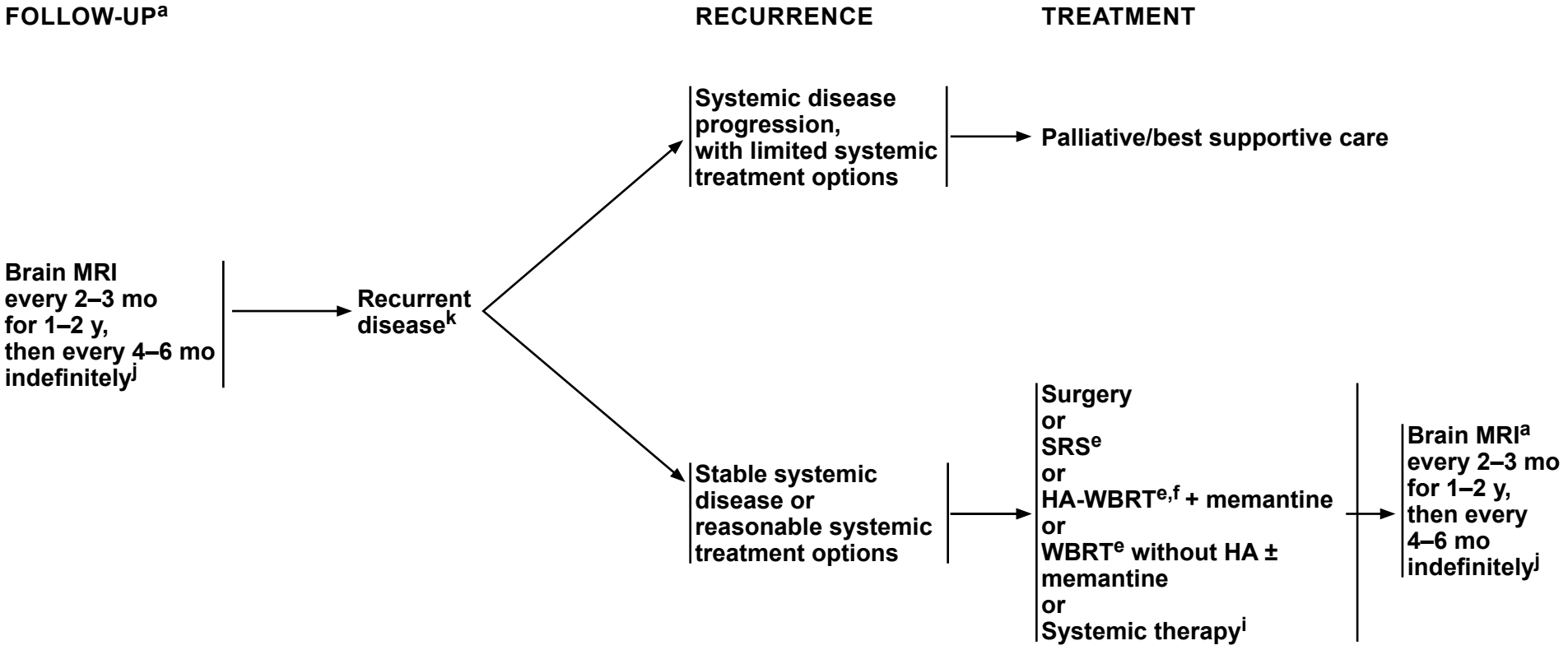

[a] Principles of Brain and Spine Tumor Imaging (BRAIN-A).
[e] Principles of Radiation Therapy for Brain and Spinal Cord (BRAIN-C).
[f] Brain metastases not within 5 mm of the hippocampi; KPS ≥70; life expectancy of at least 4 months; no leptomeningeal disease. In patients without brain metastases within 5 mm of the hippocampi, HA-WBRT + memantine was superior to WBRT + memantine in terms of cognitive preservation and patient-reported QOL (Brown PD, et al. J Clin Oncol 2020;38:1019-1029 and Brown PD, et al. Neuro Oncol 2013;15:1429-1437).
[i] Brain Metastases: Systemic Therapy (BRAIN METS-A).
[j] Imaging to evaluate emergent signs/symptoms is appropriate at any time.
[k] After SRS, recurrence on MRI can be confounded by treatment effects; consider tumor tissue sampling if there is a high index of suspicion of recurrence.

Note: All recommendations are category 2A unless otherwise indicated.

Version 3.2025, 12/05/25 © 2025 National Comprehensive Cancer Network® (NCCN®), All rights reserved. NCCN Guidelines® and this illustration may not be reproduced in any form without the express written permission of NCCN.

PLEASE NOTE that use of this NCCN Content is governed by the End-User License Agreement, and you MAY NOT distribute this Content or use it with any artificial intelligence model or tool.
Printed by A. S. M. FAZLUL KARIM CHOWDHURY on 4/20/2026 3:06:38 AM. Copyright © 2026 National Comprehensive Cancer Network, Inc. All Rights Reserved.

BRAIN METASTASES[a]: SYSTEMIC THERAPY[b]

- Tumor Agnostic[b]
  - NTRK gene fusion tumors
    - ◊ Preferred
      - – Larotrectinib[1]
      - – Entrectinib[2]
      - – Repotrectinib[3]
    - ◊ Other Recommended
      - – Temozolomide 5/28 Schedule
  - MSI-H/dMMR or TMB-H (≥10 mut/Mb) tumors for isolated brain metastases
    - ◊ Preferred
      - – Pembrolizumab (category 2B)[c,4,5]
- Breast Cancer[d]
  - HER2 positive
    - ◊ Preferred
      - – Tucatinib + trastuzumab + capecitabine (category 1) if previously treated with ≥1 regimen[6]
      - – Fam-trastuzumab deruxtecan-nxki if previously treated with ≥1 regimen[7,8]
    - ◊ Other Recommended
      - – Ado-trastuzumab emtansine (T-DM1)[9]
      - – Neratinib and T-DM1[10]
      - – Capecitabine + lapatinib[11,12]
      - – Capecitabine + neratinib[13,14]
      - – Pertuzumab and high-dose trastuzumab[e,15]
      - – Paclitaxel + neratinib (category 2B)[16]
  - HER2 non-specific
    - ◊ Other Recommended
      - – Capecitabine[17-21]
      - – Cisplatin (category 2B)[22,23]
      - – Etoposide (category 2B)[22,23]
      - – Cisplatin + etoposide (category 2B)[23,24]
      - – High-dose methotrexate (category 2B)[f,25]
  - HER2 low
    - ◊ Useful in Certain Circumstances
      - – Fam-trastuzumab deruxtecan-nxki (may also be used in patients with breast cancer that is HER2 immunohistochemistry [IHC] 1+ or 2+/in situ hybridization [ISH] negative)[26,27]
- Melanoma[d]
  - BRAF V600E positive
    - ◊ Preferred
      - – Dabrafenib[28-30]/trametinib[31]
      - – Vemurafenib[32,33]/cobimetinib[g] (category 2B)
  - BRAF non-specific
    - ◊ Preferred
      - – Ipilimumab + nivolumab[h,34-36]
    - ◊ Other Recommended
      - – Ipilimumab[37]
      - – Nivolumab[h,35]
      - – Pembrolizumab[c,38]
- Non-Small Cell Lung Cancer (NSCLC)[d]
  - *KRAS* G12C mutation
    - ◊ Adagrasib[39,40]
    - ◊ Sotorasib (category 2B)[41,42]
  - EGFR-sensitizing mutation positive
    - ◊ Preferred
      - – Osimertinib[43-46]
      - – Amivantamab-vmjw + lazertinib (for exon 19 deletion or L858R)[47]
      - – Amivantamab-vmjw + carboplatin + pemetrexed (for exon 19 deletion or L858R)[48]
    - ◊ Other Recommended
      - – Osimertinib plus platinum-pemetrexed (cisplatin or carboplatin) (category 1)[49]
      - – Pulsatile erlotinib[50-52]
      - – Afatinib (category 2B)[53]
      - – Gefitinib (category 2B)[54,55]
  - MET exon 14 mutated
    - ◊ Other Recommended
      - – Capmatinib[56]
      - – Tepotinib[57,58]
  - RET fusion positive
    - ◊ Selpercatinib[59]
  - ALK rearrangement positive
    - ◊ Preferred
      - – Brigatinib[60,61]
      - – Lorlatinib[62]
      - – Alectinib[63,64]
      - – Ceritinib[65]
  - ALK rearrangement positive or ROS1 positive
    - ◊ Crizotinib (category 2B)[66]
  - ROS1 positive
    - ◊ Repotrectinib[67]
  - PD-L1 positive
    - ◊ Other Recommended
      - – Pembrolizumab[c,38,68] (tumor proportion score [TPS] ≥1%)
      - – Nivolumab[h,69-71] (TPS ≥1%)
- Small Cell Lung Cancer[d]
  - ◊ Tarlatamab-dlle[72]
  - ◊ Topotecan (category 2B)
- Lymphoma[d]
  - ◊ High-dose methotrexate[73]
  - ◊ BTK inhibitor (eg, ibrutinib)[74]
- Renal Cell Carcinoma[d]
  - Cabozantinib[75]
  - Belzutifan (category 2B)[76] (for VHL-associated renal cell carcinoma [RCC])

Continued

Note: All recommendations are category 2A unless otherwise indicated.

Version 3.2025, 12/05/25 © 2025 National Comprehensive Cancer Network® (NCCN®), All rights reserved. NCCN Guidelines® and this illustration may not be reproduced in any form without the express written permission of NCCN.

PLEASE NOTE that use of this NCCN Content is governed by the End-User License Agreement, and you MAY NOT distribute this Content or use it with any artificial intelligence model or tool.
Printed by A. S. M. FAZLUL KARIM CHOWDHURY on 4/20/2026 3:06:38 AM. Copyright © 2026 National Comprehensive Cancer Network, Inc. All Rights Reserved.

BRAIN METASTASES: SYSTEMIC THERAPY FOOTNOTES

[a] If an active agent exists (eg, cytotoxic, targeted, immune modulating), trial of systemic therapy with good CNS penetration may be considered in select patients (eg, for patients with small asymptomatic brain metastases it is reasonable to hold on treating with radiation to see if systemic therapy can control the brain metastases). Consultation with a radiation oncologist and close MRI surveillance is strongly recommended. There are no data from prospective clinical trials comparing the two strategies to assess what the impact of delayed radiation would be in terms of survival or in delay of neurologic deficit development.
[b] An FDA-approved biosimilar is an appropriate substitute for any recommended systemic biologic therapy in the NCCN Guidelines.
[c] Pembrolizumab and berahyaluronidase alfa-pmph subcutaneous injection may be substituted for IV pembrolizumab. Pembrolizumab and berahyaluronidase alfa-pmph has different dosing and administration instructions compared to IV pembrolizumab.
[d] See the appropriate NCCN treatment guidelines for systemic therapy recommendations for newly diagnosed brain metastases for any cancers not listed here.
[e] Use active agents against primary tumor.
[f] Consider glucarpidase (carboxypeptidase G2) for prolonged methotrexate clearance due to methotrexate-induced renal toxicity. Ramsey LB, Balis FM, O'Brien MM, et al. Consensus guideline for use of glucarpidase in patients with high-dose methotrexate induced acute kidney injury and delayed methotrexate clearance. Oncologist 2018;23:52-61.
[g] Although there are no published prospective studies on the combination of vemurafenib and cobimetinib for melanoma patients with brain metastases, there is high-quality evidence that for melanoma with distant metastasis, combination therapy with vemurafenib and cobimetinib is associated with improved outcomes and safety compared with single-agent vemurafenib.
[h] Nivolumab and hyaluronidase-nvhy is not approved for concurrent use with intravenous (IV) ipilimumab; however, for nivolumab monotherapy, nivolumab and hyaluronidase-nvhy subcutaneous injection may be substituted for IV nivolumab. Nivolumab and hyaluronidase-nvhy has different dosing and administration instructions compared to IV nivolumab.

REFERENCES

[1] Hong DS, DuBois SG, Kummar S, et al. Larotrectinib in patients with TRK fusion-positive solid tumours: a pooled analysis of three phase 1/2 clinical trials. Lancet Oncol 2020;21:531-540.
[2] Doebele RC, Drilon A, Paz-Ares L, et al. Entrectinib in patients with advanced or metastatic NTRK fusion-positive solid tumours: integrated analysis of three phase 1-2 trials. Lancet Oncol 2020;21:271-282.
[3] Solomon BJ, Drilon A, Lin JJ, et al. 1372P Repotrectinib in patients (pts) with NTRK fusion-positive (NTRK+) advanced solid tumors, including NSCLC: update from the phase I/II TRIDENT-1 trial [abstract]. Ann Oncol 2023;34(Suppl):S755-S851.
[4] Marabelle A, Le DT, Ascierto PA, et al. Efficacy of pembrolizumab in patients with noncolorectal high microsatellite instability/mismatch repair-deficient cancer: Results from the phase II KEYNOTE-158 study. J Clin Oncol 2020;38:1-10.
[5] Xiang T, Zhang H, Fang W, et al. A case of dMMR/MSI-H/TMB-H colon cancer with brain metastasis treated with PD-1 monoclonal antibody. Case Reports 2024;53:58-63.
[6] Murthy RK, Loi S, Okines A, et al. Tucatinib, trastuzumab, and capecitabine for HER2-positive metastatic breast cancer. N Engl J Med 2020;382:597-609.
[7] Jerusalem G, Park YH, Yamashita T, et al. Trastuzumab deruxtecan (T-DXd) in patients with HER2+ metastatic breast cancer with brain metastases: a subgroup analysis of the DESTINY-Breast01 trial [abstract]. J Clin Oncol 2021;39(Suppl):Abstract 526.
[8] Cortés J, Kim S-B, Chung W-P, et al. Trastuzumab deruxtecan (T-DXd) vs trastuzumab emtansine (T-DM1) in patients (Pts) with HER2+ metastatic breast cancer (mBC): Results of the randomized, phase III DESTINY-Breast03 study [abstract]. Ann Oncol 2021;32(Suppl):S1287-S1288.
[9] Montemurro F, Delaloge S, Barrios CH, et al. Trastuzumab emtansine (T-DM1) in patients with HER2-positive metastatic breast cancer and brain metastases: exploratory final analysis of cohort 1 from KAMILLA, a single-arm phase IIIb clinical trial. Ann Oncol 2020;31:1350-1358.
[10] Freedman RA, Heiling HM, Li T, Trapani D, et al. Neratinib and ado-trastuzumab emtansine for pretreated and untreated human epidermal growth factor receptor 2 (HER2)-positive breast cancer brain metastases: Translational Breast Cancer Research Consortium trial 022. Ann Oncol 2024;35:993-1002.

Continued

Note: All recommendations are category 2A unless otherwise indicated.

Version 3.2025, 12/05/25 © 2025 National Comprehensive Cancer Network® (NCCN®), All rights reserved. NCCN Guidelines® and this illustration may not be reproduced in any form without the express written permission of NCCN.

PLEASE NOTE that use of this NCCN Content is governed by the End-User License Agreement, and you MAY NOT distribute this Content or use it with any artificial intelligence model or tool.
Printed by A. S. M. FAZLUL KARIM CHOWDHURY on 4/20/2026 3:06:38 AM. Copyright © 2026 National Comprehensive Cancer Network, Inc. All Rights Reserved.

BRAIN METASTASES: SYSTEMIC THERAPY REFERENCES (CONTINUED)

[11] Bachelot T, Romieu G, Campone M, et al. Lapatinib plus capecitabine in patients with previously untreated brain metastases from HER2-positive metastatic breast cancer (LANDSCAPE): a single-group phase 2 study. Lancet Oncol 2013;14:64-71.
[12] Petrelli F, Ghidini M, Lonati V, et al. The efficacy of lapatinib and capecitabine in HER-2 positive breast cancer with brain metastases: A systematic review and pooled analysis. Eur J Cancer 2017;84:141-148. 13 Freedman RA, Gelman RS, Anders CK, et al. TBCRC 022: a phase II trial of neratinib and capecitabine for patients with human epidermal growth factor receptor 2-positive breast cancer and brain metastases. J Clin Oncol 2019;37:1081-1089.
[14] Saura C, Oliveira M, Feng YH, et al. Neratinib plus capecitabine versus lapatinib plus capecitabine in HER2-positive metastatic breast cancer previously treated with ≥ 2 HER2-directed regimens: phase III NALA trial. J Clin Oncol 2020;38:3138-3149.
[15] Lin NU, Pegram M, Sahebjam S, et al. Pertuzumab plus high-dose trastuzumab in patients with progressive brain metastases and HER2-positive metastatic breast cancer: Primary analysis of a phase II study. J Clin Oncol 2021;39:2667-2675
[16] Awada A, Colomer R, Inoue K, et al. Neratinib plus paclitaxel vs trastuzumab plus paclitaxel in previously untreated metastatic ERBB2-positive breast cancer: the NEfERT-T randomized clinical trial. JAMA Oncol 2016;2:1557-1564.
[17] Rivera E, Meyers C, Groves M, et al. Phase I study of capecitabine in combination with temozolomide in the treatment of patients with brain metastases from breast carcinoma. Cancer 2006;107:1348-1354.
[18] Fabi A, Vidiri A, Ferretti G, et al. Dramatic regression of multiple brain metastases from breast cancer with capecitabine: another arrow at the bow? Cancer Invest 2006;24:466-468.
[19] Siegelmann-Danieli N, Stein M, Bar-Ziv J. Complete response of brain metastases originating in breast cancer to capecitabine therapy. Isr Med Assoc J 2003;5:833-834.
[20] Wang ML, Yung WK, Royce ME, et al. Capecitabine for 5-fluorouracil-resistant brain metastases from breast cancer. Am J Clin Oncol 2001;24:421-424.
[21] Hikino H, Yamada T, Johbara K, et al. Potential role of chemo-radiation with oral capecitabine in a breast cancer patient with central nervous system relapse. Breast 2006;15:97-99.
[22] Cocconi G, Lottici R, Bisagni G, et al. Combination therapy with platinum and etoposide of brain metastases from breast carcinoma. Cancer Invest 1990;8:327-334.
[23] Franciosi V, Cocconi G, Michiara M, et al. Front-line chemotherapy with cisplatin and etoposide for patients with brain metastases from breast carcinoma, nonsmall cell lung carcinoma, or malignant melanoma: a prospective study. Cancer 1999;85:1599-1605.
[24] Vinolas N, Graus F, Mellado B, et al. Phase II trial of cisplatinum and etoposide in brain metastases of solid tumors. J Neurooncol 1997;35:145-148.
[25] Lassman AB, Abrey LE, Shah GD, et al. Systemic high-dose intravenous methotrexate for central nervous system metastases. J Neurooncol 2006;78:255-260.
[26] Modi S, Jacot W, Yamashita T, et al. Trastuzumab deruxtecan in previously treated HER2-low advanced breast cancer. N Engl J Med 2022;387:9-20.
[27] Vaz Batista M, Perez-Garcia JM, Garrigos L, et al. The DEBBRAH trial: Trastuzumab deruxtecan in HER2-positive and HER2-low breast cancer patients with leptomeningeal carcinomatosis. Med 2025;6:100502.
[28] Long GV, Trefzer U, Davies MA, et al. Dabrafenib in patients with Val600Glu or Val600Lys BRAF-mutant melanoma metastatic to the brain (BREAK-MB): a multicentre, open-label, phase 2 trial. Lancet Oncol 2012;13:1087-1095.
[29] Falchook GS, Long GV, Kurzrock R, et al. Dabrafenib in patients with melanoma, untreated brain metastases, and other solid tumours: a phase 1 dose-escalation trial. Lancet 2012;379:1893-1901.
[30] Azer MW, Menzies AM, Haydu LE, et al. Patterns of response and progression in patients with BRAF-mutant melanoma metastatic to the brain who were treated with dabrafenib. Cancer 2014;120:530-536.
[31] Davies MA, Saiag P, Robert C, et al. Dabrafenib plus trametinib in patients with BRAFV600-mutant melanoma brain metastases (COMBI-MB): a multicentre, multicohort, open-label, phase 2 trial. Lancet Oncol 2017;18:863-873.
[32] McArthur GA, Maio M, Arance A, et al. Vemurafenib in metastatic melanoma patients with brain metastases: an open-label, single-arm, phase 2, multicentre study. Ann Oncol 2017;28:634-641.
[33] Dummer R, Goldinger SM, Turtschi CP, et al. Vemurafenib in patients with BRAF(V600) mutation-positive melanoma with symptomatic brain metastases: final results of an open-label pilot study. Eur J Cancer 2014;50:611-621.
[34] Tawbi HA, Forsyth PA, Algazi AP, et al. Combined nivolumab and ipilimumab in melanoma metastatic to the brain. N Engl J Med 2018;379:722-730.
[35] Long GV, Atkinson V, Lo S, et al. Combination nivolumab and ipilimumab or nivolumab alone in melanoma brain metastases: a multicentre randomised phase 2 study. Lancet Oncol 2018;19:672-681.
[37] Margolin K, Ernstoff MS, Hamid O, et al. Ipilimumab in patients with melanoma and brain metastases: an open-label, phase 2 trial. Lancet Oncol 2012;13:459-465.

Continued

Note: All recommendations are category 2A unless otherwise indicated.

Version 3.2025, 12/05/25 © 2025 National Comprehensive Cancer Network® (NCCN®), All rights reserved. NCCN Guidelines® and this illustration may not be reproduced in any form without the express written permission of NCCN.

PLEASE NOTE that use of this NCCN Content is governed by the End-User License Agreement, and you MAY NOT distribute this Content or use it with any artificial intelligence model or tool.
Printed by A. S. M. FAZLUL KARIM CHOWDHURY on 4/20/2026 3:06:38 AM. Copyright © 2026 National Comprehensive Cancer Network, Inc. All Rights Reserved.

BRAIN METASTASES: SYSTEMIC THERAPY REFERENCES (CONTINUED)

[36] Long GV, Atkinson V, Lo S, et al. Long-term outcomes from the randomized phase II study of nivolumab or nivolumab + ipilimumab in patients with melanoma brain metastases: Anti-PD-1 Brain Collaboration (the ABC trial). ESMO 2019 Congress.
[37] Margolin K, Ernstoff MS, Hamid O, et al. Ipilimumab in patients with melanoma and brain metastases: an open-label, phase 2 trial. Lancet Oncol 2012;13:459-465.
[38] Goldberg SB, Gettinger SN, Mahajan A, et al. Pembrolizumab for patients with melanoma or non-small-cell lung cancer and untreated brain metastases: early analysis of a non-randomised, open-label, phase 2 trial. Lancet Oncol 2016;17:976-983.
[39] Negrao MV, Spira AI, Heist RS, et al. Intracranial efficacy of adagrasib in patients from the KRYSTAL-1 trial with $KRAS^{G12C}$-mutated non-small-cell lung cancer who have untreated CNS metastases. J Clin Oncol 2023;41:4472-4477.
[40] Jänne PA, Riely GJ, Gadgeel SM, et al. Adagrasib in non-small-cell lung cancer harboring a $KRAS^{G12C}$ mutation. N Engl J Med 2022;387:120-131.
[41] de Langen AJ, Johnson ML, Mazieres J, et al. Sotorasib versus docetaxel for previously treated non-small cell lung cancer with $KRAS^{G12C}$ mutation: a randomised, open-label, phase 3 trial. Lancet 2023;401:733-746.
[42] Dingemans AMC, Syrigos K, Livi L, et al. Intracranial efficacy of sotorasib versus docetaxel in pretreated KRAS G12C-mutated advanced non-small cell lung cancer (NSCLC): Practice-informing data from a global, phase 3, randomized, controlled trial (RCT) [abstract]. J Clin Oncol 2023;41(Suppl):Abstract LBA9016.
[43] Soria JC, Ohe Y, Vansteenkiste J, et al. Osimertinib in untreated EGFR-mutated advanced non-small-cell lung cancer. N Engl J Med 2018;378:113-125.
[44] Goss G, Tsai CM, Shepherd FA, et al. CNS response to osimertinib in patients with T790M-positive advanced NSCLC: pooled data from two phase II trials. Ann Oncol 2018;29:687-693.
[45] Mok TS, Wu YL, Ahn MJ, et al. Osimertinib or platinum-pemetrexed in EGFR T790M-positive lung cancer. N Engl J Med 2017;376:629-640.
[46] Yang JCH, Kim S-W, Kim D-W, et al. Osimertinib in patients with epidermal growth factor receptor mutation-positive non-small-cell lung cancer and leptomeningeal metastases: The BLOOM study. J Clin Oncol 2020;38:538-547.
[47] Cho BC, Lu S, Felip E, et al. Amivantamab plus lazertinib in previously untreated EGFR-mutated advanced NSCLC. N Engl J Med 2024;391:1486-1498.
[48] Passaro A, Wang J, Wang Y, et al. Amivantamab plus chemotherapy with and without lazertinib in EGFR-mutant advanced NSCLC after disease progression on osimertinib: primary results from the phase III MARIPOSA-2 study. Ann Oncol 2024;35:77-90.
[49] Planchard D, Jänne PA, Cheng Y, et al. Osimertinib with or without chemotherapy in EGFR-mutated advanced NSCLC. N Engl J Med 2023;389:1935-1948.
[50] Grommes C, Oxnard GR, Kris MG, et al. "Pulsatile" high-dose weekly erlotinib for CNS metastases from EGFR mutant non-small cell lung cancer. Neuro Oncol 2011;13:1364-1369.
[51] Katayama T, Shimizu J, Suda K, et al. Efficacy of erlotinib for brain and leptomeningeal metastases in patients with lung adenocarcinoma who showed initial good response to gefitinib. J Thorac Oncol 2009;4:1415-1419.
[52] Arbour KC, Kris MG, Riely GJ, et al. Twice weekly pulse and daily continuous-dose erlotinib as initial treatment for patients with epidermal growth factor receptor-mutant lung cancers and brain metastases. Cancer 2018;124:105-109.
[53] Hoffknecht P, Tufman A, Wehler T, et al. Efficacy of the irreversible ErbB family blocker afatinib in epidermal growth factor receptor (EGFR) tyrosine kinase inhibitor (TKI)-pretreated non-small-cell lung cancer patients with brain metastases or leptomeningeal disease. J Thorac Oncol 2015;10:156-163.
[54] Ceresoli GL, Cappuzzo F, Gregorc V, et al. Gefitinib in patients with brain metastases from non-small-cell lung cancer: a prospective trial. Ann Oncol 2004;15:1042-1047.
[55] Wu C, Li YL, Wang ZM, et al. Gefitinib as palliative therapy for lung adenocarcinoma metastatic to the brain. Lung Cancer 2007;57:359-364.
[56] Wolf J, Seto T, Han JY, et al. Capmatinib in MET exon 14-mutated or MET-amplified non-small-cell lung cancer. N Engl J Med 2020;383:944 -957.
[57] Le, X, Sakai H, Felip E, et al. Tepotinib efficacy and safety in patients with MET Exon 14 Skipping NSCLC: Outcomes in patient subgroups from the VISION study with relevance for clinical practice. Clin Cancer Res 2022; 28:1117-1126.
[58] Paik PK, Felip E, Veillon R, et al. Tepotinib in non–small-cell lung cancer with *MET* exon 14 skipping mutations. N Engl J Med 2020; 383:931-943.
[59] Subbiah V, Gainor JF, Oxnard GR, et al. Intracranial efficacy of selpercatinib in RET fusion-positive non-small cell lung cancers on the LIBRETTO-001 trial. Clin Cancer Res 2021;27:4160-4167.
[60] Camidge DR, Kim HR, Ahn MJ, et al. Brigatinib versus crizotinib in ALK-positive non-small-cell lung cancer. N Engl J Med 2018;379:2027-2039.

Note: All recommendations are category 2A unless otherwise indicated.

Continued

Version 3.2025, 12/05/25 © 2025 National Comprehensive Cancer Network® (NCCN®), All rights reserved. NCCN Guidelines® and this illustration may not be reproduced in any form without the express written permission of NCCN.

PLEASE NOTE that use of this NCCN Content is governed by the End-User License Agreement, and you MAY NOT distribute this Content or use it with any artificial intelligence model or tool.
Printed by A. S. M. FAZLUL KARIM CHOWDHURY on 4/20/2026 3:06:38 AM. Copyright © 2026 National Comprehensive Cancer Network, Inc. All Rights Reserved.

BRAIN METASTASES: SYSTEMIC THERAPY REFERENCES (CONTINUED)

[61] Kim DW, Tiseo M, Ahn MJ, et al. Brigatinib in patients with crizotinib-refractory anaplastic lymphoma kinase-positive non-small-cell lung cancer: a randomized, multicenter phase II trial. J Clin Oncol 2017;35:2490-2498.
[62] Shaw AT, Bauer TM, de Marinis F, et al. First-line lorlatinib or crizotinib in advanced ALK-positive lung cancer. N Engl J Med 2020;383:2018-2029.
[63] Peters S, Camidge DR, Shaw AT, et al. Alectinib versus crizotinib in untreated ALK-positive non-small-cell lung cancers. N Engl J Med 2017;377:829-838.
[64] Gandhi L, Ou SI, Shaw AT, et al. Efficacy of alectinib in central nervous system metastases in crizotinib-resistant ALK-positive non-small-cell lung cancer: comparison of RECIST 1.1 and RANO-HGG criteria. Eur J Cancer 2017;82:27-33.
[65] Kim DW, Mehra R, Tan DSW, et al. Activity and safety of ceritinib in patients with ALK-rearranged non-small-cell lung cancer (ASCEND-1): updated results from the multicentre, open-label, phase 1 trial. Lancet Oncol 2016;17:452-463.
[66] Costa DB, Shaw AT, Ou SH, et al. Clinical experience with crizotinib in patients with advanced ALK-rearranged non-small-cell lung cancer and brain metastases. J Clin Oncol 2015;33:1881-1888.
[67] Drilon A, Camidge DR, Lin JJ, et al. Repotrectinib in ROS1 fusion-positive non-small cell lung cancer. N Engl J Med 2024;390:118-131.
[68] Kluger HM, Chiang V, Mahajan A, et al. Long-term survival of patients with melanoma with active brain metastases treated with pembrolizumab on a phase II trial. J Clin Oncol 2019;37:52-60.
[69] Gauvain C, Vauleon E, Chouaid C, et al. Intracerebral efficacy and tolerance of nivolumab in non-small-cell lung cancer patients with brain metastases. Lung Cancer 2018;116:62-66.
[70] Goldman JW, Crino L, Vokes EE, et al. P2.36: Nivolumab (nivo) in patients (pts) with advanced (adv) NSCLC and central nervous system (CNS) metastases (mets). J Thorac Oncol 2016;11:S238-S239.
[71] Rizvi NA, Mazieres J, Planchard D, et al. Activity and safety of nivolumab, an anti-PD-1 immune checkpoint inhibitor, for patients with advanced, refractory squamous non-small-cell lung cancer (CheckMate 063): a phase 2, single-arm trial. Lancet Oncol 2015;16:257-265.
[72] Ahn M-J, Cho BC, Felip E, et al. Tarlatamab for patients with previously treated small-cell lung cancer. N Engl J Med 2023;389:2063-2075.
[73] Bokstein F, Lossos A, Lossos IS, Siegal T. Central nervous system relapse of systemic non-Hodgkin's lymphoma: results of treatment based on high-dose methotrexate combination chemotherapy. Leuk Lymphoma 2002;43:587-593.
[74] Soussain C, Chouquet S, Blonski M, et al. Ibrutinib monotherapy for relapse or refractory primary CNS lymphoma and primary vitreoretinal lymphoma: Final analysis of the phase II 'proof-of-concept' iLOC study by the Lymphoma study association (LYSA) and the French oculo-cerebral lymphoma (LOC) network. Eur J Cancer 2019;117:121-130.
[75] Hirsch L, Chanza NM, Farah S, et al. Clinical activity and safety of cabozantinib for brain metastases in patients with renal cell carcinoma. JAMA Oncol 2021;7:1815-1823.
[76] Jonasch E, Donskov F, Iliopoulos O, et al. Belzutifan for renal cell carcinoma in von Hippel-Lindau disease. N Engl J Med 2021;385:2036-2046.

Note: All recommendations are category 2A unless otherwise indicated.

Version 3.2025, 12/05/25 © 2025 National Comprehensive Cancer Network® (NCCN®), All rights reserved. NCCN Guidelines® and this illustration may not be reproduced in any form without the express written permission of NCCN.

PLEASE NOTE that use of this NCCN Content is governed by the End-User License Agreement, and you MAY NOT distribute this Content or use it with any artificial intelligence model or tool.
Printed by A. S. M. FAZLUL KARIM CHOWDHURY on 4/20/2026 3:06:38 AM. Copyright © 2026 National Comprehensive Cancer Network, Inc. All Rights Reserved.

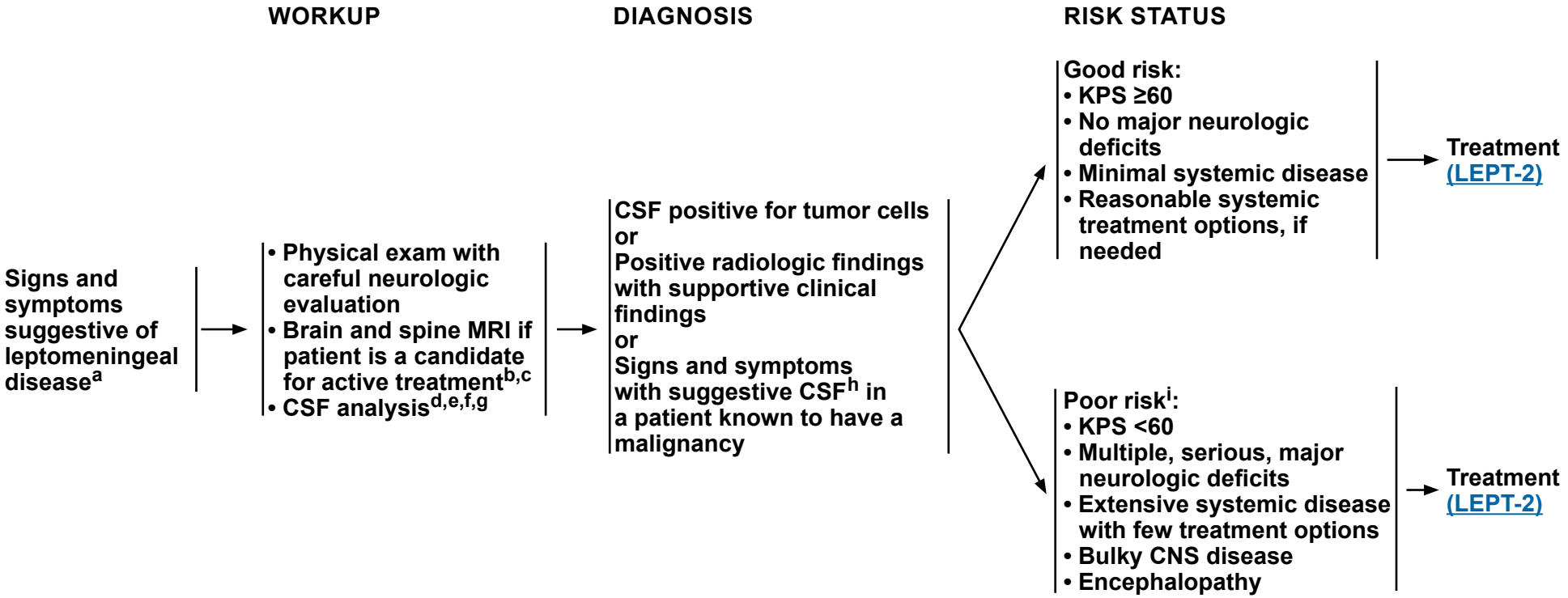

[a] Based on multidisciplinary review for treatment planning, once pathology is available. See Principles of Brain and Spine Tumor Management (BRAIN-D).
[b] Principles of Brain and Spine Tumor Imaging (BRAIN-A).
[c] Lumbar puncture should be done after MRI of spine is performed to avoid a false-positive imaging result.
[d] Caution is indicated in patients who are anticoagulated, thrombocytopenic, or who have a bulky intracranial mass.
[e] When available, assessment of CSF-tDNA increases sensitivity of tumor cell detection and assessment of response to treatment.
[f] Opening pressure should be recorded and consideration should be made of palliative CSF diversion for symptomatic benefit or hydrocephalus.
[g] For patients receiving immunotherapy, CSF sampling rather than just MRI enhancement is suggested as evidence of leptomeningeal metastases, in order to exclude immune-related aseptic meningitis.
[h] Suggestive CSF includes high white blood cell (WBC) count, low glucose, and high protein. If CSF is not positive for tumor cells, a second lumbar puncture is sometimes helpful. This is a volume-dependent test, and ideally ≥10 mL should be sent for cytologic analysis.
[i] Patients with tumors that are highly sensitive to systemic therapy or targeted therapy may be treated. Patients with a good risk status who do not desire further therapy may also be treated with palliative and/or best supportive care. See LEPT-3 for response assessment.

Note: All recommendations are category 2A unless otherwise indicated.

Version 3.2025, 12/05/25 © 2025 National Comprehensive Cancer Network® (NCCN®), All rights reserved. NCCN Guidelines® and this illustration may not be reproduced in any form without the express written permission of NCCN.

PLEASE NOTE that use of this NCCN Content is governed by the End-User License Agreement, and you MAY NOT distribute this Content or use it with any artificial intelligence model or tool.
Printed by A. S. M. FAZLUL KARIM CHOWDHURY on 4/20/2026 3:06:38 AM. Copyright © 2026 National Comprehensive Cancer Network, Inc. All Rights Reserved.

RISK STATUS | **TREATMENT**

Good risk:
- **KPS ≥60**
- **No major neurologic deficits**
- **Minimal systemic disease**
- **Reasonable systemic treatment options, if needed**

→ **Systemic therapy[j]** →

→ **• Intra-CSF therapy[j,k]**
- **If symptoms or imaging suggest CSF flow blockage, perform a CSF flow scan prior to starting intra-CSF therapy**
  If flow abnormalities confirmed:
  - ◊ **Fractionated EBRT[l] to metastatic or painful sites of obstruction and repeat CSF flow scan to see if flow abnormalities have resolved**
    or
  - ◊ **High-dose methotrexate if breast cancer or lymphoma**

→ **• RT[l]**
- **Consider involved-field RT (eg, partial or WBRT, skull base RT, focal spine RT) to bulky disease for focal disease control and to neurologically symptomatic or painful sites**
- **Consider craniospinal irradiation (CSI)[m] for CNS and CSF disease control in select patients with or without symptoms**

→ **Assessment of response (LEPT-3)**

Poor risk:[i]
- **KPS <60**
- **Multiple, serious, major neurologic deficits**
- **Extensive systemic disease with few treatment options**
- **Bulky CNS disease**
- **Encephalopathy**

→ **Palliative/best supportive care**
and
Consider involved-field RTl to neurologically symptomatic or painful sites for palliation (including spine and intracranial disease)

[i] Patients with tumors that are highly sensitive to systemic therapy or targeted therapy may be treated. Patients with a good risk status who do not desire further therapy may also be treated with palliative and/or best supportive care. See LEPT-3 for response assessment.
[j] Leptomeningeal Metastases Systemic Therapy (LEPT-A).
[k] Strongly consider Ommaya reservoir/intraventricular catheter.
[l] Principles of Radiation Therapy for Brain and Spinal Cord (BRAIN-C).
[m] Use of advanced modalities to minimize toxicity, including techniques in maximizing bone marrow sparing, is recommended when considering craniospinal RT (eg, protons when available [Yang JT, et al. J Clin Oncol 2022;40:3858-3867], or conformal photon-based techniques/IMRT). In addition, careful assessment and monitoring of blood counts should be performed given risk of hematologic toxicity.

Note: All recommendations are category 2A unless otherwise indicated.

Version 3.2025, 12/05/25 © 2025 National Comprehensive Cancer Network® (NCCN®), All rights reserved. NCCN Guidelines® and this illustration may not be reproduced in any form without the express written permission of NCCN.

PLEASE NOTE that use of this NCCN Content is governed by the End-User License Agreement, and you MAY NOT distribute this Content or use it with any artificial intelligence model or tool.
Printed by A. S. M. FAZLUL KARIM CHOWDHURY on 4/20/2026 3:06:38 AM. Copyright © 2026 National Comprehensive Cancer Network, Inc. All Rights Reserved.

TREATMENT

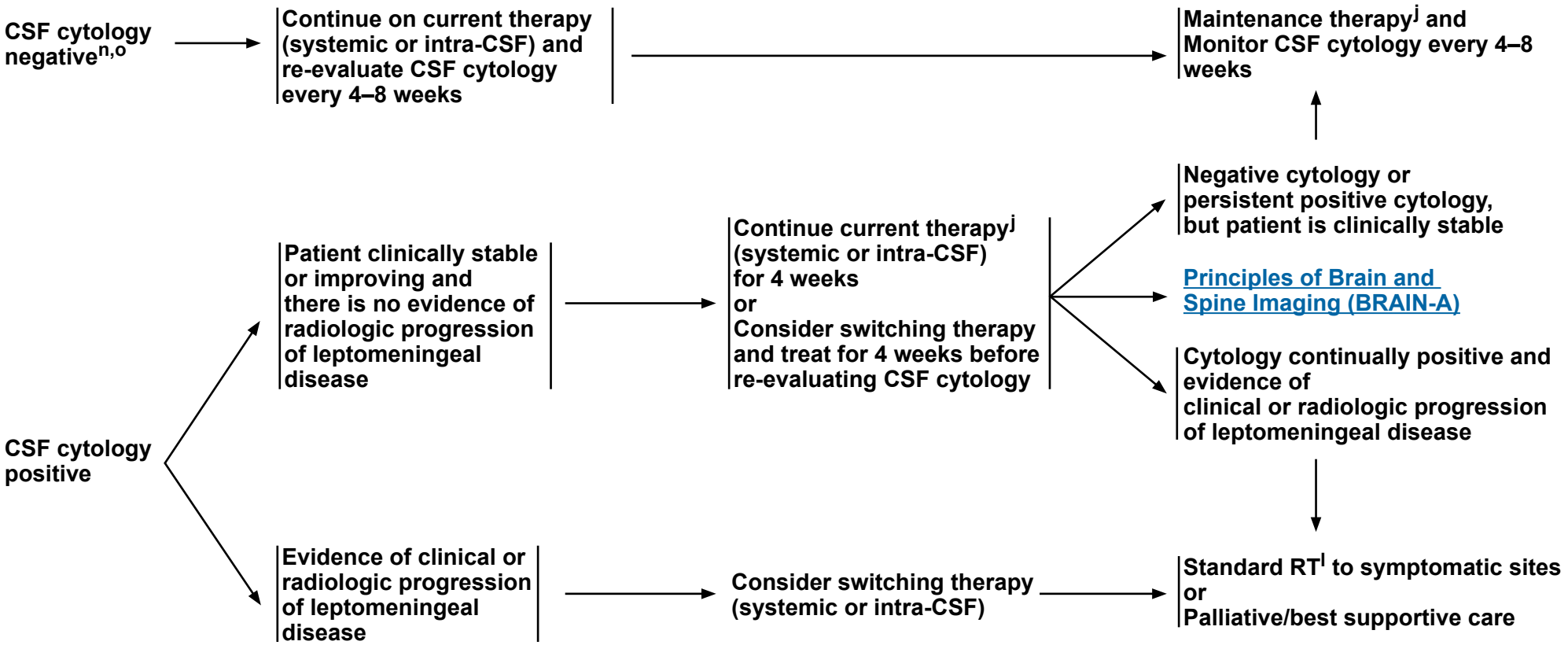

[j] Leptomeningeal Metastases Systemic Therapy (LEPT-A).
[l] Principles of Radiation Therapy for Brain and Spinal Cord (BRAIN-C).
[n] If cytologic analysis is negative from CSF obtained from an Ommaya reservoir, then assess CSF obtained via a lumbar puncture to confirm CSF cytology is negative.
[o] If CSF cytology was initially negative or new/worsening clinical signs/symptoms, then assess response with MRI of spine/brain.

Note: All recommendations are category 2A unless otherwise indicated.

Version 3.2025, 12/05/25 © 2025 National Comprehensive Cancer Network® (NCCN®), All rights reserved. NCCN Guidelines® and this illustration may not be reproduced in any form without the express written permission of NCCN.

PLEASE NOTE that use of this NCCN Content is governed by the End-User License Agreement, and you MAY NOT distribute this Content or use it with any artificial intelligence model or tool.
Printed by A. S. M. FAZLUL KARIM CHOWDHURY on 4/20/2026 3:06:38 AM. Copyright © 2026 National Comprehensive Cancer Network, Inc. All Rights Reserved.

LEPTOMENINGEAL METASTASES: SYSTEMIC THERAPY[a]

- **Treatment**
  - **Systemic therapy specific to primary cancer type; emphasizing drugs with good CNS penetration**
  - **Intra-CSF therapy[1]**
    - ◊ **Other Recommended**
      - – **Temozolomide[2]**
      - – **Thiotepa[3]**
      - – **Topotecan[4]**
      - – **Etoposide[5]**
      - – **Cytarabine[6-9]**
      - – **Methotrexate[8,10-12]**
  - **Lymphoma**
    - ◊ **Intra-CSF therapy**
      - – **Rituximab[7]**
    - ◊ **High-dose methotrexate[b,13]**
  - **Breast cancer**
    - ◊ **Preferred**
      - – **Fam-trastuzumab deruxtecan-nxki[14]**
    - ◊ **Other Recommended**
      - – **Intra-CSF therapy**
        - ▪ **Methotrexate[8,10,11]**
        - ▪ **Trastuzumab[a] (HER2 positive)[15]**
    - ◊ **Useful in Certain Circumstances**
      - – **High-dose methotrexate[b,16,17,18]**
  - **NSCLC**
    - ◊ **Preferred**
      - – **Osimertinib *EGFR* mutation positive[19,20,21]**
    - ◊ **Other Recommended**
      - – **Osimertinib[22] *EGFR* mutation positive (double dose)**
      - – **Weekly pulse erlotinib *EGFR* exon 19 deletion or exon 21 L858R mutation (category 2B)[23]**
      - – **Intrathecal (IT) pemetrexed *EGFR* mutation positive[24,25]**
    - ◊ **Useful in Certain Circumstances**
      - – **Tepotinib[26] (*MET* exon 14 mutated)**
  - **Melanoma**
    - ◊ **Useful in Certain Circumstances**
      - – **IT and intravenous (IV) nivolumab[c] (category 2B)[27]**

[a] An FDA-approved biosimilar is an appropriate substitute for any recommended systemic biologic therapy in the NCCN Guidelines.
[b] Consider glucarpidase (carboxypeptidase G2) for prolonged methotrexate clearance due to methotrexate-induced renal toxicity. Ramsey LB, Balis FM, O'Brien MM, et al. Consensus guideline for use of glucarpidase in patients with high-dose methotrexate induced acute kidney injury and delayed methotrexate clearance. Oncologist 2018;23:52-61.
[c] Nivolumab and hyaluronidase-nvhy subcutaneous injection may be substituted for IV nivolumab. Nivolumab and hyaluronidase-nvhy has different dosing and administration instructions compared to IV nivolumab.

Continued

Note: All recommendations are category 2A unless otherwise indicated.

Version 3.2025, 12/05/25 © 2025 National Comprehensive Cancer Network® (NCCN®), All rights reserved. NCCN Guidelines® and this illustration may not be reproduced in any form without the express written permission of NCCN.

PLEASE NOTE that use of this NCCN Content is governed by the End-User License Agreement, and you MAY NOT distribute this Content or use it with any artificial intelligence model or tool.
Printed by A. S. M. FAZLUL KARIM CHOWDHURY on 4/20/2026 3:06:38 AM. Copyright © 2026 National Comprehensive Cancer Network, Inc. All Rights Reserved.

LEPTOMENINGEAL METASTASES: SYSTEMIC THERAPY
REFERENCES

[1] Chamberlain MC. Leptomeningeal metastasis. Curr Opin Neurol 2009;22:665-674.
[2] Segura PP, Gil M, Balañá C, et al. Phase II trial of temozolomide for leptomeningeal metastases in patients with solid tumors. J Neurooncol 2012;109:137-142.
[3] Gutin PH, Weiss HD, Wiernik PH, Walker MD. Intrathecal N, N', N"-triethylenethiophosphoramide [thio-TEPA (NSC 6396)] in the treatment of malignant meningeal disease: phase I-II study. Cancer 1976;38:1471-1475.
[4] Groves MD, Glantz MJ, Chamberlain MC, et al. A multicenter phase II trial of intrathecal topotecan in patients with meningeal malignancies. Neuro Oncol 2008;10:208-215.
[5] Chamberlain MC, Tsao-Wei DD, Groshen S. Phase II trial of intracerebrospinal fluid etoposide in the treatment of neoplastic meningitis. Cancer 2006;106:2021-2027.
[6] Jaeckle KA, Phuphanich S, Bent MJ, et al. Intrathecal treatment of neoplastic meningitis due to breast cancer with a slow-release formulation of cytarabine. Br J Cancer 2001;84:157-163.
[7] Chamberlain MC, Johnston SK, Van Horn A, Glantz MJ. Recurrent lymphomatous meningitis treated with intra-CSF rituximab and liposomal ara-C. J Neurooncol 2009;91:271-277.
[8] Glantz MJ, Jaeckle KA, Chamberlain MC, et al. A randomized controlled trial comparing intrathecal sustained-release cytarabine (DepoCyt) to intrathecal methotrexate in patients with neoplastic meningitis from solid tumors. Clin Cancer Res 1999;5:3394-3402.
[9] Glantz MJ, LaFollette S, Jaeckle KA, et al. Randomized trial of a slow-release versus a standard formulation of cytarabine for the intrathecal treatment of lymphomatous meningitis. J Clin Oncol 1999;17:3110-3116.
[10] Grossman SA, Finkelstein DM, Ruckdeschel JC, et al. Randomized prospective comparison of intraventricular methotrexate and thiotepa in patients with previously untreated neoplastic meningitis. Eastern Cooperative Oncology Group. J Clin Oncol 1993;11:561-569.
[11] Hitchins RN, Bell DR, Woods RL, Levi JA. A prospective randomized trial of single-agent versus combination chemotherapy in meningeal carcinomatosis. J Clin Oncol 1987;5:1655-1662.
[12] Ziegler JL, Bluming AZ. Intrathecal chemotherapy in Burkitt's lymphoma. Br Med J 1971;3:508-512.
[13] Bokstein F, Lossos A, Lossos IS, Siegal T. Central nervous system relapse of systemic non-Hodgkin's lymphoma: results of treatment based on high-dose methotrexate combination chemotherapy. Leuk Lymphoma 2002;43:587-593.
[14] Alder L, Trapani D, Bradbury C, et al. Durable responses in patients with HER2+ breast cancer and leptomeningeal metastases treated with trastuzumab deruxtecan. NPJ Breast Cancer. 2023 9:19.
[15] Zagouri F, Sergentanis TN, Bartsch R, et al. Intrathecal administration of trastuzumab for the treatment of meningeal carcinomatosis in HER2-positive metastatic breast cancer: a systematic review and pooled analysis. Breast Cancer Res Treat 2013;139:13-22.
[16] Glantz MJ, Cole BF, Recht L, et al. High-dose intravenous methotrexate for patients with nonleukemic leptomeningeal cancer: is intrathecal chemotherapy necessary? J Clin Oncol 1998;16:1561-1567.
[17] Mrugala MM, Kim B, Sharma A, et al. Phase II study of systemic high-dose methotrexate and intrathecal liposomal cytarabine for treatment of leptomeningeal carcinomatosis from breast cancer. Clin Breast Cancer 2019;19:311-316.
[18] Lassman AB, Abrey LE, Shah GD, et al. Systemic high-dose intravenous methotrexate for central nervous system metastases. J Neurooncol 2006;78:255-260.
[19] Nanjo S, Hata A, Okuda C, et al. Standard-dose osimertinib for refractory leptomeningeal metastases in T790M-positive EGFR-mutant non-small cell lung cancer. Br J Cancer 2018;118:32-37.
[20] Peled N, Kian W, Inbar E, et al. Osimertinib in advanced EGFR-mutant lung adenocarcinoma with asymptomatic brain metastases: an open-label, 3-arm, phase II pilot study. Neurooncol Adv 2021;4:vdab188.
[21] Park S, Baldry R, Jung HA, et al. Phase II efficacy and safety of 80 mg osimertinib in patients with leptomeningeal metastases associated with epidermal growth factor receptor mutation-positive non-small cell lung cancer (BLOSSOM). J Clin Oncol 2024;42:2747-2756.
[22] Yang JCH, Kim S-W, Kim D-W, et al. Osimertinib in patients with epidermal growth factor receptor mutation-positive non-small-cell lung cancer and leptomeningeal metastases: the BLOOM study. J Clin Oncol 2020;38:538-547.
[23] Grommes C, Oxnard GR, Kris MG, et al. "Pulsatile" high-dose weekly erlotinib for CNS metastases from EGFR mutant non-small cell lung cancer. Neuro Oncol 2011;13:1364-1369.
[24] Fan C, Zhao Q, Li L, et al. Efficacy and safety of intrathecal pemetrexed combined with dexamethasone for treating tyrosine kinase inhibitor-failed leptomeningeal metastases from EGFR-mutant NSCLC—a prospective, open-label, single-arm phase 1/2 clinical trial (Unique Identifier:ChiCTR1800016615). J Thorac Oncol 2021;16:1359-1368.
[25] Pan Z, Yang G, Cui J, et al. A pilot phase 1 study of intrathecal pemetrexed for refractory leptomeningeal metastases from non-small-cell lung cancer. Front Oncol 2019;30:9:838.
[26] Tanaka H, Taima K, Makiguchi T, et al. Activity and bioavailability for tepotinib for leptomeningeal metastasis of NSCLC with MET exon 14 skipping mutation. Cancer Commun (Lond) 2021;41:83-87.
[27] Glitza Oliva IC, Ferguson SD, Bassett R Jr, et al. Concurrent intrathecal and intravenous nivolumab in leptomeningeal disease: phase 1 trial interim results. Nat Med 2023;29:898-905.

Note: All recommendations are category 2A unless otherwise indicated.

Version 3.2025, 12/05/25 © 2025 National Comprehensive Cancer Network® (NCCN®), All rights reserved. NCCN Guidelines® and this illustration may not be reproduced in any form without the express written permission of NCCN.

PLEASE NOTE that use of this NCCN Content is governed by the End-User License Agreement, and you MAY NOT distribute this Content or use it with any artificial intelligence model or tool.
Printed by A. S. M. FAZLUL KARIM CHOWDHURY on 4/20/2026 3:06:38 AM. Copyright © 2026 National Comprehensive Cancer Network, Inc. All Rights Reserved.

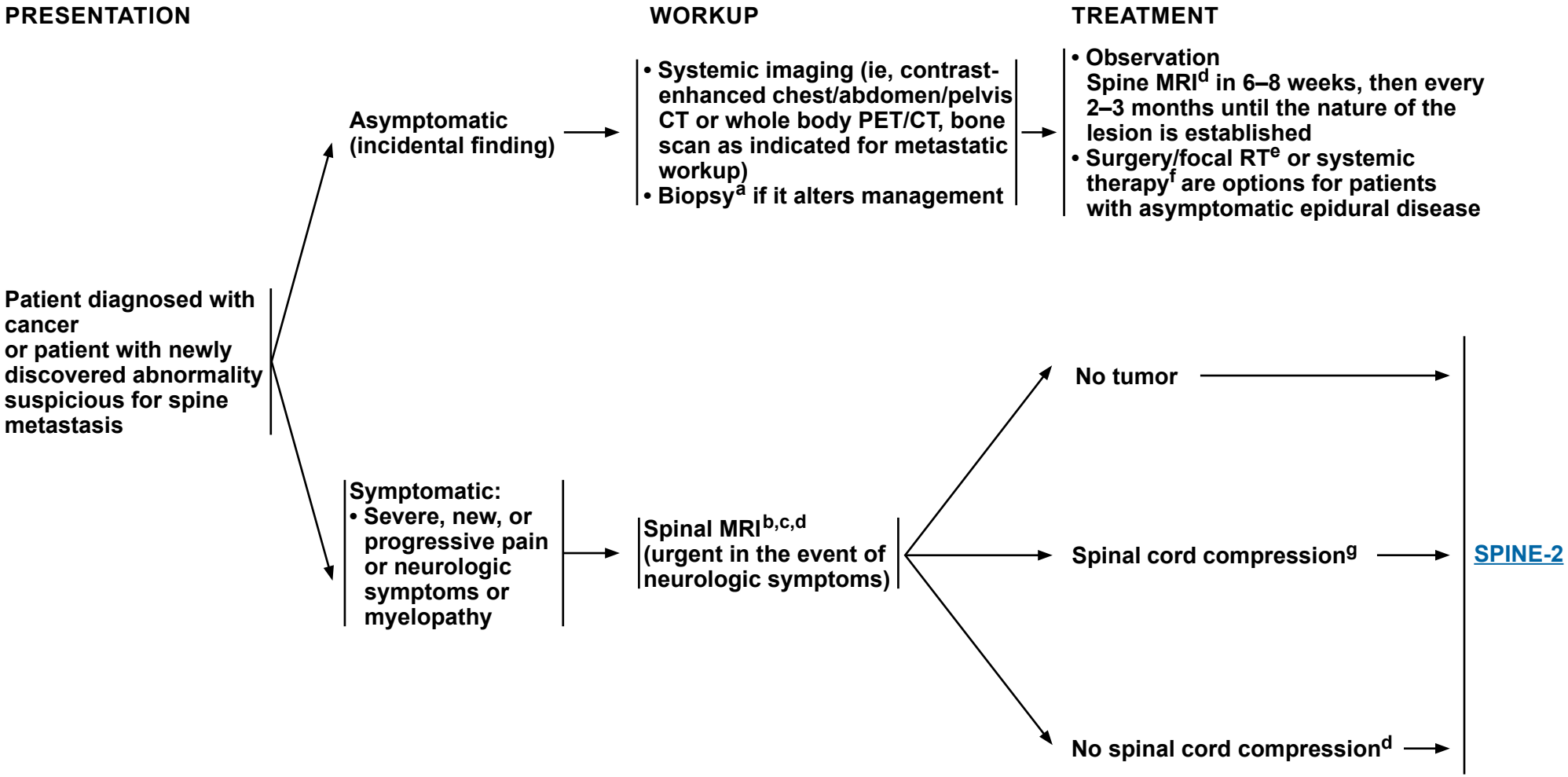

[a] Biopsy if remote history of cancer.
[b] If the patient is unable to have an MRI, then a CT myelogram is recommended, which may also be useful for RT planning.
[c] 15%–20% of patients have additional lesions. Highly recommend complete spine imaging.
[d] Principles of Brain and Spine Tumor Imaging (BRAIN-A).
[e] Principles of Radiation Therapy for Brain and Spinal Cord (BRAIN-C).
[f] Use regimen for disease-specific site.
[g] Includes cauda equina syndrome.

Note: All recommendations are category 2A unless otherwise indicated.

Version 3.2025, 12/05/25 © 2025 National Comprehensive Cancer Network® (NCCN®), All rights reserved. NCCN Guidelines® and this illustration may not be reproduced in any form without the express written permission of NCCN.

PLEASE NOTE that use of this NCCN Content is governed by the End-User License Agreement, and you MAY NOT distribute this Content or use it with any artificial intelligence model or tool.
Printed by A. S. M. FAZLUL KARIM CHOWDHURY on 4/20/2026 3:06:38 AM. Copyright © 2026 National Comprehensive Cancer Network, Inc. All Rights Reserved.

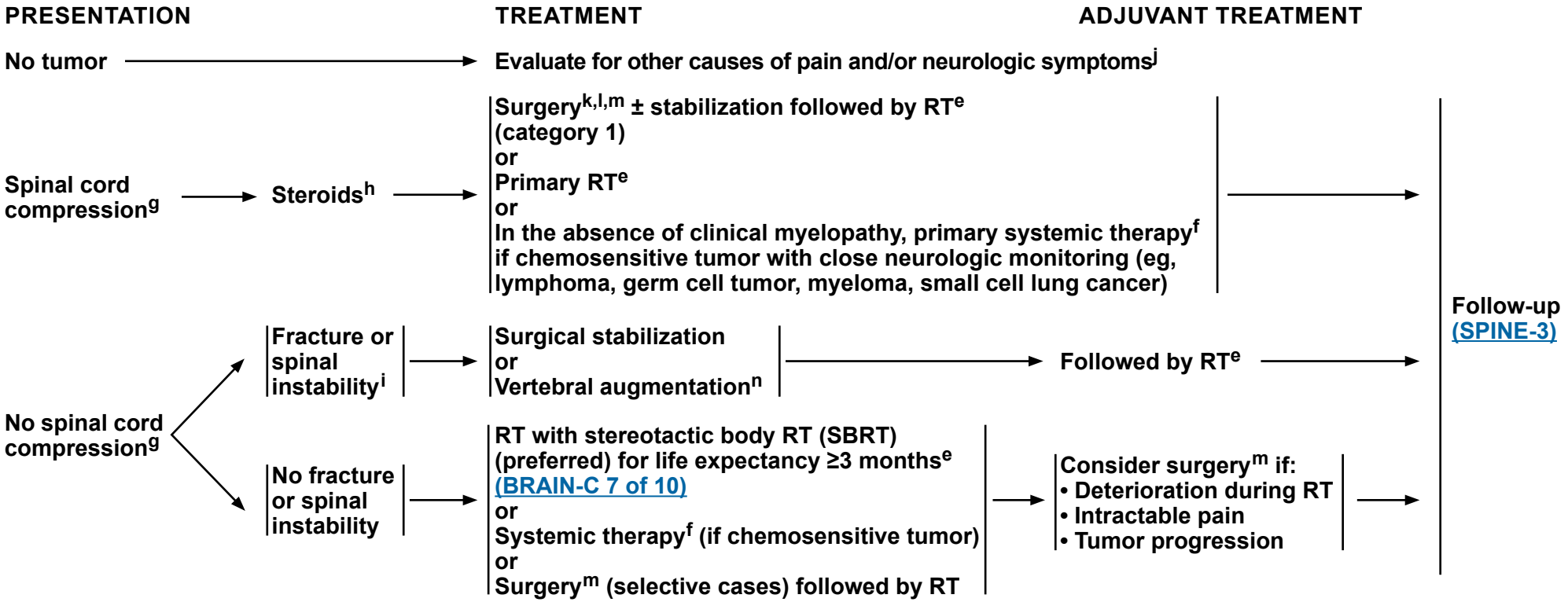

[e] Principles of Radiation Therapy for Brain and Spinal Cord (BRAIN-C).
[f] Use regimen for disease-specific site.
[g] Includes cauda equina syndrome.
[h] The recommended minimum dose of steroids is 4 mg of dexamethasone every 6 hours, although dose of steroids may vary (10–100 mg). A randomized trial supported the use of high-dose steroids (Sorensen S, et al. Eur J Cancer 1994;30A:22-27).
[i] Spinal instability is grossly defined as the presence of significant kyphosis or subluxation (deformity), or of significantly retropulsed bone fragment and may be evaluated using the Spinal Instability Neoplastic Score (Versteeg AL, et al. Spine 2016;41:S231-S237).
[j] Consider alternative diagnosis of leptomeningeal disease (LEPT-1). Questions of spine stability should be determined in consultation with a spinal surgeon.
[k] Tumor resection with or without spinal stabilization. Surgery should be focused on anatomic pathology.
[l] Regarding surgery, note the following:
- Category 1 evidence supports the role of surgery in patients with a solitary epidural spinal cord compression by a tumor not known to be radiosensitive and who are willing to undergo surgery (Patchell RA, et al. Lancet 2005;366:643-648).
- For surgery, patients with hematologic tumors (ie, lymphoma, myeloma, leukemia) should be excluded, life expectancy should be ≥3 months, and the patient should not be paraplegic for >24 hours.
- Surgery is especially indicated if the patient has any of the following: spinal instability, no history of cancer, rapid neurologic deterioration during RT, previous RT to site, and single-site spinal cord compression.

[m] Postoperative spine MRI should be delayed by at least 2–3 weeks to avoid post-surgical artifacts. See Principles of Surgery (BRAIN-B).
[n] Vertebral augmentation: vertebroplasty, kyphoplasty.

Note: All recommendations are category 2A unless otherwise indicated.

Version 3.2025, 12/05/25 © 2025 National Comprehensive Cancer Network® (NCCN®), All rights reserved. NCCN Guidelines® and this illustration may not be reproduced in any form without the express written permission of NCCN.

PLEASE NOTE that use of this NCCN Content is governed by the End-User License Agreement, and you MAY NOT distribute this Content or use it with any artificial intelligence model or tool.
Printed by A. S. M. FAZLUL KARIM CHOWDHURY on 4/20/2026 3:06:38 AM. Copyright © 2026 National Comprehensive Cancer Network, Inc. All Rights Reserved.

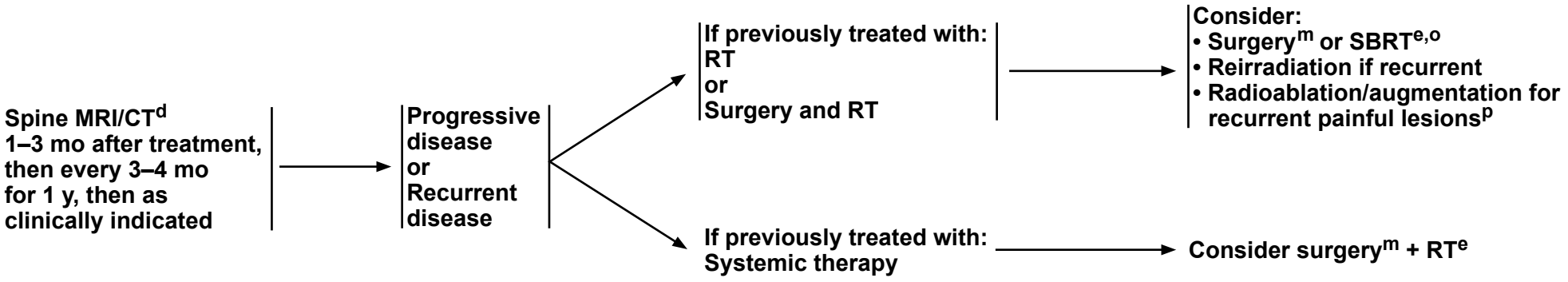

[d] Principles of Brain and Spine Tumor Imaging (BRAIN-A).
[e] Principles of Radiation Therapy for Brain and Spinal Cord (BRAIN-C).
[m] Postoperative spine MRI should be delayed by at least 2–3 weeks to avoid post-surgical artifacts. See Principles of Surgery (BRAIN-B).
[o] Garg AK, et al. Cancer 2011;117:3509-3516.
[p] Bagla S, et al. Cardiovasc Intervent Radiol 2016;39:1289-1297.

Note: All recommendations are category 2A unless otherwise indicated.

Version 3.2025, 12/05/25 © 2025 National Comprehensive Cancer Network® (NCCN®), All rights reserved. NCCN Guidelines® and this illustration may not be reproduced in any form without the express written permission of NCCN.

PLEASE NOTE that use of this NCCN Content is governed by the End-User License Agreement, and you MAY NOT distribute this Content or use it with any artificial intelligence model or tool.
Printed by A. S. M. FAZLUL KARIM CHOWDHURY on 4/20/2026 3:06:38 AM. Copyright © 2026 National Comprehensive Cancer Network, Inc. All Rights Reserved.

PRINCIPLES OF BRAIN AND SPINE TUMOR IMAGING[1]

- **Neuroimaging techniques are crucial for diagnosis, treatment planning, management decisions, and post-treatment cancer surveillance in the CNS. MRI is the standard modality utilized for all stages of CNS cancer management in patients without contraindications and is usually also recommended to investigate emergent/unexpected signs and symptoms. The most common use for "advanced" neuroimaging tools such as magnetic resonance spectroscopy (MRS), magnetic resonance (MR) perfusion, and PET scanning is to differentiate radiation necrosis from active tumor, as this might obviate the need for surgery or the discontinuation of an effective therapy.**

Magnetic Resonance Imaging (MRI)

- **MRI remains the standard-of-care imaging method for patients with any CNS neoplasm,[1] predominantly due to its superior soft tissue contrast compared to other modalities, which enables greatest sensitivity for detection and specificity for characterization of brain and spine tumors.[2]**
- **MRI is notably unable to identify the full microscopic extent of infiltrating intra-axial CNS neoplasms, such as gliomas. However, it provides the most comprehensive determination of the extent of disease compared to other clinically available imaging modalities and is reasonably accurate in predicting the biological behavior (aggressiveness). It also has a critical role in the noninvasive determination of CNS spread of neoplasms, being the most sensitive noninvasive imaging modality to detect tumor multifocality and CSF spread of neoplasms.**
- **MRI is recommended for every patient with a known or suspected CNS neoplasm at diagnosis, prior to a treatment intervention such as surgery, radiation, or chemotherapy to serve as a baseline, and for post-treatment imaging surveillance,[1] unless a contraindication to MRI is present.[3] The frequency of imaging recommendations for some common brain neoplasms is provided at the end of this section. Otherwise, guidance is provided disease-specific page. Since a range of imaging frequency is provided, it is important that the treating physician be given the flexibility to determine the frequency of imaging that is appropriate for specific patients.**

MRI Contrast Agents

- **With very few exceptions, MRI of the CNS for neuro-oncology purposes should always be performed with and without IV injection of a gadolinium-based contrast agent (GBCA).**
- **The main relative contraindications to GBCAs include pregnancy and prior allergic reactions. Interaction with some metallic devices or objects are contraindications to MRI in general, not contrast agents, and is discussed in a subsequent section.**
- **GBCAs and allergic-like reactions: Patients can develop allergic-like hypersensitivity reactions to GBCAs. Premedication to prevent these reactions and/or switching to another GBCA product are general recommendations. Protocols to obtain contrast-enhanced MRI in patients with prior GBCAs allergic-like reactions are usually in place at radiology facilities and should be followed accordingly.**
- **GBCAs and nephrogenic systemic fibrosis (NSF): GBCAs have been in clinical practice since the 1980s and have an extremely safe track record in the vast majority of patients with a very low rate of acute adverse reactions (0.07–2.4%).[4] However, in 2006, a causative link was found between some GBCAs and NSF, a debilitating disease seen in patients with end-stage renal disease and GBCAs exposure, which led institutions to screen for renal function before administration of GBCAs. Most recent scientific and clinical evidence demonstrates that NSF is associated with a specific subgroup of GBCAs. The American College of Radiology Committee on Drugs and Contrast Media considers that "the risk of NSF among patients exposed to standard or lower than standard doses of group II GBCAs is sufficiently low or possibly nonexistent such that assessment of renal function with a questionnaire or laboratory testing is optional prior to intravenous administration."[4] Given the crucial importance of GBCAs for oncology purposes, end-stage renal disease should not be a contraindication to GBCAs in most patients receiving group II agents.**

Continued

Note: All recommendations are category 2A unless otherwise indicated.

Version 3.2025, 12/05/25 © 2025 National Comprehensive Cancer Network® (NCCN®), All rights reserved. NCCN Guidelines® and this illustration may not be reproduced in any form without the express written permission of NCCN.

PLEASE NOTE that use of this NCCN Content is governed by the End-User License Agreement, and you MAY NOT distribute this Content or use it with any artificial intelligence model or tool.
Printed by A. S. M. FAZLUL KARIM CHOWDHURY on 4/20/2026 3:06:38 AM. Copyright © 2026 National Comprehensive Cancer Network, Inc. All Rights Reserved.

PRINCIPLES OF BRAIN AND SPINE TUMOR IMAGING[1]

MRI Contrast Agents (continued)

- **GBCA Retention: It is widely accepted that small amounts of GBCAs are retained in body tissues after each parenteral administration. Trace amounts of GBCAs have been identified in several body organs, including the CNS, bones, skin, and liver.[5] However, the percent of accumulation appears to be extremely low[5,6] and to date, there is no evidence of scientifically confirmed adverse effects to patients at normal clinical doses.[7] Given the crucial importance of GBCAs for diagnostic and surveillance purposes in neuro-oncology, the benefits of contrast-enhanced MRI far outweigh the theoretical risks of gadolinium retention.**

MRI Safety Concerns and Contraindications

- **MRI scanners may be associated with significant health risks to patients as a result of the use of a very powerful magnet, radiofrequency pulses, and gradient coils. However, when used properly by appropriately trained personnel and established safety procedures, MRI is an imaging modality with an extremely favorable safety track record. One of the most important steps for the safe performance of MRI studies is a safety screening step to detect the presence of objects or devices in the patient's body prior to each study. These are classified as MR Safe, MR Conditional, and MR Unsafe.[3] MR Unsafe objects/devices are typically metallic materials with ferromagnetic properties or electrical conductivity. The interaction of these objects with the equipment can generate torque/displacement, heating, organ stimulation, or damage to some electromagnetic devices with loss of function.**
- **Absolute contraindications for MRI include ferromagnetic aneurysm clips and foreign bodies in critical locations such as the eye and CNS. However, several implantable devices (such as pacemakers, stimulators, and others) may or may not be MRI Safe and require specific MRI safety evaluation. In case of relative contraindications, the treatment team and MRI experts should perform a risk-versus-benefit evaluation to determine the appropriateness of MRI or selection of a different imaging modality. As mentioned previously, given the crucial importance of MRI scans for neuro-oncology patients, all efforts should be made to perform an appropriate safety evaluation and prevent patients from losing access to MR scans.**
- **MRI scans in patients with ventricular shunts: It is relatively common for patients with brain tumors to have ventricular shunts to manage obstructive or communicating hydrocephalus. The overwhelming majority of ventricular shunts can be safely imaged on MRI and do not pose a contraindication. However, programmable ventricular shunts typically require special procedures[8] to prevent unintentional modification of shunt settings resulting from the interaction of the MRI magnet with the shunt electronics. Some patients may require evaluation of shunt settings by radiographs before and after the MRI procedure to document lack of such interference. Treatment teams should consult with their local MRI experts to ensure safe MRI scanning in these patients.**

MRI Scanning Protocols

- **There is no universally agreed upon or minimally required MRI protocol recommendation for patients with CNS tumors, and a fair amount of variation exists in clinical practice determined by local expertise and preferences. However, most centers currently utilize a minimum protocol that consists of at least T2-weighted imaging fluid-attenuated inversion recovery (T2WI-FLAIR), conventional T2WI, gradient echo (T2*) or susceptibility-weighted imaging (SWI), pre- and post-contrast T1-weighted imaging (T1WI), and diffusion-weighted imaging (DWI) for brain tumors. Some centers also utilize "advanced" MRI approaches such as dynamic susceptibility contrast (DSC), dynamic contrast enhancement or arterial spin-labeled perfusion, single- or multi-voxel spectroscopy, and other more experimental or less established MRI techniques. In recent years, expert consensus recommendations have emerged for standardized MRI protocols for primary brain tumors[9] and brain metastases,[10] with recommendations including "minimum" and "ideal" or "recommended" protocols for 1.5T and 3.T magnets. Although these recommendations are mainly proposed to reduce variability in multicenter clinical trials, they are also encouraged to be used in routine clinical practice to facilitate interinstitutional comparisons.[9]**
- **There are no current formal recommendations for standardized protocols for spinal tumors, but a general accepted minimum includes multiplanar (sagittal and axial) evaluation utilizing conventional T2WI, short tau inversion recovery (STIR) or fat-suppressed TW2I, and pre- and post-contrast T1WI imaging.**

Continued

Note: All recommendations are category 2A unless otherwise indicated.

Version 3.2025, 12/05/25 © 2025 National Comprehensive Cancer Network® (NCCN®), All rights reserved. NCCN Guidelines® and this illustration may not be reproduced in any form without the express written permission of NCCN.

PLEASE NOTE that use of this NCCN Content is governed by the End-User License Agreement, and you MAY NOT distribute this Content or use it with any artificial intelligence model or tool.
Printed by A. S. M. FAZLUL KARIM CHOWDHURY on 4/20/2026 3:06:38 AM. Copyright © 2026 National Comprehensive Cancer Network, Inc. All Rights Reserved.

PRINCIPLES OF BRAIN AND SPINE TUMOR IMAGING[1]

MR Perfusion

- MR perfusion techniques are commonly used as part of the imaging evaluation of brain tumors for diagnosis and treatment surveillance. While initially considered experimental, restricted to clinical trials and academic centers, these imaging tools are becoming more widely available and increasingly used.[11] MR perfusion can provide useful information about biological aggressiveness in some subtypes of gliomas, identify targets for stereotactic or open biopsy, and help differentiate viable/progressive hypervascular tumors from hypovascular treatment-related changes (pseudoprogression). However, there are limitations, and interpretations require consideration of other imaging and clinical data.
- Dynamic susceptibility contrast (DSC) perfusion is by far the most commonly available and used method, relies on T2* (susceptibility) effects generated by the bolus passage of a GBCA through the brain and tumor vessels, and provides main estimate measurements of brain tumor volume and blood flow. The main advantages of DSC include its widespread availability, high signal-to-noise ratio, familiarity among MRI practitioners, and more robust body of validating literature.[11] The main disadvantages include dependence on contrast injection and variabilities/artifacts caused by rates of contrast agent injection and extravasation. DSF perfusion is also limited in small lesions, lesions adjacent to large vessels, near bone/air interfaces, surgical fixation devices, and lesions adjacent to the skull base or in the spine. The use of DSC perfusion MRI is encouraged in brain tumor protocols with adherence to recommended standardized protocols for optimal image quality and decreased interinstitutional variability.[12]
- Dynamic contrast-enhanced (DCE) perfusion relies on dynamic T1-weighted signal after injection of a contrast agent and is a less popular method due to the requirements of longer imaging time, more complex post processing, and interpretation. It is also known as "permeability"[13] MRI, but depends on a mixture of different physiological properties, including blood flow, permeability, and extravascular/extracellular space ratio. The main advantage is decreased sensitivity to susceptibility effects; it is usually most useful in patients with non-diagnostic DSC due to artifacts or other limitations.
- Arterial spin labeling (ASL) perfusion is a relatively more recent method that utilizes endogenous signals from moving blood to provide perfusion information (blood flow) without need of an exogenous contrast agent, which is its most notable advantage.[13] The main disadvantages include lack of widespread availability in clinical centers, long scanning times, reduced resolution, relatively limited validation studies,[14] and lack of familiarity among practitioners. ASL is less sensitive than DSC to susceptibility and macrovascular artifacts and should be considered in patients with tumors suboptimally evaluated by DSC or who have contraindications to GBCAs.

MR Spectroscopy (MRS)

- MRS allows detection and measurement of some specific metabolites within tumors and normal brain tissue. It has been successfully used in neuro-oncology for prediction of tumor grade, selection of biopsy sites, and differentiation of viable/progressive tumors from treatment-related changes. It is currently not used or recommended for routine brain tumor imaging, mainly due to its additional imaging time requirements, variability of data acquisition, and interpretation, which limits its more widespread use. It is also limited to specific anatomical regions of the brain, with poor results in tumors adjacent to osseous or air structures, within the posterior fossa or spine. It also provides limited results in small, hemorrhagic or cystic/necrotic lesions. MRS is currently used mainly to provide additional diagnostic information in selected cases when other imaging modalities are inconclusive, and MRS results should be interpreted with caution, taking account other clinical and imaging findings.

Continued

Note: All recommendations are category 2A unless otherwise indicated.

Version 3.2025, 12/05/25 © 2025 National Comprehensive Cancer Network® (NCCN®), All rights reserved. NCCN Guidelines® and this illustration may not be reproduced in any form without the express written permission of NCCN.

PLEASE NOTE that use of this NCCN Content is governed by the End-User License Agreement, and you MAY NOT distribute this Content or use it with any artificial intelligence model or tool.
Printed by A. S. M. FAZLUL KARIM CHOWDHURY on 4/20/2026 3:06:38 AM. Copyright © 2026 National Comprehensive Cancer Network, Inc. All Rights Reserved.

PRINCIPLES OF BRAIN AND SPINE TUMOR IMAGING[1]

MR Spectroscopy (MRS) (continued)

- **More recently, MRS has been used to identify and estimate the tissue concentration of 2-hydroxyglutarate (2HG),[15-18] a metabolite that accumulates in tumors harboring mutations in the *IDH* genes. Given the crucial role of *IDH* mutations for classification, prognostication, and management decisions for gliomas, the use of MRS for noninvasive detection and quantification of 2HG clinically has gained traction in some academic centers.[17,18] However, several barriers exist for multicenter validation and routine clinical adoption of 2HG MRS, including specialized requirements for data acquisition, post processing and interpretation, and feasibility only in a subset of tumors with favorable anatomical location and features. Ongoing technical developments may help overcome these limitations in the future.**

Functional MRI (fMRI)

- **fMRI is a tool which allows indirect mapping of brain neuronal activity based on vascular changes which occur in response to neuronal activity, namely, variations in the concentration of deoxyhemoglobin. It uses fast, dynamic MRI sequences without the need of an exogenous contrast agent. It is used primarily as a precraniotomy or pre-surgery planning tool, as it allows for the non-invasive study of eloquent regions of the brain and their relationship to tumors in individual patients. fMRI is most commonly performed as a "task based" study, requiring patients to be trained to perform specific tasks or "paradigms" while on the MRI scanner, such as motor, sensory, visual and language tasks. Therefore, patients with more advanced neurological deficits may not be good candidates. Although the use of fMRI outside of academic medical centers has increased over the last years, it is still not widely available in the community due to more advanced requirements in expertise, post processing and analysis.**

Computed Tomography (CT)

- **CT should be considered as an alternative imaging technique predominantly in patients with formal contraindications to MRI (see section above) or who are unable to tolerate it (eg, severe cases of claustrophobia). Claustrophobia in MRI can be commonly managed by patient imaging in wider and shorter bore scanners, patient reassurance, and sedation, but more significant cases may require anesthesia or use of CT when the sedation risks outweigh the benefits. CT should be performed with and without contrast when substituting MRI in patients with contraindications. CT is also commonly used in emergency room or inpatient settings in patients with rapid change in neurological status in which a complication such as intracranial hemorrhage, hydrocephalus, or herniation is suspected.**

Positron Emission Tomography (PET)

- **In addition to MRI, various PET tracers for neuroimaging can provide valuable information in the differential diagnosis, delineation of tumor extent, prognostication, differentiation between tumor recurrence and treatment-related changes, and evaluation of response to anticancer therapies.[19-22] Multimodality imaging with either PET/CT or PET/MRI are both acceptable and dependent on center availability. PET/MRI has certain advantages, including 1) decreased dose of radiation; 2) reduced number of imaging sessions with simultaneous acquisition; and 3) improved soft tissue definition.[23] At centers without PET/MRI, consideration should be given to the post-fusion PET portion of PET/CT with MRI if performed within a reasonable timeframe of each other.**

Continued

Note: All recommendations are category 2A unless otherwise indicated.

Version 3.2025, 12/05/25 © 2025 National Comprehensive Cancer Network® (NCCN®), All rights reserved. NCCN Guidelines® and this illustration may not be reproduced in any form without the express written permission of NCCN.

PLEASE NOTE that use of this NCCN Content is governed by the End-User License Agreement, and you MAY NOT distribute this Content or use it with any artificial intelligence model or tool.
Printed by A. S. M. FAZLUL KARIM CHOWDHURY on 4/20/2026 3:06:38 AM. Copyright © 2026 National Comprehensive Cancer Network, Inc. All Rights Reserved.

PRINCIPLES OF BRAIN AND SPINE TUMOR IMAGING[1]

Radiolabeled Somatostatin Receptor (SSTR) Ligand PET/CT or PET/MRI in Meningiomas

- **Meningiomas overexpress somatostatin receptors (SSTRs) and allow for visualization of meningiomas using radiolabeled SSTR ligands labeled with gallium-68. Various SSTR ligands are available for routine clinical use including Ga-68 DOTA-Tyr3-octreotide (DOTATOC), Ga-68 DOTA-D-Phe1-Tyr3-octreotate (DOTATATE), or Ga-68 DOTA-I-Nal3-octreotide (DOTANOC). The most common indications for PET imaging using the above SSTR ligands include aiding in the differential diagnosis, delineation of extent of meningioma for treatment planning, and the diagnosis of meningioma disease relapse.[24]**
- **SSTR PET improves target volume delineation for radiotherapy planning (even in areas with transosseous growth), reduces radiation dose for at-risk organs, and improves local control.[25-28] SSTR PET can aide in detection and diagnosis of meningioma tissue with high sensitivity and specificity, especially in small and difficult-to-locate meningiomas (ie, skull base), optic nerve sheath meningiomas, postoperative meningioma tissue, meningioma relapse, and differentiation from dural metastases.[29-34] SSTR PET is superior to an indium-111 octreotide scan when both scans are available. Lastly, SSTR PET can be superior to MRI alone for higher grade (recurrent grade 1, or grade 2 or 3) meningiomas as part of routine management and follow-up, especially when appearance on MRI is not well-defined. Surveillance imaging can be obtained every 3 to 6 months.[24]**

Amino Acid PET/CT or PET/MRI Brain Scanning:

- **The most established radiolabeled amino acids in primary and secondary brain tumors include [11C]-methyl-L-methionine (MET), *O*-(2-[18f] fluoroethyl)-L-tyrosine (FET), and 3,4-dihydroxy-6-[18f]-fluoro-l-phenylalanine (FDOPA). Combining the above amino acid tracers with anatomical MRI improves diagnostic accuracy in primary and secondary brain tumors. Amino acid PET gives superior tumor-specific tracer uptake even in the absence of blood-brain barrier disruption.[20, 35]**
- **The above amino acid PET tracers can be considered for delineation of tumor extent, diagnostic biopsy planning, radiotherapy planning for better visualization of tumor margins, and differentiating tumor progression- and treatment-related changes per RANO/EANO/SNMMI guidelines. Several studies report sensitivities and specificities around 90%.[20,35-38] Although amino acid PET tracers have not yet reached FDA approval, eligible patients may obtain amino acid PET at centers where available.**
- **Limitations include physiological uptake in various anatomical locations depending on specific tracer used,[39] inferior spatial resolution as compared to anatomical MRI, decreased or no uptake in some lower grade gliomas,[41] and accuracy of interpretations.[42]**

Glucose PET/CT or PET/MRI Brain Scan Using FDG Assess Metabolism Within Tumor and Normal Tissue:

- **FDG-PET may be useful in certain circumstances in differentiating tumor from radiation necrosis, but has some limitations due to reduced tumor-to-background contrast and detectability.[20,35,42]**
- **Limitations include interpretation difficulties due to high regional FDG uptake in gray matter, as well as with other inflammatory processes such as trauma, infection, granulomatous diseases, hemorrhage, radiation-related effects, encephalitis, and epileptic seizures.[42]**

Note: All recommendations are category 2A unless otherwise indicated.

Continued

Version 3.2025, 12/05/25 © 2025 National Comprehensive Cancer Network® (NCCN®), All rights reserved. NCCN Guidelines® and this illustration may not be reproduced in any form without the express written permission of NCCN.

PLEASE NOTE that use of this NCCN Content is governed by the End-User License Agreement, and you MAY NOT distribute this Content or use it with any artificial intelligence model or tool.
Printed by A. S. M. FAZLUL KARIM CHOWDHURY on 4/20/2026 3:06:38 AM. Copyright © 2026 National Comprehensive Cancer Network, Inc. All Rights Reserved.

PRINCIPLES OF BRAIN AND SPINE TUMOR IMAGING[1]

Imaging Surveillance Recommendations for *IDH*-Mutant Lower Grade Glioma[43]

Glioma type	MRI monitoring after diagnosis and initial treatment
Oligodendroglioma, *IDH* mutated, 1p/19q codeleted, grade 2	After RT and chemotherapy: At least every 6–9 months until progression* After RT or chemotherapy: As often as every 3–4 months in the first 5 years, thereafter as frequently as every 3–4 months, but not longer than 6 months until progression* After surgery only: As frequently as every 3–4 months until tumor progression. For patients who underwent gross total resection, MRI every 6–9 months 5 years postsurgery until tumor progression*
Astrocytoma, *IDH* mutated, grade 2	After RT and chemotherapy: At least every 6 months until progression* After RT or chemotherapy: As often as every 3–4 months in the first 5 years, thereafter as frequently as every 3–4 months, but not longer than 6 months until progression* After surgery only: As frequently as every 3–4 months until tumor progression*
Oligodendroglioma, *IDH* mutated, 1p/19q codeleted, grade 3	After RT and chemotherapy: At least every 6–9 months until progression* After RT or chemotherapy: As often as every 3–4 months in the first 5 years, thereafter as frequently as every 3–4 months, but not longer than 6 months until progression*
Astrocytoma, *IDH* mutated, grade 3	After RT and chemotherapy: At least every 6 months until progression* After RT or chemotherapy: As often as every 3–4 months until progression*
Recurrent oligodendroglioma, *IDH* mutated, 1p/19q codeleted, grade 2 and grade 3	As often as every 3–4 months*
Recurrent astrocytoma, *IDH* mutated, grade 2 and grade 3	As often as every 2–3 months*

RT, Radiation therapy; *IDH*, isocitrate dehydrogenase
*Patients who experience change in seizures, new or worsening neurologic signs and symptoms, and/or new or higher dose steroid requirements suspicious for tumor progression should have MRI study as early as possible.

Imaging Surveillance Recommendations for Glioblastoma, *IDH* Wild-Type

- **Pre- and post-op MRI (within 48 hours), pre-radiation planning MRI 3–5 weeks post-op, post-radiation MRI 3–6 weeks post-RT, and every 2–3 months for 3 years. Then every 2–4 months indefinitely.**

Imaging Surveillance Recommendations for Primary CNS Lymphoma

- **MRI Brain every 2–3 months until year 2**

Imaging Surveillance Recommendations for Medulloblastoma

- **MRI Brain every 2–3 months until year 2**

Imaging Surveillance Recommendations for Leptomeningeal Metastases

- **Diagnosis: Staging of neuroaxis with MRI Brain and Total Spine**
- **Follow-up: Neuroimaging of site of involvement (MRI Brain and/or Total Spine) every 2–3 months until year 2; every 6 months until 5 years, then annually indefinitely**
- **It is important that the treating physician be given the flexibility to determine the frequency of imaging that is appropriate for specific patients and clinical conditions, and not be restricted to the intervals defined in these recommendations.**

Note: All recommendations are category 2A unless otherwise indicated.

Continued

Version 3.2025, 12/05/25 © 2025 National Comprehensive Cancer Network® (NCCN®), All rights reserved. NCCN Guidelines® and this illustration may not be reproduced in any form without the express written permission of NCCN.

PLEASE NOTE that use of this NCCN Content is governed by the End-User License Agreement, and you MAY NOT distribute this Content or use it with any artificial intelligence model or tool.
Printed by A. S. M. FAZLUL KARIM CHOWDHURY on 4/20/2026 3:06:38 AM. Copyright © 2026 National Comprehensive Cancer Network, Inc. All Rights Reserved.

PRINCIPLES OF BRAIN AND SPINE TUMOR IMAGING – REFERENCES

[1] Wen PY, van den Bent M, Youssef G, et al. RANO 2.0: Update to the response assessment in neuro-oncology criteria for high- and low-grade gliomas in adults. J Clin Oncol 2023;41:5187-5199.
[2] Ellingson BM, Wen PY, Cloughesy TF. Evidence and context of use for contrast enhancement as a surrogate of disease burden and treatment response in malignant glioma. Neuro Oncol 2018;20:457-471.
[3] ACR Committee on MR Safety. ACR Manual on MR Safety. American College of Radiology; 2024. Available at: [https://www.acr.org/Clinical-Resources/Clinical-Tools-and-Reference/radiology-safety/mr-safety]. Accessed: May 20,2025.
[4] ACR Committee on Drugs and Contrast Media. ACR Manual https://www.acr.org/Clinical-Resources/Clinical-Tools-and-Reference/Contrast-Manual. Accessed: May 20,2025.
[5] McDonald RJ, Levine D, Weinreb J, et al. Gadolinium retention: A research roadmap from the 2018 NIH/ACR/RSNA Workshop on Gadolinium Chelates. Radiology 2018;289:517-534.
[6] Smith APL, Marino M, Roberts J, et al. Clearance of gadolinium from the brain with no pathologic effect after repeated administration of gadodiamide in healthy rats: An analytical and histologic study. Radiology 2017;282:743-751.
[7] McDonald RJ, Weinreb JC, Davenport MS. Symptoms associated with gadolinium exposure (SAGE): A suggested term. Radiology 2022;302:270-273.
[8] Lollis SS, Mamourian AC, Vaccaro TJ, Duhaime AC. Programmable CSF shunt valves: radiographic identification and interpretation. AJNR Am J Neuroradiol Aug 2010;31:1343-1346.
[9] Ellingson BM, Bendszus M, Boxerman J, et al. Consensus recommendations for a standardized Brain Tumor Imaging Protocol in clinical trials. Neuro Oncol 2015;17:1188-1198.
[10] Kaufmann TJ, Smits M, Boxerman J, et al. Consensus recommendations for a standardized brain tumor imaging protocol for clinical trials in brain metastases. Neuro Oncol 2020;22:757-772.
[11] Welker K, Boxerman J, Kalnin A, et al. ASFNR recommendations for clinical performance of MR dynamic susceptibility contrast perfusion imaging of the brain. AJNR Am J Neuroradiol 2015;36:E41-51.
[12] Boxerman JL, Quarles CC, Hu LS, et al. Consensus recommendations for a dynamic susceptibility contrast MRI protocol for use in high-grade gliomas. Neuro Oncol 2020;22:1262-1275.
[13] Essig M, Shiroishi MS, Nguyen TB, et al. Perfusion MRI: The five most frequently asked technical questions. AJR Am J Roentgenol 2013;200:24-34.
[14] Bayraktar ES, Duygulu G, Çetinoğlu YK, et al. Comparison of ASL and DSC perfusion methods in the evaluation of response to treatment in patients with a history of treatment for malignant brain tumor. BMC Med Imaging 2024;24:70.
[15] Andronesi OC, Kim GS, Gerstner E, et al. Detection of 2-hydroxyglutarate in IDH-mutated glioma patients by in vivo spectral-editing and 2D correlation magnetic resonance spectroscopy. Sci Transl Med 2012;4:116ra4.
[16] Choi C, Ganji SK, DeBerardinis RJ, et al. 2-hydroxyglutarate detection by magnetic resonance spectroscopy in IDH-mutated patients with gliomas. Nat Med 2012;18:624-629.
[17] Choi C, Raisanen JM, Ganji SK, et al. Prospective longitudinal analysis of 2-hydroxyglutarate magnetic resonance spectroscopy identifies broad clinical utility for the management of patients with IDH-mutant glioma. J Clin Oncol 2016;34:4030-4039.
[18] Tietze A, Choi C, Mickey B, et al. Noninvasive assessment of isocitrate dehydrogenase mutation status in cerebral gliomas by magnetic resonance spectroscopy in a clinical setting. J Neurosurg 2018;128:391-398.
[19] Schwenck J, Sonanini D, Cotton JM, et al. Advances in PET imaging of cancer. Nat Rev Cancer 2023;23:474-490.
[20] Albert NL, Galldiks N, Ellingson BM, et al. PET-based response assessment criteria for diffuse gliomas (PET RANO 1.0): a report of the RANO group. Lancet Oncol 2024;25:e29-e41.
[21] Weller M, van den Bent M, Preusser M, et al. EANO guidelines on the diagnosis and treatment of diffuse gliomas of adulthood. Nat Rev Clin Oncol 2021;18:170-186.

Continued

Note: All recommendations are category 2A unless otherwise indicated.

Version 3.2025, 12/05/25 © 2025 National Comprehensive Cancer Network® (NCCN®), All rights reserved. NCCN Guidelines® and this illustration may not be reproduced in any form without the express written permission of NCCN.

PLEASE NOTE that use of this NCCN Content is governed by the End-User License Agreement, and you MAY NOT distribute this Content or use it with any artificial intelligence model or tool.
Printed by A. S. M. FAZLUL KARIM CHOWDHURY on 4/20/2026 3:06:38 AM. Copyright © 2026 National Comprehensive Cancer Network, Inc. All Rights Reserved.

PRINCIPLES OF BRAIN AND SPINE TUMOR IMAGING – REFERENCES

[22] Wen PY, Weller M, Lee EQ, et al. Glioblastoma in adults: a Society for Neuro-Oncology (SNO) and European Society of Neuro-Oncology (EANO) consensus review on current management and future directions. Neuro Oncol 2020;22:1073-1113.
[23] Langen KJ, Galldiks N, Mauler J, et al. Hybrid PET/MRI in cerebral glioma: Current status and perspectives. Cancers (Basel) 2023;15:3577.
[24] Galldiks N, Albert NL, Wollring M, et al. Advances in PET imaging for meningioma patients. Neurooncol Adv 2023;5(Suppl 1):i84-i93.
[25] Hadi I, Biczok A, Terpolilli N, et al. Multimodal therapy of cavernous sinus meningioma: Impact of surgery and (68)Ga-DOTATATE PET-guided radiation therapy on tumor control and functional outcome. Neurooncol Adv 2021;3:vdab114.
[26] Graf R, Nyuyki F, Steffen IG, et al. Contribution of 68Ga-DOTATOC PET/CT to target volume delineation of skull base meningiomas treated with stereotactic radiation therapy. Int J Radiat Oncol Biol Phys 2013;85:68-73.
[27] Kunz WG, Jungblut LM, Kazmierczak PM, et al. Improved detection of transosseous meningiomas using (68)Ga-DOTATATE PET/CT compared with contrast-enhanced MRI. J Nucl Med 2017;58:1580-1587.
[28] Kessel KA, Weber W, Yakushev I, et al. Integration of PET-imaging into radiotherapy treatment planning for low-grade meningiomas improves outcome. Eur J Nucl Med Mol Imaging 2020;47:1391-1399.
[29] Afshar-Oromieh A, Giesel FL, Linhart HG, et al. Detection of cranial meningiomas: comparison of (68)Ga-DOTATOC PET/CT and contrast-enhanced MRI. Eur J Nucl Med Mol Imaging 2012;39:1409-1415.
[30] Einhellig HC, Siebert E, Bauknecht HC, et al. Comparison of diagnostic value of 68 Ga-DOTATOC PET/MRI and standalone MRI for the detection of intracranial meningiomas. Sci Rep 2021;11:9064.
[31] Klingenstein A, Haug AR, Miller C, Hintschich C. Ga-68-DOTA-TATE PET/CT for discrimination of tumors of the optic pathway. Orbit 2015;34:16-22.
[32] Bashir A, Larsen VA, Ziebell M, Fugleholm K, Law I. Improved detection of postoperative residual meningioma with [(68)Ga]Ga-DOTA-TOC PET imaging using a high-resolution research tomograph PET scanner. Clin Cancer Res 2021;27:2216-2225.
[33] Purandare NC, Puranik A, Shah S, et al. Differentiating dural metastases from meningioma: role of 68Ga DOTA-NOC PET/CT. Nucl Med Commun 2020;41:356-362.
[34] Rachinger W, Stoecklein VM, Terpolilli NA, et al. Increased 68Ga-DOTATATE uptake in PET imaging discriminates meningioma and tumor-free tissue. J Nucl Med 2015;56:347-53.
[35] Galldiks N, Kaufmann TJ, Vollmuth P, et al. Challenges, limitations and pitfalls of PET and advanced MRI in patients with brain tumors - A report of the PET/RANO group. Neuro Oncol 2024;26:1181-1194.
[36] Galldiks N, Stoffels G, Filss C, et al. The use of dynamic O-(2-18F-fluoroethyl)-l-tyrosine PET in the diagnosis of patients with progressive and recurrent glioma. Neuro Oncol 2015;17:1293-300.
[37] Bashir A, Mathilde Jacobsen S, Molby Henriksen O, et al. Recurrent glioblastoma versus late posttreatment changes: diagnostic accuracy of O-(2-[18F]fluoroethyl)-L-tyrosine positron emission tomography (18F-FET PET). Neuro Oncol 2019;21:1595-1606.
[38] Albert NL, Weller M, Suchorska B, et al. Response assessment in neuro-oncology working group and European Association for Neuro-Oncology recommendations for the clinical use of PET imaging in gliomas. Neuro Oncol 2016;18:1199-208.
[39] Cicone F, Filss CP, Minniti G, et al. Volumetric assessment of recurrent or progressive gliomas: comparison between F-DOPA PET and perfusion-weighted MRI. Eur J Nucl Med Mol Imaging 2015;42:905-915.
[40] Smith NJ, Deaton TK, Territo W, et al. Hybrid (18)F-fluoroethyltyrosine PET and MRI with perfusion to distinguish disease progression from treatment-related change in malignant brain tumors: The quest to beat the toughest cases. J Nucl Med 2023;64:1087-1092.
[41] Hutterer M, Nowosielski M, Putzer D, et al. O-(2-18F-fluoroethyl)-L-tyrosine PET predicts failure of antiangiogenic treatment in patients with recurrent high-grade glioma. J Nucl Med 2011;52:856-864.
[42] Cecchin D, Garibotto V, Law I, Goffin K. PET imaging in neurodegeneration and neuro-oncology: Variants and pitfalls. Semin Nucl Med 2021;51:408-418.
[43] Jo J, van den Bent MJ, Nabors B, Wen PY, Schiff D. Surveillance imaging frequency in adult patients with lower-grade (WHO Grade 2 and 3) gliomas. Neuro Oncol 2022;24:1035-1047.

Note: All recommendations are category 2A unless otherwise indicated.

Version 3.2025, 12/05/25 © 2025 National Comprehensive Cancer Network® (NCCN®), All rights reserved. NCCN Guidelines® and this illustration may not be reproduced in any form without the express written permission of NCCN.

PLEASE NOTE that use of this NCCN Content is governed by the End-User License Agreement, and you MAY NOT distribute this Content or use it with any artificial intelligence model or tool.
Printed by A. S. M. FAZLUL KARIM CHOWDHURY on 4/20/2026 3:06:38 AM. Copyright © 2026 National Comprehensive Cancer Network, Inc. All Rights Reserved.

PRINCIPLES OF SURGERY

BRAIN SURGERY

Guiding Principles
- Gross total resection when appropriate
- Minimal surgical morbidity
- Accurate diagnosis

Factors
- Age
- PS
- Tumor pathology
- Feasibility of decreasing the mass effect with surgery
- Resectability, including number of lesions, location of lesions, and time since last surgery (recurrent patients)
- New versus recurrent tumor
- Suspected pathology – benign vs. malignant, possibility of other non-cancer diagnoses, projected natural history
- For patients with *IDH1* mutations, there is evidence to suggest that a supramarginal resection is most appropriate, which would include not only enhancing areas but also T2/flair areas when appropriate in terms of a safe surgical approach, with the use of any and all surgical adjuncts possible.[1]

Options
- Gross total resection where feasible
- Stereotactic biopsy[2]
- MRI-guided laser interstitial thermal therapy (LITT)[3-8] (category 2B)
  - LITT may be considered for patients who are poor surgical candidates (craniotomy or resection). Potential indications include relapsed brain metastases, radiation necrosis, glioblastomas, and other gliomas.[9,10]
- Open biopsy/debulking followed by planned observation or adjuvant therapy
- Systemic therapy implants, when indicated (see footnote ee on GLIO-9)
- Carmustine polymer wafer may be placed in the tumor resection cavity of patients.[1,11]

Tissue
- Sufficient tissue to pathologist for neuropathology evaluation and molecular correlates
- Frozen section analysis when possible to help with intraoperative decision-making
- Review by experienced neuropathologist
- Postoperative brain MRI should be performed within 48 hours for gliomas and other brain tumors to determine the extent of resection. Staging spine MRI, when appropriate, should be obtained either pre-op, or delayed by at least 2–3 weeks to avoid post-surgical artifacts
- The extent of resection should be judged on the postoperative study and used as a baseline to assess further therapeutic efficacy or tumor progression.

Surgical Adjuncts
- A number of surgical adjuncts can be considered to facilitate safe brain tumor surgery, including use of an intraoperative microscope, frameless stereotactic image guidance, preoperative functional MRI and/or diffusion tensor imaging (DTI) fiber tracking, awake craniotomy, motor and/or speech mapping, intraoperative MRI, and intraoperative fluorescence-guided surgery with 5-ALA.

References (BRAIN-B 2 of 4)

Note: All recommendations are category 2A unless otherwise indicated.

Version 3.2025, 12/05/25 © 2025 National Comprehensive Cancer Network® (NCCN®), All rights reserved. NCCN Guidelines® and this illustration may not be reproduced in any form without the express written permission of NCCN.

PLEASE NOTE that use of this NCCN Content is governed by the End-User License Agreement, and you MAY NOT distribute this Content or use it with any artificial intelligence model or tool.
Printed by A. S. M. FAZLUL KARIM CHOWDHURY on 4/20/2026 3:06:38 AM. Copyright © 2026 National Comprehensive Cancer Network, Inc. All Rights Reserved.

REFERENCES

[1] Ewend MG, Brem S, Gilbert M, et al. Treatment of single brain metastasis with resection, intracavity carmustine polymer wafers, and radiation therapy is safe and provides excellent local control. Clin Cancer Res 2007;13:3637-3641.
[2] Mohammadi AM, Sharma M, Beaumont TL, et al. Upfront magnetic resonance imaging-guided stereotactic laser-ablation in newly diagnosed glioblastoma: A multicenter review of survival outcomes compared to a matched cohort of biopsy-only patients. Neurosurgery 2019;85:762-772.
[3] Kim AH, Tatter S, Rao G, et al. Laser ablation of abnormal neurological tissue using robotic neuroblate system (laantern): 12-month outcomes and quality of life after brain tumor ablation. Neurosurgery 2020;87:E338-E346.
[4] Shah AH, Semonche A, Eichberg DG, et al. The role of laser interstitial thermal therapy in surgical neuro-oncology: Series of 100 consecutive patients. Neurosurgery 2020;87:266-275.
[5] Bastos DCA, Rao G, Oliva ICG, et al. Predictors of local control of brain metastasis treated with laser interstitial thermal therapy. Neurosurgery 2020;87:112-122.
[6] Sujijantarat N, Hong CS, Owusu KA, et al. Laser interstitial thermal therapy (LITT) vs. bevacizumab for radiation necrosis in previously irradiated brain metastases. J Neurooncol 2020;148:641-649.
[7] Ahluwalia M, Barnett GH, Deng D, et al. Laser ablation after stereotactic radiosurgery: A multicenter prospective study in patients with metastatic brain tumors and radiation necrosis. J Neurosurg 2018;130:804-811.
[8] Kamath AA, Friedman DD, Akbari SHA, et al. Glioblastoma treated with magnetic resonance imaging-guided laser interstitial thermal therapy: safety, efficacy, and outcomes. Neurosurgery 2019;84:836-843.
[9] de Groot JF, Kim AH, Prabhu S, et al. Efficacy of laser interstitial thermal therapy (LITT) for newly diagnosed and recurrent IDH wild-type glioblastoma. Neurooncol Adv 2022;4:vdac040.
[10] Johnson GW, Han RH, Smyth MD, et al. Laser interstitial thermal therapy in Grade 2/3 IDH1/2 mutant gliomas: a preliminary report and literature review. Curr Oncol 2022;29:2550-2563.
[11] Brandes AA, Tosoni A, Amista P, et al. How effective is BCNU in recurrent glioblastoma in the modern era? A phase II trial. Neurology 2004;63:1281-1284.

Continued

Note: All recommendations are category 2A unless otherwise indicated.

Version 3.2025, 12/05/25 © 2025 National Comprehensive Cancer Network® (NCCN®), All rights reserved. NCCN Guidelines® and this illustration may not be reproduced in any form without the express written permission of NCCN.

PLEASE NOTE that use of this NCCN Content is governed by the End-User License Agreement, and you MAY NOT distribute this Content or use it with any artificial intelligence model or tool.
Printed by A. S. M. FAZLUL KARIM CHOWDHURY on 4/20/2026 3:06:38 AM. Copyright © 2026 National Comprehensive Cancer Network, Inc. All Rights Reserved.

PRINCIPLES OF SURGERY

SPINE SURGERY

Guiding Principles:
- Patient selection based on overall prognosis and PS.
- Decompression of neural elements for neurologic preservation and potential neurologic improvement[1]
- Spinal stabilization for pain reduction and prevention of progressive spinal deformity
- Appropriate timing of surgery relative to radiotherapy

Factors:
- Age
- PS
- Tumor pathology
- Treatment history
- Neurologic impairment and potential for improvement
- Survival prognosis from oncologist to determine if the patient is a reasonable surgical candidate
- Several grading scales exist that can be used as adjuncts to stratify prognosis[2]
- Biopsy of tumor recommended if a large spinal operation is planned for a tumor of unknown pathology
- NOMS framework provides a useful approach for treating spinal metastatic disease[3]
- For planned instrumented stabilization, extent of disease at adjacent levels and quality of bone evaluated to determine feasibility of instrumented stabilization

Options:
- Surgery prior to radiation for spinal metastatic disease
- Timing of surgery relative to systemic therapy dosing and effects to optimize surgical safety
- Preoperative embolization for vascular tumors such as renal cell carcinoma metastases[4]
- Perioperative corticosteroids when indicated[5]
- Co-surgeon (eg, thoracic surgeon, general surgeon) when needed for exposure or complex tumor removal
- Intraoperative neuromonitoring is an option for select cases[6]
- Advanced techniques can be utilized for instrumentation placement including but not limited to: spinal neuronavigation, robot, intraoperative fluoroscopy, intraoperative CT-like imaging, screw stimulation, and three-dimensional (3D) printed guides
- Carbon fiber instrumentation for select cases requiring neuroimaging surveillance or complex radiation planning[7]
- Avoid fusion substrates contraindicated in cancer
- Extent of resection dictated by pathology; separation surgery is a useful technique for spinal metastatic disease[8]
- Direction of approach to the spine—anterior, posterior, or lateral—chosen by the surgeon to best achieve surgical goals and minimize morbidity

Continued

Note: All recommendations are category 2A unless otherwise indicated.

Version 3.2025, 12/05/25 © 2025 National Comprehensive Cancer Network® (NCCN®), All rights reserved. NCCN Guidelines® and this illustration may not be reproduced in any form without the express written permission of NCCN.

PLEASE NOTE that use of this NCCN Content is governed by the End-User License Agreement, and you MAY NOT distribute this Content or use it with any artificial intelligence model or tool.
Printed by A. S. M. FAZLUL KARIM CHOWDHURY on 4/20/2026 3:06:38 AM. Copyright © 2026 National Comprehensive Cancer Network, Inc. All Rights Reserved.

PRINCIPLES OF SURGERY

Additional:

- **Effective medical pain management in the perioperative period including patient-controlled analgesia and long-acting opioids when indicated to facilitate early mobilization**
- **Goal to discharge the patient to home to minimize treatment delay[9]**
- **Surveillance imaging to evaluate tumor recurrence/progression and instrumentation**
- **Early postoperative evaluation by medical/neuro-oncologist and radiation oncologist to avoid treatment delays**

REFERENCES

[1] Okai BK, Lipinski LJ, Ghannam MM, and Fabiano AJ. Expected motor function change following decompressive surgery for spinal metastatic disease. N Am Spine Soc J 2023;15:100240.
[2] Karim AA, Goodwin CR, Heravi A, et al. Predicting survival for metastatic spine disease: a comparison of nine scoring systems. Spine J 2023;18:1804-1814.
[3] Laufer I, Rubin DG, Eric Lis E, et al. The NOMS framework: approach to the treatment of spinal metastatic tumors. Oncologist 2013;6:744-751.
[4] Manke C, Bretschneider T, Lenhart M, et al. Spinal metastases from renal cell carcinoma: effect of preoperative particle embolization on intraoperative blood loss. AJNR Am J Neuroradiol 2001;22:997-1003.
[5] Kumar A, Weber MH, Gokaslan Z, et al. Metastatic spinal cord compression and steroid treatment: A systematic review. Clin Spine Surg 2017;30:156-163.
[6] Kumar N, Vijayaraghavan G, Ravikumar N, et al.ntraoperative neuromonitoring (IONM): Is there a role in metastatic spine tumor surgery? Spine 2019;44:E219-E224.
[7] Perez-Roman RJ, Boddu JV, Bashti M, et al. The use of carbon fiber-reinforced instrumentation in patients with spinal oncologic tumors: a systematic review of literature and future directions. World Neurosurg 2023;173:13-22.
[8] Di Perna G, Cofano F, Mantovani C, et al. Separation surgery for metastatic epidural spinal cord compression: A qualitative review. J Bone Oncol 2020;25:100320.
[9] Kumar N, Patel RS, Wang SSY, et al. Factors influencing extended hospital stay in patients undergoing metastatic spine tumour surgery and its impact on survival. J Clin Neurosci 2018;56:114-120.

Note: All recommendations are category 2A unless otherwise indicated.

Version 3.2025, 12/05/25 © 2025 National Comprehensive Cancer Network® (NCCN®), All rights reserved. NCCN Guidelines® and this illustration may not be reproduced in any form without the express written permission of NCCN.

PLEASE NOTE that use of this NCCN Content is governed by the End-User License Agreement, and you MAY NOT distribute this Content or use it with any artificial intelligence model or tool.
Printed by A. S. M. FAZLUL KARIM CHOWDHURY on 4/20/2026 3:06:38 AM. Copyright © 2026 National Comprehensive Cancer Network, Inc. All Rights Reserved.

PRINCIPLES OF RADIATION THERAPY FOR BRAIN AND SPINAL CORD

Adult Low-Grade Diffuse Glioma: WHO Grade 2 Oligodendroglioma (*IDH*-mutant, 1p19q codeleted), WHO Grade 2 *IDH*-Mutant Astrocytoma

- **Tumor volumes are best defined using pre- and postoperative MRI, usually T2 FLAIR and T1 post-contrast sequences, to define gross tumor volume (GTV). Clinical target volume (CTV) is created by expanding GTV by 1–2 cm margin editing off anatomic boundaries. The planning target volume (PTV) should receive 50–54 Gy in 1.8–2.0 Gy fractions, and doses as low as 45 Gy may also be appropriate.[1-3] Daily image guidance is required if smaller PTV margins are used (≤3 mm).**
- **New MRI for radiation treatment planning is recommended as there can be changes in mass effect, tumor bed, and cytotoxic edema. Distinguishing non-enhancing tumor from vasogenic edema on T2 FLAIR can be challenging and may warrant consultation with a neuroradiologist to inform treatment planning.**
- **For low-grade circumscribed gliomas (eg, PA), a smaller CTV margin (1 cm) is appropriate.**

High-Grade Diffuse Glioma: Glioblastoma, WHO Grade 3 Oligodendroglioma (*IDH*-mutant, 1p19q codeleted), WHO Grade 3 or 4 *IDH*-Mutant Astrocytoma

Simulation and Treatment Planning

- **Tumor volumes are best defined using pre- and postoperative MRI imaging using post-contrast T1 and FLAIR/T2 sequences to define GTV. To account for sub-diagnostic tumor infiltration, the GTV is expanded 1–2 cm (CTV) for grade 3 and 4 tumors. Although trials in glioblastoma have historically used CTV expansion in the range of 2 cm, smaller CTV expansions are supported in the literature and can be appropriate. A PTV margin of 3–5 mm is typically added to the CTV to account for daily setup errors and image registration. Daily image guidance is required if smaller PTV margins are used (≤3 mm). When edema as assessed by T2/FLAIR is included in the initial phase of treatment, fields are usually reduced for the last phase of treatment (boost). The boost target volume will typically encompass only the gross residual tumor and the resection cavity. A range of acceptable CTV margins exists. Both strategies appear to produce similar outcomes.[4]**
- **Consider proton therapy for patients with good long-term prognosis (grade 2 gliomas, grade 3 *IDH*-mutant tumors,[5] and 1p19q codeleted tumors[6]) to better spare uninvolved brain and preserve cognitive function.**

RT Dosing Information

- **The recommended dose is 60 Gy in 2.0 Gy fractions or 59.4 Gy in 1.8 Gy fractions.**
- **A slightly lower dose, such as 54–55.8 Gy in 1.8 Gy or 57 Gy in 1.9 Gy fractions, can be applied when the tumor volume is very large, there is brainstem/spinal cord involvement, or for grade 3 astrocytoma.**
- **If a boost volume is used, the initial phase of the RT plan will receive 46 Gy in 2 Gy fractions or 45–50.4 Gy in 1.8 Gy fractions. The boost plan will typically then receive 14 Gy in 2 Gy fractions or 9–14.4 Gy in 1.8 Gy fractions.[4]**
- **In patients with poor PS or older patients, a hypofractionated accelerated course should be considered with the goal of completing the treatment in 2–4 weeks. Typical fractionation schedules are 34 Gy/10 fractions or 40.05 Gy/15 fractions.[7,8] Alternatively, a shorter fractionation schedule of 25 Gy/5 fractions may be considered for older and/or frail patients with smaller tumors for whom a longer course of treatment would not be tolerable.[9]**

Continued

Note: All recommendations are category 2A unless otherwise indicated.

Version 3.2025, 12/05/25 © 2025 National Comprehensive Cancer Network® (NCCN®), All rights reserved. NCCN Guidelines® and this illustration may not be reproduced in any form without the express written permission of NCCN.

PLEASE NOTE that use of this NCCN Content is governed by the End-User License Agreement, and you MAY NOT distribute this Content or use it with any artificial intelligence model or tool.
Printed by A. S. M. FAZLUL KARIM CHOWDHURY on 4/20/2026 3:06:38 AM. Copyright © 2026 National Comprehensive Cancer Network, Inc. All Rights Reserved.

PRINCIPLES OF RADIATION THERAPY FOR BRAIN AND SPINAL CORD

Reirradiation for Gliomas

- Reirradiation of tumors of the CNS can be done safely in select circumstances, but requires careful attention to treatment technique and taking into account such patient-specific factors such as size of intended target volume, prior and cumulative doses to critical structures, and interval from the preceding radiotherapy course. While improved tumor control can be seen in appropriately selected patients, the impact on quality of life (QOL) and overall survival can vary by histology and patient PS.
- Highly focal techniques like intensity-modulated RT (IMRT), proton therapy, or SRS may be required in these reirradiation settings in order to improve dose distribution to critical structures, and reduce overlap with prior radiation fields.
- Recurrence of glioma can be managed with reirradiation in select scenarios when clinical trial options and new systemic therapy options are limited. Target volumes will be defined using contrast-enhanced T1 and T2 FLAIR MRI images. Normal tissues should include the brain, brainstem, optic nerves, optic chiasm, and cochlea. Radiation dose should be optimized and conformed to the target volume, while diminishing dose to critical structures. Treatment may be performed with highly focused modern SRS techniques for lower volume disease;[10] fractionated IMRT, including doses of 35 Gy in 10 fractions for recurrent glioblastoma;[11] and proton therapy to help spare previously irradiated normal brain. For recurrence of lower grade gliomas, more extended fractionation schedules may be considered, especially if there is a longer interval between the first and second course of radiotherapy. Image-guided RT (IGRT) using imaging techniques may be used during treatment to ensure accuracy.

Reirradiation for Brain Metastases

- Reirradiation for brain metastases can be considered after radiation necrosis is ruled out (in particular when the metastasis is recurrent after prior SRS). Establishing tumor recurrence (vs. treatment effects of necrosis) may require biopsy, surgical resection, or specialized imaging such as MR perfusion, MRS, or PET.[12] See LTD-3.
  - SRS alone is favored if there is tumor progression after prior WBRT.[13]
  - New lesions not previously treated with SRS can be treated safely in future SRS courses.[14,15]
  - For lesions previously treated with SRS, repeat SRS could be considered, but with increased risk of radiation effect.[16]
  - Single-fraction SRS has shown to be effective at either typically recommended dose or doses slightly lower for the given size.[17]
  - Fractionated SRS may help mitigate radiation necrosis risk, and provide ≥70% 1-year local control. Doses to consider include 25–30 Gy in 5 fractions or 24–27 Gy in 3 fractions.[18]
- In cases where radiation necrosis versus tumor recurrence is equivocal, LITT with biopsy or surgical resection may be considered. If pathology is positive for tumor, fractionated SRS may be considered after LITT/surgery, but with time from initial treatment taken into account. In such cases where repeat SRS is appropriate, doses of 25–30 Gy in 5 fractions may be considered.[19,20]
- In patients with targetable mutations, repeat SRS may be deferred in favor of CNS active systemic therapies (eg, osimertinib for *EGFR*-positive NSCLC or alectinib for *ALK*-positive NSCLC).
- WBRT may be considered when recurrence is too widespread to treat with focal therapies such as SRS, surgical resection, or LITT.
  - Repeat WBRT after prior WBRT may be considered in rare scenarios. Typical repeat WBRT dose is 20 Gy in 10 fractions. Consider memantine and hippocampal sparing if feasible due to increased neurocognitive effects with repeat WBRT.[21]

Note: All recommendations are category 2A unless otherwise indicated.

Continued

Version 3.2025, 12/05/25 © 2025 National Comprehensive Cancer Network® (NCCN®), All rights reserved. NCCN Guidelines® and this illustration may not be reproduced in any form without the express written permission of NCCN.

PLEASE NOTE that use of this NCCN Content is governed by the End-User License Agreement, and you MAY NOT distribute this Content or use it with any artificial intelligence model or tool.
Printed by A. S. M. FAZLUL KARIM CHOWDHURY on 4/20/2026 3:06:38 AM. Copyright © 2026 National Comprehensive Cancer Network, Inc. All Rights Reserved.

PRINCIPLES OF RADIATION THERAPY FOR BRAIN AND SPINAL CORD

Adult Intracranial and Spinal Ependymoma

- **Limited Fields:**
  - **Intracranial tumor volumes are best defined using pre- and postoperative MRI imaging, usually enhanced T1 and/or FLAIR/T2. GTV is defined as anatomic areas that are touched by preoperative tumor volume plus postoperative signal abnormality as seen on MRI.**
  - **RT Dosing Information:**
    - ◊ **CTV (GTV plus 1–2 cm margin) should receive 54–59.4 Gy in 1.8–2.0 Gy fractions. PTV margin of 3–5 mm is typically added to the CTV to account for daily setup errors and image registration.**
- **Craniospinal:**
  - **To reduce toxicity from CSI in adults, consider the use of IMRT or protons if available (for patients with positive CSF or known metastatic disease).**
  - **RT Dosing Information:**
    - ◊ **Whole brain and spine (to bottom of thecal sac) receive 36 Gy in 1.8 Gy fractions, followed by limited field to spine lesions to 45 Gy. (Gross metastatic lesions below the conus could receive higher doses of 54–60 Gy.)[22,23]**
    - ◊ **Primary intracranial site should receive a total dose of 54–59.4 Gy in 1.8–2.0 Gy fractions.**
    - ◊ **Consider boosting any gross intracranial metastatic sites to a higher dose while respecting normal tissue tolerances.**
- **Spine Ependymoma:**
  - **For spine ependymomas, see section on primary spinal cord tumors (BRAIN-C 4 of 10).[24,25]**
  - **CTV margins of 1–2 cm in the superior and inferior directions are recommended.**
  - **PTV margin of 3–5 mm is typically added to the CTV to account for daily setup errors and image registration.**

Adult Medulloblastoma

- **Standard Risk for Recurrence:**
  - **Preferred regimen is 23.4 Gy CSI[26,27,††] with involved field boost to the primary brain site to 54–55.8 Gy[1] in patients who will receive adjuvant chemotherapy. For patients who are unable to receive adjuvant chemotherapy, typically doses of 30–36 Gy CSI[26,†] with involved field boost to the primary brain site to 54–55.8 Gy are used.**
- **High Risk for Recurrence:**
  - **36 Gy CSI[27,†] with involved field boost to primary brain site to 54–55.8 Gy with adjuvant systemic therapy.**
    - ◊ **Focal spine boost to areas of gross disease, or dose escalation of CSI to 39.6 Gy may be indicated for patients with gross disease on spine MRI.**

†To reduce toxicity from CSI in adults, consider the use of IMRT or protons if available.
††Regimen supported by data from pediatric trials only.

Note: All recommendations are category 2A unless otherwise indicated.

Continued

Version 3.2025, 12/05/25 © 2025 National Comprehensive Cancer Network® (NCCN®), All rights reserved. NCCN Guidelines® and this illustration may not be reproduced in any form without the express written permission of NCCN.

PLEASE NOTE that use of this NCCN Content is governed by the End-User License Agreement, and you MAY NOT distribute this Content or use it with any artificial intelligence model or tool.
Printed by A. S. M. FAZLUL KARIM CHOWDHURY on 4/20/2026 3:06:38 AM. Copyright © 2026 National Comprehensive Cancer Network, Inc. All Rights Reserved.

PRINCIPLES OF RADIATION THERAPY FOR BRAIN AND SPINAL CORD

Primary CNS Lymphoma

- **WBRT is typically used as consolidation following high-dose methotrexate (HDMTX) based induction therapy in the primary setting in for patients who are ineligible for autologous hematopoietic cell transplant (HCT) or is used in the palliative setting.**
  - **Adjuvant RT: Can be tailored or given for patients who are ineligible for consolidation autologous HCT**
  - **Definitive: Primary RT should be first-line therapy after progression on HDMTX based upfront treatment. Cranial radiation to 20–24 Gy followed by boost to radiographically visible T1/T2 disease to 40–50 Gy is recommended. Primary RT should also be considered in patients who are ineligible for MTX-based primary therapy.**

Secondary CNS Lymphoma

- **RT Dosing:**
  - ◊ **For patients with KPS ≥70 and no extracranial disease, then cranial radiation can be given to 20–24 Gy followed by boost to radiographically visible T1/T2 disease to 40 Gy. If poor KPS (<70) or extracranial disease, then RT can be limited to either cranial RT alone to 20–24 Gy or focal involved-site RT (ISRT) to gross disease to 24–30 Gy.**
  - ◊ **When used, low-dose WBRT should be limited to 23.4 Gy in 1.8 Gy fractions following a CR to systemic therapy.[28]**
  - ◊ **For less than CR, consider WBRT to 23.4–36 Gy followed by a limited field boost to gross disease to a bioequivalent dose of 45 Gy. In select cases, focal radiation boost or focal radiation to residual disease only may be considered.[29-34]**
- **For patients who are not candidates for systemic therapy:**
  - ◊ **WBRT doses of 24–36 Gy followed by a boost to gross disease for a total dose of 45 Gy.**
- **Palliative: Primary RT should be first-line after progression on HDMTX-based upfront treatment.**

Primary Spinal Cord Tumors

- **RT Dosing:**
  - ◊ **Doses of 45–54 Gy are recommended using fractions of 1.8 Gy.**
  - ◊ **In tumors below the conus medullaris higher doses up to 60 Gy may be delivered.**
  - ◊ **CTV margins of 1–2 cm in the superior and inferior directions are recommended.**
  - ◊ **PTV margins of 3–5 mm are typically added to the CTV to account for daily setup errors and image registration.**
  - ◊ **In some instances focal SRS/SBRT to spinal tumors like hemangioblastoma may be appropriate, with care to respect normal tissue constraints of spinal cord and surrounding structures.[35]**
  - ◊ **Proton therapy may also be helpful in the setting of primary spinal cord tumors to better spare surrounding normal tissues, uninvolved cord, and nerve roots.**

Note: All recommendations are category 2A unless otherwise indicated.

Continued

Version 3.2025, 12/05/25 © 2025 National Comprehensive Cancer Network® (NCCN®), All rights reserved. NCCN Guidelines® and this illustration may not be reproduced in any form without the express written permission of NCCN.

PLEASE NOTE that use of this NCCN Content is governed by the End-User License Agreement, and you MAY NOT distribute this Content or use it with any artificial intelligence model or tool.
Printed by A. S. M. FAZLUL KARIM CHOWDHURY on 4/20/2026 3:06:38 AM. Copyright © 2026 National Comprehensive Cancer Network, Inc. All Rights Reserved.

PRINCIPLES OF RADIATION THERAPY FOR BRAIN AND SPINAL CORD

Meningiomas

- General Treatment Information
  - Sensitive and specific imaging modalities for radiation treatment planning in meningioma can be helpful, including MR perfusion and PET imaging (eg, Ga-68 DOTATATE PET-MRI and/or CT).
  - If appropriate, may be treated using SRS or fractionated SRS.
  - Highly conformal fractionated RT techniques (eg, 3D conformal RT [3D-CRT], IMRT, volumetric modulated arc therapy [VMAT], proton therapy) are recommended to spare critical structures and uninvolved tissue.
  - Stereotactic or image-guided therapy is recommended when using tight margins or when close to critical structures.

- WHO Grade 1 Meningiomas:
  - RT Dosing:
    - 54 Gy may be reduced to 50–50.4 Gy range near critical organs at risk.[36,37]
    - WHO grade 1 meningiomas may also be treated with SRS doses of 12–16 Gy in a single fraction when appropriate, or consider hypofractionated stereotactic radiation therapy (SRT) (25–30 Gy in 5 fractions) if near critical structures. Optimal dosing has not been determined.

- WHO Grade 2 Meningiomas:
  - General Treatment Information
    - Treatment should be directed to gross tumor (if present), surgical bed, and a margin (0.5–2 cm) to account for microscopic disease.
    - Limit margin expansion into the brain parenchyma if there is no evidence of brain invasion. CTVs should be edited and constrained anatomically to encompass path of extension into meningeal and dural surfaces.
  - RT Dosing:
    - 54–60 Gy in 1.8–2.0 Gy fractions. Higher doses (59.4–60 Gy) are recommended for patients with subtotally resected disease or recurrent tumors.
  - Select WHO grade 2 cases: Recurrence post prior radiation and smaller size amendable to SRS may also be treated with SRS doses of 16–20 Gy in a single fraction when appropriate, or consider hypofractionated SRT (27.5–30 Gy in 5 fractions) if near critical structures.[38,39] Optimal dosing has not been determined.

- WHO Grade 3 Meningiomas:
  - General Treatment Information
    - Treat as malignant tumors with treatment directed to gross tumor (if present), surgical bed, and a margin (1–2 cm, depending on distribution of disease and histopathology).
- RT Dosing:
  - 59.4–60 Gy in 1.8–2.0 Gy fractions. Higher doses (66–70 Gy at 2 Gy per fraction) may be needed to provide durable local control of gross tumor but require highly conformal technique and respect of normal tissue tolerances. Using techniques like IMRT with simultaneous integrated boost (SIB) are helpful in these instances.

Note: All recommendations are category 2A unless otherwise indicated.

Continued

Version 3.2025, 12/05/25 © 2025 National Comprehensive Cancer Network® (NCCN®), All rights reserved. NCCN Guidelines® and this illustration may not be reproduced in any form without the express written permission of NCCN.

PLEASE NOTE that use of this NCCN Content is governed by the End-User License Agreement, and you MAY NOT distribute this Content or use it with any artificial intelligence model or tool.
Printed by A. S. M. FAZLUL KARIM CHOWDHURY on 4/20/2026 3:06:38 AM. Copyright © 2026 National Comprehensive Cancer Network, Inc. All Rights Reserved.

PRINCIPLES OF RADIATION THERAPY FOR BRAIN AND SPINAL CORD

Brain Metastases

- SRS is generally preferred over WBRT for limited brain metastases.
- SRS treatment planning MRI with thick 1-mm slice T1+c sequence is recommended and should be obtained within 14 days of initiation of SRS.[40]
  - Maximum marginal doses from 15–24 Gy based on tumor volume is recommended.[41-44]
    - ◊ Consider fractionated SRS for brain tumor >2 cm and/or for situations where a single-fraction SRS plan exceeds normal tissue constraints (eg, V12 brain [volume of normal brain plus target volumes receiving 12 Gy] of >10 cm).[45]
      – Most common multi-fraction SRS doses include: 27 Gy in 3 fractions and 30 Gy in 5 fractions.
    - ◊ Consider preoperative SRS in select cases when logistically feasible to potentially decrease risk of post-treatment meningeal recurrence (category 2B).
    - ◊ Postoperative single multi-fraction SRS: Local recurrence rates after brain metastasis resections remain high (in the range of 50% at 1–2 years) even in the setting of a radiographic gross total resection. Postoperative SRS to the surgical cavity is supported by randomized data to improve local control over observation and to offer similar overall survival and superior cognitive preservation to postoperative WBRT.[46,47] A consensus statement regarding radiation target delineation has been published.[48] Multi-fraction SRS may be preferred for larger cavities.[49] Common dose-fractionation schedules include 16–20 Gy in 1 fraction, 24–27 Gy in 3 fractions, and 30 Gy in 5 fractions.

- WBRT: Standard doses include 30 Gy in 10 fractions and 20 Gy in 5 fractions. WBRT can be done with or without HA + memantine. HA-WBRT (plus memantine) 30 Gy in 10 fractions is preferred for patients with a better prognosis (≥4 months) and no metastases within 5 mm of the hippocampi.[50]
  - For patients with poor predicted prognosis and with symptomatic brain metastases, standard WBRT of 20 Gy in 5 fractions is a reasonable option.[51] If WBRT is given, for patients with a better prognosis, consider memantine during and after WBRT for a total of 6 months.[52]

Leptomeningeal Metastases

- Volume and dose depend on primary tumor histology and goals of care. For CSI in patients with metastatic solid tumor malignancies, techniques in maximizing bone marrow sparing should be considered (protons when available, or conformal photon-based techniques/IMRT).[53,54]

Note: All recommendations are category 2A unless otherwise indicated.

Continued

Version 3.2025, 12/05/25 © 2025 National Comprehensive Cancer Network® (NCCN®), All rights reserved. NCCN Guidelines® and this illustration may not be reproduced in any form without the express written permission of NCCN.

PLEASE NOTE that use of this NCCN Content is governed by the End-User License Agreement, and you MAY NOT distribute this Content or use it with any artificial intelligence model or tool.
Printed by A. S. M. FAZLUL KARIM CHOWDHURY on 4/20/2026 3:06:38 AM. Copyright © 2026 National Comprehensive Cancer Network, Inc. All Rights Reserved.

PRINCIPLES OF RADIATION THERAPY FOR BRAIN AND SPINAL CORD

Metastatic Spine Tumors

- **General Treatment Information**
  - Doses to vertebral body metastases will depend on patient's PS, spine stability, location in relationship to spinal cord, primary histology, presence of epidural disease, and overall treatment intent (pain relief, long-term local control, or cure).
  - Stereotactic radiation approaches (SRS/SBRT) for spinal cases may be preferred for patients with life expectancy ≥3 months where tumor ablation is a goal of treatment, in tumors considered radioresistant (eg, renal cell, melanoma, sarcoma, hepatocellular, some colorectal and NSCLC cases), and in select patients for optimal pain relief.[55]
  - Stereotactic radiation approaches may also be preferred in the setting of tumor recurrence after prior radiation as a strategy to limit radiation dose to the spinal cord or other critical structures. Careful adherence to consensus guidelines for radiosurgery planning and delivery is recommended.[49,56-57]

- RT Dosing:
  - Generally, conventional EBRT doses of 8 Gy/1 fractions, 20 Gy/5 fractions, or 30 Gy/10 fractions can be used. It is critical to consider tolerance at the spinal cord and/or nerve root. In selected cases, or recurrences after previous radiation, SBRT is appropriate.

  - Common recommended doses for spine SRS/SBRT may include:
    - ◊ 16–24 Gy in 1 fraction;
    - ◊ 24–28 Gy in 2 fractions;
    - ◊ 24–30 Gy in 3 fractions;
    - ◊ 30–40 Gy in 5 fractions

  - In patients with uncomplicated spine metastases that are treated primarily for pain relief, 8 Gy in 1 fraction has been shown to provide equivalent pain control to longer fractionation schedules. Single-fraction treatment is more convenient for patients and an important consideration for patients with poor prognoses. This treatment may be associated with higher rates of retreatment, and is a consideration for patients with a prognosis that exceeds 6 months.

  - When lower biologically effective dose (BED) with alpha/beta ratio of 2 for spinal cord regimens are utilized upfront (ie, BED ≤60 Gy, which includes up to 20 Gy in 5 fractions but does not include 30 Gy in 10 fractions), retreatment with similar BED regimens, such as 20 Gy in 5 fractions or 8 Gy in 1 fraction, can safely be considered as early as 6 weeks from initial treatment for pain relief.[58]

  - In other cases of retreatment, doses ranging from 15 Gy in 1 fraction with SBRT to 40 Gy in 20 fractions with a conformal approach have been utilized for tumor control, with careful consideration of tolerance of the spinal cord and/or nerve roots. In these instances, it is generally recommended that ≥6 months of time between treatments is required. For radiation-associated edema and treatment-related necrosis, please see BRAIN-D, 2 of 7.

Note: All recommendations are category 2A unless otherwise indicated.

Continued

Version 3.2025, 12/05/25 © 2025 National Comprehensive Cancer Network® (NCCN®), All rights reserved. NCCN Guidelines® and this illustration may not be reproduced in any form without the express written permission of NCCN.

PLEASE NOTE that use of this NCCN Content is governed by the End-User License Agreement, and you MAY NOT distribute this Content or use it with any artificial intelligence model or tool.
Printed by A. S. M. FAZLUL KARIM CHOWDHURY on 4/20/2026 3:06:38 AM. Copyright © 2026 National Comprehensive Cancer Network, Inc. All Rights Reserved.

PRINCIPLES OF RADIATION THERAPY FOR BRAIN AND SPINAL CORD
REFERENCES

[1] Karim AB, Maat B, Hatlevoll R, et al. A randomized trial on dose-response in radiation therapy of low-grade cerebral glioma: European Organization for Research and Treatment of Cancer (EORTC) Study 22844. Int J Radiat Oncol Biol Phys 1996;36:549-556.
[2] Shaw E, Arusell R, Scheithauer B, et al. Prospective randomized trial of low- versus high-dose radiation therapy in adults with supratentorial low-grade glioma: initial report of a North Central Cancer Treatment Group/Radiation Therapy Oncology Group/Eastern Cooperative Oncology Group study. J Clin Oncol 2002;20:2267-2276.
[3] van den Bent MJ, Afra D, de Witte O, et al. Long-term efficacy of early versus delayed radiotherapy for low-grade astrocytoma and oligodendroglioma in adults: the EORTC 22845 randomised trial. Lancet 2005;366:985-990.
[4] Cabrera AR, Kirkpatrick JP, Fiveash JB, et al. Radiation therapy for glioblastoma: Executive summary of an American Society for Radiation Oncology Evidence-Based Clinical Practice Guideline. Pract Radiat Oncol 2016;6:217-225.
[5] Buckner JC, Shaw EG, Pugh SL, et al. Radiation plus procarbazine, CCNU, and vincristine in low-grade glioma. N Engl J Med 2016;374:1344-1355.
[6] Shih HA, Sherman JC, Nachtigall LB, et al. Proton therapy for low-grade gliomas: results from a prospective trial. Cancer 2015;121:1712-1719.
[7] Malmström A, Grønberg BH, Marosi C, et al. Temozolomide versus standard 6-week radiotherapy versus hypofractionated radiotherapy in patients older than 60 years with glioblastoma: the Nordic randomised, phase 3 trial. Lancet Oncol 2012;13:916-920.
[8] Roa W, Brasher PM, Bauman G, et al. Abbreviated course of radiation therapy in older patients with glioblastoma multiforme: a prospective randomized clinical trial. J Clin Oncol 2004;22:1583-1588.
[9] Roa W, Kepka L, Kumar N, et al. International Atomic Energy Agency randomized phase III study of radiation therapy in elderly and/or frail patients with newly diagnosed glioblastoma multiforme. J Clin Oncol 2015;33:4145-4150.
[10] Gutin PH, Iwamoto FM, Beal K, et al. Safety and efficacy of bevacizumab with hypofractionated stereotactic irradiation for recurrent malignant gliomas. Int J Radiat Oncol Biol Phys 2009;75:156-163.
[11] Tsien CI, Pugh SL, Dicker AP, et al· NRG Oncology/RTOG1205: A randomized phase II trial of concurrent bevacizumab and reirradiation versus bevacizumab alone as treatment for recurrent glioblastoma. J Clin Oncol 2023;41:1285-1295.
[12] Mayo ZS, Billena C, Shu JH, et al. The dilemma of radiation necrosis from diagnosis to treatment in the management of brain metastases. Neuro Oncol 2024;26:(12 Suppl 2):S56-S65.
[13] Chao ST, Barnett GH, Vogelbaum MA, et al. Salvage stereotactic radiosurgery effectively treats recurrences from whole-brain radiation therapy. Cancer 2008;113:2198-204.
[14] Kotecha R, Damico N, Miller JA, et al. Three or more courses of stereotactic radiosurgery for patients with multiply recurrent brain metastases. Neurosurgery 2017;80:871-879.
[15] Shultz DB, Modlin LA, Jayachandran P, et al. Repeat courses of stereotactic radiosurgery (SRS), deferring whole-brain irradiation, for new brain metastases after initial SRS. Int J Radiat Oncol Biol Phys 2015;92:993-999.
[16] Kowalchuk RO, Niranjan A, Lee CC, et al. Reirradiation with stereotactic radiosurgery after local or marginal recurrence of brain metastases from previous radiosurgery. Int J Radiat Oncol Biol Phys 2022;112:726-734.
[17] Singh R, Didwania P, Lehrer EJ, et al. Repeat stereotactic radiosurgery for locally recurrent brain metastases previously treated with stereotactic radiosurgery: A systematic review and meta-analysis of efficacy and safety. J Radiosurg SBRT 2022;8:1-10.
[18] Yan M, Lee M, Myrehaug S, et al. Hypofractionated stereotactic radiosurgery (HSRS) as a salvage treatment for brain metastases failing prior stereotactic radiosurgery (SRS). J Neurooncol 2023;162:119-128.
[19] Buszek SM, Tran B, Long JP, et al. Postoperative management of recurrence after radiosurgery and surgical resection for brain metastases and predicting benefit from adjuvant radiation. Pract Radiat Oncol 2023;13:e499-e503.
[20] Dharnipragada R, Shah RA, Reynolds M, et al. Laser interstitial thermal therapy followed by consolidation stereotactic radiosurgery (LITT-cSRS) in patients with newly diagnosed brain metastasis. J Neurooncol 2024;169:155-163.
[21] Guo S, Balagamwala EH, Reddy C, et al. Clinical and radiographic outcomes from repeat whole-brain radiation therapy for brain metastases in the age of stereotactic radiosurgery. Am J Clin Oncol 2016;39:288-293.

Note: All recommendations are category 2A unless otherwise indicated.

Continued

Version 3.2025, 12/05/25 © 2025 National Comprehensive Cancer Network® (NCCN®), All rights reserved. NCCN Guidelines® and this illustration may not be reproduced in any form without the express written permission of NCCN.

PLEASE NOTE that use of this NCCN Content is governed by the End-User License Agreement, and you MAY NOT distribute this Content or use it with any artificial intelligence model or tool.
Printed by A. S. M. FAZLUL KARIM CHOWDHURY on 4/20/2026 3:06:38 AM. Copyright © 2026 National Comprehensive Cancer Network, Inc. All Rights Reserved.

PRINCIPLES OF RADIATION THERAPY FOR BRAIN AND SPINAL CORD
REFERENCES

[22] Emami B, Lyman J, Brown A, et al. Tolerance of normal tissue to therapeutic irradiation. Int J Radiat Oncol Biol Phys 1991;21:109-122.
[23] Pieters RS, Niemierko A, Fullerton BC, Munzenrider JE. Cauda equina tolerance to high-dose fractionated irradiation. Int J Radiat Oncol Biol Phys 2006;64:251-257.
[24] Abdel-Wahab M, Etuk B, Palermo J, et al. Spinal cord gliomas: A multi-institutional retrospective analysis. Int J Radiat Oncol Biol Phys 2006;64:1060-1071.
[25] Lee SH, Chung CK, Kim CH, et al. Long-term outcomes of surgical resection with or without adjuvant radiation therapy for treatment of spinal ependymoma: a retrospective multicenter study by the Korea Spinal Oncology Research Group. Neuro Oncol 2013;15:921-929.
[26] Brown AP, Barney CL, Grosshans DR. Proton beam craniospinal irradiation reduces acute toxicity for adults with medulloblastoma. Int J Radiat Oncol Biol Phys 2013;86:277-284.
[27] Packer RJ, Gajjar A, Vezina G, et al. Phase III study of craniospinal radiation therapy followed by adjuvant systemic therapy for newly diagnosed average-risk medulloblastoma. J Clin Oncol 2006;24:4202-4208.
[28] Morris PG, Correa DD, Yahalom J, et al. Rituximab, methotrexate, procarbazine, and vincristine followed by consolidation reduced-dose whole-brain radiotherapy and cytarabine in newly diagnosed primary CNS lymphoma: final results and long-term outcome. J Clin Oncol 2013;31:3971-3979.
[29] Ghesquières H, Ferlay C, Sebban C, et al. Long-term follow-up of an age-adapted C5R protocol followed by radiotherapy in 99 newly diagnosed primary CNS lymphomas: a prospective multicentric phase II study of the Groupe d'Etude des Lymphomes de l'Adulte (GELA). Ann Oncol 2010;4:842-850.
[30] Shah GD, Yahalom J, Correa DD, et al. Combined immunochemotherapy with reduced whole-brain radiotherapy for newly diagnosed primary CNS lymphoma. J Clin Oncol 2007;30:4730-4735.
[31] Thiel E, Korfel A, Martus P, et al. High-dose methotrexate with or without whole brain radiotherapy for primary CNS lymphoma (G-PCNSL-SG-1): a phase 3, randomised, non-inferiority trial. Lancet Oncol 2010;11:1036-1047.
[32] Kasenda B, Loeffler J, Illerhaus G, et al. The role of whole brain radiation in primary CNS lymphoma. Blood 2016;1:32-36.
[33] Foreman BE, Mullikin TC, Floyd SR, et al. Long-term outcomes with reduced-dose whole-brain radiotherapy and a stereotactic radiosurgery boost for primary central nervous system lymphoma Neurooncol Adv 2023;5:vdad097.
[34] Laucis AM, Selwa K, Sun Y, et al. Efficacy and toxicity with radiation field designs and concurrent temozolomide for CNS lymphoma. Neurooncol Pract 2022;9:536-544.
[35] Daly ME, Choi CYH, Gibbs IC, et al. Tolerance of the spinal cord to stereotactic radiosurgery: insights from hemangioblastomas Int J Radiat Oncol Biol Phys 2011;80:213-220.
[36] Rogers L, Barani I, Chamberlain M, et al. Meningiomas: knowledge base, treatment outcomes, and uncertainties. A RANO review. J Neurosurg 2015;122:4-23.
[37] Goldsmith BJ, Wara WM, Wilson CB, Larson DA. Postoperative irradiation for subtotally resected meningiomas. A retrospective analysis of 140 patients treated from 1967 to 1990. J Neurosurg 1994;82:195
[38] Kowalchuk RO, Shepard MJ, Sheehan K, et al. Treatment of WHO grade 2 meningiomas with stereotactic radiosurgery: Identification of an optimal group for SRS using RPA. Int J Radiat Oncol Biol Phys 2021;110:804-814.
[39] Momin AA, Shao J, Soni P, et al. Outcomes of salvage radiation for recurrent world health organization grade II meningiomas: a retrospective cohort study. J Neurooncol 2021;152:373-382.
[40] Seymour ZA, Fogh SE, Westcott SK, et al. Interval from imaging to treatment delivery in the radiation surgery age: How long is too long? Int J Radiat Oncol Biol Phys 2015;93:126-132.
[41] Aoyama H, Shirato H, Tago M, et al. Stereotactic radiosurgery plus whole-brain radiation therapy vs stereotactic radiosurgery alone for treatment of brain metastases: A randomized controlled trial. JAMA 2006;295:2483-2491.
[42] Hughes RT, Masters AH, McTyre ER, et al. Initial SRS for patients with 5-15 brain metastases: results of a multi-institutional experience. Int J Radiat Oncol Biol Phys 2019;104:1091-1098.
[43] Shaw E, Scott C, Souhami L, et al. Single dose radiosurgical treatment of recurrent previously irradiated primary brain tumors and brain metastases: final report of RTOG protocol 90-05. Int J Radiat Oncol Biol Phys 2000;47:291-298.
[44] Yamamoto M, Serizawa T, Shuto T, et al. Stereotactic radiosurgery for patients with multiple brain metastases (JLGK0901): a multi-institutional prospective observational study. Lancet Oncol 2014;15:387-395.
[45] Brown PD, Ballman KV, Cerhan JH, et al. Postoperative stereotactic radiosurgery compared with whole brain radiotherapy for resected metastatic brain disease (NCCTG N107C/CEC.3): a multicentre, randomised, controlled, phase 3 trial. Lancet Oncol 2017;18:1049-1060.
[46] Minniti G, Scaringi C, Paolini S, et al. Single-fraction versus multifraction (3 x 9 gy) stereotactic radiosurgery for large (>2 cm) brain metastases: a comparative analysis of local control and risk of radiation-induced brain necrosis. Int J Radiat Oncol Biol Phys 2016;95:1142-1148.

Note: All recommendations are category 2A unless otherwise indicated.

Continued

Version 3.2025, 12/05/25 © 2025 National Comprehensive Cancer Network® (NCCN®), All rights reserved. NCCN Guidelines® and this illustration may not be reproduced in any form without the express written permission of NCCN.

PLEASE NOTE that use of this NCCN Content is governed by the End-User License Agreement, and you MAY NOT distribute this Content or use it with any artificial intelligence model or tool.
Printed by A. S. M. FAZLUL KARIM CHOWDHURY on 4/20/2026 3:06:38 AM. Copyright © 2026 National Comprehensive Cancer Network, Inc. All Rights Reserved.

PRINCIPLES OF RADIATION THERAPY FOR BRAIN AND SPINAL CORD
REFERENCES

[47] Mahajan A, Ahmed S, McAleer MF, et al. Post-operative stereotactic radiosurgery versus observation for completely resected brain metastases: a single-centre, randomised, controlled, phase 3 trial. Lancet Oncol 2017;18:1040-1048.
[48] Redmond KJ, Robertson S, Lo SS, et al. Consensus contouring guidelines for postoperative stereotactic body radiation therapy for metastatic solid tumor malignancies to the spine. Int J Radiat Oncol Biol Phys 2017;97:64-74.
[49] Cox BW, Spratt DE, Lovelock M, et al. International Spine Radiosurgery Consortium consensus guidelines for target volume definition in spinal stereotactic radiosurgery. Int J Radiat Oncol Biol Phys 2012;83:e597-605.
[50] Dunne EM, Sahgal A, Lo SS, et al. International consensus recommendations for target volume delineation specific to sacral metastases and spinal stereotactic body radiation therapy (SBRT). Radiother Oncol 2020;145:21-29.
[51] Andrews DW, Scott CB, Sperduto PW, et al. Whole brain radiation therapy with or without stereotactic radiosurgery boost for patients with one to three brain metastases: phase III results of the RTOG 9508 randomized trial. Lancet 2004;363:1665-1672.
[52] Brown PD, Pugh S, Laack NN, et al. Memantine for the prevention of cognitive dysfunction in patients receiving whole-brain radiotherapy: a randomized, double-blind, placebo-controlled trial. Neuro Oncol 2013;15:1429-1437.
[53] Yang JT, Wijetunga NA, Yamada J, et al. Clinical trial of proton craniospinal irradiation for leptomeningeal metastases. Neuro Oncol 2021;23:134-143.
[54] Yang JT, Wijetunga NA, Pentsova E, et al. Randomized phase II trial of proton craniospinal irradiation versus photon involved-field radiotherapy for patients with solid tumor leptomeningeal metastasis. J Clin Oncol 2022;40:3858-3867.
[55] Zeng KL, Myrehaug S, Soliman H, et al. Mature local control and reirradiation rates comparing spine stereotactic body radiation therapy with conventional palliative external beam radiation therapy. Int J Radiat Oncol Biol Phys 2022;114:293-300.
[56] Redmond KJ, Lo SS, Soltys SG, et al. Consensus guidelines for postoperative stereotactic body radiation therapy for spinal metastases: results of an international survey. J Neurosurg Spine 2017;26:299-306.
[57] Redmond KJ, Robertson S, Lo SS, et al. Consensus contouring guidelines for postoperative stereotactic body radiation therapy for metastatic solid tumor malignancies to the spine. Int J Radiat Oncol Biol Phys 2017;97:64-74.
[58] Jones B, Dale RG, Deehan C, et al. The role of biologically effective dose (BED) in clinical oncology. Clin Oncol (R Coll Radiol) 2001;13:71-81.

Note: All recommendations are category 2A unless otherwise indicated.

Version 3.2025, 12/05/25 © 2025 National Comprehensive Cancer Network® (NCCN®), All rights reserved. NCCN Guidelines® and this illustration may not be reproduced in any form without the express written permission of NCCN.

PLEASE NOTE that use of this NCCN Content is governed by the End-User License Agreement, and you MAY NOT distribute this Content or use it with any artificial intelligence model or tool.
Printed by A. S. M. FAZLUL KARIM CHOWDHURY on 4/20/2026 3:06:38 AM. Copyright © 2026 National Comprehensive Cancer Network, Inc. All Rights Reserved.

PRINCIPLES OF BRAIN AND SPINE TUMOR MANAGEMENT

General

Patients diagnosed with a tumor involving the brain, spinal cord, and related support structures should be referred to practitioners who are experienced in the diagnosis and management of these lesions.[a] The patient may (and should) be presented with options for care, which may include procedures or treatments best done by other specialists. The care options should then be discussed with the patient and their chosen supports in a manner that is understandable and culturally and educationally sensitive. It is strongly encouraged to discuss goals of care with the patient.

Multidisciplinary Care

During the course of their treatment, most patients will be seen by multiple subspecialists. Close and regular communication among all providers across disciplines is essential. Brain tumor board or multidisciplinary clinic care models are strongly recommended. These models facilitate interactions among multiple subspecialists, ideally including allied health services (ie, physical, occupational, and speech therapies; nursing; psychology; social work) for optimizing treatment plan recommendations.

- **Patients with malignant primary brain tumors can benefit from inpatient rehabilitation as deemed appropriate.**
- **As treatment proceeds, it is important that the patient and family understand the role of each team member. One practitioner should be identified early on as the main point of contact for follow-up care questions. This individual can facilitate referral to the appropriate specialist.**
- **Offering patients the option of participation in a clinical trial is strongly encouraged. Practitioners should discuss any local, regional, and national options for which the patient may be eligible and the advantages and disadvantages of participation. Centers treating neuro-oncology patients are encouraged to participate in large collaborative trials in order to have local options to offer patients.**
- **Patients should be educated on the importance of informed consent and side effects when receiving systemic therapy.**
- **Throughout treatment the patient's QOL should remain the highest priority and guide clinical decision-making. While responses on imaging are benchmarks of successful therapy, other indicators of success such as overall well-being, function in day-to-day activities, social and family interactions, nutrition, pain control, long-term consequences of treatment, and psychological issues must be considered.**
- **Patients should be informed of the possibility of pseudoprogression, its approximate incidence, and potential investigations that may be needed in the event that pseudoprogression is suspected. Close follow-up imaging, MR perfusion, MRS, PET/CT imaging, and repeat surgery may be necessary if clinically indicated. Educate patients on the uncertainty of imaging as a whole, and the potential need for corollary testing to interpret scans.**
- **For patients with spine tumors, it is important to assemble a multidisciplinary team to integrate diagnosis, treatment, symptom management, and rehabilitation. Patients with spine tumors have complex physical, psychological, and social care needs.**

References on BRAIN-D 6 of 7

[a] Depending on local referral patterns and available expertise, this physician may be a neurosurgeon, neurologist, medical oncologist, or radiation oncologist.

Continued

Note: All recommendations are category 2A unless otherwise indicated.

Version 3.2025, 12/05/25 © 2025 National Comprehensive Cancer Network® (NCCN®), All rights reserved. NCCN Guidelines® and this illustration may not be reproduced in any form without the express written permission of NCCN.

PLEASE NOTE that use of this NCCN Content is governed by the End-User License Agreement, and you MAY NOT distribute this Content or use it with any artificial intelligence model or tool.
Printed by A. S. M. FAZLUL KARIM CHOWDHURY on 4/20/2026 3:06:38 AM. Copyright © 2026 National Comprehensive Cancer Network, Inc. All Rights Reserved.

PRINCIPLES OF BRAIN AND SPINE TUMOR MANAGEMENT

Multidisciplinary Care (continued)

Optimal management requires a multidisciplinary team including those with the following expertise: neuro-oncology/medical and radiation oncology; surgery (ie, neurosurgery, orthopedic surgery, surgical oncology); radiology; interventional pain specialties; physical and rehabilitation medicine; physiatry; bowel and bladder care, back care, and ambulation support; physical therapy; occupational therapy; psychological and/or social services; and nutritional support.

- **Practitioners should become familiar with palliative and hospice care resources that are available in their community in order to help educate patients and families that involvement of these services does not indicate a state of hopelessness, no further treatment, or abandonment. Palliative and pain management care should be integrated into management of neuro-oncology patients early in the course of their treatment[1] (NCCN Guidelines for Palliative Care).**

Medical Management

Corticosteroids

- **Steroid therapy should be carefully monitored. If a patient is asymptomatic, steroids may be unnecessary. In general, the lowest dose of steroids should be used for the shortest time possible.[b] Downward titration of the dose should be attempted whenever possible.**
  Twice-daily (BID) or once-daily dosing is recommended for dexamethasone. Patients with extensive mass effect should receive steroids for at least 24 hours before RT. Patients with a high risk of gastrointestinal (GI) side effects (eg, perioperative patients, prior history of ulcers/GI bleed, receiving nonsteroidal anti-inflammatory drugs [NSAIDs] or anticoagulation) should receive H2 blockers or proton pump inhibitors. Care should be taken to watch for development of steroid side effects.[c]
- **Consider prophylactic treatment of *pneumocystis jiroveci* pneumonia (PJP) for patients undergoing long-term steroid therapy (NCCN Guidelines for Prevention and Treatment of Cancer-Related Infections).**

Brain Edema and Treatment-Associated Necrosis/Radionecrosis

- **Careful questioning for subtle symptoms should be undertaken if edema is extensive on imaging.**
- **Symptomatic:**
  - **Corticosteroids and confirmatory diagnostic study[2,3]**
    - **Consider surgical resection**
    - **Consider bevacizumab if symptoms do not resolve with corticosteroids or patient is unable to tolerate corticosteroids. Re-evaluate every 4–6 weeks.[4,5]**
    - **Slow steroid taper, follow serial MR every 2–3 months.**
    - **Consider hyperbaric oxygen treatment in select cases that are unresponsive to corticosteroids.**
- **If asymptomatic:**
  - **Follow with serial MR and neurologic exam every 2–3 months.**
- **LITT is a minimally invasive technique using photothermal technology and can be considered on a case-by-case basis for treatment of radiation necrosis in patients with a history of RT for primary brain tumor or metastatic disease.[6,7] Consultation with neurosurgeons trained in LITT should be done when the procedure is considered.**

[b] An exception to this rule is in the case of suspected CNS lymphoma. Steroids should be avoided where possible (PCNS-1) prior to biopsy to allow for the best chance of diagnosis.

[c] Refractory hyperglycemia, skin changes, visual changes, fluid retention, and myopathy. If any of these changes occur, it is imperative to evaluate potential palliative treatments for them and also to evaluate the current dose of steroids to see if it can be reduced in an attempt to mitigate these side effects. Clinical monitoring for adrenal insufficiency is recommended when weaning steroids for patients who have been on long-term steroid therapy.

Note: All recommendations are category 2A unless otherwise indicated.

References on BRAIN-D 6 of 7

Continued

Version 3.2025, 12/05/25 © 2025 National Comprehensive Cancer Network® (NCCN®), All rights reserved. NCCN Guidelines® and this illustration may not be reproduced in any form without the express written permission of NCCN.

PLEASE NOTE that use of this NCCN Content is governed by the End-User License Agreement, and you MAY NOT distribute this Content or use it with any artificial intelligence model or tool.
Printed by A. S. M. FAZLUL KARIM CHOWDHURY on 4/20/2026 3:06:38 AM. Copyright © 2026 National Comprehensive Cancer Network, Inc. All Rights Reserved.

PRINCIPLES OF BRAIN AND SPINE TUMOR MANAGEMENT

Seizures

- **Seizures are frequent in patients with primary or metastatic brain tumors. Despite this, studies have shown that the use of older, "traditional" anti-seizure medications, including phenytoin, phenobarbital, and valproic acid as prophylaxis against seizures in patients who have never had a seizure or who are undergoing neurosurgical procedures, is ineffective and is not recommended. Newer agents (ie, levetiracetam, topiramate, lamotrigine, pregabalin) have not yet been systematically studied.**
- **Seizure prophylaxis is not recommended as routine in asymptomatic patients but is reasonable to consider perioperatively.**
- **Many anti-seizure medications have significant effects on the cytochrome P450 system, and may have effects on the metabolism of numerous chemotherapeutic agents such as irinotecan, gefitinib, erlotinib, and temsirolimus among others. When possible, such enzyme-inducing antiepileptic drugs (EIAEDs) should be avoided (ie, phenytoin, phenobarbital, carbamazepine), and non-EIAEDs should be used instead (ie, levetiracetam, topiramate, valproic acid, lacosamide). Patients should be closely monitored for any adverse effects of the anti-seizure medications or chemotherapeutic agents.**
- **Consult with neurologists for the management of seizures.**
- **Refer to the Epilepsy Foundation (www.epilepsy.com).**

References on BRAIN-D 6 of 7

Continued

Note: All recommendations are category 2A unless otherwise indicated.

Version 3.2025, 12/05/25 © 2025 National Comprehensive Cancer Network® (NCCN®), All rights reserved. NCCN Guidelines® and this illustration may not be reproduced in any form without the express written permission of NCCN.

PLEASE NOTE that use of this NCCN Content is governed by the End-User License Agreement, and you MAY NOT distribute this Content or use it with any artificial intelligence model or tool.
Printed by A. S. M. FAZLUL KARIM CHOWDHURY on 4/20/2026 3:06:38 AM. Copyright © 2026 National Comprehensive Cancer Network, Inc. All Rights Reserved.

PRINCIPLES OF BRAIN AND SPINE TUMOR MANAGEMENT

Medical Management (continued)

Endocrine Disorders

- Endocrinopathies are common in patients with brain tumors. This may be affected by concomitant steroid use as well as by radiotherapy, surgery, and certain medical therapies. Patients who present with a declining sense of well-being or QOL should be evaluated not only for abnormalities related to their hypothalamic pituitary and adrenal axis, but also with regard to thyroid and gonad function. For patients who received prior RT, long-term monitoring of the hypothalamic pituitary and adrenal axis may be considered (eg, adrenocorticotropic hormone [ACTH] stimulation test, thyroid monitoring).

Fatigue (see the NCCN Guidelines for Cancer-Related Fatigue)

- Fatigue is commonly experienced by patients with brain tumors. This symptom can be severe, persistent, emotionally overwhelming, and not related to the degree or duration of physical activity. Screening should be initiated to identify any underlying medical sources of this symptom, after which patients should be encouraged to start a physical exercise program or increase their level of activity if already exercising, as physical exercise has the best evidence for the prevention and treatment of cancer-related fatigue (see Healthy Lifestyles in NCCN Guidelines for Survivorship). More data are needed on the use of CNS stimulants.
- The effects of psychostimulants on cancer-related fatigue has not been proven, but psychostimulants did improve attention in patients with cancer, thus improving cognitive engagement to allow exercise.

Psychiatric Disease (see the NCCN Guidelines for Distress Management including NCCN Distress Thermometer [DIS-A])

- There is increasing evidence that physical exercise can help reduce anxiety and improve mood. Patients should be encouraged to start an exercise routine at diagnosis (see Healthy Lifestyles in NCCN Guidelines for Survivorship).
- Depression and/or anxiety is common in neuro-oncology patients. These symptoms are greater than simple sadness or anxiety associated with the diagnosis of a tumor. The vegetative symptoms associated with depression or severe anxiety may become very disabling for the patient and distressing for the family. These symptoms will respond to psychotropic medications as they do in patients with no tumors. If less severe, strong support from behavioral health allies and other qualified counselors is also extremely beneficial. All oncology providers and team members should be sensitive to these symptoms and inquire about them in follow-up visits in order to determine if the patient may be a candidate for psychological or psychiatric treatment. Communication between members of the patient's health care team regarding the patient's response to treatment is important.[8] Anti-seizure medications, anxiolytics, some systemic therapy agents, antiemetics, and other agents used directly in cancer therapy may affect mental status, alertness, and mood. Alterations in thought processes should trigger an investigation for any treatable causes, including endocrine disorders, infection, side effects of medication, or tumor progression.

Venous Thromboembolism (VTE) (see the NCCN Guidelines for Cancer-Associated Venous Thromboembolic Disease)

- Treatment with direct oral anticoagulants is recommended for VTE prophylaxis in patients with adult-type diffuse gliomas who are deemed to be at high risk of VTE.[9,10,11,12]

Hearing Loss

- Bevacizumab is recommended for NF2 vestibular schwannomas with hearing loss.[13]

References on BRAIN-D 6 of 7

Continued

Note: All recommendations are category 2A unless otherwise indicated.

Version 3.2025, 12/05/25 © 2025 National Comprehensive Cancer Network® (NCCN®), All rights reserved. NCCN Guidelines® and this illustration may not be reproduced in any form without the express written permission of NCCN.

PLEASE NOTE that use of this NCCN Content is governed by the End-User License Agreement, and you MAY NOT distribute this Content or use it with any artificial intelligence model or tool.
Printed by A. S. M. FAZLUL KARIM CHOWDHURY on 4/20/2026 3:06:38 AM. Copyright © 2026 National Comprehensive Cancer Network, Inc. All Rights Reserved.

PRINCIPLES OF BRAIN AND SPINE TUMOR MANAGEMENT

Assessment and Management of Neurocognitive Dysfunction

- **Up to 90% of individuals with supratentorial brain tumors experience some degree of neurocognitive dysfunction.[14-16]**
- **Degree of neurocognitive dysfunction can vary as a result of a variety of factors not limited to tumor- and treatment-related effects. For instance, CNS tumor size, grade, and location influence the likelihood, degree of severity, and specific pattern of cognitive symptoms.[17] In glioma, *IDH1* mutation confers a more favorable cognitive prognosis at the time of initial diagnosis and after surgery.[18-20] Treatments for brain tumors can also negatively impact cognition.[13-25]**
- **Neurocognitive impairment has been shown to be a sensitive indicator of tumor progression[26,27] and a predictor of overall survival in glioma.[28,29] Perhaps more importantly, neurocognitive deficits result in impaired ability to work[30] and instrumental activities of daily living[31] or functional independence, directly hindering QOL.[32]**
- **Neurocognitive screening tools, such as the Mini-Mental State Examination and Montreal Cognitive Assessment (MMSE;[33] MoCA[34]), are insensitive to important neurocognitive changes such as executive function, sustained attention, and processing speed.[35-37] Neuropsychological evaluation is the gold standard for assessment of neurocognitive function, as it objectively and comprehensively characterizes cognitive, behavioral, and emotional issues related to the patient's disease as well as cognitive strengths and identifies treatable risk factors that contribute to neurocognitive difficulty and reduced functioning (eg, depression,[38] sleep disturbance).[39] Evaluations provide patient-specific recommendations,[40] which may include implementation of compensatory strategies in daily activities, referral for psychotherapy or neurocognitive rehabilitation, and guidance regarding work or school accommodations. There is increasing evidence that physical exercise can help preserve cognitive function. Patients should be encouraged to start an exercise routine at diagnosis (see Healthy Lifestyles in NCCN Guidelines for Survivorship).**
- **Where available, neuropsychological evaluation should be performed as needed based on physician assessment to monitor for neurocognitive decline and/or recovery, as well as determine patient-centered treatment recommendations aimed at maximizing safety, functioning, and QOL.[41]**

Health Maintenance (see the NCCN Guidelines for Survivorship)

References on BRAIN-D 6 of 7

Note: All recommendations are category 2A unless otherwise indicated.

Version 3.2025, 12/05/25 © 2025 National Comprehensive Cancer Network® (NCCN®), All rights reserved. NCCN Guidelines® and this illustration may not be reproduced in any form without the express written permission of NCCN.

PLEASE NOTE that use of this NCCN Content is governed by the End-User License Agreement, and you MAY NOT distribute this Content or use it with any artificial intelligence model or tool.
Printed by A. S. M. FAZLUL KARIM CHOWDHURY on 4/20/2026 3:06:38 AM. Copyright © 2026 National Comprehensive Cancer Network, Inc. All Rights Reserved.

PRINCIPLES OF BRAIN AND SPINE TUMOR MANAGEMENT
REFERENCES

[1] Ferrell BR, Temel JS, Temin S, et al. Integration of palliative care into standard oncology care: American Society of Clinical Oncology Clinical Practice Guideline update. J Clin Oncol 2017;35:96-112.
[2] Hoefnagels FWA, Lagerwaard FJ, Sanchez E, et al. Radiological progression of cerebral metastases after radiosurgery: assessment of perfusion MRI for differentiating between necrosis and recurrence. J Neurol 2009;256:878-887.
[3] Barajas RF, Chang JS, Sneed PK, et al. Distinguishing recurrent intra-axial metastatic tumor from radiation necrosis following gammaknife radiosurgery using dynamic susceptibility-weighted contrast-enhanced perfusion MR imaging. AJNR Am J Neuroradiol 2009;30:367-372.
[4] Levin VA, Bidaut L, Hou P, et al. Randomized double-blind placebo-controlled trial of bevacizumab therapy for radiation necrosis of the central nervous system. Int J Radiat Oncol Biol Phys 2011;79:1487-1495.
[5] Chung C, Bryant A, Brown PD. Interventions for the treatment of brain radionecrosis after radiotherapy or radiosurgery. Cochrane Database Syst Rev 2018;7:CD011492.
[6] Ahluwalia M, Barnett GH, Deng D, et al. Laser ablation after stereotactic radiosurgery: a multicenter prospective study in patients with metastatic brain tumors and radiation necrosis. J Neurosurg 2018;130:804-811.
[7] Kim AH, Tatter S, Rao G, et al. Laser Ablation of Abnormal Neurological Tissue Using Robotic NeuroBlate System (LAANTERN): 12-month outcomes and quality of life after brain tumor ablation. Neurosurgery 2020;87:E338-E346.
[8] Andersen BL, DeRubeis RJ, Berman BS, et al. Screening, assessment, and care of anxiety and depressive symptoms in adults with cancer: an American Society of Clinical Oncology guideline adaptation. J Clin Oncol 2014;32:1605-1619.
[9] Thomas AA, Wright H, Chan K, et al. Safety of apixaban for venous thromboembolic primary prophylaxis in patients with newly diagnosed malignant glioma. J Thromb Thrombolysis 2022;53:479-484.
[10] Carney BY, Uhlmann EJ, Puligandla M, et al. Intracranial hemorrhage with direct oral anticoagulants in patients with brain tumors. J Thromb Haemost 2019;17:72-76.
[11] Reed-Guy L, Desai AS, Phillips RE, et al. Risk of intracranial hemorrhage with direct oral anticoagulants vs low molecular weight heparin in glioblastoma: A retrospective cohort study. Neuro Oncol 2022;24:2172-2179.
[12] Miranda S, Benhamou Y, Wells P, et al. Safety of primary thromboprophylaxis using apixaban in ambulatory cancer patients with intracranial metastatic disease or primary brain tumors. Thromb Haemost 2019;119:1886-1887.
[13] Plotkin SR, Duda DG, Muzikansky A, et al. Multicenter, prospective, phase II and biomarker study of high-dose bevacizumab as induction therapy in patients with neurofibromatosis type 2 and progressive vestibular schwannoma. J Clin Oncol 2019;37:3446-3454.
[14] Tucha O, Smely C, Preier M, Lange KW. Cognitive deficits before treatment among patients with brain tumors. Neurosurgery 2000;47:324-333. Discussion 333-334.
[15] Taphoorn MJ, Klein M. Cognitive deficits in adult patients with brain tumours. Lancet Neurol 2004;3:159-168.
[16] Witgert ME, Meyers CA. Neurocognitive and quality of life measures in patients with metastatic brain disease. Neurosurg Clin N Am 2011;22:79-85.
[17] Noll KR, Sullaway C, Ziu M, et al. Relationships between tumor grade and neurocognitive functioning in patients with glioma of the left temporal lobe prior to surgical resection. Neuro Oncol 2014;17:580-587.
[18] van Kessel E, Emons MAC, Wajer IH, et al. Tumor-related neurocognitive dysfunction in patients with diffuse glioma: a retrospective cohort study prior to antitumor treatment. Neurooncol Pract 2019;6:463-472.
[19] Noll KR, Weinberg JS, Ziu M, et al. Neurocognitive changes associated with surgical resection of left and right temporal lobe glioma. Neurosurgery 2015;77:777-785.
[20] Kesler SR, Noll K, Cahill DP, et al. The effect of IDH1 mutation on the structural connectome in malignant astrocytoma. J Neurooncol 2017;131:565-574.
[21] Wefel JS, Noll KR, Rao G, Cahill DP. Neurocognitive function varies by IDH1 genetic mutation status in patients with malignant glioma prior to surgical resection. Neuro Oncol 2016;18:1656-1663.
[22] van Kessel E, Snijders TJ, Baumfalk AE, et al. Neurocognitive changes after awake surgery in glioma patients: a retrospective cohort study. J Neurooncol 2020;146:97-109.

Continued

Note: All recommendations are category 2A unless otherwise indicated.

Version 3.2025, 12/05/25 © 2025 National Comprehensive Cancer Network® (NCCN®), All rights reserved. NCCN Guidelines® and this illustration may not be reproduced in any form without the express written permission of NCCN.

PLEASE NOTE that use of this NCCN Content is governed by the End-User License Agreement, and you MAY NOT distribute this Content or use it with any artificial intelligence model or tool.
Printed by A. S. M. FAZLUL KARIM CHOWDHURY on 4/20/2026 3:06:38 AM. Copyright © 2026 National Comprehensive Cancer Network, Inc. All Rights Reserved.

PRINCIPLES OF BRAIN AND SPINE TUMOR MANAGEMENT
REFERENCES

[23] Armstrong TS, Wefel JS, Wang M, et al. Net clinical benefit analysis of radiation therapy oncology group 0525: a phase III trial comparing conventional adjuvant Temozolomide with dose-intensive temozolomide in patients with newly diagnosed glioblastoma. J Clin Oncol 2013;31:4076-4084.
[24] Prust MJ, Jafari-Khouzani K, Kalpathy-Cramer J, et al. Standard chemoradiation for glioblastoma results in progressive brain volume loss. Neurology 2015;85:683-691.
[25] Makale MT, McDonald CR, Hattangadi-Gluth JA, et al. Mechanisms of radiotherapy-associated cognitive disability in patients with brain tumours. Nat Rev Neurol 2017;13:52-64.
[26] Meyers CA, Hess KR. Multifaceted end points in brain tumor clinical trials: cognitive deterioration precedes MRI progression. Neuro Oncol 2003;5:89-95.
[27] Noll KR, Sullaway CM, Wefel JS. Depressive symptoms and executive function in relation to survival in patients with glioblastoma. J Neurooncol 2019;142:183-191.
[28] Johnson DR, Sawyer AM, Meyers CA, et al. Early measures of cognitive function predict survival in patients with newly diagnosed glioblastoma. Neuro Oncol 2012;14:808-816.
[29] Meyers CA, Hess KR, Yung YK, Levin VA. Cognitive function as a predictor of survival in patients with recurrent malignant glioma. J Clin Oncol 2000;18:646-650.
[30] Mandonnet E, De Witt Hamer P, Poisson I, et al. Initial experience using awake surgery for glioma: oncological, functional, and employment outcomes in a consecutive series of 25 cases. Neurosurgery 2015;76:382-389; discussion 389.
[31] Chaytor N, Schmitter-Edgecombe M. The ecological validity of neuropsychological tests: a review of the literature on everyday cognitive skills. Neuropsychol Rev 2003;13:181-197.
[32] Henriksson R, Asklund T, Poulsen HS. Impact of therapy on quality of life, neurocognitive function and their correlates in glioblastoma multiforme: a review. J Neurooncol 2011;104:639-646.
[33] Folstein MF, Folstein SE, McHugh PR. "Mini-mental state". A practical method for grading the cognitive state of patients for the clinician. J Psychiatr Res 1975;12:189-198.
[34] Nasreddine ZS, Phillips NA, Bedirian V, et al. The Montreal Cognitive Assessment, MoCA: a brief screening tool for mild cognitive impairment. J Am Geriatr Soc 2005;53:695-699.
[35] Meyers CA, Wefel JS. The use of the mini-mental state examination to assess cognitive functioning in cancer trials: no ifs, ands, buts, or sensitivity. J Clin Oncol 2003;21:3557-3558.
[36] Racine CA, Li J, Molinaro AM, et al. Neurocognitive function in newly diagnosed low-grade glioma patients undergoing surgical resection with awake mapping techniques. Neurosurgery 2015;77:371-9; discussion 379.
[37] Robinson GA, Biggs V, Walker DG. Cognitive screening in brain tumors: short but sensitive enough? Front Oncol 2015;5:60.
[38] McDermott LM, Ebmeier KP. A meta-analysis of depression severity and cognitive function. J Affect Disord 2009;119:1-8.
[39] Waters F, Bucks RS. Neuropsychological effects of sleep loss: implication for neuropsychologists. J Int Neuropsychol Soc 2011;17:571-586.
[40] Gehring K, Aaronson NK, Taphoorn MJ, et al. Interventions for cognitive deficits in patients with a brain tumor: an update. Expert Rev Anticancer Ther 2010;10:1779-1795.
[41] Noll KR, Bradshaw ME, Parsons MW, et al. Monitoring of neurocognitive function in the care of patients with Brain tumors. Curr Treat Options Neurol 2019;21:33.

Note: All recommendations are category 2A unless otherwise indicated.

Version 3.2025, 12/05/25 © 2025 National Comprehensive Cancer Network® (NCCN®), All rights reserved. NCCN Guidelines® and this illustration may not be reproduced in any form without the express written permission of NCCN.

PLEASE NOTE that use of this NCCN Content is governed by the End-User License Agreement, and you MAY NOT distribute this Content or use it with any artificial intelligence model or tool.
Printed by A. S. M. FAZLUL KARIM CHOWDHURY on 4/20/2026 3:06:38 AM. Copyright © 2026 National Comprehensive Cancer Network, Inc. All Rights Reserved.

PRINCIPLES OF BRAIN TUMOR PATHOLOGY

- **Incorporation of relevant diagnostic markers, including histopathologic and molecular information, as per the 5th edition of the WHO 2021 Classification of Tumors of the Central Nervous System, should be considered standard practice for tumor classification.**
- **Molecular/genetic characterization complements standard histologic analysis, providing additional diagnostic and prognostic information that can greatly improve diagnostic accuracy, influence treatment selection, and improve management decision-making.**

Standard Histopathologic Examination and Classification

- **Histologic subgrouping of CNS neoplasms provides valuable prognostic information, as is described in the WHO 2021 Classification of Tumors of the Central Nervous System.[1]**
- **Interobserver discrepancies in histologic diagnosis and grading are a recognized issue, due to the inherently subjective nature of certain aspects of histopathologic interpretation (eg, astrocytic vs. oligodendroglial morphology). Also, surgical sampling does not always capture all the relevant diagnostic features in morphologically heterogeneous tumors.**
- **Even so, the traditional histologic classification of CNS neoplasms into primary neuroectodermal neoplasms (eg, glial, neuronal, embryonal), other primary CNS neoplasms (eg, lymphoma, germ cell, meningeal), metastatic neoplasms, and non-neoplastic conditions mimicking tumors remains fundamental to any pathologic assessment.**

Molecular Characterization

- **With the use of genetic and molecular testing, histologically similar CNS neoplasms can be differentiated more accurately in terms of prognosis and, in some instances, response to different therapies.[2-6]**
- **Molecular characterization of primary CNS tumors has substantially impacted clinical trial eligibility and risk stratification in the past 10 years, thereby evolving the standard of care towards an integrated tumor diagnosis in neuro-oncology.**
- **Molecular/genetic characterization does not replace standard histologic assessment, but serves as a complementary approach to provide additional diagnostic and prognostic information that often enhances treatment selection.**
- **Genome-wide profiling of CpG methylation patterns has been shown to be a powerful way to classify brain tumors, including those with equivocal histologic features.[7] While this testing method is rapidly gaining popularity, it cannot yet be regarded as a gold standard for diagnosis in all cases, because some tumors have methylation patterns that are so rare they have not yet been correlated with specific clinical/biological behavior.**
- **Some diffusely infiltrative astrocytomas lack the histologic features of glioblastoma (necrosis and/or microvascular proliferation) but have the molecular hallmarks of glioblastoma, including one or more of the following: *IDH* wild-type; *EGFR* amplification; gain of chromosome 7 and loss of chromosome 10; and *TERT* promoter mutation. In such cases, the tumor can now be diagnosed as "Glioblastoma, *IDH* wild-type, WHO grade 4." Because these tumors have similar clinical outcomes as typical grade 4 glioblastomas, they may be treated as such.[8,9]**

Continued
References

Note: All recommendations are category 2A unless otherwise indicated.

Version 3.2025, 12/05/25 © 2025 National Comprehensive Cancer Network® (NCCN®), All rights reserved. NCCN Guidelines® and this illustration may not be reproduced in any form without the express written permission of NCCN.

PLEASE NOTE that use of this NCCN Content is governed by the End-User License Agreement, and you MAY NOT distribute this Content or use it with any artificial intelligence model or tool.
Printed by A. S. M. FAZLUL KARIM CHOWDHURY on 4/20/2026 3:06:38 AM. Copyright © 2026 National Comprehensive Cancer Network, Inc. All Rights Reserved.

PRINCIPLES OF BRAIN TUMOR PATHOLOGY: MOLECULAR MARKERS

The following molecular markers are often used by neuropathologists to facilitate characterization of gliomas and/or by neuro-oncologists to guide treatment decisions:

Molecular Characterization (continued)

- The Panel encourages molecular testing of glioblastoma because if a driver mutation (such as *BRAF* V600E mutation or *NTRK* fusion) is detected, it may be reasonable to treat with a targeted therapy on a compassionate use basis and/or the patient may have more treatment options in the context of a clinical trial. Molecular testing also has a valuable role in improving diagnostic accuracy and prognostic stratification that may inform treatment selection.
- The following comprises a high-yield list of alterations as informed by the 2021 WHO classification system, and is not comprehensive for all clinically relevant molecular alterations in all gliomas.
  - Mutations: *IDH1* R132 and *IDH2* R172, *TERT* promoter, *ATRX, EGFR, BRAF* V600E, and *H3-3A* mutation (K27 or G34)
  - Copy number alterations: 1p/19q codeletion, *EGFR* amplification, gain of chromosome 7, loss of chromosome 10, and *CDKN2A/B* deletion
- NGS is now the preferred approach for pathologic workup of CNS tumors, as it screens for multiple diagnostic and prognostic mutations in one test.
- NGS results from tumor tissue cannot prove the existence of a heritable cancer predisposition syndrome (eg, Lynch syndrome, Li-Fraumeni syndrome). If such a syndrome is suspected based on clinical and family history, genetic counseling and testing of "germline" DNA from the bloodstream is required.

***IDH1* and *IDH2* Mutation**

- Recommendation: *IDH* mutation testing is required for the workup of all gliomas.
- Description: *IDH1* and *IDH2* are metabolic enzymes. Specific mutations in genes encoding these enzymes lead to the aberrant production of D-2-hydroxyglutarate, an oncometabolite that causes epigenetic modifications in affected cells.[9] Diffusely infiltrative astrocytomas with *IDH* mutation are mostly WHO grade 2–3. However, some develop the traditional grade 4 histologic features of necrosis and/or microvascular proliferation, which does suggest more aggressive behavior and worse prognosis, but are still not as severe as *IDH* wild-type glioblastomas. Such tumors are now called "Astrocytoma, *IDH*-mutant, WHO grade 4," to distinguish them from *IDH* wild-type glioblastoma.[9,10] Some *IDH*-mutant astrocytomas do not show grade 4 histologic features, yet contain homozygous deletion in *CDKN2A/B*. These should also be called "Astrocytoma, *IDH*-mutant, WHO grade 4."[10-15]
- Detection: The most common *IDH1* mutation (R132H) is reliably screened by mutation-specific IHC, which is recommended for all patients with glioma. If the R132H immunostain result is negative, in the appropriate clinical context, sequencing of *IDH1* and *IDH2* is highly recommended to detect less common *IDH1* and *IDH2* mutations. Prior to age 55 years, sequencing of *IDH1* and *IDH2* is required if the R132H immunostain result is negative, or if the glioma is only grade 2 or 3 histologically. Standard sequencing methods include Sanger sequencing, pyrosequencing, and NGS, and can be performed on formalin-fixed, paraffin-embedded tissue.[8]
- Diagnostic value:
  - *IDH* mutations define WHO grade 2 and 3 astrocytomas and oligodendrogliomas, and grade 4 *IDH*-mutant astrocytomas. Their presence distinguishes lower-grade gliomas from glioblastomas, which are *IDH* wild-type.[10,16] Detection of these mutations in a specimen that is otherwise equivocal for tumor may also be regarded as evidence that a diffusely infiltrative glioma is present.[8]
  - True grade 1 non-infiltrative gliomas, such as PAs and gangliogliomas, do not contain *IDH* mutations. In such cases, detection of an *IDH* mutation indicates that the tumor is at least a grade 2 diffusely infiltrative glioma.[8]
- Prognostic value:
  - *IDH* mutations are commonly associated with *MGMT* (O6-methylguanine-DNA methyltransferase) promoter methylation.[4]
  - *IDH1* or *2* mutations are associated with a relatively favorable prognosis and are important in stratification for clinical trials.[17]
  - In grade 2 or 3 infiltrative gliomas, wild-type *IDH1* or *2* is associated with increased risk of aggressive disease.[4]
  - *IDH1* or *2* mutations are associated with a survival benefit for patients treated with radiation or alkylating systemic therapy.[18,19]

Continued
References

Note: All recommendations are category 2A unless otherwise indicated.

Version 3.2025, 12/05/25 © 2025 National Comprehensive Cancer Network® (NCCN®), All rights reserved. NCCN Guidelines® and this illustration may not be reproduced in any form without the express written permission of NCCN.

PLEASE NOTE that use of this NCCN Content is governed by the End-User License Agreement, and you MAY NOT distribute this Content or use it with any artificial intelligence model or tool.
Printed by A. S. M. FAZLUL KARIM CHOWDHURY on 4/20/2026 3:06:38 AM. Copyright © 2026 National Comprehensive Cancer Network, Inc. All Rights Reserved.

PRINCIPLES OF BRAIN TUMOR PATHOLOGY: MOLECULAR MARKERS

The following molecular markers are often used by neuropathologists to facilitate characterization of gliomas and/or by neuro-oncologists to guide treatment decisions:

Codeletion of 1p and 19q

- **Recommendation: 1p/19q testing is an essential part of molecular diagnostics for oligodendroglioma.**
- **Description: This codeletion represents an unbalanced translocation (1;19)(q10;p10), leading to whole-arm deletion of 1p and 19q.[20]**
- **Detection: The codeletion of 1p and 19q is detectable by array-based genomic copy number testing (preferable), or fluorescence in situ hybridization (FISH).**
- **Diagnostic value: 1p/19q codeletion is strongly associated with oligodendroglial histology and helps confirm the oligodendroglial character of tumors with equivocal or mixed histologic features.[21]**
  - ***IDH*-mutated gliomas that do NOT show loss of *ATRX* (for example, by IHC) should be strongly considered for 1p/19q testing, even if not clearly oligodendroglial by histology. Conversely, *IDH1* wild-type gliomas do not contain true whole-arm 1p/19q codeletion.[22] Therefore, 1p/19q testing is unnecessary if a glioma is definitely *IDH* wild-type, and a glioma should not be regarded as 1p/19q-codeleted without an accompanying *IDH* mutation, regardless of test results.**
  - **A tumor should only be diagnosed as an oligodendroglioma if it contains both an *IDH* mutation and 1p/19q codeletion. Furthermore, the term "oligoastrocytoma" should no longer be used, as such morphologically ambiguous tumors can reliably be resolved into astrocytomas and oligodendrogliomas with molecular testing.[23]**
- **Prognostic value: The codeletion confers a favorable prognosis and is predictive of response to alkylating systemic therapy with or without RT.[24,25]**

***MGMT* Promoter Methylation**

- **Recommendation: *MGMT* promoter methylation is an essential part of molecular diagnostics for all high-grade gliomas (grade 3 and 4).**
- **Description: *MGMT* is a DNA repair enzyme that reverses the DNA damage caused by alkylating agents, resulting in tumor resistance to temozolomide and nitrosourea-based systemic therapy. Methylation of the *MGMT* promoter silences *MGMT*, making the tumor more sensitive to treatment with alkylating agents.[26]**
- **Detection: There are multiple ways to test for *MGMT* promoter methylation, including methylation-specific polymerase chain reaction (PCR),[27] methylation-specific high-resolution melting, pyrosequencing,[28] and droplet-digital PCR. One study suggested that pyrosequencing is the best prognostic stratifier among glioblastomas treated with temozolomide.[29,30] However, quantitative methylation-specific (qMS)-PCR remains the assay that has had the most validation in clinical trials.[27]**
- **Prognostic value:**
  - ***MGMT* promoter methylation is strongly associated with *IDH* mutations and genome-wide epigenetic changes (G-CIMP phenotype).[4]**
  - ***MGMT* promoter methylation confers a survival advantage in glioblastoma and is used for risk stratification in clinical trials.[31]**
  - ***MGMT* promoter methylation is particularly useful in treatment decisions for older adult patients with high-grade gliomas (grades 3–4).[32,33]**
  - **Patients with glioblastoma that is not *MGMT* promoter methylated derive less benefit from treatment with temozolomide compared to those whose tumors are methylated.[31]**

Note: All recommendations are category 2A unless otherwise indicated.

Continued
References

Version 3.2025, 12/05/25 © 2025 National Comprehensive Cancer Network® (NCCN®), All rights reserved. NCCN Guidelines® and this illustration may not be reproduced in any form without the express written permission of NCCN.

PLEASE NOTE that use of this NCCN Content is governed by the End-User License Agreement, and you MAY NOT distribute this Content or use it with any artificial intelligence model or tool.
Printed by A. S. M. FAZLUL KARIM CHOWDHURY on 4/20/2026 3:06:38 AM. Copyright © 2026 National Comprehensive Cancer Network, Inc. All Rights Reserved.

PRINCIPLES OF BRAIN TUMOR PATHOLOGY: MOLECULAR MARKERS

The following molecular markers are often used by neuropathologists to facilitate characterization of gliomas and/or by neuro-oncologists to guide treatment decisions:

ATRX Mutation

- Recommendation: *ATRX* mutation testing is required for the workup of glioma.[34]
- Description:
  - *ATRX* encodes a chromatin regulator protein. Loss-of-function mutations enable alternative lengthening of telomeres.[35]
- Detection: *ATRX* mutations can be detected by IHC for wild-type *ATRX* (loss of wild-type expression) and/or sequencing.[36]
- Diagnostic value: *ATRX* mutations in glioma are strongly associated with *IDH* mutations, and are nearly always mutually exclusive with 1p/19q codeletion.[36,37] *ATRX* deficiency, coupled with *IDH* mutation and *TP53* mutation, is typical of astrocytoma. Since the *ATRX* immunostain can be false-negative due to thermal artifact, always interpret *ATRX* immunostaining using admixed nonneoplastic cells as positive controls (eg, endothelial cells, neurons, inflammatory cells). [5,36,38]

TERT (Promoter Mutation)

- Recommendation: *TERT* promoter mutation testing is recommended for the workup of gliomas.
- Description: *TERT* encodes telomerase, the enzyme responsible for maintaining telomere length in dividing cells. *TERT* mutations found in gliomas are located in its noncoding promoter region, and cause increased expression of the TERT protein.[39]
- Detection: *TERT* mutation can be detected by sequencing of the promoter region.[40]
- Diagnostic value: *TERT* promoter mutations are nearly always present in 1p/19q codeleted oligodendroglioma, and are found in most glioblastomas. *TERT* promoter mutation, in combination with *IDH* mutation and 1p/19q codeletion, is characteristic of oligodendroglioma. Absence of *TERT* promoter mutation, coupled with the presence of mutant *IDH*, strongly suggests astrocytoma.
- Prognostic value: In the absence of an *IDH* mutation, *TERT* promoter mutation in diffusely infiltrative gliomas is associated with reduced overall survival compared to similar gliomas lacking *TERT* promoter mutation.[4,41,42]
  Combined *TERT* promoter mutation and *IDH* mutations in the absence of 1p/19q codeletion is an uncommon event, but such tumors have a prognosis as favorable as gliomas with all three molecular alterations.[4,41]

H3-3A Mutation

- Recommendation: H3-3A and *HIST1H3B* mutation testing is recommended in the appropriate clinical context.
- Description:
  - The most common histone mutation in brain tumors, H3K27M, is caused by a lysine-to-methionine substitution in the *H3-3A* gene and inhibits the trimethylation of *H3.3* histone. *G34* mutations are more common in cortical gliomas in children.[43-45]
  - Another variant in *H3-3A*, resulting in a G34V (or R) mutation in histone 3.3, is characteristic of some diffusely infiltrative gliomas arising not in the midline, but in the cerebral hemispheres. These gliomas tend to occur in children and younger adults and are *IDH* wild-type but *ATRX* and *TP53* mutant. Thus, the 5th edition of the WHO classification calls these tumors "Diffuse hemispheric glioma, *H3.3 G34*-mutant, WHO grade 4."[1]
- Detection:
  - Diffuse midline gliomas should be screened for H3-3A mutations, specifically the H3K27M mutation. While sequencing is the gold standard, H3K27M-specific IHC, paired with H3K27 trimethylation immunostaining, is a reasonable alternative, especially when tissue is scarce. In these gliomas, H3K27M immunopositivity should be associated with loss of histone trimethylation immunostaining.[46-50]

Continued
References

Note: All recommendations are category 2A unless otherwise indicated.

Version 3.2025, 12/05/25 © 2025 National Comprehensive Cancer Network® (NCCN®), All rights reserved. NCCN Guidelines® and this illustration may not be reproduced in any form without the express written permission of NCCN.

PLEASE NOTE that use of this NCCN Content is governed by the End-User License Agreement, and you MAY NOT distribute this Content or use it with any artificial intelligence model or tool.
Printed by A. S. M. FAZLUL KARIM CHOWDHURY on 4/20/2026 3:06:38 AM. Copyright © 2026 National Comprehensive Cancer Network, Inc. All Rights Reserved.

PRINCIPLES OF BRAIN TUMOR PATHOLOGY: MOLECULAR MARKERS

The following molecular markers are often used by neuropathologists to facilitate characterization of gliomas and/or by neuro-oncologists to guide treatment decisions:

- Detection: (continued)
  - Although a *K27M* histone antibody is available,[51] it is not 100% specific and interpretation can be difficult for non-experts. Therefore, screening by *H3-3A* and *HIST1H3B* sequencing is a viable alternative and the preferred approach, especially since it will also detect mutations in *G34*.
- Diagnostic value: Histone mutations most commonly occur in pediatric midline gliomas (eg, diffuse intrinsic pontine gliomas [DIPG]), although midline gliomas in adults can also contain histone mutations.[52] Their presence can be considered solid evidence of an infiltrative glioma, which is often helpful in small biopsies of midline lesions that may not be fully diagnostic with light microscopy or do not fully resemble infiltrative gliomas.[43,44,53]
- Prognostic value: *K27M* gliomas typically do not have *MGMT* promoter methylation, and the mutation is an adverse prognostic marker in children and adults. The *G34* mutation does not appear to have any prognostic significance once the diagnosis of glioblastoma has been established.[44,53,54]

***BRAF* Mutation**

- Recommendation: *BRAF* fusion and/or mutation testing is recommended in the appropriate clinical context.
- Description: Activating mutations in *BRAF*, most commonly the V600E variant seen in other cancers (eg, melanoma), are present in a wide range of CNS tumors, including 60%–80% of supratentorial grade 2–3 PXAs, 30% of DNETs, 20% of grade 1 gangliogliomas, and 5% of grade 1 PAs. Diffusely infiltrative gliomas can also harbor a *BRAF* mutation, especially in children. *BRAF* V600E has even been found in nonneoplastic cortical dysplasia. In contrast, activating *BRAF* fusions can be seen in newer WHO entities including diffuse leptomeningeal glioneuronal tumor and HGAP and occur predominately in PA of the posterior fossa, although some supratentorial PA also have this fusion.[55-57]
- Detection: *BRAF* V600E is best detected by sequencing, and *BRAF* fusions can be detected with RNA sequencing or other PCR-based breakpoint methods that capture the main 16–9, 15–9, and 16–11 breakpoints between *BRAF* and its main fusion partner, *KIAA1549*. FISH is too unreliable to detect *BRAF* fusions.[55]
- Diagnostic value: The presence of a *BRAF* fusion is reliable evidence that the tumor is a PA, provided the histology is compatible. *BRAF* V600E is more complicated, as it can occur in a variety of tumors over all four WHO grades and requires integration with histology.[55]
- Prognostic value: Tumors with *BRAF* fusions tend to be indolent, with occasional recurrence but only rare progression to lethality. *BRAF* V600E tumors show a much greater range of outcomes and need to be considered in context with other mutations and clinicopathologic findings (eg, *CDKN2A/B* deletion). *BRAF* V600E tumors may respond to BRAF inhibitors such as vemurafenib, but comprehensive clinical trials are still ongoing.[52,58-59]

Ependymomas

- Detection:
  - Posterior fossa ependymomas are categorized as two groups: A (PFA) and B (PFB). PFA ependymomas are more common in infants and young children, and typically behave in a more aggressive manner than PFB ependymomas. Loss of H3K27 trimethylation by IHC is characteristic of PFA ependymomas, although genomic methylation profiling is the gold standard to differentiate PFA and PFB ependymomas, and should be used whenever possible.[9,60-65]

Note: All recommendations are category 2A unless otherwise indicated.

Continued
References

Version 3.2025, 12/05/25 © 2025 National Comprehensive Cancer Network® (NCCN®), All rights reserved. NCCN Guidelines® and this illustration may not be reproduced in any form without the express written permission of NCCN.

PLEASE NOTE that use of this NCCN Content is governed by the End-User License Agreement, and you MAY NOT distribute this Content or use it with any artificial intelligence model or tool.
Printed by A. S. M. FAZLUL KARIM CHOWDHURY on 4/20/2026 3:06:38 AM. Copyright © 2026 National Comprehensive Cancer Network, Inc. All Rights Reserved.

PRINCIPLES OF BRAIN TUMOR PATHOLOGY: MOLECULAR MARKERS

The following molecular markers are often used by neuropathologists to facilitate characterization of gliomas and/or by neuro-oncologists to guide treatment decisions:

Ependymomas (continued)

- ***ZFTA* Fusion**
  - Recommendation: Testing for *ZFTA* and *YAP1* fusions is recommended in the appropriate clinical context.
  - Description: Ependymomas arising in the supratentorium often contain activating fusions of *ZFTA*. This leads to increased NF-kappa-B signaling and more aggressive behavior. This event is more common in children than in adults, and occurs only in the supratentorium, not the posterior fossa or spine.[66,67]
  - Detection: *ZFTA* fusion can be detected with RNA sequencing or a break-apart FISH probe set.[68]
  - Diagnostic value: Detection of *ZFTA* fusion is not required for the diagnosis of ependymoma, as this entity is still diagnosed by light microscopy.
  - Prognostic value: *ZFTA* fusion-positive ependymomas are now a distinct entity in the WHO classification of CNS tumors, as this subset of ependymomas tends to be more aggressive than other supratentorial ependymomas, including those with *YAP1* fusions.[1,66,67,69]
- ***MYCN* Amplification**
  - A subset of spinal cord ependymomas show *MYCN* amplification. Such tumors tend to behave more aggressively, and are therefore now codified as SP-EPN-MYCN. As is often the case in other tumor types (eg, medulloblastoma), *MYCN* amplification is strongly associated with more aggressive behavior and worse prognosis. The difference in outcomes is distinct enough that a special diagnosis of "spinal ependymoma, MYCN-amplified" is now used in the new 5th WHO classification.[1]

Medulloblastoma Molecular Subtyping

- Recommendation: Medulloblastoma testing should be referred to academic tertiary centers with expertise in this area.
- Description:
  - Medulloblastomas are WHO grade 4 tumors that predominantly arise from the cerebellum in pediatric patients, but can also occur in adults. The WHO committee on CNS tumors now recommends subclassification of these tumors into four distinct groups: i) WNT-activated; ii) SHH-activated and *TP53*-mutant; iii) SHH-activated and *TP53*-wild type; and iv) non-WNT/non-SHH.[1,70]
- Detection: Virtually all WNT-driven medulloblastomas will contain mutations in either *CTNNB1* or, less commonly, *APC* (the latter mutation may be germline if the patient has Turcot syndrome). Unlike in children, 50% of adult medulloblastomas with loss of 6q and positive nuclear catenin had no *CTNNB1* mutations, pointing towards the possibility of alternative mechanisms of WNT pathway activation in adult medulloblastoma.[71] Adult and pediatric medulloblastomas are genetically distinct and require different algorithms for molecular risk stratification. WNT-driven tumors will also usually contain monosomy 6. 6q loss is not confined to WNT in adults; it is also described in SHH and Group 4. Monosomy 6 is a specific marker for pediatric WNT, but not for adult WNT.[72] However, nuclear staining for beta-catenin in WNT-medulloblastomas can be very focal and might be misinterpreted as negative or equivocal. Differentiating between WNT-activated, SHH-activated, and non-WNT/non-SHH tumors is best classified by DNA methylation arrays or an IHC panel composed of beta-catenin, *GAB1*, and *YAP1*. Because there are a variety of hotspots in *TP53*, gene sequencing is recommended in SHH-activated medulloblastomas.[73-76]
- Diagnostic value: None of the molecular markers associated with each medulloblastoma subtype is specific to medulloblastomas; the diagnosis of medulloblastoma is still made on the basis of light microscopy.
- Prognostic value: The most important aspect of medulloblastoma molecular diagnostics is that the WNT-activated subset has a markedly better prognosis relative to the other three subtypes, regardless of age at diagnosis. Among SHH-activated medulloblastomas, detection of *TP53* mutations is associated with more aggressive behavior, often in the setting of germline *TP53* mutations. Wildtype SHH-activated medulloblastomas have a variable course, and are uncommon in adults.[74-79] Non-WNT/non-SHH medulloblastomas also show a variable course.[1,70,77] WNT tumors have worse prognosis in adults compared to children based on retrospective data.[72] 6q loss and positive nuclear catenin have no clear prognostic role in adult medulloblastomas.

Continued
References

Note: All recommendations are category 2A unless otherwise indicated.

Version 3.2025, 12/05/25 © 2025 National Comprehensive Cancer Network® (NCCN®), All rights reserved. NCCN Guidelines® and this illustration may not be reproduced in any form without the express written permission of NCCN.

PLEASE NOTE that use of this NCCN Content is governed by the End-User License Agreement, and you MAY NOT distribute this Content or use it with any artificial intelligence model or tool.
Printed by A. S. M. FAZLUL KARIM CHOWDHURY on 4/20/2026 3:06:38 AM. Copyright © 2026 National Comprehensive Cancer Network, Inc. All Rights Reserved.

PRINCIPLES OF BRAIN TUMOR PATHOLOGY: MOLECULAR MARKERS

The following molecular markers are often used by neuropathologists to facilitate characterization of gliomas and/or by neuro-oncologists to guide treatment decisions:

Meningiomas

- **Recommendation: Genomic copy number profiling and DNA methylation profiling are recommended for recurrent meningiomas, grade 1 meningiomas that barely miss the official WHO grade 2 criteria (eg, 3 mitoses/1.6 mm,[80] or 2–3 "soft" histopathologic criteria), tumors that meet grade 2–3 histopathologic criteria, or those with specific histologic patterns (eg, chordoid, clear cell, rhabdoid, papillary).[81] Screening for *TERT* promoter mutations may also be considered.**
- **Description: The chromosomal alterations most consistently associated with aggressive behavior include the combination of -22q and -1p, as well as homozygous loss of *CDKN2A/B* on 9p21.[81] Other losses have also been implicated as adverse prognostic markers, but may vary according to the study.[80-88] Several classifiers predicated on aberrant genomic DNA methylation patterns also exist, and have been shown to add prognostic value beyond standard histopathologic grading.[81,82,86]**
- **Detection: Any validated assay that measures copy number imbalances across the entire genome may be used to evaluate meningiomas. Targeted assays like FISH, however, are not recommended because they do not cover enough of the genome. The Infinium MethylationEPIC 850K array is currently the most widely used assay for genomic methylation profiling, and when validated internally, can also screen for genomic copy number alterations. While certain pathologic mutations are associated with specific meningioma subtypes, none have sufficient diagnostic or prognostic value to warrant routine screening by NGS. Expression profiling of specific genes may also soon add prognostic value,[88] although such testing will eventually require additional external validation.**
- **Diagnostic value: Screening for chromosomal losses or *TERT* promoter mutations is not required for the diagnosis of meningioma. Methylation profiling, in contrast, may be of use in differentiating ambiguous cases from other mesenchymal-type tumors that arise in the dura, including sarcomas.**
- **Prognostic value: Concomitant loss of 22q and 1p is sufficient to assign CNS WHO grade 2 to a meningioma. Two or more whole-arm losses affecting chromosomes 6, 10, 14, or 18 also suggest higher risk tumors.[81] Homozygous loss of *CDKN2A/B* or *TERT* promoter mutation justify assigning CNS WHO grade 3 to a meningioma.[81]**

Note: All recommendations are category 2A unless otherwise indicated.

References

Version 3.2025, 12/05/25 © 2025 National Comprehensive Cancer Network® (NCCN®), All rights reserved. NCCN Guidelines® and this illustration may not be reproduced in any form without the express written permission of NCCN.

PLEASE NOTE that use of this NCCN Content is governed by the End-User License Agreement, and you MAY NOT distribute this Content or use it with any artificial intelligence model or tool.
Printed by A. S. M. FAZLUL KARIM CHOWDHURY on 4/20/2026 3:06:38 AM. Copyright © 2026 National Comprehensive Cancer Network, Inc. All Rights Reserved.

PRINCIPLES OF BRAIN TUMOR PATHOLOGY
REFERENCES

[1] Gritsch S, Batchelor TT, Gonzalez Castro LN. Diagnostic, therapeutic, and prognostic implications of the 2021 World Health Organization classification of tumors of the central nervous system. Cancer 2022;128:47-58.
[2] Weller M, Pfister SM, Wick W, et al. Molecular neuro-oncology in clinical practice: a new horizon. Lancet Oncol 2013;14:e370-379.
[3] Hegi ME, Stupp R. Withholding temozolomide in glioblastoma patients with unmethylated MGMT promoter--still a dilemma? Neuro Oncol 2015;17:1425-1427.
[4] Eckel-Passow JE, Lachance DH, Molinaro AM, et al. Glioma groups based on 1p/19q, IDH, and TERT promoter mutations in tumors. N Engl J Med 2015;372:2499-2508.
[5] Cancer Genome Atlas Research Network; Brat DJ, Verhaak RG, Aldape KD, et al. Comprehensive, integrative genomic analysis of diffuse lower-grade gliomas. N Engl J Med 2015;372:2481-2498.
[6] Dubbink HJ, Atmodimedjo PN, Kros JM, et al. Molecular classification of anaplastic oligodendroglioma using next-generation sequencing: a report of the prospective randomized EORTC Brain Tumor Group 26951 phase III trial. Neuro Oncol 2016;18:388-400.
[7] Capper D, Jones DTW, Sill M, et al. DNA methylation-based classification of central nervous system tumours. Nature 2018;555:469-474.
[8] Horbinski C. What do we know about IDH1/2 mutations so far, and how do we use it? Acta Neuropathol 2013;125:621-636.
[9] Brat DJ, Aldape K, Colman H, et al. cIMPACT-NOW update 3: recommended diagnostic criteria for "Diffuse astrocytic glioma, IDH-wildtype, with molecular features of glioblastoma, WHO grade IV." Acta Neuropathol 2018;136:805-810.
[10] Brat DJ, Aldape K, Colman H, et al. cIMPACT-NOW update 5: recommended grading criteria and terminologies for IDH-mutant astrocytomas. Acta Neuropathol 2020;139:603-608.
[11] Appay R, Dehais C, Maurage CA, et al. CDKN2A homozygous deletion is a strong adverse prognosis factor in diffuse malignant IDH-mutant gliomas. Neuro Oncol 2019;21:1519-1528.
[12] Cimino PJ, Holland EC. Targeted copy number analysis outperforms histologic grading in predicting patient survival for WHO grades II/III IDH-mutant astrocytomas. Neuro Oncol 2019;21:819-821.
[13] Reis GF, Pekmezci M, Hansen HM, et al. CDKN2A loss is associated with shortened overall survival in lower-grade (World Health Organization Grades II-III) astrocytomas. J Neuropathol Exp Neurol 2015;74:442-452.
[14] Shirahata M, Ono T, Stichel D, et al. Novel, improved grading system(s) for IDH-mutant astrocytic gliomas. Acta Neuropathol 2018;136:153-166.
[15] Yang RR, Shi ZF, Zhang ZY, et al. IDH mutant lower grade (WHO Grades II/III) astrocytomas can be stratified for risk by CDKN2A, CDK4 and PDGFRA copy number alterations. Brain Pathol 2020;30:541-553.
[16] Yan H, Parsons DW, Jin G, et al. IDH1 and IDH2 mutations in gliomas. N Engl J Med 2009;360:765-773.
[17] Sanson M, Marie Y, Paris S, et al. Isocitrate dehydrogenase 1 codon 132 mutation is an important prognostic biomarker in gliomas. J Clin Oncol 2009;27:4150-4154.
[18] Hartmann C, Hentschel B, Wick W, et al. Patients with IDH1 wild type anaplastic astrocytomas exhibit worse prognosis than IDH1-mutated glioblastomas, and IDH1 mutation status accounts for the unfavorable prognostic effect of higher age: implications for classification of gliomas. Acta Neuropathol 2010;120:707-718.
[19] Houillier C, Wang X, Kaloshi G, et al. IDH1 or IDH2 mutations predict longer survival and response to temozolomide in low-grade gliomas. Neurology 2010;75:1560-1566.
[20] Jenkins RB, Blair H, Ballman KV, et al. A t(1;19)(q10;p10) mediates the combined deletions of 1p and 19q and predicts a better prognosis of patients with oligodendroglioma. Cancer Res 2006;66:9852-9861.
[21] Burger PC, Minn AY, Smith JS, et al. Losses of chromosomal arms 1p and 19q in the diagnosis of oligodendroglioma. A study of paraffin-embedded sections. Mod Pathol 2001;14:842-853.
[22] Labussiere M, Idbaih A, Wang XW, et al. All the 1p19q codeleted gliomas are mutated on IDH1 or IDH2. Neurology 2010;74:1886-1890.
[23] Sahm F, Reuss D, Koelsche C, et al. Farewell to oligoastrocytoma: in situ molecular genetics favor classification as either oligodendroglioma or astrocytoma. Acta Neuropathol 2014;128:551-559.
[24] van den Bent MJ, Brandes AA, Taphoorn MJ, et al. Adjuvant procarbazine, lomustine, and vincristine chemotherapy in newly diagnosed anaplastic oligodendroglioma: long-term follow-up of EORTC brain tumor group study 26951. J Clin Oncol 2013;31:344-350.
[25] Cairncross G, Wang M, Shaw E, et al. Phase III trial of chemoradiotherapy for anaplastic oligodendroglioma: Long-term results of RTOG 9402. J Clin Oncol 2013;31:337-343.
[26] Esteller M, Garcia-Foncillas J, Andion E, et al. Inactivation of the DNA-repair gene MGMT and the clinical response of gliomas to alkylating agents. N Engl J Med 2000;343:1350-1354.
[27] Vlassenbroeck I, Califice S, Diserens AC, et al. Validation of real-time methylation-specific PCR to determine O6-methylguanine-DNA methyltransferase gene promoter methylation in glioma. J Mol Diagn 2008;10:332-337.
[28] Xie H, Tubbs R, Yang B. Detection of MGMT promoter methylation in glioblastoma using pyrosequencing. Int J Clin Exp Pathol 20s15;8:636-642.
[29] Quillien V, Lavenu A, Karayan-Tapon L, et al. Comparative assessment of 5 methods (methylation-specific polymerase chain reaction, methylight, pyrosequencing, methylation-sensitive high-resolution melting, and immunohistochemistry) to analyze o6-methylguanine-DNA-methyltranferase in a series of 100 glioblastoma patients. Cancer 2012;118:4201-4211.

Note: All recommendations are category 2A unless otherwise indicated.

Continued

Version 3.2025, 12/05/25 © 2025 National Comprehensive Cancer Network® (NCCN®), All rights reserved. NCCN Guidelines® and this illustration may not be reproduced in any form without the express written permission of NCCN.

PLEASE NOTE that use of this NCCN Content is governed by the End-User License Agreement, and you MAY NOT distribute this Content or use it with any artificial intelligence model or tool.
Printed by A. S. M. FAZLUL KARIM CHOWDHURY on 4/20/2026 3:06:38 AM. Copyright © 2026 National Comprehensive Cancer Network, Inc. All Rights Reserved.

PRINCIPLES OF BRAIN TUMOR PATHOLOGY
REFERENCES

[30] Bady P, Sciuscio D, Diserens AC, et al. MGMT methylation analysis of glioblastoma on the Infinium methylation BeadChip identifies two distinct CpG regions associated with gene silencing and outcome, yielding a prediction model for comparisons across datasets, tumor grades, and CIMP-status. Acta Neuropathol 2012;124:547-560.
[31] Hegi ME, Diserens AC, Gorlia T, et al. MGMT gene silencing and benefit from temozolomide in glioblastoma. N Engl J Med 2005;352:997-1003.
[32] Malmstrom A, Gronberg BH, Marosi C, et al. Temozolomide versus standard 6-week radiotherapy versus hypofractionated radiotherapy in patients older than 60 years with glioblastoma: the Nordic randomised, phase 3 trial. Lancet Oncol 2012;13:916-926.
[33] Wick W, Platten M, Meisner C, et al. Temozolomide chemotherapy alone versus radiotherapy alone for malignant astrocytoma in the elderly: the NOA-08 randomised, phase 3 trial. Lancet Oncol 2012;13:707-715.
[34] Ikemura M, Shibahara J, Mukasa A, et al. Utility of ATRX immunohistochemistry in diagnosis of adult diffuse gliomas. Histopathology 2016;69:260-267.
[35] Koschmann C, Calinescu AA, Nunez FJ, et al. ATRX loss promotes tumor growth and impairs nonhomologous end joining DNA repair in glioma. Sci Transl Med 2016;8:328ra28.
[36] Reuss DE, Sahm F, Schrimpf D, et al. ATRX and IDH1-R132H immunohistochemistry with subsequent copy number analysis and IDH sequencing as a basis for an "integrated" diagnostic approach for adult astrocytoma, oligodendroglioma and glioblastoma. Acta Neuropathol 2015;129:133-146.
[37] Hewer E, Vajtai I, Dettmer MS, et al. Combined ATRX/IDH1 immunohistochemistry predicts genotype of oligoastrocytomas. Histopathology 2026;68:272-278.
[38] Louis DN, Giannini C, Capper D, et al. cIMPACT-NOW update 2: diagnostic clarifications for diffuse midline glioma, H3K27M-mutant and diffuse astrocytoma/anaplastic astrocytoma, IDH-mutant. Acta Neuropathol 2018;135:639-642.
[39] Arita H, Narita Y, Fukushima S, et al. Upregulating mutations in the TERT promoter commonly occur in adult malignant gliomas and are strongly associated with total 1p19q loss. Acta Neuropathol 2013;126:267-276.
[40] Nikiforova MN, Wald AI, Melan MA, et al. Targeted next-generation sequencing panel (GlioSeq) provides comprehensive genetic profiling of central nervous system tumors. Neuro Oncol 2016;18:379-387.
[41] Killela PJ, Reitman ZJ, Jiao Y, et al. TERT promoter mutations occur frequently in gliomas and a subset of tumors derived from cells with low rates of self-renewal. Proc Natl Acad Sci U S A 2013;110:6021-6026.
[42] Arita H, Yamasaki K, Matsushita Y, et al. A combination of TERT promoter mutation and MGMT methylation status predicts clinically relevant subgroups of newly diagnosed glioblastomas. Acta Neuropathol Commun 2016;4:79.
[43] Schwartzentruber J, Korshunov A, Liu XY, et al. Driver mutations in histone H3.3 and chromatin remodelling genes in paediatric glioblastoma. Nature 2012;482:226-231.
[44] Sturm D, Witt H, Hovestadt V, et al. Hotspot mutations in H3F3A and IDH1 define distinct epigenetic and biological subgroups of glioblastoma. Cancer Cell 2012;22:425-437.
[45] Wu G, Broniscer A, McEachron TA, et al. Somatic histone H3 alterations in pediatric diffuse intrinsic pontine gliomas and non-brainstem glioblastomas. Nat Genet 2012;44:251-253.
[46] Louis DN, Giannini C, Capper D, et al. cIMPACT-NOW update 2: Diagnostic clarifications for diffuse midline glioma, H3K27M-mutant and diffuse astrocytoma/anaplastic astrocytoma, IDH-mutant. Acta Neuropathol 2018;135:639-642.
[47] Buczkowicz P, Hoeman C, Rakopoulos P, et al. Genomic analysis of diffuse intrinsic pontine gliomas identifies three molecular subgroups and recurrent activating ACVR1 mutations. Nat Genet 2014;46:451-456.
[48] Ryall S, Krishnatry R, Arnoldo A, et al. Targeted detection of genetic alterations reveal the prognostic impact of H3K27M and MAPK pathway aberrations in paediatric thalamic glioma. Acta Neuropathol Commun 2016;4:93.
[49] Ebrahimi A, Skardelly M, Schuhmann MU, et al. High frequency of H3K27m mutations in adult midline gliomas. J Cancer Res Clin Oncol 2019;145:839-850.
[50] Mackay A, Burford A, Carvalho D, et al. Integrated molecular meta-analysis of 1,000 pediatric high-grade and diffuse intrinsic pontine glioma. Cancer Cell 2017;32:520-537 e525.
[51] Bechet D, Gielen GG, Korshunov A, et al. Specific detection of methionine 27 mutation in histone 3 variants (H3K27M) in fixed tissue from high-grade astrocytomas. Acta Neuropathol 2014;128:733-741.
[52] Horbinski C, Nikiforova MN, Hagenkord JM, et al. Interplay among BRAF, p16, p53, and MIB1 in pediatric low-grade gliomas. Neuro Oncol 2012;14:777-789.
[53] Meyronet D, Esteban-Mader M, Bonnet C, et al. Characteristics of H3 K27M-mutant gliomas in adults. Neuro Oncol 2017;19:1127-1134.
[54] Khuong-Quang DA, Buczkowicz P, Rakopoulos P, et al. K27M mutation in histone H3.3 defines clinically and biologically distinct subgroups of pediatric diffuse intrinsic pontine gliomas. Acta Neuropathol 2012;124:439-447.
[55] Horbinski C. To BRAF or not to BRAF: is that even a question anymore? J Neuropathol Exp Neurol 2013;72:2-7.
[56] Qaddoumi I, Orisme W, Wen J, et al. Genetic alterations in uncommon low-grade neuroepithelial tumors: BRAF, FGFR1, and MYB mutations occur at high frequency and align with morphology. Acta Neuropathol 2016;131:833-845.
[57] Chappe C, Padovani L, Scavarda D, et al. Dysembryoplastic neuroepithelial tumors share with pleomorphic xanthoastrocytomas and gangliogliomas BRAF(V600E) mutation and expression. Brain Pathol 2013;23:574-583.
[58] Hawkins C, Walker E, Mohamed N, et al. BRAF-KIAA1549 fusion predicts better clinical outcome in pediatric low-grade astrocytoma. Clin Cancer Res 2011;17:4790-4798.
[59] Horbinski C, Hamilton RL, Nikiforov Y, Pollack IF. Association of molecular alterations, including BRAF, with biology and outcome in pilocytic astrocytomas. Acta Neuropathol 2010;119:641-649.

Note: All recommendations are category 2A unless otherwise indicated.

Continued

Version 3.2025, 12/05/25 © 2025 National Comprehensive Cancer Network® (NCCN®), All rights reserved. NCCN Guidelines® and this illustration may not be reproduced in any form without the express written permission of NCCN.

PLEASE NOTE that use of this NCCN Content is governed by the End-User License Agreement, and you MAY NOT distribute this Content or use it with any artificial intelligence model or tool.
Printed by A. S. M. FAZLUL KARIM CHOWDHURY on 4/20/2026 3:06:38 AM. Copyright © 2026 National Comprehensive Cancer Network, Inc. All Rights Reserved.

PRINCIPLES OF BRAIN TUMOR PATHOLOGY
REFERENCES

[60] Ellison DW, Aldape KD, Capper D, et al. cIMPACT-NOW update 7: Advancing the molecular classification of ependymal tumors. Brain Pathol 2020;30:863-866.
[61] Pajtler KW, Mack SC, Ramaswamy V, et al. The current consensus on the clinical management of intracranial ependymoma and its distinct molecular variants. Acta Neuropathol 2017;133:5-12.
[62] Neumann JE, Spohn M, Obrecht D, et al. Molecular characterization of histopathological ependymoma variants. Acta Neuropathol 2020;139:305-318.
[63] Pajtler KW, Witt H, Sill M, et al. Molecular classification of ependymal tumors across all CNS compartments, histopathological grades, and age groups. Cancer Cell 2015;27:728-743.
[64] Upadhyaya SA, Robinson GW, Onar-Thomas A, et al. Molecular grouping and outcomes of young children with newly diagnosed ependymoma treated on the multi-institutional SJYC07 trial. Neuro Oncol 2019;21:1319-1330.
[65] Panwalkar P, Clark J, Ramaswamy V, et al. Immunohistochemical analysis of H3K27me3 demonstrates global reduction in group-A childhood posterior fossa ependymoma and is a powerful predictor of outcome. Acta Neuropathol 2017;134:705-714.
[66] Parker M, Mohankumar KM, Punchihewa C, et al. C11orf95-RELA fusions drive oncogenic NF-kappaB signalling in ependymoma. Nature 2014;506:451-455.
[67] Pajtler KW, Witt H, Sill M, et al. Molecular classification of ependymal tumors across all CNS compartments, histopathological grades, and age groups. Cancer Cell 2015;27:728-743.
[68] Olsen TK, Panagopoulos I, Gorunova L, et al. Novel fusion genes and chimeric transcripts in ependymal tumors. Genes Chromosomes Cancer 2016;55:944-953.
[69] Hubner JM, Kool M, Pfister SM, et al. Epidemiology, molecular classification and WHO grading of ependymoma. J Neurosurg Sci 2018;62:46-50.
[70] Kool M, Korshunov A, Remke M, et al. Molecular subgroups of medulloblastoma: an international meta-analysis of transcriptome, genetic aberrations, and clinical data of WNT, SHH, Group 3, and Group 4 medulloblastomas. Acta Neuropathol 2012;123:473-484.
[71] Korshunov A, Remke M, Werft W, et al. Adult and pediatric medulloblastomas are genetically distinct and require different algorithms for molecular risk stratification. J Clin Oncol 2010;28:3054-3060.
[72] Remke M, Hielscher T, Northcott PA, et al. Adult medulloblastoma comprises three major molecular variants. J Clin Oncol 2011;29:2717-2723.
[73] Northcott PA, Buchhalter I, Morrissy AS, et al. The whole-genome landscape of medulloblastoma subtypes. Nature 2017;547:311-317.
[74] Ellison DW, Kocak M, Dalton J, et al. Definition of disease-risk stratification groups in childhood medulloblastoma using combined clinical, pathologic, and molecular variables. J Clin Oncol 2011;29:1400-1407.
[75] Schwalbe EC, Williamson D, Lindsey JC, et al. DNA methylation profiling of medulloblastoma allows robust subclassification and improved outcome prediction using formalin-fixed biopsies. Acta Neuropathol 2013;125:359-371.
[76] Taylor MD, Northcott PA, Korshunov A, et al. Molecular subgroups of medulloblastoma: the current consensus. Acta Neuropathol 2012;123:465-472.
[77] Zhukova N, Ramaswamy V, Remke M, et al. Subgroup-specific prognostic implications of TP53 mutation in medulloblastoma. J Clin Oncol 2013;31:2927-2935.
[78] Kool M, Jones DT, Jager N, et al. Genome sequencing of SHH medulloblastoma predicts genotype-related response to smoothened inhibition. Cancer Cell 2014;25:393-405.
[79] Waszak SM, Northcott PA, Buchhalter I, et al. Spectrum and prevalence of genetic predisposition in medulloblastoma: a retrospective genetic study and prospective validation in a clinical trial cohort. Lancet Oncol 2018;19:785-798.
[80] Choudhury A, Magill ST, Eaton CD, et al. Meningioma DNA methylation groups identify biological drivers and therapeutic vulnerabilities. Nat Genet 2022;54:649-659.
[81] Sahm F, Aldape KD, Brastianos PK, et al. cIMPACT-NOW update 8: Clarifications on molecular risk parameters and recommendations for WHO grading of meningiomas. Neuro Oncol 2025;27:319-330.
[82] Nassiri F, Liu J, Patil V, et al. A clinically applicable integrative molecular classification of meningiomas. Nature 2021;597:119-125.
[83] Youngblood MW, Miyagishima DF, Jin L, et al. Associations of meningioma molecular subgroup and tumor recurrence. Neuro Oncol 202; 23:783-794.
[84] Bayley JC 5th, Hadley CC, Harmanci AO, et al. Multiple approaches converge on three biological subtypes of meningioma and extract new insights from published studies. Sci Adv 2022; 8:eabm6247.
[85] Driver J, Hoffman SE, Tavakol S, et al. A molecularly integrated grade for meningioma. Neuro Oncol 2022;24:796-808.
[86] Sahm F, Schrimpf D, Stichel D, et al. DNA methylation-based classification and grading system for meningioma: a multicentre, retrospective analysis. Lancet Oncol 2017;18:682-694.
[87] Wang JZ, Patil V, Landry AP, et al. Molecular classification to refine surgical and radiotherapeutic decision-making in meningioma. Nat Med 2024;30:3173-3183.
[88] Chen WC, Choudhury A, Youngblood MW, et al. Targeted gene expression profiling predicts meningioma outcomes and radiotherapy responses. Nat Med 2023;29:3067-3076.

Note: All recommendations are category 2A unless otherwise indicated.

Version 3.2025, 12/05/25 © 2025 National Comprehensive Cancer Network® (NCCN®), All rights reserved. NCCN Guidelines® and this illustration may not be reproduced in any form without the express written permission of NCCN.

PLEASE NOTE that use of this NCCN Content is governed by the End-User License Agreement, and you MAY NOT distribute this Content or use it with any artificial intelligence model or tool.
Printed by A. S. M. FAZLUL KARIM CHOWDHURY on 4/20/2026 3:06:38 AM. Copyright © 2026 National Comprehensive Cancer Network, Inc. All Rights Reserved.

PRINCIPLES OF CANCER RISK ASSESSMENT AND COUNSELING

- **See the following for a thorough discussion of how and when to consider testing, important elements of pre-test counseling, points to consider when using multi-gene testing, how tumor testing can inform germline testing, important elements in post-test counseling, and the importance of family communication:**
  - **Principles of Cancer Risk Assessment and Counseling (NCCN Guidelines for Genetic/Familial High-Risk Assessment: Breast, Ovarian, Pancreatic, and Prostate [EVAL-A])**
- **For pedigree development, see Pedigree: First-, Second-, and Third-Degree Relatives of Proband (NCCN Guidelines for Genetic/Familial High-Risk Assessment: Breast, Ovarian, Pancreatic, and Prostate [EVAL-B])**

- **When to consider genetic testing for (tuberous sclerosis, phakomatoses including *NF1*, and VHL syndrome):**
  - **For Li-Fraumeni syndrome, see NCCN Guidelines for Genetic/Familial High-Risk Assessment: Breast, Ovarian, Pancreatic, and Prostate**
  - **For hereditary non-polyposis colorectal cancer (HNPCC or Lynch syndrome) and familial adenomatous polyposis (FAP)/attenuated FAP (AFAP) (for desmoid tumors), see NCCN Guidelines for Genetic/Familial High-Risk Assessment: Colorectal, Endometrial, and Gastric**
  - **For patients with personal/family history suggestive of other cancer predisposition syndromes, consider further genetics assessment**

Note: All recommendations are category 2A unless otherwise indicated.

Version 3.2025, 12/05/25 © 2025 National Comprehensive Cancer Network® (NCCN®), All rights reserved. NCCN Guidelines® and this illustration may not be reproduced in any form without the express written permission of NCCN.

PLEASE NOTE that use of this NCCN Content is governed by the End-User License Agreement, and you MAY NOT distribute this Content or use it with any artificial intelligence model or tool.
Printed by A. S. M. FAZLUL KARIM CHOWDHURY on 4/20/2026 3:06:38 AM. Copyright © 2026 National Comprehensive Cancer Network, Inc. All Rights Reserved.

ABBREVIATIONS

2HG	2-hydroxyglutarate
3D	three-dimensional
3D-CRT	three-dimensional conformal radiation therapy
ACTH	adrenocorticotropic hormone
AFAP	attenuated familial adenomatous polyposis
ARV	antiretroviral
ASL	arterial spin labeling
BED	biologically effective dose
CBC	complete blood count
CNS	central nervous system
CR	complete response
CRu	complete response, unconfirmed
CSF	cerebrospinal fluid
CSI	craniospinal irradiation
CTV	clinical target volume
DCE	dynamic contrast-enhanced
DIPG	diffuse intrinsic pontine glioma
dMMR	mismatch repair deficient
DNET	dysembryoplastic neuroepithelial tumor
DSC	dynamic susceptibility contrast
DWI	diffusion-weighted imaging
EBRT	external beam radiation therapy
EIAED	enzyme-inducing antiepileptic drug
FAP	familial adenomatous polyposis
FISH	fluorescence in situ hybridization
FLAIR	fluid-attenuated inversion recovery
FSH	follicle-stimulating hormone
GBCA	gadolinium-based contrast agent
GH	growth hormone
GI	gastrointestinal
GFR	glomerular filtration rate
GTV	gross tumor volume
HA	hippocampal avoidance
HA-WBRT	hippocampal avoidance with WBRT
HBV	hepatitis B virus
HGAP	high-grade astrocytoma with piloid features
HCT	hematopoietic cell transplant
HIV	human immunodeficiency virus
HNPCC	hereditary non-polyposis colorectal cancer
IGF-1	insulin-like growth factor 1
IGRT	image-guided radiation therapy
IHC	immunohistochemistry
IMRT	intensity-modulated radiation therapy
ISH	in situ hybridization
ISRT	involved-site radiation therapy
KPS	Karnofsky Performance Status
LDH	lactate dehydrogenase
LH	luteinizing hormone
LITT	laser interstitial thermal therapy
MMSE	Mini-Mental State Examination
MoCA	Montreal Cognitive Assessment
MR	magnetic resonance
MRS	magnetic resonance spectroscopy
MSI-H	microsatellite instability-high
NF1	neurofibromatosis type 1
NF2	neurofibromatosis type 2
NGS	next-generation sequencing
NSAID	nonsteroidal anti-inflammatory drug
NSCLC	non-small cell lung cancer
NSF	nephrogenic systemic fibrosis
PA	pilocytic astrocytoma
PCR	polymerase chain reaction
PFA	posterior fossa type A
PFB	posterior fossa type B
PFS	progression-free survival
PJP	pneumocystis jiroveci pneumonia
PN	plexiform neurofibromas
PS	performance status
PTV	planning target volume
PXA	pleomorphic xanthoastrocytoma
qMS	quantitative methylation-specific
QOL	quality of life

Continued

Version 3.2025, 12/05/25 © 2025 National Comprehensive Cancer Network® (NCCN®), All rights reserved. NCCN Guidelines® and this illustration may not be reproduced in any form without the express written permission of NCCN.

PLEASE NOTE that use of this NCCN Content is governed by the End-User License Agreement, and you MAY NOT distribute this Content or use it with any artificial intelligence model or tool.
Printed by A. S. M. FAZLUL KARIM CHOWDHURY on 4/20/2026 3:06:38 AM. Copyright © 2026 National Comprehensive Cancer Network, Inc. All Rights Reserved.

ABBREVIATIONS

RCC	renal cell carcinoma
SBRT	stereotactic body radiation therapy
SEGA	subependymal giant cell astrocytoma
SHH	sonic hedgehog
SIB	simultaneous integrated boost
SRS	stereotactic radiosurgery
SRT	stereotactic radiation therapy
SSTR	somatostatin receptor
STIR	short tau inversion recovery
SWI	susceptibility-weighted imaging
T1WI	T1-weighted imaging
T2WI	T2-weighted imaging
T2WI-FLAIR	T2-weighted imaging fluid-attenuated inversion recovery
tDNA	tumor-derived deoxyribonucleic acid
TMB-H	tumor mutational burden-high
TPS	tumor proportion score
TSH	thyroid-stimulating hormone
TTF	tumor treating field
VHL	von Hippel-Lindau
VMAT	volumetric modulated arc therapy
VP	ventriculoperitoneal
VTE	venous thromboembolism
WBC	white blood cell
WBRT	whole brain radiation therapy

Version 3.2025, 12/05/25 © 2025 National Comprehensive Cancer Network® (NCCN®), All rights reserved. NCCN Guidelines® and this illustration may not be reproduced in any form without the express written permission of NCCN.

PLEASE NOTE that use of this NCCN Content is governed by the End-User License Agreement, and you MAY NOT distribute this Content or use it with any artificial intelligence model or tool.
Printed by A. S. M. FAZLUL KARIM CHOWDHURY on 4/20/2026 3:06:38 AM. Copyright © 2026 National Comprehensive Cancer Network, Inc. All Rights Reserved.

NCCN Categories of Evidence and Consensus	
Category 1	Based upon high-level evidence (≥1 randomized phase 3 trials or high-quality, robust meta-analyses), there is uniform NCCN consensus (≥85% support of the Panel) that the intervention is appropriate.
Category 2A	Based upon lower-level evidence, there is uniform NCCN consensus (≥85% support of the Panel) that the intervention is appropriate.
Category 2B	Based upon lower-level evidence, there is NCCN consensus (≥50%, but <85% support of the Panel) that the intervention is appropriate.
Category 3	Based upon any level of evidence, there is major NCCN disagreement that the intervention is appropriate.

All recommendations are category 2A unless otherwise indicated.

NCCN Categories of Preference	
Preferred intervention	Interventions that are based on superior efficacy, safety, and evidence; and, when appropriate, affordability.
Other recommended intervention	Other interventions that may be somewhat less efficacious, more toxic, or based on less mature data; or significantly less affordable for similar outcomes.
Useful in certain circumstances	Other interventions that may be used for selected patient populations (defined with recommendation).

All recommendations are considered appropriate.

Version 3.2025, 12/05/25 © 2025 National Comprehensive Cancer Network® (NCCN®), All rights reserved. NCCN Guidelines® and this illustration may not be reproduced in any form without the express written permission of NCCN.

PLEASE NOTE that use of this NCCN Content is governed by the End-User License Agreement, and you MAY NOT distribute this Content or use it with any artificial intelligence model or tool.
Printed by A. S. M. FAZLUL KARIM CHOWDHURY on 4/20/2026 3:06:38 AM. Copyright © 2026 National Comprehensive Cancer Network, Inc. All Rights Reserved.

Discussion

This discussion corresponds to the NCCN Guidelines for Central Nervous System Cancers. Last updated: September 28, 2022.

Table of Contents

Overview **MS-2**

Literature Search Criteria and Guidelines Update Methodology **MS-2**

Principles of Management **MS-2**

Treatment Principles **MS-3**

Gliomas **MS-3**

- Molecular Profiling for Gliomas MS-4
- Low-Grade Gliomas MS-7
- High-Grade Gliomas (Including Glioblastoma) MS-12

Intracranial and Spinal Ependymomas **MS-21**

- Molecular Markers MS-21
- Treatment Overview MS-21
- NCCN Recommendations MS-22

Adult Medulloblastoma **MS-24**

- Treatment Overview MS-24
- NCCN Recommendations MS-25

Primary CNS Lymphomas **MS-26**

- Treatment Overview MS-26
- NCCN Recommendations MS-29

Primary Spinal Cord Tumors **MS-32**

- Treatment Overview MS-32
- NCCN Recommendations MS-33

Meningiomas **MS-34**

- Imaging MS-34
- Treatment Overview MS-34
- NCCN Recommendations MS-36

Brain Metastases **MS-36**

- Treatment Overview MS-37
- NCCN Recommendations MS-45

Leptomeningeal Metastases **MS-47**

- Treatment Overview MS-47
- NCCN Recommendations MS-48

Metastatic Spinal Tumors **MS-50**

- Treatment Overview MS-50
- NCCN Recommendations MS-53

References **MS-56**

Discussion update in progress

Version 3.2025 © 2025 National Comprehensive Cancer Network© (NCCN©), All rights reserved. NCCN Guidelines® and this illustration may not be reproduced in any form without the express written permission of NCCN.

PLEASE NOTE that use of this NCCN Content is governed by the End-User License Agreement, and you MAY NOT distribute this Content or use it with any artificial intelligence model or tool.
Printed by A. S. M. FAZLUL KARIM CHOWDHURY on 4/20/2026 3:06:38 AM. Copyright © 2026 National Comprehensive Cancer Network, Inc. All Rights Reserved.

Overview

In the year 2022, an estimated 25,050 people in the United States will be diagnosed with a malignant primary central nervous system (CNS) tumor, and these tumors will be responsible for approximately 18,280 deaths.[1] Though survival for CNS cancers has largely improved in recent decades, less improvement has been observed in older adults, due to higher incidence of glioblastoma in this population.[2]

The NCCN Guidelines for CNS Cancers focus on management of the following adult CNS cancers: glioma (WHO grade 1, oligodendroglioma [1p19q codeleted, *IDH*-mutant], *IDH*-mutant astrocytoma, glioblastoma), intracranial and spinal ependymomas, medulloblastoma, limited and extensive brain metastases, leptomeningeal metastases, non–AIDS-related primary CNS lymphomas (PCNSLs), metastatic spine tumors, meningiomas, and primary spinal cord tumors. These guidelines are updated annually to include new information or treatment philosophies as they become available. However, because this field continually evolves, practitioners should use all of the available information to determine the best clinical options for their patients.

Literature Search Criteria and Guidelines Update Methodology

Prior to the update of this version of the NCCN Guidelines for Central Nervous System Cancers, an electronic search of the PubMed database was performed to obtain key literature in the field of neuro-oncology, using the following search terms: {[(brain OR spine OR spinal OR supratentorial OR cranial OR intracranial OR leptomeningeal) AND (cancer OR carcinoma OR tumor OR metastases OR lesion)] OR glioma OR astrocytoma OR oligodendroglioma OR glioblastoma OR ependymoma OR medulloblastoma OR (primary central nervous system lymphoma) OR meningioma}. The PubMed database was chosen because it remains the most widely used resource for medical literature and indexes peer-reviewed biomedical literature.[3]

NCCN recommendations have been developed to be inclusive of individuals of all sexual and gender identities to the greatest extent possible. When citing data and recommendations from other organizations, the terms *men*, *male*, *women*, and *female* will be used to be consistent with the cited sources.

Principles of Management

Primary brain tumors are a heterogeneous group of neoplasms with varied outcomes and management strategies. Primary brain tumors range from pilocytic astrocytomas, which are very uncommon, noninvasive, and surgically curable, to glioblastoma, the most common malignant brain tumor in adults, which is highly invasive and virtually incurable. Brain metastases can also be quite variable. These patients may have one or dozens of brain metastases, and they may have a malignancy that is highly responsive or, alternatively, highly resistant to radiation therapy (RT) or systemic therapy. Moreover, patients with brain metastases may have rapidly progressive systemic disease or no systemic cancer at all. Because of this marked heterogeneity, the prognostic features and treatment options for primary and metastatic brain tumors must be carefully reviewed on an individual basis and sensitively communicated to each patient. In addition, these CNS tumors are associated with a range of symptoms such as seizures, fatigue, psychiatric disorders, impaired mobility, neurocognitive dysfunction, difficulty speaking, and short-term memory problems, as well as complications such as intracerebral edema, endocrinopathies, and venous thromboembolism that can seriously impact patients' quality of life.

The involvement of an interdisciplinary team, including neurosurgeons, radiation oncologists, medical oncologists, neurologists, and

Discussion update in progress

Version 3.2025 © 2025 National Comprehensive Cancer Network© (NCCN©), All rights reserved. NCCN Guidelines® and this illustration may not be reproduced in any form without the express written permission of NCCN.

PLEASE NOTE that use of this NCCN Content is governed by the End-User License Agreement, and you MAY NOT distribute this Content or use it with any artificial intelligence model or tool.
Printed by A. S. M. FAZLUL KARIM CHOWDHURY on 4/20/2026 3:06:38 AM. Copyright © 2026 National Comprehensive Cancer Network, Inc. All Rights Reserved.

neuroradiologists, is a key factor in the appropriate management of these patients. For any type of malignant brain tumors, the NCCN Panel strongly recommends brain tumor board for multidisciplinary review of each patient's case once the pathology report is available. Further discussion of multidisciplinary care and allied services, as well as guidelines on medical management of various disease complications, can be found in *Principles of Brain and Spine Tumor Management* in the algorithm.

Treatment Principles

The information contained in the algorithms and principles of management sections in the NCCN Guidelines for CNS Cancers are designed to help clinicians navigate through the complex management of patients with CNS tumors. Several important principles guide surgical management and treatment with RT and systemic therapy for adults with brain tumors.

Regardless of tumor histology, neurosurgeons generally provide the best outcome for their patients if they remove as much tumor as safely possible (ideally achieving a gross total resection [GTR]) and thereby provide sufficient representative tumor tissue to ensure an accurate diagnosis. Decisions regarding aggressiveness of surgery for primary and metastatic brain tumors are complex and depend on the: 1) age and performance status (PS) of the patient; 2) proximity to "eloquent" areas of the brain; 3) feasibility of decreasing the mass effect with aggressive surgery; 4) resectability of the tumor (including the number and location of lesions); and 5) time since last surgery in patients with recurrent disease.[4] Further discussion can be found in the *Principles of Brain Tumor Surgery* in the algorithm. It is recommended to consult neurosurgeons with extensive experience in the management of intracranial and spine neoplasms.

Surgical options include stereotactic biopsy, open biopsy, subtotal resection (STR), or GTR. The pathologic diagnosis is critical and may be difficult to accurately determine without sufficient tumor tissue. Review of the tumor tissue by an experienced neuropathologist is highly recommended. The *Principles of Brain Tumor Pathology* describe guiding principles for diagnosis of CNS tumor pathology, given the addition of molecular parameters for accurately diagnosing primary brain tumors in the 2016 WHO classification of CNS tumors[5], which were further expanded upon in the 2021 WHO classification.[6]

Radiation oncologists use several different treatment modalities to treat patients with primary brain tumors. Standard fractionated external beam RT (EBRT) is the most common approach and is administered within a limited field (covering tumor or surgical cavity and a small margin of adjacent brain tissue). Hypofractionated radiation is an appropriate option for select patients (ie, older adults and patients with a poor PS). For the treatment of brain metastases, whole-brain RT (WBRT) and stereotactic radiosurgery (SRS) are primarily used. The dose of RT administered varies depending on the type of tumor, as discussed in the *Principles of Radiation Therapy for Brain and Spinal Cord*.

Regarding systemic therapy, multiple options exist for treating brain tumors. Alkylating agents remain the most effective chemotherapy for primary brain tumors. For brain metastases, choice of systemic therapy should be based on an agent's activity against the primary tumor and the ability of the agent to cross the blood-brain barrier (BBB). Standard systemic therapy options for each tumor subtype are listed in the *Principles of Brain and Spinal Cord Tumor Systemic Therapy*; however, since the efficacy of these chemotherapies is limited and better treatments for brain tumors are needed, enrollment in a clinical trial is the preferred treatment for eligible patients.

Gliomas

The NCCN Guidelines for CNS Cancers include recommendations for management of the following adult gliomas:[6]

Discussion update in progress

Version 3.2025 © 2025 National Comprehensive Cancer Network© (NCCN©), All rights reserved. NCCN Guidelines® and this illustration may not be reproduced in any form without the express written permission of NCCN.

PLEASE NOTE that use of this NCCN Content is governed by the End-User License Agreement, and you MAY NOT distribute this Content or use it with any artificial intelligence model or tool.
Printed by A. S. M. FAZLUL KARIM CHOWDHURY on 4/20/2026 3:06:38 AM. Copyright © 2026 National Comprehensive Cancer Network, Inc. All Rights Reserved.

- WHO Grade 1: pilocytic astrocytoma, pleomorphic xanthoastrocytoma, ganglioglioma, and subependymal giant cell astrocytoma (SEGA)
- Oligodendrogliomas (*IDH*-mutant, 1p19q codeleted)
- *IDH*-mutant astrocytoma
- Glioblastoma

Molecular Profiling for Gliomas

Integrated histopathologic and molecular characterization of gliomas, as per WHO classification,[6] should be standard practice. Molecular/genetic characterization complements standard histologic analysis, providing additional diagnostic and prognostic information that improves diagnostic accuracy and aids in treatment selection and management decision-making. Histopathologic and molecular analysis of CNS tumors is limited by inter-observer discrepancies and surgical sampling that doesn't always capture all relevant diagnostic features in morphologically heterogeneous tumors.

Updated Classification of Gliomas Based on Histology and Molecular Features

In 2016, the WHO classification for grade 2–3 gliomas was revised as follows: 1) oligodendrogliomas were gliomas that have whole arm 1p/19q codeletion and *IDH1* or *IDH2* (together referred to as "*IDH*") mutation (unless molecular data were not available and could not be obtained, in which case designation was based on histology with appropriate caveats); 2) anaplastic gliomas were further subdivided according to *IDH* mutation status; and 3) oligoastrocytoma was no longer a valid designation unless molecular data (1p/19q codeletion and *IDH* mutation status) were not available and could not be obtained.[5] Such tumors were described as "oligoastrocytoma, not otherwise specified (NOS)" to indicate that the characterization of the tumor was incomplete. Very rare cases of concurrent, spatially distinct oligodendroglioma (1p/19q codeleted) and astrocytoma (1p/19q intact) components in the same tumor could also be labeled oligoastrocytoma.[5] Correlations between the molecularly defined 2016 WHO categories and the histology-based 2007 WHO categories were limited and varied across studies.[7-10] Thus, the change from 2007 WHO to 2016 WHO reclassified a large proportion of gliomas.

The fifth edition of the WHO classification of CNS tumors was published in 2021.[6,11] In this newest classification, adult diffuse gliomas are subsumed within a supercategory of gliomas and glioneuronal tumors, and are split into three subtypes: 1) *IDH*-mutant astrocytoma; 2) oligodendroglioma, 1p/19q-codeleted and *IDH*-mutant; and 3) glioblastoma, *IDH* wild-type. WHO grades are now further specified for select CNS tumors, including diffuse gliomas. Specifically, *IDH*-mutant astrocytoma can be grade 2, 3, or 4. Oligodendroglioma (1p/19q-codeleted and *IDH*-mutant) can be grade 2 or 3. Glioblastoma, *IDH* wild-type, can only be grade 4. This updated classification further takes into account the importance of molecular data for accurately diagnosing CNS tumors.[6]

Multiple independent studies on gliomas have conducted genome-wide analyses evaluating an array of molecular features, including DNA copy number, DNA methylation, and mutations, in large populations of patients with grade 2–4 tumors.[9,12,13] Unsupervised clustering analyses, an unbiased method for identifying molecularly similar tumors, have been used to identify subgroups of gliomas with distinct molecular profiles.[9,12,13] Remarkably, further analysis has shown that these molecular subgroups could be distinguished based on only a handful of molecular features, including *IDH* mutation and 1p/19q codeletion, biomarkers independently verified by numerous studies as hallmarks for distinguishing molecular subgroups in grade 2–3 gliomas.[7-10,13-19] The unsupervised clustering analysis published by the Cancer Genome Atlas Research Network

Discussion update in progress

Version 3.2025 © 2025 National Comprehensive Cancer Network© (NCCN©), All rights reserved. NCCN Guidelines® and this illustration may not be reproduced in any form without the express written permission of NCCN.

PLEASE NOTE that use of this NCCN Content is governed by the End-User License Agreement, and you MAY NOT distribute this Content or use it with any artificial intelligence model or tool.
Printed by A. S. M. FAZLUL KARIM CHOWDHURY on 4/20/2026 3:06:38 AM. Copyright © 2026 National Comprehensive Cancer Network, Inc. All Rights Reserved.

supports the idea that the majority of grade 2–3 tumors can be divided into three molecular subtypes: 1) mutation of *IDH* with 1p/19q codeletion; 2) *IDH*-mutant with no 1p/19q codeletion; and 3) no mutation of *IDH* (ie, *IDH* wild-type).[9] Multiple studies have shown that the 1p/19q codeletion is strongly associated with *IDH* mutations, such that true whole-arm 1p/19q codeletion in *IDH* wild-type tumors is extremely rare.[7,8,16,20,21] In a tumor that is equivocal, the presence of an *IDH* mutation indicates at least a grade 2 diffusely infiltrative glioma.[22] Some *IDH*-mutant diffusely infiltrative astrocytomas develop the traditional grade 4 histologic features of necrosis and/or microvascular proliferation, which suggest more aggressive behavior and worse prognosis, but still not as severe as *IDH* wild-type glioblastoma. Such tumors are now referred to as astrocytoma, *IDH*-mutant, WHO grade 4, to distinguish them from *IDH* wild-type glioblastoma.[23,24] Grade 1 non-infiltrative gliomas do not have *IDH* mutations.[22]

Other mutations commonly detected in gliomas can have diagnostic and prognostic value, such as those involving the histone chaperone protein, ATRX, which is most often found in grade 2–3 gliomas and secondary glioblastomas.[25,26] *ATRX* mutation is robustly associated with *IDH* mutations, and this combination, along with *TP53* mutations, is diagnostic of astrocytoma.[27] In contrast, *ATRX* mutation is nearly always mutually exclusive with 1p/19q codeletion. Since loss of normal nuclear ATRX immunostaining is a fairly reliable indicator of an *ATRX* mutation, an *IDH* mutant glioma that has loss of normal nuclear *ATRX* immunostaining is much more likely to be an astrocytoma than an oligodendroglioma.

Mutations in the promoter region of the *telomerase reverse transcriptase* (*TERT*) gene occur frequently in *IDH* wild-type glioblastomas and *IDH* mutant, 1p/19q codeleted oligodendrogliomas.[28,29] Absence of *TERT* promoter mutation, coupled with *IDH* mutation and lack of 1p/19q codeletion, is indicative of astrocytoma. Some *IDH* wild-type diffusely infiltrative astrocytomas lack the histologic features of glioblastoma (necrosis and/or microvascular proliferation) but have one or more molecular hallmarks of glioblastoma, including the following: *EGFR* amplification; gain of chromosome 7 and loss of chromosome 10; and *TERT* promoter mutation. In such cases, the tumor can still be diagnosed as glioblastoma, *IDH* wild-type, WHO grade 4. These tumors have similar clinical outcomes as typical histologic grade 4 *IDH* wild-type glioblastomas, so they may be managed accordingly.[22,24] Similarly, the 2021 updated WHO classification of CNS tumors also now includes *CDKN2A/B* homozygous deletion as evidence of grade 4 status in *IDH* mutant astrocytomas, even if such astrocytomas lack necrosis and microvascular proliferation.[6,23,30-33]

H3K27M mutations in the histone-encoding *H3-3A* gene are mostly found in diffuse midline gliomas in both children and adults.[34] Patients with these H3K27M mutated gliomas tend to have a very poor prognosis regardless of histologic appearance, so they are classified as WHO grade 4.[34,35] Another variant in *H3-3A*, resulting in a G34V (or R) mutation in histone 3.3, is characteristic of some diffusely infiltrative gliomas arising not in the midline, but in the cerebral hemispheres. These gliomas tend to occur in children and younger adults and are *IDH* wild-type, but still have mutations in *ATRX* and *TP53*. Thus, the 5th edition of the WHO classification calls these tumors “Diffuse hemispheric glioma, H3.3 G34-mutant, WHO grade 4.”[6] H3K27M immunopositivity is associated with loss of histone trimethylation immunostaining in diffuse midline gliomas.[36-40] The presence of a histone mutation can be considered solid evidence of an infiltrative glioma, which is often helpful in small biopsies of midline lesions that may not be fully diagnostic with light microscopy and/or do not clearly look like infiltrative gliomas.[34,41] Both kinds of *H3-3A* mutant gliomas are now subsumed by the 2021 WHO classification under “pediatric-type diffuse high grade gliomas,” even if such tumors arise in adults.[6,11] Histone-driven

Discussion update in progress

Version 3.2025 © 2025 National Comprehensive Cancer Network© (NCCN©), All rights reserved. NCCN Guidelines® and this illustration may not be reproduced in any form without the express written permission of NCCN.

PLEASE NOTE that use of this NCCN Content is governed by the End-User License Agreement, and you MAY NOT distribute this Content or use it with any artificial intelligence model or tool.
Printed by A. S. M. FAZLUL KARIM CHOWDHURY on 4/20/2026 3:06:38 AM. Copyright © 2026 National Comprehensive Cancer Network, Inc. All Rights Reserved.

gliomas are no longer called glioblastomas, as that term is now reserved exclusively for *IDH* wild-type gliomas meeting the criteria discussed above.

Prognostic Relevance of Molecular Subgroups in Glioma

Numerous large studies of patients with brain tumors have determined that, among WHO grade 2–3 gliomas, 1p/19q codeletion correlates with greatly improved progression-free survival (PFS) and overall survival (OS).[8,13,14,42-44] Likewise, the presence of an *IDH* mutation is a strong favorable prognostic marker for OS in grade 2–3 gliomas.[9,16] Analyses within single treatment arms showed that the *IDH* status is prognostic for outcome across a variety of postoperative adjuvant options. For example, in the NOA-04 phase III randomized trial, *IDH* mutation was associated with improved PFS, longer time to treatment failure, and extended OS in each of the three treatment arms: standard RT (n = 160); combination therapy with procarbazine, lomustine, and vincristine (PCV; RT upon progression; n = 78); and temozolomide (TMZ; RT upon progression; n = 80).[43]

Multiple independent studies, covering multiple grades and histology-based subtypes of gliomas,[9,13,42] as well as smaller studies limited to 1 to 2 grades or histologic subtypes,[8,45-47] have consistently supported the subdivision of gliomas by molecular subtype (eg, by *IDH* and 1p/19q status) as recommended by the WHO 2021 CNS tumor classification, as this yields greater prognostic separation than subdivision by histology alone. Multiple studies have shown that, among patients with grade 2–3 gliomas, the *IDH*-mutant plus 1p/19q-codeletion group (ie, oligodendroglioma) has the best prognosis, followed by *IDH*-mutant without 1p/19q codeletion (ie, astrocytoma); the *IDH* wild-type group (ie, glioblastoma) has the worst prognosis.[8-10,42-44] Analyses within single treatment arms have confirmed this trend in prognosis across a variety of postoperative adjuvant treatment options.[8,43,44,47] *TERT* promoter mutations in patients with high-grade *IDH* wild-type glioma are associated with shorter OS, compared to *IDH* wild-type tumors without a *TERT* promoter mutation.[10,29,48] However, a multivariable analysis of data from 291 patients with *IDH*-mutant, 1p/19q-codeleted oligodendrogliomas showed that absence of a *TERT* promoter mutation was associated with worse OS, compared to those with *TERT* promoter-mutant oligodendrogliomas (HR, 2.72; 95% CI, 1.05–7.04; $P = .04$).[49] An analysis of an older database, which included 271 patients with WHO grade 2 glioma who were diagnosed according to the 2007 WHO classification, showed that *IDH*-mutant gliomas were associated with increased OS and better response to TMZ than *IDH* wild-type gliomas.[8]

MGMT (O-6-methylguanine-DNA methyltransferase) is a DNA repair enzyme that can cause resistance to DNA-alkylating drugs.[50] *MGMT* promoter methylation is associated with better survival outcomes in patients with high-grade glioma and is a predictive factor for response to treatment with alkylating chemotherapy such as TMZ or lomustine,[35,51-53] even in older adult patients.[54,55] *IDH* mutations are commonly associated with *MGMT* promoter methylation.[10] Tumors with H3K27M mutations are far less likely to be *MGMT* promoter methylated[34] and are associated with even worse prognosis than *IDH* wild-type glioblastomas.[41,56] Patients whose hemispheric high-grade gliomas contain *H3-3A* G34 mutations, however, have relatively higher rates of *MGMT* promoter methylation than H3K27M diffuse midline gliomas, and do not have a worse prognosis than other *IDH* wild-type glioblastomas.[41,57]

Most WHO grade 1 pilocytic astrocytomas in pediatric patients contain *BRAF* fusions or, less commonly, *BRAF* V600E mutations, especially those arising in the posterior fossa; such tumors are rarely high grade.[58] *BRAF* fusion is associated with better prognosis in pediatric low-grade astrocytoma.[58-60] The likelihood of a *BRAF* fusion in a pilocytic astrocytoma decreases with age.[58] *BRAF* V600E is present in 60% to 80% of pleomorphic xanthoastrocytomas, although it has also been found in

Discussion update in progress

Version 3.2025 © 2025 National Comprehensive Cancer Network© (NCCN©), All rights reserved. NCCN Guidelines® and this illustration may not be reproduced in any form without the express written permission of NCCN.

PLEASE NOTE that use of this NCCN Content is governed by the End-User License Agreement, and you MAY NOT distribute this Content or use it with any artificial intelligence model or tool.
Printed by A. S. M. FAZLUL KARIM CHOWDHURY on 4/20/2026 3:06:38 AM. Copyright © 2026 National Comprehensive Cancer Network, Inc. All Rights Reserved.

many other low-grade gliomas, such as gangliogliomas and dysembryoplastic neuroepithelial tumors,[35,58,61] as well as less than 5% of glioblastomas (especially epithelioid glioblastoma).[62] Pediatric low-grade glioma with *BRAF* fusions tend to be indolent with occasional recurrence, but only rarely do they progress to cause death.[59,60,63] Retrospective studies have shown that *BRAF* V600E may be associated with increased risk of progression in pediatric low-grade gliomas,[64] but one study found that this association was not quite statistically significant (N = 198; P = .07).[60] Some studies have shown that tumors with a *BRAF* V600E mutation may respond to BRAF inhibitors such as vemurafenib,[65-67] but ongoing trials will further clarify targeted treatment options in the presence of a *BRAF* fusion or V600E mutation (eg, NCT03224767, NCT03430947). *BRAF* fusion and/or mutation testing are clinically indicated in patients with low-grade glioma.

NCCN Molecular Testing Recommendations for Glioma

Recommendations for molecular testing of glioma tumors are provided in the *Principles of Brain Tumor Pathology* section in the algorithm. Based on studies showing that *IDH* status is associated with better prognosis in patients with grade 2–3 glioma,[20,42,43,68] the panel recommends *IDH* mutation testing in patients with glioma. Immunohistochemistry (IHC) can detect the most common (canonical) *IDH* mutation, *IDH1* R132H. However, sequencing must be done to detect non-canonical *IDH1* mutations (eg, *IDH1* R132C) and *IDH2* mutations. Since *ATRX* and *IDH* mutations frequently co-occur, a lack of *ATRX* immunostaining, coupled with negative R132H immunostaining for *IDH1* in a glioma, should trigger screening for such non-canonical *IDH* mutations.[27]

Testing for 1p/19q codeletion is essential for the diagnosis of oligodendroglioma. However, since true whole-arm 1p/19q codeletion is essentially nonexistent in the absence of an *IDH* mutation,[20,21,69] 1p/19q testing is not necessary in tumors that are definitely *IDH* wild-type, and tumors without an *IDH* mutation should not be regarded as truly 1p/19q-codeleted, even when results suggest otherwise. Mutation testing for *ATRX* and *TERT* promoter are also recommended, given the diagnostic value of these mutations.[25,27-29] *IDH*-mutated gliomas that do not show loss of nuclear ATRX immunostaining should be strongly considered for 1p/19q testing, even if not clearly oligodendroglial by histology. *H3-3A* and *HIST1H3B* sequencing and *BRAF* fusion and/or mutation testing may be carried out as clinically indicated. A K27M histone-specific antibody is available, but it can be difficult to interpret.[70]

Grade 3–4 gliomas should undergo testing for *MGMT* promoter methylation, since *MGMT* promoter-methylated tumors typically respond better to alkylating chemotherapy, compared to unmethylated tumors.[51,54,55,71] There are several accepted methods for testing *MGMT* promoter methylation. Methylation-specific PCR is the assay that has the most validation in clinical trials,[72] but a 2012 study including 100 patients with glioblastoma treated with TMZ suggested that pyrosequencing may be the best prognostic stratifier.[73] Molecular testing of glioblastomas is encouraged by the panel, as patients with a detected driver mutation (eg, *BRAF* V600E mutation or *NTRK* fusion) may be treated with a targeted therapy on a compassionate use basis, and these tests improve diagnostic accuracy and prognostic stratification. Detection of genetic or epigenetic alterations could also expand clinical trial options for a brain tumor patient.

Low-Grade Gliomas

Low-grade gliomas (ie, pilocytic and diffusely infiltrative astrocytomas, oligodendrogliomas) are a diverse group of relatively uncommon malignancies classified as grade 1 and 2 under the WHO grading system.[6] Low-grade gliomas comprise approximately 5% to 10% of all CNS tumors.[74] Seizure is a common symptom (81%) of low-grade gliomas, and is more frequently associated with oligodendrogliomas.[75,76] The median duration from onset of symptoms to diagnosis ranges from 6 to 17 months.

Discussion update in progress

Version 3.2025 © 2025 National Comprehensive Cancer Network© (NCCN©), All rights reserved. NCCN Guidelines® and this illustration may not be reproduced in any form without the express written permission of NCCN.

PLEASE NOTE that use of this NCCN Content is governed by the End-User License Agreement, and you MAY NOT distribute this Content or use it with any artificial intelligence model or tool.
Printed by A. S. M. FAZLUL KARIM CHOWDHURY on 4/20/2026 3:06:38 AM. Copyright © 2026 National Comprehensive Cancer Network, Inc. All Rights Reserved.

Grade 1 Gliomas

Diffuse astrocytomas are poorly circumscribed and invasive, and most gradually evolve into higher-grade astrocytomas. Although these were traditionally considered benign, they can behave aggressively and will undergo anaplastic transformation within 5 years in approximately half of patients.[77,78] The most common non-infiltrative astrocytomas are pilocytic astrocytomas. Other grade 1 gliomas in which treatment recommendations are included in the NCCN Guidelines for CNS Cancers are pleomorphic xanthoastrocytoma, SEGA, and ganglioglioma, though these grade 1 gliomas are uncommon. Pleomorphic xanthoastrocytomas are associated with favorable prognosis,[79,80] though mitotic index is associated with survival outcomes.[80,81] Gangliogliomas are commonly located in the temporal lobe, and the most significant predictors of survival are low tumor grade and younger age.[82]

SEGAs are typically located at the caudothalamic groove adjacent to the foramen of Monro. Though they are generally slow-growing and histologically benign, they can also be associated with manifestations such as hydrocephalus, intracranial pressure, and seizures.[83] SEGAs can be distinguished from subependymal nodules by their characteristic serial growth.[84] These tumors occur in 5% to 20% of individuals with tuberous sclerosis complex (TSC).[85-87]

Treatment

Grade 1 gliomas are usually curable by surgery alone. Indication for treatment of SEGAs is based on development of new symptoms or radiologic evidence of tumor growth.[84] Though surgery is sometimes a recommended option for SEGAs, many are in an area not amenable to resection, and recurrence may occur following resection.[88,89] Surgery may pose risks because of the frequent location of SEGAs near the foramen of Monro, but in specialized centers, morbidity is acceptable, and surgical mortality is extremely low.[90]

There is some evidence that BRAF inhibitors, as well as a BRAF/MEK inhibitor combination, may be used for treatment of low-grade gliomas that are BRAF mutated. The phase II VE-BASKET study showed that vemurafenib was efficacious in BRAF-mutated low-grade gliomas, particularly PXA, with an overall response rate (ORR) of 42.9% (n = 7), median PFS of 5.7 months, and median OS not reached.[67] Another phase II trial including 13 patients with BRAF-mutated low-grade glioma showed that dabrafenib/trametinib was associated with an ORR of 69%.[91] Case reports have demonstrated clinical activity for the combination BRAF/MEK inhibitor dabrafenib/trametinib in patients with *BRAF* V600E mutant glioma.[92,93]

Reducing or stabilizing the volume of SEGAs through systemic therapy has been investigated. A phase III trial showed that 78 patients with SEGA and TSC who received everolimus, an mTOR inhibitor, had at least a 50% reduction in tumor volume, compared to 39 patients who received a placebo (35% vs. 0%; $P < .001$), and 6-month PFS was 100% versus 86%, respectively ($P < .001$).[94] Analyses from a long-term follow-up showed that median duration of response was not reached, with response duration ranging from 2.1 months to 31.1 months.[95] Tumor volume reduction rates of 30% and 50% were maintained in patients in the everolimus arm for more than 3 years. This regimen was generally well-tolerated, with the most frequently reported grade 3 or 4 adverse events being stomatitis (8%) and pneumonia (8%). Everolimus has also been investigated in a phase II trial including 58 patients with recurrent grade 2 gliomas, with a 6-month PFS rate of 84%.[96] Medical therapy of SEGA, while effective, is a long-term commitment, unless it is being used short-term to facilitate surgical resection. Once mTOR inhibitor therapy is stopped, lesions typically recur, usually within several months, and eventually reach pretreatment volume. The lesions will continue to grow unless therapy is reintroduced. Most patients tolerate long-term therapy with mTOR inhibitors quite well.[97]

Discussion update in progress

Version 3.2025 © 2025 National Comprehensive Cancer Network© (NCCN©), All rights reserved. NCCN Guidelines® and this illustration may not be reproduced in any form without the express written permission of NCCN.

PLEASE NOTE that use of this NCCN Content is governed by the End-User License Agreement, and you MAY NOT distribute this Content or use it with any artificial intelligence model or tool.
Printed by A. S. M. FAZLUL KARIM CHOWDHURY on 4/20/2026 3:06:38 AM. Copyright © 2026 National Comprehensive Cancer Network, Inc. All Rights Reserved.

NCCN Recommendations

When possible, maximal safe resection is recommended for grade 1 gliomas, and the actual extent of resection should be documented with a T2-weighted or FLAIR MRI scan within 48 hours after surgery. Patients may be observed following surgery. If incomplete resection or biopsy, or if surgery was not feasible, then RT may be considered if there is significant tumor growth or if neurologic symptoms are present or develop. A BRAF/MEK inhibitor combination may be used for patients with *BRAF* V600E mutant low-grade glioma. TRK inhibitors larotrectinib and entrectinib may be used for patients with *NTRK* gene fusion-positive tumors.[98,99] Treatment with an mTOR inhibitor (eg, everolimus) should be considered for patients with SEGA,[94,95] though institutional expertise and patient preference should guide treatment decision-making for these rare tumors.[84]

Grade 2 Oligodendroglioma (IDH-mutant, 1p19q codeleted) and IDH-mutant Astrocytoma

Radiographically, low-grade oligodendrogliomas appear well demarcated, occasionally contain calcifications, and do not often enhance with contrast. In histology, the typical “fried egg” appearance of these tumors is evident as a fixation artifact in paraffin but not in frozen sections. Survival rates tend to be better in oligodendrogliomas than in other gliomas (ie, diffuse astrocytomas, anaplastic astrocytomas, glioblastoma).[74]

Factors prognostic for PFS or OS in patients with grade 2 gliomas include age, tumor diameter, tumor crossing midline, neurologic status or PS prior to surgery, and the presence of certain molecular markers (see section above on *Molecular Profiling for Gliomas)*.[8,14,100-105] For example, *IDH1/2* mutation is associated with a favorable prognosis in patients with grade 2 and 3 gliomas,[9,10,43] supporting the emerging idea that molecular analysis should play a much larger role in treatment decision-making, relative to histopathology.[76]

Treatment Overview

Surgery

Surgery remains an important diagnostic and therapeutic modality. The primary surgical goals are maximal safe resection to delay progression and improve survival, relief of symptoms, and provision of adequate tissue for a pathologic diagnosis and grading. Needle biopsies are often performed when lesions are in deep or critical regions of the brain. Biopsy results can be misleading, because gliomas often have varying degrees of cellularity, mitoses, or necrosis from one region to another; thus, small samples can provide erroneous histologic grade or diagnosis.[106,107]

Surgical resection plays an important role in the management of low-grade gliomas. A systematic review showed that GTR was significantly associated with decreased mortality and lower risk of disease progression up to 10 years after treatment, compared to STR.[108] Because these tumors are relatively uncommon, published series generally include patients treated for decades, which introduces additional variables. For example, the completeness of surgical excision was based on the surgeon’s report in older studies. This approach is relatively unreliable when compared with assessment by modern postoperative imaging studies. Furthermore, many patients also received RT, and thus the net effect of the surgical procedure on outcome is difficult to evaluate. Two meta-analyses including studies of primary low-grade gliomas show that extent of resection is a significant prognostic factor for PFS and/or OS.[109,110] Maximal safe resection may also delay or prevent malignant progression[110-112] and recurrence.[113] Patients who undergo an STR, open biopsy, or stereotactic biopsy are, therefore, considered to be at higher risk for progression. GTR is also associated with improved seizure control compared to STR.[110]

Biological considerations also favor an attempt at a complete excision of a low-grade glioma. First, the tumor may contain higher-grade foci, which

Discussion update in progress

Version 3.2025 © 2025 National Comprehensive Cancer Network© (NCCN©), All rights reserved. NCCN Guidelines® and this illustration may not be reproduced in any form without the express written permission of NCCN.

PLEASE NOTE that use of this NCCN Content is governed by the End-User License Agreement, and you MAY NOT distribute this Content or use it with any artificial intelligence model or tool.
Printed by A. S. M. FAZLUL KARIM CHOWDHURY on 4/20/2026 3:06:38 AM. Copyright © 2026 National Comprehensive Cancer Network, Inc. All Rights Reserved.

may not be reflected in a small specimen. Second, complete excision may decrease the risk of future dedifferentiation to a more malignant tumor.[114] Third, removal of a large tumor burden may enhance the benefit of RT. As a result of these considerations, the general recommendation for treating a low-grade glioma is to first attempt as complete an excision of tumor as possible (based on postsurgical MRI verification) without compromising function. However, for tumors that involve eloquent areas, a total removal may not be feasible, and an aggressive approach could result in neurologic deficits. Residual tumor volume may also be a prognostic factor, with a randomized single institution study showing that the OS benefit of maximal safe resection was limited to patients with a residual tumor volume less than 15 cm^3.[115]

Adjuvant Therapy

A large meta-analysis, including data from phase 3 trials (EORTC 22844 and 22845,[116,117] and NCCTG 86-72-51[103]), confirmed that surgery followed by RT significantly improves PFS but not OS in patients with low-grade gliomas.[118] Early versus late postoperative RT did not significantly affect OS, however, suggesting that observation is a reasonable option for some patients with newly diagnosed gliomas.[117]

Final results of a phase 3 randomized clinical trial, RTOG 9802, which assessed the efficacy of adjuvant RT versus RT followed by 6 cycles of PCV in patients with newly diagnosed supratentorial WHO grade 2 gliomas and at least one of two risk factors for disease progression (STR or age ≥40 years)[119] showed significant improvements in both PFS and OS with the addition of PCV. [120] The median survival time increased from 7.8 years to 13.3 years (P = .02), and the 10-year survival rate increased from 41% to 62%. It is important to note, however, that roughly three-quarters of the study participants had a Karnofsky Performance Status (KPS) score of 90 to 100, and the median age was around 40 years.[119] Exploratory analyses based on histologic subgroups showed a statistically significant improvement in OS for all subgroups except for patients with astrocytoma.[120] Given that the study participants treated with PCV after RT experienced a significantly higher incidence of grade 3 or 4 adverse events (specifically neutropenia, gastrointestinal disorder, and fatigue),[119,120] PCV may be difficult to tolerate in patients who are older or with poor PS. A retrospective subgroup analysis suggests that the survival benefit with the addition of PCV was seen only in *IDH*-mutant tumors; patients with oligodendrogliomas benefited more than those with astrocytomas; the *IDH* wild-type subgroup did not appear to benefit from the chemotherapy.[121]

Combined treatment with RT plus TMZ is supported by a phase 2 multicenter trial (RTOG 0424) in patients with supratentorial WHO grade 2 tumors and additional risk factors (ie, age ≥40 years, astrocytoma, bi-hemispherical, tumor diameter ≥6 cm, neurologic function status >1).[122,123] However, since the historical controls included patients treated in an earlier time period using different RT protocols, prospective controlled trials are needed to determine whether treatment with TMZ concurrently and following RT is as efficacious as PCV following radiation. There are currently no phase III data to support the use of RT and TMZ over RT and PCV for the treatment of patients with newly diagnosed, high-risk, low-grade glioma. The phase 3 randomized EORTC 22033-26033 trial showed that PFS is not significantly different for adjuvant RT versus dose-dense TMZ in patients with resected or biopsied supratentorial grade 2 glioma and more than one risk factor (N = 477).[15] However, analyses of OS have not yet been reported for this trial.

Radiation Therapy

When RT is given to patients with low-grade gliomas, it is administered with restricted margins. A T2-weighted (occasionally enhanced T1) and/or FLAIR MRI scan is the best means for evaluating tumor extent, because these tumors enhance weakly or not at all. The clinical target volume

Discussion update in progress

Version 3.2025 © 2025 National Comprehensive Cancer Network© (NCCN©), All rights reserved. NCCN Guidelines® and this illustration may not be reproduced in any form without the express written permission of NCCN.

PLEASE NOTE that use of this NCCN Content is governed by the End-User License Agreement, and you MAY NOT distribute this Content or use it with any artificial intelligence model or tool.
Printed by A. S. M. FAZLUL KARIM CHOWDHURY on 4/20/2026 3:06:38 AM. Copyright © 2026 National Comprehensive Cancer Network, Inc. All Rights Reserved.

(CTV) is defined by the FLAIR or T2-weighted tumor with a 1- to 2-cm margin. Every attempt should be made to decrease the RT dose outside the target volume. This can be achieved with 3-dimensional (3D) planning or intensity-modulated RT (IMRT), with improved target coverage and normal brain/critical structure sparing often shown with IMRT.[124,125] The recommended dosing for postoperative RT is based on results from two phase 3 randomized trials showing that higher dose RT had no significant effect on OS or time to progression,[103,116] and on several retrospective analyses showing similar results.[102,104,126] Because higher doses offer no clear advantages, the CNS Panel recommends lower-dose RT (45–54 Gy) for treatment of low-grade gliomas (grades 1 and 2), including high-risk cases. However, *IDH* wild-type low-grade gliomas have similar survival only slightly better than *IDH* wild-type glioblastomas.[9] Therefore, an RT dose of 59.4 to 60 Gy may be considered for this subset of patients with low-grade glioma. Preliminary data suggest that proton therapy could reduce the radiation dose to developing brain tissue and potentially diminish toxicities without compromising disease control.[127]

Recurrent or Progressive Disease

Though the survival impact is unclear, surgery for recurrent disease in patients with low-grade glioma may reduce symptoms, provide tissue for evaluation, and potentially allow for molecular characterization of the tumor.[128-131] Maximal safe resection could play an important role for optimizing survival outcomes; a threshold value is unknown, but >90% extent of resection is suggested.[131] For patients without previous RT, results of the RTOG 9802 trial[119,120] support use of chemotherapy with RT. Data from phase II trials inform recommendations for chemotherapy treatment of patients with recurrent or progressive low-grade glioma.[132-138] Patients should be enrolled in clinical trials evaluating systemic therapy options.

NCCN Recommendations

Primary and Adjuvant Treatment

For treatment recommendations for newly diagnosed WHO grade 2 gliomas (oligodendroglioma [*IDH*-mutant, 1p19q codeleted] and *IDH*-mutant astrocytoma), the panel used the RTOG 9802[119,120] criteria for determining if a patient is considered to be at low or high risk for tumor progression: patients are categorized as being at low risk if they are ≤40 years and underwent a GTR; high-risk patients are >40 years of age and/or underwent an STR. However, the panel acknowledges that other prognostic factors have been used to guide adjuvant treatment choice in other studies of patients with low-grade glioma,[139] such as tumor size, presence of neurologic deficits, loss of *CDKN2A* homozygous deletion, and the *IDH* mutation status of the tumor.[15,100] If these other risk factors are considered, and treatment of a patient is warranted, then the panel recommends that the patient be treated as high-risk.

Patients with low-risk WHO grade 2 glioma may be observed following surgery. Close follow-up is essential as over half of these patients will develop tumor progression within 5 years.[105] Following surgery, RT followed by PCV is a category 1 recommendation for patients with WHO grade 2 glioma who are considered to be at high risk for tumor progression, based on the practice-changing results from the RTOG 9802 study,[119,120] as discussed above. When PCV is indicated, carmustine may be substituted for lomustine. There is currently a lack of prospective randomized phase 3 data for the use of radiation and TMZ in patients with low-grade glioma, but interim data from the phase III CATNON trial illustrate that there is a benefit from adjuvant TMZ in patients with newly diagnosed 1p19q non-codeleted WHO grade 3 gliomas.[140] Therefore, RT followed by adjuvant TMZ is a category 2A option. Data from EORTC and NCIC studies, which included patients with glioblastoma, support RT with concurrent and adjuvant TMZ as an evidence-based regimen.[141,142] Therefore, this is also a category 2A option. Because PCV is generally a

Discussion update in progress

Version 3.2025 © 2025 National Comprehensive Cancer Network© (NCCN©), All rights reserved. NCCN Guidelines® and this illustration may not be reproduced in any form without the express written permission of NCCN.

PLEASE NOTE that use of this NCCN Content is governed by the End-User License Agreement, and you MAY NOT distribute this Content or use it with any artificial intelligence model or tool.
Printed by A. S. M. FAZLUL KARIM CHOWDHURY on 4/20/2026 3:06:38 AM. Copyright © 2026 National Comprehensive Cancer Network, Inc. All Rights Reserved.

more difficult chemotherapy regimen to tolerate than TMZ, it may be reasonable to treat an elderly patient or a patient with multiple comorbidities with RT and TMZ instead of RT and PCV, but there are currently no data to show that doing so would result in similar improvement in OS.

Since the design of RTOG 9802[119,120] did not address whether all patients should be treated with RT followed by PCV immediately after a tissue diagnosis (an observation arm was not included for patients with high-risk glioma [defined as >40 years of age and/or underwent an STR][105] in the study), observation after tissue diagnosis may be a reasonable option for some patients with high-risk WHO grade 2 glioma who are neurologically asymptomatic or who have stable disease. However, close monitoring of such patients with brain MRI is important. Results from EORTC 22845, which showed that treatment with RT at diagnosis versus at progression did not significantly impact OS, provide rationale for observation in select cases with low-grade gliomas as an initial approach, deferring RT.[117] Long-term toxicity from radiation needs to be a consideration, especially for young patients with 1p19q codeletion, for whom there is slightly higher risk of radiation necrosis.[143]

Recurrence

At the time of recurrence, surgery is recommended if resectable disease is present. Because recurrence on neuroimaging may be confounded by treatment effects, biopsy of unresectable disease should be considered to confirm recurrence. There is a propensity for low-grade gliomas to transform to higher-grade gliomas over time. Therefore, documenting the histopathologic transformation of a low-grade glioma to a high-grade glioma may also enable patients to have clinical trial opportunities, since most clinical trials in the recurrent setting are for patients with high-grade gliomas. Moreover, sampling of tumor tissue to confirm recurrence is encouraged to obtain tissue for next-generation sequencing, the results of which may inform treatment selection and/or clinical trial eligibility.

Surgery for recurrent low-grade disease may be followed by the following treatment options for patients previously treated with fractionated EBRT: 1) systemic therapy including clinical trials; 2) consideration of reirradiation with or without systemic therapy; and 3) palliative/best supportive care. Reirradiation is a good choice if the new lesion is outside the target of previous RT or if the recurrence is small and geometrically favorable. For patients with low-risk features for whom GTR was achieved, observation with no further treatment may be considered.

Based on the strength of the RTOG 9802 results,[119,120] RT with systemic therapy is a treatment option for patients with recurrent or progressive low-grade gliomas who have not had prior RT. Options include RT + adjuvant PCV, RT + adjuvant TMZ, and RT + concurrent and adjuvant TMZ. RT alone is generally not the preferred treatment option except in select cases, such as a patient with a poor PS, or who does not want to undergo systemic therapy treatment. Systemic therapy alone (eg, TMZ, PCV, carmustine/lomustine) is also a treatment option for these patients, though this is a category 2B option based on less panel consensus.

Discussion update in progress

High-Grade Gliomas (Including Glioblastoma)

High-grade gliomas (defined as WHO grade 3 and 4 gliomas) account for more than half of all malignant primary tumors of the CNS.[2] Whereas the prognosis for glioblastoma (grade 4 glioma) is grim (5-year survival rates around 6%, with higher rates among younger age groups), outcomes for WHO grade 3 gliomas are typically better, depending on the molecular features of the tumor (see *Molecular Profiling for Gliomas: Prognostic Relevance of Molecular Subgroups in Glioma* above in this Discussion).[74] Challenges regarding treatment of glioblastoma include the inability of

Version 3.2025 © 2025 National Comprehensive Cancer Network© (NCCN©), All rights reserved. NCCN Guidelines® and this illustration may not be reproduced in any form without the express written permission of NCCN.

PLEASE NOTE that use of this NCCN Content is governed by the End-User License Agreement, and you MAY NOT distribute this Content or use it with any artificial intelligence model or tool.
Printed by A. S. M. FAZLUL KARIM CHOWDHURY on 4/20/2026 3:06:38 AM. Copyright © 2026 National Comprehensive Cancer Network, Inc. All Rights Reserved.

most systemic therapy agents to penetrate the BBB and heterogeneity among genetic drivers.[144]

High-grade astrocytomas diffusely infiltrate surrounding tissues and frequently cross the midline to involve the contralateral brain. Patients with these neoplasms often present with symptoms of increased intracranial pressure, seizures, or focal neurologic findings related to the size and location of the tumor and associated vasogenic edema. High-grade astrocytomas usually do not have associated hemorrhage or calcification but can produce considerable edema and mass effect, and on brain MRI they typically enhance on T1-weighted images after the administration of intravenous contrast. Tumor cells have been found in peritumoral edema, which corresponds to T2-weighted signal abnormalities. Thus, this volume is frequently used to define RT treatment volumes.

It can be challenging to assess the results of therapy by brain MRI, because the extent and distribution of contrast enhancement, edema, and mass effect are a function of BBB integrity. Thus, factors that increase permeability of the BBB (such as surgery, RT, tapering of corticosteroids, and immunotherapies) can mimic tumor progression radiographically by increasing the presence of contrast enhancement and associated vasogenic edema. Furthermore, anti-VEGF therapy (ie, bevacizumab) suppresses vascular permeability and provides a radiographic appearance of a response, despite residual disease (pseudoresponse).[145]

WHO grade 3 oligodendrogliomas (*IDH*-mutant, 1p19q codeleted) are relatively rare.[74] This distinct subtype has a much better prognosis compared to other high-grade gliomas (WHO grade 3 *IDH*-mutant astrocytomas and glioblastomas).

Treatment Overview

Surgery

The goals of surgery are to obtain a diagnosis, alleviate symptoms related to increased intracranial pressure or compression by tumor, increase survival, and decrease the need for corticosteroids. A meta-analysis including six studies with 1618 patients with glioblastoma showed that GTR is associated with superior OS and PFS, compared to incomplete resection and biopsy.[146] Unfortunately, the infiltrative nature of high-grade astrocytomas frequently renders GTR difficult. There are data suggesting that resection of all fluid-attenuated inversion recovery (FLAIR) signal abnormalities in high-grade *IDH*-mutant gliomas is associated with improved survival.[147] However, a newer and larger study did not find greater benefit of resection in *IDH*-mutant tumors compared to *IDH* wild-type high-grade gliomas.[148]

Unfortunately, nearly all high-grade gliomas recur. Re-resection at the time of recurrence may improve the outcome for select patients.[149] According to an analysis by Park et al,[150] tumor involvement in specific critical brain areas, poor KPS score, and large tumor volume ($\geq$50 cm^3) were associated with unfavorable re-resection outcomes.

Radiation Therapy

Conformal RT (CRT) techniques, which include 3D-CRT and IMRT, are recommended for performing focal brain irradiation. IMRT often will provide superior dosimetric target coverage and better sparing of critical structures than 3D-CRT.[125] Several randomized controlled trials conducted in the 1970s showed that radiation improved both local control and survival in patients with newly diagnosed high-grade gliomas.[151,152] Sufficient radiation doses are required to maximize this survival benefit. However, radiation dose escalation above 60 Gy has not been shown to be beneficial.[153] The recommended radiation dose for high-grade astrocytomas is 60 Gy in 2.0 Gy fractions or 59.4 Gy in 1.8 Gy fractions

Discussion update in progress

Version 3.2025 © 2025 National Comprehensive Cancer Network© (NCCN©), All rights reserved. NCCN Guidelines® and this illustration may not be reproduced in any form without the express written permission of NCCN.

PLEASE NOTE that use of this NCCN Content is governed by the End-User License Agreement, and you MAY NOT distribute this Content or use it with any artificial intelligence model or tool.
Printed by A. S. M. FAZLUL KARIM CHOWDHURY on 4/20/2026 3:06:38 AM. Copyright © 2026 National Comprehensive Cancer Network, Inc. All Rights Reserved.

with an initial RT plan to 46 Gy in 2 Gy fractions or 45 to 50.4 Gy in 1.8 fractions, respectively, followed by a boost plan of 14 Gy in 2 Gy fractions or 9 to 14.4 Gy in 1.8 Gy fractions, respectively.[153]

WHO grade 3 oligodendrogliomas are conventionally treated with the same dose of radiation as WHO grade 3 and 4 *IDH*-mutant astrocytomas and glioblastoma; however, given the better prognosis in patients with oligodendroglioma, radiation treatments are generally administered in a lower dose per fraction (1.8 Gy/fraction vs. 2.0 Gy/fraction) to theoretically decrease the risk of late side effects. Accordingly, as per trials such as RTOG 9813,[68] these gliomas are treated to 50.4 Gy in 1.8 Gy fractions for 28 fractions followed by a five-fraction boost of 1.8 Gy/fraction to a total of 59.4 Gy. Recurrence of glioma can be managed with reirradiation in select scenarios when clinical trial options and systemic therapy options are limited. This can be performed with either highly focused SRS technique for lower volume disease[154] or fractionated IMRT including doses of 35 Gy in 10 fractions.[155]

RT targets for high-grade gliomas are generated from a gross tumor volume (GTV), CTV, and planning target volume (PTV). The GTV encompasses any gross tumor remaining after maximal safe resection as well as the surgical cavity as determined by postoperative imaging. Strategies for GTV definition vary with respect to the inclusion of edema in an initial target volume. When edema is included in an initial phase of treatment, fields are usually reduced for the last phase of treatment. The CTV is an expansion of the GTV by adding an approximately 2-cm margin for WHO grade 3 and 4 gliomas (although smaller CTV expansions are supported in the literature and can be appropriate) to account for a non-enhancing tumor. The CTV is then expanded to a PTV to account for daily setup errors and image registration. The boost target volume will typically encompass only the gross residual tumor and the resection cavity.

Special attention has been given to determining the optimal therapy in older adults with glioblastoma, given their especially poor prognosis, often limited functional status, and increased risk of developing side effects. Overall, the approach in these patients has been to reduce treatment time while maintaining treatment efficacy. Roa et al randomized patients ≥60 years with a poor PS (KPS <70) to 60 Gy in 30 fractions given over 6 weeks versus 40 Gy in 15 fractions given over 3 weeks and found no difference in survival between these two regimens.[156] However, fewer patients who received 40 Gy over a shorter time period required a post-treatment increase in corticosteroid dose, compared to the patients who received 60 Gy over the longer time period (23% vs. 49%, respectively; $P = .02$). A subsequent study provided support for using a regimen of 34 Gy in 10 fractions over 2 weeks in older adult patients.[54] Moreover, another study performed by Roa et al showed that an even shorter course of focal brain radiation consisting of 25 Gy in 5 fractions over 1 week is a reasonable alternative to 40 Gy in 15 fractions over 3 weeks in patients with newly diagnosed glioblastoma who have a poor prognosis (ie, patients who are older adults and/or frail).[157] However, this was a small study that had some limitations, notably overly broad eligibility criteria and poorly defined non-inferiority margin.[158,159]

A randomized trial of hypofractionated RT (40 Gy given over 3 weeks) with concurrent and adjuvant TMZ versus hypofractionated RT alone in patients ≥65 years showed an improvement in median OS and PFS with the addition of concurrent and adjuvant TMZ (5-year OS of 9.8% vs. 1.9%, respectively; median OS of 14.6 months vs. 12.1 months, respectively; HR for mortality, 0.63; 95% CI, 0.53–0.75; $P < .001$; 5-year PFS of 4.1% vs. 1.3%, respectively; HR, 0.56; 95% CI, 0.47–0.66; $P < .001$).[160] The largest benefit was noted in patients with MGMT promoter methylation (see discussion of *Systemic Therapy* for *Glioblastoma*, below). Of note, a comparison of standard focal brain radiation (60 Gy given over 6 weeks) with concurrent and adjuvant TMZ versus hypofractionated radiation (40

Discussion update in progress

Version 3.2025 © 2025 National Comprehensive Cancer Network© (NCCN©), All rights reserved. NCCN Guidelines® and this illustration may not be reproduced in any form without the express written permission of NCCN.

PLEASE NOTE that use of this NCCN Content is governed by the End-User License Agreement, and you MAY NOT distribute this Content or use it with any artificial intelligence model or tool.
Printed by A. S. M. FAZLUL KARIM CHOWDHURY on 4/20/2026 3:06:38 AM. Copyright © 2026 National Comprehensive Cancer Network, Inc. All Rights Reserved.

Gy given over 3 weeks) with concurrent and adjuvant TMZ in elderly patients has not been performed in patients ≥65 years. Therefore, standard radiation (60 Gy given over 6 weeks) with concurrent and adjuvant TMZ (with or without alternating electric field therapy; see discussion of this treatment option below) is also a reasonable treatment option for an older adult patient who has a good PS and wishes to be treated aggressively. Ultimately, quality of life remains an important consideration in the optimal management of this patient population.

Systemic Therapy

WHO Grade 3 Oligodendroglioma (IDH-mutant, 1p19q codeleted)

The addition of PCV to RT for the treatment of newly diagnosed WHO grade 3 oligodendrogliomas is supported by results from two phase III trials, one which tested RT followed by PCV for 6 cycles (EORTC 26951[161,162]) and the other which assessed 4 cycles of dose-intensive PCV administered prior to RT (RTOG 9402[44,163,164]). Both studies compared the combination therapy to RT alone and found significant increases in median OS when PCV was added to RT for the upfront management of WHO grade 3 oligodendroglioma.

The EORTC 26951 trial showed that, among the entire group of 368 histopathologically diagnosed study patients with anaplastic oligodendroglioma or anaplastic oligoastrocytoma (based on the 1993 WHO classification[165]), RT followed by 6 cycles of PCV significantly improved median PFS and OS (42.3 vs. 30.6 months; HR, 0.75; 95% CI, 0.60–0.95; $P = .018$) compared with RT alone.[162] Moreover, in an exploratory subgroup analysis of the 80 patients whose tumors were 1p19q codeleted (grade 3 oligodendroglioma based on the 2021 WHO classification), the benefit was even more pronounced (OS not reached in the RT + PCV group vs. 112 months in the RT group; HR, 0.56; 95% CI, 0.31–1.03).[20,161,162]

RTOG 9402 randomized 291 patients with histopathologically diagnosed anaplastic oligodendroglioma or anaplastic oligoastrocytoma to treatment with an intensive PCV regimen followed by RT or RT alone.[164] As with EORTC 26951, the inclusion of patients with “anaplastic” glioma was based on an earlier WHO classification.[5] In contrast to the EORTC 26951 study, no difference in median OS was observed between the two arms (4.6 years vs. 4.7 years; HR, 0.79; 95% CI, 0.60–1.04; $P = .10$). However, an unplanned subgroup analysis of the 126 patients whose tumors were 1p19q codeleted found a doubling in median OS (14.7 vs. 7.3 years; HR, 0.59; 95% CI, 0.37–0.95; $P = .03$) when PCV was added to RT as upfront treatment.

As would be predicted, in both studies toxicity was higher in the treatment arms that included PCV. In EORTC 26951, 70% of patients in the RT followed by PCV arm did not complete the planned six cycles of treatment.[161,162] In RTOG 9402, there was also a high rate of study treatment discontinuation and acute toxicities (mainly hematologic), including two early deaths attributed to PCV-induced neutropenia.[163,164] Given the similar efficacy results of the two studies, and the two deaths that occurred from the intensive PCV regimen in RTOG 9402, the panel recommends that PCV be administered after RT, as per EORTC 26951, for optimal management.

The phase III CODEL study was designed to assess the efficacy of TMZ for the treatment of newly diagnosed WHO grade 3 oligodendrogliomas. The initial treatment arms were RT alone, RT + TMZ, and TMZ alone. Initial results showed that patients who received TMZ alone had significantly shorter PFS than patients treated with RT (either RT alone or with TMZ) (2.9 years vs. not reached, respectively; HR, 3.12; 95% CI, 1.26–7.69; $P = .009$).[166] When the results of RTOG 9402 and EORTC 26951 were reported showing significant improvement in median OS with RT + PCV upfront in patients with WHO grade 2 oligodendroglioma, the

Discussion update in progress

Version 3.2025 © 2025 National Comprehensive Cancer Network© (NCCN©), All rights reserved. NCCN Guidelines® and this illustration may not be reproduced in any form without the express written permission of NCCN.

PLEASE NOTE that use of this NCCN Content is governed by the End-User License Agreement, and you MAY NOT distribute this Content or use it with any artificial intelligence model or tool.
Printed by A. S. M. FAZLUL KARIM CHOWDHURY on 4/20/2026 3:06:38 AM. Copyright © 2026 National Comprehensive Cancer Network, Inc. All Rights Reserved.

CODEL study was redesigned to compare RT + PCV to RT + TMZ in patients with WHO grade 2 or 3 oligodendroglioma. This study is ongoing.

WHO Grade 3 and 4 IDH-Mutant Astrocytoma

The RTOG 9813 trial showed that RT with concurrent TMZ resulted in similar outcomes as RT with concurrent nitrosourea (either CCNU [lomustine] or BCNU [carmustine]) therapy in patients with newly diagnosed anaplastic (grade 3) astrocytomas. At the time of study accrual, the diagnosis of anaplastic (grade 3) astrocytoma was based on tumor morphology. Retrospective analysis of tumor tissue showed that 44.1% of study participants had tumors that were *IDH1-R132H* mutated. There was perhaps slightly better PFS with TMZ (HR, 0.70; 95% CI, 0.50–0.98; P = .039);[68] however, the toxicity of nitrosourea was significantly worse than for TMZ, and resulted in higher rates of discontinuation due to toxicity (79% vs. 40%, respectively; P < .001).

The ongoing CATNON phase 3 randomized trial is testing RT alone, as well as RT with adjuvant TMZ, concurrent TMZ, or both, in patients with newly diagnosed anaplastic astrocytoma. As in previous trials,[161,163] the inclusion of patients with “anaplastic astrocytoma” is based on an earlier WHO classification.[5] An initial interim analysis showed that adjuvant TMZ significantly improved PFS (HR, 0.62; 95% CI, 0.50–0.76) and OS (HR, 0.67; 95% CI, 0.51–0.88).[140] Median OS for the group of patients treated with post-RT TMZ had not been reached, but median OS at 5 years was 55.9% (95% CI, 47.2–63.8) with and 44.1% (36.3–51.6) without adjuvant TMZ. A second interim analysis showed that, in terms of OS, patients with *IDH*-mutant anaplastic astrocytomas (grade 3 *IDH*-mutant astrocytoma, per the WHO 2021 classification) benefitted from treatment with adjuvant TMZ (HR, 0.48; 95% CI, 0.35–0.67; P < .0001), but not those participants whose tumors were *IDH* wild-type (HR, 1.00; 95% CI, 0.75–.98; P = 0.98).[167] There was also no definite benefit to concurrent TMZ in patients with *IDH*-mutant anaplastic astrocytomas (HR, 0.80; 95% CI, 0.58–1.10; P = .17). Further follow-up and molecular analyses are ongoing.

Glioblastoma

Adjuvant involved-field RT with concurrent and adjuvant TMZ is the standard recommended treatment for patients with newly diagnosed glioblastoma and good PS based on the results of the phase III, randomized EORTC-NCIC study of 573 patients with newly diagnosed glioblastoma who were aged ≤70 years and had a WHO PS ≤2.[160] Patients received either 1) daily TMZ administered concomitantly with postoperative RT followed by 6 cycles of adjuvant TMZ; or 2) RT alone. The chemoradiation arm resulted in a statistically better median survival (14.6 vs. 12.1 months) and 2-year survival (26.5% vs. 10.4%) when compared with RT alone. Final analysis confirmed the survival advantage at 5 years (10% vs. 2%).[160] However, the study design does not shed light on which component is responsible for the improvement: TMZ administered with RT, TMZ following RT, or possibly both.

The TMZ dose used in the EORTC-NCIC trial is 75 mg/m^2 daily concurrent with RT, then 150 to 200 mg/m^2 post-irradiation on a 5-day schedule every 28 days. Alternate schedules, such as a 75 to 100 mg/m^2 for 21 out of 28 days regimen or 50 mg/m^2 daily, have been explored in a phase II trial for newly diagnosed glioblastoma.[168] However, a comparison of the dose-intense 21/28 and standard 5/28 schedules in the RTOG 0525 phase III study showed no difference in PFS, OS, or by MGMT methylation status with the post-radiation dose-intense TMZ, compared to the standard post-radiation TMZ dose.[169] A pooled analysis of individual patient data from four randomized trials[142,169-171] of patients with newly diagnosed glioblastoma determined that treating with post-radiation TMZ beyond six cycles does not improve OS, even for patients whose tumors are MGMT promoter methylated.[172] A recent prospective, randomized phase II study showed no improvement in 6-month PFS, PFS, or OS with continuing

Discussion update in progress

Version 3.2025 © 2025 National Comprehensive Cancer Network© (NCCN©), All rights reserved. NCCN Guidelines® and this illustration may not be reproduced in any form without the express written permission of NCCN.

PLEASE NOTE that use of this NCCN Content is governed by the End-User License Agreement, and you MAY NOT distribute this Content or use it with any artificial intelligence model or tool.
Printed by A. S. M. FAZLUL KARIM CHOWDHURY on 4/20/2026 3:06:38 AM. Copyright © 2026 National Comprehensive Cancer Network, Inc. All Rights Reserved.

treatment with TMZ beyond 6 cycles, and doing so was associated with greater toxicity.[173]

MGMT Promoter-Methylated Glioblastoma

The presence of MGMT promoter methylation in glioblastoma is both a prognostic marker and a predictive one for response to treatment with alkylating agents. In the small (N = 31), single-arm phase II UKT-03 trial,[174,175] postoperative RT and TMZ combined with lomustine in patients with newly diagnosed glioblastoma resulted in a median OS of 34.3 months,[174] which compared favorably to the historical control data of 23.4 months in patients with MGMT promoter-methylated tumors who were treated with RT and TMZ in the EORTC-NCIC trial.[160] Based on this improvement in survival with combination alkylating agents in patients with MGMT promoter-methylated glioblastoma, the phase III CeTeG/NOA-09 trial randomized patients with newly diagnosed MGMT-promoter–methylated glioblastoma (aged 18–70 and KPS ≥70) to treatment with RT and lomustine + TMZ or RT and TMZ alone.[176] Analysis of the modified intent-to-treat population (N = 129) showed that OS was significantly improved in the TMZ + lomustine arm versus the TMZ arm (median OS of 48.1 months vs. 31.4 months, respectively; *P* = .049). Of note, PFS was not significantly improved, which the investigators hypothesized could have been due to a higher incidence of pseudoprogression in the TMZ + lomustine arm. Grade 3 and 4 adverse events were only slightly higher in the TMZ + lomustine arm (59% vs. 51%, respectively), but the study was too small to adequately define the toxicity profile of RT with TMZ + lomustine. Analysis of health-related quality of life showed no significant differences between the study arms.[177]

Older Adults

Building on the findings that hypofractionated RT alone has similar efficacy and is better tolerated compared to standard RT alone in older adults with newly diagnosed glioblastoma, a phase III randomized trial with 562 newly diagnosed patients ≥65 years of age compared hypofractionated RT with concurrent and adjuvant TMZ to hypofractionated radiation alone. Patients in the combination therapy arm had better PFS (5.3 months vs. 3.9 months; HR, 0.50; 95% CI, 0.41–0.60; *P* < .001) and median OS (9.3 months vs. 7.6 months; HR, 0.67; 95% CI, 0.56–0.80; *P* < .001) compared to patients treated with hypofractionated RT alone.[141] The greatest improvement in median OS was seen in patients with MGMT promoter-methylated tumors (13.5 months RT + TMZ vs. 7.7 months RT alone; HR, 0.53; 95% CI, 0.38–0.73; *P* < .001). The benefit of adding TMZ to RT was smaller in patients with MGMT promoter-unmethylated tumors and did not quite reach statistical significance (10.0 months vs. 7.9 months, respectively; HR, 0.75; 95% CI, 0.56–1.01; *P* = .055; *P* = .08 for interaction).

Two phase III studies in elderly newly diagnosed glioblastoma patients assessed treatment with TMZ alone versus radiation.[54,55] The Nordic trial randomized 291 patients aged ≥60 years with good PS across three treatment groups: TMZ, hypofractionated RT, or standard RT.[54] Patients >70 years had better survival with TMZ or hypofractionated RT compared to standard RT, and patients whose tumors were MGMT promoter-methylated benefitted more from treatment with TMZ compared to patients with MGMT promoter-unmethylated tumors (median OS 9.7 vs. 6.8 months; HR, 0.56; 95% CI, 0.34–0.93; *P* = .02). The NOA-08 study assessed the efficacy of TMZ alone compared to standard RT in 373 patients aged ≥65 years.[55] TMZ was found to be noninferior to standard RT; median OS was similar in both groups (8.6 months in the TMZ arm vs. 9.6 months in the standard RT arm; HR, 1.09; 95% CI, 0.84–1.42; *P* [non-inferiority] = .033). For patients whose tumors were MGMT promoter-methylated, event-free survival was longer with TMZ treatment compared to standard RT (8.4 months vs. 4.6 months). Neither the Nordic trial nor the NOA-08 trial included a combination RT and TMZ control arm, which is the treatment regimen typically offered to patients who are fit enough to

Discussion update in progress

Version 3.2025 © 2025 National Comprehensive Cancer Network© (NCCN©), All rights reserved. NCCN Guidelines® and this illustration may not be reproduced in any form without the express written permission of NCCN.

PLEASE NOTE that use of this NCCN Content is governed by the End-User License Agreement, and you MAY NOT distribute this Content or use it with any artificial intelligence model or tool.
Printed by A. S. M. FAZLUL KARIM CHOWDHURY on 4/20/2026 3:06:38 AM. Copyright © 2026 National Comprehensive Cancer Network, Inc. All Rights Reserved.

tolerate it, regardless of age. Although radiation in combination with TMZ is recommended over single-modality therapy for newly diagnosed patients with glioblastoma who are >70 years of age and have good PS, the results of these two phase III studies support the recommendation that TMZ alone as initial therapy may be a reasonable option for those elderly patients who have MGMT promoter-methylated tumors and would initially prefer to delay treatment with radiation.[54,55]

Alternating Electric Field Therapy

In 2015, the FDA approved alternating electric field therapy for the treatment of patients with newly diagnosed glioblastoma based on the results of the open-label phase III EF-14 clinical trial. This portable medical device generates low-intensity alternating electric fields to stop mitosis/cell division. In the EF-14 trial, 695 patients with newly diagnosed glioblastoma and good PS (KPS ≥70) were randomized to TMZ alone on a 5/28-day schedule or the same TMZ and alternating electric field therapy, following completion of standard focal brain radiation and daily TMZ.[178] The results of the study showed an improvement in median PFS (6.7 vs. 4.0 months, respectively; HR, 0.63; 95% CI, 0.52–0.76; $P < .001$) and OS (20.9 vs. 16.0 months, respectively; HR, 0.63; 95% CI, 0.53–0.76; $P < .001$) in patients who received TMZ plus alternating electric field therapy.[179] The number of adverse events was not statistically different between the two treatment groups except for a greater frequency of mild to moderate local skin irritation/itchiness in the patients treated with the alternating electric fields.[180] There was no increased frequency of seizures.[181,182] Based on the results of this study, concurrent treatment with adjuvant TMZ and alternating electric fields is a category 1 recommendation for newly diagnosed glioblastoma patients ≤70 years of age who have a good PS. This is also considered a reasonable treatment option for patients >70 years of age with good PS and newly diagnosed glioblastoma who are treated with standard focal brain radiation and concurrent daily TMZ.

Therapy for Recurrence

Patients with malignant gliomas eventually develop tumor recurrence or progression. Surgical resection of locally recurrent disease is reasonable followed by treatment with systemic therapy. Unfortunately, there is no established second-line therapy for recurrent gliomas. If there has been a long-time interval between stopping TMZ and development of tumor progression, it is reasonable to restart a patient on TMZ,[183] particularly if the patient's tumor is MGMT methylated. Similarly, a nitrosourea, such as carmustine or lomustine,[184-187] would be a reasonable second-line therapy, especially in a patient whose tumor is MGMT methylated. Although no studies of bevacizumab in patients with recurrent glioblastoma have demonstrated an improvement in survival, bevacizumab is FDA approved for the treatment of recurrent glioblastoma based on improvement in PFS.[188-190] Of note, improvement in PFS may be due to bevacizumab's ability to decrease BBB permeability (resulting in less contrast enhancement and vasogenic edema) rather than a true anti-tumor effect.[191,192] Treatment with regorafenib for recurrent glioblastoma is supported by the results of a randomized phase II trial in which OS was greater for patients randomized to receive regorafenib, compared to those who received lomustine (median OS of 7.4 months vs. 5.6 months, respectively; HR, 0.50; 95% CI, 0.33–0.75; $P < .001$).[193] Of note, the median OS in the lomustine arm in this trial was lower than reported in other randomized phase II and III trials. A phase III study of regorafenib is being planned.

Other routes of chemotherapy delivery have been evaluated. Local administration of carmustine using a biodegradable polymer (wafer) placed intraoperatively in the surgical cavity has demonstrated a statistically significant improvement in survival for patients with recurrent high-grade gliomas (31 vs. 23 weeks; adjusted HR, 0.67; $P = .006$).[194] Patients who receive carmustine wafers are at greater risk for seizures and postoperative infections. When wafers are used, it is important to

Discussion update in progress

Version 3.2025 © 2025 National Comprehensive Cancer Network© (NCCN©), All rights reserved. NCCN Guidelines® and this illustration may not be reproduced in any form without the express written permission of NCCN.

PLEASE NOTE that use of this NCCN Content is governed by the End-User License Agreement, and you MAY NOT distribute this Content or use it with any artificial intelligence model or tool.
Printed by A. S. M. FAZLUL KARIM CHOWDHURY on 4/20/2026 3:06:38 AM. Copyright © 2026 National Comprehensive Cancer Network, Inc. All Rights Reserved.

achieve a watertight dural closure and have sufficient use of steroids and antiepileptics in the perioperative period to prevent adverse events.[195] Clinicians and patients should be aware that treatment with the carmustine wafer may prevent participation in a clinical trial involving a locally delivered investigational agent.

Alternating electric field therapy is also FDA approved for treating recurrent glioblastoma based on the safety results of this medical device from the EF-11 clinical trial.[196] This phase III study randomized 237 patients with recurrent glioblastoma to alternating electric field therapy or the treating oncologist's choice of chemotherapy. The study did not meet its primary endpoint of demonstrating an improvement in survival in the cohort of patients treated with alternating electric field therapy. Although median OS was similar in both of the treatment arms (6.6 vs. 6 months), the study had not been powered for a non-inferiority determination. Due to lack of clear efficacy data for alternating electric field therapy in EF-11, the panel is divided about recommending it for the treatment of recurrent glioblastoma. Similarly, re-irradiation may be reasonable to consider for some recurrent glioblastoma patients, but the panel is also divided about this option. A systematic review including 50 non-comparative studies of 2095 patients with recurrent glioblastoma who were treated with re-irradiation showed pooled 6- and 12-month OS rates of 73% and 36%, respectively, and 6- and 12-month PFS rates of 43% and 17%, respectively.[197] Over half of the studies (29 out of 50) were rated as poor quality, indicating a need for better quality studies in this area. Further, there is no recommended dose or type of radiation used in the recurrent setting due to inconsistent trial design among these studies.

NCCN Recommendations

Primary Treatment

When a patient presents with a clinical and radiologic picture suggestive of a high-grade glioma, neurosurgical input is needed regarding the feasibility of maximal safe resection. For first-line treatment of high-grade glioma, the NCCN Guidelines recommend maximal safe resection whenever possible. One exception is when CNS lymphoma is suspected; a biopsy should be performed before steroids are administered, and management should follow the corresponding pathway if the diagnosis is confirmed. When maximal resection is performed, the extent of tumor debulking should be documented with a postoperative MRI scan with and without contrast performed within 48 hours after surgery. Multidisciplinary consultation is encouraged once the pathology is available.

Adjuvant Therapy

RT is generally recommended after maximal safe resection for the treatment of high-grade gliomas to improve local control and survival. For postoperative treatment of WHO grade 3 oligodendroglioma (*IDH*-mutant, 1p19q codeletion) and WHO grade 3 or 4 *IDH*-mutant astrocytoma in patients with good PS (KPS ≥60), focal brain radiation and chemotherapy are the recommended options. For patients with WHO grade 3 oligodendroglioma, RT plus PCV, given before or after RT, is preferred, based on the results of the RTOG 9402[44,164] and EORTC 26951 studies.[161,162] The panel advises administering PCV after RT as per EORTC 26951 instead of the dose-intensive PCV used prior to RT in the RTOG 9402 study[164] due to better patient tolerance. Regarding PCV, carmustine may be substituted for lomustine. RT, with or without concurrent TMZ, followed by adjuvant TMZ is also a reasonable option,[198] particularly if it is predicted that the patient might have significant difficulty tolerating PCV due to age or coexisting medical conditions. The panel awaits the results of the CODEL study to see if treatment with TMZ will be as efficacious as PCV in this patient population.

In the case of patients with WHO grade 3 or 4 *IDH*-mutant astrocytoma and good PS, RT, with or without concurrent TMZ and followed by adjuvant TMZ, is preferred based on the second interim analysis results of

Discussion update in progress

Version 3.2025 © 2025 National Comprehensive Cancer Network© (NCCN©), All rights reserved. NCCN Guidelines® and this illustration may not be reproduced in any form without the express written permission of NCCN.

PLEASE NOTE that use of this NCCN Content is governed by the End-User License Agreement, and you MAY NOT distribute this Content or use it with any artificial intelligence model or tool.
Printed by A. S. M. FAZLUL KARIM CHOWDHURY on 4/20/2026 3:06:38 AM. Copyright © 2026 National Comprehensive Cancer Network, Inc. All Rights Reserved.

the CATNON trial showing improvement in survival with RT followed by 12 cycles of TMZ compared to RT alone.[140,167]

For patients diagnosed with glioblastoma, the adjuvant options mainly depend on the patient's age, PS (as defined by KPS), and MGMT promoter methylation status.[51,54,160,199] Category 1 recommendations for patients aged ≤70 years with a good PS, regardless of the tumor's MGMT methylation status, include standard brain RT plus concurrent and adjuvant TMZ with or without alternating electric field therapy. Because patients with newly diagnosed MGMT promoter-unmethylated glioblastoma are likely to receive less benefit from TMZ, RT alone is included as a reasonable option, particularly if the patient is eligible to participate in a clinical trial, which omits the use of upfront TMZ.

Category 1 treatment recommendations for patients >70 years of age with newly diagnosed glioblastoma, a good PS, and MGMT promoter-methylated tumors include hypofractionated brain RT plus concurrent and adjuvant TMZ[141] or standard brain RT plus concurrent and adjuvant TMZ and alternating electric field therapy. For those patients >70 years with newly diagnosed glioblastoma, a good PS, and with MGMT-unmethylated or -indeterminant tumors, hypofractionated brain radiation with concurrent and adjuvant TMZ[141] is preferred, but standard brain RT plus concurrent and adjuvant TMZ and alternating electric field therapy is also a reasonable option (category 1)[178,179] for patients >70 years of age who want to be treated as aggressively as possible. The complete list of recommendations that the panel did not consider category 1 can be found in the treatment algorithms for patients with glioblastoma who are >70 years.

For patients with poor PS (KPS <60) who have newly diagnosed WHO grade 3 oligodendroglioma (*IDH*-mutant, 1p19q codeletion) or WHO grade 3 or 4 *IDH*-mutant astrocytoma, hypofractionated brain RT with or without concurrent or adjuvant TMZ is preferred. For patients with glioblastoma who have a poor PS (regardless of age), single modality therapy is recommended: hypofractionated brain RT or TMZ for patients with MGMT promoter-methylated tumors. Palliative/best supportive care is also a reasonable option for patients with newly diagnosed high-grade gliomas with poor PS.

Follow-up and Recurrence

Patients should be followed closely with serial brain MRI scans (at 2–8 weeks post-irradiation, then every 2–4 months for 3 years, then every 3–6 months indefinitely) after the completion of treatment for newly diagnosed disease. Scans may appear worse during the first 3 months or longer after completion of RT even though there may be no actual tumor progression.[144] This finding of "pseudoprogression" occurs more often in patients whose tumors are MGMT promoter methylated.[200,201] Early MRI scans allow for appropriate titration of corticosteroid doses based on the extent of mass effect and brain edema. Later scans are used to identify tumor recurrence. Early detection of recurrence is warranted, because local and systemic treatment options are available for patients with recurrent disease. Biopsy, MR spectroscopy, MR perfusion, or brain PET/CT can be considered to try to determine if the changes seen on brain MRI are due to pseudoprogression or RT-induced necrosis versus actual disease progression.[202,203] RT-induced necrosis tends to be detected between 6 and 24 months following RT treatment.[201]

Management of recurrent tumors depends on the extent of disease and patient condition. The efficacy of current treatment options for recurrent disease remains poor; therefore, enrollment in a clinical trial, whenever possible, is preferred for the management of recurrent disease. Preferred systemic therapy options for recurrent disease include re-treatment with TMZ (if there has been a long interval between completion of adjuvant TMZ and development of recurrent disease),[133,183,204-206] carmustine/lomustine,[184-187,207] bevacizumab,[188,208-213] regorafenib,[193] and

Discussion update in progress

Version 3.2025 © 2025 National Comprehensive Cancer Network© (NCCN©), All rights reserved. NCCN Guidelines® and this illustration may not be reproduced in any form without the express written permission of NCCN.

PLEASE NOTE that use of this NCCN Content is governed by the End-User License Agreement, and you MAY NOT distribute this Content or use it with any artificial intelligence model or tool.
Printed by A. S. M. FAZLUL KARIM CHOWDHURY on 4/20/2026 3:06:38 AM. Copyright © 2026 National Comprehensive Cancer Network, Inc. All Rights Reserved.

PCV.[134,214,215] A patient with a poor PS should receive palliative/best supportive care.

Intracranial and Spinal Ependymomas

Ependymomas constitute up to 1.6% of CNS tumors.[74] In adults, ependymomas occur more often in the spinal canal than in the intracranial compartment (supratentorial and posterior fossa). These tumors can cause hydrocephalus and increased intracranial pressure, mimic brainstem lesions, cause multiple cranial nerve palsies, produce localizing cerebellar deficits, and cause neck stiffness and head tilt if they infiltrate the upper portion of the cervical cord.[216,217] Posterior fossa ependymomas are categorized as two groups: A (PFA) and B (PFB). PFA ependymomas are more common in infants and young children, and typically behave in a more aggressive manner than PFB ependymomas.

This section focuses on adult spinal and intracranial ependymal tumors, including grade 2 differentiated (classic ependymomas) and grade 3 (anaplastic ependymomas) tumors. The NCCN Guidelines also include recommendations for management of myxopapillary spinal ependymomas. cIMPACT-NOW recommends diagnosing myxopapillary ependymomas as grade 2,[218] as outcomes for these tumors are not significantly different than those for classic ependymoma.[219]

Molecular Markers

Ependymomas arising in the supratentorium often contain activating fusions of *ZFTA*, with the most common *ZFTA* partner being RELA. RELA activating fusions occur in about 19% of patients with ependymomas and are more likely to occur in children than in adults.[220] Ependymomas with RELA activating fusions are more likely to be advanced and aggressive than RELA fusion-negative ependymomas (including those with *YAP1* fusion), with a greater likelihood of being grade 2 or 3, and with shorter PFS and OS.[220,221] In the 2016 WHO classification system, RELA fusion-positive ependymoma was designated as a subtype.[5] Testing for *ZFTA* and *YAP1* fusions is recommended when clinically appropriate.

MYCN-amplified spinal ependymoma has been identified as an aggressive form of ependymoma[222,223] and thus is now designated as a subtype in the 2021 WHO classification.[6,218] Loss of H3K27 trimethylation by IHC is characteristic of PFA ependymomas, and genomic methylation profiling is recommended for differentiation of PFA and PFB ependymomas.[24,218,224]

Treatment Overview

Surgery

There is a paucity of robust studies addressing the role of surgery in this uncommon disease, but multiple case series have reported that patients with totally resected tumors tend to have the best survival for both low- and high-grade ependymomas.[225-229] Grade 1 subependymomas are non-infiltrative and can often be cured by resection alone. For myxopapillary ependymomas, complete resection of the mass without capsular violation (marginal en bloc resection) can be curative.[230] In a retrospective analysis by Rodriguez et al,[231] patients who underwent surgery had a better outcome than those who did not (HR, 1.99; $P < .001$). Supratentorial ependymomas generally have a poorer prognosis than their infratentorial counterparts, because a greater proportion of supratentorial lesions are of high grade.

Radiation Therapy

The survival benefits of RT following surgery have been established for anaplastic ependymomas and suboptimally resected tumors, although much of the data are derived from pediatric patients. Rodriguez et al[231] reviewed over 2400 cases of ependymomas in the SEER database and reported that patients with partially resected tumors who do not receive RT have a poorer prognosis than those who are treated with RT (HR, 1.75; $P = .024$). The short-term and 10-year survival rate after RT reached over

Discussion update in progress

Version 3.2025 © 2025 National Comprehensive Cancer Network© (NCCN©), All rights reserved. NCCN Guidelines® and this illustration may not be reproduced in any form without the express written permission of NCCN.

PLEASE NOTE that use of this NCCN Content is governed by the End-User License Agreement, and you MAY NOT distribute this Content or use it with any artificial intelligence model or tool.
Printed by A. S. M. FAZLUL KARIM CHOWDHURY on 4/20/2026 3:06:38 AM. Copyright © 2026 National Comprehensive Cancer Network, Inc. All Rights Reserved.

70% and 50%, respectively.[232-234] The value of RT is more controversial for differentiated ependymomas,[226,235] with data demonstrating improved survival mainly for subtotally resected tumors.[227,231] Emerging data show poor survival rates in patients with supratentorial non-anaplastic ependymoma who do not receive RT following GTR.[236] Further, much of the data supporting observation following surgical resection are based on retrospective studies.[237-239] Given the availability of highly CRT modalities and the relatively lower level of concerns for late effects of RT in adults (vs. children), RT is recommended as the standard adjuvant treatment approach in these patients until high-quality evidence supporting observation alone becomes available.

In the past, the standard practice was to irradiate the entire craniospinal axis or administer WBRT. However, studies have demonstrated that: 1) local recurrence is the primary pattern of failure; 2) spinal seeding is uncommon in the absence of local failure; 3) the patterns of failure are similar in patients with high-grade tumors who are treated with local fields or craniospinal axis irradiation; and 4) spinal metastases may not be prevented by prophylactic treatment.[240-242] Prophylactic craniospinal RT or WBRT does not lead to improvement in survival compared to conformal regional RT with higher doses in modern studies of non-disseminated disease.[228,235,243]

The typical craniospinal irradiation scheme includes 36 Gy in 1.8 Gy fractions to the whole brain and spine, followed by limited-field irradiation to spine lesions to 45 Gy. For intracranial ependymomas, the primary brain site should receive a total of 54 to 59.4 Gy in 1.8 to 2.0 Gy fractions. PTV of margin of 3 to 5 mm is typically added to the CTV. Tolerance of the cauda equina is in the range of 54 to 60 Gy.[244,245] Therefore, a boost to gross intracranial metastatic sites (respecting normal tissue tolerances) may be considered.

For spinal ependymomas, patients could receive local RT to 45 to 54 Gy in 1.8 Gy fractions, with higher doses up to 60 Gy being reasonable for spinal tumors below the conus medullaris. These dosing recommendations are consistent with those for primary spinal cord tumors. However, it is important to note that retrospective analyses have shown that adjuvant RT does not consistently improve disease outcomes in patients with these tumors.[246-248]

Proton beam craniospinal irradiation may be considered when clinically appropriate and when toxicity is a concern. SRS has been used as a boost after EBRT or to treat recurrence with some success, although data on long-term results are still lacking.[249-251]

Systemic Therapy

Studies regarding the role of chemotherapy have largely been in the setting of pediatric ependymomas; the role of chemotherapy in the treatment of ependymomas in adult patients remains poorly defined. No study has demonstrated a survival advantage with the addition of chemotherapy to RT in newly diagnosed tumors. However, chemotherapy is sometimes considered as an alternative to palliative/best supportive care or RT in the recurrence setting. Possible options include platinum-based regimens (cisplatin or carboplatin),[252,253] etoposide,[254,255] nitrosourea-based regimens (lomustine or carmustine),[253] bevacizumab,[256] and temozolomide.[257] The combination of lapatinib, a tyrosine kinase inhibitor (TKI), and dose-dense TMZ has been evaluated in a phase II trial in patients with recurrent grade 1, 2, and 3 ependymoma.[258]

NCCN Recommendations

Primary and Adjuvant Treatment

In general, when feasible, management of rare tumors such as ependymomas should begin with a timely and early consultation with centers of neuro-oncologic expertise. Whenever possible, maximal safe

Discussion update in progress

Version 3.2025 © 2025 National Comprehensive Cancer Network© (NCCN©), All rights reserved. NCCN Guidelines® and this illustration may not be reproduced in any form without the express written permission of NCCN.

PLEASE NOTE that use of this NCCN Content is governed by the End-User License Agreement, and you MAY NOT distribute this Content or use it with any artificial intelligence model or tool.
Printed by A. S. M. FAZLUL KARIM CHOWDHURY on 4/20/2026 3:06:38 AM. Copyright © 2026 National Comprehensive Cancer Network, Inc. All Rights Reserved.

resection should be attempted with contrast-enhanced brain image verification within 48 hours after surgery. Spine MRI, if not done prior to surgery, should be delayed by at least 2 to 3 weeks after surgery to avoid post-surgical artifacts. If maximal resection is not feasible at diagnosis, STR or biopsy (stereotactic or open) should be performed. Due to the established relationship between the extent of resection and outcome, multidisciplinary review and re-resection (if possible) should be considered if MRI shows that initial resection is incomplete. For spinal myxopapillary ependymomas, en bloc resection without capsule violation is recommended whenever feasible.

The adjuvant treatment algorithm depends on the extent of surgical resection, histology, and staging by craniospinal MRI and cerebrospinal fluid (CSF) cytology. For spinal ependymomas, brain MRI should be obtained to determine if these are drop metastases from a primary brain lesion. CSF dissemination develops in up to 15% of intracranial ependymomas. Lumbar puncture for CSF cytology, which is indicated when there is clinical concern for meningeal dissemination, should be done following spine MRI and, if not done prior to surgery, should be delayed at least 2 weeks after surgery to avoid a false-positive result. Lumbar puncture may be contraindicated in some cases (for example, if there is increased intracranial pressure and risk of herniation).

RT is the appropriate postoperative management for patients with negative findings for tumor dissemination on MRI scans and CSF analysis. Patients with grade 1 spinal ependymomas that have been totally resected may not require adjuvant RT, as the recurrence rate tends to be low. For patients who have undergone maximum safe resection for low-grade intracranial ependymoma with no signs of dissemination on MRI and CSF analysis, adjuvant RT may be considered. RT is also an adjuvant treatment option for patients with myxopapillary ependymoma who had an STR or if capsule violation occurred, even if CSF cytology is negative. Craniospinal RT is recommended when MRI spine or CSF results reveal metastatic disease, regardless of histology and extent of resection.

Follow-up and Recurrence

Follow-up of ependymoma depends on tumor grade and the location and extent of the disease. For localized disease, contrast-enhanced brain and spine MRI (if initially positive) should be done 2 to 3 weeks postoperatively and then every 3 to 4 months for one year. The interval can then be extended to every 4 to 6 months in the years 2 through 4, every 6 to 12 months for years 5 through 10, then as clinically indicated depending on the physician's concern regarding the extent of disease, histology, and other relevant factors. If tumor recurrence in the brain or spine is noted on one of these scans, restaging by brain and spine MRI as well as CSF analysis is necessary. More frequent MRI scans may also be indicated indefinitely for close follow-up in this setting. Resection is recommended if possible.

Upon disease progression or recurrence, treatment options depend on extent of disease, imaging and CSF findings, and prior treatment. For patients not previously irradiated, treatment with RT or consideration of SRS in appropriate cases for localized recurrence (negative MRI scan and CSF results), or craniospinal RT, when there is evidence of neuraxis metastasis, is recommended. For patients who have received prior RT treatment, clinical trials, systemic therapy, or palliative/best supportive care (in the setting of poor functional status) are the treatment options for those with evidence of recurrence with or without metastasis based on imaging and CSF findings. Patients who have received prior RT, are in good functional status, and do not show evidence of neuraxis metastatic disease should be considered for enrollment in a clinical trial. Re-irradiation and systemic therapy may also be considered for these patients, as clinically appropriate.

Discussion update in progress

Version 3.2025 © 2025 National Comprehensive Cancer Network© (NCCN©), All rights reserved. NCCN Guidelines® and this illustration may not be reproduced in any form without the express written permission of NCCN.

PLEASE NOTE that use of this NCCN Content is governed by the End-User License Agreement, and you MAY NOT distribute this Content or use it with any artificial intelligence model or tool.
Printed by A. S. M. FAZLUL KARIM CHOWDHURY on 4/20/2026 3:06:38 AM. Copyright © 2026 National Comprehensive Cancer Network, Inc. All Rights Reserved.

Adult Medulloblastoma

Although medulloblastoma is the most common brain tumor in children, it also can occur in adults,[259] though it makes up only 1% of CNS tumors in adults.[260] These tumors are often located in the cerebellar hemisphere[261] and can be broken into distinct molecular subtypes: WNT-activated, SHH-activated, and non-WNT/non-SHH.[6,259,262] Subtype analysis continues to evolve.[263] Adult medulloblastoma tends to be different genomically from pediatric medulloblastoma, including differing prognostic markers.[264] 6q loss is a prognostic marker in pediatric medulloblastoma, but not in adult medulloblastoma.[265] Tumors activated by SHH signaling are common in adult medulloblastoma.[259,265,266] Metastatic disease is less common in adult medulloblastoma than in children. It tends to occur in patients with non-WNT, non-SHH disease.[267] One study showed that tumors activated by WNT signaling are associated with good OS outcomes ($P < .001$), based on a sample of patients with medulloblastoma that included children, infants, and adults, though trends were not statistically significant in analysis including only adults ($n = 65$).[259] An analysis of 28 adult patients with medulloblastomas showed that WNT signaling was associated with worse prognosis.[265] Somatic *CTNNB1* mutations are very common in WNT-activated tumors; germline *APC* mutations occur in these tumors as well but are less common.[268] In patients with tumors activated by SHH signaling, prognosis is poor for those with tumors that are *TP53*-mutant, compared to those with SHH-activated tumors that are not *TP53*-mutant, even when controlling for histology, sex, presence of distantly metastatic disease, and age.[269] Therefore, WHO further classifies SHH-mutant medulloblastoma as *TP53*-mutant and *TP53* wild-type.[6,270]

Treatment Overview

Since adult medulloblastoma is a rare adult CNS malignancy, patients should be considered for referral to specialized brain tumor centers. Given the impact of surgical treatment on survival, need for reproductive endocrine and fertility evaluation, consideration of stem cell collection, and the role of early neuro-rehabilitation, the panel strongly recommends referral to a specialized brain tumor center with experience in medulloblastoma. Adjuvant treatment initiation should not be delayed. Patients with rare CNS tumors should be considered for registration in national registries of rare tumors, https://clinicaltrials.gov/ct2/show/NCT02851706.

Surgery

Evidence in adult patients is meager for this rare disease and there are no randomized trial data, but there is general consensus that surgical resection should be the routine initial treatment to establish diagnosis, relieve symptoms, and maximize local control. Complete resection can be achieved in half of the patients[271-273] and is associated with improved survival.[271,274] When viewed by molecular subtype, near-total resection (<1.5 cm residual) and GTR produced equivalent OS for SHH, WNT, and Group 3 patients.[275] In addition, surgical placement of a ventriculoperitoneal shunt can be used to treat hydrocephalus.

Radiation Therapy

Adjuvant RT following surgery is the current standard of care, although most studies are based on the pediatric population. The conventional dose is 30 to 36 Gy of craniospinal irradiation and a boost to a total of 54 to 55.8 Gy to the primary brain site.[271,274] Data from pediatric trials support use of a lower craniospinal dose of 23.4 Gy, combined with systemic therapy, while maintaining 54 to 55.8 Gy to the posterior fossa.[276-278] A randomized pediatric trial for standard-risk patients treated with radiation alone found an increased relapse risk with dose reduction.[279] A multicenter study including 70 adults with nonmetastatic medulloblastoma showed that reduced-dose craniospinal irradiation (23.4 or 35.2 Gy with a boost of 55.2 Gy to the fossa posterior) with maintenance chemotherapy is feasible.[280] It is reasonable to consider proton beam for craniospinal irradiation where available, as it is associated with less toxicity.[281] SRS demonstrated safety

Discussion update in progress

Version 3.2025 © 2025 National Comprehensive Cancer Network© (NCCN©), All rights reserved. NCCN Guidelines® and this illustration may not be reproduced in any form without the express written permission of NCCN.

PLEASE NOTE that use of this NCCN Content is governed by the End-User License Agreement, and you MAY NOT distribute this Content or use it with any artificial intelligence model or tool.
Printed by A. S. M. FAZLUL KARIM CHOWDHURY on 4/20/2026 3:06:38 AM. Copyright © 2026 National Comprehensive Cancer Network, Inc. All Rights Reserved.

and efficacy in a small series of 12 adult patients with residual or recurrent disease.[282] Concomitant chemotherapy (vincristine) is typically omitted in adults given potential for severe toxicity.

Systemic Therapy

The use of post-irradiation systemic therapy to allow RT dose reduction is becoming increasingly common especially for children,[276,277] but optimal use of adjuvant chemotherapy is still unclear for adult patients.[273,283-286] Neoadjuvant therapy has not shown a benefit in pediatric or adult patients.[287-289] It is used in infants to defer radiation. A phase III study that enrolled more than 400 patients between 3 and 21 years of age with average-risk disease to receive post-irradiation cisplatin-based chemotherapy regimens recorded an encouraging 86% 5-year survival.[278]

In the setting of recurrence, several regimens are in use in the recurrence setting, most of which include etoposide.[290-293] Temozolomide has also been used in this setting.[133,294] High-dose chemotherapy in combination with autologous stem cell transplantation is a feasible strategy for patients who have had good response with conventional-dose chemotherapy, although long-term control is rarely achieved.[292,295] SHH-pathway inhibitors that have been evaluated in phase II trials including adults with recurrent medulloblastoma include vismodegib[296] and sonidegib.[297] Patients in these trials with SHH-activated disease were more likely to respond than patients with non-SHH disease.[296,297]

NCCN Recommendations

Primary Treatment

MRI scan is the gold standard in the assessment of medulloblastoma. The typical tumor shows enhancement and heterogeneity. Diffusion-weighted abnormalities are also characteristic of medulloblastoma. Fourth ventricular floor infiltration is a common finding related to worse prognosis.[283,285,286] Multidisciplinary consultation before treatment initiation is advised. Maximal safe resection is recommended wherever possible. Contrast-enhanced brain MRI should be performed within 48 hours following surgery, but spinal MRI should be delayed by 2 to 3 weeks. Because of the propensity of medulloblastoma to CSF seeding, CSF sampling after spine imaging via lumbar puncture is also necessary for staging. Molecular profiling is recommended, as identification of clinically relevant medulloblastoma subtypes (eg, SHH-activated) may encourage opportunities for clinical trial enrollment. Medulloblastoma should be staged according to the modified Chang system using information from both imaging and surgery.[298,299]

Adjuvant Therapy

Patients should be stratified according to recurrence risk for planning of adjuvant therapy (reviewed by Brandes et al[300]). The NCCN Panel agrees that patients with large cell medulloblastoma, disease dissemination, unresectable tumors, or residual tumors greater than 1.5 cm^2 post-surgery are at heightened risk. These patients should undergo irradiation of the neuraxis and systemic therapy. Collection of stem cells before RT may be considered on the condition that RT is not delayed for potential future autologous stem cell reinfusion at disease progression. For patients at average risk, craniospinal RT with or without systemic therapy or reduced-dose craniospinal RT with systemic therapy followed by post-irradiation systemic therapy are viable options.

Recurrence and Progression

There are no robust data supporting an optimal follow-up schedule for medulloblastoma. Panel recommendations include brain MRI every 3 months for the first 2 years, every 6 to 12 months for 5 to 10 years, then every 1 to 2 years or as clinically indicated. If recurrent disease is detected on these scans, CSF sampling is also required, and concurrent spine imaging should be performed. Bone scans; contrast-enhanced CT scans

Discussion update in progress

Version 3.2025 © 2025 National Comprehensive Cancer Network© (NCCN©), All rights reserved. NCCN Guidelines® and this illustration may not be reproduced in any form without the express written permission of NCCN.

PLEASE NOTE that use of this NCCN Content is governed by the End-User License Agreement, and you MAY NOT distribute this Content or use it with any artificial intelligence model or tool.
Printed by A. S. M. FAZLUL KARIM CHOWDHURY on 4/20/2026 3:06:38 AM. Copyright © 2026 National Comprehensive Cancer Network, Inc. All Rights Reserved.

of the chest, abdomen, and pelvis; and bone marrow biopsies may be considered as indicated.

Maximal safe resection should be attempted for recurrent medulloblastoma if symptomatic and there is no evidence of dissemination. Additional options include systemic therapy alone and RT alone. High-dose chemotherapy with autologous stem cell rescue may be considered for patients showing no evidence of disease after conventional reinduction chemotherapy. Patients with metastases should be managed by systemic therapy or best supportive care, which can include palliative RT. In very select cases, intrathecal chemotherapy might be utilized.

Primary CNS Lymphomas

PCNSL accounts for approximately 3% of all neoplasms and 4% to 6% of all extranodal lymphomas.[301] It is an aggressive form of non-Hodgkin lymphoma that develops within the brain, spinal cord, eye, or leptomeninges without evidence of systemic involvement. The overall incidence of PCNSL in immunocompetent patients is 0.47 per 100,000 person-years, with higher incidence in males than in females and an increasing incidence with age.[301] The greatest increase in incidence has been reported in older adults with 1.8 per 100,000 patient-years reported in patients aged ≥65 years and 1.9 in patients aged ≥75 years, indicating that, in immunocompetent patients, PCNSL is a disease of older adults.[301,302] Non-immunosuppressed patients have a better prognosis than AIDS-related cases,[303] and survival of this group has improved over the years with treatment advances.[304,305] For more guidance on treatment of patients with PCNSL who are living with HIV, see the NCCN Guidelines for Cancer in People with HIV (available at www.NCCN.org).

Pathologically, PCNSL is an angiocentric neoplasm composed of a dense monoclonal proliferation of lymphocytes, usually diffuse large B cells.[306] More than 90% of these primary CNS diffuse large B-cell lymphoma cases are of the activated B-cell–like (ABC) subtype.[307] The tumor is infiltrative and typically extends beyond the primary lesion, as shown by CT or MRI scans, into regions of the brain with an intact BBB.[307] The brain parenchyma is involved in more than 90% of all PCNSL patients, and the condition can be multifocal in more than 50% of cases. Leptomeningeal involvement may occur, either localized to adjacent parenchymal sites or in diffuse form (that is, positive cytology) in up to 30% of patients. Ocular involvement may develop independently in 10% to 20% of patients. Patients with PCNSL can present with various symptoms because of the multifocal nature of the disease. In a retrospective review of 248 immunocompetent patients, 43% had mental status changes, 33% showed signs of elevated intracranial pressure, 14% had seizures, and 4% suffered visual symptoms at diagnosis.[308]

PCNSL occurs in about 7% to 15% of patients with post-transplant lymphoproliferative disorders (PTLDs)[309-312] and is associated with poor prognosis.[311,313,314] PTLDs are a heterogeneous group of lymphoid neoplasms associated with immunosuppression following solid organ transplantation (SOT) or allogeneic hematopoietic stem cell transplantation (HCT).[315-317] For guidance on managing transplant recipients, see the Post-Transplant Lymphoproliferative Disorders sub-algorithm in the NCCN Guidelines for Diffuse Large B-Cell Lymphoma (available at www.NCCN.org).

Treatment Overview

Steroid Administration

Steroids can rapidly alleviate signs and symptoms of PCNSL and improve PS. However, as these drugs are cytolytic, they can significantly decrease enhancement and size of tumors on CT and MRI scans as well as affect the histologic appearance. In the absence of significant mass effect, it is recommended that steroids be withheld or used judiciously until diagnostic tissue can be obtained if PCNSL is suspected.

Discussion update in progress

Version 3.2025 © 2025 National Comprehensive Cancer Network© (NCCN©), All rights reserved. NCCN Guidelines® and this illustration may not be reproduced in any form without the express written permission of NCCN.

PLEASE NOTE that use of this NCCN Content is governed by the End-User License Agreement, and you MAY NOT distribute this Content or use it with any artificial intelligence model or tool.
Printed by A. S. M. FAZLUL KARIM CHOWDHURY on 4/20/2026 3:06:38 AM. Copyright © 2026 National Comprehensive Cancer Network, Inc. All Rights Reserved.

Stereotactic Biopsy

In contrast to the principles previously outlined for invasive astrocytomas and other gliomas, the surgical goals for PCNSL are different, with the main goal being establishment of diagnosis under minimal risk of morbidity. Currently, most authors recommend biopsy rather than resection.[318] This approach stems from the fact that data do not demonstrate a survival advantage for patients who have had a complete resection or extensive STR when compared with those who have had only a stereotactic biopsy. In addition, STR is associated with risk for postoperative neurologic deficits.[308]

Systemic Therapy

Methotrexate is the most effective agent against PCNSL. It is commonly used in combination with other drugs such as procarbazine, vincristine, cytarabine, rituximab, and temozolomide.[319-333] High doses of intravenous methotrexate are necessary (≥3.5 g/m^2) to overcome the BBB and achieve therapeutic levels in the CSF. Intrathecal methotrexate can be useful in select cases where CSF cytology yields positive findings and when patients cannot tolerate systemic methotrexate at 3.5 g/m^2 or higher. Other intrathecal chemotherapy options in this setting include cytarabine[334] and rituximab.[335] Phase II trials in the United States and Europe have shown that high-dose chemotherapy with autologous stem cell transplantation following high-dose methotrexate-based chemotherapy is feasible and well-tolerated, with little evidence of neurotoxicity.[329,336-343]

Renal dysfunction induced by high-dose methotrexate therapy is a potentially lethal medical emergency due to heightened toxicities resulting from a delay in methotrexate excretion. Early intervention with glucarpidase, a recombinant bacterial enzyme that provides an alternative route for methotrexate clearance, has shown efficacy in rapidly reducing plasma concentrations of methotrexate and preventing severe toxicity.[344,345]

Other regimens combined with methotrexate have been evaluated as induction therapy for PCNSL. The international randomized phase 2 MATRix trial randomized patients with newly diagnosed PCNSL (N = 219) into one of three study arms: 1) methotrexate and cytarabine; 2) methotrexate, cytarabine, and rituximab; and 3) methotrexate, cytarabine, rituximab, and thiotepa (MATRix).[346] Complete response was more likely to have been achieved in the MATRix arm (49%; 95% CI, 38%–60%) compared to the methotrexate, cytarabine, and rituximab arm (30%; 95% CI, 21%–42%) and the methotrexate + cytarabine arm (23%; 95% CI, 14%–31%). In the multicenter international randomized HOVON study, patients with newly diagnosed PCNSL (N = 200) were randomized to receive methotrexate, carmustine, teniposide, and prednisolone with or without rituximab.[333] OS at 1, 2, and 3 years was 79% (95% CI, 69%–86%), 65% (95% CI, 55%–74%), and 61% (95% CI, 51%–71%), respectively, for the arm that did not receive rituximab, and 79% (95% CI, 69%–85%), 71% (95% CI, 60%–79%), and 58% (95% CI, 46%–68%), respectively, for the arm that received rituximab. Limitations of these studies include selective inclusion criteria with exclusion of patients aged >70 years.[333,346] The MATRix study showed that this regimen was associated with significant marrow toxicity.[346] Other limitations of the HOVON study include use of consolidation WBRT in younger patients, which may not be tolerable in older patients; and only six doses of rituximab administered.[333] Further, teniposide is not FDA approved for this indication and is no longer available in the United States. Methotrexate/carmustine/teniposide/prednisone with or without rituximab was subsequently removed from the Guidelines as an induction therapy option in 2022.

It has become clear that consolidative therapy can result in significant and sometimes lethal neurotoxic effects from consolidation RT, especially in patients >60 years of age.[323,347,348] Complete response to chemotherapy ranges from 42% to 61%, with OS ranging between 14 and 55 months. A

Discussion update in progress

Version 3.2025 © 2025 National Comprehensive Cancer Network© (NCCN©), All rights reserved. NCCN Guidelines® and this illustration may not be reproduced in any form without the express written permission of NCCN.

PLEASE NOTE that use of this NCCN Content is governed by the End-User License Agreement, and you MAY NOT distribute this Content or use it with any artificial intelligence model or tool.
Printed by A. S. M. FAZLUL KARIM CHOWDHURY on 4/20/2026 3:06:38 AM. Copyright © 2026 National Comprehensive Cancer Network, Inc. All Rights Reserved.

number of phase II trials have adopted the approach of chemotherapy without planned RT.[320,323,349-353] However, a high fraction of patients who have forgone initial RT—typically older or with significant comorbidities—may fail to achieve complete response to chemotherapy. Studies investigating the efficacy of methotrexate-based regimens as induction therapy for patients with PCNSL have utilized WBRT, including reduced WBRT following cytarabine as consolidation treatment.[322-324]

There are currently no conclusive prospective data published comparing consolidation with high-dose chemotherapy regimens or high-dose chemotherapy with autologous stem cell transplantation versus maintenance therapy or observation, and there are different approaches at different institutions. Consolidation with high-dose chemotherapy and autologous stem cell transplant is frequently considered for fitter patients. Eligibility criteria used in the respective trials that studied these regimens need to be carefully considered when considering this approach, and referral to centers with subspecialty expertise in PCNSL should be considered.

Cytarabine combined with etoposide as high-dose consolidation therapy following induction treatment with methotrexate, temozolomide, and rituximab was evaluated in the multicenter Alliance 50202 trial.[354] This protocol was feasible and generally well-tolerated, with one treatment-related death.

High-dose chemotherapy with autologous stem cell transplantation in the relapsed/refractory setting has been tested with some success in two phase 2 European trials,[355,356] although evidence of its advantage over conventional treatment is lacking. The German Cooperative PCNSL Study Group evaluated the safety and efficacy of rituximab, high-dose cytarabine, and thiotepa followed by autologous stem cell transplantation in 39 patients with relapsed or refractory PCNSL with previous high-dose methotrexate-based treatment.[356] A complete response was achieved in 56% of the patients. Out of the remaining patients, only one had progressive disease (18% of the patients had a partial response or stable disease). However, median OS was not reached, with a 2-year OS rate of 56.4%. Median PFS was 12.4 months, with a 2-year PFS rate of 46%. A phase 2 trial from France evaluated the efficacy of high-dose cytarabine and etoposide followed by autologous stem cell transplantation in 43 patients with relapsed or refractory PCNSL with previous high-dose methotrexate-based treatment.[355] Out of the 27 patients who completed autologous stem-cell rescue, median OS was 58.6 months (2-year OS was 69%) and median PFS was 41.1 months (2-year PFS was 58%).

High-dose chemotherapy and autologous stem cell transplantation as part of initial treatment has now been explored in several trials. High complete response rates and 2-year PFS have been demonstrated.[329,357] Whether high-dose chemotherapy and autologous stem cell rescue provide any additional benefit over consolidative conventional-dose is being investigated in two trials currently in progress. Consolidative conventional-dose chemotherapy (NCTNA51101, MATRIX)[358] or consolidative WBRT (ANOCEF-GOELAMS, IELSG32)[359] have resulted in equivalent 2-year PFS in randomized phase II trials. Toxicities differ and might be a basis for individual patient selection. Of note, longitudinal neurocognitive assessment in the IELSG32 study showed persistent neurocognitive impairment in the consolidative WBRT group, but not in the high-dose chemotherapy group. Preliminary analysis of the NCTN A51101 trial showed a median PFS of 2.4 years for consolidative non-myeloablative chemotherapy, compared to a median PFS of 6 years after myeloablative consolidation, both following initial induction therapy.[360] The extent to which the patient selection inherent in high-dose chemotherapy trials underlies these favorable outcomes remains to be determined.

Unfortunately, even for patients who initially achieved complete response, about half will eventually relapse. Re-treatment with high-dose

Discussion update in progress

Version 3.2025 © 2025 National Comprehensive Cancer Network© (NCCN©), All rights reserved. NCCN Guidelines® and this illustration may not be reproduced in any form without the express written permission of NCCN.

PLEASE NOTE that use of this NCCN Content is governed by the End-User License Agreement, and you MAY NOT distribute this Content or use it with any artificial intelligence model or tool.
Printed by A. S. M. FAZLUL KARIM CHOWDHURY on 4/20/2026 3:06:38 AM. Copyright © 2026 National Comprehensive Cancer Network, Inc. All Rights Reserved.

methotrexate may produce a second response in patients who achieved complete response with prior exposure.[361] Rituximab as well as ibrutinib may be used in combination with high-dose methotrexate retreatment.[362] Several other regimens, including ibrutinib,[363,364] rituximab,[365] TMZ with or without rituximab,[366-369] lenalidomide with or without rituximab,[370] high-dose cytarabine,[371] pomalidomide,[372] and pemetrexed[373] have also shown activity in the relapsed/refractory disease setting, but none has been established as a standard of care.

Radiation Therapy

Historically, WBRT was the treatment standard to cover the multifocal nature of the disease. The majority of studies demonstrated the limitation of high-dose RT and led to the recommended dose of 24 to 36 Gy in 1.8 to 2.0 Gy fractions to the whole brain, without a boost.[322,324,374-377] Although RT alone is useful for initial tumor control, frequent and rapid relapse of the disease led to a short OS of 12 to 17 months.[303,376] This dismal outcome has prompted the addition of pre-irradiation methotrexate-based combination chemotherapy in later studies. This approach yields impressive response rates of up to 94% and improved OS ranging from 33 to 60 months.[322-324,332,347,348,374,378,379] However, excessive grade 3 and 4 hematologic toxicity (≤78%) as well as RT-induced delayed neurotoxicity (≤32%) sometimes leading to deaths are primary concerns, although most of these studies utilized a high RT dose of greater than or equal to 40 Gy. Of note, younger patients (aged <60 years) consistently fare better, and there is a higher incidence of late neurotoxic effects in older patients, but significant neurotoxicity can also occur in younger adults.

Thiel and colleagues[380] conducted a randomized, phase III, non-inferiority trial of high-dose methotrexate plus ifosfamide with or without WBRT in 318 patients with PCNSL. There was no difference in OS (HR, 1.06; 95% CI, 0.80–1.40; $P = .71$), but the primary hypothesis (0.9 non-inferiority margin) was not proven. Patients who received WBRT had a higher rate of neurotoxicity than those who did not (49% vs. 26%). The panel currently recommends that patients receiving WBRT because they are not candidates for chemotherapy should receive a dose of 24 to 36 Gy with a boost to gross disease, for a total dose of 45 Gy.

Although WBRT alone is seldom sufficient as primary treatment and is primarily reserved for patients who cannot tolerate multimodal treatment, it may be a reasonable treatment option for patients not suitable for other systemic therapies or clinical trials. Results from a phase II trial showed that reduced-dose WBRT (23.4 Gy in 1.8 Gy/fraction) following a complete response to induction chemotherapy was associated with disease response and long-term control, as well as low neurotoxicity.[381] When administered after chemotherapy failure, WBRT has shown response rates reaching nearly 75%.[382] Median PFS was 9.7 months overall, 57.6 months in patients who had achieved a CR with WBRT, and 9.7 months in patients with a PR. For patients who had a less than complete response to chemotherapy, a dosing schedule consistent with that used for induction treatment may be used, followed by a limited field to gross disease, or focal RT to residual disease.

NCCN Recommendations

Initial Evaluation

Neuroradiologic evaluation is important in the diagnosis of PCNSL and to evaluate the effectiveness of subsequent therapy. With MRI, the tumor is often isointense or hypointense on T1- and T2-weighted images and enhances frequently.[383] In addition, restricted diffusion can be seen in the area of the enhancing abnormality on diffusion-weighted imaging sequences. On a CT scan, PCNSL is usually isodense or hyperdense compared to the brain and enhances in most cases. Hallmark features include a periventricular distribution, ring enhancement, multiple lesions, and a smaller amount of edema than might otherwise be expected from a similar-sized metastatic tumor or glioma. If contrast-enhanced brain MRI

Discussion update in progress

Version 3.2025 © 2025 National Comprehensive Cancer Network© (NCCN©), All rights reserved. NCCN Guidelines® and this illustration may not be reproduced in any form without the express written permission of NCCN.

PLEASE NOTE that use of this NCCN Content is governed by the End-User License Agreement, and you MAY NOT distribute this Content or use it with any artificial intelligence model or tool.
Printed by A. S. M. FAZLUL KARIM CHOWDHURY on 4/20/2026 3:06:38 AM. Copyright © 2026 National Comprehensive Cancer Network, Inc. All Rights Reserved.

(or contrast-enhanced CT if MRI is contraindicated) suggests PCNSL, clinicians are advised to hold the use of steroids if possible before diagnosis is established, since the imaging and histologic features of PCNSL can be profoundly affected by these drugs.

Patients with an enhancing brain lesion consistent with PCNSL should receive a biopsy (if lesion is amenable to biopsy), as this is the most direct and rapid route to achieve a pathologic diagnosis. Because the role of maximal surgical resection is limited to alleviating symptoms of raised intracranial pressure or preventing herniation,[308] stereotactic biopsy is generally preferred to minimize invasiveness.[318] Even with molecular marker testing, however, a biopsy can occasionally be falsely negative, particularly if the patient had been treated previously with steroids. Thus, if a biopsy is nondiagnostic, the panel recommends that the steroids be tapered and that the patient be followed closely, both clinically and radiographically. If and when the lesion recurs, there should be a prompt repeat CSF evaluation or rebiopsy before the initiation of steroids. If, on the other hand, no definitive diagnosis of lymphoma is made from biopsy and the patient has not received steroid therapy, workup for other diagnoses (for example, inflammatory processes) or repeat CSF evaluation/rebiopsy is recommended. In some cases, diagnosis can be made by CSF analysis or by pathologic diagnosis of vitreoretinal disease.

Evaluation for Extent of Disease

Once the diagnosis of PCNSL is established, the patient should undergo a thorough staging workup detailed by The International PCNSL Collaborative Group.[318] This workup involves a complete CNS evaluation including imaging of the entire neuraxis (MRI of the spine with contrast). If possible, this should be done before CSF analysis is attempted to avoid post-lumbar puncture artifacts that can be mistaken for leptomeningeal disease on imaging.

A lumbar puncture with evaluation of CSF (15–20 mL of spinal fluid) should be considered, if it can be done safely and without concern for herniation from increased intracranial pressure, and if it will not delay diagnosis and treatment. A delay in treatment may compromise patient outcomes.[354] Caution should be taken in patients who are anticoagulated, thrombocytopenic, or who have a bulky intracranial mass. CSF analysis should include flow cytometric analysis, CSF cytology, and cell count. The yield for a positive diagnostic test can be increased by the use of molecular markers of monoclonality, such as an immunoglobulin gene rearrangement.

Since disease is sometimes detected in the retina and optic nerve, a full ophthalmologic exam should be done, which should include a slit-lamp eye examination. In some cases, the diagnosis of lymphoma is made by vitrectomy; in this case, flow cytometric analysis is recommended. In addition, blood work (CBC and chemistry panel) and a contrast-enhanced body CT or PET/CT[384] are required to rule out systemic involvement. Elevated lactate dehydrogenase (LDH) serum level is associated with worse survival in patients with PCNSL,[385,386] and LDH should be evaluated as part of the workup for this disease. Bone marrow biopsy is a category 2B option that may be considered. In men >60 years of age, testicular ultrasound may be considered (category 2B). In these patients, regular testicular examination is encouraged. If both testicular examination and CT or PET/CT imaging are negative, then testicular ultrasound may not be necessary.

An HIV blood test should also be performed, because both prognosis and treatment of patients with HIV-related PCNSL may be different than that of patients who are otherwise immunocompetent. HIV-positive patients should receive highly active retroviral therapy in addition to their cancer therapy.

Discussion update in progress

Version 3.2025 © 2025 National Comprehensive Cancer Network© (NCCN©), All rights reserved. NCCN Guidelines® and this illustration may not be reproduced in any form without the express written permission of NCCN.

PLEASE NOTE that use of this NCCN Content is governed by the End-User License Agreement, and you MAY NOT distribute this Content or use it with any artificial intelligence model or tool.
Printed by A. S. M. FAZLUL KARIM CHOWDHURY on 4/20/2026 3:06:38 AM. Copyright © 2026 National Comprehensive Cancer Network, Inc. All Rights Reserved.

Newly Diagnosed Disease

Induction treatment should be initiated as soon as possible following confirmation of diagnosis. The International PCNSL Collaborative Group has published treatment response criteria for complete response, unconfirmed complete response, partial response, progressive disease, and relapsed disease.[318] Given the dramatic effect of steroids on symptom relief, they are commonly administered concurrently with workup. A high-dose methotrexate-containing regimen is the recommended induction treatment. In the case of methotrexate-induced renal dysfunction, consider glucarpidase to aid clearance. Non–methotrexate-based regimens may be used if the patient cannot tolerate methotrexate, usually those with impaired renal function.

If a patient is found to have malignant uveitis, orbital RT may be considered because of poor penetration of systemic chemotherapy into the uveal fluid. However, there are reports of clearance of ocular lymphoma in patients who were treated with systemic high-dose methotrexate.[320] Therefore, for a patient with PCNSL who has asymptomatic ocular involvement, a reasonable strategy is to delay RT to the globe in order to see if high-dose methotrexate is effective. Referral to a neuro-ophthalmologist or ophthalmologic oncologist for intraocular injection of chemotherapy (category 2B) is also an option.

WBRT may be used in patients who are not candidates for chemotherapy. For a patient treated with WBRT, consideration of intra-CSF chemotherapy plus focal spinal RT are treatment options if the lumbar puncture or spinal MRI are positive. Intrathecal chemotherapy options include methotrexate, cytarabine, and rituximab.

Treatment following induction high-dose methotrexate-based therapy depends on disease response.[318] Given the rarity of this disease, there are few high-quality studies to inform treatment decision-making. For patients who have a complete or unconfirmed complete response, consolidation therapy options that may be considered include high-dose chemotherapy (cytarabine/thiotepa followed by carmustine/thiotepa; or thiotepa/busulfan/cyclophosphamide [TBC]) with stem cell rescue[329,336-342] or low-dose WBRT. However, WBRT in this setting may increase neurotoxicity,[380,387] especially in patients >60 years.[323,347,348] High-dose cytarabine with or without etoposide is also a consolidation treatment option for patients who had a complete response to induction high-dose methotrexate-based therapy (this regimen may also be considered in patients who do not have a complete response).[322-324,354] If there is not a complete or unconfirmed complete disease response following induction therapy, it is recommended to pursue another systemic therapy or WBRT in order to rapidly induce a response, diminish neurologic morbidity, and optimize quality of life. Best supportive care is another option for patients with residual disease following methotrexate-based treatment who are not candidates for other reasonable rescue therapies.

Relapsed or Refractory Disease

Patients should be followed using brain MRI. Imaging of the spine and CSF sampling may be done as clinically indicated for patients with spine disease. If there is ocular involvement, ophthalmologic exams may also be carried out.

For patients who are treated with prior WBRT and ultimately relapse, they may consider further chemotherapy (systemic and/or intrathecal), focal reirradiation, or palliative/best supportive care.

For patients who were initially treated with high-dose methotrexate-based chemotherapy but did not receive WBRT, the decision about whether to use other systemic therapy or proceed to RT at the time of relapse depends on the duration of response to initial chemotherapy. If a patient had experienced a relatively long-term response of about one year or more, then treating either with the same (in most cases, high-dose methotrexate-based therapy) or another regimen is reasonable. However,

Discussion update in progress

Version 3.2025 © 2025 National Comprehensive Cancer Network© (NCCN©), All rights reserved. NCCN Guidelines® and this illustration may not be reproduced in any form without the express written permission of NCCN.

PLEASE NOTE that use of this NCCN Content is governed by the End-User License Agreement, and you MAY NOT distribute this Content or use it with any artificial intelligence model or tool.
Printed by A. S. M. FAZLUL KARIM CHOWDHURY on 4/20/2026 3:06:38 AM. Copyright © 2026 National Comprehensive Cancer Network, Inc. All Rights Reserved.

for patients who either have no response or relapsed within a very short time after systemic therapy, recommendations include switching to a different chemotherapy regimen, or WBRT, or involved-field RT with or without chemotherapy.[382] In either case, palliative/best supportive care remains an option.

High-dose chemotherapy with stem cell rescue may also be considered as treatment for relapsed/refractory disease in patients who did not previously receive this treatment (ie, patients who were treated with high-dose methotrexate-based therapy or with WBRT) (category 2B). Regardless of primary treatment received, stem cell rescue should only be used for relapsed/refractory disease if there is a complete or partial response to re-induction high-dose chemotherapy.

For patients previously treated with high-dose chemotherapy with stem cell rescue, retreatment may be considered if there was a previous disease response and if time to relapse was at least one year. For patients who did not have a response to high-dose chemotherapy with stem cell rescue, and the time to relapse was less than one year, treatment options include RT to the whole brain or to the involved field. Regardless of time to relapse, using a different systemic therapy regimen (without stem cell rescue) and best supportive care are also options.

As there is no uniform standard of care for the treatment of refractory or relapsed PCNSL, participation in clinical trials is encouraged.

Primary Spinal Cord Tumors

Spinal tumors are classified according to their anatomic location as extradural, intradural-extramedullary, and intradural-intramedullary. Extradural tumors are primarily due to metastatic disease and are discussed in the section *Metastatic Spinal Tumors*. This section focuses on intradural primary spinal tumors.

Primary spinal cord tumors are a histologically diverse set of diseases that represent 2% to 4% of all primary CNS tumors. The overall incidence is 0.74 per 100,000 person-years with a 10-year survival rate of 64%.[388] Extramedullary lesions, most commonly benign meningiomas, account for 70% to 80% of spinal cord tumors.[389] Astrocytomas (more prevalent in children) and ependymomas (more prevalent in adults) are the most common intramedullary tumors. Clinicians are advised to refer to the corresponding sections in these guidelines for further details regarding these subtypes, as intracranial and spinal lesions are biologically similar.

Individuals with type I neurofibromatosis, type II neurofibromatosis, and von Hippel-Lindau (VHL) syndrome are predisposed to form, respectively, spinal astrocytomas, spinal peripheral nerve sheath tumors, spinal ependymomas, and intramedullary hemangioblastomas.

Since 70% of primary spinal cord tumors are low-grade and slow-growing,[388] it is common for patients to suffer from pain for months to years before diagnosis. Pain that worsens at night is a classic symptom for intramedullary lesions. Progressive motor weakness occurs in half of the patients, and patients may experience sensory loss with late autonomic dysfunction (incontinence).

Treatment Overview

Observation

Many asymptomatic primary tumors of the spinal cord, especially grade 1 meningiomas and peripheral nerve sheath tumors, follow an indolent course and can be followed by observation without immediate intervention.

Surgery

Surgery is the preferred primary treatment when the tumor is symptomatic and amenable to surgical resection. For lesions that are radiographically well defined, such as ependymoma, WHO grade 1 astrocytoma, hemangioblastoma, schwannoma, and WHO grade 1 meningioma,

Discussion update in progress

Version 3.2025 © 2025 National Comprehensive Cancer Network© (NCCN©), All rights reserved. NCCN Guidelines® and this illustration may not be reproduced in any form without the express written permission of NCCN.

PLEASE NOTE that use of this NCCN Content is governed by the End-User License Agreement, and you MAY NOT distribute this Content or use it with any artificial intelligence model or tool.
Printed by A. S. M. FAZLUL KARIM CHOWDHURY on 4/20/2026 3:06:38 AM. Copyright © 2026 National Comprehensive Cancer Network, Inc. All Rights Reserved.

potentially curative, maximal, safe resection is the goal. En bloc total resection yielded excellent local control rates of more than 90%.[390-393]

GTR is seldom feasible with grade 2 or higher astrocytomas because they are infiltrative and poorly circumscribed. In a study of 202 patients with intramedullary tumors, over 80% of grade 1 astrocytomas were completely resected, while total resection was achieved in only 12% of grade 2 tumors.[394] Nevertheless, Benes et al[395] conducted a review of 38 studies on spinal astrocytomas and concluded that maximal safe resection should be attempted whenever possible based on reports of survival benefit.

Radiation Therapy

RT is not recommended as the primary therapy without surgery and unknown histology because of the potential for limited response and low RT tolerance of the spinal cord. It is also not advisable following GTR of certain histologies, as select spinal cord tumors that can be excised completely have a low local recurrence rate.

A large retrospective analysis including more than 1700 patients with primary spinal gliomas found an association between RT and worse cause-specific survival and OS, although there may be a bias that patients who received RT had more adverse factors.[396] The role of adjuvant RT following incomplete excision or biopsy remains controversial.[395,397,398] One exception is primary spinal myxopapillary ependymoma, for which postoperative RT has been demonstrated to reduce the rate of tumor progression.[399,400] On the other hand, EBRT is considered a viable option at disease progression or recurrence. SRS has also shown safety and efficacy in several patient series, including patients with spinal cord hemangioblastoma.[401-404]

Systemic Therapy

Unfortunately, evidence on efficacious chemotherapeutic agents for primary spinal cord tumors is too scant for specific recommendations. The panel agrees that systemic therapy should be an option where surgery and RT fail, but there is no consensus on the best regimen. Systemic therapy is best given in the setting of a clinical trial.

In August 2021, the FDA approved the HIF-2alpha inhibitor belzutifan for the treatment of patients with VHL-associated CNS hemangioblastomas not requiring immediate surgery. Approval was based on results of a nonrandomized phase 2 trial that included patients with VHL-associated renal cell carcinoma (N = 61).[405] Objective response in patients with CNS hemangioblastoma was 30% (n = 50).

NCCN Recommendations

MRI imaging is the gold standard for diagnosis of spinal cord lesions. However, CT myelogram may be used for diagnosis in patients for whom MRI is contraindicated. Asymptomatic patients may be observed (especially for suspected low-grade) or resected, while all symptomatic patients should undergo some form of surgery. The surgical plan and outcome are influenced by whether a clear surgical plan is available.[406] Whenever possible, maximal safe resection should be attempted, with a spine MRI 2 to 3 weeks following surgery to assess the extent of the resection. Postoperative adjuvant RT is appropriate if symptoms persist after incomplete resection or biopsy, or for patients with myxopapillary ependymoma that has been incompletely resected. Patients should be managed according to the pathology results (see *Low-Grade Gliomas*, *High-Grade Gliomas [Including Glioblastoma]*, and *Intracranial and Spinal Ependymomas*). Those diagnosed with hemangioblastoma should consider screening for VHL syndrome including neuraxis imaging.[407]

All patients should be followed by sequential MRI scans, with a greater frequency in patients with high-grade tumors. At progression or recurrence, re-resection is the first choice. If this is not feasible, conventional EBRT is the next option. Systemic therapy is reserved for

Discussion update in progress

Version 3.2025 © 2025 National Comprehensive Cancer Network© (NCCN©), All rights reserved. NCCN Guidelines® and this illustration may not be reproduced in any form without the express written permission of NCCN.

PLEASE NOTE that use of this NCCN Content is governed by the End-User License Agreement, and you MAY NOT distribute this Content or use it with any artificial intelligence model or tool.
Printed by A. S. M. FAZLUL KARIM CHOWDHURY on 4/20/2026 3:06:38 AM. Copyright © 2026 National Comprehensive Cancer Network, Inc. All Rights Reserved.

cases where both surgery and RT are contraindicated. Specific regimens are dependent on primary tumor type. Belzutifan is a systemic therapy option for patients with VHL-associated CNS hemangioblastoma not requiring immediate surgery.[405]

Meningiomas

Meningiomas are extra-axial CNS tumors arising from the arachnoid cap cells in the meninges. They are most often discovered in middle-to-late adult life, and have a female predominance. The annual incidence for males and females reported by the Central Brain Tumor Registry of the United States (CBTRUS) are 1.8 and 3.4 per 100,000 people, respectively.[408] In a review of 319 cases using the WHO grading scale, 92% of meningiomas are WHO grade 1, 6% are grade 2 (atypical), and 2% are grade 3.[409] Small tumors are often asymptomatic, incidental findings.[410] Seizure is a common presenting symptom occurring in 27% of patients.[411]

Imaging

Brain imaging with contrast-enhanced CT or MRI is the most common method of diagnosing, monitoring, and evaluating response to treatment (review by Campbell et al[412]). The CT scan best reveals the chronic effects of slowly growing mass lesions on bone remodeling. Calcification in the tumor (seen in 25%) and hyperostosis of the surrounding skull are features of an intracranial meningioma that can be easily identified on a non-contrast CT scan. Nonetheless, MRI reveals a number of imaging characteristics highly suggestive of meningioma, and in SRS articles, MR has been used to operationally define pathology. These MR findings include a tumor that is dural-based and isointense with gray matter, demonstrates prominent and homogeneous enhancement (>95%), has frequent CSF/vascular cleft(s), and often has an enhancing dural tail (60%). However, approximately 10% to 15% of meningiomas have an atypical MRI appearance mimicking metastases or malignant gliomas. In particular, secretory meningiomas may have a significant amount of peritumoral edema. Cerebral angiography is occasionally performed, often for surgical planning, as meningiomas are vascular tumors prone to intraoperative bleeding. In some instances preoperative embolization is helpful for operative hemostasis management. Angiographic findings consistent with a meningioma include a dual vascular supply with dural arteries supplying the central tumor and pial arteries supplying the tumor periphery. A “sunburst effect” may be seen due to enlarged and multiple dural arteries, and a prolonged vascular stain or so-called “blushing” can be seen, which results from intratumoral venous stasis and expanded intratumoral blood volume.

Meningiomas are also known to have high somatostatin receptor density, which allows for the use of octreotide brain scintigraphy to help delineate extent of disease and to pathologically define an extra-axial lesion.[413-415] Octreotide imaging with radiolabeled indium or, more recently, gallium may be particularly useful in distinguishing residual tumor from postoperative scarring in subtotally resected/recurrent tumors.

Treatment Overview

Observation

Studies that examined the growth rate of incidental meningiomas in otherwise asymptomatic patients suggested that many asymptomatic meningiomas may be followed safely with serial brain imaging until either the tumor enlarges significantly or becomes symptomatic.[416,417] These studies confirm the tenet that many meningiomas grow very slowly and that a decision not to operate is justified in selected asymptomatic patients. As the growth rate is unpredictable in any individual, repeat brain imaging is mandatory to monitor an incidental asymptomatic meningioma.

Discussion update in progress

Version 3.2025 © 2025 National Comprehensive Cancer Network© (NCCN©), All rights reserved. NCCN Guidelines® and this illustration may not be reproduced in any form without the express written permission of NCCN.

PLEASE NOTE that use of this NCCN Content is governed by the End-User License Agreement, and you MAY NOT distribute this Content or use it with any artificial intelligence model or tool.
Printed by A. S. M. FAZLUL KARIM CHOWDHURY on 4/20/2026 3:06:38 AM. Copyright © 2026 National Comprehensive Cancer Network, Inc. All Rights Reserved.

Surgery

The treatment of meningiomas is dependent upon both patient-related factors (ie, age, PS, medical comorbidities) and treatment-related factors (ie, reasons for symptoms, resectability, goals of surgery). Most patients diagnosed with surgically accessible symptomatic meningioma undergo surgical resection to relieve neurologic symptoms. Complete surgical resection may be curative and is therefore the treatment of choice, if feasible. Both the tumor grade and the extent of resection impact the rate of recurrence. In a cohort of 581 patients, 10-year PFS was 75% following GTR but dropped to 39% for patients receiving STR.[418] Short-term recurrences reported for grade 1, 2, and 3 meningiomas were 1% to 16%, 20% to 41%, and 56% to 63%, respectively.[419-421] The Simpson classification scheme that evaluates meningioma surgery based on extent of resection of the tumor and its dural attachment (grades 1–5 in decreasing degree of completeness) correlates with local recurrence rates.[422] First proposed in 1957, it is still being widely used by surgeons today.

Radiation Therapy

Safe GTR is sometimes not feasible due to tumor location. In this case, SRS followed by adjuvant EBRT has been shown to result in long-term survival comparable to GTR (86% vs. 88%, respectively), compared to only 51% with incomplete resection alone.[423] Of 92 patients with grade 1 tumors, Soyuer and colleagues found that RT following SRS reduced progression compared to incomplete resection alone, but has no effect on OS.[424] Conformal fractionated RT (eg, 3D-CRT, IMRT, VMAT, proton therapy) may be used in patients with grade 1 meningiomas to spare critical structures and uninvolved tissue.[425]

Because high-grade meningiomas have a significant probability of recurrence even following GTR,[426] postoperative high-dose EBRT (>54 Gy) has become the accepted standard of care for these tumors to improve local control.[427] Initial results of the phase II RTOG 0539 trial showed that patients with high-risk meningioma treated with IMRT (60 Gy in 30 fractions) had a 3-year PFS rate of 58.8%.[428] High risk was defined as new or recurrent grade 3, recurrent grade 2, or new grade 2 with SRS. Since new and recurrent tumors were grouped together, this study does not provide clarification on the appropriate role of RT following GTR in patients with newly diagnosed WHO grade 2 disease, and the role of post-GTR RT in these cases remains controversial.

The use of SRS (either single fraction or fractionated) in the management of meningiomas continues to evolve. Advocates have suggested this therapy in lieu of EBRT for small (<35 mm), recurrent, or partially resected tumors. In addition, it has been used as primary therapy in surgically inaccessible tumors (ie, base-of-skull meningiomas) or in patients deemed poor surgical candidates because of advanced age or medical comorbidities. Nonrandomized and retrospective studies show that SRS is associated with excellent tumor control and good survival outcomes, particularly in grade 1 tumors, indicating that this treatment is effective as primary and second-line treatment for meningiomas smaller than 3.5 cm.[429-433] However, optimal dosing has not been determined. SRS may also be considered in carefully selected patients with grade 2 meningiomas, such as those with recurrent disease.[434,435]

Systemic Therapy

For meningiomas that recur despite surgery and/or RT, or are not amenable to treatment with surgery or RT, systemic therapies are often considered. Due to the rarity of these patients requiring systemic therapy, large randomized trials are lacking. Historical estimates of 6-month PFS rates in these patients range from 0% to 29%.[436] Smaller studies support the use of targeted therapy including somatostatin analogues in select cases.[437,438] Studies investigating anti-angiogenic therapies in meningioma have also demonstrated improved results.

Discussion update in progress

Version 3.2025 © 2025 National Comprehensive Cancer Network© (NCCN©), All rights reserved. NCCN Guidelines® and this illustration may not be reproduced in any form without the express written permission of NCCN.

PLEASE NOTE that use of this NCCN Content is governed by the End-User License Agreement, and you MAY NOT distribute this Content or use it with any artificial intelligence model or tool.
Printed by A. S. M. FAZLUL KARIM CHOWDHURY on 4/20/2026 3:06:38 AM. Copyright © 2026 National Comprehensive Cancer Network, Inc. All Rights Reserved.

A prospective, multicenter, nonrandomized, phase II trial evaluating the safety and efficacy of sunitinib in 36 heavily pretreated patients with refractory meningioma showed a 6-month PFS rate of 42%, with a median PFS rate of 5.2 months and a median OS rate of 24.6 months.[439] However, toxicities were considerable, with 60% of patients experiencing grade 3 or higher toxicity.

Retrospective data support the use of bevacizumab for patients with recurrent meningioma, especially for patients with symptoms driven by RT necrosis, with a 6-month PFS rate of 43.8% for recurrent surgery and radiation-refractory grade 2 and 3 meningioma with bevacizumab monotherapy.[440,441] In a phase II trial evaluating the efficacy and safety of bevacizumab combined with everolimus for recurrent meningioma (*N* = 17), stable disease was reported in 88% of patients, with no complete or partial responses reported.[442] The median PFS and OS rates were 22.0 months and 23.8 months, respectively, with 18-month PFS and OS rates of 57% and 69%, respectively. Treatment was discontinued in 22% of patients due to toxicity.

NCCN Recommendations

Initial Treatment

Meningiomas are typically diagnosed by brain MRI. Surgery or octreotide scan may be considered for confirmation. For treatment planning, multidisciplinary panel consultation is encouraged. Patients are stratified by the presence or absence of symptoms and the tumor size. Most asymptomatic patients with small tumors (≤3 cm) are best managed by observation; otherwise, patients should undergo surgical resection whenever possible. Non-surgical candidates should undergo RT.

Regardless of tumor size and symptom status, all patients with surgically resected grade 3 meningioma (even after GTR) should receive adjuvant RT to enhance local control. For patients with grade 2 meningioma, postoperative RT is recommended for incomplete resection, though observation is an option in select patients (eg, those unfit for RT). In the case of complete resection in patients with grade 2 meningioma, postoperative RT may be considered, although this treatment strategy remains controversial. Patients with grade 1 meningioma may be observed following surgery, though postoperative RT may be considered in patients with symptomatic disease. SRS may be used in lieu of conventional RT as adjuvant or primary therapy in asymptomatic cases.

Follow-up and Recurrence

In the absence of data, panelists have varying opinions on the best surveillance scheme and clinicians should follow patients based on individual clinical conditions. Generally, malignant or recurrent meningiomas are followed more closely than grade 1 and 2 tumors. A typical schedule for low-grade tumors is MRI every 3 months in year 1, then every 6 to 12 months for another 5 years. After 5 years, imaging may be done every 1 to 3 years as clinically indicated.

Upon detection of recurrence, the lesion should be resected whenever possible, followed by RT. Non-surgical candidates should receive RT. Systemic therapy is reserved for patients with an unresectable recurrence refractory to RT. Observation is an option if there is no clinical indication for treatment at recurrence.

Brain Metastases

Metastases to the brain are the most common intracranial tumors in adults and may occur up to 10 times more frequently than primary brain tumors. Population-based data reported that about 8% to 10% of patients with cancer are affected by symptomatic metastatic tumors in the brain.[443,444] Based on autopsy studies, brain metastases have been shown to be present in 25% of patients with cancer.[445]

Discussion update in progress

Version 3.2025 © 2025 National Comprehensive Cancer Network© (NCCN©), All rights reserved. NCCN Guidelines® and this illustration may not be reproduced in any form without the express written permission of NCCN.

PLEASE NOTE that use of this NCCN Content is governed by the End-User License Agreement, and you MAY NOT distribute this Content or use it with any artificial intelligence model or tool.
Printed by A. S. M. FAZLUL KARIM CHOWDHURY on 4/20/2026 3:06:38 AM. Copyright © 2026 National Comprehensive Cancer Network, Inc. All Rights Reserved.

As a result of advances in diagnosis and treatment, many patients improve with proper management and do not die of progression of these metastatic lesions. Primary lung cancers are the most common source,[446] and melanoma has the highest rates of brain metastases among patients with metastatic disease.[447,448] Diagnosis of CNS involvement is increasing in patients with breast cancer as therapy for metastatic disease is improving.[449]

Nearly 80% of brain metastases occur in the cerebral hemispheres, an additional 15% occur in the cerebellum, and 5% occur in the brainstem.[450] Parenchymal lesions typically follow a pattern of hematogenous spread to the gray-white junction where the relatively narrow caliber of the blood vessels tends to trap tumor emboli. Patients with brain metastases may present with a single or solitary metastasis or numerous lesions present on MRI. With improved detection and higher resolution of brain MRI, metastases can now be detected at sizes in the 2- to 3-mm range. Patients may be diagnosed with brain metastases on screening MRI without any symptoms. Among patients with symptomatic brain metastases, presenting symptoms may be similar to those of other mass lesions in the brain, such as headache, nausea, seizures, and neurologic impairment.

Treatment Overview

Surgery

Despite advances in surgical techniques, surgery alone for brain metastases results in unacceptable local control rates and adjuvant RT, discussed below, is appropriate to consider.[451,452] The objectives of surgery for brain metastasis include retrieval of tissue for diagnosis, reduction of mass effect, and improvement of edema.[453] Randomized trials reported in the 1990s demonstrated an OS benefit with surgical resection for patients with single brain metastases. In a study of 48 patients, Patchell et al[454] demonstrated that surgery followed by WBRT compared with WBRT alone improved OS (40 vs. 15 weeks in WBRT arm; $P < .01$) and functional dependence (38 vs. 8 weeks; $P < .005$), as well as decreased recurrence (20% vs. 52%; $P < .02$). Similarly, adding surgery to WBRT led to longer survival and functional independence compared to WBRT alone in another randomized study by Vecht and colleagues (n = 63).[455] A third study of 84 patients found no difference in survival between the two strategies; however, patients with extensive systemic disease and lower performance level were included, which likely resulted in poorer outcomes in the surgical arm.[456]

For patients with recurrent brain metastases or radiation necrosis who are poor surgical candidates, laser interstitial thermal ablation may represent a reasonable less invasive treatment option.[457-461] Advantages of laser thermal ablation include rapid discharge from the hospital (within 24–48 hours) and avoidance of stay in the intensive care unit (ICU), rehabilitation facility, or other extended care facility.

Stereotactic Radiosurgery

SRS offers an excellent minimally invasive ablative treatment option for brain metastases. Patients undergoing SRS avoid the risk of surgery-related morbidity, and SRS is generally preferred over surgery for patients with small, asymptomatic lesions that do not require surgery and for patients with lesions that are not surgically accessible.[453] Late side effects of SRS such as symptomatic edema and RT necrosis are relatively uncommon, but may be observed at higher rates when treating larger lesions or at higher doses.[462]

The role of stereotactic SRS alone for limited brain metastases has been established by multiple phase III randomized trials comparing SRS alone to SRS plus WBRT.[463-466] Collectively, these studies demonstrate comparable OS and superior cognitive preservation and quality of life with SRS alone compared to SRS plus WBRT. The role of SRS for patients with multiple metastases has also continued to expand. A prospective trial

Discussion update in progress

Version 3.2025 © 2025 National Comprehensive Cancer Network© (NCCN©), All rights reserved. NCCN Guidelines® and this illustration may not be reproduced in any form without the express written permission of NCCN.

PLEASE NOTE that use of this NCCN Content is governed by the End-User License Agreement, and you MAY NOT distribute this Content or use it with any artificial intelligence model or tool.
Printed by A. S. M. FAZLUL KARIM CHOWDHURY on 4/20/2026 3:06:38 AM. Copyright © 2026 National Comprehensive Cancer Network, Inc. All Rights Reserved.

of 1194 patients found no differences in OS or neurologic mortality with SRS for 2 to 4 versus 5 to 10 brain metastases.[467] A number of analyses have suggested that total volume of brain metastases and the rate of developing new brain metastases may be more important prognostic factors for OS than the number of discrete brain metastases.[468-471] Taken together, patients with multiple lesions but a low total volume of disease, as well as those with relatively indolent rates of developing new CNS lesions, can represent suitable candidates for SRS. Additionally, patients with a favorable histology of the primary tumor (such as breast cancer) or controlled primary tumors may benefit from a strategy of SRS regardless of the number of brain metastases present.[472,473] While brain metastases arising from small cell lung cancer have historically been treated with WBRT, a large international retrospective study and a subsequent meta-analysis of retrospective studies suggested that SRS may be suitable in some cases.[474,475] Brain metastases in patients with radio-resistant primary tumors such as melanoma and renal cell carcinoma can achieve good local control with SRS.[476] Other predictors of longer survival with SRS include younger age, good PS, and primary tumor control.[468,472,473,477] However, there are a number of contemporary series supporting SRS in patients with a poor prognosis, with poor KPS, or who are older.[478-481] A systematic review including 32 retrospective studies showed that SRS is also safe and effective in patients with metastases of the brainstem.[482]

Maximal marginal doses for SRS use should be based on tumor volume and location in the brain, and doses range from 15 to 24 Gy when treating lesions with a single fraction of SRS.[463,467,483,484] For large metastases, local control is generally low, and radionecrosis risk is high with single-fraction SRS.[485] Multi-fraction SRS may be considered for larger tumors, with the most common doses being 27 Gy in 3 fractions and 30 Gy in 5 fractions.[486-488] In the recurrence setting, several patient series have demonstrated local control rates greater than 70% with SRS for patients with good PS and stable disease who have received prior WBRT.[489-492]

Postoperative SRS also represents an important strategy to improve local control after resection of brain metastases. After resection alone, the rates of local recurrence are relatively high, and have been reported in the range of 50% at 1 to 2 years in prospective trials. Postoperative SRS to the surgical cavity is supported by a randomized phase III trial including 132 patients with resected brain metastases (1–3 lesions). This trial demonstrated that postoperative SRS was associated with a higher 12-month local recurrence-free rate compared to no postoperative treatment (72% vs. 43%, respectively; HR, 0.46; 95% CI, 0.24–0.88; $P = .015$).[451] A separate randomized phase III trial comparing postoperative SRS with postoperative WBRT demonstrated similar OS and better cognitive preservation with a strategy of postoperative SRS, despite superior CNS control outcomes with WBRT.[493] Contouring guidelines for postoperative SRS have been published elsewhere.[494]

Whole-Brain Radiation Therapy

Historically, WBRT was the mainstay of treatment for metastatic lesions in the brain. Although the role of WBRT has diminished over the last several decades, WBRT continues to play a role in the modern era, primarily in clinical scenarios where SRS and surgery are not feasible or indicated (eg, diffuse brain metastases, high brain metastasis velocity, leptomeningeal disease). The standard dosing for WBRT is 30 Gy in 10 fractions, as supported by the CC001 study.[495] There is limited evidence to support more protracted WBRT regimens longer than 10 fractions, especially as quality of life may be impacted with longer fractionation schemes beyond 10 fractions. For patients with poor prognoses and symptomatic brain metastases, 20 Gy in 5 fractions may also be used.

The impact of WBRT in addition to SRS has been evaluated in multiple randomized controlled studies.[463-466,496] A 2018 Cochrane meta-analysis of randomized controlled trials found that the addition of WBRT to SRS alone was associated with better CNS disease control outcomes, no differences

Discussion update in progress

Version 3.2025 © 2025 National Comprehensive Cancer Network© (NCCN©), All rights reserved. NCCN Guidelines® and this illustration may not be reproduced in any form without the express written permission of NCCN.

PLEASE NOTE that use of this NCCN Content is governed by the End-User License Agreement, and you MAY NOT distribute this Content or use it with any artificial intelligence model or tool.
Printed by A. S. M. FAZLUL KARIM CHOWDHURY on 4/20/2026 3:06:38 AM. Copyright © 2026 National Comprehensive Cancer Network, Inc. All Rights Reserved.

in OS, and worse neurocognitive outcomes or quality of life in several trials.[497] The randomized phase III EORTC 22952 trial failed to show an OS benefit from WBRT following resection or SRS, compared to observation,[466] even in subgroup analyses including only patients with controlled extracranial disease and a favorable prognostic score.[498] Overall, for patients treated with SRS for brain metastases, the routine addition of WBRT is not recommended due to increased cognitive and quality-of-life toxicity and the lack of an OS benefit. Conversely, results from the randomized phase III RTOG 9508 trial showed that an SRS boost could improve local control in select patients (eg, large lesions or radioresistant histology) already receiving WBRT.[496]

The randomized phase III non-inferiority QUARTZ trial compared WBRT to optimal supportive care in patients with non-small cell lung cancer (NSCLC) who were not candidates for SRS, due to various factors including age, PS, and extent of disease. No differences in OS or quality of life were observed with WBRT versus optimal supportive care, which suggests that this population may derive minimal benefit from WBRT.[499] Moreover, as noted above, a number of studies support SRS for older patients and those with poor prognosis who have historically received WBRT.[478-481,500] The optimal treatment strategy for brain metastases for patients with a poor prognosis is highly individualized and may call for best supportive care, WBRT, SRS, or trials of CNS-active systemic agents depending on the clinical scenarios.

In light of the well-characterized deleterious cognitive effects of WBRT,[464,465,493] a number of trials have evaluated strategies to promote cognitive preservation in patients with brain metastases including investigation of neuroprotective agents, anatomical avoidance strategies, and deferral of WBRT in favor of alternate strategies such as SRS or trials of CNS-active systemic agents. In patients undergoing WBRT for brain metastases, the RTOG 0614 (N = 554) compared concurrent and adjuvant memantine, an N-methyl-D-aspartate receptor antagonist, to placebo. Memantine was well-tolerated in patients receiving WBRT for brain metastases, and the rates of toxicity were similar to patients receiving placebo.[501] There was a trend toward less decline in episodic memory (HVLT-R Delayed Recall) in the memantine arm compared to placebo at 24 weeks (P = .059). The memantine arm had significantly longer time to cognitive decline (HR, 0.78; 95% CI, 0.62–0.99; P = .01), and the probability of cognitive function failure at 24 weeks was 54% in the memantine arm and 65% in the placebo arm. However, for most cognitive endpoints, no significant differences were observed between memantine and placebo, despite numerical trends that generally favored the memantine arm. For patients with a favorable prognosis, consideration of memantine during WBRT and for up to 6 months afterward is recommended.

To evaluate an anatomic-avoidance strategy to promote cognitive preservation, the single-arm phase II RTOG-0933 trial showed that reduced radiation dose to the hippocampal neural stem-cell compartment was associated with a smaller decline in recall (P < .001) compared to a historical control.[502] Based on these results, the phase III NRG-CC001 trial evaluated WBRT with memantine with or without hippocampal avoidance (HA).[495] There were no significant differences in survival outcomes. However, risk of cognitive failure was significantly lower in the HA arm than in the control arm (HR, 0.76; 95% CI, 0.60–0.98; P = .03). For patients with a favorable prognosis (≥4 months), without brain metastases within 5 mm of the hippocampus or leptomeningeal disease, HA-WBRT plus memantine is the preferred approach for delivering WBRT.

In the postoperative setting, phase 3 trials have evaluated the role of WBRT after surgical resection of brain metastases. Patchell conducted a study that randomized 95 patients with single intracranial metastases to surgery with or without adjuvant WBRT.[503] Postoperative RT was

Discussion update in progress

Version 3.2025 © 2025 National Comprehensive Cancer Network© (NCCN©), All rights reserved. NCCN Guidelines® and this illustration may not be reproduced in any form without the express written permission of NCCN.

PLEASE NOTE that use of this NCCN Content is governed by the End-User License Agreement, and you MAY NOT distribute this Content or use it with any artificial intelligence model or tool.
Printed by A. S. M. FAZLUL KARIM CHOWDHURY on 4/20/2026 3:06:38 AM. Copyright © 2026 National Comprehensive Cancer Network, Inc. All Rights Reserved.

associated with a dramatic reduction in tumor recurrence (18% vs. 70%; $P < .001$) and likelihood of neurologic deaths (14% vs. 44%; $P = .003$). OS, a secondary endpoint, showed no difference between the arms. The aforementioned EORTC 22952 trial randomized patients treated with local therapy (surgery or SRS) to observation versus WBRT.[466] Patients randomized to WBRT were found to have superior brain disease control and less death from neurological causes, but inferior quality of life and no differences in OS.[466,504] The NCCTG N107C/CEC-3 randomized phase III trial included 194 patients with resected brain metastases randomized to either postoperative SRS or WBRT.[493] Although there was no significant difference between the treatment arms for OS, cognitive deterioration at 6 months was less frequent in the SRS arm than in the WBRT arm (52% vs. 85%, respectively; $P < .001$), and cognitive deterioration-free survival was also superior for postoperative SRS compared to WBRT (median 3.7 months vs. median 3.0 months; HR, 0.47; 95% CI, 0.35–0.63; $P < .001$). In another phase III trial, 215 patients with 1 to 3 brain metastases from melanoma were randomized to either WBRT or observation following local treatment with surgery or SRS.[505] Although the local failure rate was significantly lower in the WBRT arm (20.0% vs. 33.6%, respectively; $P = .03$), there were no significant differences between the study arms for intracranial failure, OS, and deterioration in performance status. Further, grade 1 to 2 toxicity during the first 2 to 4 months was more frequently reported in the WBRT arm.

Systemic Therapy

Many tumors that metastasize to the brain are not chemosensitive or have already been heavily pretreated with organ-specific effective agents. Poor penetration through the BBB is an additional concern.[447] However, there are increasing numbers of systemic treatment options with demonstrated activity in the brain, and it is now reasonable to treat some of these patients (ie, those with asymptomatic brain metastases) with systemic therapy upfront instead of upfront SRS or WBRT.

Specific recommended regimens for brain metastases are based on effective treatment of the primary tumor (see below). However, there is also an increasing number of “basket” studies that evaluate the efficacy of targeted therapy options for a specific mutation or biomarker, regardless of tumor type. For example, the TRK inhibitors larotrectinib and entrectinib were found to be active in patients with brain metastases from *NTRK* gene fusion-positive solid tumors.[98,99]

As CNS-active systemic agents are changing paradigms for the management of brain metastases, it is important to acknowledge that there is a paucity of prospective data to characterize optimal strategies regarding radiation and systemic therapy combinations or sequencing. When considering a trial of upfront systemic therapy alone for brain metastases, a multidisciplinary discussion between medical and radiation oncology is recommended. Ongoing CNS surveillance with brain MRIs is essential to allow early interventions in cases of progression or inadequate response.

Melanoma

Rapid advancements in melanoma have produced effective systemic options for metastatic disease.[506,507] These include multiple immunotherapy options. Two phase II trials support the use of a combination of the immunotherapy agents ipilimumab and nivolumab for patients with asymptomatic untreated brain metastases from melanoma.[508-510] In one of these trials, which was conducted in Australia, intracranial responses were observed in 46% of patients who received this combination, with a complete response observed in 17% ($n = 79$), and median duration of response was not reached at the time of publication (median 14 months of follow-up).[508] In the second trial, CheckMate 204, the intracranial response was 57.4%, with a complete response of 33% ($N = 101$).[510] The median duration of intracranial response was not reached at time of publication, with 58% of responses lasting more than 2 years.

Discussion update in progress

Version 3.2025 © 2025 National Comprehensive Cancer Network© (NCCN©), All rights reserved. NCCN Guidelines® and this illustration may not be reproduced in any form without the express written permission of NCCN.

PLEASE NOTE that use of this NCCN Content is governed by the End-User License Agreement, and you MAY NOT distribute this Content or use it with any artificial intelligence model or tool.
Printed by A. S. M. FAZLUL KARIM CHOWDHURY on 4/20/2026 3:06:38 AM. Copyright © 2026 National Comprehensive Cancer Network, Inc. All Rights Reserved.

Intracranial 36-month PFS and OS were 54.1% and 71.9%, respectively. Limited disease response was observed in patients with symptomatic disease, though this could potentially have been attributed to corticosteroid use. In both of these trials, grade 3 or 4 treatment-related adverse events occurred in just over half of the patients evaluated.[508,510] Results from the Australian trial also suggest there may be a role for nivolumab monotherapy for patients with asymptomatic untreated brain metastases (*n* = 27), with an intracranial response rate of 20%.[508] For patients with asymptomatic untreated lesions, the response rate for patients who received ipilimumab/nivolumab was better than for nivolumab monotherapy. This trial also evaluated nivolumab monotherapy for a small number of patients for whom local therapy failed (*n* = 16), but the intracranial response rate was low (6%). A nonrandomized phase II study supports ipilimumab monotherapy for patients with small asymptomatic brain metastases from melanoma (*n* = 51), with a CNS disease control rate of 24% (no complete responses).[511] Most of the patients in this study had received previous systemic or local treatment. Nivolumab monotherapy is a reasonable treatment option for a carefully monitored patient whose goal is to avoid radiation.

The anti-PD-1 antibody pembrolizumab is also supported for treatment of both untreated and progressive brain metastases from melanoma, based on early results of a phase II trial showing a CNS ORR of 22% (*n* = 18).[512] Long-term follow-up from this trial showed a CNS response in 26% of the sample (*N* = 23), with four complete responses.[513] In patients who had a CNS response, these responses were ongoing at 24 months in all of the patients. Median PFS and OS were 2 months and 17 months, respectively. Grade 3–4 treatment-related adverse events were minimal. Despite data showing that brain metastases can respond to immune checkpoint inhibitors, the data do not yet provide any robust comparison of these agents from treatment of brain metastases from melanoma.

There is also evidence that brain metastases from melanoma can respond to BRAF/MEK inhibitor combination therapy. The nonrandomized phase II COMBI-MB trial demonstrated clinical benefit and acceptable toxicity for the combination of the BRAF inhibitor dabrafenib with the MEK inhibitor trametinib in 125 patients with brain metastases from *BRAF* V600-mutant melanoma.[514] Among the patients with asymptomatic brain metastases, an intracranial response was observed in 58% of those with untreated metastases and in 56% of those with previously treated metastases. In patients with symptomatic brain metastases, an intracranial response was observed in 59%. Use of the BRAF inhibitor vemurafenib for patients with both newly diagnosed and previously treated brain metastases from *BRAF* V600-mutant melanoma is supported by nonrandomized studies.[515,516] Although there are no published prospective studies on the combination of vemurafenib and cobimetinib for patients with brain metastases from melanoma, there is high-quality evidence that, for distantly metastatic melanoma, combination therapy with vemurafenib and cobimetinib is associated with improved outcomes, compared with vemurafenib monotherapy.[517,518] A case series showed that the BRAF/MEK inhibitor combination encorafenib/binimetinib showed good CNS penetration.[519] Prospective randomized trials are needed to determine which *BRAF*-directed therapy options provide the best results in patients with brain metastases from melanoma.

Lung Cancer

Systemic treatment options for patients with brain metastases from NSCLC include immunotherapy agents and targeted therapies for cancer that is anaplastic lymphoma kinase (ALK) rearrangement-positive and EGFR mutation-positive.

PD-1/PD-L1 Inhibitors

A phase II trial showed a 33% response rate for pembrolizumab in 18 patients with brain metastases from PD-L1-positive NSCLC.[512] Pooled

Discussion update in progress

Version 3.2025 © 2025 National Comprehensive Cancer Network© (NCCN©), All rights reserved. NCCN Guidelines® and this illustration may not be reproduced in any form without the express written permission of NCCN.

PLEASE NOTE that use of this NCCN Content is governed by the End-User License Agreement, and you MAY NOT distribute this Content or use it with any artificial intelligence model or tool.
Printed by A. S. M. FAZLUL KARIM CHOWDHURY on 4/20/2026 3:06:38 AM. Copyright © 2026 National Comprehensive Cancer Network, Inc. All Rights Reserved.

analyses from a phase II trial[520] and two phase III trials[521,522] showed that nivolumab for patients with previously treated brain metastases from NSCLC is well-tolerated, though results from these analyses are currently only reported in abstract form.[523] Nivolumab for patients with brain metastases from NSCLC is also supported by results from a retrospective multi-institutional study.[524]

ALK Inhibitors

At time of diagnosis, brain metastases are present in 24% of patients with ALK rearrangement-positive NSCLC.[525] In general, the panel prefers second- and third-generation ALK inhibitors for patients with brain metastases from ALK rearrangement-positive NSCLC, based on better activity profiles. Crizotinib inhibits *ALK* rearrangements, *ROS1* rearrangements, and some MET TKIs. Crizotinib does demonstrate some CNS activity,[526] but the response and control rates appear to be clearly lower than newer generation ALK inhibitors.

In a randomized phase III trial, the ALK inhibitor alectinib was compared to crizotinib in 303 patients with advanced ALK rearrangement-positive NSCLC and no previous systemic therapy treatment.[527] Brain metastases were reported in 40.3% of the sample. Among these patients, a CNS response was observed in 81% of patients in the alectinib arm (8 complete responses) and 50% of patients in the crizotinib arm (1 complete response). The median duration of intracranial response in these 122 patients was 17.3 months in the alectinib arm and 5.5 months in the crizotinib arm. Pooled analyses from two phase II studies[528,529] including patients with ALK rearrangement-positive NSCLC that progressed on crizotinib showed that alectinib was associated with a good objective response rate and excellent disease control in patients with brain metastases.[530] Patients who did not receive previous brain RT seemed to have a better response to alectinib than patients with previous RT, but the sample size for these analyses was small.

In a similar randomized phase III trial, brigatinib, another ALK inhibitor, was compared to crizotinib in 275 patients with locally advanced or metastatic ALK rearrangement-positive NSCLC and no previous systemic therapy treatment.[531] Among patients with brain metastases (n = 90), an intracranial response was more likely in the brigatinib arm than in the crizotinib arm (67% vs. 17%, respectively; OR, 13.00; 95% CI, 4.38–38.61). Complete intracranial responses were observed in 16 patients who received brigatinib and 2 patients who received crizotinib. Twelve-month survival without intracranial disease progression was greater in the brigatinib arm than in the crizotinib arm (67% vs. 21%, respectively; HR, 0.27; 95% CI, 0.13–0.54). Brigatinib treatment in patients with brain metastases from ALK rearrangement-positive NSCLC and disease progression on crizotinib is supported by the phase II ALTA trial, which showed an intracranial response rate of 67%.[532] Median intracranial PFS was 12.8 months in these patients. A dosing schedule of 180 mg once daily with a 7-day lead-in at 90 mg was used to reduce the chance of early-onset moderate to severe pulmonary adverse events.

The ALK inhibitor ceritinib was evaluated in a phase I trial including 246 patients with ALK rearrangement-positive NSCLC.[533] About half the sample had brain metastases (n = 124). Retrospective analyses were used to evaluate intracranial response in these patients. Disease control rate was 78.9% in patients not previously treated with an ALK inhibitor and 65.3% in patients with previous ALK inhibitor treatment. However, most of these patients had received RT to the brain. Therefore, based on this study, it is difficult to draw conclusions regarding the contribution of RT versus ceritinib to disease control rates in these patients. In the nonrandomized phase II ASCEND-7 trial, out of 97 patients with measurable brain metastasis from ALK-positive NSCLC, the intracranial ORR for ceritinib was 39.2%.[534] Intracranial ORR was higher in patients who were ALK-naïve, compared to those previously treated with an ALK inhibitor (47.5% vs 33.3%, respectively).

Discussion update in progress

Version 3.2025 © 2025 National Comprehensive Cancer Network© (NCCN©), All rights reserved. NCCN Guidelines® and this illustration may not be reproduced in any form without the express written permission of NCCN.

PLEASE NOTE that use of this NCCN Content is governed by the End-User License Agreement, and you MAY NOT distribute this Content or use it with any artificial intelligence model or tool.
Printed by A. S. M. FAZLUL KARIM CHOWDHURY on 4/20/2026 3:06:38 AM. Copyright © 2026 National Comprehensive Cancer Network, Inc. All Rights Reserved.

A phase II trial in which the third-generation ALK/ROS1 TKI lorlatinib was evaluated in patients with ALK-positive NSCLC previously treated with an ALK TKI showed that this agent may be active against CNS metastases.[535] Post hoc efficacy analyses from the randomized phase III CROWN trial in which patients with advanced or metastatic ALK-positive NSCLC were randomized to receive lorlatinib or crizotinib showed that, in 78 patients with brain metastases at baseline, complete CNS response was observed in 61% of patients who received lorlatinib, compared to 15% in those who received crizotinib.[536] Among the complete responses in the lorlatinib arm, median duration of response was not reached.

Epidermal Growth Factor Receptor Tyrosine Kinase Inhibitors

Some treatment options for patients with advanced NSCLC that harbor EGFR-TKI–sensitizing mutations have been evaluated and are now available.

Older-generation EGFR-TKIs have demonstrated some CNS activity. Gefitinib for treatment of patients with CNS metastases from NSCLC is supported by phase II studies.[537,538] Pulsatile erlotinib is supported by a phase I study including patients with untreated CNS metastases from EGFR-sensitizing mutation-positive NSCLC.[539] Afatinib treatment was evaluated in patients with CNS metastasis from NSCLC and with disease progression following platinum-based chemotherapy and either erlotinib or gefitinib (n = 100).[540] Cerebral response was observed in 35% of these patients, and disease control was observed in 66%.

In a randomized phase III FLAURA trial, the EGFR-TKI osimertinib was compared to a different EGFR-TKI (gefitinib or erlotinib) in 556 patients with previously untreated EGFR-sensitizing mutation-positive NSCLC.[541] CNS metastases were reported in 20.9% of the sample. Median PFS was greater for these patients in the osimertinib arm than in the standard EGFR-TKI arm (15.2 months vs. 9.6 months, respectively; HR, 0.47; 95% CI, 0.30–0.74; $P < .001$). Preplanned exploratory analyses including 41 patients with at least one measurable CNS lesion showed a CNS ORR of 91% in the osimertinib arm, compared to 68% in the EGFR-TKI arm, but this difference did not reach statistical significance (OR, 4.6; 95% CI, 0.9–34.9; $P = .066$).[542] Twenty-three percent of patients in the osimertinib arm had a complete CNS response, compared to none of the patients in the EGFR-TKI arm. CNS disease control rate did not significantly differ between the study arms in patients with at least one measurable CNS lesion.

Osimertinib has also been evaluated in the randomized phase III AURA3 trial, in which it was compared to pemetrexed with platinum-based therapy in 419 patients with *T790M* mutation-positive advanced NSCLC that progressed after first-line EGFR-TKI therapy.[543] CNS metastases were reported in 34.4% of the sample. Median PFS was greater for these patients in the osimertinib arm than in the pemetrexed/platinum arm (8.5 months vs. 4.2 months, respectively; HR, 0.32; 95% CI, 0.21–0.49). Preplanned analyses including 46 patients with at least one measurable CNS lesion showed a significantly greater CNS ORR for the osimertinib arm than in the pemetrexed/platinum arm (70% vs. 31%, respectively; OR, 5.13; 95% CI, 1.44–20.64; $P = .015$).[544] CNS disease control rate was 93% in the osimertinib arm, compared to 63% in the pemetrexed/platinum arm. Median CNS duration of response was also longer in the patients who received osimertinib.

Results from the nonrandomized phase II T790M cohort of the Japanese OCEAN study showed an ORR of 66.7% among 39 patients previously untreated with RT.[545] Pooled analyses from two phase II studies[546,547] including patients with *T790M*-positive advanced NSCLC that progressed following treatment with EGFR-TKI therapy showed a CNS ORR of 54% and disease control rate of 92%.[548] Median CNS duration of response and median PFS were not reached.

MET Inhibitors

Discussion update in progress

Version 3.2025 © 2025 National Comprehensive Cancer Network© (NCCN©), All rights reserved. NCCN Guidelines® and this illustration may not be reproduced in any form without the express written permission of NCCN.

PLEASE NOTE that use of this NCCN Content is governed by the End-User License Agreement, and you MAY NOT distribute this Content or use it with any artificial intelligence model or tool.
Printed by A. S. M. FAZLUL KARIM CHOWDHURY on 4/20/2026 3:06:38 AM. Copyright © 2026 National Comprehensive Cancer Network, Inc. All Rights Reserved.

MET exon 14 skipping mutations are present in 3% to 4% of patients with NSCLC.[549-551] A phase 2 study of the MET inhibitor capmatinib showed a 53.8% intracranial response rate in 13 patients with NSCLC with a MET exon14 skipping mutation and brain metastases.[552]

RET Inhibitors

RET fusions are found in 1% to 2% of patients with NSCLC.[553,554] In the phase I/II LIBRETTO-001 trial, treatment with the RET inhibitor selpercatinib was evaluated in 80 patients with brain metastases.[555] Intracranial PFS was 13.7 months. An intracranial ORR of 82% in 22 patients with measurable CNS-involved disease at baseline was observed, with complete responses in 23%. Among 38 intracranial responders, median duration of intracranial response was not reached.

Other Systemic Therapy Options

A phase I/II study of topotecan plus WBRT has shown a 72% response rate in 75 patients with brain metastases.[556] Unfortunately, a follow-up phase III trial including only patients with brain metastases from lung cancer was closed early due to slow accrual.[557]

Breast Cancer

Capecitabine combined with a number of agents has been evaluated in patients with brain metastases from HER2-positive breast cancer. Capecitabine combined with the TKI lapatinib for patients with brain metastases from HER2-positive breast cancer is supported by a systematic review and pooled analysis showing an ORR of 29.2%, a disease control rate of 65.1%, and a 2-year OS rate of 33.4%.[558]

In the HER2CLIMB phase III trial, patients with HER2-positive metastatic breast cancer who were previously treated with HER2-directed therapy (N = 612) were randomized to receive trastuzumab and capecitabine combined with either the TKI tucatinib or a placebo.[559] Among the patients with brain metastases at baseline (47.5% of the sample), both PFS (HR, 0.46; 95% CI, 0.31–0.67) and OS (HR, 0.58; 95% CI, 0.40–0.85) were superior in the tucatinib arm. The estimated 1-year PFS was 24.9% for these patients who received tucatinib, compared to 0% in patients who received the placebo, with duration of PFS being 7.6 months and 5.4 months, respectively. Exploratory analyses of 291 patients with brain metastases showed that both CNS PFS (HR, 0.36; 95% CI, 0.22–0.57; P <.00001) and OS (HR, 0.49; 95% CI, 0.30–0.80; P = .004) were significantly greater in patients who received tucatinib, compared to patients who received the placebo.[560] Based on study results, the FDA approved tucatinib in combination with trastuzumab and capecitabine in 2020 for patients with advanced unresectable or metastatic HER2-positive breast cancer (including patients with brain metastases) who were previously treated with HER2-directed therapy.

A phase II study supports use of capecitabine combined with the TKI neratinib in patients with CNS metastases from HER2-positive breast cancer.[561] CNS metastases in most of the patients were previously treated with surgery or RT. Results from this study helped inform development of the phase III NALA trial, in which patients with HER2-positive metastatic breast cancer who received at least 2 lines of HER2-directed therapy were randomized to receive capecitabine and neratinib or capecitabine and lapatinib (N = 621).[562] Patients in the capecitabine/neratinib arm had superior PFS compared to those in the capecitabine/lapatinib arm (HR, 0.76; 95% CI, 0.63–0.93; P = .006), though there was no OS advantage. Further, patients who received capecitabine/neratinib were less likely to have required intervention for symptomatic CNS metastases than patients in the capecitabine/lapatinib arm (22.8% vs. 29.2%, respectively; P = .043). Subgroup analyses of 101 patients who had known CNS metastases at baseline showed that mean PFS through 24 months was greater in the capecitabine/neratinib arm (7.8 months) than in the capecitabine/lapatinib arm (5.5 months), but this result did not reach statistical significance (HR, 0.66; 95% CI, 0.41–1,05; P = .074).[563] Among

Discussion update in progress

Version 3.2025 © 2025 National Comprehensive Cancer Network© (NCCN©), All rights reserved. NCCN Guidelines® and this illustration may not be reproduced in any form without the express written permission of NCCN.

PLEASE NOTE that use of this NCCN Content is governed by the End-User License Agreement, and you MAY NOT distribute this Content or use it with any artificial intelligence model or tool.
Printed by A. S. M. FAZLUL KARIM CHOWDHURY on 4/20/2026 3:06:38 AM. Copyright © 2026 National Comprehensive Cancer Network, Inc. All Rights Reserved.

patients with at least one target CNS lesion (n = 32), intracranial ORR was 26.3% in the capecitabine/neratinib arm and 15.4% in the capecitabine/lapatinib arm. In a randomized phase II trial evaluating paclitaxel combined with neratinib, compared to trastuzumab combined with paclitaxel, in patients with untreated metastatic HER2-positive breast cancer, incidence of symptomatic or progressive CNS events were significantly lower in the neratinib arm (8.3% vs. 17.3%, respectively; HR, 0.48; 95% CI, 0.29–0.79; *P* = .002).[564] Though patients with asymptomatic CNS metastases at baseline were eligible to participate in this trial, they comprised only 3.8% of the study sample, limiting the conclusions that can be drawn about the efficacy of this regimen for these patients.

Trastuzumab, a large monoclonal antibody, is used for treatment of HER2-positive breast cancer, but it does not penetrate the BBB. Therefore, there are concerns about risk of breast cancer metastasizing to the brain for patients treated with normal-dose trastuzumab.[565] Results of the primary efficacy analysis from the phase 2 PATRICIA study including 39 patients with metastatic HER2-positive breast cancer and CNS progression (previously treated with RT) showed an intracranial ORR of 11% with median duration of response of 4.6 months for high-dose trastuzumab with pertuzumab.[566]

Two HER2-targeting antibody-drug conjugates have been evaluated for treatment of brain metastases from HER2-positive breast cancer. A study describing exploratory analyses from the nonrandomized phase IIIb KAMILLA study showed that the antibody-drug conjugate ado-trastuzumab emtansine, which contains the cytotoxic agent DM1, was associated with a 21.4% ORR (mostly partial responses) in 126 patients with measurable CNS metastases.[567] CNS tumors significantly diminished in size in 50% (95% CI, 18.7%–81.3%). Subgroup analysis from the ongoing open-label phase II DESTINY-Breast01 trial showed that the antibody-drug conjugate fam-trastuzumab deruxtecan-nxki (deruxtecan being a DNA topoisomerase 1 inhibitor) was associated with a 58% ORR in 24 patients with asymptomatic brain metastases from HER2-positive breast cancer who were previously treated with ado-trastuzumab emtansine.[568] Partial intracranial responses were observed in 41%. In the multicenter open-label randomized phase III DESTINY-Breast03 trial, in which fam-trastuzumab deruxtecan-nxki is being compared to ado-trastuzumab emtansine in patients with metastatic HER2-positive breast cancer previously treated with trastuzumab and a taxane, results presented at an annual meeting showed that median PFS was significantly greater in the fam-trastuzumab deruxtecan-nxki arm, compared to the ado-trastuzumab emtansine arm (15.0 months vs. 5.7 months, respectively; HR, 0.38; 95% CI, 0.23–0.64).[569]

Capecitabine monotherapy treatment in patients with brain metastases from breast cancer is supported by a phase I trial[570] and case reports.[571-574] A study of high-dose methotrexate in patients mostly with breast cancer achieved disease control in 56% of patients.[575] The use of cisplatin and etoposide monotherapies and combination therapy in patients with brain metastases from breast cancer is supported by nonrandomized studies published in the 1990s.[576-578]

Discussion update in progress

NCCN Recommendations

Workup

Brain MRI with and without contrast is recommended for diagnosis, visualization, and monitoring in patients with brain metastases. Patients who present with a single mass or multiple lesions on MRI or CT imaging suggestive of metastatic cancer to the brain, and who do not have a known primary, require a careful systemic workup with chest x-ray or CT with contrast, abdominal or pelvic CT with contrast, or other tests as indicated. Whole-body PET/CT may be considered. If no other readily accessible tumor is available for biopsy, a stereotactic or open biopsy resection is indicated to establish a diagnosis.

Version 3.2025 © 2025 National Comprehensive Cancer Network© (NCCN©), All rights reserved. NCCN Guidelines® and this illustration may not be reproduced in any form without the express written permission of NCCN.

PLEASE NOTE that use of this NCCN Content is governed by the End-User License Agreement, and you MAY NOT distribute this Content or use it with any artificial intelligence model or tool.
Printed by A. S. M. FAZLUL KARIM CHOWDHURY on 4/20/2026 3:06:38 AM. Copyright © 2026 National Comprehensive Cancer Network, Inc. All Rights Reserved.

Treatment for Limited Metastatic Lesions

The panel defines "limited" brain metastases as patients for whom SRS represents an effective alternative to WBRT, but with more cognitive protection.[467] Because brain metastases are often managed by physicians from multiple disciplines, the NCCN Panel encourages multidisciplinary consultation prior to treatment for optimal planning.

Surgical resection may be considered in select cases (eg, for management of mass effect or other symptoms; for tumors >3 cm that are surgically accessible; if there is no other readily accessible tumor to be biopsied). For patients with newly diagnosed or stable systemic disease, treatment options include SRS (preferred) and WBRT (HA-WBRT with memantine, if eligible). Patients eligible for HA-WBRT with memantine include those with a life expectancy of at least 4 months and brain metastases not within 5 mm of the hippocampi. When patients are managed with SRS, NCCN does not recommend the routine addition of WBRT, as this approach has been consistently associated with cognitive deterioration and no difference in survival,[464] but the addition of SRS boost in very select patients (ie, large lesions or radioresistant histology) already receiving WBRT may be considered for the purpose of local disease control.[496] The management of patients with disseminated systemic disease or poor prognosis should be individualized and may include strategies of best supportive care, WBRT (HA-WBRT with memantine, if eligible), SRS, or a trial of CNS-active systemic agents; multidisciplinary evaluation is encouraged.

In patients with systemic cancers with options for CNS-active systemic therapies (eg, *ALK* or *EGFR* mutations in NSCLC; *BRAF* mutations in metastatic melanoma, HER2-positive breast cancer), upfront systemic therapy alone may be considered in carefully selected, asymptomatic patients. When considering a trial of upfront systemic therapy alone for brain metastases, NCCN recommends a multidisciplinary discussion between medical and radiation oncologists and ongoing CNS surveillance with brain MRIs to allow for early interventions in cases of progression or inadequate response.

Patients should be followed with brain MRI every 2 to 3 months for 1 to 2 years and then every 4 to 6 months indefinitely. Closer follow-up every 2 months may be particularly helpful for patients treated with SRS or systemic therapy alone.[465] Following SRS, imaging changes may reflect treatment changes or tumor progression. Advanced MRI, multidisciplinary review, or observation with early repeat imaging may be considered. Tumor sampling may be considered if recurrence versus treatment effect remains unclear. Upon detection of recurrent disease, prior therapy clearly influences the choice of further therapies. Patients with recurrent CNS disease should be assessed for local versus systemic disease, because the optimal therapy may differ. For local recurrences, patients who were previously treated with surgery only can receive the following options: 1) surgery with consideration of SRS or RT to the surgical bed; 2) single-dose or fractionated SRS; 3) WBRT (HA-WBRT with memantine, if eligible); or 4) systemic therapy. However, patients who previously received WBRT generally should not undergo WBRT at recurrence due to concern regarding neurotoxicity. If the patient had previous SRS with a durable response for greater than 6 months, reconsider SRS if imaging or biopsy supports active tumor and not necrosis. Repeat SRS to a prior location is a category 2B recommendation.

If isolated CNS disease progression occurs in the setting of limited systemic treatment options and poor PS, management of brain metastases should be individualized and may include best supportive care, WBRT (HA-WBRT with memantine, if eligible), SRS, and CNS-active systemic agents. WBRT re-irradiation is generally discouraged due to toxicity to cognition and quality of life and should be administered only in highly selected circumstances. Laser thermal ablation is an option for

Discussion update in progress

Version 3.2025 © 2025 National Comprehensive Cancer Network© (NCCN©), All rights reserved. NCCN Guidelines® and this illustration may not be reproduced in any form without the express written permission of NCCN.

PLEASE NOTE that use of this NCCN Content is governed by the End-User License Agreement, and you MAY NOT distribute this Content or use it with any artificial intelligence model or tool.
Printed by A. S. M. FAZLUL KARIM CHOWDHURY on 4/20/2026 3:06:38 AM. Copyright © 2026 National Comprehensive Cancer Network, Inc. All Rights Reserved.

patients with relapsed brain metastases or refractory radiation necrosis who are not considered surgical candidates. This procedure should only be carried out at an experienced academic center.

Treatment for Extensive Metastatic Lesions

Patients diagnosed with extensive metastatic lesions should generally be treated with WBRT (HA-WBRT with memantine, if eligible) or SRS as primary therapy. For WBRT dosing, the standard dosing is 30 Gy in 10 fractions, with limited evidence to support prolonged fractionation schemes beyond 10 fractions. For patients with poor neurologic performance, a more rapid course of RT can be considered (20 Gy, delivered in 5 fractions). SRS may be considered in select patients, particularly those with good PS and low overall tumor volume. Some patients may be eligible for upfront systemic therapy treatment. Palliative neurosurgery may also be considered if a lesion is causing a life-threatening mass effect, hemorrhage, or hydrocephalus.

After WBRT or SRS, patients should have a repeat contrast-enhanced brain MRI scan every 2 to 3 months for 1 to 2 years, then every 4 to 6 months indefinitely. Some patients will need brain MRIs every 2 to 3 months indefinitely based on the frequency of detecting new metastases. Treatment for recurrences are individualized and may include best supportive care, surgery, WBRT (HA-WBRT with memantine, if eligible), SRS, or a trial of CNS-active systemic therapy; multidisciplinary review is recommended. Repeat WBRT is generally discouraged due to toxicity to cognition and quality of life and should only be administered in highly selected circumstances.

Leptomeningeal Metastases

Leptomeningeal metastasis or neoplastic meningitis refers to malignant cells' multifocal seeding of the leptomeninges. It is known as leptomeningeal carcinomatosis or carcinomatous meningitis when these cells originate from a solid tumor. When it is related to systemic lymphoma, it is called lymphomatous meningitis, and when associated with leukemia, it is termed leukemic meningitis. Leptomeningeal metastasis occurs in approximately 5% of patients with cancer.[579] This disorder is being diagnosed with increasing frequency as patients with cancer live longer with improved systemic therapeutics and as neuroimaging studies improve. Most cases arise from breast cancers, lung cancers, and melanoma, which have the highest rate of leptomeningeal spread.[580,581]

Tumor cells gain access to the leptomeninges by hematogenous dissemination, lymphatic spread, or direct extension. Once these cells reach the CSF, they are disseminated throughout the neuraxis by the constant flow of CSF. Infiltration of the leptomeninges by any malignancy is a serious complication that results in substantial morbidity and mortality. Common symptoms depend on location of involvement. When the posterior fossa is involved, patients can present with new cranial nerve palsies. Spinal cord-related symptoms can include pain (neck, back or radicular), focal motor or sensory dysfunction, and bowel/bladder dysfunction. Common signs of involvement of the ventricular system include headache, nausea/vomiting, and confusion. The median survival of patients diagnosed with this disorder is typically 2 to 4 months with death resulting from progressive neurologic dysfunction, but survival may be extended by early detection and intervention.[580,581] Of note, the underlying tumor type can have some impact on OS.[581,582]

Treatment Overview

Treatment goals in patients with leptomeningeal metastases are to improve or stabilize the patient's neurologic symptoms and to prolong survival.[583] Unfortunately, there is a lack of standard treatments due to meager evidence in literature. Because treatment is largely palliative,

Discussion update in progress

Version 3.2025 © 2025 National Comprehensive Cancer Network© (NCCN©), All rights reserved. NCCN Guidelines® and this illustration may not be reproduced in any form without the express written permission of NCCN.

PLEASE NOTE that use of this NCCN Content is governed by the End-User License Agreement, and you MAY NOT distribute this Content or use it with any artificial intelligence model or tool.
Printed by A. S. M. FAZLUL KARIM CHOWDHURY on 4/20/2026 3:06:38 AM. Copyright © 2026 National Comprehensive Cancer Network, Inc. All Rights Reserved.

aggressive chemotherapy should only be given to patients most likely to benefit (see *Patient Stratification*).

Radiation Therapy

RT is mainly given for symptom alleviation, CSF flow correction, or debulking to facilitate systemic therapy.[581,584-586] SRS may be an option for patients with focal leptomeningeal disease, particularly in the setting of focal disease causing CSF flow disruption.[587]

Surgery

The role of neurosurgery for leptomeningeal metastases is mainly limited to intraventricular catheter and subcutaneous reservoir placement for drug administration.[588] This is preferred over lumbar punctures because of improved drug delivery, safety, superior pharmacokinetics, lower inter-patient variability, and patient comfort.[589]

Systemic Therapy

Some systemically administered agents can reach the leptomeninges, while others do not traverse the blood CSF barrier. Intrathecal chemotherapy can address non-bulky leptomeningeal disease, although it is essential to note that it is an effective treatment for brain parenchymal disease. Some drugs have good CNS penetration, particularly organ-specific targeted therapies or systemically administered chemotherapies given in high doses.[583] Intrathecal therapy can involve either administration via a lumbar puncture or intraventricular injections via an Ommaya reservoir. However, both intra-CSF therapy and high-dose systemic therapy are associated with significant toxicity or complications and are therefore generally restricted to patients with good performance status.

Agents used for intra-CSF therapy are often histology-specific and, because they are directly injected into the CSF, have good drug bioavailability. The panel included intrathecal options deemed appropriate based on moderate benefit: methotrexate[590-592]; cytarabine[591,593,594]; thiotepa[592,595]; rituximab for lymphoma[596]; topotecan[597,598]; etoposide[599]; and trastuzumab for HER2-positive breast cancer.[600] Interferon alfa was removed as an intra-CSF chemotherapy option in 2020 due to discontinuation.

Breast cancers[575,601] and lymphomas[593,602] are also particularly responsive to high-dose methotrexate. In addition, osimertinib and weekly pulse erlotinib have been used for metastatic NSCLC with EGFR-sensitizing mutations [exon 19 deletion or exon 21 L858R mutation only for erlotinib (category 2B)].[603-607]

NCCN Recommendations

Patient Evaluation

Patients present with signs and symptoms ranging from injury to nerves that traverse the subarachnoid space, direct tumor invasion of the brain or spinal cord, alteration of the local blood supply, obstruction of normal CSF flow pathways leading to increased intracranial pressure, or interference with normal brain function. Patients should have a physical examination with a careful neurologic evaluation. MRI of the brain and spine should also be performed for accurate staging, particularly if the patient is a candidate for active treatment. A definitive diagnosis is most commonly made by CSF analysis via lumbar puncture if it is safe for the patient. The CSF protein is typically increased, and there may be a pleocytosis or decreased glucose levels and ultimately positive CSF cytology for tumor cells. Assessment of circulating tumor cells increases the sensitivity of tumor cell detection in CSF.[608-610] This assessment is now CLIA-approved in some states and should be done when it is available. CSF cytology testing has approximately 50% sensitivity with the first lumbar puncture, and up to 90% sensitivity after repeated CSF analyses in affected patients.[585,586] Clinicians should be aware that lumbar punctures may be contraindicated in patients with anticoagulation, thrombocytopenia, or bulky intracranial disease. In these cases, suspicious CSF biochemical

Discussion update in progress

Version 3.2025 © 2025 National Comprehensive Cancer Network© (NCCN©), All rights reserved. NCCN Guidelines® and this illustration may not be reproduced in any form without the express written permission of NCCN.

PLEASE NOTE that use of this NCCN Content is governed by the End-User License Agreement, and you MAY NOT distribute this Content or use it with any artificial intelligence model or tool.
Printed by A. S. M. FAZLUL KARIM CHOWDHURY on 4/20/2026 3:06:38 AM. Copyright © 2026 National Comprehensive Cancer Network, Inc. All Rights Reserved.

results combined with suggestive clinical and/or radiologic features should be considered. Although a positive CSF cytology in patients with solid tumors is virtually always diagnostic, reactive lymphocytes from infections (for example, herpes zoster infection) can often be mistaken for malignant lymphocytes.

Patient Stratification

Once the diagnosis has been established, the patient's overall status should be carefully assessed to determine how aggressively the carcinomatous or lymphomatous meningitis should be treated. Unfortunately, this disease is most common in patients with advanced, treatment-refractory systemic malignancies for whom treatment options are limited. In general, fixed neurologic deficits (such as cranial nerve palsies or paraplegia) do not resolve with therapy, although encephalopathies may improve dramatically. As a result, patients should be stratified into "poor-risk" and "good-risk" groups. The poor-risk group includes patients with KPS below 60; multiple, serious, major neurologic deficits; extensive systemic disease with few treatment options; bulky CNS disease; and neoplastic meningitis related to encephalopathy. The good-risk group includes patients with KPS greater than or equal to 60, no major neurologic deficits, minimal systemic disease, and reasonable systemic treatment options. Many patients fall between these two groups, and clinical judgment will dictate how aggressive their treatment should be.

Treatment

Patients in the poor-risk group are usually offered palliative/supportive care measures, though patients considered good-risk may also receive palliative/best supportive care if they do not desire further treatment. Fractionated EBRT to neurologically symptomatic sites (eg, to the whole brain for increased intracranial pressure or to the lumbosacral spine for a developing cauda equina syndrome) can be considered to temporarily improve function.

Chemotherapy (systemic or intrathecal) is recommended for patients considered good-risk. These patients may also receive SRS, WBRT, or involved-field RT to neurologically symptomatic or painful sites and to areas of bulky disease identified on neuroimaging studies. Craniospinal RT may also be considered, but only in highly select patients given the substantial toxicity and resultant bone marrow suppression that can limit future cancer-directed therapies.

CSF flow abnormalities are common in patients with neoplastic meningitis, and these often lead to increased intracranial pressure. Administering chemotherapy into the ventricle of a patient with a ventricular outlet obstruction increases the patient's risk for leukoencephalopathy. In addition, the agent administered may not reach the lumbar subarachnoid space where the original CSF cytology was positive if there are flow obstructions. Therefore, a CSF flow scan should be carried out if there are concerns about a CSF flow blockage (eg, a patient with hydrocephalus) before administration of intrathecal systemic therapy. If significant flow abnormalities are seen, fractionated EBRT can be administered to the sites of obstruction before repeating a CSF flow scan. High-dose systemically administered methotrexate remains an option for patients with breast cancer or lymphoma, as normal CSF flow is not required to reach cytotoxic concentrations.

The patient should be reassessed clinically and with a repeat CSF cytology. Cytology should be sampled from the lumbar spine, if possible, or via an intraventricular port. Neuraxis imaging with MRI is recommended if CSF cytology was initially negative or if there are new or worsening symptoms. Spine/brain MRI imaging can be considered for sites that were previously positive on a radiograph.

If negative cytology is achieved after induction, continue the induction chemotherapy for another month before switching to maintenance intrathecal chemotherapy. The CSF cytology status should be followed

Discussion update in progress

Version 3.2025 © 2025 National Comprehensive Cancer Network© (NCCN©), All rights reserved. NCCN Guidelines® and this illustration may not be reproduced in any form without the express written permission of NCCN.

PLEASE NOTE that use of this NCCN Content is governed by the End-User License Agreement, and you MAY NOT distribute this Content or use it with any artificial intelligence model or tool.
Printed by A. S. M. FAZLUL KARIM CHOWDHURY on 4/20/2026 3:06:38 AM. Copyright © 2026 National Comprehensive Cancer Network, Inc. All Rights Reserved.

every 4 to 8 weeks. If the patient is clinically stable or improving after induction and there is no clinical or radiologic evidence of progressive leptomeningeal disease, the patient should receive another 4 weeks of "induction" intrathecal chemotherapy or should consider switching intrathecal drugs for 4 weeks. This regimen should be followed by maintenance therapy and monthly cytology if the cytology has converted to negative or is improving (still positive) while the patient is clinically stable.

Progressive Disease

If the patient's clinical status is deteriorating from progressive leptomeningeal disease or if the cytology is persistently positive, the clinician has several options: 1) RT to symptomatic sites; 2) systemic chemotherapy; or 3) palliative or best supportive care.

Metastatic Spinal Tumors

Bone metastases are a growing problem among patients with cancer due to increasing life expectancy, with the spine being the most frequently affected site. Spinal metastases primarily arise from breast, lung, prostate, and renal cancers.[611,612] Extradural lesions account for about 95% of spinal tumors, mostly in the thoracic region.

Some patients are found to have vertebral involvement as an asymptomatic, incidental finding. However, for most affected patients, pain is the primary presenting symptom preceding neurologic dysfunction. Three types of pain have been classically defined. Local pain due to tumor growth is often described as a constant, deep aching that improves with steroid medications. Mechanical back pain varies with movement and position and is attributed to structural spinal instability. While seldom responsive to steroids, mechanical pain can be alleviated by surgical stabilization. Radicular pain is a sharp or stabbing sensation that occurs when nerve roots are compressed by the tumor. Patients may experience any one or a combination of these types of pain.

Spinal cord compression is the most debilitating complication of spine metastases. It affects 5% to 10% of all patients with cancer, with more than 20,000 cases diagnosed each year in the United States.[613] The majority of patients initially complain of progressive radicular pain.[614] This is followed by neurologic symptoms such as motor weakness and sensory loss, and may even include autonomic bladder dysfunction. If left untreated, neurologic deficits rapidly progress to paralysis. Unfortunately, a study of 319 patients with cord compression revealed significant delay in the report of initial pain (3 months) as well as diagnosis (2 months) that can lead to irreversible spinal cord damage.[615] Therefore, it is paramount that the clinician watches for early suspicious signs and establishes prompt diagnosis by spine MRI. Once diagnosed, spinal cord compression is considered a medical emergency; intervention should be implemented immediately to prevent further neurologic decline.

Treatment Overview

Dissemination to the spinal column is largely incurable. Therefore, the goals of treatment are palliation and improvement of quality of life through preservation of neurologic function, pain relief, and stabilization of mechanical structure. Exceptions include patients with oligometastases for which surgery or other ablative treatments such as stereotactic radiation may achieve prolonged disease control and, in rare cases, possible cure.[616] Patients with spine metastases require care from a multidisciplinary team, including neurosurgeons; orthopedic surgeons; radiologists and interventional radiologists; and specialists in pain management; care of the bowel, bladder, and back; and ambulatory support.

Discussion update in progress

Version 3.2025 © 2025 National Comprehensive Cancer Network© (NCCN©), All rights reserved. NCCN Guidelines® and this illustration may not be reproduced in any form without the express written permission of NCCN.

PLEASE NOTE that use of this NCCN Content is governed by the End-User License Agreement, and you MAY NOT distribute this Content or use it with any artificial intelligence model or tool.
Printed by A. S. M. FAZLUL KARIM CHOWDHURY on 4/20/2026 3:06:38 AM. Copyright © 2026 National Comprehensive Cancer Network, Inc. All Rights Reserved.

The type and aggressiveness of the primary tumor often dictates the choice of treatment, as different cancers have varying sensitivities to systemic therapy and RT. In addition, patient characteristics including PS and comorbidities will determine whether they can tolerate surgery and, if so, which surgical technique should be used.

Surgery

There is general consensus that a patient should have a life expectancy of at least 3 months to be a surgical candidate. Paraplegia for over 24 hours is a strong relative contraindication due to low chances of improvement when prolonged neurologic deficits exist before surgery.[617] Patients with hematologic malignancies should also be excluded, as they are best managed by RT or systemic therapy. Because estimation of life expectancy can be difficult, several groups have developed prognostic scoring systems to help predict surgical outcomes.[618-621]

Modern surgical techniques enable surgeons to achieve 360° decompression of the spinal cord, and stabilization can be performed concomitantly, if required. The development of a plethora of spinal implants composed of high-quality materials such as titanium greatly improves reconstruction outcome. The surgical approach—anterior, posterior, or combined/circumferential—is primarily determined by disease anatomy.[622,623]

Sundaresan and colleagues[616] reported favorable results using a variety of surgical approaches on 80 patients with solitary spine metastases. Both pain and mobility were improved in the majority of patients. OS reached 30 months, with 18% of patients surviving 5 years or more. The best outcome was observed in patients with kidney and breast cancers.

Surgery followed by adjuvant EBRT has emerged as a highly effective approach in relieving spinal cord compression and restoring function, especially for solid tumors. A meta-analysis including 24 surgery cohort studies and four RT studies found that patients are twice as likely to regain ambulatory function after surgery than RT alone.[624] However, data also revealed significant surgery-related mortality (6.3%) and morbidity (23%). In another review of literature from 1964 to 2005, anterior decompression with stabilization plus RT was associated with superior outcome over RT alone or laminectomy, achieving 75% mean improvement in neurologic function. However, high surgical mortality rate (mean 10%) was also reported.[625]

To date, only one relevant randomized trial has been reported.[626] Approximately 100 patients with metastatic spinal compression were randomized to surgery plus postoperative RT or RT alone. Compared to the RT group, significantly more patients in the surgery group regained walking ability (84% vs. 57%; $P = .001$) and for a longer period of time (median 122 days vs. 13 days; $P = .003$). The impressive results were obtained with strict eligibility criteria. The study excluded patients with radiosensitive tumors, neurologic deficits for 24 hours, multiple spinal tumors, lesions only compressing spinal roots, and prior RT to the vertebrae. Although studies demonstrated high efficacy of surgery, the formidable complications related to surgery cannot be overlooked. Using the Nationwide Inpatient Sample all-payer database, Patil et al[627] reviewed data of more than 26,000 patients who had undergone surgery for spinal metastases. The in-hospital mortality and complication rates were 5.6% and 22%, respectively. The most common complications were pulmonary (6.7%) and hemorrhages or hematomas (5.9%). Clearly, careful individual patient selection based on life expectancy and overall health is warranted.

Radiation Therapy

Traditionally, EBRT has been the main form of treatment for spinal metastases. In the modern surgery era, RT alone is often not sufficient in achieving decompression or stabilization (see above), but it is routinely used as adjuvant therapy following surgery as it is difficult to obtain wide

Discussion update in progress

Version 3.2025 © 2025 National Comprehensive Cancer Network© (NCCN©), All rights reserved. NCCN Guidelines® and this illustration may not be reproduced in any form without the express written permission of NCCN.

PLEASE NOTE that use of this NCCN Content is governed by the End-User License Agreement, and you MAY NOT distribute this Content or use it with any artificial intelligence model or tool.
Printed by A. S. M. FAZLUL KARIM CHOWDHURY on 4/20/2026 3:06:38 AM. Copyright © 2026 National Comprehensive Cancer Network, Inc. All Rights Reserved.

negative margins. Given the potential impact of RT on wound healing, most studies posed an interval of 1 to 3 weeks between resection and subsequent RT.[628]

In general, solid tumors are considered either moderately radiosensitive (eg, breast and prostate cancers) or radioresistant (eg, melanoma; osteosarcomas; cancers of the thyroid, colon, and kidney).[629] On the other hand, hematologic malignancies such as lymphomas and multiple myelomas are highly responsive to RT and systemic therapy. Hence, RT alone is often utilized as therapy for these cancers, even in the presence of cord compression. An excellent response to RT alone for spinal compression was reported by Marazano and colleagues.[630] Three hundred patients with predominately solid tumor histologies were randomized to a short-course (8 Gy x 2 days) or split-course (5 Gy x 3 days; 3 Gy x 5 days) schedule. After RT, 35% of nonambulatory patients regained walking ability, and pain relief was recorded in 57% of patients with a median survival of 4 months. Efficacy of RT was highly dependent on the histology: 70% of patients with nonambulatory breast cancer recovered mobility compared to only 20% of hepatocellular carcinoma patients. A randomized controlled trial including 342 patients with metastatic cancer (solid tumor) and spinal cord or cauda equina compression showed that single-fraction dosing (ie, 8 Gy in 1 fraction) did not meet criteria for noninferiority for ambulatory status at 8 weeks (compared to 20 Gy in 5 fractions).[631]

Where there is no compression, fracture, or instability, EBRT is effective in achieving local control as a primary treatment. A systematic review of seven retrospective studies including 885 patients reported a mean local control rate of 77% with EBRT.[629] RT is also a mainstay of palliative treatment for patients with poor PS, significant comorbidities, and/or limited life expectancy (<3–4 months). Klimo's meta-analysis, including 543 patients treated by RT, revealed pain control rates of 54% to 83%.[624]

Unlike surgery, RT has no immediate significant treatment-related complications and very few local recurrences. However, it increases surgical complications as it impairs wound healing.

Stereotactic radiation approaches (SRS or stereotactic body RT [SBRT]) allow precise high-dose targeting in one or two fractions while minimizing exposure of the nearby spinal cord and other organs at risk.[632] This is especially important in pre-irradiated patients. Consensus guidelines should be followed for stereotactic radiation planning and delivery.[632-634] Reasonable dosing schedules for the postoperative setting have been published by Redmond et al.[634]

A review including 59 publications with 5655 patients who received SRS for spinal metastases showed 1-year local control rates of 80% to 90% for newly diagnosed disease, 80% following surgery, and 65% for previously irradiated disease.[635] Results of the phase II/III RTOG 0631 trial demonstrated the feasibility of SRS for these patients.[636] The phase III component of this trial comparing single-dose stereotactic RT of 16 or 18 Gy to single-dose EBRT of 8 Gy in patients with one to three spinal metastases found no differences in the primary endpoint of pain response at 3 months.[637] However, improvements in pain responses were observed in an open-label randomized multicenter phase II/III trial in which SRS (24 Gy in 2 fractions) was compared to EBRT (20 Gy in 5 fractions) in 229 patients with painful spine metastases.[638] Intent-to-treat analyses showed that complete response to pain was significantly greater in the SRS arm than in the EBRT arm (35% vs. 14%, respectively; RR, 1.33; 95% CI, 1.14–1.55; $P = .0003$).

In addition to the goal of pain improvement, stereotactic radiation can also be used as a strategy to improve disease control and survival outcomes in patients with oligometastatic disease. For example, in the open-label randomized phase II SABR-COMET trial, standard palliative RT was compared to stereotactic ablative radiotherapy (SABR) in 99 patients with

Discussion update in progress

Version 3.2025 © 2025 National Comprehensive Cancer Network© (NCCN©), All rights reserved. NCCN Guidelines® and this illustration may not be reproduced in any form without the express written permission of NCCN.

PLEASE NOTE that use of this NCCN Content is governed by the End-User License Agreement, and you MAY NOT distribute this Content or use it with any artificial intelligence model or tool.
Printed by A. S. M. FAZLUL KARIM CHOWDHURY on 4/20/2026 3:06:38 AM. Copyright © 2026 National Comprehensive Cancer Network, Inc. All Rights Reserved.

1 to 5 metastatic lesions and a controlled primary tumor.[639] Five-year OS was significantly greater in the SABR arm than in the palliative RT arm (42.3% vs. 17.7%; *P* = .006).

Vertebral Augmentation

Percutaneous vertebroplasty and kyphoplasty involve injection of cement (polymethyl methacrylate) into the vertebral body. Vertebroplasty is a direct injection, while kyphoplasty involves inserting a balloon that provides a cavity for the injection. These vertebral augmentation procedures immediately reinforce and stabilize the column, thereby relieving pain and preventing further fractures.[640] They are suitable in poor surgical candidates with painful fractures, but are relatively contraindicated in the case of spinal cord compression because they do not achieve decompression. Symptomatic complications occur in up to 8% of patients (mostly with vertebroplasty), including embolization of the cement and local metastasis along the needle tract.

Percutaneous radiofrequency ablation (RFA) can also be considered for the treatment of spinal metastases to promote pain improvement and disease control. In a multicenter prospective trial including 50 patients with painful vertebral body metastases, RFA in the thoracic/lumbar region with cement augmentation was associated with improved pain and health-related quality of life.[641]

Systemic Therapy

Corticosteroids remain a routine initial prescription for patients presenting with cord compression, with a number of theoretical benefits including anti-inflammation, reduction in edema, short-term neurologic function improvement, and enhanced blood flow. However, the preference between high-dose dexamethasone (96 mg daily) and low-dose (10–16 mg daily) is still unclear.[642-644]

Systemic therapy has a limited role in metastatic spinal tumors except for chemosensitive tumors such as lymphoma, myeloma, small cell lung cancer, and germ cell tumors. Agents efficacious for the primary tumor are used.

NCCN Recommendations

Workup

Initial workup depends on the presence or absence of symptoms. Patients with an incidental, asymptomatic, metastatic lesion confirmed by systemic imaging can be observed with MRI. However, biopsy and further treatment of an incidental lesion are indicated if treatment of the patient is altered as a result of treatment of the incidental lesion. In the absence of symptoms, it is not mandatory to obtain a spinal MRI for every incidental metastatic lesion seen on surveillance bone scans. The alternate category involves severe or new back pain. Increasing intensity, duration, and changes in the character of pain should trigger an evaluation with an MRI study, even in patients with pre-existing degenerative spine conditions. Immediate spinal MRI is warranted in the occurrence of neurologic symptoms, including weakness, paresthesias, and bladder or bowel incontinence. Contrast can be used to highlight and further evaluate any focal abnormality. The MRI can be used to image the entire spine or a focal area of interest. If the patient is unable to have an MRI, then a CT myelogram is recommended.

A normal neurologic examination implies that there is no spinal radiculopathy or myelopathy correlating with the patient's symptoms. In this case, other causes should be considered (eg, leptomeningeal disease). An abnormal neurologic examination includes motor abnormalities, sphincter abnormalities, and/or sensory deficits attributable to a dysfunction of nerve root(s) and/or the spinal cord. Therefore, detection of radiculopathy, myelopathy, or cauda equina syndrome is indicative of an abnormal examination. However, reflex asymmetry and/or

Discussion update in progress

Version 3.2025 © 2025 National Comprehensive Cancer Network© (NCCN©), All rights reserved. NCCN Guidelines® and this illustration may not be reproduced in any form without the express written permission of NCCN.

PLEASE NOTE that use of this NCCN Content is governed by the End-User License Agreement, and you MAY NOT distribute this Content or use it with any artificial intelligence model or tool.
Printed by A. S. M. FAZLUL KARIM CHOWDHURY on 4/20/2026 3:06:38 AM. Copyright © 2026 National Comprehensive Cancer Network, Inc. All Rights Reserved.

presence of pathologic reflexes, as well as sensory deficits of a stocking/glove distribution are excluded. Spinal instability may be evaluated using the Spine Instability Neoplastic Score.[645]

Treatment

Once metastatic vertebral involvement is diagnosed, treatment is based on whether the patient is suffering from spinal cord compression, fracture, or spinal instability. In the presence of multiple metastatic spinal tumors, the one causing the patient's main symptoms is addressed first. Additional tumors can be treated at a later point according to the algorithm.

Radiographic spinal cord compression implies deformation of the spinal cord because of epidural tumor, retropulsed bone fragment, or both. It should be noted that epidural tumor may occupy part of the spinal canal with or without partial obliteration of CSF around the spinal cord. Those cases are excluded because there is no cord deformation. For tumors occurring below L1, any canal compression of 50% or more should be considered of equal importance as spinal cord compression. Patients with radiographic cord compression should start on dexamethasone (10–100 mg) to alleviate symptoms. Decompressive surgery (concomitant stabilization if indicated) and adjuvant RT is the preferred treatment (category 1) where there is spinal instability and no surgical contraindication. Primary EBRT alone is appropriate for patients with radiosensitive cancers (hematologic malignancies) and without evidence of spinal instability. Many fractionation schemes are available (8 Gy in 1 fraction, 20 Gy in 5 fractions, or 30 Gy in 10 fractions); the most common is a total of 30 Gy in 3-Gy daily fractions for 10 days.[646,647] Tolerance at the spinal cord and/or nerve route must be considered in determining dose. Primary systemic therapy is also an option for chemo-responsive tumors in the absence of clinical myelopathy, with close neurologic monitoring. In general, a treatment interval of at least 6 months is recommended.

Metastases to the spine without cord compression include the presence of tumor in the vertebral body, pedicle(s), lamina, transverse, or spinous process. It can also include epidural disease without cord deformation. Patients in this category should be assessed for fractures and spinal instability. Because the criteria for spinal destabilization secondary to tumor remain unclear, consultation by a surgeon is recommended. *Spinal instability* is grossly defined as the presence of significant kyphosis or subluxation (deformity) or of significantly retropulsed bone fragment. Not every pathologic fracture implies unstable structure. The degree of kyphosis or subluxation compatible with instability depends on the location of the tumor in the spine. The cross-sectional area of the vertebral body unaffected by the tumor and the patient's bone mineral density are additional factors affecting stability. In addition, vertebral body involvement is more important than dorsal element involvement with regard to stability. Circumferential disease as well as junctional and contiguous tumor location should be taken into account when assessing spinal stability. If fracture or instability is detected, the patient should undergo surgical stabilization or minimally invasive vertebral augmentation to relieve pain. These procedures should be followed by adjuvant RT to obtain local control.

If no fracture or instability is found, EBRT is the treatment of choice. Stereotactic RT is a preferred option for oligometastatic lesions and may also be appropriate for radioresistant histologies. Other alternatives are systemic therapy for responsive tumors, or surgery plus adjuvant RT in select cases. Patients experiencing intractable pain or rapid neurologic decline during RT should be considered for surgery. Neurologic deterioration is apparent when the patient's neurologic examination is becoming worse on a daily basis and the patient's ambulatory status is threatened. Intractable pain means that pain is not controlled with oral analgesics or that the patient cannot tolerate the medication due to side effects.

Discussion update in progress

Version 3.2025 © 2025 National Comprehensive Cancer Network© (NCCN©), All rights reserved. NCCN Guidelines® and this illustration may not be reproduced in any form without the express written permission of NCCN.

PLEASE NOTE that use of this NCCN Content is governed by the End-User License Agreement, and you MAY NOT distribute this Content or use it with any artificial intelligence model or tool.
Printed by A. S. M. FAZLUL KARIM CHOWDHURY on 4/20/2026 3:06:38 AM. Copyright © 2026 National Comprehensive Cancer Network, Inc. All Rights Reserved.

Progression and Recurrence

Follow-up involves MRI or CT imaging within 1 to 3 months post-treatment, then every 3 to 4 months for 1 year, then as clinically indicated. Upon detection of progression or recurrence on imaging scans, management strategy is based on previous treatment. Patients who underwent prior RT or surgery plus adjuvant RT may consider surgery or re-irradiation to the recurred area. Stereotactic RT may be appropriate for select patients. Clinicians should plan 6 months or more between treatments in consideration of tolerance of the spine and its nerve roots. Retreatment dose should be limited to no more than 10 Gy to the surface of the spinal cord. Radioablation/augmentation may be used as clinically indicated for painful lesions. In patients who were previously treated with systemic therapy, surgery may be indicated depending upon the degree of spinal stability/cord compression. RT may also be considered.

Discussion update in progress

Version 3.2025 © 2025 National Comprehensive Cancer Network© (NCCN©), All rights reserved. NCCN Guidelines® and this illustration may not be reproduced in any form without the express written permission of NCCN.

PLEASE NOTE that use of this NCCN Content is governed by the End-User License Agreement, and you MAY NOT distribute this Content or use it with any artificial intelligence model or tool.
Printed by A. S. M. FAZLUL KARIM CHOWDHURY on 4/20/2026 3:06:38 AM. Copyright © 2026 National Comprehensive Cancer Network, Inc. All Rights Reserved.

References

1. Siegel RL, Miller KD, Fuchs HE, Jemal A. Cancer statistics, 2022. CA Cancer J Clin 2022;72:7-33. Available at: https://www.ncbi.nlm.nih.gov/pubmed/35020204.

2. Miller KD, Ostrom QT, Kruchko C, et al. Brain and other central nervous system tumor statistics, 2021. CA Cancer J Clin 2021;71:381-406. Available at: https://www.ncbi.nlm.nih.gov/pubmed/34427324.

3. U.S. National Library of Medicine-Key MEDLINE® Indicators. Available at: http://www.nlm.nih.gov/bsd/bsd_key.html. Accessed July 24, 2014.

4. Sawaya R, Hammoud M, Schoppa D, et al. Neurosurgical outcomes in a modern series of 400 craniotomies for treatment of parenchymal tumors. Neurosurgery 1998;42:1044-1055; discussion 1055-1046. Available at: http://www.ncbi.nlm.nih.gov/pubmed/9588549.

5. Louis DN, Perry A, Reifenberger G, et al. The 2016 World Health Organization Classification of Tumors of the Central Nervous System: a summary. Acta Neuropathol 2016;131:803-820. Available at: http://www.ncbi.nlm.nih.gov/pubmed/27157931.

6. Louis DN, Perry A, Wesseling P, et al. The 2021 WHO Classification of Tumors of the Central Nervous System: a summary. Neuro Oncol 2021;23:1231-1251. Available at: https://www.ncbi.nlm.nih.gov/pubmed/34185076.

7. Yan H, Parsons DW, Jin G, et al. IDH1 and IDH2 mutations in gliomas. N Engl J Med 2009;360:765-773. Available at: http://www.ncbi.nlm.nih.gov/pubmed/19228619.

8. Houillier C, Wang X, Kaloshi G, et al. IDH1 or IDH2 mutations predict longer survival and response to temozolomide in low-grade gliomas. Neurology 2010;75:1560-1566. Available at: https://www.ncbi.nlm.nih.gov/pubmed/20975057.

9. Cancer Genome Atlas Research Network, Brat DJ, Verhaak RG, et al. Comprehensive, integrative genomic analysis of diffuse lower-grade gliomas. N Engl J Med 2015;372:2481-2498. Available at: http://www.ncbi.nlm.nih.gov/pubmed/26061751.

10. Eckel-Passow JE, Lachance DH, Molinaro AM, et al. Glioma groups based on 1p/19q, IDH, and TERT promoter mutations in tumors. N Engl J Med 2015;372:2499-2508. Available at: http://www.ncbi.nlm.nih.gov/pubmed/26061753.

11. Gritsch S, Batchelor TT, Gonzalez Castro LN. Diagnostic, therapeutic, and prognostic implications of the 2021 World Health Organization classification of tumors of the central nervous system. Cancer 2022;128:47-58. Available at: https://www.ncbi.nlm.nih.gov/pubmed/34633681.

12. Wiestler B, Capper D, Sill M, et al. Integrated DNA methylation and copy-number profiling identify three clinically and biologically relevant groups of anaplastic glioma. Acta Neuropathol 2014;128:561-571. Available at: https://www.ncbi.nlm.nih.gov/pubmed/25008768.

13. Weller M, Weber RG, Willscher E, et al. Molecular classification of diffuse cerebral WHO grade II/III gliomas using genome- and transcriptome-wide profiling improves stratification of prognostically distinct patient groups. Acta Neuropathol 2015;129:679-693. Available at: https://www.ncbi.nlm.nih.gov/pubmed/25783747.

14. Nitta M, Muragaki Y, Maruyama T, et al. Proposed therapeutic strategy for adult low-grade glioma based on aggressive tumor resection. Neurosurg Focus 2015;38:E7. Available at: https://www.ncbi.nlm.nih.gov/pubmed/25599276.

15. Baumert BG, Hegi ME, van den Bent MJ, et al. Temozolomide chemotherapy versus radiotherapy in high-risk low-grade glioma (EORTC 22033-26033): a randomised, open-label, phase 3 intergroup study. Lancet Oncol 2016;17:1521-1532. Available at: https://www.ncbi.nlm.nih.gov/pubmed/27686946.

16. Sanson M, Marie Y, Paris S, et al. Isocitrate dehydrogenase 1 codon 132 mutation is an important prognostic biomarker in gliomas. J Clin Oncol

Discussion update in progress

Version 3.2025 © 2025 National Comprehensive Cancer Network© (NCCN©), All rights reserved. NCCN Guidelines® and this illustration may not be reproduced in any form without the express written permission of NCCN.

PLEASE NOTE that use of this NCCN Content is governed by the End-User License Agreement, and you MAY NOT distribute this Content or use it with any artificial intelligence model or tool.
Printed by A. S. M. FAZLUL KARIM CHOWDHURY on 4/20/2026 3:06:38 AM. Copyright © 2026 National Comprehensive Cancer Network, Inc. All Rights Reserved.

2009;27:4150-4154. Available at: https://www.ncbi.nlm.nih.gov/pubmed/19636000.

17. Sahm F, Reuss D, Koelsche C, et al. Farewell to oligoastrocytoma: in situ molecular genetics favor classification as either oligodendroglioma or astrocytoma. Acta Neuropathol 2014;128:551-559. Available at: https://www.ncbi.nlm.nih.gov/pubmed/25143301.

18. Pai T, Epari S, Desai S, et al. Histological spectrum of oligodendroglial tumors: Only a subset shows 1p/19q codeletion. Neurol India 2017;65:113-120. Available at: https://www.ncbi.nlm.nih.gov/pubmed/28084254.

19. Neumann JE, Dorostkar MM, Korshunov A, et al. Distinct histomorphology in molecular subgroups of glioblastomas in young patients. J Neuropathol Exp Neurol 2016;75:408-414. Available at: https://www.ncbi.nlm.nih.gov/pubmed/26975364.

20. Dubbink HJ, Atmodimedjo PN, Kros JM, et al. Molecular classification of anaplastic oligodendroglioma using next-generation sequencing: a report of the prospective randomized EORTC Brain Tumor Group 26951 phase III trial. Neuro Oncol 2016;18:388-400. Available at: http://www.ncbi.nlm.nih.gov/pubmed/26354927.

21. Labussiere M, Idbaih A, Wang XW, et al. All the 1p19q codeleted gliomas are mutated on IDH1 or IDH2. Neurology 2010;74:1886-1890. Available at: https://www.ncbi.nlm.nih.gov/pubmed/20427748.

22. Horbinski C. What do we know about IDH1/2 mutations so far, and how do we use it? Acta Neuropathol 2013;125:621-636. Available at: https://www.ncbi.nlm.nih.gov/pubmed/23512379.

23. Brat DJ, Aldape K, Colman H, et al. cIMPACT-NOW update 5: recommended grading criteria and terminologies for IDH-mutant astrocytomas. Acta Neuropathol 2020;139:603-608. Available at: https://www.ncbi.nlm.nih.gov/pubmed/31996992.

24. Brat DJ, Aldape K, Colman H, et al. cIMPACT-NOW update 3: recommended diagnostic criteria for "Diffuse astrocytic glioma, IDH-wildtype, with molecular features of glioblastoma, WHO grade IV". Acta Neuropathol 2018;136:805-810. Available at: https://www.ncbi.nlm.nih.gov/pubmed/30259105.

25. Jiao Y, Killela PJ, Reitman ZJ, et al. Frequent ATRX, CIC, FUBP1 and IDH1 mutations refine the classification of malignant gliomas. Oncotarget 2012;3:709-722. Available at: https://www.ncbi.nlm.nih.gov/pubmed/22869205.

26. Leeper HE, Caron AA, Decker PA, et al. IDH mutation, 1p19q codeletion and ATRX loss in WHO grade II gliomas. Oncotarget 2015;6:30295-30305. Available at: https://www.ncbi.nlm.nih.gov/pubmed/26210286.

27. Reuss DE, Sahm F, Schrimpf D, et al. ATRX and IDH1-R132H immunohistochemistry with subsequent copy number analysis and IDH sequencing as a basis for an "integrated" diagnostic approach for adult astrocytoma, oligodendroglioma and glioblastoma. Acta Neuropathol 2015;129:133-146. Available at: https://www.ncbi.nlm.nih.gov/pubmed/25427834.

28. Arita H, Narita Y, Fukushima S, et al. Upregulating mutations in the TERT promoter commonly occur in adult malignant gliomas and are strongly associated with total 1p19q loss. Acta Neuropathol 2013;126:267-276. Available at: https://www.ncbi.nlm.nih.gov/pubmed/23764841.

29. Killela PJ, Reitman ZJ, Jiao Y, et al. TERT promoter mutations occur frequently in gliomas and a subset of tumors derived from cells with low rates of self-renewal. Proc Natl Acad Sci U S A 2013;110:6021-6026. Available at: https://www.ncbi.nlm.nih.gov/pubmed/23530248.

30. Appay R, Dehais C, Maurage CA, et al. CDKN2A homozygous deletion is a strong adverse prognosis factor in diffuse malignant IDH-mutant gliomas. Neuro Oncol 2019;21:1519-1528. Available at: https://www.ncbi.nlm.nih.gov/pubmed/31832685.

31. Cimino PJ, Holland EC. Targeted copy number analysis outperforms histologic grading in predicting patient survival for WHO grades II/III IDH-

Discussion update in progress

Version 3.2025 © 2025 National Comprehensive Cancer Network© (NCCN©), All rights reserved. NCCN Guidelines® and this illustration may not be reproduced in any form without the express written permission of NCCN.

PLEASE NOTE that use of this NCCN Content is governed by the End-User License Agreement, and you MAY NOT distribute this Content or use it with any artificial intelligence model or tool.
Printed by A. S. M. FAZLUL KARIM CHOWDHURY on 4/20/2026 3:06:38 AM. Copyright © 2026 National Comprehensive Cancer Network, Inc. All Rights Reserved.

mutant astrocytomas. Neuro Oncol 2019;21:819-821. Available at: https://www.ncbi.nlm.nih.gov/pubmed/30918961.

32. Reis GF, Pekmezci M, Hansen HM, et al. CDKN2A loss is associated with shortened overall survival in lower-grade (World Health Organization Grades II-III) astrocytomas. J Neuropathol Exp Neurol 2015;74:442-452. Available at: https://www.ncbi.nlm.nih.gov/pubmed/25853694.

33. Yang RR, Shi ZF, Zhang ZY, et al. IDH mutant lower grade (WHO Grades II/III) astrocytomas can be stratified for risk by CDKN2A, CDK4 and PDGFRA copy number alterations. Brain Pathol 2020;30:541-553. Available at: https://www.ncbi.nlm.nih.gov/pubmed/31733156.

34. Meyronet D, Esteban-Mader M, Bonnet C, et al. Characteristics of H3 K27M-mutant gliomas in adults. Neuro Oncol 2017;19:1127-1134. Available at: https://www.ncbi.nlm.nih.gov/pubmed/28201752.

35. Kristensen BW, Priesterbach-Ackley LP, Petersen JK, Wesseling P. Molecular pathology of tumors of the central nervous system. Ann Oncol 2019;30:1265-1278. Available at: https://www.ncbi.nlm.nih.gov/pubmed/31124566.

36. Louis DN, Giannini C, Capper D, et al. cIMPACT-NOW update 2: diagnostic clarifications for diffuse midline glioma, H3 K27M-mutant and diffuse astrocytoma/anaplastic astrocytoma, IDH-mutant. Acta Neuropathol 2018;135:639-642. Available at: https://www.ncbi.nlm.nih.gov/pubmed/29497819.

37. Buczkowicz P, Hoeman C, Rakopoulos P, et al. Genomic analysis of diffuse intrinsic pontine gliomas identifies three molecular subgroups and recurrent activating ACVR1 mutations. Nat Genet 2014;46:451-456. Available at: https://www.ncbi.nlm.nih.gov/pubmed/24705254.

38. Ryall S, Krishnatry R, Arnoldo A, et al. Targeted detection of genetic alterations reveal the prognostic impact of H3K27M and MAPK pathway aberrations in paediatric thalamic glioma. Acta Neuropathol Commun 2016;4:93. Available at: https://www.ncbi.nlm.nih.gov/pubmed/27577993.

39. Ebrahimi A, Skardelly M, Schuhmann MU, et al. High frequency of H3 K27M mutations in adult midline gliomas. J Cancer Res Clin Oncol 2019;145:839-850. Available at: https://www.ncbi.nlm.nih.gov/pubmed/30610375.

40. Mackay A, Burford A, Carvalho D, et al. Integrated molecular meta-analysis of 1,000 pediatric high-grade and diffuse intrinsic pontine glioma. Cancer Cell 2017;32:520-537 e525. Available at: https://www.ncbi.nlm.nih.gov/pubmed/28966033.

41. Sturm D, Witt H, Hovestadt V, et al. Hotspot mutations in H3F3A and IDH1 define distinct epigenetic and biological subgroups of glioblastoma. Cancer Cell 2012;22:425-437. Available at: https://www.ncbi.nlm.nih.gov/pubmed/23079654.

42. Jiang H, Cui Y, Wang J, Lin S. Impact of epidemiological characteristics of supratentorial gliomas in adults brought about by the 2016 world health organization classification of tumors of the central nervous system. Oncotarget 2017;8:20354-20361. Available at: https://www.ncbi.nlm.nih.gov/pubmed/27888628.

43. Wick W, Roth P, Hartmann C, et al. Long-term analysis of the NOA-04 randomized phase III trial of sequential radiochemotherapy of anaplastic glioma with PCV or temozolomide. Neuro Oncol 2016;18:1529-1537. Available at: https://www.ncbi.nlm.nih.gov/pubmed/27370396.

44. Cairncross JG, Wang M, Jenkins RB, et al. Benefit from procarbazine, lomustine, and vincristine in oligodendroglial tumors is associated with mutation of IDH. J Clin Oncol 2014;32:783-790. Available at: http://www.ncbi.nlm.nih.gov/pubmed/24516018.

45. Everhard S, Kaloshi G, Criniere E, et al. MGMT methylation: a marker of response to temozolomide in low-grade gliomas. Ann Neurol 2006;60:740-743. Available at: http://www.ncbi.nlm.nih.gov/pubmed/17192931.

46. Gorovets D, Kannan K, Shen R, et al. IDH mutation and neuroglial developmental features define clinically distinct subclasses of lower grade

Discussion update in progress

Version 3.2025 © 2025 National Comprehensive Cancer Network© (NCCN©), All rights reserved. NCCN Guidelines® and this illustration may not be reproduced in any form without the express written permission of NCCN.

PLEASE NOTE that use of this NCCN Content is governed by the End-User License Agreement, and you MAY NOT distribute this Content or use it with any artificial intelligence model or tool.
Printed by A. S. M. FAZLUL KARIM CHOWDHURY on 4/20/2026 3:06:38 AM. Copyright © 2026 National Comprehensive Cancer Network, Inc. All Rights Reserved.

diffuse astrocytic glioma. Clin Cancer Res 2012;18:2490-2501. Available at: https://www.ncbi.nlm.nih.gov/pubmed/22415316.

47. Wahl M, Phillips JJ, Molinaro AM, et al. Chemotherapy for adult low-grade gliomas: clinical outcomes by molecular subtype in a phase II study of adjuvant temozolomide. Neuro Oncol 2017;19:242-251. Available at: https://www.ncbi.nlm.nih.gov/pubmed/27571885.

48. Arita H, Yamasaki K, Matsushita Y, et al. A combination of TERT promoter mutation and MGMT methylation status predicts clinically relevant subgroups of newly diagnosed glioblastomas. Acta Neuropathol Commun 2016;4:79. Available at: https://www.ncbi.nlm.nih.gov/pubmed/27503138.

49. Pekmezci M, Rice T, Molinaro AM, et al. Adult infiltrating gliomas with WHO 2016 integrated diagnosis: additional prognostic roles of ATRX and TERT. Acta Neuropathol 2017;133:1001-1016. Available at: https://www.ncbi.nlm.nih.gov/pubmed/28255664.

50. Mollemann M, Wolter M, Felsberg J, et al. Frequent promoter hypermethylation and low expression of the MGMT gene in oligodendroglial tumors. Int J Cancer 2005;113:379-385. Available at: http://www.ncbi.nlm.nih.gov/pubmed/15455350.

51. Hegi ME, Diserens AC, Gorlia T, et al. MGMT gene silencing and benefit from temozolomide in glioblastoma. N Engl J Med 2005;352:997-1003. Available at: http://www.ncbi.nlm.nih.gov/pubmed/15758010.

52. Hegi ME, Diserens AC, Godard S, et al. Clinical trial substantiates the predictive value of O-6-methylguanine-DNA methyltransferase promoter methylation in glioblastoma patients treated with temozolomide. Clin Cancer Res 2004;10:1871-1874. Available at: https://www.ncbi.nlm.nih.gov/pubmed/15041700.

53. Bell EH, Zhang P, Fisher BJ, et al. Association of MGMT promoter methylation status with survival outcomes in patients with high-risk glioma treated with radiotherapy and temozolomide: an analysis from the NRG Oncology/RTOG 0424 trial. JAMA Oncol 2018;4:1405-1409. Available at: https://www.ncbi.nlm.nih.gov/pubmed/29955793.

54. Malmstrom A, Gronberg BH, Marosi C, et al. Temozolomide versus standard 6-week radiotherapy versus hypofractionated radiotherapy in patients older than 60 years with glioblastoma: the Nordic randomised, phase 3 trial. Lancet Oncol 2012;13:916-926. Available at: http://www.ncbi.nlm.nih.gov/pubmed/22877848.

55. Wick W, Platten M, Meisner C, et al. Temozolomide chemotherapy alone versus radiotherapy alone for malignant astrocytoma in the elderly: the NOA-08 randomised, phase 3 trial. Lancet Oncol 2012;13:707-715. Available at: http://www.ncbi.nlm.nih.gov/pubmed/22578793.

56. Khuong-Quang DA, Buczkowicz P, Rakopoulos P, et al. K27M mutation in histone H3.3 defines clinically and biologically distinct subgroups of pediatric diffuse intrinsic pontine gliomas. Acta Neuropathol 2012;124:439-447. Available at: https://www.ncbi.nlm.nih.gov/pubmed/22661320.

57. Korshunov A, Capper D, Reuss D, et al. Histologically distinct neuroepithelial tumors with histone 3 G34 mutation are molecularly similar and comprise a single nosologic entity. Acta Neuropathol 2016;131:137-146. Available at: https://www.ncbi.nlm.nih.gov/pubmed/26482474.

58. Horbinski C. To BRAF or not to BRAF: is that even a question anymore? J Neuropathol Exp Neurol 2013;72:2-7. Available at: https://www.ncbi.nlm.nih.gov/pubmed/23242278.

59. Hawkins C, Walker E, Mohamed N, et al. BRAF-KIAA1549 fusion predicts better clinical outcome in pediatric low-grade astrocytoma. Clin Cancer Res 2011;17:4790-4798. Available at: https://www.ncbi.nlm.nih.gov/pubmed/21610142.

60. Horbinski C, Nikiforova MN, Hagenkord JM, et al. Interplay among BRAF, p16, p53, and MIB1 in pediatric low-grade gliomas. Neuro Oncol 2012;14:777-789. Available at: https://www.ncbi.nlm.nih.gov/pubmed/22492957.

61. Penman CL, Faulkner C, Lowis SP, Kurian KM. Current understanding of BRAF alterations in diagnosis, prognosis, and therapeutic targeting in

Discussion update in progress

Version 3.2025 © 2025 National Comprehensive Cancer Network© (NCCN©), All rights reserved. NCCN Guidelines® and this illustration may not be reproduced in any form without the express written permission of NCCN.

PLEASE NOTE that use of this NCCN Content is governed by the End-User License Agreement, and you MAY NOT distribute this Content or use it with any artificial intelligence model or tool.
Printed by A. S. M. FAZLUL KARIM CHOWDHURY on 4/20/2026 3:06:38 AM. Copyright © 2026 National Comprehensive Cancer Network, Inc. All Rights Reserved.

pediatric low-grade gliomas. Front Oncol 2015;5:54. Available at: http://na1.replicon.com/NCCN/main.aspx.

62. Kleinschmidt-DeMasters BK, Aisner DL, Birks DK, Foreman NK. Epithelioid GBMs show a high percentage of BRAF V600E mutation. Am J Surg Pathol 2013;37:685-698. Available at: https://www.ncbi.nlm.nih.gov/pubmed/23552385.

63. Horbinski C, Hamilton RL, Nikiforov Y, Pollack IF. Association of molecular alterations, including BRAF, with biology and outcome in pilocytic astrocytomas. Acta Neuropathol 2010;119:641-649. Available at: https://www.ncbi.nlm.nih.gov/pubmed/20044755.

64. Mistry M, Zhukova N, Merico D, et al. BRAF mutation and CDKN2A deletion define a clinically distinct subgroup of childhood secondary high-grade glioma. J Clin Oncol 2015;33:1015-1022. Available at: https://www.ncbi.nlm.nih.gov/pubmed/25667294.

65. Chapman PB, Hauschild A, Robert C, et al. Improved survival with vemurafenib in melanoma with BRAF V600E mutation. N Engl J Med 2011;364:2507-2516. Available at: http://www.ncbi.nlm.nih.gov/pubmed/21639808.

66. McArthur GA, Chapman PB, Robert C, et al. Safety and efficacy of vemurafenib in BRAF(V600E) and BRAF(V600K) mutation-positive melanoma (BRIM-3): extended follow-up of a phase 3, randomised, open-label study. Lancet Oncol 2014;15:323-332. Available at: http://www.ncbi.nlm.nih.gov/pubmed/24508103.

67. Kaley T, Touat M, Subbiah V, et al. BRAF inhibition in BRAF(V600)-mutant gliomas: results from the VE-BASKET Study. J Clin Oncol 2018;36:3477-3484. Available at: https://www.ncbi.nlm.nih.gov/pubmed/30351999.

68. Chang S, Zhang P, Cairncross JG, et al. Phase III randomized study of radiation and temozolomide versus radiation and nitrosourea therapy for anaplastic astrocytoma: results of NRG Oncology RTOG 9813. Neuro Oncol 2017;19:252-258. Available at: https://www.ncbi.nlm.nih.gov/pubmed/27994066.

69. Olar A, Wani KM, Alfaro-Munoz KD, et al. IDH mutation status and role of WHO grade and mitotic index in overall survival in grade II-III diffuse gliomas. Acta Neuropathol 2015;129:585-596. Available at: https://www.ncbi.nlm.nih.gov/pubmed/25701198.

70. Bechet D, Gielen GG, Korshunov A, et al. Specific detection of methionine 27 mutation in histone 3 variants (H3K27M) in fixed tissue from high-grade astrocytomas. Acta Neuropathol 2014;128:733-741. Available at: https://www.ncbi.nlm.nih.gov/pubmed/25200321.

71. Hegi ME, Genbrugge E, Gorlia T, et al. MGMT promoter methylation cutoff with safety margin for selecting glioblastoma patients into trials omitting temozolomide: a pooled analysis of four clinical trials. Clin Cancer Res 2019;25:1809-1816. Available at: https://www.ncbi.nlm.nih.gov/pubmed/30514777.

72. Vlassenbroeck I, Califice S, Diserens AC, et al. Validation of real-time methylation-specific PCR to determine O6-methylguanine-DNA methyltransferase gene promoter methylation in glioma. J Mol Diagn 2008;10:332-337. Available at: https://www.ncbi.nlm.nih.gov/pubmed/18556773.

73. Quillien V, Lavenu A, Karayan-Tapon L, et al. Comparative assessment of 5 methods (methylation-specific polymerase chain reaction, MethyLight, pyrosequencing, methylation-sensitive high-resolution melting, and immunohistochemistry) to analyze O6-methylguanine-DNA-methyltranferase in a series of 100 glioblastoma patients. Cancer 2012;118:4201-4211. Available at: https://www.ncbi.nlm.nih.gov/pubmed/22294349.

74. Ostrom QT, Cioffi G, Waite K, et al. CBTRUS statistical report: primary brain and other central nervous system tumors diagnosed in the United States in 2014-2018. Neuro Oncol 2021;23:iii1-iii105. Available at: https://www.ncbi.nlm.nih.gov/pubmed/34608945.

75. Chang EF, Potts MB, Keles GE, et al. Seizure characteristics and control following resection in 332 patients with low-grade gliomas. J Neurosurg 2008;108:227-235. Available at: http://www.ncbi.nlm.nih.gov/pubmed/18240916.

Discussion update in progress

Version 3.2025 © 2025 National Comprehensive Cancer Network© (NCCN©), All rights reserved. NCCN Guidelines® and this illustration may not be reproduced in any form without the express written permission of NCCN.

PLEASE NOTE that use of this NCCN Content is governed by the End-User License Agreement, and you MAY NOT distribute this Content or use it with any artificial intelligence model or tool.
Printed by A. S. M. FAZLUL KARIM CHOWDHURY on 4/20/2026 3:06:38 AM. Copyright © 2026 National Comprehensive Cancer Network, Inc. All Rights Reserved.

76. Schiff D, Van den Bent M, Vogelbaum MA, et al. Recent developments and future directions in adult lower-grade gliomas: Society for Neuro-Oncology (SNO) and European Association of Neuro-Oncology (EANO) consensus. Neuro Oncol 2019;21:837-853. Available at: https://www.ncbi.nlm.nih.gov/pubmed/30753579.

77. Piepmeier J, Christopher S, Spencer D, et al. Variations in the natural history and survival of patients with supratentorial low-grade astrocytomas. Neurosurgery 1996;38:872-878; discussion 878-879. Available at: http://www.ncbi.nlm.nih.gov/pubmed/8727811.

78. Afra D, Osztie E, Sipos L, Vitanovics D. Preoperative history and postoperative survival of supratentorial low-grade astrocytomas. Br J Neurosurg 1999;13:299-305. Available at: http://www.ncbi.nlm.nih.gov/pubmed/10562842.

79. Gallo P, Cecchi PC, Locatelli F, et al. Pleomorphic xanthoastrocytoma: long-term results of surgical treatment and analysis of prognostic factors. Br J Neurosurg 2013;27:759-764. Available at: https://www.ncbi.nlm.nih.gov/pubmed/23514331.

80. Giannini C, Scheithauer BW, Burger PC, et al. Pleomorphic xanthoastrocytoma: what do we really know about it? Cancer 1999;85:2033-2045. Available at: https://www.ncbi.nlm.nih.gov/pubmed/10223246.

81. Ida CM, Rodriguez FJ, Burger PC, et al. Pleomorphic xanthoastrocytoma: natural history and long-term follow-up. Brain Pathol 2015;25:575-586. Available at: https://www.ncbi.nlm.nih.gov/pubmed/25318587.

82. Varshneya K, Sarmiento JM, Nuno M, et al. A national perspective of adult gangliogliomas. J Clin Neurosci 2016;30:65-70. Available at: https://www.ncbi.nlm.nih.gov/pubmed/27083133.

83. Tahiri Elousrouti L, Lamchahab M, Bougtoub N, et al. Subependymal giant cell astrocytoma (SEGA): a case report and review of the literature. J Med Case Rep 2016;10:35. Available at: https://www.ncbi.nlm.nih.gov/pubmed/26861567.

84. Roth J, Roach ES, Bartels U, et al. Subependymal giant cell astrocytoma: diagnosis, screening, and treatment. Recommendations from the International Tuberous Sclerosis Complex Consensus Conference 2012. Pediatr Neurol 2013;49:439-444. Available at: https://www.ncbi.nlm.nih.gov/pubmed/24138953.

85. Adriaensen ME, Schaefer-Prokop CM, Stijnen T, et al. Prevalence of subependymal giant cell tumors in patients with tuberous sclerosis and a review of the literature. Eur J Neurol 2009;16:691-696. Available at: https://www.ncbi.nlm.nih.gov/pubmed/19236458.

86. Goh S, Butler W, Thiele EA. Subependymal giant cell tumors in tuberous sclerosis complex. Neurology 2004;63:1457-1461. Available at: https://www.ncbi.nlm.nih.gov/pubmed/15505165.

87. Skalicky AM, Rentz AM, Liu Z, et al. The burden of subependymal giant cell astrocytomas associated with tuberous sclerosis complex: results of a patient and caregiver survey. J Child Neurol 2015;30:563-569. Available at: https://www.ncbi.nlm.nih.gov/pubmed/24667738.

88. Franz DN, Bissler JJ, McCormack FX. Tuberous sclerosis complex: neurological, renal and pulmonary manifestations. Neuropediatrics 2010;41:199-208. Available at: https://www.ncbi.nlm.nih.gov/pubmed/21210335.

89. Sun P, Kohrman M, Liu J, et al. Outcomes of resecting subependymal giant cell astrocytoma (SEGA) among patients with SEGA-related tuberous sclerosis complex: a national claims database analysis. Curr Med Res Opin 2012;28:657-663. Available at: https://www.ncbi.nlm.nih.gov/pubmed/22375958.

90. Berhouma M, Dubourg J, Messerer M. Neurology: Letter to the editor. Re: Sun P, Kohrman M, Liu J et al. Outcomes of resecting subependymal giant cell astrocytoma (SEGA) among patients with SEGA-related tuberous sclerosis complex: a national claims database analysis. Curr Med Res Opin 2012;28:657-63. Curr Med Res Opin 2012;28:1571-1572; author reply 1572-1573. Available at: https://www.ncbi.nlm.nih.gov/pubmed/22876836.

Discussion update in progress

Version 3.2025 © 2025 National Comprehensive Cancer Network© (NCCN©), All rights reserved. NCCN Guidelines® and this illustration may not be reproduced in any form without the express written permission of NCCN.

PLEASE NOTE that use of this NCCN Content is governed by the End-User License Agreement, and you MAY NOT distribute this Content or use it with any artificial intelligence model or tool.
Printed by A. S. M. FAZLUL KARIM CHOWDHURY on 4/20/2026 3:06:38 AM. Copyright © 2026 National Comprehensive Cancer Network, Inc. All Rights Reserved.

91. Wen PY, Stein A, van den Bent M, et al. Dabrafenib plus trametinib in patients with BRAF(V600E)-mutant low-grade and high-grade glioma (ROAR): a multicentre, open-label, single-arm, phase 2, basket trial. Lancet Oncol 2022;23:53-64. Available at: https://www.ncbi.nlm.nih.gov/pubmed/34838156.

92. Brown NF, Carter T, Kitchen N, Mulholland P. Dabrafenib and trametinib in BRAFV600E mutated glioma. CNS Oncol 2017;6:291-296. Available at: https://www.ncbi.nlm.nih.gov/pubmed/28984141.

93. Marks AM, Bindra RS, DiLuna ML, et al. Response to the BRAF/MEK inhibitors dabrafenib/trametinib in an adolescent with a BRAF V600E mutated anaplastic ganglioglioma intolerant to vemurafenib. Pediatr Blood Cancer 2018;65:e26969. Available at: https://www.ncbi.nlm.nih.gov/pubmed/29380516.

94. Franz DN, Belousova E, Sparagana S, et al. Efficacy and safety of everolimus for subependymal giant cell astrocytomas associated with tuberous sclerosis complex (EXIST-1): a multicentre, randomised, placebo-controlled phase 3 trial. Lancet 2013;381:125-132. Available at: https://www.ncbi.nlm.nih.gov/pubmed/23158522.

95. Franz DN, Belousova E, Sparagana S, et al. Everolimus for subependymal giant cell astrocytoma in patients with tuberous sclerosis complex: 2-year open-label extension of the randomised EXIST-1 study. Lancet Oncol 2014;15:1513-1520. Available at: https://www.ncbi.nlm.nih.gov/pubmed/25456370.

96. Wahl M, Chang SM, Phillips JJ, et al. Probing the phosphatidylinositol 3-kinase/mammalian target of rapamycin pathway in gliomas: A phase 2 study of everolimus for recurrent adult low-grade gliomas. Cancer 2017;123:4631-4639. Available at: https://www.ncbi.nlm.nih.gov/pubmed/28759109.

97. Ebrahimi-Fakhari D, Franz DN. Pharmacological treatment strategies for subependymal giant cell astrocytoma (SEGA). Expert Opin Pharmacother 2020;21:1329-1336. Available at: https://www.ncbi.nlm.nih.gov/pubmed/32338549.

98. Doebele RC, Drilon A, Paz-Ares L, et al. Entrectinib in patients with advanced or metastatic NTRK fusion-positive solid tumours: integrated analysis of three phase 1-2 trials. Lancet Oncol 2020;21:271-282. Available at: https://www.ncbi.nlm.nih.gov/pubmed/31838007.

99. Hong DS, DuBois SG, Kummar S, et al. Larotrectinib in patients with TRK fusion-positive solid tumours: a pooled analysis of three phase 1/2 clinical trials. Lancet Oncol 2020;21:531-540. Available at: https://www.ncbi.nlm.nih.gov/pubmed/32105622.

100. Pignatti F, van den Bent M, Curran D, et al. Prognostic factors for survival in adult patients with cerebral low-grade glioma. J Clin Oncol 2002;20:2076-2084. Available at: http://www.ncbi.nlm.nih.gov/pubmed/11956268.

101. Daniels TB, Brown PD, Felten SJ, et al. Validation of EORTC prognostic factors for adults with low-grade glioma: a report using intergroup 86-72-51. Int J Radiat Oncol Biol Phys 2011;81:218-224. Available at: http://www.ncbi.nlm.nih.gov/pubmed/21549518.

102. Lo SS, Cho KH, Hall WA, et al. Does the extent of surgery have an impact on the survival of patients who receive postoperative radiation therapy for supratentorial low-grade gliomas? Int J Cancer 2001;96 Suppl:71-78. Available at: http://www.ncbi.nlm.nih.gov/pubmed/11992388.

103. Shaw E, Arusell R, Scheithauer B, et al. Prospective randomized trial of low- versus high-dose radiation therapy in adults with supratentorial low-grade glioma: initial report of a North Central Cancer Treatment Group/Radiation Therapy Oncology Group/Eastern Cooperative Oncology Group study. J Clin Oncol 2002;20:2267-2276. Available at: http://www.ncbi.nlm.nih.gov/pubmed/11980997.

104. Lo SS, Hall WA, Cho KH, et al. Radiation dose response for supratentorial low-grade glioma--institutional experience and literature review. J Neurol Sci 2003;214:43-48. Available at: http://www.ncbi.nlm.nih.gov/pubmed/12972387.

105. Shaw EG, Berkey B, Coons SW, et al. Recurrence following neurosurgeon-determined gross-total resection of adult supratentorial low-

Discussion update in progress

Version 3.2025 © 2025 National Comprehensive Cancer Network© (NCCN©), All rights reserved. NCCN Guidelines® and this illustration may not be reproduced in any form without the express written permission of NCCN.

PLEASE NOTE that use of this NCCN Content is governed by the End-User License Agreement, and you MAY NOT distribute this Content or use it with any artificial intelligence model or tool.
Printed by A. S. M. FAZLUL KARIM CHOWDHURY on 4/20/2026 3:06:38 AM. Copyright © 2026 National Comprehensive Cancer Network, Inc. All Rights Reserved.

grade glioma: results of a prospective clinical trial. J Neurosurg 2008;109:835-841. Available at: http://www.ncbi.nlm.nih.gov/pubmed/18976072.

106. Jackson RJ, Fuller GN, Abi-Said D, et al. Limitations of stereotactic biopsy in the initial management of gliomas. Neuro Oncol 2001;3:193-200. Available at: https://www.ncbi.nlm.nih.gov/pubmed/11465400.

107. Villena Martin M, Pena Pardo FJ, Jimenez Aragon F, et al. Metabolic targeting can improve the efficiency of brain tumor biopsies. Semin Oncol 2020;47:148-154. Available at: https://www.ncbi.nlm.nih.gov/pubmed/32513423.

108. Brown TJ, Bota DA, van Den Bent MJ, et al. Management of low-grade glioma: a systematic review and meta-analysis. Neurooncol Pract 2019;6:249-258. Available at: https://www.ncbi.nlm.nih.gov/pubmed/31386075.

109. Yang K, Nath S, Koziarz A, et al. Biopsy versus subtotal versus gross total resection in patients with low-grade glioma: a systematic review and meta-analysis. World Neurosurg 2018;120:e762-e775. Available at: https://www.ncbi.nlm.nih.gov/pubmed/30172972.

110. Tang S, Liao J, Long Y. Comparative assessment of the efficacy of gross total versus subtotal total resection in patients with glioma: a meta-analysis. Int J Surg 2019;63:90-97. Available at: https://www.ncbi.nlm.nih.gov/pubmed/30742934.

111. McGirt MJ, Chaichana KL, Attenello FJ, et al. Extent of surgical resection is independently associated with survival in patients with hemispheric infiltrating low-grade gliomas. Neurosurgery 2008;63:700-707; author reply 707-708. Available at: http://www.ncbi.nlm.nih.gov/pubmed/18981880.

112. Jakola AS, Myrmel KS, Kloster R, et al. Comparison of a strategy favoring early surgical resection vs a strategy favoring watchful waiting in low-grade gliomas. JAMA 2012;308:1881-1888. Available at: https://www.ncbi.nlm.nih.gov/pubmed/23099483.

113. Berger MS, Deliganis AV, Dobbins J, Keles GE. The effect of extent of resection on recurrence in patients with low grade cerebral hemisphere gliomas. Cancer 1994;74:1784-1791. Available at: http://www.ncbi.nlm.nih.gov/pubmed/8082081.

114. Kilic T, Ozduman K, Elmaci I, et al. Effect of surgery on tumor progression and malignant degeneration in hemispheric diffuse low-grade astrocytomas. J Clin Neurosci 2002;9:549-552. Available at: http://www.ncbi.nlm.nih.gov/pubmed/12383413.

115. Roelz R, Strohmaier D, Jabbarli R, et al. Residual tumor volume as best outcome predictor in low grade glioma - a nine-years near-randomized survey of surgery vs. biopsy. Sci Rep 2016;6:32286. Available at: https://www.ncbi.nlm.nih.gov/pubmed/27574036.

116. Karim AB, Maat B, Hatlevoll R, et al. A randomized trial on dose-response in radiation therapy of low-grade cerebral glioma: European Organization for Research and Treatment of Cancer (EORTC) Study 22844. Int J Radiat Oncol Biol Phys 1996;36:549-556. Available at: http://www.ncbi.nlm.nih.gov/pubmed/8948338.

117. van den Bent MJ, Afra D, de Witte O, et al. Long-term efficacy of early versus delayed radiotherapy for low-grade astrocytoma and oligodendroglioma in adults: the EORTC 22845 randomised trial. Lancet 2005;366:985-990. Available at: http://www.ncbi.nlm.nih.gov/pubmed/16168780.

118. Gorlia T, Wu W, Wang M, et al. New validated prognostic models and prognostic calculators in patients with low-grade gliomas diagnosed by central pathology review: a pooled analysis of EORTC/RTOG/NCCTG phase III clinical trials. Neuro Oncol 2013;15:1568-1579. Available at: http://www.ncbi.nlm.nih.gov/pubmed/24049111.

119. Shaw EG, Wang M, Coons SW, et al. Randomized trial of radiation therapy plus procarbazine, lomustine, and vincristine chemotherapy for supratentorial adult low-grade glioma: initial results of RTOG 9802. J Clin Oncol 2012;30:3065-3070. Available at: http://www.ncbi.nlm.nih.gov/pubmed/22851558.

Discussion update in progress

Version 3.2025 © 2025 National Comprehensive Cancer Network© (NCCN©), All rights reserved. NCCN Guidelines® and this illustration may not be reproduced in any form without the express written permission of NCCN.

PLEASE NOTE that use of this NCCN Content is governed by the End-User License Agreement, and you MAY NOT distribute this Content or use it with any artificial intelligence model or tool.
Printed by A. S. M. FAZLUL KARIM CHOWDHURY on 4/20/2026 3:06:38 AM. Copyright © 2026 National Comprehensive Cancer Network, Inc. All Rights Reserved.

120. Buckner JC, Shaw EG, Pugh SL, et al. Radiation plus procarbazine, CCNU, and vincristine in low-grade glioma. N Engl J Med 2016;374:1344-1355. Available at: https://www.ncbi.nlm.nih.gov/pubmed/27050206.

121. Bell EH, Zhang P, Shaw EG, et al. Comprehensive genomic analysis in NRG Oncology/RTOG 9802: A phase III trial of radiation versus radiation plus procarbazine, lomustine (CCNU), and vincristine in high-risk low-grade glioma. J Clin Oncol 2020;38:3407-3417. Available at: https://www.ncbi.nlm.nih.gov/pubmed/32706640.

122. Fisher BJ, Hu C, Macdonald DR, et al. Phase 2 study of temozolomide-based chemoradiation therapy for high-risk low-grade gliomas: preliminary results of Radiation Therapy Oncology Group 0424. Int J Radiat Oncol Biol Phys 2015;91:497-504. Available at: http://www.ncbi.nlm.nih.gov/pubmed/25680596.

123. Fisher BJ, Pugh SL, Macdonald DR, et al. Phase 2 study of a temozolomide-based chemoradiation therapy regimen for high-risk, low-grade gliomas: long-term results of Radiation Therapy Oncology Group 0424. Int J Radiat Oncol Biol Phys 2020;107:720-725. Available at: https://www.ncbi.nlm.nih.gov/pubmed/32251755.

124. Navarria P, Pessina F, Cozzi L, et al. Can advanced new radiation therapy technologies improve outcome of high grade glioma (HGG) patients? analysis of 3D-conformal radiotherapy (3DCRT) versus volumetric-modulated arc therapy (VMAT) in patients treated with surgery, concomitant and adjuvant chemo-radiotherapy. BMC Cancer 2016;16:362. Available at: https://www.ncbi.nlm.nih.gov/pubmed/27287048.

125. Ding M, Newman F, Chen C, et al. Dosimetric comparison between 3DCRT and IMRT using different multileaf collimators in the treatment of brain tumors. Med Dosim 2009;34:1-8. Available at: https://www.ncbi.nlm.nih.gov/pubmed/19181248.

126. Shaw EG, Daumas-Duport C, Scheithauer BW, et al. Radiation therapy in the management of low-grade supratentorial astrocytomas. J Neurosurg 1989;70:853-861. Available at: http://www.ncbi.nlm.nih.gov/pubmed/2715812.

127. Indelicato DJ, Rotondo RL, Uezono H, et al. Outcomes following proton therapy for pediatric low-grade glioma. Int J Radiat Oncol Biol Phys 2019;104:149-156. Available at: https://www.ncbi.nlm.nih.gov/pubmed/30684665.

128. Nahed BV, Redjal N, Brat DJ, et al. Management of patients with recurrence of diffuse low grade glioma: A systematic review and evidence-based clinical practice guideline. J Neurooncol 2015;125:609-630. Available at: https://www.ncbi.nlm.nih.gov/pubmed/26530264.

129. Ramakrishna R, Hebb A, Barber J, et al. Outcomes in reoperated low-grade gliomas. Neurosurgery 2015;77:175-184; discussion 184. Available at: https://www.ncbi.nlm.nih.gov/pubmed/25850601.

130. Smith JS, Chang EF, Lamborn KR, et al. Role of extent of resection in the long-term outcome of low-grade hemispheric gliomas. J Clin Oncol 2008;26:1338-1345. Available at: https://www.ncbi.nlm.nih.gov/pubmed/18323558.

131. Uppstrom TJ, Singh R, Hadjigeorgiou GF, et al. Repeat surgery for recurrent low-grade gliomas should be standard of care. Clin Neurol Neurosurg 2016;151:18-23. Available at: https://www.ncbi.nlm.nih.gov/pubmed/27736650.

132. Kesari S, Schiff D, Drappatz J, et al. Phase II study of protracted daily temozolomide for low-grade gliomas in adults. Clin Cancer Res 2009;15:330-337. Available at: http://www.ncbi.nlm.nih.gov/pubmed/19118062.

133. Nicholson HS, Kretschmar CS, Krailo M, et al. Phase 2 study of temozolomide in children and adolescents with recurrent central nervous system tumors: a report from the Children's Oncology Group. Cancer 2007;110:1542-1550. Available at: http://www.ncbi.nlm.nih.gov/pubmed/17705175.

134. Soffietti R, Ruda R, Bradac GB, Schiffer D. PCV chemotherapy for recurrent oligodendrogliomas and oligoastrocytomas. Neurosurgery 1998;43:1066-1073. Available at: http://www.ncbi.nlm.nih.gov/pubmed/9802850.

Discussion update in progress

Version 3.2025 © 2025 National Comprehensive Cancer Network© (NCCN©), All rights reserved. NCCN Guidelines® and this illustration may not be reproduced in any form without the express written permission of NCCN.

PLEASE NOTE that use of this NCCN Content is governed by the End-User License Agreement, and you MAY NOT distribute this Content or use it with any artificial intelligence model or tool.
Printed by A. S. M. FAZLUL KARIM CHOWDHURY on 4/20/2026 3:06:38 AM. Copyright © 2026 National Comprehensive Cancer Network, Inc. All Rights Reserved.

135. Moghrabi A, Friedman HS, Ashley DM, et al. Phase II study of carboplatin (CBDCA) in progressive low-grade gliomas. Neurosurg Focus 1998;4:e3. Available at: http://www.ncbi.nlm.nih.gov/pubmed/17168503.

136. Brandes AA, Basso U, Vastola F, et al. Carboplatin and teniposide as third-line chemotherapy in patients with recurrent oligodendroglioma or oligoastrocytoma: a phase II study. Ann Oncol 2003;14:1727-1731. Available at: http://www.ncbi.nlm.nih.gov/pubmed/14630676.

137. Triebels VH, Taphoorn MJ, Brandes AA, et al. Salvage PCV chemotherapy for temozolomide-resistant oligodendrogliomas. Neurology 2004;63:904-906. Available at: http://www.ncbi.nlm.nih.gov/pubmed/15365146.

138. Fangusaro J, Onar-Thomas A, Young Poussaint T, et al. Selumetinib in paediatric patients with BRAF-aberrant or neurofibromatosis type 1-associated recurrent, refractory, or progressive low-grade glioma: a multicentre, phase 2 trial. Lancet Oncol 2019;20:1011-1022. Available at: https://www.ncbi.nlm.nih.gov/pubmed/31151904.

139. van den Bent MJ, Smits M, Kros JM, Chang SM. Diffuse infiltrating oligodendroglioma and astrocytoma. J Clin Oncol 2017;35:2394-2401. Available at: https://www.ncbi.nlm.nih.gov/pubmed/28640702.

140. van den Bent MJ, Baumert B, Erridge SC, et al. Interim results from the CATNON trial (EORTC study 26053-22054) of treatment with concurrent and adjuvant temozolomide for 1p/19q non-co-deleted anaplastic glioma: a phase 3, randomised, open-label intergroup study. Lancet 2017;390:1645-1653. Available at: https://www.ncbi.nlm.nih.gov/pubmed/28801186.

141. Perry JR, Laperriere N, O'Callaghan CJ, et al. Short-course radiation plus temozolomide in elderly patients with glioblastoma. N Engl J Med 2017;376:1027-1037. Available at: https://www.ncbi.nlm.nih.gov/pubmed/28296618.

142. Stupp R, Mason WP, van den Bent MJ, et al. Radiotherapy plus concomitant and adjuvant temozolomide for glioblastoma. N Engl J Med 2005;352:987-996. Available at: http://www.ncbi.nlm.nih.gov/pubmed/15758009.

143. Acharya S, Robinson CG, Michalski JM, et al. Association of 1p/19q codeletion and radiation necrosis in adult cranial gliomas after proton or photon therapy. Int J Radiat Oncol Biol Phys 2018;101:334-343. Available at: https://www.ncbi.nlm.nih.gov/pubmed/29534896

https://www.redjournal.org/article/S0360-3016(18)30223-2/fulltext.

144. Wen PY, Weller M, Lee EQ, et al. Glioblastoma in adults: a Society for Neuro-Oncology (SNO) and European Society of Neuro-Oncology (EANO) consensus review on current management and future directions. Neuro Oncol 2020;22:1073-1113. Available at: https://www.ncbi.nlm.nih.gov/pubmed/32328653.

145. Arevalo OD, Soto C, Rabiei P, et al. Assessment of glioblastoma response in the era of bevacizumab: longstanding and emergent challenges in the imaging evaluation of pseudoresponse. Front Neurol 2019;10:460. Available at: https://www.ncbi.nlm.nih.gov/pubmed/31133966.

146. Li XZ, Li YB, Cao Y, et al. Prognostic implications of resection extent for patients with glioblastoma multiforme: a meta-analysis. J Neurosurg Sci 2017;61:631-639. Available at: https://www.ncbi.nlm.nih.gov/pubmed/26824196.

147. Beiko J, Suki D, Hess KR, et al. IDH1 mutant malignant astrocytomas are more amenable to surgical resection and have a survival benefit associated with maximal surgical resection. Neuro Oncol 2014;16:81-91. Available at: https://www.ncbi.nlm.nih.gov/pubmed/24305719.

148. Molinaro AM, Hervey-Jumper S, Morshed RA, et al. Association of maximal extent of resection of contrast-enhanced and non-contrast-enhanced tumor with survival within molecular subgroups of patients with newly diagnosed glioblastoma. JAMA Oncol 2020;6:495-503. Available at: https://www.ncbi.nlm.nih.gov/pubmed/32027343.

Discussion update progress

Version 3.2025 © 2025 National Comprehensive Cancer Network© (NCCN©), All rights reserved. NCCN Guidelines® and this illustration may not be reproduced in any form without the express written permission of NCCN.

PLEASE NOTE that use of this NCCN Content is governed by the End-User License Agreement, and you MAY NOT distribute this Content or use it with any artificial intelligence model or tool.
Printed by A. S. M. FAZLUL KARIM CHOWDHURY on 4/20/2026 3:06:38 AM. Copyright © 2026 National Comprehensive Cancer Network, Inc. All Rights Reserved.

149. Barker FG, 2nd, Chang SM, Gutin PH, et al. Survival and functional status after resection of recurrent glioblastoma multiforme. Neurosurgery 1998;42:709-720; discussion 720-703. Available at: http://www.ncbi.nlm.nih.gov/pubmed/9574634.

150. Park JK, Hodges T, Arko L, et al. Scale to predict survival after surgery for recurrent glioblastoma multiforme. J Clin Oncol 2010;28:3838-3843. Available at: http://www.ncbi.nlm.nih.gov/pubmed/20644085.

151. Kristiansen K, Hagen S, Kollevold T, et al. Combined modality therapy of operated astrocytomas grade III and IV. Confirmation of the value of postoperative irradiation and lack of potentiation of bleomycin on survival time: a prospective multicenter trial of the Scandinavian Glioblastoma Study Group. Cancer 1981;47:649-652. Available at: http://www.ncbi.nlm.nih.gov/pubmed/6164465.

152. Walker MD, Alexander E, Jr., Hunt WE, et al. Evaluation of BCNU and/or radiotherapy in the treatment of anaplastic gliomas. A cooperative clinical trial. J Neurosurg 1978;49:333-343. Available at: http://www.ncbi.nlm.nih.gov/pubmed/355604.

153. Cabrera AR, Kirkpatrick JP, Fiveash JB, et al. Radiation therapy for glioblastoma: Executive summary of an American Society for Radiation Oncology Evidence-Based Clinical Practice Guideline. Pract Radiat Oncol 2016;6:217-225. Available at: https://www.ncbi.nlm.nih.gov/pubmed/27211230.

154. Gutin PH, Iwamoto FM, Beal K, et al. Safety and efficacy of bevacizumab with hypofractionated stereotactic irradiation for recurrent malignant gliomas. Int J Radiat Oncol Biol Phys 2009;75:156-163. Available at: https://www.ncbi.nlm.nih.gov/pubmed/19167838.

155. Fogh SE, Andrews DW, Glass J, et al. Hypofractionated stereotactic radiation therapy: an effective therapy for recurrent high-grade gliomas. J Clin Oncol 2010;28:3048-3053. Available at: https://www.ncbi.nlm.nih.gov/pubmed/20479391.

156. Roa W, Brasher PM, Bauman G, et al. Abbreviated course of radiation therapy in older patients with glioblastoma multiforme: a prospective randomized clinical trial. J Clin Oncol 2004;22:1583-1588. Available at: http://www.ncbi.nlm.nih.gov/pubmed/15051755.

157. Roa W, Kepka L, Kumar N, et al. International Atomic Energy Agency randomized phase III study of radiation therapy in elderly and/or frail patients with newly diagnosed glioblastoma multiforme. J Clin Oncol 2015;33:4145-4150. Available at: https://www.ncbi.nlm.nih.gov/pubmed/26392096.

158. Finazzi T. One week of radiotherapy for glioblastoma: a noninferiority trial? J Clin Oncol 2016;34:2192. Available at: https://www.ncbi.nlm.nih.gov/pubmed/27069081.

159. Kim H, Leiby BE, Shi W. Too little, too soon: short-course radiotherapy in elderly patients with glioblastoma. J Clin Oncol 2016;34:2191-2192. Available at: https://www.ncbi.nlm.nih.gov/pubmed/27069070.

160. Stupp R, Hegi ME, Mason WP, et al. Effects of radiotherapy with concomitant and adjuvant temozolomide versus radiotherapy alone on survival in glioblastoma in a randomised phase III study: 5-year analysis of the EORTC-NCIC trial. Lancet Oncol 2009;10:459-466. Available at: http://www.ncbi.nlm.nih.gov/pubmed/19269895.

161. van den Bent MJ, Carpentier AF, Brandes AA, et al. Adjuvant procarbazine, lomustine, and vincristine improves progression-free survival but not overall survival in newly diagnosed anaplastic oligodendrogliomas and oligoastrocytomas: a randomized European Organisation for Research and Treatment of Cancer phase III trial. J Clin Oncol 2006;24:2715-2722. Available at: http://www.ncbi.nlm.nih.gov/pubmed/16782911.

162. van den Bent MJ, Brandes AA, Taphoorn MJ, et al. Adjuvant procarbazine, lomustine, and vincristine chemotherapy in newly diagnosed anaplastic oligodendroglioma: long-term follow-up of EORTC brain tumor group study 26951. J Clin Oncol 2013;31:344-350. Available at: http://www.ncbi.nlm.nih.gov/pubmed/23071237.

Discussion update in progress

Version 3.2025 © 2025 National Comprehensive Cancer Network© (NCCN©), All rights reserved. NCCN Guidelines® and this illustration may not be reproduced in any form without the express written permission of NCCN.

PLEASE NOTE that use of this NCCN Content is governed by the End-User License Agreement, and you MAY NOT distribute this Content or use it with any artificial intelligence model or tool.
Printed by A. S. M. FAZLUL KARIM CHOWDHURY on 4/20/2026 3:06:38 AM. Copyright © 2026 National Comprehensive Cancer Network, Inc. All Rights Reserved.

163. Cairncross G, Berkey B, Shaw E, et al. Phase III trial of chemotherapy plus radiotherapy compared with radiotherapy alone for pure and mixed anaplastic oligodendroglioma: Intergroup Radiation Therapy Oncology Group Trial 9402. J Clin Oncol 2006;24:2707-2714. Available at: http://www.ncbi.nlm.nih.gov/pubmed/16782910.

164. Cairncross G, Wang M, Shaw E, et al. Phase III trial of chemoradiotherapy for anaplastic oligodendroglioma: long-term results of RTOG 9402. J Clin Oncol 2013;31:337-343. Available at: http://www.ncbi.nlm.nih.gov/pubmed/23071247.

165. Kleihues P, Burger PC, Scheithauer BW. Histological Typing of Tumours of the Central Nervous System. New York, NY: Springer-Verlag; 1993.

166. Jaeckle KA, Ballman KV, van den Bent M, et al. CODEL: phase III study of RT, RT + TMZ, or TMZ for newly diagnosed 1p/19q codeleted oligodendroglioma. Analysis from the initial study design. Neuro Oncol 2021;23:457-467. Available at: https://www.ncbi.nlm.nih.gov/pubmed/32678879.

167. van den Bent MJ, Tesileanu CMS, Wick W, et al. Adjuvant and concurrent temozolomide for 1p/19q non-co-deleted anaplastic glioma (CATNON; EORTC study 26053-22054): second interim analysis of a randomised, open-label, phase 3 study. Lancet Oncol 2021;22:813-823. Available at: https://www.ncbi.nlm.nih.gov/pubmed/34000245.

168. Clarke JL, Iwamoto FM, Sul J, et al. Randomized phase II trial of chemoradiotherapy followed by either dose-dense or metronomic temozolomide for newly diagnosed glioblastoma. J Clin Oncol 2009;27:3861-3867. Available at: http://www.ncbi.nlm.nih.gov/pubmed/19506159.

169. Gilbert MR, Wang M, Aldape KD, et al. Dose-dense temozolomide for newly diagnosed glioblastoma: a randomized phase III clinical trial. J Clin Oncol 2013;31:4085-4091. Available at: http://www.ncbi.nlm.nih.gov/pubmed/24101040.

170. Stupp R, Hegi ME, Gorlia T, et al. Cilengitide combined with standard treatment for patients with newly diagnosed glioblastoma with methylated MGMT promoter (CENTRIC EORTC 26071-22072 study): a multicentre, randomised, open-label, phase 3 trial. Lancet Oncol 2014;15:1100-1108. Available at: http://www.ncbi.nlm.nih.gov/pubmed/25163906.

171. Nabors LB, Fink KL, Mikkelsen T, et al. Two cilengitide regimens in combination with standard treatment for patients with newly diagnosed glioblastoma and unmethylated MGMT gene promoter: results of the open-label, controlled, randomized phase II CORE study. Neuro Oncol 2015;17:708-717. Available at: http://www.ncbi.nlm.nih.gov/pubmed/25762461.

172. Blumenthal DT, Gorlia T, Gilbert MR, et al. Is more better? The impact of extended adjuvant temozolomide in newly diagnosed glioblastoma: a secondary analysis of EORTC and NRG Oncology/RTOG. Neuro Oncol 2017;19:1119-1126. Available at: https://www.ncbi.nlm.nih.gov/pubmed/28371907.

173. Balana C, Vaz MA, Manuel Sepulveda J, et al. A phase II randomized, multicenter, open-label trial of continuing adjuvant temozolomide beyond 6 cycles in patients with glioblastoma (GEINO 14-01). Neuro Oncol 2020;22:1851-1861. Available at: https://www.ncbi.nlm.nih.gov/pubmed/32328662.

174. Glas M, Happold C, Rieger J, et al. Long-term survival of patients with glioblastoma treated with radiotherapy and lomustine plus temozolomide. J Clin Oncol 2009;27:1257-1261. Available at: https://www.ncbi.nlm.nih.gov/pubmed/19188676.

175. Herrlinger U, Rieger J, Koch D, et al. Phase II trial of lomustine plus temozolomide chemotherapy in addition to radiotherapy in newly diagnosed glioblastoma: UKT-03. J Clin Oncol 2006;24:4412-4417. Available at: https://www.ncbi.nlm.nih.gov/pubmed/16983109.

176. Herrlinger U, Tzaridis T, Mack F, et al. Lomustine-temozolomide combination therapy versus standard temozolomide therapy in patients with newly diagnosed glioblastoma with methylated MGMT promoter (CeTeG/NOA-09): a randomised, open-label, phase 3 trial. Lancet

Discussion update in progress

Version 3.2025 © 2025 National Comprehensive Cancer Network© (NCCN©), All rights reserved. NCCN Guidelines® and this illustration may not be reproduced in any form without the express written permission of NCCN.

PLEASE NOTE that use of this NCCN Content is governed by the End-User License Agreement, and you MAY NOT distribute this Content or use it with any artificial intelligence model or tool.
Printed by A. S. M. FAZLUL KARIM CHOWDHURY on 4/20/2026 3:06:38 AM. Copyright © 2026 National Comprehensive Cancer Network, Inc. All Rights Reserved.

2019;393:678-688. Available at: https://www.ncbi.nlm.nih.gov/pubmed/30782343.

177. Weller J, Tzaridis T, Mack F, et al. Health-related quality of life and neurocognitive functioning with lomustine-temozolomide versus temozolomide in patients with newly diagnosed, MGMT-methylated glioblastoma (CeTeG/NOA-09): a randomised, multicentre, open-label, phase 3 trial. Lancet Oncol 2019;20:1444-1453. Available at: https://www.ncbi.nlm.nih.gov/pubmed/31488360.

178. Stupp R, Taillibert S, Kanner AA, et al. Maintenance therapy with tumor-treating fields plus temozolomide vs temozolomide alone for glioblastoma: a randomized clinical trial. JAMA 2015;314:2535-2543. Available at: http://www.ncbi.nlm.nih.gov/pubmed/26670971.

179. Stupp R, Taillibert S, Kanner A, et al. Effect of tumor-treating fields plus maintenance temozolomide vs maintenance temozolomide alone on survival in patients with glioblastoma: a randomized clinical trial. JAMA 2017;318:2306-2316. Available at: https://www.ncbi.nlm.nih.gov/pubmed/29260225.

180. Taphoorn MJB, Dirven L, Kanner AA, et al. Influence of treatment with tumor-treating fields on health-related quality of life of patients with newly diagnosed glioblastoma: a secondary analysis of a randomized clinical trial. JAMA Oncol 2018;4:495-504. Available at: https://www.ncbi.nlm.nih.gov/pubmed/29392280.

181. Chamberlain MC. Treatment for patients with newly diagnosed glioblastoma. JAMA 2016;315:2348. Available at: https://www.ncbi.nlm.nih.gov/pubmed/27272590.

182. Sampson JH. Alternating electric fields for the treatment of glioblastoma. JAMA 2015;314:2511-2513. Available at: https://www.ncbi.nlm.nih.gov/pubmed/26670969.

183. Perry JR, Rizek P, Cashman R, et al. Temozolomide rechallenge in recurrent malignant glioma by using a continuous temozolomide schedule: the "rescue" approach. Cancer 2008;113:2152-2157. Available at: http://www.ncbi.nlm.nih.gov/pubmed/18756530.

184. Brandes AA, Tosoni A, Amista P, et al. How effective is BCNU in recurrent glioblastoma in the modern era? A phase II trial. Neurology 2004;63:1281-1284. Available at: https://www.ncbi.nlm.nih.gov/pubmed/15477552.

185. Reithmeier T, Graf E, Piroth T, et al. BCNU for recurrent glioblastoma multiforme: efficacy, toxicity and prognostic factors. BMC Cancer 2010;10:30. Available at: https://www.ncbi.nlm.nih.gov/pubmed/20122270.

186. Wick W, Puduvalli VK, Chamberlain MC, et al. Phase III study of enzastaurin compared with lomustine in the treatment of recurrent intracranial glioblastoma. J Clin Oncol 2010;28:1168-1174. Available at: http://www.ncbi.nlm.nih.gov/pubmed/20124186.

187. Taal W, Oosterkamp HM, Walenkamp AM, et al. Single-agent bevacizumab or lomustine versus a combination of bevacizumab plus lomustine in patients with recurrent glioblastoma (BELOB trial): a randomised controlled phase 2 trial. Lancet Oncol 2014;15:943-953. Available at: https://www.ncbi.nlm.nih.gov/pubmed/25035291.

188. Friedman HS, Prados MD, Wen PY, et al. Bevacizumab alone and in combination with irinotecan in recurrent glioblastoma. J Clin Oncol 2009;27:4733-4740. Available at: http://www.ncbi.nlm.nih.gov/pubmed/19720927.

189. Wick W, Gorlia T, Bendszus M, et al. Lomustine and bevacizumab in progressive glioblastoma. N Engl J Med 2017;377:1954-1963. Available at: https://www.ncbi.nlm.nih.gov/pubmed/29141164.

190. Ameratunga M, Pavlakis N, Wheeler H, et al. Anti-angiogenic therapy for high-grade glioma. Cochrane Database Syst Rev 2018;11:CD008218. Available at: https://www.ncbi.nlm.nih.gov/pubmed/30480778.

191. Wick W, Weller M, van den Bent M, Stupp R. Bevacizumab and recurrent malignant gliomas: a European perspective. J Clin Oncol 2010;28:e188-189; author reply e190-182. Available at: https://www.ncbi.nlm.nih.gov/pubmed/20159801.

Discussion update in progress

Version 3.2025 © 2025 National Comprehensive Cancer Network© (NCCN©), All rights reserved. NCCN Guidelines® and this illustration may not be reproduced in any form without the express written permission of NCCN.

PLEASE NOTE that use of this NCCN Content is governed by the End-User License Agreement, and you MAY NOT distribute this Content or use it with any artificial intelligence model or tool.
Printed by A. S. M. FAZLUL KARIM CHOWDHURY on 4/20/2026 3:06:38 AM. Copyright © 2026 National Comprehensive Cancer Network, Inc. All Rights Reserved.

192. Kaley T, Nolan C, Carver A, Omuro A. Bevacizumab for acute neurologic deterioration in patients with glioblastoma. CNS Oncol 2013;2:413-418. Available at: https://www.ncbi.nlm.nih.gov/pubmed/25054664.

193. Lombardi G, De Salvo GL, Brandes AA, et al. Regorafenib compared with lomustine in patients with relapsed glioblastoma (REGOMA): a multicentre, open-label, randomised, controlled, phase 2 trial. Lancet Oncol 2019;20:110-119. Available at: https://www.ncbi.nlm.nih.gov/pubmed/30522967.

194. Brem H, Piantadosi S, Burger PC, et al. Placebo-controlled trial of safety and efficacy of intraoperative controlled delivery by biodegradable polymers of chemotherapy for recurrent gliomas. The Polymer-brain Tumor Treatment Group. Lancet 1995;345:1008-1012. Available at: http://www.ncbi.nlm.nih.gov/pubmed/7723496.

195. McGirt MJ, Brem H. Carmustine wafers (Gliadel) plus concomitant temozolomide therapy after resection of malignant astrocytoma: growing evidence for safety and efficacy. Ann Surg Oncol 2010;17:1729-1731. Available at: https://www.ncbi.nlm.nih.gov/pubmed/20422453.

196. Stupp R, Wong ET, Kanner AA, et al. NovoTTF-100A versus physician's choice chemotherapy in recurrent glioblastoma: a randomised phase III trial of a novel treatment modality. Eur J Cancer 2012;48:2192-2202. Available at: http://www.ncbi.nlm.nih.gov/pubmed/22608262.

197. Kazmi F, Soon YY, Leong YH, et al. Re-irradiation for recurrent glioblastoma (GBM): a systematic review and meta-analysis. J Neurooncol 2019;142:79-90. Available at: https://www.ncbi.nlm.nih.gov/pubmed/30523605.

198. Panageas KS, Iwamoto FM, Cloughesy TF, et al. Initial treatment patterns over time for anaplastic oligodendroglial tumors. Neuro Oncol 2012;14:761-767. Available at: https://www.ncbi.nlm.nih.gov/pubmed/22661585.

199. Minniti G, Scaringi C, Lanzetta G, et al. Standard (60 gy) or short-course (40 gy) irradiation plus concomitant and adjuvant temozolomide for elderly patients with glioblastoma: a propensity-matched analysis. Int J Radiat Oncol Biol Phys 2015;91:109-115. Available at: http://www.ncbi.nlm.nih.gov/pubmed/25442339.

200. Brandes AA, Franceschi E, Tosoni A, et al. MGMT promoter methylation status can predict the incidence and outcome of pseudoprogression after concomitant radiochemotherapy in newly diagnosed glioblastoma patients. J Clin Oncol 2008;26:2192-2197. Available at: https://www.ncbi.nlm.nih.gov/pubmed/18445844.

201. Ellingson BM, Chung C, Pope WB, et al. Pseudoprogression, radionecrosis, inflammation or true tumor progression? challenges associated with glioblastoma response assessment in an evolving therapeutic landscape. J Neurooncol 2017;134:495-504. Available at: https://www.ncbi.nlm.nih.gov/pubmed/28382534.

202. Tsien C, Galban CJ, Chenevert TL, et al. Parametric response map as an imaging biomarker to distinguish progression from pseudoprogression in high-grade glioma. J Clin Oncol 2010;28:2293-2299. Available at: http://www.ncbi.nlm.nih.gov/pubmed/20368564.

203. Fink J, Born D, Chamberlain MC. Pseudoprogression: relevance with respect to treatment of high-grade gliomas. Curr Treat Options Oncol 2011;12:240-252. Available at: http://www.ncbi.nlm.nih.gov/pubmed/21594589.

204. Perry JR, Belanger K, Mason WP, et al. Phase II trial of continuous dose-intense temozolomide in recurrent malignant glioma: RESCUE study. J Clin Oncol 2010;28:2051-2057. Available at: http://www.ncbi.nlm.nih.gov/pubmed/20308655.

205. Weller M, Tabatabai G, Kastner B, et al. MGMT promoter methylation is a strong prognostic biomarker for benefit from dose-intensified temozolomide rechallenge in progressive glioblastoma: the DIRECTOR trial. Clin Cancer Res 2015;21:2057-2064. Available at: https://www.ncbi.nlm.nih.gov/pubmed/25655102.

206. Yung WK, Albright RE, Olson J, et al. A phase II study of temozolomide vs. procarbazine in patients with glioblastoma multiforme at

Discussion update in progress

Version 3.2025 © 2025 National Comprehensive Cancer Network© (NCCN©), All rights reserved. NCCN Guidelines® and this illustration may not be reproduced in any form without the express written permission of NCCN.

PLEASE NOTE that use of this NCCN Content is governed by the End-User License Agreement, and you MAY NOT distribute this Content or use it with any artificial intelligence model or tool.
Printed by A. S. M. FAZLUL KARIM CHOWDHURY on 4/20/2026 3:06:38 AM. Copyright © 2026 National Comprehensive Cancer Network, Inc. All Rights Reserved.

first relapse. Br J Cancer 2000;83:588-593. Available at: http://www.ncbi.nlm.nih.gov/pubmed/10944597.

207. Prados M, Rodriguez L, Chamberlain M, et al. Treatment of recurrent gliomas with 1,3-bis(2-chloroethyl)-1-nitrosourea and alpha-difluoromethylornithine. Neurosurgery 1989;24:806-809. Available at: https://www.ncbi.nlm.nih.gov/pubmed/2546093.

208. Chamberlain MC, Johnston S. Bevacizumab for recurrent alkylator-refractory anaplastic oligodendroglioma. Cancer 2009;115:1734-1743. Available at: http://www.ncbi.nlm.nih.gov/pubmed/19197992.

209. Chamberlain MC, Johnston S. Salvage chemotherapy with bevacizumab for recurrent alkylator-refractory anaplastic astrocytoma. J Neurooncol 2009;91:359-367. Available at: http://www.ncbi.nlm.nih.gov/pubmed/18953491.

210. Norden AD, Young GS, Setayesh K, et al. Bevacizumab for recurrent malignant gliomas: efficacy, toxicity, and patterns of recurrence. Neurology 2008;70:779-787. Available at: http://www.ncbi.nlm.nih.gov/pubmed/18316689.

211. Cloughesy T, Prados MD, Mikkelsen T. A phase 2 randomized non-comparative clinical trial of the effect of bevacizumab alone or in combination with irinotecan on 6-month progression free survival in recurrent refractory glioblastoma [abstract]. J Clin Oncol 2008;26(Suppl 15):2010b. Available at: http://meeting.ascopubs.org/cgi/content/abstract/26/15_suppl/2010b.

212. Kreisl TN, Kim L, Moore K, et al. Phase II trial of single-agent bevacizumab followed by bevacizumab plus irinotecan at tumor progression in recurrent glioblastoma. J Clin Oncol 2009;27:740-745. Available at: http://www.ncbi.nlm.nih.gov/pubmed/19114704.

213. Vredenburgh JJ, Desjardins A, Herndon JE, 2nd, et al. Phase II trial of bevacizumab and irinotecan in recurrent malignant glioma. Clin Cancer Res 2007;13:1253-1259. Available at: http://www.ncbi.nlm.nih.gov/pubmed/17317837.

214. Carvalho BF, Fernandes AC, Almeida DS, et al. Second-line chemotherapy in recurrent glioblastoma: a 2-cohort study. Oncol Res Treat 2015;38:348-354. Available at: https://www.ncbi.nlm.nih.gov/pubmed/26278578.

215. Schmidt F, Fischer J, Herrlinger U, et al. PCV chemotherapy for recurrent glioblastoma. Neurology 2006;66:587-589. Available at: https://www.ncbi.nlm.nih.gov/pubmed/16505319.

216. DeVita VT, Lawrence TS, Rosenberg SA. DeVita, Hellman, and Rosenberg's Cancer: Principles and Practice of Oncology (ed 8). Philadelphia: Lippincott Williams & Wilkins; 2008.

217. Packer RJ, Hoffman HJ, Friedman HS. Tumors of the fourth ventricle. In: Levin VA, ed. Cancer in the Nervous System. New York: Churchill Livingstone; 1996:153-156.

218. Ellison DW, Aldape KD, Capper D, et al. cIMPACT-NOW update 7: advancing the molecular classification of ependymal tumors. Brain Pathol 2020;30:863-866. Available at: https://www.ncbi.nlm.nih.gov/pubmed/32502305.

219. Vera-Bolanos E, Aldape K, Yuan Y, et al. Clinical course and progression-free survival of adult intracranial and spinal ependymoma patients. Neuro Oncol 2015;17:440-447. Available at: https://www.ncbi.nlm.nih.gov/pubmed/25121770.

220. Pajtler KW, Witt H, Sill M, et al. Molecular classification of ependymal tumors across all CNS compartments, histopathological grades, and age groups. Cancer Cell 2015;27:728-743. Available at: https://www.ncbi.nlm.nih.gov/pubmed/25965575.

221. Hubner JM, Kool M, Pfister SM, Pajtler KW. Epidemiology, molecular classification and WHO grading of ependymoma. J Neurosurg Sci 2018;62:46-50. Available at: https://www.ncbi.nlm.nih.gov/pubmed/28895660.

222. Ghasemi DR, Sill M, Okonechnikov K, et al. MYCN amplification drives an aggressive form of spinal ependymoma. Acta Neuropathol

Discussion update in progress

Version 3.2025 © 2025 National Comprehensive Cancer Network© (NCCN©), All rights reserved. NCCN Guidelines® and this illustration may not be reproduced in any form without the express written permission of NCCN.

PLEASE NOTE that use of this NCCN Content is governed by the End-User License Agreement, and you MAY NOT distribute this Content or use it with any artificial intelligence model or tool.
Printed by A. S. M. FAZLUL KARIM CHOWDHURY on 4/20/2026 3:06:38 AM. Copyright © 2026 National Comprehensive Cancer Network, Inc. All Rights Reserved.

2019;138:1075-1089. Available at: https://www.ncbi.nlm.nih.gov/pubmed/31414211.

223. Swanson AA, Raghunathan A, Jenkins RB, et al. Spinal cord ependymomas with MYCN amplification show aggressive clinical behavior. J Neuropathol Exp Neurol 2019;78:791-797. Available at: https://www.ncbi.nlm.nih.gov/pubmed/31373367.

224. Neumann JE, Spohn M, Obrecht D, et al. Molecular characterization of histopathological ependymoma variants. Acta Neuropathol 2020;139:305-318. Available at: https://www.ncbi.nlm.nih.gov/pubmed/31679042.

225. Kawabata Y, Takahashi JA, Arakawa Y, Hashimoto N. Long-term outcome in patients harboring intracranial ependymoma. J Neurosurg 2005;103:31-37. Available at: http://www.ncbi.nlm.nih.gov/pubmed/16121970.

226. Metellus P, Figarella-Branger D, Guyotat J, et al. Supratentorial ependymomas: prognostic factors and outcome analysis in a retrospective series of 46 adult patients. Cancer 2008;113:175-185. Available at: http://www.ncbi.nlm.nih.gov/pubmed/18470910.

227. Metellus P, Barrie M, Figarella-Branger D, et al. Multicentric French study on adult intracranial ependymomas: prognostic factors analysis and therapeutic considerations from a cohort of 152 patients. Brain 2007;130:1338-1349. Available at: http://www.ncbi.nlm.nih.gov/pubmed/17449478.

228. Paulino AC, Wen BC, Buatti JM, et al. Intracranial ependymomas: an analysis of prognostic factors and patterns of failure. Am J Clin Oncol 2002;25:117-122. Available at: http://www.ncbi.nlm.nih.gov/pubmed/11943886.

229. Schwartz TH, Kim S, Glick RS, et al. Supratentorial ependymomas in adult patients. Neurosurgery 1999;44:721-731. Available at: http://www.ncbi.nlm.nih.gov/pubmed/10201296.

230. Abdulaziz M, Mallory GW, Bydon M, et al. Outcomes following myxopapillary ependymoma resection: the importance of capsule integrity. Neurosurg Focus 2015;39:E8. Available at: https://www.ncbi.nlm.nih.gov/pubmed/26235025

https://thejns.org/downloadpdf/journals/neurosurg-focus/39/2/article-pE8.pdf.

231. Rodriguez D, Cheung MC, Housri N, et al. Outcomes of malignant CNS ependymomas: an examination of 2408 cases through the Surveillance, Epidemiology, and End Results (SEER) database (1973-2005). J Surg Res 2009;156:340-351. Available at: http://www.ncbi.nlm.nih.gov/pubmed/19577759.

232. Mansur DB, Perry A, Rajaram V, et al. Postoperative radiation therapy for grade II and III intracranial ependymoma. Int J Radiat Oncol Biol Phys 2005;61:387-391. Available at: http://www.ncbi.nlm.nih.gov/pubmed/15667957.

233. Merchant TE, Fouladi M. Ependymoma: new therapeutic approaches including radiation and chemotherapy. J Neurooncol 2005;75:287-299. Available at: http://www.ncbi.nlm.nih.gov/pubmed/16195801.

234. Taylor RE. Review of radiotherapy dose and volume for intracranial ependymoma. Pediatr Blood Cancer 2004;42:457-460. Available at: http://www.ncbi.nlm.nih.gov/pubmed/15049020.

235. Reni M, Brandes AA, Vavassori V, et al. A multicenter study of the prognosis and treatment of adult brain ependymal tumors. Cancer 2004;100:1221-1229. Available at: http://www.ncbi.nlm.nih.gov/pubmed/15022290.

236. Snider CA, Yang K, Mack SC, et al. Impact of radiation therapy and extent of resection for ependymoma in young children: A population-based study. Pediatr Blood Cancer 2018;65. Available at: https://www.ncbi.nlm.nih.gov/pubmed/29115718.

237. Ghia AJ, Mahajan A, Allen PK, et al. Supratentorial gross-totally resected non-anaplastic ependymoma: population based patterns of care

Discussion update in progress

Version 3.2025 © 2025 National Comprehensive Cancer Network© (NCCN©), All rights reserved. NCCN Guidelines® and this illustration may not be reproduced in any form without the express written permission of NCCN.

PLEASE NOTE that use of this NCCN Content is governed by the End-User License Agreement, and you MAY NOT distribute this Content or use it with any artificial intelligence model or tool.
Printed by A. S. M. FAZLUL KARIM CHOWDHURY on 4/20/2026 3:06:38 AM. Copyright © 2026 National Comprehensive Cancer Network, Inc. All Rights Reserved.

and outcomes analysis. J Neurooncol 2013;115:513-520. Available at: https://www.ncbi.nlm.nih.gov/pubmed/24085643.

238. Metellus P, Guyotat J, Chinot O, et al. Adult intracranial WHO grade II ependymomas: long-term outcome and prognostic factor analysis in a series of 114 patients. Neuro Oncol 2010;12:976-984. Available at: https://www.ncbi.nlm.nih.gov/pubmed/20484442.

239. Nuno M, Yu JJ, Varshneya K, et al. Treatment and survival of supratentorial and posterior fossa ependymomas in adults. J Clin Neurosci 2016;28:24-30. Available at: https://www.ncbi.nlm.nih.gov/pubmed/26810473.

240. Goldwein JW, Corn BW, Finlay JL, et al. Is craniospinal irradiation required to cure children with malignant (anaplastic) intracranial ependymomas? Cancer 1991;67:2766-2771. Available at: http://www.ncbi.nlm.nih.gov/pubmed/2025840.

241. Vanuytsel L, Brada M. The role of prophylactic spinal irradiation in localized intracranial ependymoma. Int J Radiat Oncol Biol Phys 1991;21:825-830. Available at: http://www.ncbi.nlm.nih.gov/pubmed/1831193.

242. Vanuytsel LJ, Bessell EM, Ashley SE, et al. Intracranial ependymoma: long-term results of a policy of surgery and radiotherapy. Int J Radiat Oncol Biol Phys 1992;23:313-319. Available at: http://www.ncbi.nlm.nih.gov/pubmed/1587752.

243. Merchant TE, Li C, Xiong X, et al. Conformal radiotherapy after surgery for paediatric ependymoma: a prospective study. Lancet Oncol 2009;10:258-266. Available at: http://www.ncbi.nlm.nih.gov/pubmed/19274783.

244. Pieters RS, Niemierko A, Fullerton BC, Munzenrider JE. Cauda equina tolerance to high-dose fractionated irradiation. Int J Radiat Oncol Biol Phys 2006;64:251-257. Available at: https://www.ncbi.nlm.nih.gov/pubmed/15993548.

245. Emami B, Lyman J, Brown A, et al. Tolerance of normal tissue to therapeutic irradiation. Int J Radiat Oncol Biol Phys 1991;21:109-122. Available at: https://www.ncbi.nlm.nih.gov/pubmed/2032882.

246. Lee SH, Chung CK, Kim CH, et al. Long-term outcomes of surgical resection with or without adjuvant radiation therapy for treatment of spinal ependymoma: a retrospective multicenter study by the Korea Spinal Oncology Research Group. Neuro Oncol 2013;15:921-929. Available at: https://www.ncbi.nlm.nih.gov/pubmed/23576600.

247. Abdel-Wahab M, Etuk B, Palermo J, et al. Spinal cord gliomas: A multi-institutional retrospective analysis. Int J Radiat Oncol Biol Phys 2006;64:1060-1071. Available at: https://www.ncbi.nlm.nih.gov/pubmed/16373081.

248. Kotecha R, Tom MC, Naik M, et al. Analyzing the role of adjuvant or salvage radiotherapy for spinal myxopapillary ependymomas. J Neurosurg Spine 2020:1-6. Available at: https://www.ncbi.nlm.nih.gov/pubmed/32357340.

249. Kano H, Niranjan A, Kondziolka D, et al. Outcome predictors for intracranial ependymoma radiosurgery. Neurosurgery 2009;64:279-287; discussion 287-278. Available at: http://www.ncbi.nlm.nih.gov/pubmed/19190457.

250. Lo SS, Abdulrahman R, Desrosiers PM, et al. The role of Gamma Knife Radiosurgery in the management of unresectable gross disease or gross residual disease after surgery in ependymoma. J Neurooncol 2006;79:51-56. Available at: http://www.ncbi.nlm.nih.gov/pubmed/16557349.

251. Mansur DB, Drzymala RE, Rich KM, et al. The efficacy of stereotactic radiosurgery in the management of intracranial ependymoma. J Neurooncol 2004;66:187-190. Available at: http://www.ncbi.nlm.nih.gov/pubmed/15015785.

252. Brandes AA, Cavallo G, Reni M, et al. A multicenter retrospective study of chemotherapy for recurrent intracranial ependymal tumors in adults by the Gruppo Italiano Cooperativo di Neuro-Oncologia. Cancer

Discussion update in progress

Version 3.2025 © 2025 National Comprehensive Cancer Network© (NCCN©), All rights reserved. NCCN Guidelines® and this illustration may not be reproduced in any form without the express written permission of NCCN.

PLEASE NOTE that use of this NCCN Content is governed by the End-User License Agreement, and you MAY NOT distribute this Content or use it with any artificial intelligence model or tool.
Printed by A. S. M. FAZLUL KARIM CHOWDHURY on 4/20/2026 3:06:38 AM. Copyright © 2026 National Comprehensive Cancer Network, Inc. All Rights Reserved.

2005;104:143-148. Available at: http://www.ncbi.nlm.nih.gov/pubmed/15912507.

253. Gornet MK, Buckner JC, Marks RS, et al. Chemotherapy for advanced CNS ependymoma. J Neurooncol 1999;45:61-67. Available at: http://www.ncbi.nlm.nih.gov/pubmed/10728911.

254. Chamberlain MC. Recurrent intracranial ependymoma in children: salvage therapy with oral etoposide. Pediatr Neurol 2001;24:117-121. Available at: http://www.ncbi.nlm.nih.gov/pubmed/11275460.

255. Sandri A, Massimino M, Mastrodicasa L, et al. Treatment with oral etoposide for childhood recurrent ependymomas. J Pediatr Hematol Oncol 2005;27:486-490. Available at: https://www.ncbi.nlm.nih.gov/pubmed/16189442.

256. Green RM, Cloughesy TF, Stupp R, et al. Bevacizumab for recurrent ependymoma. Neurology 2009;73:1677-1680. Available at: http://www.ncbi.nlm.nih.gov/pubmed/19917990.

257. Ruda R, Bosa C, Magistrello M, et al. Temozolomide as salvage treatment for recurrent intracranial ependymomas of the adult: a retrospective study. Neuro Oncol 2016;18:261-268. Available at: http://www.ncbi.nlm.nih.gov/pubmed/26323606.

258. Gilbert MR, Yuan Y, Wu J, et al. A phase II study of dose-dense temozolomide and lapatinib for recurrent low-grade and anaplastic supratentorial, infratentorial, and spinal cord ependymoma. Neuro Oncol 2021;23:468-477. Available at: https://www.ncbi.nlm.nih.gov/pubmed/33085768.

259. Kool M, Korshunov A, Remke M, et al. Molecular subgroups of medulloblastoma: an international meta-analysis of transcriptome, genetic aberrations, and clinical data of WNT, SHH, Group 3, and Group 4 medulloblastomas. Acta Neuropathol 2012;123:473-484. Available at: https://www.ncbi.nlm.nih.gov/pubmed/22358457.

260. Sant M, Minicozzi P, Lagorio S, et al. Survival of European patients with central nervous system tumors. Int J Cancer 2012;131:173-185. Available at: https://www.ncbi.nlm.nih.gov/pubmed/21805473.

261. Brandes AA, Franceschi E. Shedding light on adult medulloblastoma: current management and opportunities for advances. Am Soc Clin Oncol Educ Book 2014:e82-87. Available at: https://www.ncbi.nlm.nih.gov/pubmed/24857151.

262. Northcott PA, Buchhalter I, Morrissy AS, et al. The whole-genome landscape of medulloblastoma subtypes. Nature 2017;547:311-317. Available at: https://www.ncbi.nlm.nih.gov/pubmed/28726821.

263. Sharma T, Schwalbe EC, Williamson D, et al. Second-generation molecular subgrouping of medulloblastoma: an international meta-analysis of Group 3 and Group 4 subtypes. Acta Neuropathol 2019;138:309-326. Available at: https://www.ncbi.nlm.nih.gov/pubmed/31076851.

264. Korshunov A, Remke M, Werft W, et al. Adult and pediatric medulloblastomas are genetically distinct and require different algorithms for molecular risk stratification. J Clin Oncol 2010;28:3054-3060. Available at: https://www.ncbi.nlm.nih.gov/pubmed/20479417.

265. Remke M, Hielscher T, Northcott PA, et al. Adult medulloblastoma comprises three major molecular variants. J Clin Oncol 2011;29:2717-2723. Available at: https://www.ncbi.nlm.nih.gov/pubmed/21632505.

266. Taylor MD, Northcott PA, Korshunov A, et al. Molecular subgroups of medulloblastoma: the current consensus. Acta Neuropathol 2012;123:465-472. Available at: https://www.ncbi.nlm.nih.gov/pubmed/22134537.

267. Prados MD, Warnick RE, Wara WM, et al. Medulloblastoma in adults. Int J Radiat Oncol Biol Phys 1995;32:1145-1152. Available at: https://www.ncbi.nlm.nih.gov/pubmed/7607936.

268. Waszak SM, Northcott PA, Buchhalter I, et al. Spectrum and prevalence of genetic predisposition in medulloblastoma: a retrospective genetic study and prospective validation in a clinical trial cohort. Lancet

Discussion update in progress

Version 3.2025 © 2025 National Comprehensive Cancer Network© (NCCN©), All rights reserved. NCCN Guidelines® and this illustration may not be reproduced in any form without the express written permission of NCCN.

PLEASE NOTE that use of this NCCN Content is governed by the End-User License Agreement, and you MAY NOT distribute this Content or use it with any artificial intelligence model or tool.
Printed by A. S. M. FAZLUL KARIM CHOWDHURY on 4/20/2026 3:06:38 AM. Copyright © 2026 National Comprehensive Cancer Network, Inc. All Rights Reserved.

Oncol 2018;19:785-798. Available at: https://www.ncbi.nlm.nih.gov/pubmed/29753700.

269. Zhukova N, Ramaswamy V, Remke M, et al. Subgroup-specific prognostic implications of TP53 mutation in medulloblastoma. J Clin Oncol 2013;31:2927-2935. Available at: https://www.ncbi.nlm.nih.gov/pubmed/23835706.

270. Brandes AA, Bartolotti M, Marucci G, et al. New perspectives in the treatment of adult medulloblastoma in the era of molecular oncology. Crit Rev Oncol Hematol 2015;94:348-359. Available at: https://www.ncbi.nlm.nih.gov/pubmed/25600839.

271. Chan AW, Tarbell NJ, Black PM, et al. Adult medulloblastoma: prognostic factors and patterns of relapse. Neurosurgery 2000;47:623-631; discussion 631-622. Available at: http://www.ncbi.nlm.nih.gov/pubmed/10981749.

272. Frost PJ, Laperriere NJ, Wong CS, et al. Medulloblastoma in adults. Int J Radiat Oncol Biol Phys 1995;32:951-957. Available at: http://www.ncbi.nlm.nih.gov/pubmed/7607969.

273. Kunschner LJ, Kuttesch J, Hess K, Yung WK. Survival and recurrence factors in adult medulloblastoma: the M.D. Anderson Cancer Center experience from 1978 to 1998. Neuro Oncol 2001;3:167-173. Available at: http://www.ncbi.nlm.nih.gov/pubmed/11465397.

274. Chargari C, Feuvret L, Levy A, et al. Reappraisal of clinical outcome in adult medulloblastomas with emphasis on patterns of relapse. Br J Neurosurg 2010;24:460-467. Available at: http://www.ncbi.nlm.nih.gov/pubmed/20726753.

275. Thompson EM, Hielscher T, Bouffet E, et al. Prognostic value of medulloblastoma extent of resection after accounting for molecular subgroup: a retrospective integrated clinical and molecular analysis. Lancet Oncol 2016;17:484-495. Available at: https://www.ncbi.nlm.nih.gov/pubmed/26976201.

276. Douglas JG, Barker JL, Ellenbogen RG, Geyer JR. Concurrent chemotherapy and reduced-dose cranial spinal irradiation followed by conformal posterior fossa tumor bed boost for average-risk medulloblastoma: efficacy and patterns of failure. Int J Radiat Oncol Biol Phys 2004;58:1161-1164. Available at: http://www.ncbi.nlm.nih.gov/pubmed/15001259.

277. Merchant TE, Kun LE, Krasin MJ, et al. Multi-institution prospective trial of reduced-dose craniospinal irradiation (23.4 Gy) followed by conformal posterior fossa (36 Gy) and primary site irradiation (55.8 Gy) and dose-intensive chemotherapy for average-risk medulloblastoma. Int J Radiat Oncol Biol Phys 2008;70:782-787. Available at: http://www.ncbi.nlm.nih.gov/pubmed/17892918.

278. Packer RJ, Gajjar A, Vezina G, et al. Phase III study of craniospinal radiation therapy followed by adjuvant chemotherapy for newly diagnosed average-risk medulloblastoma. J Clin Oncol 2006;24:4202-4208. Available at: https://www.ncbi.nlm.nih.gov/pubmed/16943538.

279. Deutsch M, Thomas PR, Krischer J, et al. Results of a prospective randomized trial comparing standard dose neuraxis irradiation (3,600 cGy/20) with reduced neuraxis irradiation (2,340 cGy/13) in patients with low-stage medulloblastoma. A Combined Children's Cancer Group-Pediatric Oncology Group Study. Pediatr Neurosurg 1996;24:167-176; discussion 176-167. Available at: http://www.ncbi.nlm.nih.gov/pubmed/8873158.

280. Friedrich C, von Bueren AO, von Hoff K, et al. Treatment of adult nonmetastatic medulloblastoma patients according to the paediatric HIT 2000 protocol: a prospective observational multicentre study. Eur J Cancer 2013;49:893-903. Available at: http://www.ncbi.nlm.nih.gov/pubmed/23182688.

281. Brown AP, Barney CL, Grosshans DR, et al. Proton beam craniospinal irradiation reduces acute toxicity for adults with medulloblastoma. Int J Radiat Oncol Biol Phys 2013;86:277-284. Available at: http://www.ncbi.nlm.nih.gov/pubmed/23433794.

Discussion update in progress

Version 3.2025 © 2025 National Comprehensive Cancer Network© (NCCN©), All rights reserved. NCCN Guidelines® and this illustration may not be reproduced in any form without the express written permission of NCCN.

PLEASE NOTE that use of this NCCN Content is governed by the End-User License Agreement, and you MAY NOT distribute this Content or use it with any artificial intelligence model or tool.
Printed by A. S. M. FAZLUL KARIM CHOWDHURY on 4/20/2026 3:06:38 AM. Copyright © 2026 National Comprehensive Cancer Network, Inc. All Rights Reserved.

282. Germanwala AV, Mai JC, Tomycz ND, et al. Boost Gamma Knife surgery during multimodality management of adult medulloblastoma. J Neurosurg 2008;108:204-209. Available at: http://www.ncbi.nlm.nih.gov/pubmed/18240913.

283. Carrie C, Lasset C, Alapetite C, et al. Multivariate analysis of prognostic factors in adult patients with medulloblastoma. Retrospective study of 156 patients. Cancer 1994;74:2352-2360. Available at: http://www.ncbi.nlm.nih.gov/pubmed/7922986.

284. Riffaud L, Saikali S, Leray E, et al. Survival and prognostic factors in a series of adults with medulloblastomas. J Neurosurg 2009;111:478-487. Available at: http://www.ncbi.nlm.nih.gov/pubmed/19231932.

285. Padovani L, Sunyach MP, Perol D, et al. Common strategy for adult and pediatric medulloblastoma: a multicenter series of 253 adults. Int J Radiat Oncol Biol Phys 2007;68:433-440. Available at: http://www.ncbi.nlm.nih.gov/pubmed/17498567.

286. Herrlinger U, Steinbrecher A, Rieger J, et al. Adult medulloblastoma: prognostic factors and response to therapy at diagnosis and at relapse. J Neurol 2005;252:291-299. Available at: http://www.ncbi.nlm.nih.gov/pubmed/16189725.

287. Moots PL, O'Neill A, Londer H, et al. Preradiation Chemotherapy for Adult High-risk Medulloblastoma: A Trial of the ECOG-ACRIN Cancer Research Group (E4397). Am J Clin Oncol 2018;41:588-594. Available at: https://www.ncbi.nlm.nih.gov/pubmed/27635620.

288. Tarbell NJ, Friedman H, Polkinghorn WR, et al. High-risk medulloblastoma: a pediatric oncology group randomized trial of chemotherapy before or after radiation therapy (POG 9031). J Clin Oncol 2013;31:2936-2941. Available at: https://www.ncbi.nlm.nih.gov/pubmed/23857975.

289. Zeltzer PM, Boyett JM, Finlay JL, et al. Metastasis stage, adjuvant treatment, and residual tumor are prognostic factors for medulloblastoma in children: conclusions from the Children's Cancer Group 921 randomized phase III study. J Clin Oncol 1999;17:832-845. Available at: https://www.ncbi.nlm.nih.gov/pubmed/10071274.

290. Ashley DM, Meier L, Kerby T, et al. Response of recurrent medulloblastoma to low-dose oral etoposide. J Clin Oncol 1996;14:1922-1927. Available at: http://www.ncbi.nlm.nih.gov/pubmed/8656261.

291. Chamberlain MC, Kormanik PA. Chronic oral VP-16 for recurrent medulloblastoma. Pediatr Neurol 1997;17:230-234. Available at: https://www.ncbi.nlm.nih.gov/pubmed/9390699.

292. Dunkel IJ, Gardner SL, Garvin JH, Jr., et al. High-dose carboplatin, thiotepa, and etoposide with autologous stem cell rescue for patients with previously irradiated recurrent medulloblastoma. Neuro Oncol 2010;12:297-303. Available at: http://www.ncbi.nlm.nih.gov/pubmed/20167818.

293. Gururangan S, Krauser J, Watral MA, et al. Efficacy of high-dose chemotherapy or standard salvage therapy in patients with recurrent medulloblastoma. Neuro Oncol 2008;10:745-751. Available at: https://www.ncbi.nlm.nih.gov/pubmed/18755919.

294. Wang CH, Hsu TR, Wong TT, Chang KP. Efficacy of temozolomide for recurrent embryonal brain tumors in children. Childs Nerv Syst 2009;25:535-541. Available at: https://www.ncbi.nlm.nih.gov/pubmed/19107490.

295. Gill P, Litzow M, Buckner J, et al. High-dose chemotherapy with autologous stem cell transplantation in adults with recurrent embryonal tumors of the central nervous system. Cancer 2008;112:1805-1811. Available at: http://www.ncbi.nlm.nih.gov/pubmed/18300237.

296. Robinson GW, Orr BA, Wu G, et al. Vismodegib exerts targeted efficacy against recurrent sonic hedgehog-subgroup medulloblastoma: results from phase II Pediatric Brain Tumor Consortium Studies PBTC-025B and PBTC-032. J Clin Oncol 2015;33:2646-2654. Available at: https://www.ncbi.nlm.nih.gov/pubmed/26169613.

Discussion update in progress

Version 3.2025 © 2025 National Comprehensive Cancer Network© (NCCN©), All rights reserved. NCCN Guidelines® and this illustration may not be reproduced in any form without the express written permission of NCCN.

PLEASE NOTE that use of this NCCN Content is governed by the End-User License Agreement, and you MAY NOT distribute this Content or use it with any artificial intelligence model or tool.
Printed by A. S. M. FAZLUL KARIM CHOWDHURY on 4/20/2026 3:06:38 AM. Copyright © 2026 National Comprehensive Cancer Network, Inc. All Rights Reserved.

297. Kieran MW, Chisholm J, Casanova M, et al. Phase I study of oral sonidegib (LDE225) in pediatric brain and solid tumors and a phase II study in children and adults with relapsed medulloblastoma. Neuro Oncol 2017;19:1542-1552. Available at: https://www.ncbi.nlm.nih.gov/pubmed/28605510.

298. Cohen ME, Duffner P, eds. Brain tumors in children (ed 2). New York: McGraw-Hill; 1994.

299. Chang CH, Housepian EM, Herbert C, Jr. An operative staging system and a megavoltage radiotherapeutic technic for cerebellar medulloblastomas. Radiology 1969;93:1351-1359. Available at: http://www.ncbi.nlm.nih.gov/pubmed/4983156.

300. Brandes AA, Franceschi E, Tosoni A, et al. Adult neuroectodermal tumors of posterior fossa (medulloblastoma) and of supratentorial sites (stPNET). Crit Rev Oncol Hematol 2009;71:165-179. Available at: http://www.ncbi.nlm.nih.gov/pubmed/19303318.

301. Villano JL, Koshy M, Shaikh H, et al. Age, gender, and racial differences in incidence and survival in primary CNS lymphoma. Br J Cancer 2011;105:1414-1418. Available at: https://www.ncbi.nlm.nih.gov/pubmed/21915121.

302. O'Neill BP, Decker PA, Tieu C, Cerhan JR. The changing incidence of primary central nervous system lymphoma is driven primarily by the changing incidence in young and middle-aged men and differs from time trends in systemic diffuse large B-cell non-Hodgkin's lymphoma. Am J Hematol 2013;88:997-1000. Available at: https://www.ncbi.nlm.nih.gov/pubmed/23873804.

303. Fine HA, Mayer RJ. Primary central nervous system lymphoma. Ann Intern Med 1993;119:1093-1104. Available at: http://www.ncbi.nlm.nih.gov/pubmed/8239229.

304. Norden AD, Drappatz J, Wen PY, Claus EB. Survival among patients with primary central nervous system lymphoma, 1973-2004. J Neurooncol 2011;101:487-493. Available at: https://www.ncbi.nlm.nih.gov/pubmed/20556477.

305. Uldrick TS, Pipkin S, Scheer S, Hessol NA. Factors associated with survival among patients with AIDS-related primary central nervous system lymphoma. AIDS 2014;28:397-405. Available at: https://www.ncbi.nlm.nih.gov/pubmed/24076659.

306. Gerstner ER, Batchelor TT. Primary central nervous system lymphoma. Arch Neurol 2010;67:291-297. Available at: http://www.ncbi.nlm.nih.gov/pubmed/20212226.

307. Batchelor TT. Primary central nervous system lymphoma: A curable disease. Hematol Oncol 2019;37 Suppl 1:15-18. Available at: https://www.ncbi.nlm.nih.gov/pubmed/31187523.

308. Bataille B, Delwail V, Menet E, et al. Primary intracerebral malignant lymphoma: report of 248 cases. J Neurosurg 2000;92:261-266. Available at: http://www.ncbi.nlm.nih.gov/pubmed/10659013.

309. Buell JF, Gross TG, Hanaway MJ, et al. Posttransplant lymphoproliferative disorder: significance of central nervous system involvement. Transplant Proc 2005;37:954-955. Available at: https://www.ncbi.nlm.nih.gov/pubmed/15848587.

310. Cavaliere R, Petroni G, Lopes MB, et al. Primary central nervous system post-transplantation lymphoproliferative disorder: an International Primary Central Nervous System Lymphoma Collaborative Group Report. Cancer 2010;116:863-870. Available at: https://www.ncbi.nlm.nih.gov/pubmed/20052713.

311. Evens AM, David KA, Helenowski I, et al. Multicenter analysis of 80 solid organ transplantation recipients with post-transplantation lymphoproliferative disease: outcomes and prognostic factors in the modern era. J Clin Oncol 2010;28:1038-1046. Available at: https://www.ncbi.nlm.nih.gov/pubmed/20085936.

312. Penn I, Porat G. Central nervous system lymphomas in organ allograft recipients. Transplantation 1995;59:240-244. Available at: https://www.ncbi.nlm.nih.gov/pubmed/7839447.

Discussion update in progress

Version 3.2025 © 2025 National Comprehensive Cancer Network© (NCCN©), All rights reserved. NCCN Guidelines® and this illustration may not be reproduced in any form without the express written permission of NCCN.

PLEASE NOTE that use of this NCCN Content is governed by the End-User License Agreement, and you MAY NOT distribute this Content or use it with any artificial intelligence model or tool.
Printed by A. S. M. FAZLUL KARIM CHOWDHURY on 4/20/2026 3:06:38 AM. Copyright © 2026 National Comprehensive Cancer Network, Inc. All Rights Reserved.

313. Leblond V, Dhedin N, Mamzer Bruneel MF, et al. Identification of prognostic factors in 61 patients with posttransplantation lymphoproliferative disorders. J Clin Oncol 2001;19:772-778. Available at: https://www.ncbi.nlm.nih.gov/pubmed/11157030.

314. Nalesnik MA. Clinicopathologic characteristics of post-transplant lymphoproliferative disorders. Recent Results Cancer Res 2002;159:9-18. Available at: https://www.ncbi.nlm.nih.gov/pubmed/11785849.

315. Curtis RE, Travis LB, Rowlings PA, et al. Risk of lymphoproliferative disorders after bone marrow transplantation: a multi-institutional study. Blood 1999;94:2208-2216. Available at: https://www.ncbi.nlm.nih.gov/pubmed/10498590.

316. Jacobson CA, LaCasce AS. Lymphoma: risk and response after solid organ transplant. Oncology (Williston Park) 2010;24:936-944. Available at: https://www.ncbi.nlm.nih.gov/pubmed/21138175.

317. Wagner HJ, Rooney CM, Heslop HE. Diagnosis and treatment of posttransplantation lymphoproliferative disease after hematopoietic stem cell transplantation. Biol Blood Marrow Transplant 2002;8:1-8. Available at: https://www.ncbi.nlm.nih.gov/pubmed/11846351.

318. Abrey LE, Batchelor TT, Ferreri AJM, et al. Report of an international workshop to standardize baseline evaluation and response criteria for primary CNS lymphoma. J Clin Oncol 2005;23:5034-5043. Available at: http://www.ncbi.nlm.nih.gov/pubmed/15955902.

319. Holdhoff M, Mrugala MM, Grommes C, et al. Challenges in the treatment of newly diagnosed and recurrent primary central nervous system lymphoma. J Natl Compr Canc Netw 2020;18:1571-1578. Available at: https://www.ncbi.nlm.nih.gov/pubmed/33152700.

320. Batchelor T, Carson K, O'Neill A, et al. Treatment of primary CNS lymphoma with methotrexate and deferred radiotherapy: a report of NABTT 96-07. J Clin Oncol 2003;21:1044-1049. Available at: http://www.ncbi.nlm.nih.gov/pubmed/12637469.

321. Chamberlain MC, Johnston SK. High-dose methotrexate and rituximab with deferred radiotherapy for newly diagnosed primary B-cell CNS lymphoma. Neuro Oncol 2010;12:736-744. Available at: http://www.ncbi.nlm.nih.gov/pubmed/20511181.

322. DeAngelis LM, Seiferheld W, Schold SC, et al. Combination chemotherapy and radiotherapy for primary central nervous system lymphoma: Radiation Therapy Oncology Group Study 93-10. J Clin Oncol 2002;20:4643-4648. Available at: http://www.ncbi.nlm.nih.gov/pubmed/12488408.

323. Gavrilovic IT, Hormigo A, Yahalom J, et al. Long-term follow-up of high-dose methotrexate-based therapy with and without whole brain irradiation for newly diagnosed primary CNS lymphoma. J Clin Oncol 2006;24:4570-4574. Available at: http://www.ncbi.nlm.nih.gov/pubmed/17008697.

324. Shah GD, Yahalom J, Correa DD, et al. Combined immunochemotherapy with reduced whole-brain radiotherapy for newly diagnosed primary CNS lymphoma. J Clin Oncol 2007;25:4730-4735. Available at: http://www.ncbi.nlm.nih.gov/pubmed/17947720.

325. Wieduwilt MJ, Valles F, Issa S, et al. Immunochemotherapy with intensive consolidation for primary CNS lymphoma: a pilot study and prognostic assessment by diffusion-weighted MRI. Clin Cancer Res 2012;18:1146-1155. Available at: https://www.ncbi.nlm.nih.gov/pubmed/22228634.

326. Gregory G, Arumugaswamy A, Leung T, et al. Rituximab is associated with improved survival for aggressive B cell CNS lymphoma. Neuro Oncol 2013;15:1068-1073. Available at: http://www.ncbi.nlm.nih.gov/pubmed/23502429.

327. Holdhoff M, Ambady P, Abdelaziz A, et al. High-dose methotrexate with or without rituximab in newly diagnosed primary CNS lymphoma. Neurology 2014;83:235-239. Available at: http://www.ncbi.nlm.nih.gov/pubmed/24928128.

Discussion update in progress

Version 3.2025 © 2025 National Comprehensive Cancer Network© (NCCN©), All rights reserved. NCCN Guidelines® and this illustration may not be reproduced in any form without the express written permission of NCCN.

PLEASE NOTE that use of this NCCN Content is governed by the End-User License Agreement, and you MAY NOT distribute this Content or use it with any artificial intelligence model or tool.
Printed by A. S. M. FAZLUL KARIM CHOWDHURY on 4/20/2026 3:06:38 AM. Copyright © 2026 National Comprehensive Cancer Network, Inc. All Rights Reserved.

328. Ly KI, Crew LL, Graham CA, Mrugala MM. Primary central nervous system lymphoma treated with high-dose methotrexate and rituximab: A single-institution experience. Oncol Lett 2016;11:3471-3476. Available at: https://www.ncbi.nlm.nih.gov/pubmed/27123138.

329. Omuro A, Correa DD, DeAngelis LM, et al. R-MPV followed by high-dose chemotherapy with TBC and autologous stem-cell transplant for newly diagnosed primary CNS lymphoma. Blood 2015;125:1403-1410. Available at: https://www.ncbi.nlm.nih.gov/pubmed/25568347.

330. Glass J, Won M, Schultz CJ, et al. Phase I and II study of induction chemotherapy with methotrexate, rituximab, and temozolomide, followed by whole-brain radiotherapy and postirradiation temozolomide for primary CNS lymphoma: NRG Oncology RTOG 0227. J Clin Oncol 2016;34:1620-1625. Available at: https://www.ncbi.nlm.nih.gov/pubmed/27022122.

331. Song Y, Wen Y, Xue W, et al. Effect of rituximab on primary central nervous system lymphoma: a meta-analysis. Int J Hematol 2017;106:612-621. Available at: https://www.ncbi.nlm.nih.gov/pubmed/28900847.

332. Ferreri AJ, Reni M, Foppoli M, et al. High-dose cytarabine plus high-dose methotrexate versus high-dose methotrexate alone in patients with primary CNS lymphoma: a randomised phase 2 trial. Lancet 2009;374:1512-1520. Available at: http://www.ncbi.nlm.nih.gov/pubmed/19767089.

333. Bromberg JEC, Issa S, Bakunina K, et al. Rituximab in patients with primary CNS lymphoma (HOVON 105/ALLG NHL 24): a randomised, open-label, phase 3 intergroup study. Lancet Oncol 2019;20:216-228. Available at: https://www.ncbi.nlm.nih.gov/pubmed/30630772.

334. Ferreri AJ, Reni M, Pasini F, et al. A multicenter study of treatment of primary CNS lymphoma. Neurology 2002;58:1513-1520. Available at: https://www.ncbi.nlm.nih.gov/pubmed/12034789.

335. Schulz H, Pels H, Schmidt-Wolf I, et al. Intraventricular treatment of relapsed central nervous system lymphoma with the anti-CD20 antibody rituximab. Haematologica 2004;89:753-754. Available at: http://www.ncbi.nlm.nih.gov/pubmed/15194546.

336. Abrey LE, Moskowitz CH, Mason WP, et al. Intensive methotrexate and cytarabine followed by high-dose chemotherapy with autologous stem-cell rescue in patients with newly diagnosed primary CNS lymphoma: an intent-to-treat analysis. J Clin Oncol 2003;21:4151-4156. Available at: http://www.ncbi.nlm.nih.gov/pubmed/14615443.

337. Montemurro M, Kiefer T, Schuler F, et al. Primary central nervous system lymphoma treated with high-dose methotrexate, high-dose busulfan/thiotepa, autologous stem-cell transplantation and response-adapted whole-brain radiotherapy: results of the multicenter Ostdeutsche Studiengruppe Hamato-Onkologie OSHO-53 phase II study. Ann Oncol 2007;18:665-671. Available at: http://www.ncbi.nlm.nih.gov/pubmed/17185743.

338. Colombat P, Lemevel A, Bertrand P, et al. High-dose chemotherapy with autologous stem cell transplantation as first-line therapy for primary CNS lymphoma in patients younger than 60 years: a multicenter phase II study of the GOELAMS group. Bone Marrow Transplant 2006;38:417-420. Available at: http://www.ncbi.nlm.nih.gov/pubmed/16951691.

339. Illerhaus G, Muller F, Feuerhake F, et al. High-dose chemotherapy and autologous stem-cell transplantation without consolidating radiotherapy as first-line treatment for primary lymphoma of the central nervous system. Haematologica 2008;93:147-148. Available at: http://www.ncbi.nlm.nih.gov/pubmed/18166803.

340. Cote GM, Hochberg EP, Muzikansky A, et al. Autologous stem cell transplantation with thiotepa, busulfan, and cyclophosphamide (TBC) conditioning in patients with CNS involvement by non-Hodgkin lymphoma. Biol Blood Marrow Transplant 2012;18:76-83. Available at: http://www.ncbi.nlm.nih.gov/pubmed/21749848.

341. Kasenda B, Schorb E, Fritsch K, et al. Prognosis after high-dose chemotherapy followed by autologous stem-cell transplantation as first-line treatment in primary CNS lymphoma--a long-term follow-up study. Ann Oncol 2012;23:2670-2675. Available at: http://www.ncbi.nlm.nih.gov/pubmed/22473593.

Discussion update in progress

Version 3.2025 © 2025 National Comprehensive Cancer Network© (NCCN©), All rights reserved. NCCN Guidelines® and this illustration may not be reproduced in any form without the express written permission of NCCN.

PLEASE NOTE that use of this NCCN Content is governed by the End-User License Agreement, and you MAY NOT distribute this Content or use it with any artificial intelligence model or tool.
Printed by A. S. M. FAZLUL KARIM CHOWDHURY on 4/20/2026 3:06:38 AM. Copyright © 2026 National Comprehensive Cancer Network, Inc. All Rights Reserved.

342. DeFilipp Z, Li S, El-Jawahri A, et al. High-dose chemotherapy with thiotepa, busulfan, and cyclophosphamide and autologous stem cell transplantation for patients with primary central nervous system lymphoma in first complete remission. Cancer 2017;123:3073-3079. Available at: https://www.ncbi.nlm.nih.gov/pubmed/28369839.

343. Ferreri AJM, Cwynarski K, Pulczynski E, et al. Whole-brain radiotherapy or autologous stem-cell transplantation as consolidation strategies after high-dose methotrexate-based chemoimmunotherapy in patients with primary CNS lymphoma: results of the second randomisation of the International Extranodal Lymphoma Study Group-32 phase 2 trial. Lancet Haematol 2017;4:e510-e523. Available at: https://www.ncbi.nlm.nih.gov/pubmed/29054815.

344. Widemann BC, Balis FM, Kim A, et al. Glucarpidase, leucovorin, and thymidine for high-dose methotrexate-induced renal dysfunction: clinical and pharmacologic factors affecting outcome. J Clin Oncol 2010;28:3979-3986. Available at: http://www.ncbi.nlm.nih.gov/pubmed/20679598.

345. Widemann BC, Balis FM, Kempf-Bielack B, et al. High-dose methotrexate-induced nephrotoxicity in patients with osteosarcoma. Cancer 2004;100:2222-2232. Available at: http://www.ncbi.nlm.nih.gov/pubmed/15139068.

346. Ferreri AJ, Cwynarski K, Pulczynski E, et al. Chemoimmunotherapy with methotrexate, cytarabine, thiotepa, and rituximab (MATRix regimen) in patients with primary CNS lymphoma: results of the first randomisation of the International Extranodal Lymphoma Study Group-32 (IELSG32) phase 2 trial. Lancet Haematol 2016;3:e217-227. Available at: https://www.ncbi.nlm.nih.gov/pubmed/27132696.

347. Abrey LE, Yahalom J, DeAngelis LM. Treatment for primary CNS lymphoma: the next step. J Clin Oncol 2000;18:3144-3150. Available at: http://www.ncbi.nlm.nih.gov/pubmed/10963643.

348. Bessell EM, Lopez-Guillermo A, Villa S, et al. Importance of radiotherapy in the outcome of patients with primary CNS lymphoma: an analysis of the CHOD/BVAM regimen followed by two different radiotherapy treatments. J Clin Oncol 2002;20:231-236. Available at: http://www.ncbi.nlm.nih.gov/pubmed/11773174.

349. Gerstner ER, Carson KA, Grossman SA, Batchelor TT. Long-term outcome in PCNSL patients treated with high-dose methotrexate and deferred radiation. Neurology 2008;70:401-402. Available at: http://www.ncbi.nlm.nih.gov/pubmed/18227422.

350. Hoang-Xuan K, Taillandier L, Chinot O, et al. Chemotherapy alone as initial treatment for primary CNS lymphoma in patients older than 60 years: a multicenter phase II study (26952) of the European Organization for Research and Treatment of Cancer Brain Tumor Group. J Clin Oncol 2003;21:2726-2731. Available at: http://www.ncbi.nlm.nih.gov/pubmed/12860951.

351. Pels H, Schmidt-Wolf IG, Glasmacher A, et al. Primary central nervous system lymphoma: results of a pilot and phase II study of systemic and intraventricular chemotherapy with deferred radiotherapy. J Clin Oncol 2003;21:4489-4495. Available at: http://www.ncbi.nlm.nih.gov/pubmed/14597744.

352. Illerhaus G, Marks R, Muller F, et al. High-dose methotrexate combined with procarbazine and CCNU for primary CNS lymphoma in the elderly: results of a prospective pilot and phase II study. Ann Oncol 2009;20:319-325. Available at: http://www.ncbi.nlm.nih.gov/pubmed/18953065.

353. Juergens A, Pels H, Rogowski S, et al. Long-term survival with favorable cognitive outcome after chemotherapy in primary central nervous system lymphoma. Ann Neurol 2010;67:182-189. Available at: http://www.ncbi.nlm.nih.gov/pubmed/20225195.

354. Rubenstein JL, Hsi ED, Johnson JL, et al. Intensive chemotherapy and immunotherapy in patients with newly diagnosed primary CNS lymphoma: CALGB 50202 (Alliance 50202). J Clin Oncol 2013;31:3061-3068. Available at: https://www.ncbi.nlm.nih.gov/pubmed/23569323.

355. Soussain C, Hoang-Xuan K, Taillandier L, et al. Intensive chemotherapy followed by hematopoietic stem-cell rescue for refractory

Discussion update in progress

Version 3.2025 © 2025 National Comprehensive Cancer Network© (NCCN©), All rights reserved. NCCN Guidelines® and this illustration may not be reproduced in any form without the express written permission of NCCN.

PLEASE NOTE that use of this NCCN Content is governed by the End-User License Agreement, and you MAY NOT distribute this Content or use it with any artificial intelligence model or tool.
Printed by A. S. M. FAZLUL KARIM CHOWDHURY on 4/20/2026 3:06:38 AM. Copyright © 2026 National Comprehensive Cancer Network, Inc. All Rights Reserved.

and recurrent primary CNS and intraocular lymphoma: Societe Francaise de Greffe de Moelle Osseuse-Therapie Cellulaire. J Clin Oncol 2008;26:2512-2518. Available at: http://www.ncbi.nlm.nih.gov/pubmed/18413641.

356. Kasenda B, Ihorst G, Schroers R, et al. High-dose chemotherapy with autologous haematopoietic stem cell support for relapsed or refractory primary CNS lymphoma: a prospective multicentre trial by the German Cooperative PCNSL study group. Leukemia 2017;31:2623-2629. Available at: https://www.ncbi.nlm.nih.gov/pubmed/28559537.

357. Illerhaus G, Kasenda B, Ihorst G, et al. High-dose chemotherapy with autologous haemopoietic stem cell transplantation for newly diagnosed primary CNS lymphoma: a prospective, single-arm, phase 2 trial. Lancet Haematol 2016;3:e388-397. Available at: https://www.ncbi.nlm.nih.gov/pubmed/27476790.

358. Schorb E, Finke J, Ferreri AJ, et al. High-dose chemotherapy and autologous stem cell transplant compared with conventional chemotherapy for consolidation in newly diagnosed primary CNS lymphoma--a randomized phase III trial (MATRix). BMC Cancer 2016;16:282. Available at: https://www.ncbi.nlm.nih.gov/pubmed/27098429.

359. Houillier C, Taillandier L, Dureau S, et al. Radiotherapy or autologous stem-cell transplantation for primary CNS lymphoma in patients 60 years of age and younger: results of the Intergroup ANOCEF-GOELAMS randomized phase II PRECIS study. J Clin Oncol 2019;37:823-833. Available at: https://www.ncbi.nlm.nih.gov/pubmed/30785830.

360. Batchelor T, Giri S, Ruppert AS, et al. Myeloablative versus non-myeloablative consolidative chemotherapy for newly diagnosed primary central nervous system lymphoma: results of CALGB 51101 (Alliance). J Clin Oncol 2021;39:7506-7506. Available at: https://ascopubs.org/doi/abs/10.1200/JCO.2021.39.15_suppl.7506.

361. Plotkin SR, Betensky RA, Hochberg FH, et al. Treatment of relapsed central nervous system lymphoma with high-dose methotrexate. Clin Cancer Res 2004;10:5643-5646. Available at: http://www.ncbi.nlm.nih.gov/pubmed/15355887.

362. Grommes C, Tang SS, Wolfe J, et al. Phase 1b trial of an ibrutinib-based combination therapy in recurrent/refractory CNS lymphoma. Blood 2019;133:436-445. Available at: https://www.ncbi.nlm.nih.gov/pubmed/30567753.

363. Grommes C, Pastore A, Palaskas N, et al. Ibrutinib unmasks critical role of bruton tyrosine kinase in primary CNS lymphoma. Cancer Discov 2017;7:1018-1029. Available at: https://www.ncbi.nlm.nih.gov/pubmed/28619981.

364. Soussain C, Choquet S, Blonski M, et al. Ibrutinib monotherapy for relapse or refractory primary CNS lymphoma and primary vitreoretinal lymphoma: final analysis of the phase II 'proof-of-concept' iLOC study by the Lymphoma study association (LYSA) and the French oculo-cerebral lymphoma (LOC) network. Eur J Cancer 2019;117:121-130. Available at: https://www.ncbi.nlm.nih.gov/pubmed/31279304.

365. Batchelor TT, Grossman SA, Mikkelsen T, et al. Rituximab monotherapy for patients with recurrent primary CNS lymphoma. Neurology 2011;76:929-930. Available at: https://www.ncbi.nlm.nih.gov/pubmed/21383331.

366. Nayak L, Abrey LE, Drappatz J, et al. Multicenter phase II study of rituximab and temozolomide in recurrent primary central nervous system lymphoma. Leuk Lymphoma 2013;54:58-61. Available at: https://www.ncbi.nlm.nih.gov/pubmed/22656234.

367. Reni M, Zaja F, Mason W, et al. Temozolomide as salvage treatment in primary brain lymphomas. Br J Cancer 2007;96:864-867. Available at: http://www.ncbi.nlm.nih.gov/pubmed/17325700.

368. Makino K, Nakamura H, Hide T, Kuratsu J. Salvage treatment with temozolomide in refractory or relapsed primary central nervous system lymphoma and assessment of the MGMT status. J Neurooncol 2012;106:155-160. Available at: https://www.ncbi.nlm.nih.gov/pubmed/21720808.

Discussion update in progress

Version 3.2025 © 2025 National Comprehensive Cancer Network© (NCCN©), All rights reserved. NCCN Guidelines® and this illustration may not be reproduced in any form without the express written permission of NCCN.

PLEASE NOTE that use of this NCCN Content is governed by the End-User License Agreement, and you MAY NOT distribute this Content or use it with any artificial intelligence model or tool.
Printed by A. S. M. FAZLUL KARIM CHOWDHURY on 4/20/2026 3:06:38 AM. Copyright © 2026 National Comprehensive Cancer Network, Inc. All Rights Reserved.

369. Enting RH, Demopoulos A, DeAngelis LM, Abrey LE. Salvage therapy for primary CNS lymphoma with a combination of rituximab and temozolomide. Neurology 2004;63:901-903. Available at: http://www.ncbi.nlm.nih.gov/pubmed/15365145.

370. Rubenstein JL, Geng H, Fraser EJ, et al. Phase 1 investigation of lenalidomide/rituximab plus outcomes of lenalidomide maintenance in relapsed CNS lymphoma. Blood Adv 2018;2:1595-1607. Available at: https://www.ncbi.nlm.nih.gov/pubmed/29986852.

371. DeAngelis LM, Kreis W, Chan K, et al. Pharmacokinetics of ara-C and ara-U in plasma and CSF after high-dose administration of cytosine arabinoside. Cancer Chemother Pharmacol 1992;29:173-177. Available at: http://www.ncbi.nlm.nih.gov/pubmed/1733548.

372. Tun HW, Johnston PB, DeAngelis LM, et al. Phase 1 study of pomalidomide and dexamethasone for relapsed/refractory primary CNS or vitreoretinal lymphoma. Blood 2018;132:2240-2248. Available at: https://www.ncbi.nlm.nih.gov/pubmed/30262659.

373. Raizer JJ, Rademaker A, Evens AM, et al. Pemetrexed in the treatment of relapsed/refractory primary central nervous system lymphoma. Cancer 2012;118:3743-3748. Available at: http://www.ncbi.nlm.nih.gov/pubmed/22179954.

374. DeAngelis LM, Yahalom J, Thaler HT, Kher U. Combined modality therapy for primary CNS lymphoma. J Clin Oncol 1992;10:635-643. Available at: http://www.ncbi.nlm.nih.gov/pubmed/1548527.

375. Fisher B, Seiferheld W, Schultz C, et al. Secondary analysis of Radiation Therapy Oncology Group study (RTOG) 9310: an intergroup phase II combined modality treatment of primary central nervous system lymphoma. J Neurooncol 2005;74:201-205. Available at: http://www.ncbi.nlm.nih.gov/pubmed/16193393.

376. Nelson DF, Martz KL, Bonner H, et al. Non-Hodgkin's lymphoma of the brain: can high dose, large volume radiation therapy improve survival? Report on a prospective trial by the Radiation Therapy Oncology Group (RTOG): RTOG 8315. Int J Radiat Oncol Biol Phys 1992;23:9-17. Available at: http://www.ncbi.nlm.nih.gov/pubmed/1572835.

377. Schultz C, Scott C, Sherman W, et al. Preirradiation chemotherapy with cyclophosphamide, doxorubicin, vincristine, and dexamethasone for primary CNS lymphomas: initial report of radiation therapy oncology group protocol 88-06. J Clin Oncol 1996;14:556-564. Available at: http://www.ncbi.nlm.nih.gov/pubmed/8636771.

378. Poortmans PM, Kluin-Nelemans HC, Haaxma-Reiche H, et al. High-dose methotrexate-based chemotherapy followed by consolidating radiotherapy in non-AIDS-related primary central nervous system lymphoma: European Organization for Research and Treatment of Cancer Lymphoma Group Phase II Trial 20962. J Clin Oncol 2003;21:4483-4488. Available at: http://www.ncbi.nlm.nih.gov/pubmed/14597741.

379. Ghesquieres H, Ferlay C, Sebban C, et al. Long-term follow-up of an age-adapted C5R protocol followed by radiotherapy in 99 newly diagnosed primary CNS lymphomas: a prospective multicentric phase II study of the Groupe d'Etude des Lymphomes de l'Adulte (GELA). Ann Oncol 2010;21:842-850. Available at: http://www.ncbi.nlm.nih.gov/pubmed/19914958.

380. Thiel E, Korfel A, Martus P, et al. High-dose methotrexate with or without whole brain radiotherapy for primary CNS lymphoma (G-PCNSL-SG-1): a phase 3, randomised, non-inferiority trial. Lancet Oncol 2010;11:1036-1047. Available at: http://www.ncbi.nlm.nih.gov/pubmed/20970380.

381. Morris PG, Correa DD, Yahalom J, et al. Rituximab, methotrexate, procarbazine, and vincristine followed by consolidation reduced-dose whole-brain radiotherapy and cytarabine in newly diagnosed primary CNS lymphoma: final results and long-term outcome. J Clin Oncol 2013;31:3971-3979. Available at: http://www.ncbi.nlm.nih.gov/pubmed/24101038.

382. Nguyen PL, Chakravarti A, Finkelstein DM, et al. Results of whole-brain radiation as salvage of methotrexate failure for immunocompetent

Discussion update in progress

Version 3.2025 © 2025 National Comprehensive Cancer Network© (NCCN©), All rights reserved. NCCN Guidelines® and this illustration may not be reproduced in any form without the express written permission of NCCN.

PLEASE NOTE that use of this NCCN Content is governed by the End-User License Agreement, and you MAY NOT distribute this Content or use it with any artificial intelligence model or tool.
Printed by A. S. M. FAZLUL KARIM CHOWDHURY on 4/20/2026 3:06:38 AM. Copyright © 2026 National Comprehensive Cancer Network, Inc. All Rights Reserved.

patients with primary CNS lymphoma. J Clin Oncol 2005;23:1507-1513. Available at: http://www.ncbi.nlm.nih.gov/pubmed/15735126.

383. Coulon A, Lafitte F, Hoang-Xuan K, et al. Radiographic findings in 37 cases of primary CNS lymphoma in immunocompetent patients. Eur Radiol 2002;12:329-340. Available at: http://www.ncbi.nlm.nih.gov/pubmed/11870430.

384. Mohile NA, Deangelis LM, Abrey LE. The utility of body FDG PET in staging primary central nervous system lymphoma. Neuro Oncol 2008;10:223-228. Available at: http://www.ncbi.nlm.nih.gov/pubmed/18287338.

385. Ferreri AJ, Blay JY, Reni M, et al. Prognostic scoring system for primary CNS lymphomas: the International Extranodal Lymphoma Study Group experience. J Clin Oncol 2003;21:266-272. Available at: https://www.ncbi.nlm.nih.gov/pubmed/12525518.

386. Jahr G, Broi MD, Holte H, Jr., et al. Evaluation of Memorial Sloan-Kettering Cancer Center and International Extranodal Lymphoma Study Group prognostic scoring systems to predict overall survival in intracranial primary CNS lymphoma. Brain Behav 2018;8:e00928. Available at: https://www.ncbi.nlm.nih.gov/pubmed/29541540.

387. Doolittle ND, Korfel A, Lubow MA, et al. Long-term cognitive function, neuroimaging, and quality of life in primary CNS lymphoma. Neurology 2013;81:84-92. Available at: https://www.ncbi.nlm.nih.gov/pubmed/23685932.

388. Schellinger KA, Propp JM, Villano JL, McCarthy BJ. Descriptive epidemiology of primary spinal cord tumors. J Neurooncol 2008;87:173-179. Available at: http://www.ncbi.nlm.nih.gov/pubmed/18084720.

389. Grimm S, Chamberlain MC. Adult primary spinal cord tumors. Expert Rev Neurother 2009;9:1487-1495. Available at: http://www.ncbi.nlm.nih.gov/pubmed/19831838.

390. Gezen F, Kahraman S, Canakci Z, Beduk A. Review of 36 cases of spinal cord meningioma. Spine (Phila Pa 1976) 2000;25:727-731. Available at: http://www.ncbi.nlm.nih.gov/pubmed/10752106.

391. Solero CL, Fornari M, Giombini S, et al. Spinal meningiomas: review of 174 operated cases. Neurosurgery 1989;25:153-160. Available at: http://www.ncbi.nlm.nih.gov/pubmed/2671779.

392. Volpp PB, Han K, Kagan AR, Tome M. Outcomes in treatment for intradural spinal cord ependymomas. Int J Radiat Oncol Biol Phys 2007;69:1199-1204. Available at: http://www.ncbi.nlm.nih.gov/pubmed/17689025.

393. Yang S, Yang X, Hong G. Surgical treatment of one hundred seventy-four intramedullary spinal cord tumors. Spine (Phila Pa 1976) 2009;34:2705-2710. Available at: http://www.ncbi.nlm.nih.gov/pubmed/19910775.

394. Raco A, Esposito V, Lenzi J, et al. Long-term follow-up of intramedullary spinal cord tumors: a series of 202 cases. Neurosurgery 2005;56:972-981; discussion 972-981. Available at: http://www.ncbi.nlm.nih.gov/pubmed/15854245.

395. Benes V, 3rd, Barsa P, Benes V, Jr., Suchomel P. Prognostic factors in intramedullary astrocytomas: a literature review. Eur Spine J 2009;18:1397-1422. Available at: http://www.ncbi.nlm.nih.gov/pubmed/19562388.

396. Milano MT, Johnson MD, Sul J, et al. Primary spinal cord glioma: a Surveillance, Epidemiology, and End Results database study. J Neurooncol 2010;98:83-92. Available at: http://www.ncbi.nlm.nih.gov/pubmed/19898743.

397. Sgouros S, Malluci CL, Jackowski A. Spinal ependymomas--the value of postoperative radiotherapy for residual disease control. Br J Neurosurg 1996;10:559-566. Available at: http://www.ncbi.nlm.nih.gov/pubmed/9115651.

Discussion update in progress

Version 3.2025 © 2025 National Comprehensive Cancer Network© (NCCN©), All rights reserved. NCCN Guidelines® and this illustration may not be reproduced in any form without the express written permission of NCCN.

PLEASE NOTE that use of this NCCN Content is governed by the End-User License Agreement, and you MAY NOT distribute this Content or use it with any artificial intelligence model or tool.
Printed by A. S. M. FAZLUL KARIM CHOWDHURY on 4/20/2026 3:06:38 AM. Copyright © 2026 National Comprehensive Cancer Network, Inc. All Rights Reserved.

398. Lee TT, Gromelski EB, Green BA. Surgical treatment of spinal ependymoma and post-operative radiotherapy. Acta Neurochir (Wien) 1998;140:309-313. Available at: http://www.ncbi.nlm.nih.gov/pubmed/9689321.

399. Akyurek S, Chang EL, Yu TK, et al. Spinal myxopapillary ependymoma outcomes in patients treated with surgery and radiotherapy at M.D. Anderson Cancer Center. J Neurooncol 2006;80:177-183. Available at: http://www.ncbi.nlm.nih.gov/pubmed/16648988.

400. Pica A, Miller R, Villa S, et al. The results of surgery, with or without radiotherapy, for primary spinal myxopapillary ependymoma: a retrospective study from the rare cancer network. Int J Radiat Oncol Biol Phys 2009;74:1114-1120. Available at: http://www.ncbi.nlm.nih.gov/pubmed/19250760.

401. Ryu SI, Kim DH, Chang SD. Stereotactic radiosurgery for hemangiomas and ependymomas of the spinal cord. Neurosurg Focus 2003;15:E10. Available at: http://www.ncbi.nlm.nih.gov/pubmed/15323467.

402. Gerszten PC, Burton SA, Ozhasoglu C, et al. Radiosurgery for benign intradural spinal tumors. Neurosurgery 2008;62:887-895; discussion 895-886. Available at: http://www.ncbi.nlm.nih.gov/pubmed/18496194.

403. Dodd RL, Ryu MR, Kamnerdsupaphon P, et al. CyberKnife radiosurgery for benign intradural extramedullary spinal tumors. Neurosurgery 2006;58:674-685; discussion 674-685. Available at: http://www.ncbi.nlm.nih.gov/pubmed/16575331.

404. Daly ME, Choi CY, Gibbs IC, et al. Tolerance of the spinal cord to stereotactic radiosurgery: insights from hemangioblastomas. Int J Radiat Oncol Biol Phys 2011;80:213-220. Available at: https://www.ncbi.nlm.nih.gov/pubmed/21481724.

405. Jonasch E, Donskov F, Iliopoulos O, et al. Belzutifan for renal cell carcinoma in von Hippel-Lindau disease. N Engl J Med 2021;385:2036-2046. Available at: https://www.ncbi.nlm.nih.gov/pubmed/34818478.

406. Garces-Ambrossi GL, McGirt MJ, Mehta VA, et al. Factors associated with progression-free survival and long-term neurological outcome after resection of intramedullary spinal cord tumors: analysis of 101 consecutive cases. J Neurosurg Spine 2009;11:591-599. Available at: http://www.ncbi.nlm.nih.gov/pubmed/19929363.

407. Alliance TV. The VHL Handbook: What You Need to Know About VHL (ed 5th ed.). Boston, MA: VHL Alliance; 2015.

408. Surawicz TS, McCarthy BJ, Kupelian V, et al. Descriptive epidemiology of primary brain and CNS tumors: results from the Central Brain Tumor Registry of the United States, 1990-1994. Neuro Oncol 1999;1:14-25. Available at: http://www.ncbi.nlm.nih.gov/pubmed/11554386.

409. Mahmood A, Caccamo DV, Tomecek FJ, Malik GM. Atypical and malignant meningiomas: a clinicopathological review. Neurosurgery 1993;33:955-963. Available at: http://www.ncbi.nlm.nih.gov/pubmed/8134008.

410. Vernooij MW, Ikram MA, Tanghe HL, et al. Incidental findings on brain MRI in the general population. N Engl J Med 2007;357:1821-1828. Available at: http://www.ncbi.nlm.nih.gov/pubmed/17978290.

411. Lieu AS, Howng SL. Intracranial meningiomas and epilepsy: incidence, prognosis and influencing factors. Epilepsy Res 2000;38:45-52. Available at: http://www.ncbi.nlm.nih.gov/pubmed/10604605.

412. Campbell BA, Jhamb A, Maguire JA, et al. Meningiomas in 2009: controversies and future challenges. Am J Clin Oncol 2009;32:73-85. Available at: http://www.ncbi.nlm.nih.gov/pubmed/19194129.

413. Nathoo N, Ugokwe K, Chang AS, et al. The role of 111indium-octreotide brain scintigraphy in the diagnosis of cranial, dural-based meningiomas. J Neurooncol 2007;81:167-174. Available at: http://www.ncbi.nlm.nih.gov/pubmed/16850106.

414. Nyuyki F, Plotkin M, Graf R, et al. Potential impact of (68)Ga-DOTATOC PET/CT on stereotactic radiotherapy planning of meningiomas.

Discussion update in progress

Version 3.2025 © 2025 National Comprehensive Cancer Network© (NCCN©), All rights reserved. NCCN Guidelines® and this illustration may not be reproduced in any form without the express written permission of NCCN.

PLEASE NOTE that use of this NCCN Content is governed by the End-User License Agreement, and you MAY NOT distribute this Content or use it with any artificial intelligence model or tool.
Printed by A. S. M. FAZLUL KARIM CHOWDHURY on 4/20/2026 3:06:38 AM. Copyright © 2026 National Comprehensive Cancer Network, Inc. All Rights Reserved.

Eur J Nucl Med Mol Imaging 2010;37:310-318. Available at: http://www.ncbi.nlm.nih.gov/pubmed/19763565.

415. Gehler B, Paulsen F, Oksuz MO, et al. [68Ga]-DOTATOC-PET/CT for meningioma IMRT treatment planning. Radiat Oncol 2009;4:56. Available at: http://www.ncbi.nlm.nih.gov/pubmed/19922642.

416. Nakamura M, Roser F, Michel J, et al. The natural history of incidental meningiomas. Neurosurgery 2003;53:62-70; discussion 70-61. Available at: http://www.ncbi.nlm.nih.gov/pubmed/12823874.

417. Olivero WC, Lister JR, Elwood PW. The natural history and growth rate of asymptomatic meningiomas: a review of 60 patients. J Neurosurg 1995;83:222-224. Available at: http://www.ncbi.nlm.nih.gov/pubmed/7616265.

418. Stafford SL, Perry A, Suman VJ, et al. Primarily resected meningiomas: outcome and prognostic factors in 581 Mayo Clinic patients, 1978 through 1988. Mayo Clin Proc 1998;73:936-942. Available at: http://www.ncbi.nlm.nih.gov/pubmed/9787740.

419. Mahmood A, Qureshi NH, Malik GM. Intracranial meningiomas: analysis of recurrence after surgical treatment. Acta Neurochir (Wien) 1994;126:53-58. Available at: http://www.ncbi.nlm.nih.gov/pubmed/8042555.

420. Mathiesen T, Lindquist C, Kihlstrom L, Karlsson B. Recurrence of cranial base meningiomas. Neurosurgery 1996;39:2-7; discussion 8-9. Available at: http://www.ncbi.nlm.nih.gov/pubmed/8805134.

421. Perry A, Stafford SL, Scheithauer BW, et al. Meningioma grading: an analysis of histologic parameters. Am J Surg Pathol 1997;21:1455-1465. Available at: http://www.ncbi.nlm.nih.gov/pubmed/9414189.

422. Simpson D. The recurrence of intracranial meningiomas after surgical treatment. J Neurol Neurosurg Psychiatry 1957;20:22-39. Available at: http://www.ncbi.nlm.nih.gov/pubmed/13406590.

423. Condra KS, Buatti JM, Mendenhall WM, et al. Benign meningiomas: primary treatment selection affects survival. Int J Radiat Oncol Biol Phys 1997;39:427-436. Available at: http://www.ncbi.nlm.nih.gov/pubmed/9308947.

424. Soyuer S, Chang EL, Selek U, et al. Radiotherapy after surgery for benign cerebral meningioma. Radiother Oncol 2004;71:85-90. Available at: http://www.ncbi.nlm.nih.gov/pubmed/15066300.

425. Pirzkall A, Debus J, Haering P, et al. Intensity modulated radiotherapy (IMRT) for recurrent, residual, or untreated skull-base meningiomas: preliminary clinical experience. Int J Radiat Oncol Biol Phys 2003;55:362-372. Available at: https://www.ncbi.nlm.nih.gov/pubmed/12527049.

426. Aghi MK, Carter BS, Cosgrove GR, et al. Long-term recurrence rates of atypical meningiomas after gross total resection with or without postoperative adjuvant radiation. Neurosurgery 2009;64:56-60; discussion 60. Available at: http://www.ncbi.nlm.nih.gov/pubmed/19145156.

427. Hug EB, Devries A, Thornton AF, et al. Management of atypical and malignant meningiomas: role of high-dose, 3D-conformal radiation therapy. J Neurooncol 2000;48:151-160. Available at: http://www.ncbi.nlm.nih.gov/pubmed/11083080.

428. Rogers CL, Won M, Vogelbaum MA, et al. High-risk meningioma: initial outcomes from NRG Oncology/RTOG 0539. Int J Radiat Oncol Biol Phys 2020;106:790-799. Available at: https://www.ncbi.nlm.nih.gov/pubmed/31786276.

429. Selch MT, Ahn E, Laskari A, et al. Stereotactic radiotherapy for treatment of cavernous sinus meningiomas. Int J Radiat Oncol Biol Phys 2004;59:101-111. Available at: https://www.ncbi.nlm.nih.gov/pubmed/15093905.

430. Pollock BE, Stafford SL, Utter A, et al. Stereotactic radiosurgery provides equivalent tumor control to Simpson Grade 1 resection for patients with small- to medium-size meningiomas. Int J Radiat Oncol Biol

Discussion update in progress

Version 3.2025 © 2025 National Comprehensive Cancer Network© (NCCN©), All rights reserved. NCCN Guidelines® and this illustration may not be reproduced in any form without the express written permission of NCCN.

PLEASE NOTE that use of this NCCN Content is governed by the End-User License Agreement, and you MAY NOT distribute this Content or use it with any artificial intelligence model or tool.
Printed by A. S. M. FAZLUL KARIM CHOWDHURY on 4/20/2026 3:06:38 AM. Copyright © 2026 National Comprehensive Cancer Network, Inc. All Rights Reserved.

Phys 2003;55:1000-1005. Available at: http://www.ncbi.nlm.nih.gov/pubmed/12605979.

431. Kondziolka D, Mathieu D, Lunsford LD, et al. Radiosurgery as definitive management of intracranial meningiomas. Neurosurgery 2008;62:53-58; discussion 58-60. Available at: http://www.ncbi.nlm.nih.gov/pubmed/18300891.

432. Compter I, Zaugg K, Houben RM, et al. High symptom improvement and local tumor control using stereotactic radiotherapy when given early after diagnosis of meningioma. A multicentre study. Strahlenther Onkol 2012;188:887-893. Available at: http://www.ncbi.nlm.nih.gov/pubmed/22961046.

433. Debus J, Wuendrich M, Pirzkall A, et al. High efficacy of fractionated stereotactic radiotherapy of large base-of-skull meningiomas: long-term results. J Clin Oncol 2001;19:3547-3553. Available at: http://www.ncbi.nlm.nih.gov/pubmed/11481362.

434. Kowalchuk RO, Shepard MJ, Sheehan K, et al. Treatment of WHO grade 2 meningiomas with stereotactic radiosurgery: identification of an optimal group for SRS using RPA. Int J Radiat Oncol Biol Phys 2021;110:804-814. Available at: https://www.ncbi.nlm.nih.gov/pubmed/33548341.

435. Momin AA, Shao J, Soni P, et al. Outcomes of salvage radiation for recurrent world health organization grade II meningiomas: a retrospective cohort study. J Neurooncol 2021;152:373-382. Available at: https://www.ncbi.nlm.nih.gov/pubmed/33590402.

436. Kaley T, Barani I, Chamberlain M, et al. Historical benchmarks for medical therapy trials in surgery- and radiation-refractory meningioma: a RANO review. Neuro Oncol 2014;16:829-840. Available at: https://www.ncbi.nlm.nih.gov/pubmed/24500419.

437. Chamberlain MC, Glantz MJ, Fadul CE. Recurrent meningioma: salvage therapy with long-acting somatostatin analogue. Neurology 2007;69:969-973. Available at: http://www.ncbi.nlm.nih.gov/pubmed/17785665.

438. Johnson DR, Kimmel DW, Burch PA, et al. Phase II study of subcutaneous octreotide in adults with recurrent or progressive meningioma and meningeal hemangiopericytoma. Neuro Oncol 2011;13:530-535. Available at: http://www.ncbi.nlm.nih.gov/pubmed/21558077.

439. Kaley TJ, Wen P, Schiff D, et al. Phase II trial of sunitinib for recurrent and progressive atypical and anaplastic meningioma. Neuro Oncol 2015;17:116-121. Available at: http://www.ncbi.nlm.nih.gov/pubmed/25100872.

440. Lou E, Sumrall AL, Turner S, et al. Bevacizumab therapy for adults with recurrent/progressive meningioma: a retrospective series. J Neurooncol 2012;109:63-70. Available at: https://www.ncbi.nlm.nih.gov/pubmed/22535433.

441. Nayak L, Iwamoto FM, Rudnick JD, et al. Atypical and anaplastic meningiomas treated with bevacizumab. J Neurooncol 2012;109:187-193. Available at: https://www.ncbi.nlm.nih.gov/pubmed/22544653.

442. Shih KC, Chowdhary S, Rosenblatt P, et al. A phase II trial of bevacizumab and everolimus as treatment for patients with refractory, progressive intracranial meningioma. J Neurooncol 2016;129:281-288. Available at: https://www.ncbi.nlm.nih.gov/pubmed/27311730.

443. Barnholtz-Sloan JS, Sloan AE, Davis FG, et al. Incidence proportions of brain metastases in patients diagnosed (1973 to 2001) in the Metropolitan Detroit Cancer Surveillance System. J Clin Oncol 2004;22:2865-2872. Available at: http://www.ncbi.nlm.nih.gov/pubmed/15254054.

444. Schouten LJ, Rutten J, Huveneers HA, Twijnstra A. Incidence of brain metastases in a cohort of patients with carcinoma of the breast, colon, kidney, and lung and melanoma. Cancer 2002;94:2698-2705. Available at: http://www.ncbi.nlm.nih.gov/pubmed/12173339.

445. Fox BD, Cheung VJ, Patel AJ, et al. Epidemiology of metastatic brain tumors. Neurosurg Clin N Am 2011;22:1-6, v. Available at: https://www.ncbi.nlm.nih.gov/pubmed/21109143.

Discussion update in progress

Version 3.2025 © 2025 National Comprehensive Cancer Network© (NCCN©), All rights reserved. NCCN Guidelines® and this illustration may not be reproduced in any form without the express written permission of NCCN.

PLEASE NOTE that use of this NCCN Content is governed by the End-User License Agreement, and you MAY NOT distribute this Content or use it with any artificial intelligence model or tool.
Printed by A. S. M. FAZLUL KARIM CHOWDHURY on 4/20/2026 3:06:38 AM. Copyright © 2026 National Comprehensive Cancer Network, Inc. All Rights Reserved.

446. Gould J. Breaking down the epidemiology of brain cancer. Nature 2018;561:S40-S41. Available at: https://www.ncbi.nlm.nih.gov/pubmed/30258156.

447. Maher EA, Mietz J, Arteaga CL, et al. Brain metastasis: opportunities in basic and translational research. Cancer Res 2009;69:6015-6020. Available at: https://www.ncbi.nlm.nih.gov/pubmed/19638593.

448. Cagney DN, Martin AM, Catalano PJ, et al. Incidence and prognosis of patients with brain metastases at diagnosis of systemic malignancy: a population-based study. Neuro Oncol 2017;19:1511-1521. Available at: https://www.ncbi.nlm.nih.gov/pubmed/28444227.

449. Lin NU, Bellon JR, Winer EP. CNS metastases in breast cancer. J Clin Oncol 2004;22:3608-3617. Available at: http://www.ncbi.nlm.nih.gov/pubmed/15337811.

450. Eichler AF, Loeffler JS. Multidisciplinary management of brain metastases. Oncologist 2007;12:884-898. Available at: http://www.ncbi.nlm.nih.gov/pubmed/17673619.

451. Mahajan A, Ahmed S, McAleer MF, et al. Post-operative stereotactic radiosurgery versus observation for completely resected brain metastases: a single-centre, randomised, controlled, phase 3 trial. Lancet Oncol 2017;18:1040-1048. Available at: https://www.ncbi.nlm.nih.gov/pubmed/28687375.

452. Churilla TM, Chowdhury IH, Handorf E, et al. Comparison of local control of brain metastases with stereotactic radiosurgery vs surgical resection: a secondary analysis of a randomized clinical trial. JAMA Oncol 2019;5:243-247. Available at: https://www.ncbi.nlm.nih.gov/pubmed/30419088.

453. Ewend MG, Morris DE, Carey LA, et al. Guidelines for the initial management of metastatic brain tumors: role of surgery, radiosurgery, and radiation therapy. J Natl Compr Canc Netw 2008;6:505-513; quiz 514. Available at: https://www.ncbi.nlm.nih.gov/pubmed/18492462.

454. Patchell RA, Tibbs PA, Walsh JW, et al. A randomized trial of surgery in the treatment of single metastases to the brain. N Engl J Med 1990;322:494-500. Available at: http://www.ncbi.nlm.nih.gov/pubmed/2405271.

455. Vecht CJ, Haaxma-Reiche H, Noordijk EM, et al. Treatment of single brain metastasis: radiotherapy alone or combined with neurosurgery? Ann Neurol 1993;33:583-590. Available at: http://www.ncbi.nlm.nih.gov/pubmed/8498838.

456. Mintz AH, Kestle J, Rathbone MP, et al. A randomized trial to assess the efficacy of surgery in addition to radiotherapy in patients with a single cerebral metastasis. Cancer 1996;78:1470-1476. Available at: http://www.ncbi.nlm.nih.gov/pubmed/8839553.

457. Ahluwalia M, Barnett GH, Deng D, et al. Laser ablation after stereotactic radiosurgery: a multicenter prospective study in patients with metastatic brain tumors and radiation necrosis. J Neurosurg 2018;130:804-811. Available at: https://www.ncbi.nlm.nih.gov/pubmed/29726782.

458. Bastos DCA, Rao G, Oliva ICG, et al. Predictors of local control of brain metastasis treated with laser interstitial thermal therapy. Neurosurgery 2020;87:112-122. Available at: https://www.ncbi.nlm.nih.gov/pubmed/31539421.

459. Kim AH, Tatter S, Rao G, et al. Laser ablation of abnormal neurological tissue using robotic NeuroBlate system (LAANTERN): 12-month outcomes and quality of life after brain tumor ablation. Neurosurgery 2020;87:E338-E346. Available at: https://www.ncbi.nlm.nih.gov/pubmed/32315434.

460. Shah AH, Semonche A, Eichberg DG, et al. The role of laser interstitial thermal therapy in surgical neuro-oncology: series of 100 consecutive patients. Neurosurgery 2020;87:266-275. Available at: https://www.ncbi.nlm.nih.gov/pubmed/31742351.

461. Sujijantarat N, Hong CS, Owusu KA, et al. Laser interstitial thermal therapy (LITT) vs. bevacizumab for radiation necrosis in previously

Discussion update in progress

Version 3.2025 © 2025 National Comprehensive Cancer Network© (NCCN©), All rights reserved. NCCN Guidelines® and this illustration may not be reproduced in any form without the express written permission of NCCN.

PLEASE NOTE that use of this NCCN Content is governed by the End-User License Agreement, and you MAY NOT distribute this Content or use it with any artificial intelligence model or tool.
Printed by A. S. M. FAZLUL KARIM CHOWDHURY on 4/20/2026 3:06:38 AM. Copyright © 2026 National Comprehensive Cancer Network, Inc. All Rights Reserved.

irradiated brain metastases. J Neurooncol 2020;148:641-649. Available at: https://www.ncbi.nlm.nih.gov/pubmed/32602021.

462. Suh JH. Stereotactic radiosurgery for the management of brain metastases. N Engl J Med 2010;362:1119-1127. Available at: http://www.ncbi.nlm.nih.gov/pubmed/20335588.

463. Aoyama H, Shirato H, Tago M, et al. Stereotactic radiosurgery plus whole-brain radiation therapy vs stereotactic radiosurgery alone for treatment of brain metastases: a randomized controlled trial. JAMA 2006;295:2483-2491. Available at: http://www.ncbi.nlm.nih.gov/pubmed/16757720.

464. Brown PD, Jaeckle K, Ballman KV, et al. Effect of radiosurgery alone vs radiosurgery with whole brain radiation therapy on cognitive function in patients with 1 to 3 brain metastases: a randomized clinical trial. JAMA 2016;316:401-409. Available at: https://www.ncbi.nlm.nih.gov/pubmed/27458945.

465. Chang EL, Wefel JS, Hess KR, et al. Neurocognition in patients with brain metastases treated with radiosurgery or radiosurgery plus whole-brain irradiation: a randomised controlled trial. Lancet Oncol 2009;10:1037-1044. Available at: http://www.ncbi.nlm.nih.gov/pubmed/19801201.

466. Kocher M, Soffietti R, Abacioglu U, et al. Adjuvant whole-brain radiotherapy versus observation after radiosurgery or surgical resection of one to three cerebral metastases: results of the EORTC 22952-26001 study. J Clin Oncol 2011;29:134-141. Available at: http://www.ncbi.nlm.nih.gov/pubmed/21041710.

467. Yamamoto M, Serizawa T, Shuto T, et al. Stereotactic radiosurgery for patients with multiple brain metastases (JLGK0901): a multi-institutional prospective observational study. Lancet Oncol 2014;15:387-395. Available at: http://www.ncbi.nlm.nih.gov/pubmed/24621620.

468. Bhatnagar AK, Flickinger JC, Kondziolka D, Lunsford LD. Stereotactic radiosurgery for four or more intracranial metastases. Int J Radiat Oncol Biol Phys 2006;64:898-903. Available at: http://www.ncbi.nlm.nih.gov/pubmed/16338097.

469. Banfill KE, Bownes PJ, St Clair SE, et al. Stereotactic radiosurgery for the treatment of brain metastases: impact of cerebral disease burden on survival. Br J Neurosurg 2012;26:674-678. Available at: http://www.ncbi.nlm.nih.gov/pubmed/22747250.

470. Chang WS, Kim HY, Chang JW, et al. Analysis of radiosurgical results in patients with brain metastases according to the number of brain lesions: is stereotactic radiosurgery effective for multiple brain metastases? J Neurosurg 2010;113 Suppl:73-78. Available at: http://www.ncbi.nlm.nih.gov/pubmed/21121789.

471. Farris M, McTyre ER, Cramer CK, et al. Brain metastasis velocity: a novel prognostic metric predictive of overall survival and freedom from whole-brain radiation therapy after distant brain failure following upfront radiosurgery alone. Int J Radiat Oncol Biol Phys 2017;98:131-141. Available at: https://www.ncbi.nlm.nih.gov/pubmed/28586952.

472. Karlsson B, Hanssens P, Wolff R, et al. Thirty years' experience with Gamma Knife surgery for metastases to the brain. J Neurosurg 2009;111:449-457. Available at: http://www.ncbi.nlm.nih.gov/pubmed/19199505.

473. Kased N, Binder DK, McDermott MW, et al. Gamma Knife radiosurgery for brain metastases from primary breast cancer. Int J Radiat Oncol Biol Phys 2009;75:1132-1140. Available at: http://www.ncbi.nlm.nih.gov/pubmed/19345514.

474. Rusthoven CG, Yamamoto M, Bernhardt D, et al. Evaluation of first-line radiosurgery vs whole-brain radiotherapy for small cell lung cancer brain metastases: the FIRE-SCLC Cohort Study. JAMA Oncol 2020;6:1028-1037. Available at: https://www.ncbi.nlm.nih.gov/pubmed/32496550.

475. Gaebe K, Li AY, Park A, et al. Stereotactic radiosurgery versus whole brain radiotherapy in patients with intracranial metastatic disease and small-cell lung cancer: a systematic review and meta-analysis. Lancet

Discussion update in progress

Version 3.2025 © 2025 National Comprehensive Cancer Network© (NCCN©), All rights reserved. NCCN Guidelines® and this illustration may not be reproduced in any form without the express written permission of NCCN.

PLEASE NOTE that use of this NCCN Content is governed by the End-User License Agreement, and you MAY NOT distribute this Content or use it with any artificial intelligence model or tool.
Printed by A. S. M. FAZLUL KARIM CHOWDHURY on 4/20/2026 3:06:38 AM. Copyright © 2026 National Comprehensive Cancer Network, Inc. All Rights Reserved.

Oncol 2022;23:931-939. Available at: https://www.ncbi.nlm.nih.gov/pubmed/35644163.

476. Hanson PW, Elaimy AL, Lamoreaux WT, et al. A concise review of the efficacy of stereotactic radiosurgery in the management of melanoma and renal cell carcinoma brain metastases. World J Surg Oncol 2012;10:176. Available at: http://www.ncbi.nlm.nih.gov/pubmed/22931379.

477. Hunter GK, Suh JH, Reuther AM, et al. Treatment of five or more brain metastases with stereotactic radiosurgery. Int J Radiat Oncol Biol Phys 2012;83:1394-1398. Available at: http://www.ncbi.nlm.nih.gov/pubmed/22209150.

478. Minniti G, Esposito V, Clarke E, et al. Stereotactic radiosurgery in elderly patients with brain metastases. J Neurooncol 2013;111:319-325. Available at: https://www.ncbi.nlm.nih.gov/pubmed/23187817.

479. Higuchi Y, Yamamoto M, Serizawa T, et al. Stereotactic radiosurgery in elderly patients with brain metastases: comparison with non-elderly patients using database of a multi-institutional prospective observational study (JLGK0901-Elderly). J Neurooncol 2019;144:393-402. Available at: https://www.ncbi.nlm.nih.gov/pubmed/31338786.

480. Raman S, Mou B, Hsu F, et al. Whole brain radiotherapy versus stereotactic radiosurgery in poor-prognosis patients with one to 10 brain metastases: a randomised feasibility study. Clin Oncol (R Coll Radiol) 2020;32:442-451. Available at: https://www.ncbi.nlm.nih.gov/pubmed/32085923.

481. Chen L, Shen C, Redmond KJ, et al. Use of stereotactic radiosurgery in elderly and very elderly patients with brain metastases to limit toxicity associated with whole brain radiation therapy. Int J Radiat Oncol Biol Phys 2017;98:939-947. Available at: https://www.ncbi.nlm.nih.gov/pubmed/28602418.

482. Chen WC, Baal UH, Baal JD, et al. Efficacy and safety of stereotactic radiosurgery for brainstem metastases: a systematic review and meta-analysis. JAMA Oncol 2021;7:1033-1040. Available at: https://www.ncbi.nlm.nih.gov/pubmed/33983393.

483. Shaw E, Scott C, Souhami L, et al. Single dose radiosurgical treatment of recurrent previously irradiated primary brain tumors and brain metastases: final report of RTOG protocol 90-05. Int J Radiat Oncol Biol Phys 2000;47:291-298. Available at: http://www.ncbi.nlm.nih.gov/pubmed/10802351.

484. Redmond KJ, Gui C, Benedict S, et al. Tumor control probability of radiosurgery and fractionated stereotactic radiosurgery for brain metastases. Int J Radiat Oncol Biol Phys 2021;110:53-67. Available at: https://www.ncbi.nlm.nih.gov/pubmed/33390244.

485. Wiggenraad R, Verbeek-de Kanter A, Kal HB, et al. Dose-effect relation in stereotactic radiotherapy for brain metastases. A systematic review. Radiother Oncol 2011;98:292-297. Available at: https://www.ncbi.nlm.nih.gov/pubmed/21316787.

486. Minniti G, Scaringi C, Paolini S, et al. Single-fraction versus multifraction (3 x 9 Gy) stereotactic radiosurgery for large (>2 cm) brain metastases: a comparative analysis of local control and risk of radiation-induced brain necrosis. Int J Radiat Oncol Biol Phys 2016;95:1142-1148. Available at: https://www.ncbi.nlm.nih.gov/pubmed/27209508.

487. Al-Omair A, Soliman H, Xu W, et al. Hypofractionated stereotactic radiotherapy in five daily fractions for post-operative surgical cavities in brain metastases patients with and without prior whole brain radiation. Technol Cancer Res Treat 2013;12:493-499. Available at: https://www.ncbi.nlm.nih.gov/pubmed/23617283.

488. Soltys SG, Seiger K, Modlin LA, et al. A phase I/II dose-escalation trial of 3-fraction stereotactic radiosurgery (SRS) for large resection cavities of brain metastases. Int J Radiat Oncol Biol Phys 2015;93:S38. Available at: https://doi.org/10.1016/j.ijrobp.2015.07.093.

489. Akyurek S, Chang EL, Mahajan A, et al. Stereotactic radiosurgical treatment of cerebral metastases arising from breast cancer. Am J Clin Oncol 2007;30:310-314. Available at: http://www.ncbi.nlm.nih.gov/pubmed/17551311.

Discussion update in progress

Version 3.2025 © 2025 National Comprehensive Cancer Network© (NCCN©), All rights reserved. NCCN Guidelines® and this illustration may not be reproduced in any form without the express written permission of NCCN.

PLEASE NOTE that use of this NCCN Content is governed by the End-User License Agreement, and you MAY NOT distribute this Content or use it with any artificial intelligence model or tool.
Printed by A. S. M. FAZLUL KARIM CHOWDHURY on 4/20/2026 3:06:38 AM. Copyright © 2026 National Comprehensive Cancer Network, Inc. All Rights Reserved.

490. Noel G, Proudhom MA, Valery CA, et al. Radiosurgery for re-irradiation of brain metastasis: results in 54 patients. Radiother Oncol 2001;60:61-67. Available at: http://www.ncbi.nlm.nih.gov/pubmed/11410305.

491. Sheehan J, Kondziolka D, Flickinger J, Lunsford LD. Radiosurgery for patients with recurrent small cell lung carcinoma metastatic to the brain: outcomes and prognostic factors. J Neurosurg 2005;102 Suppl:247-254. Available at: http://www.ncbi.nlm.nih.gov/pubmed/15662819.

492. Caballero JA, Sneed PK, Lamborn KR, et al. Prognostic factors for survival in patients treated with stereotactic radiosurgery for recurrent brain metastases after prior whole brain radiotherapy. Int J Radiat Oncol Biol Phys 2012;83:303-309. Available at: http://www.ncbi.nlm.nih.gov/pubmed/22079723.

493. Brown PD, Ballman KV, Cerhan JH, et al. Postoperative stereotactic radiosurgery compared with whole brain radiotherapy for resected metastatic brain disease (NCCTG N107C/CEC.3): a multicentre, randomised, controlled, phase 3 trial. Lancet Oncol 2017;18:1049-1060. Available at: https://www.ncbi.nlm.nih.gov/pubmed/28687377.

494. Soliman H, Ruschin M, Angelov L, et al. Consensus contouring guidelines for postoperative completely resected cavity stereotactic radiosurgery for brain metastases. Int J Radiat Oncol Biol Phys 2018;100:436-442. Available at: https://www.ncbi.nlm.nih.gov/pubmed/29157748.

495. Brown PD, Gondi V, Pugh S, et al. Hippocampal avoidance during whole-brain radiotherapy plus memantine for patients with brain metastases: phase III trial NRG Oncology CC001. J Clin Oncol 2020;38:1019-1029. Available at: https://www.ncbi.nlm.nih.gov/pubmed/32058845.

496. Andrews DW, Scott CB, Sperduto PW, et al. Whole brain radiation therapy with or without stereotactic radiosurgery boost for patients with one to three brain metastases: phase III results of the RTOG 9508 randomised trial. Lancet 2004;363:1665-1672. Available at: http://www.ncbi.nlm.nih.gov/pubmed/15158627.

497. Tsao MN, Xu W, Wong RK, et al. Whole brain radiotherapy for the treatment of newly diagnosed multiple brain metastases. Cochrane Database Syst Rev 2018;1:CD003869. Available at: https://www.ncbi.nlm.nih.gov/pubmed/29365347.

498. Churilla TM, Handorf E, Collette S, et al. Whole brain radiotherapy after stereotactic radiosurgery or surgical resection among patients with one to three brain metastases and favorable prognoses: a secondary analysis of EORTC 22952-26001. Ann Oncol 2017;28:2588-2594. Available at: https://www.ncbi.nlm.nih.gov/pubmed/28961826.

499. Mulvenna P, Nankivell M, Barton R, et al. Dexamethasone and supportive care with or without whole brain radiotherapy in treating patients with non-small cell lung cancer with brain metastases unsuitable for resection or stereotactic radiotherapy (QUARTZ): results from a phase 3, non-inferiority, randomised trial. Lancet 2016;388:2004-2014. Available at: https://www.ncbi.nlm.nih.gov/pubmed/27604504.

500. Yomo S, Hayashi M. Is upfront stereotactic radiosurgery a rational treatment option for very elderly patients with brain metastases? A retrospective analysis of 106 consecutive patients age 80 years and older. BMC Cancer 2016;16:948. Available at: https://www.ncbi.nlm.nih.gov/pubmed/27978813.

501. Brown PD, Pugh S, Laack NN, et al. Memantine for the prevention of cognitive dysfunction in patients receiving whole-brain radiotherapy: a randomized, double-blind, placebo-controlled trial. Neuro Oncol 2013;15:1429-1437. Available at: https://www.ncbi.nlm.nih.gov/pubmed/23956241.

502. Gondi V, Pugh SL, Tome WA, et al. Preservation of memory with conformal avoidance of the hippocampal neural stem-cell compartment during whole-brain radiotherapy for brain metastases (RTOG 0933): a phase II multi-institutional trial. J Clin Oncol 2014;32:3810-3816. Available at: https://www.ncbi.nlm.nih.gov/pubmed/25349290.

503. Patchell RA, Tibbs PA, Regine WF, et al. Postoperative radiotherapy in the treatment of single metastases to the brain: a randomized trial.

Discussion update in progress

Version 3.2025 © 2025 National Comprehensive Cancer Network© (NCCN©), All rights reserved. NCCN Guidelines® and this illustration may not be reproduced in any form without the express written permission of NCCN.

PLEASE NOTE that use of this NCCN Content is governed by the End-User License Agreement, and you MAY NOT distribute this Content or use it with any artificial intelligence model or tool.
Printed by A. S. M. FAZLUL KARIM CHOWDHURY on 4/20/2026 3:06:38 AM. Copyright © 2026 National Comprehensive Cancer Network, Inc. All Rights Reserved.

JAMA 1998;280:1485-1489. Available at: http://www.ncbi.nlm.nih.gov/pubmed/9809728.

504. Soffietti R, Kocher M, Abacioglu UM, et al. A European Organisation for Research and Treatment of Cancer phase III trial of adjuvant whole-brain radiotherapy versus observation in patients with one to three brain metastases from solid tumors after surgical resection or radiosurgery: quality-of-life results. J Clin Oncol 2013;31:65-72. Available at: https://www.ncbi.nlm.nih.gov/pubmed/23213105.

505. Hong AM, Fogarty GB, Dolven-Jacobsen K, et al. Adjuvant whole-brain radiation therapy compared with observation after local treatment of melanoma brain metastases: a multicenter, randomized phase III trial. J Clin Oncol 2019;37:3132-3141. Available at: https://www.ncbi.nlm.nih.gov/pubmed/31553661.

506. Glitza Oliva IC, Schvartsman G, Tawbi H. Advances in the systemic treatment of melanoma brain metastases. Ann Oncol 2018;29:1509-1520. Available at: https://www.ncbi.nlm.nih.gov/pubmed/29790899.

507. Turajlic S, Larkin J. Immunotherapy for melanoma metastatic to the brain. N Engl J Med 2018;379:789-790. Available at: https://www.ncbi.nlm.nih.gov/pubmed/30134137.

508. Long GV, Atkinson V, Lo S, et al. Combination nivolumab and ipilimumab or nivolumab alone in melanoma brain metastases: a multicentre randomised phase 2 study. Lancet Oncol 2018;19:672-681. Available at: https://www.ncbi.nlm.nih.gov/pubmed/29602646.

509. Tawbi HA, Forsyth PA, Algazi A, et al. Combined nivolumab and ipilimumab in melanoma metastatic to the brain. N Engl J Med 2018;379:722-730. Available at: https://www.ncbi.nlm.nih.gov/pubmed/30134131.

510. Tawbi HA, Forsyth PA, Hodi FS, et al. Long-term outcomes of patients with active melanoma brain metastases treated with combination nivolumab plus ipilimumab (CheckMate 204): final results of an open-label, multicentre, phase 2 study. Lancet Oncol 2021;22:1692-1704. Available at: https://www.ncbi.nlm.nih.gov/pubmed/34774225.

511. Margolin K, Ernstoff MS, Hamid O, et al. Ipilimumab in patients with melanoma and brain metastases: an open-label, phase 2 trial. Lancet Oncol 2012;13:459-465. Available at: http://www.ncbi.nlm.nih.gov/pubmed/22456429.

512. Goldberg SB, Gettinger SN, Mahajan A, et al. Pembrolizumab for patients with melanoma or non-small-cell lung cancer and untreated brain metastases: early analysis of a non-randomised, open-label, phase 2 trial. Lancet Oncol 2016;17:976-983. Available at: https://www.ncbi.nlm.nih.gov/pubmed/27267608.

513. Kluger HM, Chiang V, Mahajan A, et al. Long-term survival of patients with melanoma with active brain metastases treated with pembrolizumab on a phase II trial. J Clin Oncol 2019;37:52-60. Available at: https://www.ncbi.nlm.nih.gov/pubmed/30407895.

514. Davies MA, Saiag P, Robert C, et al. Dabrafenib plus trametinib in patients with BRAFV600-mutant melanoma brain metastases (COMBI-MB): a multicentre, multicohort, open-label, phase 2 trial. Lancet Oncol 2017;18:863-873. Available at: https://www.ncbi.nlm.nih.gov/pubmed/28592387.

515. McArthur GA, Maio M, Arance A, et al. Vemurafenib in metastatic melanoma patients with brain metastases: an open-label, single-arm, phase 2, multicentre study. Ann Oncol 2017;28:634-641. Available at: https://www.ncbi.nlm.nih.gov/pubmed/27993793.

516. Dummer R, Goldinger SM, Turtschi CP, et al. Vemurafenib in patients with BRAF(V600) mutation-positive melanoma with symptomatic brain metastases: final results of an open-label pilot study. Eur J Cancer 2014;50:611-621. Available at: http://www.ncbi.nlm.nih.gov/pubmed/24295639.

517. Ascierto PA, McArthur GA, Dreno B, et al. Cobimetinib combined with vemurafenib in advanced BRAF(V600)-mutant melanoma (coBRIM): updated efficacy results from a randomised, double-blind, phase 3 trial. Lancet Oncol 2016;17:1248-1260. Available at: https://www.ncbi.nlm.nih.gov/pubmed/27480103.

Discussion update in progress

Version 3.2025 © 2025 National Comprehensive Cancer Network© (NCCN©), All rights reserved. NCCN Guidelines® and this illustration may not be reproduced in any form without the express written permission of NCCN.

PLEASE NOTE that use of this NCCN Content is governed by the End-User License Agreement, and you MAY NOT distribute this Content or use it with any artificial intelligence model or tool.
Printed by A. S. M. FAZLUL KARIM CHOWDHURY on 4/20/2026 3:06:38 AM. Copyright © 2026 National Comprehensive Cancer Network, Inc. All Rights Reserved.

518. Larkin J, Ascierto PA, Dreno B, et al. Combined vemurafenib and cobimetinib in BRAF-mutated melanoma. N Engl J Med 2014;371:1867-1876. Available at: http://www.ncbi.nlm.nih.gov/pubmed/25265494.

519. Holbrook K, Lutzky J, Davies MA, et al. Intracranial antitumor activity with encorafenib plus binimetinib in patients with melanoma brain metastases: a case series. Cancer 2020;126:523-530. Available at: https://www.ncbi.nlm.nih.gov/pubmed/31658370.

520. Rizvi NA, Mazieres J, Planchard D, et al. Activity and safety of nivolumab, an anti-PD-1 immune checkpoint inhibitor, for patients with advanced, refractory squamous non-small-cell lung cancer (CheckMate 063): a phase 2, single-arm trial. Lancet Oncol 2015;16:257-265. Available at: https://www.ncbi.nlm.nih.gov/pubmed/25704439.

521. Brahmer J, Reckamp KL, Baas P, et al. Nivolumab versus docetaxel in advanced squamous-cell non-small-cell lung cancer. N Engl J Med 2015;373:123-135. Available at: http://www.ncbi.nlm.nih.gov/pubmed/26028407.

522. Borghaei H, Paz-Ares L, Horn L, et al. Nivolumab versus docetaxel in advanced nonsquamous non-small-cell lung cancer. N Engl J Med 2015;373:1627-1639. Available at: http://www.ncbi.nlm.nih.gov/pubmed/26412456.

523. Goldman JW, Crino L, Vokes EE, et al. P2.36: Nivolumab (nivo) in patients (pts) with advanced (adv) NSCLC and central nervous system (CNS) metastases (mets). J Thorac Oncol 2016;11:S238-S239. Available at: https://www.jto.org/article/S1556-0864(16)30816-4/fulltext.

524. Gauvain C, Vauleon E, Chouaid C, et al. Intracerebral efficacy and tolerance of nivolumab in non-small-cell lung cancer patients with brain metastases. Lung Cancer 2018;116:62-66. Available at: https://www.ncbi.nlm.nih.gov/pubmed/29413052.

525. Rangachari D, Yamaguchi N, VanderLaan PA, et al. Brain metastases in patients with EGFR-mutated or ALK-rearranged non-small-cell lung cancers. Lung Cancer 2015;88:108-111. Available at: https://www.ncbi.nlm.nih.gov/pubmed/25682925.

526. Costa DB, Shaw AT, Ou SH, et al. Clinical experience with crizotinib in patients with advanced ALK-rearranged non-small-cell lung cancer and brain metastases. J Clin Oncol 2015;33:1881-1888. Available at: https://www.ncbi.nlm.nih.gov/pubmed/25624436.

527. Peters S, Camidge DR, Shaw AT, et al. Alectinib versus crizotinib in untreated ALK-positive non-small-cell lung cancers. N Engl J Med 2017;377:829-838. Available at: https://www.ncbi.nlm.nih.gov/pubmed/28586279.

528. Ou SI, Ahn JS, De Petris L, et al. Alectinib in crizotinib-refractory ALK-rearranged non-small-cell lung cancer: a phase II global study. J Clin Oncol 2016;34:661-668. Available at: http://www.ncbi.nlm.nih.gov/pubmed/26598747.

529. Shaw AT, Gandhi L, Gadgeel S, et al. Alectinib in ALK-positive, crizotinib-resistant, non-small-cell lung cancer: a single-group, multicentre, phase 2 trial. Lancet Oncol 2016;17:234-242. Available at: http://www.ncbi.nlm.nih.gov/pubmed/26708155.

530. Gandhi L, Ou SI, Shaw AT, et al. Efficacy of alectinib in central nervous system metastases in crizotinib-resistant ALK-positive non-small-cell lung cancer: comparison of RECIST 1.1 and RANO-HGG criteria. Eur J Cancer 2017;82:27-33. Available at: https://www.ncbi.nlm.nih.gov/pubmed/28646771.

531. Camidge DR, Kim HR, Ahn MJ, et al. Brigatinib versus crizotinib in ALK-positive non-small-cell lung cancer. N Engl J Med 2018;379:2027-2039. Available at: https://www.ncbi.nlm.nih.gov/pubmed/30280657.

532. Kim DW, Tiseo M, Ahn MJ, et al. Brigatinib in patients with crizotinib-refractory anaplastic lymphoma kinase-positive non-small-cell lung cancer: a randomized, multicenter phase II trial. J Clin Oncol 2017;35:2490-2498. Available at: https://www.ncbi.nlm.nih.gov/pubmed/28475456.

533. Kim DW, Mehra R, Tan DSW, et al. Activity and safety of ceritinib in patients with ALK-rearranged non-small-cell lung cancer (ASCEND-1): updated results from the multicentre, open-label, phase 1 trial. Lancet

Discussion update in progress

Version 3.2025 © 2025 National Comprehensive Cancer Network© (NCCN©), All rights reserved. NCCN Guidelines® and this illustration may not be reproduced in any form without the express written permission of NCCN.

PLEASE NOTE that use of this NCCN Content is governed by the End-User License Agreement, and you MAY NOT distribute this Content or use it with any artificial intelligence model or tool.
Printed by A. S. M. FAZLUL KARIM CHOWDHURY on 4/20/2026 3:06:38 AM. Copyright © 2026 National Comprehensive Cancer Network, Inc. All Rights Reserved.

Oncol 2016;17:452-463. Available at: https://www.ncbi.nlm.nih.gov/pubmed/26973324.

534. Chow LQM, Barlesi F, Bertino EM, et al. ASCEND-7: efficacy and safety of ceritinib treatment in patients with ALK-positive non-small cell lung cancer metastatic to the brain and/or leptomeninges. Clin Cancer Res 2022;28:2506-2516. Available at: https://www.ncbi.nlm.nih.gov/pubmed/35091443.

535. Bauer TM, Shaw AT, Johnson ML, et al. Brain penetration of lorlatinib: cumulative incidences of CNS and non-CNS progression with lorlatinib in patients with previously treated ALK-positive non-small-cell lung cancer. Target Oncol 2020;15:55-65. Available at: https://www.ncbi.nlm.nih.gov/pubmed/32060867.

536. Solomon BJ, Bauer TM, Ou SI, et al. Post hoc analysis of lorlatinib intracranial efficacy and safety in patients with ALK-positive advanced non-small-cell lung cancer from the phase III CROWN study. J Clin Oncol 2022:JCO2102278. Available at: https://www.ncbi.nlm.nih.gov/pubmed/35605188.

537. Ceresoli GL, Cappuzzo F, Gregorc V, et al. Gefitinib in patients with brain metastases from non-small-cell lung cancer: a prospective trial. Ann Oncol 2004;15:1042-1047. Available at: https://www.ncbi.nlm.nih.gov/pubmed/15205197.

538. Wu C, Li YL, Wang ZM, et al. Gefitinib as palliative therapy for lung adenocarcinoma metastatic to the brain. Lung Cancer 2007;57:359-364. Available at: https://www.ncbi.nlm.nih.gov/pubmed/17434236.

539. Arbour KC, Kris MG, Riely GJ, et al. Twice weekly pulse and daily continuous-dose erlotinib as initial treatment for patients with epidermal growth factor receptor-mutant lung cancers and brain metastases. Cancer 2018;124:105-109. Available at: https://www.ncbi.nlm.nih.gov/pubmed/28940498.

540. Hoffknecht P, Tufman A, Wehler T, et al. Efficacy of the irreversible ErbB family blocker afatinib in epidermal growth factor receptor (EGFR) tyrosine kinase inhibitor (TKI)-pretreated non-small-cell lung cancer patients with brain metastases or leptomeningeal disease. J Thorac Oncol 2015;10:156-163. Available at: https://www.ncbi.nlm.nih.gov/pubmed/25247337.

541. Soria JC, Ohe Y, Vansteenkiste J, et al. Osimertinib in untreated EGFR-mutated advanced non-small-cell lung cancer. N Engl J Med 2018;378:113-125. Available at: https://www.ncbi.nlm.nih.gov/pubmed/29151359.

542. Reungwetwattana T, Nakagawa K, Cho BC, et al. CNS response to osimertinib versus standard epidermal growth factor receptor tyrosine kinase inhibitors in patients with untreated EGFR-mutated advanced non-small-cell lung cancer. J Clin Oncol 2018:JCO2018783118. Available at: https://www.ncbi.nlm.nih.gov/pubmed/30153097.

543. Mok TS, Wu YL, Ahn MJ, et al. Osimertinib or platinum-pemetrexed in EGFR T790M-positive lung cancer. N Engl J Med 2017;376:629-640. Available at: https://www.ncbi.nlm.nih.gov/pubmed/27959700.

544. Wu YL, Ahn MJ, Garassino MC, et al. CNS efficacy of osimertinib in patients with T790M-positive advanced non-small-cell lung cancer: data from a randomized phase III trial (AURA3). J Clin Oncol 2018;36:2702-2709. Available at: https://www.ncbi.nlm.nih.gov/pubmed/30059262.

545. Yamaguchi H, Wakuda K, Fukuda M, et al. A phase II study of osimertinib for radiotherapy-naive central nervous system metastasis from NSCLC: results for the T790M cohort of the OCEAN study (LOGIK1603/WJOG9116L). J Thorac Oncol 2021;16:2121-2132. Available at: https://www.ncbi.nlm.nih.gov/pubmed/34419684.

546. Yang JC, Ahn MJ, Kim DW, et al. Osimertinib in pretreated T790M-positive advanced non-small-cell lung cancer: AURA study phase II extension component. J Clin Oncol 2017;35:1288-1296. Available at: https://www.ncbi.nlm.nih.gov/pubmed/28221867.

547. Goss G, Tsai CM, Shepherd FA, et al. Osimertinib for pretreated EGFR Thr790Met-positive advanced non-small-cell lung cancer (AURA2): a multicentre, open-label, single-arm, phase 2 study. Lancet Oncol

Discussion update in progress

Version 3.2025 © 2025 National Comprehensive Cancer Network© (NCCN©), All rights reserved. NCCN Guidelines® and this illustration may not be reproduced in any form without the express written permission of NCCN.

PLEASE NOTE that use of this NCCN Content is governed by the End-User License Agreement, and you MAY NOT distribute this Content or use it with any artificial intelligence model or tool.
Printed by A. S. M. FAZLUL KARIM CHOWDHURY on 4/20/2026 3:06:38 AM. Copyright © 2026 National Comprehensive Cancer Network, Inc. All Rights Reserved.

2016;17:1643-1652. Available at: https://www.ncbi.nlm.nih.gov/pubmed/27751847.

548. Goss G, Tsai CM, Shepherd FA, et al. CNS response to osimertinib in patients with T790M-positive advanced NSCLC: pooled data from two phase II trials. Ann Oncol 2018;29:687-693. Available at: https://www.ncbi.nlm.nih.gov/pubmed/29293889.

549. Awad MM, Oxnard GR, Jackman DM, et al. MET exon 14 mutations in non-small-cell lung cancer are associated with advanced age and stage-dependent MET genomic amplification and c-Met overexpression. J Clin Oncol 2016;34:721-730. Available at: https://www.ncbi.nlm.nih.gov/pubmed/26729443.

550. Frampton GM, Ali SM, Rosenzweig M, et al. Activation of MET via diverse exon 14 splicing alterations occurs in multiple tumor types and confers clinical sensitivity to MET inhibitors. Cancer Discov 2015;5:850-859. Available at: https://www.ncbi.nlm.nih.gov/pubmed/25971938.

551. Schrock AB, Frampton GM, Suh J, et al. Characterization of 298 patients with lung cancer harboring MET exon 14 skipping alterations. J Thorac Oncol 2016;11:1493-1502. Available at: https://www.ncbi.nlm.nih.gov/pubmed/27343443.

552. Wolf J, Seto T, Han JY, et al. Capmatinib in MET exon 14-mutated or MET-amplified non-small-cell lung cancer. N Engl J Med 2020;383:944-957. Available at: https://www.ncbi.nlm.nih.gov/pubmed/32877583.

553. Tsuta K, Kohno T, Yoshida A, et al. RET-rearranged non-small-cell lung carcinoma: a clinicopathological and molecular analysis. Br J Cancer 2014;110:1571-1578. Available at: https://www.ncbi.nlm.nih.gov/pubmed/24504365.

554. Wang R, Hu H, Pan Y, et al. RET fusions define a unique molecular and clinicopathologic subtype of non-small-cell lung cancer. J Clin Oncol 2012;30:4352-4359. Available at: https://www.ncbi.nlm.nih.gov/pubmed/23150706.

555. Subbiah V, Gainor JF, Oxnard GR, et al. Intracranial efficacy of selpercatinib in RET fusion-positive non-small cell lung cancers on the LIBRETTO-001 trial. Clin Cancer Res 2021;27:4160-4167. Available at: https://www.ncbi.nlm.nih.gov/pubmed/34088726.

556. Hedde JP, Neuhaus T, Schuller H, et al. A phase I/II trial of topotecan and radiation therapy for brain metastases in patients with solid tumors. Int J Radiat Oncol Biol Phys 2007;68:839-844. Available at: http://www.ncbi.nlm.nih.gov/pubmed/17379446.

557. Neuhaus T, Ko Y, Muller RP, et al. A phase III trial of topotecan and whole brain radiation therapy for patients with CNS-metastases due to lung cancer. Br J Cancer 2009;100:291-297. Available at: http://www.ncbi.nlm.nih.gov/pubmed/19127261.

558. Petrelli F, Ghidini M, Lonati V, et al. The efficacy of lapatinib and capecitabine in HER-2 positive breast cancer with brain metastases: A systematic review and pooled analysis. Eur J Cancer 2017;84:141-148. Available at: https://www.ncbi.nlm.nih.gov/pubmed/28810186.

559. Murthy RK, Loi S, Okines A, et al. Tucatinib, trastuzumab, and capecitabine for HER2-positive metastatic breast cancer. N Engl J Med 2020;382:597-609. Available at: https://www.ncbi.nlm.nih.gov/pubmed/31825569.

560. Lin NU, Borges V, Anders C, et al. Intracranial efficacy and survival with tucatinib plus trastuzumab and capecitabine for previously treated HER2-positive breast cancer with brain metastases in the HER2CLIMB trial. J Clin Oncol 2020;38:2610-2619. Available at: https://www.ncbi.nlm.nih.gov/pubmed/32468955.

561. Freedman RA, Gelman RS, Anders CK, et al. TBCRC 022: a phase II trial of neratinib and capecitabine for patients with human epidermal growth factor receptor 2-positive breast cancer and brain metastases. J Clin Oncol 2019;37:1081-1089. Available at: https://www.ncbi.nlm.nih.gov/pubmed/30860945.

562. Saura C, Oliveira M, Feng YH, et al. Neratinib plus capecitabine versus lapatinib plus capecitabine in HER2-positive metastatic breast

Discussion update in progress

Version 3.2025 © 2025 National Comprehensive Cancer Network© (NCCN©), All rights reserved. NCCN Guidelines® and this illustration may not be reproduced in any form without the express written permission of NCCN.

PLEASE NOTE that use of this NCCN Content is governed by the End-User License Agreement, and you MAY NOT distribute this Content or use it with any artificial intelligence model or tool.
Printed by A. S. M. FAZLUL KARIM CHOWDHURY on 4/20/2026 3:06:38 AM. Copyright © 2026 National Comprehensive Cancer Network, Inc. All Rights Reserved.

cancer previously treated with >/= 2 HER2-directed regimens: phase III NALA trial. J Clin Oncol 2020;38:3138-3149. Available at: https://www.ncbi.nlm.nih.gov/pubmed/32678716.

563. Hurvitz SA, Saura C, Oliveira M, et al. Efficacy of neratinib plus capecitabine in the subgroup of patients with central nervous system involvement from the NALA trial. Oncologist 2021;26:e1327-e1338. Available at: https://www.ncbi.nlm.nih.gov/pubmed/34028126.

564. Awada A, Colomer R, Inoue K, et al. Neratinib plus paclitaxel vs trastuzumab plus paclitaxel in previously untreated metastatic ERBB2-positive breast cancer: the NEfERT-T randomized clinical trial. JAMA Oncol 2016;2:1557-1564. Available at: https://www.ncbi.nlm.nih.gov/pubmed/27078022.

565. Lai R, Dang CT, Malkin MG, Abrey LE. The risk of central nervous system metastases after trastuzumab therapy in patients with breast carcinoma. Cancer 2004;101:810-816. Available at: https://www.ncbi.nlm.nih.gov/pubmed/15305414.

566. Lin NU, Pegram M, Sahebjam S, et al. Pertuzumab plus high-dose trastuzumab in patients with progressive brain metastases and HER2-positive metastatic breast cancer: primary analysis of a phase II study. J Clin Oncol 2021;39:2667-2675. Available at: https://www.ncbi.nlm.nih.gov/pubmed/33945296.

567. Montemurro F, Delaloge S, Barrios CH, et al. Trastuzumab emtansine (T-DM1) in patients with HER2-positive metastatic breast cancer and brain metastases: exploratory final analysis of cohort 1 from KAMILLA, a single-arm phase IIIb clinical trial(). Ann Oncol 2020;31:1350-1358. Available at: https://www.ncbi.nlm.nih.gov/pubmed/32634611.

568. Jerusalem GHM, Park YH, Yamashita T, et al. Trastuzumab deruxtecan (T-DXd) in patients with HER2+ metastatic breast cancer with brain metastases: a subgroup analysis of the DESTINY-Breast01 trial. J Clin Oncol 2021;39:526-526. Available at: https://ascopubs.org/doi/abs/10.1200/JCO.2021.39.15_suppl.526.

569. Cortés J, Kim S, Chung W, et al. Trastuzumab deruxtecan (T-DXd) vs trastuzumab emtansine (T-DM1) in patients (Pts) with HER2+ metastatic breast cancer (mBC): results of the randomized phase III DESTINY-Breast03 study. Ann Oncol 2021;32:S1283-S1346. Available at:

570. Rivera E, Meyers C, Groves M, et al. Phase I study of capecitabine in combination with temozolomide in the treatment of patients with brain metastases from breast carcinoma. Cancer 2006;107:1348-1354. Available at: http://www.ncbi.nlm.nih.gov/pubmed/16909414.

571. Fabi A, Vidiri A, Ferretti G, et al. Dramatic regression of multiple brain metastases from breast cancer with capecitabine: another arrow at the bow? Cancer Invest 2006;24:466-468. Available at: http://www.ncbi.nlm.nih.gov/pubmed/16777702.

572. Hikino H, Yamada T, Johbara K, et al. Potential role of chemo-radiation with oral capecitabine in a breast cancer patient with central nervous system relapse. Breast 2006;15:97-99. Available at: http://www.ncbi.nlm.nih.gov/pubmed/16005228.

573. Siegelmann-Danieli N, Stein M, Bar-Ziv J. Complete response of brain metastases originating in breast cancer to capecitabine therapy. Isr Med Assoc J 2003;5:833-834. Available at: https://www.ncbi.nlm.nih.gov/pubmed/14650117.

574. Wang ML, Yung WK, Royce ME, et al. Capecitabine for 5-fluorouracil-resistant brain metastases from breast cancer. Am J Clin Oncol 2001;24:421-424. Available at: http://www.ncbi.nlm.nih.gov/pubmed/11474279.

575. Lassman AB, Abrey LE, Shah GD, et al. Systemic high-dose intravenous methotrexate for central nervous system metastases. J Neurooncol 2006;78:255-260. Available at: http://www.ncbi.nlm.nih.gov/pubmed/16344918.

576. Vinolas N, Graus F, Mellado B, et al. Phase II trial of cisplatinum and etoposide in brain metastases of solid tumors. J Neurooncol 1997;35:145-148. Available at: https://www.ncbi.nlm.nih.gov/pubmed/9266451.

Discussion update in progress

Version 3.2025 © 2025 National Comprehensive Cancer Network© (NCCN©), All rights reserved. NCCN Guidelines® and this illustration may not be reproduced in any form without the express written permission of NCCN.

PLEASE NOTE that use of this NCCN Content is governed by the End-User License Agreement, and you MAY NOT distribute this Content or use it with any artificial intelligence model or tool.
Printed by A. S. M. FAZLUL KARIM CHOWDHURY on 4/20/2026 3:06:38 AM. Copyright © 2026 National Comprehensive Cancer Network, Inc. All Rights Reserved.

577. Franciosi V, Cocconi G, Michiara M, et al. Front-line chemotherapy with cisplatin and etoposide for patients with brain metastases from breast carcinoma, nonsmall cell lung carcinoma, or malignant melanoma: a prospective study. Cancer 1999;85:1599-1605. Available at: http://www.ncbi.nlm.nih.gov/pubmed/10193952.

578. Cocconi G, Lottici R, Bisagni G, et al. Combination therapy with platinum and etoposide of brain metastases from breast carcinoma. Cancer Invest 1990;8:327-334. Available at: http://www.ncbi.nlm.nih.gov/pubmed/2207757.

579. Graber JJ, Kesari S. Leptomeningeal metastases. Curr Treat Options Oncol 2018;19:3. Available at: https://www.ncbi.nlm.nih.gov/pubmed/29362920.

580. Waki F, Ando M, Takashima A, et al. Prognostic factors and clinical outcomes in patients with leptomeningeal metastasis from solid tumors. J Neurooncol 2009;93:205-212. Available at: http://www.ncbi.nlm.nih.gov/pubmed/19043775.

581. Lamba N, Wen PY, Aizer AA. Epidemiology of brain metastases and leptomeningeal disease. Neuro Oncol 2021;23:1447-1456. Available at: https://www.ncbi.nlm.nih.gov/pubmed/33908612.

582. Pan Z, Yang G, He H, et al. Concurrent radiotherapy and intrathecal methotrexate for treating leptomeningeal metastasis from solid tumors with adverse prognostic factors: a prospective and single-arm study. Int J Cancer 2016;139:1864-1872. Available at: https://www.ncbi.nlm.nih.gov/pubmed/27243238.

583. Wang N, Bertalan MS, Brastianos PK. Leptomeningeal metastasis from systemic cancer: review and update on management. Cancer 2018;124:21-35. Available at: https://www.ncbi.nlm.nih.gov/pubmed/29165794.

584. Liaw CC, Ng KT, Huang JS, et al. Meningeal carcinomatosis from solid tumors: clinical analysis of 42 cases. J Formos Med Assoc 1992;91:299-303. Available at: http://www.ncbi.nlm.nih.gov/pubmed/1354692.

585. Thakkar JP, Kumthekar P, Dixit KS, et al. Leptomeningeal metastasis from solid tumors. J Neurol Sci 2020;411:116706. Available at: https://www.ncbi.nlm.nih.gov/pubmed/32007755.

586. Venur VA, Chukwueke UN, Lee EQ. Advances in management of brain and leptomeningeal metastases. Curr Neurol Neurosci Rep 2020;20:26. Available at: https://www.ncbi.nlm.nih.gov/pubmed/32506161.

587. Wolf A, Donahue B, Silverman JS, et al. Stereotactic radiosurgery for focal leptomeningeal disease in patients with brain metastases. J Neurooncol 2017;134:139-143. Available at: https://www.ncbi.nlm.nih.gov/pubmed/28536993.

588. Sandberg DI, Bilsky MH, Souweidane MM, et al. Ommaya reservoirs for the treatment of leptomeningeal metastases. Neurosurgery 2000;47:49-54; discussion 54-45. Available at: http://www.ncbi.nlm.nih.gov/pubmed/10917346.

589. Fleischhack G, Jaehde U, Bode U. Pharmacokinetics following intraventricular administration of chemotherapy in patients with neoplastic meningitis. Clin Pharmacokinet 2005;44:1-31. Available at: http://www.ncbi.nlm.nih.gov/pubmed/15634030.

590. Boogerd W, van den Bent MJ, Koehler PJ, et al. The relevance of intraventricular chemotherapy for leptomeningeal metastasis in breast cancer: a randomised study. Eur J Cancer 2004;40:2726-2733. Available at: http://www.ncbi.nlm.nih.gov/pubmed/15571954.

591. Glantz MJ, Jaeckle KA, Chamberlain MC, et al. A randomized controlled trial comparing intrathecal sustained-release cytarabine (DepoCyt) to intrathecal methotrexate in patients with neoplastic meningitis from solid tumors. Clin Cancer Res 1999;5:3394-3402. Available at: http://www.ncbi.nlm.nih.gov/pubmed/10589750.

592. Grossman SA, Finkelstein DM, Ruckdeschel JC, et al. Randomized prospective comparison of intraventricular methotrexate and thiotepa in patients with previously untreated neoplastic meningitis. Eastern Cooperative Oncology Group. J Clin Oncol 1993;11:561-569. Available at: http://www.ncbi.nlm.nih.gov/pubmed/8445432.

Discussion update in progress

Version 3.2025 © 2025 National Comprehensive Cancer Network© (NCCN©), All rights reserved. NCCN Guidelines® and this illustration may not be reproduced in any form without the express written permission of NCCN.

PLEASE NOTE that use of this NCCN Content is governed by the End-User License Agreement, and you MAY NOT distribute this Content or use it with any artificial intelligence model or tool.
Printed by A. S. M. FAZLUL KARIM CHOWDHURY on 4/20/2026 3:06:38 AM. Copyright © 2026 National Comprehensive Cancer Network, Inc. All Rights Reserved.

593. Glantz MJ, LaFollette S, Jaeckle KA, et al. Randomized trial of a slow-release versus a standard formulation of cytarabine for the intrathecal treatment of lymphomatous meningitis. J Clin Oncol 1999;17:3110-3116. Available at: http://www.ncbi.nlm.nih.gov/pubmed/10506606.

594. Jaeckle KA, Phuphanich S, Bent MJ, et al. Intrathecal treatment of neoplastic meningitis due to breast cancer with a slow-release formulation of cytarabine. Br J Cancer 2001;84:157-163. Available at: http://www.ncbi.nlm.nih.gov/pubmed/11161370.

595. Gutin PH, Weiss HD, Wiernik PH, Walker MD. Intrathecal N, N', N"-triethylenethiophosphoramide [thio-TEPA (NSC 6396)] in the treatment of malignant meningeal disease: phase I-II study. Cancer 1976;38:1471-1475. Available at: https://www.ncbi.nlm.nih.gov/pubmed/825215.

596. Chamberlain MC, Johnston SK, Van Horn A, Glantz MJ. Recurrent lymphomatous meningitis treated with intra-CSF rituximab and liposomal ara-C. J Neurooncol 2009;91:271-277. Available at: http://www.ncbi.nlm.nih.gov/pubmed/18820836.

597. Groves MD, Glantz MJ, Chamberlain MC, et al. A multicenter phase II trial of intrathecal topotecan in patients with meningeal malignancies. Neuro Oncol 2008;10:208-215. Available at: http://www.ncbi.nlm.nih.gov/pubmed/18316473.

598. Jaeckle KA, Dixon JG, Anderson SK, et al. Intra-CSF topotecan in treatment of breast cancer patients with leptomeningeal metastases. Cancer Med 2020;9:7935-7942. Available at: https://www.ncbi.nlm.nih.gov/pubmed/32885617.

599. Chamberlain MC, Tsao-Wei DD, Groshen S. Phase II trial of intracerebrospinal fluid etoposide in the treatment of neoplastic meningitis. Cancer 2006;106:2021-2027. Available at: http://www.ncbi.nlm.nih.gov/pubmed/16583432.

600. Zagouri F, Sergentanis TN, Bartsch R, et al. Intrathecal administration of trastuzumab for the treatment of meningeal carcinomatosis in HER2-positive metastatic breast cancer: a systematic review and pooled analysis. Breast Cancer Res Treat 2013;139:13-22. Available at: http://www.ncbi.nlm.nih.gov/pubmed/23588955.

601. Mrugala MM, Kim B, Sharma A, et al. Phase II study of systemic high-dose methotrexate and intrathecal liposomal cytarabine for treatment of leptomeningeal carcinomatosis from breast cancer. Clin Breast Cancer 2019;19:311-316. Available at: https://www.ncbi.nlm.nih.gov/pubmed/31175053.

602. Bokstein F, Lossos A, Lossos IS, Siegal T. Central nervous system relapse of systemic non-Hodgkin's lymphoma: results of treatment based on high-dose methotrexate combination chemotherapy. Leuk Lymphoma 2002;43:587-593. Available at: http://www.ncbi.nlm.nih.gov/pubmed/12002763.

603. Grommes C, Oxnard GR, Kris MG, et al. "Pulsatile" high-dose weekly erlotinib for CNS metastases from EGFR mutant non-small cell lung cancer. Neuro Oncol 2011;13:1364-1369. Available at: http://www.ncbi.nlm.nih.gov/pubmed/21865399.

604. Yang JCH, Kim SW, Kim DW, et al. Osimertinib in patients with epidermal growth factor receptor mutation-positive non-small-cell lung cancer and leptomeningeal metastases: the BLOOM study. J Clin Oncol 2020;38:538-547. Available at: https://www.ncbi.nlm.nih.gov/pubmed/31809241.

605. Nanjo S, Hata A, Okuda C, et al. Standard-dose osimertinib for refractory leptomeningeal metastases in T790M-positive EGFR-mutant non-small cell lung cancer. Br J Cancer 2018;118:32-37. Available at: https://www.ncbi.nlm.nih.gov/pubmed/29190637.

606. Ahn MJ, Chiu CH, Cheng Y, et al. Osimertinib for patients with leptomeningeal metastases associated with EGFR T790M-positive advanced NSCLC: the AURA leptomeningeal metastases analysis. J Thorac Oncol 2020;15:637-648. Available at: https://www.ncbi.nlm.nih.gov/pubmed/31887431.

607. Lee J, Choi Y, Han J, et al. Osimertinib improves overall survival in patients with EGFR-mutated NSCLC with leptomeningeal metastases

Discussion update in progress

Version 3.2025 © 2025 National Comprehensive Cancer Network© (NCCN©), All rights reserved. NCCN Guidelines® and this illustration may not be reproduced in any form without the express written permission of NCCN.

PLEASE NOTE that use of this NCCN Content is governed by the End-User License Agreement, and you MAY NOT distribute this Content or use it with any artificial intelligence model or tool.
Printed by A. S. M. FAZLUL KARIM CHOWDHURY on 4/20/2026 3:06:38 AM. Copyright © 2026 National Comprehensive Cancer Network, Inc. All Rights Reserved.

regardless of T790M mutational status. J Thorac Oncol 2020;15:1758-1766. Available at: https://www.ncbi.nlm.nih.gov/pubmed/32652216.

608. Lee JS, Melisko ME, Magbanua MJ, et al. Detection of cerebrospinal fluid tumor cells and its clinical relevance in leptomeningeal metastasis of breast cancer. Breast Cancer Res Treat 2015;154:339-349. Available at: https://www.ncbi.nlm.nih.gov/pubmed/26520840.

609. Lin X, Fleisher M, Rosenblum M, et al. Cerebrospinal fluid circulating tumor cells: a novel tool to diagnose leptomeningeal metastases from epithelial tumors. Neuro Oncol 2017;19:1248-1254. Available at: https://www.ncbi.nlm.nih.gov/pubmed/28821205.

610. Nayak L, Fleisher M, Gonzalez-Espinoza R, et al. Rare cell capture technology for the diagnosis of leptomeningeal metastasis in solid tumors. Neurology 2013;80:1598-1605; discussion 1603. Available at: https://www.ncbi.nlm.nih.gov/pubmed/23553479.

611. Ibrahim A, Crockard A, Antonietti P, et al. Does spinal surgery improve the quality of life for those with extradural (spinal) osseous metastases? An international multicenter prospective observational study of 223 patients. Invited submission from the Joint Section Meeting on Disorders of the Spine and Peripheral Nerves, March 2007. J Neurosurg Spine 2008;8:271-278. Available at: http://www.ncbi.nlm.nih.gov/pubmed/18312079.

612. Byrne TN. Spinal cord compression from epidural metastases. N Engl J Med 1992;327:614-619. Available at: http://www.ncbi.nlm.nih.gov/pubmed/1296600.

613. Schmidt MH, Klimo P, Jr., Vrionis FD. Metastatic spinal cord compression. J Natl Compr Canc Netw 2005;3:711-719. Available at: http://www.ncbi.nlm.nih.gov/pubmed/16194459.

614. Helweg-Larsen S, Sorensen PS. Symptoms and signs in metastatic spinal cord compression: a study of progression from first symptom until diagnosis in 153 patients. Eur J Cancer 1994;30A:396-398. Available at: http://www.ncbi.nlm.nih.gov/pubmed/8204366.

615. Levack P, Graham J, Collie D, et al. Don't wait for a sensory level--listen to the symptoms: a prospective audit of the delays in diagnosis of malignant cord compression. Clin Oncol (R Coll Radiol) 2002;14:472-480. Available at: http://www.ncbi.nlm.nih.gov/pubmed/12512970.

616. Sundaresan N, Rothman A, Manhart K, Kelliher K. Surgery for solitary metastases of the spine: rationale and results of treatment. Spine (Phila Pa 1976) 2002;27:1802-1806. Available at: http://www.ncbi.nlm.nih.gov/pubmed/12195075.

617. North RB, LaRocca VR, Schwartz J, et al. Surgical management of spinal metastases: analysis of prognostic factors during a 10-year experience. J Neurosurg Spine 2005;2:564-573. Available at: http://www.ncbi.nlm.nih.gov/pubmed/15945430.

618. Tomita K, Kawahara N, Kobayashi T, et al. Surgical strategy for spinal metastases. Spine (Phila Pa 1976) 2001;26:298-306. Available at: http://www.ncbi.nlm.nih.gov/pubmed/11224867.

619. Tokuhashi Y, Matsuzaki H, Oda H, et al. A revised scoring system for preoperative evaluation of metastatic spine tumor prognosis. Spine (Phila Pa 1976) 2005;30:2186-2191. Available at: http://www.ncbi.nlm.nih.gov/pubmed/16205345.

620. van der Linden YM, Dijkstra SP, Vonk EJ, et al. Prediction of survival in patients with metastases in the spinal column: results based on a randomized trial of radiotherapy. Cancer 2005;103:320-328. Available at: http://www.ncbi.nlm.nih.gov/pubmed/15593360.

621. Bartels RH, Feuth T, van der Maazen R, et al. Development of a model with which to predict the life expectancy of patients with spinal epidural metastasis. Cancer 2007;110:2042-2049. Available at: http://www.ncbi.nlm.nih.gov/pubmed/17853394.

622. Choi D, Crockard A, Bunger C, et al. Review of metastatic spine tumour classification and indications for surgery: the consensus statement of the Global Spine Tumour Study Group. Eur Spine J 2010;19:215-222. Available at: http://www.ncbi.nlm.nih.gov/pubmed/20039084.

Discussion update in progress

Version 3.2025 © 2025 National Comprehensive Cancer Network© (NCCN©), All rights reserved. NCCN Guidelines® and this illustration may not be reproduced in any form without the express written permission of NCCN.

PLEASE NOTE that use of this NCCN Content is governed by the End-User License Agreement, and you MAY NOT distribute this Content or use it with any artificial intelligence model or tool.
Printed by A. S. M. FAZLUL KARIM CHOWDHURY on 4/20/2026 3:06:38 AM. Copyright © 2026 National Comprehensive Cancer Network, Inc. All Rights Reserved.

623. Eleraky M, Papanastassiou I, Vrionis FD. Management of metastatic spine disease. Curr Opin Support Palliat Care 2010;4:182-188. Available at: http://www.ncbi.nlm.nih.gov/pubmed/20671554.

624. Klimo P, Jr., Thompson CJ, Kestle JR, Schmidt MH. A meta-analysis of surgery versus conventional radiotherapy for the treatment of metastatic spinal epidural disease. Neuro Oncol 2005;7:64-76. Available at: http://www.ncbi.nlm.nih.gov/pubmed/15701283.

625. Witham TF, Khavkin YA, Gallia GL, et al. Surgery insight: current management of epidural spinal cord compression from metastatic spine disease. Nat Clin Pract Neurol 2006;2:87-94; quiz 116. Available at: http://www.ncbi.nlm.nih.gov/pubmed/16932530.

626. Patchell RA, Tibbs PA, Regine WF, et al. Direct decompressive surgical resection in the treatment of spinal cord compression caused by metastatic cancer: a randomised trial. Lancet 2005;366:643-648. Available at: http://www.ncbi.nlm.nih.gov/pubmed/16112300.

627. Patil CG, Lad SP, Santarelli J, Boakye M. National inpatient complications and outcomes after surgery for spinal metastasis from 1993-2002. Cancer 2007;110:625-630. Available at: http://www.ncbi.nlm.nih.gov/pubmed/17577227.

628. Itshayek E, Yamada J, Bilsky M, et al. Timing of surgery and radiotherapy in the management of metastatic spine disease: a systematic review. Int J Oncol 2010;36:533-544. Available at: http://www.ncbi.nlm.nih.gov/pubmed/20126972.

629. Gerszten PC, Mendel E, Yamada Y. Radiotherapy and radiosurgery for metastatic spine disease: what are the options, indications, and outcomes? Spine (Phila Pa 1976) 2009;34:S78-92. Available at: http://www.ncbi.nlm.nih.gov/pubmed/19829280.

630. Maranzano E, Bellavita R, Rossi R, et al. Short-course versus split-course radiotherapy in metastatic spinal cord compression: results of a phase III, randomized, multicenter trial. J Clin Oncol 2005;23:3358-3365. Available at: http://www.ncbi.nlm.nih.gov/pubmed/15738534.

631. Hoskin PJ, Hopkins K, Misra V, et al. Effect of single-fraction vs multifraction radiotherapy on ambulatory status among patients with spinal canal compression from metastatic cancer: the SCORAD randomized clinical trial. JAMA 2019;322:2084-2094. Available at: https://www.ncbi.nlm.nih.gov/pubmed/31794625.

632. Redmond KJ, Robertson S, Lo SS, et al. Consensus contouring guidelines for postoperative stereotactic body radiation therapy for metastatic solid tumor malignancies to the spine. Int J Radiat Oncol Biol Phys 2017;97:64-74. Available at: https://www.ncbi.nlm.nih.gov/pubmed/27843035.

633. Cox BW, Spratt DE, Lovelock M, et al. International Spine Radiosurgery Consortium consensus guidelines for target volume definition in spinal stereotactic radiosurgery. Int J Radiat Oncol Biol Phys 2012;83:e597-605. Available at: https://www.ncbi.nlm.nih.gov/pubmed/22608954.

634. Redmond KJ, Lo SS, Soltys SG, et al. Consensus guidelines for postoperative stereotactic body radiation therapy for spinal metastases: results of an international survey. J Neurosurg Spine 2017;26:299-306. Available at: https://www.ncbi.nlm.nih.gov/pubmed/27834628.

635. Glicksman RM, Tjong MC, Neves-Junior WFP, et al. Stereotactic ablative radiotherapy for the management of spinal metastases: a review. JAMA Oncol 2020;6:567-577. Available at: https://www.ncbi.nlm.nih.gov/pubmed/31895403.

636. Ryu S, Pugh SL, Gerszten PC, et al. RTOG 0631 phase 2/3 study of image guided stereotactic radiosurgery for localized (1-3) spine metastases: phase 2 results. Pract Radiat Oncol 2014;4:76-81. Available at: https://www.ncbi.nlm.nih.gov/pubmed/24890347.

637. Ryu S, Deshmukh S, Timmerman RD, et al. Radiosurgery compared to external beam radiotherapy for localized spine metastasis: phase III results of NRG Oncology/RTOG 0631. International Journal of Radiation Oncology*Biology*Physics 2019;105:S2-S3. Available at: https://doi.org/10.1016/j.ijrobp.2019.06.382.

Discussion update in progress

Version 3.2025 © 2025 National Comprehensive Cancer Network© (NCCN©), All rights reserved. NCCN Guidelines® and this illustration may not be reproduced in any form without the express written permission of NCCN.

PLEASE NOTE that use of this NCCN Content is governed by the End-User License Agreement, and you MAY NOT distribute this Content or use it with any artificial intelligence model or tool.
Printed by A. S. M. FAZLUL KARIM CHOWDHURY on 4/20/2026 3:06:38 AM. Copyright © 2026 National Comprehensive Cancer Network, Inc. All Rights Reserved.

638. Sahgal A, Myrehaug SD, Siva S, et al. Stereotactic body radiotherapy versus conventional external beam radiotherapy in patients with painful spinal metastases: an open-label, multicentre, randomised, controlled, phase 2/3 trial. Lancet Oncol 2021;22:1023-1033. Available at: https://www.ncbi.nlm.nih.gov/pubmed/34126044.

639. Palma DA, Olson R, Harrow S, et al. Stereotactic ablative radiotherapy for the comprehensive treatment of oligometastatic cancers: long-term results of the SABR-COMET phase II randomized trial. J Clin Oncol 2020;38:2830-2838. Available at: https://www.ncbi.nlm.nih.gov/pubmed/32484754.

640. Mendel E, Bourekas E, Gerszten P, Golan JD. Percutaneous techniques in the treatment of spine tumors: what are the diagnostic and therapeutic indications and outcomes? Spine (Phila Pa 1976) 2009;34:S93-100. Available at: http://www.ncbi.nlm.nih.gov/pubmed/19829281.

641. Bagla S, Sayed D, Smirniotopoulos J, et al. Multicenter prospective clinical series evaluating radiofrequency ablation in the treatment of painful spine metastases. Cardiovasc Intervent Radiol 2016;39:1289-1297. Available at: https://www.ncbi.nlm.nih.gov/pubmed/27343124.

642. Sorensen S, Helweg-Larsen S, Mouridsen H, Hansen HH. Effect of high-dose dexamethasone in carcinomatous metastatic spinal cord compression treated with radiotherapy: a randomised trial. Eur J Cancer 1994;30A:22-27. Available at: http://www.ncbi.nlm.nih.gov/pubmed/8142159.

643. Vecht CJ, Haaxma-Reiche H, van Putten WL, et al. Initial bolus of conventional versus high-dose dexamethasone in metastatic spinal cord compression. Neurology 1989;39:1255-1257. Available at: http://www.ncbi.nlm.nih.gov/pubmed/2771077.

644. Heimdal K, Hirschberg H, Slettebo H, et al. High incidence of serious side effects of high-dose dexamethasone treatment in patients with epidural spinal cord compression. J Neurooncol 1992;12:141-144. Available at: http://www.ncbi.nlm.nih.gov/pubmed/1560260.

645. Fisher CG, DiPaola CP, Ryken TC, et al. A novel classification system for spinal instability in neoplastic disease: an evidence-based approach and expert consensus from the Spine Oncology Study Group. Spine (Phila Pa 1976) 2010;35:E1221-1229. Available at: https://www.ncbi.nlm.nih.gov/pubmed/20562730.

646. Kwok Y, Regine WF, Patchell RA. Radiation therapy alone for spinal cord compression: time to improve upon a relatively ineffective status quo. J Clin Oncol 2005;23:3308-3310. Available at: http://www.ncbi.nlm.nih.gov/pubmed/15738546.

647. Rades D, Stalpers LJA, Veninga T, et al. Evaluation of five radiation schedules and prognostic factors for metastatic spinal cord compression. J Clin Oncol 2005;23:3366-3375. Available at: http://www.ncbi.nlm.nih.gov/pubmed/15908648.

Discussion Update in progress

Version 3.2025 © 2025 National Comprehensive Cancer Network© (NCCN©), All rights reserved. NCCN Guidelines® and this illustration may not be reproduced in any form without the express written permission of NCCN.