National Comprehensive Cancer Network®

NCCN Clinical Practice Guidelines in Oncology (NCCN Guidelines®)

Pediatric Central Nervous System Cancers

Version 1.2026 — November 25, 2025

NCCN recognizes the importance of clinical trials and encourages participation when applicable and available. Trials should be designed to maximize inclusiveness and broad representative enrollment.

Version 1.2026, 11/25/25 © 2025 National Comprehensive Cancer Network® (NCCN®), All rights reserved. NCCN Guidelines® and this illustration may not be reproduced in any form without the express written permission of NCCN.

PLEASE NOTE that use of this NCCN Content is governed by the End-User License Agreement, and you MAY NOT distribute this Content or use it with any artificial intelligence model or tool.
Printed by A. S. M. FAZLUL KARIM CHOWDHURY on 4/20/2026 3:38:59 AM. Copyright © 2026 National Comprehensive Cancer Network, Inc. All Rights Reserved.

NCCN Guidelines Version 1.2026
Pediatric Central Nervous System Cancers

***Amar Gajjar, MD/Chair €**
St. Jude Children's Research Hospital/The University of Tennessee Health Science Center

***Anita Mahajan, MD/Vice-Chair §**
Mayo Clinic Comprehensive Cancer Center

Tejus Bale, MD, PhD ≠
Memorial Sloan Kettering Cancer Center

Daniel C. Bowers, MD € ‡
UT Southwestern Simmons Comprehensive Cancer Center | Children's Medical Center Dallas

Liz Canan, MHA
Mayo Clinic Comprehensive Cancer Center

Susan Chi, MD Y €
Dana-Farber/Boston Children's Cancer and Blood Disorders Center

Andrew Cluster, MD €
Siteman Cancer Center at Barnes-Jewish Hospital and Washington University School of Medicine | St. Louis Children's Hospital

Kenneth Cohen, MD, MBA € Y
Johns Hopkins Kimmel Cancer Center | Johns Hopkins Children's Center

Bonnie Cole, MD ≠
Fred Hutchinson Cancer Center | Seattle Children's Hospital

Scott L. Coven, DO, MPH Y €
Indiana University Melvin and Bren Simon Comprehensive Cancer Center | Riley Children's Health

Wendy Darlington, MD, MAPP €
The UChicago Medicine Comprehensive Cancer Center | UChicago Medicine Comer Children's Hospital

Jennifer Elster, MD Y
UC San Diego Moores Cancer Center | Rady Children's Hospital-San Diego

Ralph Ermoian, MD §
Fred Hutchinson Cancer Center | Seattle Children's Hospital

Andrea Franson, MD, MS € Y
University of Michigan Rogel Cancer Center | C.S. Mott Children's Hospital

Elizabeth George, MBBS ф
UCSF Helen Diller Family Comprehensive Cancer Center | UCSF Benioff Children's Hospital

Jeffrey Helgager, MD, PhD ≠
University of Wisconsin Carbone Cancer Center | American Family Children's Hospital

Chi Lin, MD, PhD §
Fred & Pamela Buffett Cancer Center | Children's Hospital & Medical Center

Laura Metrock, MD Y ‡
O'Neal Comprehensive Cancer Center at UAB | Children's of Alabama

Ronica Nanda, MD §
Moffitt Cancer Center

Joshua Palmer, MD §
The Ohio State University Comprehensive Cancer Center - James Cancer Hospital and Solove Research Institute | Nationwide Children's Hospital

Sonia Partap, MD € Y
Stanford Cancer Institute | Lucile Packard Children's Hospital

Ashley Plant, MD € Y
Robert H. Lurie Comprehensive Cancer Center of Northwestern University | Ann & Robert H. Lurie Children's Hospital of Chicago

Sumit Pruthi, MD ф
Vanderbilt-Ingram Cancer Center | Monroe Carrell Jr. Children's Hospital at Vanderbilt

Renee Reynolds, MD ¶
Roswell Park Comprehensive Cancer Center | Roswell Park Oishei Children's Cancer and Blood Disorders Program

Duncan Stearns, MD € ‡
Case Comprehensive Cancer Center/University Hospitals Seidman Cancer Center and Cleveland Clinic Taussig Cancer Institute | University Hospitals Rainbow Babies & Children's Hospital

Phillip Storm, MD ¶
Abramson Cancer Center at the University of Pennsylvania | Children's Hospital of Philadelphia

Anthony Wang, MD ¶
UCLA Jonsson Comprehensive Cancer Center | UCLA Mattel Children's Hospital

Leo D. Wang, MD, PhD ‡
City of Hope National Medical Center

Nicholas Whipple, MD, MPH €
Huntsman Cancer Institute at the University of Utah | Primary Children's Hospital

Wafik Zaky, MBBCh € ‡
The University of Texas MD Anderson Cancer Center

NCCN
Nicole McMillian, MS
Swathi Ramakrishnan, PhD

ф Diagnostic radiology	€ Pediatric oncology
‡ Hematology/Hematology oncology	§ Radiotherapy/Radiation oncology
Þ Internal medicine	¶ Surgery/Surgical oncology
Ψ Neurology/Neuro-oncology	* Discussion Section Writing Committee
≠ Pathology	

NCCN Guidelines Panel Disclosures

Version 1.2026, 11/25/25 © 2025 National Comprehensive Cancer Network® (NCCN®), All rights reserved. NCCN Guidelines® and this illustration may not be reproduced in any form without the express written permission of NCCN.

PLEASE NOTE that use of this NCCN Content is governed by the End-User License Agreement, and you MAY NOT distribute this Content or use it with any artificial intelligence model or tool.
Printed by A. S. M. FAZLUL KARIM CHOWDHURY on 4/20/2026 3:38:59 AM. Copyright © 2026 National Comprehensive Cancer Network, Inc. All Rights Reserved.

NCCN Guidelines Version 1.2026
Pediatric Central Nervous System Cancers

NCCN Pediatric Central Nervous System Cancers Panel Members
Summary of the Guidelines Updates

Pediatric Diffuse High-Grade Gliomas
Introduction (PGLIO INTRO)
Radiologic Presentation (PGLIO-1)
Adjuvant Treatment and Follow-up (PGLIO-2 and PGLIO-3)
Treatment for Recurrent Disease or Progressive Disease (PGLIO-4)

Principles of:
- Neuroimaging (PGLIO-A)
- Neuropathology (PGLIO-B)
- Surgery (PGLIO-C)
- Radiation Therapy Management (PGLIO-D)
- Systemic Therapy (PGLIO-E)

Pediatric Medulloblastoma: Children and Adolescents
Introduction (PMB INTRO)
Radiologic Presentation (PMB-1)
WNT and SHH Adjuvant/Maintenance Treatment (PMB-2)
Combined (includes Groups 3 and 4), Adjuvant/Maintenance Treatment (PMB-3)
Follow-up/Surveillance (PMB-4)
Treatment for Recurrent Disease or Progressive Disease (PMB-5)

Principles of:
- Neuroimaging (PMB-A)
- Neuropathology (PMB-B)
- Surgery (PMB-C)
- Radiation Therapy Management (PMB-D)
- Systemic Therapy (PMB-E)

Abbreviations (ABBR-1)

Find an NCCN Member Institution: https://www.nccn.org/home/member-institutions.

NCCN Categories of Evidence and Consensus: All recommendations are category 2A unless otherwise indicated.

See NCCN Categories of Evidence and Consensus.

NCCN Categories of Preference: All recommendations are considered appropriate.

See NCCN Categories of Preference.

The NCCN Guidelines® are a statement of evidence and consensus of the authors regarding their views of currently accepted approaches to treatment. Any clinician seeking to apply or consult the NCCN Guidelines is expected to use independent medical judgment in the context of individual clinical circumstances to determine any patient's care or treatment. The National Comprehensive Cancer Network® (NCCN®) makes no representations or warranties of any kind regarding their content, use or application and disclaims any responsibility for their application or use in any way. The NCCN Guidelines are copyrighted by National Comprehensive Cancer Network®. All rights reserved. The NCCN Guidelines and the illustrations herein may not be reproduced in any form without the express written permission of NCCN. ©2025.

PLEASE NOTE that use of this NCCN Content is governed by the End-User License Agreement, and you MAY NOT distribute this Content or use it with any artificial intelligence model or tool.
Printed by A. S. M. FAZLUL KARIM CHOWDHURY on 4/20/2026 3:38:59 AM. Copyright © 2026 National Comprehensive Cancer Network, Inc. All Rights Reserved.

Updates in Version 1.2026 of the NCCN Guidelines for Pediatric Central Nervous System Cancers from Version 3.2025 include:

Pediatric Diffuse High-Grade Gliomas
PGLIO-4
- Footnote l is new: Highly consider restaging spine imaging.

PGLIO-A 3 of 4
- PET Studies (The same changes were also made for medulloblastoma on PMB-A 3 of 4)
  - Revised: Assess ~~brain tissue metabolism with radiopharmaceuticals~~ *tumor biology by using tracers with distinct mechanisms of uptake, allowing differentiation of different biological processes within the tumor*.
  - 1st Bullet revised: "May be useful in *tumor delineation*, differentiating between neoplasm and radiation necrosis, tumor grading, or identifying *a* more..."
  - 2nd Bullet revised: "~~Limitations:~~ Limited spatial resolution compared to brain CT and MRI; heterogenous..."

PGLIO-B 3 of 4
- Molecular Alterations Consistent with “High-Grade” in Pediatric Diffuse Gliomas: Added *H3 G34 mutation*

PGLIO-C
- Postoperative Management revised:
  - Monitor for signs and symptoms of increased intracranial pressure. *Either ventriculoperitoneal (VP) shunt or endoscopic third ventriculostomy (ETV) are acceptable CSF diversion techniques.*
  - *Early consultation with radiation oncology and neuro-oncology is recommended.*
  - *Consider anti-seizure medications for seizure prophylaxis. Early consultation with neurology is recommended, in cases involving longstanding or multiple-recurrent seizures.*
  - *Early physical therapy, occupational therapy, and speech therapy intervention are recommended in cases of motor dysfunction.*
  - *Consider referral to a child life social worker for family/patient support.*
  - Bullets deleted
    - Consider the following:
      - Seizure prophylaxis
      - Antibiotics for infection prophylaxis
      - Deep vein thrombosis (DVT) prophylaxis

PGLIO-D 2 of 4
- Diffuse Midline Glioma/Diffuse Intrinsic Pontine Glioma; 6th Bullet; Tumor volumes; Last sub-bullet revised: "...and may not be uniform in all dimensions. ~~The clinician should consider the effects of the beam penumbra when designing the treatment apertures.~~"

Continued

Version 1.2026, 11/25/25 © 2025 National Comprehensive Cancer Network® (NCCN®), All rights reserved. NCCN Guidelines® and this illustration may not be reproduced in any form without the express written permission of NCCN.

PLEASE NOTE that use of this NCCN Content is governed by the End-User License Agreement, and you MAY NOT distribute this Content or use it with any artificial intelligence model or tool.
Printed by A. S. M. FAZLUL KARIM CHOWDHURY on 4/20/2026 3:38:59 AM. Copyright © 2026 National Comprehensive Cancer Network, Inc. All Rights Reserved.

Updates in Version 1.2026 of the NCCN Guidelines for Pediatric Central Nervous System Cancers from Version 3.2025 include:

Pediatric Diffuse High-Grade Gliomas (continued)

PGLIO-D 3 of 4
- Normal Tissue Constraints; Brainstem constraints revised:
  - If photons are used:
    - Dmax <60 Gy, D50% ~~<52.4~~ *<56.7* Gy
    - *If primary is in brain stem, no limit to D50%*

PGLIO-D 4 of 4
- New references added:
  - Lu VM, Welby JP, Mahajan A, et al. Reirradiation for diffuse intrinsic pontine glioma: a systematic review and meta-analysis. Childs Nerv Syst 2019;35:739-746.
  - Amsbaugh MJ, Mahajan A, Thall PF, et al. A phase 1/2 trial of reirradiation for diffuse intrinsic pontine glioma. Int J Radiat Oncol Biol Phys 2019;104:144-148.

PGLIO-E 1 of 3
- Footnote d is new: For DMG (pontine location) and DIPG: Clinical trials are preferred and standard RT alone may be considered.
- Footnote e is new: Pembrolizumab and berahyaluronidase alfa-pmph subcutaneous injection may be substituted for IV pembrolizumab. Pembrolizumab and berahyaluronidase alfa-pmph has different dosing and administration instructions compared to IV pembrolizumab.

Pediatric Medulloblastoma: Children and Adolescents

PMB INTRO 2 of 3
- Treatment; New bullet added: Craniospinal radiation is not recommended for patients <3 years of age, but radiation-avoiding strategies may be used for patients <3 years of age per the treating physician's discretion.

PMB-4
- Page title revised: Follow-Up/Surveillance *May Include*

PMB-D 1 of 3
- CT Simulation/Tumor Volumes
  - 2nd Bullet revised: CT simulation for treatment planning should include ~~<0.3~~ ≤0.3 cm slice thickness.
- 7th Bullet revised: CTV boost: GTV + 10–15 mm can be modified *to limit extension* at the level of brainstem 2–5 mm.

PMB-D 3 of 3
- Uninvolved brain (Brain – PTV); Constraints revised: "No more than 1% or 1 cc of the tissue outside of ~~either~~ *the* PTV receiving more..."
- Footnote g is new: These limits may not be achievable in patients with high-risk features, but should be minimized to as low as possible.

MS-1
- The Discussion has been updated to reflect the changes in the algorithm.

Version 1.2026, 11/25/25 © 2025 National Comprehensive Cancer Network® (NCCN®), All rights reserved. NCCN Guidelines® and this illustration may not be reproduced in any form without the express written permission of NCCN.

PLEASE NOTE that use of this NCCN Content is governed by the End-User License Agreement, and you MAY NOT distribute this Content or use it with any artificial intelligence model or tool.
Printed by A. S. M. FAZLUL KARIM CHOWDHURY on 4/20/2026 3:38:59 AM. Copyright © 2026 National Comprehensive Cancer Network, Inc. All Rights Reserved.

INTRODUCTION TO PEDIATRIC DIFFUSE HIGH-GRADE GLIOMAS[1-5,a]

All patients with pediatric diffuse high-grade gliomas should be cared for by a multidisciplinary team with experience managing central nervous system (CNS) tumors.[b] At this time, the Pediatric Diffuse High-Grade Gliomas Guideline refers to children and adolescents ≤21 years of age.

Epidemiology of Pediatric Diffuse High-Grade Gliomas

- 14.8% of all intracranial neoplasms are among children and adolescents (<19 years).
- The incidence of pediatric diffuse high-grade gliomas among children and adolescents is roughly 1.8 per 100,000 population.
- Incidence varies with age.
- 5-year overall survival is <20%.
- Prognostic features include age at presentation (<3 and >13 years), tumor location, sex, extent of resection, and genomic profile.

Risk Factors

- Inherited predispositions to cancer include, but are not limited to:
  - Neurofibromatosis type 1 (NF1)
  - Li-Fraumeni syndrome
  - Turcot syndrome/Lynch syndrome/constitutional mismatch repair deficiency (CMMRD):
    - Mutations in *APC*/familial adenomatous polyposis (FAP) locus (more often associated with medulloblastoma)
    - Mutations in mismatch repair (MMR) genes
- Exposure to ionizing radiation: Therapeutic cranial radiation treatments increase risk for pediatric diffuse high-grade gliomas.

Clinical Presentation

- The most common symptoms include effects of increased intracranial pressure, such as headache, nausea, and vomiting.
- Other presenting symptoms include seizure, hemiparesis, monoparesis, cranial nerve deficits, ataxia, hemisensory loss, dysphasia, aphasia, and memory impairment.
- Presenting symptoms among infants include increased head circumference and loss of developmental milestones.
- Shorter length of symptoms is associated with worse prognosis in older studies.

Treatment

- Treatment for pediatric diffuse high-grade gliomas frequently includes surgery, radiation therapy (RT), and chemotherapy.
- Goals of surgery include the safe reduction of tumor-associated mass effect and obtaining adequate tissue for histologic and molecular classification.
- Referral for cancer predisposition evaluation and/or genetic counseling should be considered.

[a] Primary spinal cord tumors are not addressed in these guidelines.
[b] A multidisciplinary team that includes pediatric oncologists/neuro-oncologists, pediatric radiation oncologists, pathologists with expertise in neuropathology and molecular pathology, pediatric neuroradiologists, and pediatric neurosurgeons is strongly encouraged.

Note: All recommendations are category 2A unless otherwise indicated.

References

Version 1.2026, 11/25/25 © 2025 National Comprehensive Cancer Network® (NCCN®), All rights reserved. NCCN Guidelines® and this illustration may not be reproduced in any form without the express written permission of NCCN.

PLEASE NOTE that use of this NCCN Content is governed by the End-User License Agreement, and you MAY NOT distribute this Content or use it with any artificial intelligence model or tool.
Printed by A. S. M. FAZLUL KARIM CHOWDHURY on 4/20/2026 3:38:59 AM. Copyright © 2026 National Comprehensive Cancer Network, Inc. All Rights Reserved.

INTRODUCTION TO PEDIATRIC DIFFUSE HIGH-GRADE GLIOMAS
REFERENCES

[1] Udaka YT, Packer RJ. Pediatric brain tumors. Neurol Clin 2018;36:533-556.
[2] Coleman C, Stoller S, Grotzer M, Stucklin AG. Pediatric hemispheric high-grade glioma: targeting the future. Cancer Metastasis Rev 2020;39:245-260.
[3] Ostrom QT, Patil N, Cioffi G, et al. CBTRUS Statistical Report: Primary Brain and Other Central Nervous System Tumors Diagnosed in the United States in 2013–2017, Neuro-Oncology 2020;22(12 Suppl 2):iv1-iv96.
[4] Jones C, Karajannis MA, Jones DTW, et al. Pediatric high-grade glioma: biologically and clinically in need of new thinking. Neuro Oncol 2017;19:153-161.
[5] Hatoum R, Chen J, Lavergne P, et al. Extent of tumor resection and survival in pediatric patients with high-grade gliomas: A systematic review and meta-analysis. JAMA Netw Open 2022;5:e2226551.

Note: All recommendations are category 2A unless otherwise indicated.

Version 1.2026, 11/25/25 © 2025 National Comprehensive Cancer Network® (NCCN®), All rights reserved. NCCN Guidelines® and this illustration may not be reproduced in any form without the express written permission of NCCN.

PLEASE NOTE that use of this NCCN Content is governed by the End-User License Agreement, and you MAY NOT distribute this Content or use it with any artificial intelligence model or tool.
Printed by A. S. M. FAZLUL KARIM CHOWDHURY on 4/20/2026 3:38:59 AM. Copyright © 2026 National Comprehensive Cancer Network, Inc. All Rights Reserved.

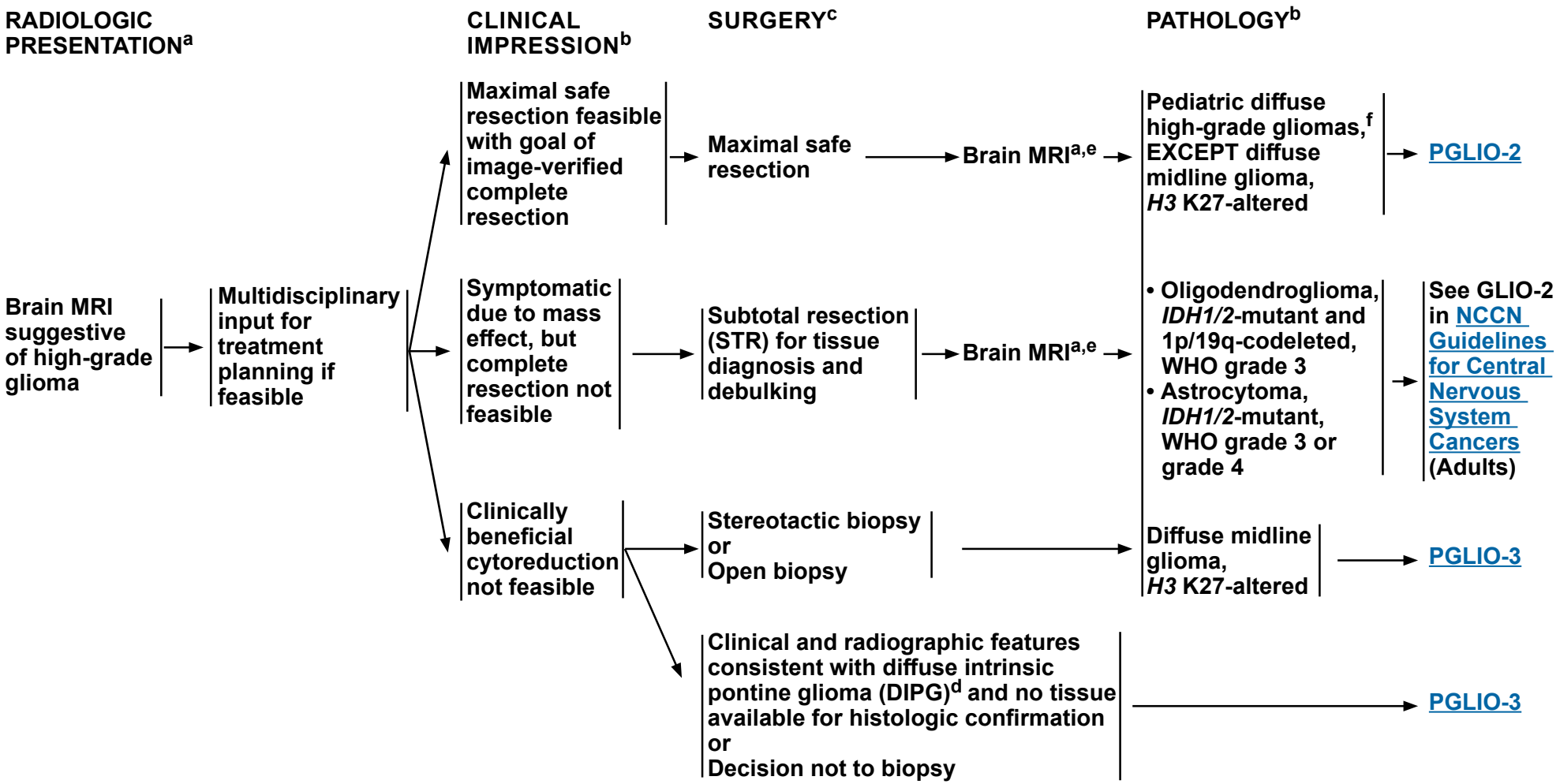

[a] Principles of Neuroimaging (PGLIO-A).
[b] Principles of Neuropathology (PGLIO- B).
[c] The goals of surgery are to obtain a pathologic diagnosis and molecular genetic characterization, alleviate symptoms related to increased intracranial pressure or tumor mass effect, increase survival, and decrease corticosteroid dose requirements. See Principles of Surgery (PGLIO-C).
[d] Encourage biopsy if atypical features on MRI are present, if patient is <3 years of age, or if standard of care at institution.
[e] Postoperative follow-up is ideally between 24–48 hours.
[f] Diagnoses include diffuse hemispheric glioma, *H3* G34-mutant; pediatric diffuse high-grade glioma, *H3* wild-types and *IDH* wild-type; and infant-type hemispheric glioma, in addition to other high-grade glial entities.

Note: All recommendations are category 2A unless otherwise indicated.

Version 1.2026, 11/25/25 © 2025 National Comprehensive Cancer Network® (NCCN®), All rights reserved. NCCN Guidelines® and this illustration may not be reproduced in any form without the express written permission of NCCN.

PLEASE NOTE that use of this NCCN Content is governed by the End-User License Agreement, and you MAY NOT distribute this Content or use it with any artificial intelligence model or tool.
Printed by A. S. M. FAZLUL KARIM CHOWDHURY on 4/20/2026 3:38:59 AM. Copyright © 2026 National Comprehensive Cancer Network, Inc. All Rights Reserved.

NCCN Guidelines Version 1.2026
Pediatric Diffuse High-Grade Gliomas

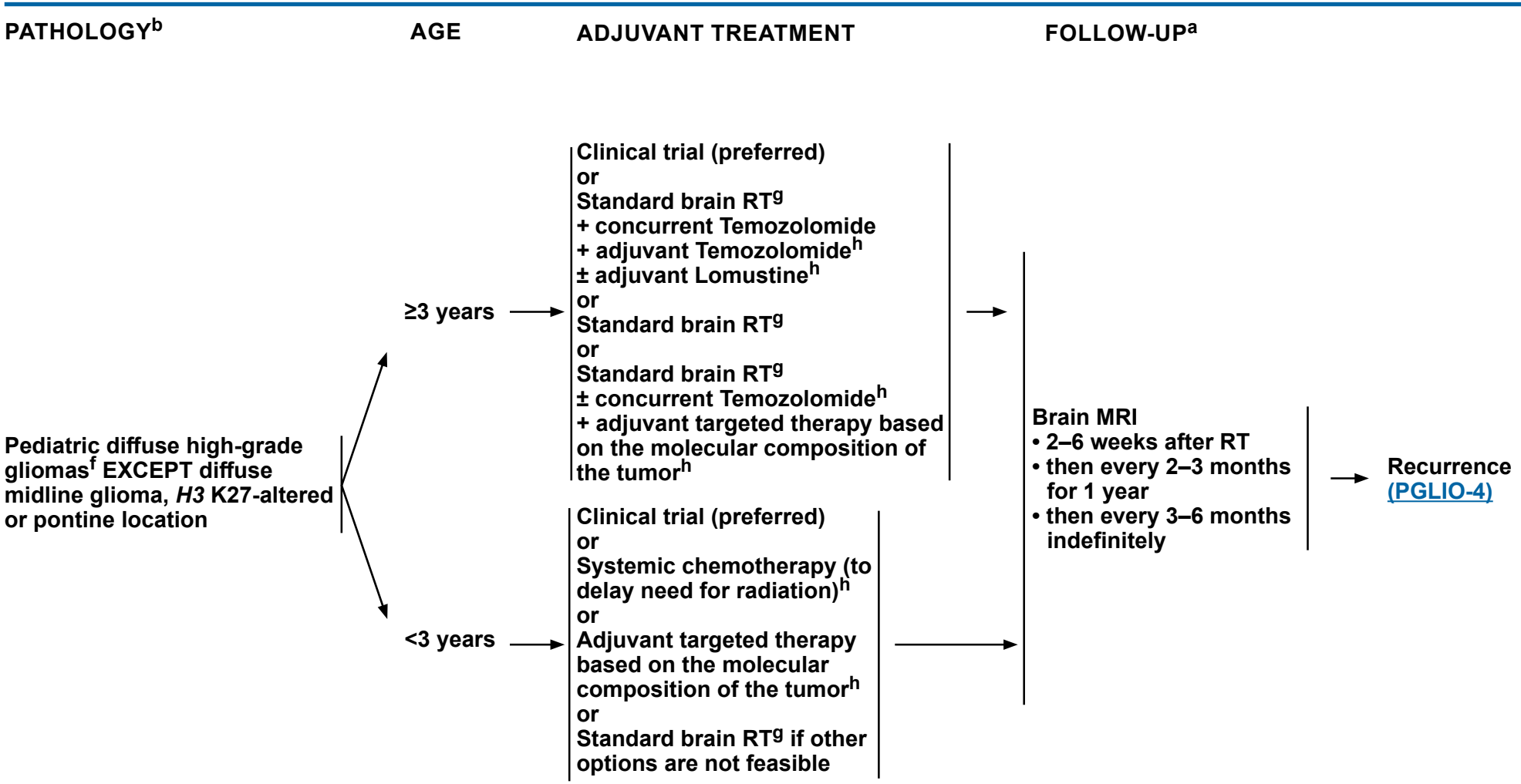

[a] Principles of Neuroimaging (PGLIO-A).
[b] Principles of Neuropathology (PGLIO-B).
[f] Diagnoses include diffuse hemispheric glioma, *H3* G34-mutant; pediatric diffuse high-grade glioma, *H3* wild-types and *IDH* wild-type; and infant-type hemispheric glioma, in addition to other high-grade glial entities.
[g] Principles of Radiation Therapy Management (PGLIO-D).
[h] Principles of Systemic Therapy (PGLIO-E).

Note: All recommendations are category 2A unless otherwise indicated.

Version 1.2026, 11/25/25 © 2025 National Comprehensive Cancer Network® (NCCN®), All rights reserved. NCCN Guidelines® and this illustration may not be reproduced in any form without the express written permission of NCCN.

PLEASE NOTE that use of this NCCN Content is governed by the End-User License Agreement, and you MAY NOT distribute this Content or use it with any artificial intelligence model or tool.
Printed by A. S. M. FAZLUL KARIM CHOWDHURY on 4/20/2026 3:38:59 AM. Copyright © 2026 National Comprehensive Cancer Network, Inc. All Rights Reserved.

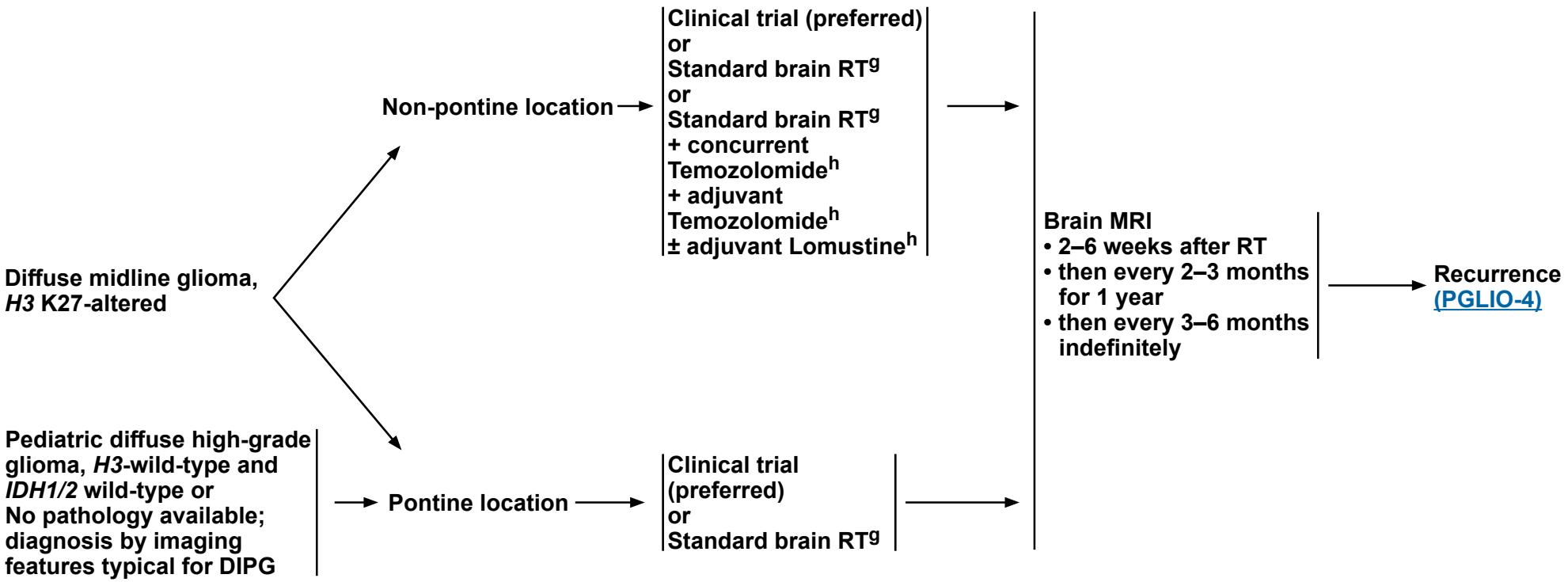

[a] Principles of Neuroimaging (PGLIO-A).
[b] Principles of Neuropathology (PGLIO-B).
[g] Principles of Radiation Therapy Management (PGLIO-D).
[h] Principles of Systemic Therapy (PGLIO-E).

Note: All recommendations are category 2A unless otherwise indicated.

Version 1.2026, 11/25/25 © 2025 National Comprehensive Cancer Network® (NCCN®), All rights reserved. NCCN Guidelines® and this illustration may not be reproduced in any form without the express written permission of NCCN.

PLEASE NOTE that use of this NCCN Content is governed by the End-User License Agreement, and you MAY NOT distribute this Content or use it with any artificial intelligence model or tool.
Printed by A. S. M. FAZLUL KARIM CHOWDHURY on 4/20/2026 3:38:59 AM. Copyright © 2026 National Comprehensive Cancer Network, Inc. All Rights Reserved.

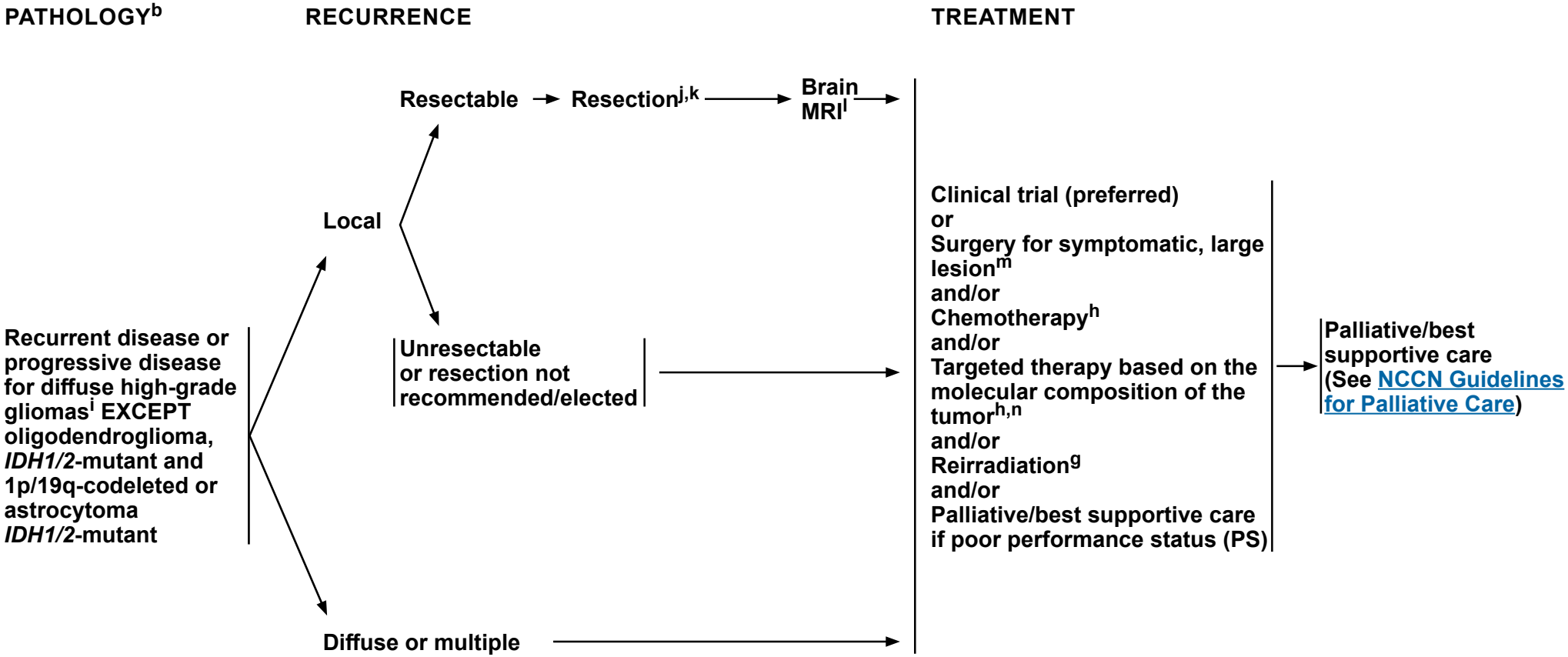

[b] Principles of Neuropathology (PGLIO-B).
[g] Principles of Radiation Therapy Management (PGLIO-D).
[h] Principles of Systemic Therapy (PGLIO-E).
[i] Diagnoses include diffuse hemispheric glioma, *H3* G34-mutant; pediatric diffuse high-grade glioma, *H3* wild-types and *IDH* wild-type; infant-type hemispheric glioma; and diffuse midline glioma, *H3* K27-altered, in addition to other high-grade glial entities.
[j] Principles of Surgery (PGLIO-C).
[k] Consider enrollment in phase 0 or preoperative clinical trials before resection.
[l] Highly consider restaging spine imaging.
[m] Re-resection at the time of recurrence may improve outcomes. As in adult patients with diffuse high-grade glioma, tumor involvement in specific critical brain areas and poor PS score may be associated with unfavorable re-resection outcomes.
[n] For high tumor mutational burden (TMB) or personal or family history of CMMRD, consider checkpoint blockade; RAF and MEK inhibition for tumors with *BRAF* V600E mutation, and TRK inhibitors for tumors with *NTRK1/2/3* gene fusion are recommended.

Note: All recommendations are category 2A unless otherwise indicated.

Version 1.2026, 11/25/25 © 2025 National Comprehensive Cancer Network® (NCCN®), All rights reserved. NCCN Guidelines® and this illustration may not be reproduced in any form without the express written permission of NCCN.

PLEASE NOTE that use of this NCCN Content is governed by the End-User License Agreement, and you MAY NOT distribute this Content or use it with any artificial intelligence model or tool.
Printed by A. S. M. FAZLUL KARIM CHOWDHURY on 4/20/2026 3:38:59 AM. Copyright © 2026 National Comprehensive Cancer Network, Inc. All Rights Reserved.

PRINCIPLES OF NEUROIMAGING[a]

Conventional MRI is recommended for tumor diagnosis, surgical guidance, and therapeutic monitoring. It may be complemented by advanced neuroimaging techniques such as magnetic resonance (MR) perfusion imaging, MR spectroscopy, and PET to enhance diagnostic capability, differentiate radiation necrosis from active neoplasm, and guide biopsy. Baseline imaging of the brain and spine, especially by MRI, is recommended before treatment for high-grade gliomas. Imaging is always recommended to investigate the etiology of emergent signs and symptoms. The following pages list imaging modalities available and used in neuro-oncology to make treatment decisions.

[a] Some imaging modalities or techniques may not be available at all institutions.

Note: All recommendations are category 2A unless otherwise indicated.

Continued

Version 1.2026, 11/25/25 © 2025 National Comprehensive Cancer Network® (NCCN®), All rights reserved. NCCN Guidelines® and this illustration may not be reproduced in any form without the express written permission of NCCN.

PLEASE NOTE that use of this NCCN Content is governed by the End-User License Agreement, and you MAY NOT distribute this Content or use it with any artificial intelligence model or tool.
Printed by A. S. M. FAZLUL KARIM CHOWDHURY on 4/20/2026 3:38:59 AM. Copyright © 2026 National Comprehensive Cancer Network, Inc. All Rights Reserved.

PRINCIPLES OF NEUROIMAGING[a]

MRI[1-4] of the Brain and/or Spine (entire neural axis) (with and without IV contrast)

- **Benefits: Excellent soft-tissue contrast and depiction of neoplasms through a combination of standard, universally available pulse sequences; able to demonstrate characteristic imaging appearance of pediatric high-grade gliomas to facilitate diagnosis and evaluate for metastatic disease; and confers no ionizing radiation**
- **Limitations: Relatively long examinations and sensitive to patient motion, so younger children generally require deep sedation/anesthesia; implanted metallic devices can cause significant artifact; and some implants are unsafe in MRI environment**
- **Pediatric high-grade glioma typically presents as infiltrative T2/FLAIR heterogenous intracranial masses with indistinct borders, heterogeneous enhancement, and mass effect. T2 hypointensity or reduced diffusion may indicate high cellularity.[1,5]**
- **Brain and spine MRI with and without gadolinium is the recommended imaging modality for staging and response evaluation for high-grade glioma.**
- **Rapid sequence MRI is not a substitute for a full brain and spine MRI when staging or assessing for response evaluation for high-grade glioma.**
- **CT is not recommended for staging and response evaluation for high-grade glioma unless in the very rare cases where MRI is not feasible.**
- **Basic MRI sequences of the brain should include: T2/FLAIR, diffusion-weighted imaging (DWI), gradient echo (GRE) or susceptibility weighted imaging (SWI), T1-weighted images pre-contrast, as well as T1-weighted images in two planes post-contrast (one of which would ideally be acquired as a 3D sequence)[6,7] (see Table 1 [PGLIO-A 3A of 4]).**
  - **These should be utilized for initial preliminary diagnostic evaluation and immediate postoperative follow-up (ideally within 24–48 hours postoperative, if clinically feasible) to facilitate comparison of disease burden (measurable and non-measurable disease) on initial examination and extent of resection on immediate postoperative scan.**
  - **2D acquisitions should be ≤4-mm slices; 3D acquisitions should be nearly isotropic.**
  - **T1 post-contrast sequences should be obtained as either 3D T1-weighted GRE or turbo spin echo (TSE) acquisitions for planar reconstructions and/or volumetric analysis of tumors.**
- **Basic imaging of the spine should include sagittal and axial T2-weighted and post-contrast T1-weighted images of the entire neural axis. Additional sequences such as high-resolution heavily T2-weighted images, 3D balanced steady-state free precession (bSSFP) sequence (CISS/FIESTA-C), and/or DWI may be helpful[1,7] (see Table 2 [PGLIO-A 3B of 4])**
  - **These should be utilized to evaluate for infiltrative disease within the spinal cord as well as leptomeningeal spread of neoplasm.**
  - **Sagittal slices should be ≤3 mm and axial slices may be 3- to 4-mm slices.**
  - **Preoperative spine imaging should be performed at the time of brain imaging, because many children require sedation to tolerate the examination and to prevent potential confusion for blood products in the spinal canal in the postoperative setting.**
  - **Postoperative spine MRIs should be delayed to occur at least 10 to 14 days postoperatively, if evaluating for leptomeningeal spread of neoplasm to avoid confusion with blood products.**
- **For MRI contrast, group II gadolinium-based contrast agents (GBCAs) are recommended for use given the potential of higher gadolinium retention with linear GBCAs.[6]**
- **Follow-up studies of the brain and spine should be performed at intervals defined by the treatment algorithms. More frequent imaging may be necessary if indicated by the treating physician in the event of clinical deterioration or evolving imaging findings that are concerning for recurrent or residual disease.**
  - **Longitudinal follow-up studies may be complemented by MR perfusion or MR spectroscopy, if those techniques are available, to assess response to therapy or to evaluate for progression, pseudoprogression, or radiation necrosis.**

[a] Some imaging modalities or techniques may not be available at all institutions.

Continued
References

Note: All recommendations are category 2A unless otherwise indicated.

Version 1.2026, 11/25/25 © 2025 National Comprehensive Cancer Network® (NCCN®), All rights reserved. NCCN Guidelines® and this illustration may not be reproduced in any form without the express written permission of NCCN.

PLEASE NOTE that use of this NCCN Content is governed by the End-User License Agreement, and you MAY NOT distribute this Content or use it with any artificial intelligence model or tool.
Printed by A. S. M. FAZLUL KARIM CHOWDHURY on 4/20/2026 3:38:59 AM. Copyright © 2026 National Comprehensive Cancer Network, Inc. All Rights Reserved.

PRINCIPLES OF NEUROIMAGING[a]

CT of the Brain (with contrast or with and without contrast)

- Can be used for rapid assessment in the acute setting and for the evaluation of acute intracranial hemorrhage, ventriculomegaly, and shunt-related complications
- Recommended in those patients in whom an MRI is not available or contraindicated because of unsafe implants or foreign bodies
- Noncontrast CT is generally sufficient to rule out acute intracranial abnormality. Patients should subsequently undergo MRI unless contraindicated or not available. In those cases, CT with contrast may be obtained to evaluate the mass, understanding it has limited sensitivity compared to MRI.[6]
- Benefits: Shorter acquisition time; generally no sedation is needed; ideal in acutely emergent or immediate postoperative settings; and sensitive to acute blood products and calcium
- Limitations: Ionizing radiation; limited soft-tissue contrast; limited evaluation of metastatic disease; and metal causes streak artifact, which limits evaluation

MR Perfusion[6,8-10]: Measures cerebral blood volume and/or cerebral blood flow in neoplasms; choice of various techniques (dynamic susceptibility contrast-enhanced [DSC] vs. dynamic contrast-enhanced [DCE] vs. arterial spin labeling [ASL] perfusion) will depend upon user availability and preference

- May be helpful for grading neoplasms, assessing response to therapy, identifying malignant degeneration and pseudoprogression, distinguishing radiation necrosis from recurrent neoplasm, and choosing biopsy site
- Limitations: Reliability degraded by adjacent metal, blood byproducts, air, and bone/soft tissue interface; other general limitations of MRI are as previously listed

MR Spectroscopy[6,10,11]: Assess metabolites of neoplasms (choice of single voxel vs. multivoxel spectroscopy will depend on user preference and availability)

- May be helpful for grading neoplasms, assessing response to therapy, identifying malignant degeneration and pseudoprogression, distinguishing radiation necrosis from recurrent neoplasm, and choosing biopsy site
- Limitations: Complex acquisition technique and post-processing that benefits from expertise; long acquisition times; requires nonstandard acquisition and post-processing; reliability degraded by adjacent metal, blood byproducts, and bone/soft tissue/air interfaces

PET Studies: Assess tumor biology by using tracers with distinct mechanisms of uptake, allowing differentiation of different biological processes within the tumor.

- May be useful in tumor delineation, differentiating between neoplasm and radiation necrosis, tumor grading, or identifying a more aggressive focus for biopsy
- Limited spatial resolution compared to brain CT and MRI; heterogenous availability of radioisotopes; and additional radiation exposure

Supplemental Imaging for Preoperative Planning:

- Isotropic volumetric MRI to accurately localize the neoplasms by coregistering the data with intraoperative guidance software; often complemented with isotropic CT studies to improve localization[6]
- Functional MRI studies can be used to depict spatial relationships between eloquent cortex (eg, regions of the brain primarily responsible for speech, vision, and motor and sensory function) and the neoplasms to serve as a road map and promote safe resections[6]
- Diffusion tensor imaging (DTI) with tractography may also be used to localize major white matter tracts underlying the eloquent cortex that could also compromise vital functions if injured during surgery[6]

Continued
References

[a] Some imaging modalities or techniques may not be available at all institutions.

Note: All recommendations are category 2A unless otherwise indicated.

Version 1.2026, 11/25/25 © 2025 National Comprehensive Cancer Network® (NCCN®), All rights reserved. NCCN Guidelines® and this illustration may not be reproduced in any form without the express written permission of NCCN.

PLEASE NOTE that use of this NCCN Content is governed by the End-User License Agreement, and you MAY NOT distribute this Content or use it with any artificial intelligence model or tool.
Printed by A. S. M. FAZLUL KARIM CHOWDHURY on 4/20/2026 3:38:59 AM. Copyright © 2026 National Comprehensive Cancer Network, Inc. All Rights Reserved.

PRINCIPLES OF NEUROIMAGING[a,b]

TABLE 1: Recommended MRI Sequences for Evaluation of Pediatric Brain Tumors

	Sequence	Plane	Slice Thickness (mm)	Gap	Minimum In-plane Resolution	Approximate Acquisition Time (minutes)	Comments
	3D T1 IR-GRE (MPRAGE/SPGR/TFE) or 3D T1 TSE (SPACE/CUBE/VISTA)	Sagittal or axial	1–1.5	0	1 × 1 mm	5–6	Can use either 3D technique
	DWI with ADC Single-shot or multi-shot EPI; *b* value of 0 and 1000	Axial	≤4	0	2 × 2 mm	3–5	Can substitute with DTI
	SWI or GRE	Axial Axial	≤4 ≤4	0 0	1 × 1 mm 1 × 1 mm	3–5	SWI preferred over GRE if available
Contrast administration[c]							
	T2 TSE/FSE	Axial or coronal	≤4	0	1 × 1 mm	3–5	Can be done pre- or post-contrast
	3D T1 IR-GRE (MPRAGE/SPGR/FFE/TFE) or 3D T1 TSE (SPACE/CUBE/VISTA)	Sagittal or axial	1–1.5	0	1 × 1 mm	5–6	Same technique that was used pre-contrast; axial plane for surgical navigation
	T1 TSE/FSE	Axial or coronal	1.0	0%–10%	1 × 1 mm	3–5	Both axial and coronal may be done if 3D T1 sequence not available or degraded by motion
	3D T2 FLAIR or T2 FLAIR TSE/FSE	Sagittal Axial	1–1.5 ≤4	0 0	1 × 1 mm 1 × 1 mm	5–6 4–5	3D preferred over 2D if available

Note: 3D T1 IR-GRE gradient echo: MPRAGE = Siemens; Fast SPGR = GE; TFE = Philips. 3D T1 TSE/FSE: SPACE = Siemens; CUBE = GE; VISTA = Philips. NEX (number of excitations or averages) ≥1. Parallel imaging up to 2×.
Abbreviations: 3D, three-dimensional; ADC, apparent diffusion coefficient; DTI, diffusion tensor imaging; DWI, diffusion-weighted imaging; EPI, echo-planar imaging; FLAIR, fluid-attenuated inversion recovery; GRE, gradient-recalled echo; IR-GRE, inversion recovery gradient-recalled echo; SWI, susceptibility-weighted imaging; TSE/FSE turbo spin echo/fast spin echo.

[a] Some imaging modalities or techniques may not be available at all institutions.
[b] Adapted with permission from Jaju A, Li Y, Dahmoush H, et al. Imaging of pediatric brain tumors: A COG Diagnostic Imaging Committee/SPR Oncology Committee/ASPNR White Paper. Pediatr Blood Cancer 2023;70:Suppl 4(Suppl 4):e30147.
[c] The order of post-contrast sequences should be kept consistent.

Note: All recommendations are category 2A unless otherwise indicated.

Continued

Version 1.2026, 11/25/25 © 2025 National Comprehensive Cancer Network® (NCCN®), All rights reserved. NCCN Guidelines® and this illustration may not be reproduced in any form without the express written permission of NCCN.

PLEASE NOTE that use of this NCCN Content is governed by the End-User License Agreement, and you MAY NOT distribute this Content or use it with any artificial intelligence model or tool.
Printed by A. S. M. FAZLUL KARIM CHOWDHURY on 4/20/2026 3:38:59 AM. Copyright © 2026 National Comprehensive Cancer Network, Inc. All Rights Reserved.

PRINCIPLES OF NEUROIMAGING[a,d]

TABLE 2: Recommended MRI Sequences for Evaluating Spinal Metastatic Disease in Pediatric Brain Tumor

Plane	Sequence	Contrast Phase	Coverage	Recommendations	Comments
Sagittal	T1W, 2D SE/TSE[e]	Post-contrast	Entire spine	Required	1. Slice thickness ≤3 mm (≤10% slice gap) 2. The z-axis FOV can be covered by 1, 2, or 3 different sequences based on the length of the vertebral column 3. T1 FLAIR is suggested to decrease CSF pulsation artifact
Axial	A. T1W, 2D SE/TSE[e] or B. T1W, 3D gradient[e,f]	Post-contrast	Entire spine	Required	A: Slice thickness ≤4 mm with ≤10% gap B: ≤10% slice gap
Axial or sagittal	T2W, 2D SE/TSE	Pre- or post-contrast	Entire spine	Encouraged	Slice thickness ≤4 mm for axial and ≤3 mm for sagittal with ≤10% gap
Sagittal or coronal	Heavily T2W 3D myelography sequence[g]	Pre- or post-contrast	Entire spine or lumbar region	Encouraged	
Sagittal	DWI[h]	Pre- or post-contrast[i]	Entire spine	Optional	Sagittal DWI can be more sensitive for leptomeningeal metastases from embryonal tumors
Sagittal	T1W, 2D SE/TSE	Pre-contrast	Entire spine	Optional	Slice thickness ≤3 mm, with ≤10% gap
Sagittal	2D STIR	Pre-contrast	Entire spine	Optional	Slice thickness ≤3 mm, with ≤10% gap

Note: Smaller b value (b = 800 or 500) and minimized frequency encoding are options for better signal-to-noise ratio.
Abbreviations: DWI, diffusion-weighted imaging; FLAIR, fluid-attenuated inversion recovery; FOV, field of view; SE, spin echo; STIR, short tau inversion recovery; T1W, T1-weighted imaging; TSE, turbo spin echo.

[a] Some imaging modalities or techniques may not be available at all institutions.
[d] Adapted with permission from Rogers SN, Udayasankar U, Pruthi S, et al. Imaging of pediatric spine and spinal cord tumors: A COG Diagnostic Imaging Committee/SPR Oncology Committee/ASPNR White Paper. Pediatr Blood Cancer 2023;70:Suppl 4(Suppl 4):e30150.
[e] Fat saturation may improve the contrast between drop metastases and adjacent epidural fat; however, fat saturation may cause artifact on some MRI scanners. Therefore, this should be performed according to institutional preference.
[f] Volume interpolated GRE sequences (VIBE for Siemens, LAVA for GE, THRIVE for Phillips, TIGRE for Hitachi, and 3D QUICK for Toshiba) are preferred.
[g] Balanced steady-state free precession sequence (CISS for Siemens, FIESTA-C for GE, and DRIVE for Phillips) is preferred.
[h] Spine DWI imaging needs optimization of the DWI sequences. RESOLVE DWI technique or PROPELLER/BLADE DWI methods are preferred for spine imaging compared to the standard single-shot DWI technique.
[i] Some hospitals may not perform post-contrast imaging.

Note: All recommendations are category 2A unless otherwise indicated.

Version 1.2026, 11/25/25 © 2025 National Comprehensive Cancer Network® (NCCN®), All rights reserved. NCCN Guidelines® and this illustration may not be reproduced in any form without the express written permission of NCCN.

PLEASE NOTE that use of this NCCN Content is governed by the End-User License Agreement, and you MAY NOT distribute this Content or use it with any artificial intelligence model or tool.
Printed by A. S. M. FAZLUL KARIM CHOWDHURY on 4/20/2026 3:38:59 AM. Copyright © 2026 National Comprehensive Cancer Network, Inc. All Rights Reserved.

REFERENCES

[1] Erker C, Tamrazi B, Poussaint TY, et al. Response assessment in paediatric high-grade glioma: recommendations from the Response Assessment in Pediatric Neuro-Oncology (RAPNO) working group. Lancet Oncol 2020;21:e317-e329. Erratum in: Lancet Oncol 2020;21:e372.
[2] Cooney TM, Cohen KJ, Guimaraes CV, et al. Response assessment in diffuse intrinsic pontine glioma: recommendations from the Response Assessment in Pediatric Neuro-Oncology (RAPNO) working group. Lancet Oncol 2020;21:e330-e336.
[3] Jaspan T, Morgan PS, Warmuth-Metz M, et al. Response assessment in pediatric neuro-oncology: Implementation and expansion of the RANO criteria in a randomized phase II trial of pediatric patients with newly diagnosed high-grade gliomas. AJNR Am J Neuroradiol 2016;37:1581-1587.
[4] Ellingson BM, Bendszus M, Boxerman J, et al. Consensus recommendations for a standardized brain tumor imaging protocol in clinical trials. Neuro Oncol 2015;17:1188-1198.
[5] Subramanian S, Ahmad T. Childhood Brain Tumors. StatPearls [Internet]. Treasure Island (FL): StatPearls Publishing;2023.
[6] Jaju A, Li Y, Dahmoush H, et al. Imaging of pediatric brain tumors: A COG Diagnostic Imaging Committee/SPR Oncology Committee/ASPNR White Paper. Pediatr Blood Cancer 2023;70 Suppl 4:e30147.
[7] Rogers SN, Udayasankar U, Pruthi S, et al. Imaging of pediatric spine and spinal cord tumors: A COG Diagnostic Imaging Committee/SPR Oncology Committee/ASPNR White Paper. Pediatr Blood Cancer 2023;70 Suppl 4:e30150.
[8] Wan B, Wang S, Tu M, et al. The diagnostic performance of perfusion MRI for differentiating glioma recurrence from pseudoprogression: A meta-analysis. Medicine (Baltimore) 2017;96:e6333.
[9] Barajas RF Jr, Chang JS, Segal MR, et al. Differentiation of recurrent glioblastoma multiforme from radiation necrosis after external beam radiation therapy with dynamic susceptibility-weighted contrast-enhanced perfusion MR imaging. Radiology 2009;253:486-496.
[10] van Dijken BRJ, van Laar PJ, Holtman GA, van der Hoorn A. Diagnostic accuracy of magnetic resonance imaging techniques for treatment response evaluation in patients with high-grade glioma, a systematic review and meta-analysis. Eur Radiol 2017;27:4129-4144.
[11] Zhang H, Ma L, Wang Q, et al. Role of magnetic resonance spectroscopy for the differentiation of recurrent glioma from radiation necrosis: a systematic review and meta-analysis. Eur J Radiol 2014;83:2181-2189.

Note: All recommendations are category 2A unless otherwise indicated.

Version 1.2026, 11/25/25 © 2025 National Comprehensive Cancer Network® (NCCN®), All rights reserved. NCCN Guidelines® and this illustration may not be reproduced in any form without the express written permission of NCCN.

PLEASE NOTE that use of this NCCN Content is governed by the End-User License Agreement, and you MAY NOT distribute this Content or use it with any artificial intelligence model or tool.
Printed by A. S. M. FAZLUL KARIM CHOWDHURY on 4/20/2026 3:38:59 AM. Copyright © 2026 National Comprehensive Cancer Network, Inc. All Rights Reserved.

PRINCIPLES OF NEUROPATHOLOGY

The standard practice for tumor classification should involve integration of histologic and molecular features, as per the World Health Organization (WHO) 2021 Classification of Tumors of the Central Nervous System. A general workflow for processing of tissue and tumor characterization using histologic, immunohistochemical (IHC), and molecular data is presented. However, this is not meant to serve as an exhaustive algorithm for diagnosis and classification of the multitude of subtypes of pediatric diffuse high-grade gliomas that have presently been described.

Standard Histopathologic Examination and Classification

Histologic and IHC examination of the tumor should be performed. Care should be taken to conserve tissue, and IHC studies for molecular markers may be skipped in lieu of submitting tissue directly for molecular studies in cases where the specimen is scant. Commonly used IHC markers for molecular alterations, and broad indications for using them, are presented below. Molecular alterations demonstrated by IHC may require confirmation by molecular methods (Molecular Characterization [PGLIO-B 2 of 4]).

Commonly Used IHC Markers for High-Grade Glial Tumors

- ***BRAF* V600E (particularly if epithelioid or piloid histology): Potentially therapeutically actionable**
- ***H3* K27me3 (particularly for midline, diffuse glial tumors[1]): Loss (negativity) is diagnostic of diffuse midline glioma, *H3* K27-altered, WHO grade 4, with fulfillment of appropriate histologic parameters, particularly with a supportive molecular profile. Should be used in conjunction with *H3* K27M, in which positivity is also diagnostic of this entity in the appropriate context**
- ***INI1* (*SMARCB1*) rhabdoid morphology**
- ***IDH1* R132H (particularly for adolescent and young adult [AYA] patients): Positivity is diagnostic of an *IDH1/2*-mutant diffuse glioma including oligodendroglioma, *IDH1/2*-mutant and 1p/19q-codeleted, and astrocytoma, *IDH1/2*-mutant. These tumors are considered to be adult-type diffuse gliomas and are beyond the scope of these guidelines. Please refer to the adult NCCN Guidelines for Central Nervous System Cancers.**

Limited Tissue Sample/Specimen

- **When tissue is limited, recommend obtaining the following if possible:**
  - **Hematoxylin and eosin (H&E) histology**
  - **Limited IHC panel**
  - **Next-generation sequencing (NGS)**
  - **Methylation profiling**
- **Limited IHC panels should only use stains that would provide essential diagnostic information; in cases of particularly limited tissue, stains for mutations (such as *IDH1* R132H or *BRAF* V600E) already covered by NGS can also be omitted if redundant.**

Continued
References

Note: All recommendations are category 2A unless otherwise indicated.

Version 1.2026, 11/25/25 © 2025 National Comprehensive Cancer Network® (NCCN®), All rights reserved. NCCN Guidelines® and this illustration may not be reproduced in any form without the express written permission of NCCN.

PLEASE NOTE that use of this NCCN Content is governed by the End-User License Agreement, and you MAY NOT distribute this Content or use it with any artificial intelligence model or tool.
Printed by A. S. M. FAZLUL KARIM CHOWDHURY on 4/20/2026 3:38:59 AM. Copyright © 2026 National Comprehensive Cancer Network, Inc. All Rights Reserved.

PRINCIPLES OF NEUROPATHOLOGY

Molecular Characterization

- **Pediatric diffuse high-grade gliomas comprise a rare, but biologically diverse group of tumors. In adults, molecular workup has remained relatively simple, with focus on distinguishing *IDH*-mutant from *IDH*-wild-type gliomas. However, in the majority of pediatric tumors, there exists a high degree of histologic overlap and non-specificity of histologic features amongst the numerous recognized pathologic entities, and underlying molecular alterations in pediatric gliomas are distinct from those seen in adults. This underscores the immense importance of molecular testing in pediatric tumor diagnostics.**
  - **Molecular testing in many cases is critical to diagnosis, distinguishing high-grade tumors from lower grade counterparts, and uncovering alterations that have been demonstrated to be prognostically relevant[2-7] (Table 1, PGLIO-B 3 of 4).**
  - **While targeted therapies are still limited, clinical trial stratification is becoming increasingly dependent on molecular characterization.**
- **In light of the number of genes of interest, in conjunction with the many types of recurrent alterations (including point mutations, insertion/deletions, copy number variations, and fusions), broad molecular testing is required for comprehensive classification of pediatric diffuse high-grade gliomas:**
  - **Copy number and fusion detection:**
    - **NGS with fusion detection (ie, *ROS1*, *MET*, *NTRK1/2/3*, *ALK*, *FGFR1/2/3*)**
    - **RNA sequencing**
    - **High-resolution copy number array**
  - **DNA methylation-based analysis may offer objective, more precise tumor classification; however, it should not be used as a first-line molecular test**
- **In the pediatric population, dedicated germline testing should be strongly considered in the appropriate clinical context, recognizing that not all sequencing assays readily distinguish between germline and somatic variants.[8,9]**

Continued
References

Note: All recommendations are category 2A unless otherwise indicated.

Version 1.2026, 11/25/25 © 2025 National Comprehensive Cancer Network® (NCCN®), All rights reserved. NCCN Guidelines® and this illustration may not be reproduced in any form without the express written permission of NCCN.

PLEASE NOTE that use of this NCCN Content is governed by the End-User License Agreement, and you MAY NOT distribute this Content or use it with any artificial intelligence model or tool.
Printed by A. S. M. FAZLUL KARIM CHOWDHURY on 4/20/2026 3:38:59 AM. Copyright © 2026 National Comprehensive Cancer Network, Inc. All Rights Reserved.

PRINCIPLES OF NEUROPATHOLOGY

Table 1[a,6,7,10]

Molecular Alterations of Significance in Pediatric Gliomas	Molecular Alterations Consistent with "High Grade" in Pediatric Diffuse Gliomas
• *IDH1/2* mutations with or without 1p/19q-codeletion (adult-type gliomas) • *H3* K27Me3 loss (epigenetic loss of trimethylation at this site) • *H3-3A* K28M mutation (historic synonyms *H3.3* K27M and *H3F3A* p.K28M) • *H3C2* p.K28M mutation (historic synonyms *H3.1* K27M and *HIST1H3B* K27M) • *H3C3* p.K28M mutation (historic synonym *HIST1H3C* K27M) • *H3* G34 mutation • *MYB* fusion • *MYBL1* fusion • *BRAF* V600E mutation • *BRAF* fusion • *BCOR* internal tandem duplication • *BCOR::EP300* fusion • *EGFR* mutations • *FGFR1* TKD-duplicated • *FGFR1* mutation • *FGFR1* fusion • *FGFR2* fusion • *NTRK1/2/3* fusion • *ALK* fusion • *ROS1* fusion • *MET* fusion • Other MAPK pathway alterations • *NF1* mutations	• Homozygous deletion of *CDKN2A/2B* • *TP53* mutation • Amplification of *PDGFRA*, *EGFR*, *MET*, or *MYCN* • Complex karyotype • *H3* K27Me3 loss by IHC/*H3* K27M mutation by sequencing–informs a grade 4 neoplasm in appropriate context • DNA MMR deficiency (*MLH1*, *MSH2*, *MSH6,* or *PMS2* mutations and *MLH1* hypermethylation) • *POLE* mutation • *H3* G34 mutation

[a] Human gene nomenclature evolves over time. For a current list of gene nomenclature, please refer to the HGNC database, Human Genome Organization (HUGO) Gene Nomenclature Committee site: https://www.genenames.org.

References

Note: All recommendations are category 2A unless otherwise indicated.

Version 1.2026, 11/25/25 © 2025 National Comprehensive Cancer Network® (NCCN®), All rights reserved. NCCN Guidelines® and this illustration may not be reproduced in any form without the express written permission of NCCN.

PLEASE NOTE that use of this NCCN Content is governed by the End-User License Agreement, and you MAY NOT distribute this Content or use it with any artificial intelligence model or tool.
Printed by A. S. M. FAZLUL KARIM CHOWDHURY on 4/20/2026 3:38:59 AM. Copyright © 2026 National Comprehensive Cancer Network, Inc. All Rights Reserved.

PRINCIPLES OF NEUROPATHOLOGY
REFERENCES

[1] WHO classification of tumours series, 5th ed; vol 6. Available from: https://tumourclassification.iarc.who.int/chapters/45.
[2] Ryall S, Zapotocky M, Fukuoka K, et al. Integrated molecular and clinical analysis of 1,000 pediatric low-grade gliomas. Cancer Cell 2020;37:569-583.
[3] Clarke M, Mackay A, Ismer B, et al. Infant high-grade gliomas comprise multiple subgroups characterized by novel targetable 3 gene fusions and favorable outcomes. Cancer Discov 2020;10:942-963.
[4] Guerreiro Stucklin AS, Ryall S, Fukuoka, et al. Alterations in ALK/ROS1/NTRK/MET drive a group of infantile hemispheric gliomas. Nat Commun 2019;10:4343.
[5] Johnson A, Severson E, Gay L, et al. Comprehensive genomic profiling of 282 pediatric low- and high-grade gliomas reveals genomic drivers, tumor mutational burden, and hypermutation signatures. Oncologist 1017;22:1478-1490.
[6] Ellison DW, Hawkins C, Jones DWT, et al. cIMPACT-NOW update 4: diffuse gliomas characterized by MYB, MYBL1, or FGFR1 alterations or $BRAF^{V600E}$ mutation. Acta Neuropathol 2019;137:683-687.
[7] Louis DN, Wesseling P, Aldape K, et al. cIMPACT-NOW update 6: new entity and diagnostic principle recommendations of the cIMPACT-Utrecht meeting on future CNS tumor classification and grading. Brain Pathol 2020;30:844-856.
[8] Zhang J, Walsh MF, Wu G, et al. Germline mutations in predisposition genes in pediatric cancer. N Engl J Med 2015;373:2336-2346.
[9] Akhavanfard S, Padmanabhan R, Yehia L, et al. Comprehensive germline genomic profiles of children, adolescents and young adults with solid tumors. Nat Commun 2020;11:2206.
[10] Das A, MacFarland SP, Meade J, et al. Clinical updates and surveillance recommendations for DNA replication repair deficiency syndromes in children and young adults. Clin Cancer Res 2024;30:3378-3387.

Note: All recommendations are category 2A unless otherwise indicated.

Version 1.2026, 11/25/25 © 2025 National Comprehensive Cancer Network® (NCCN®), All rights reserved. NCCN Guidelines® and this illustration may not be reproduced in any form without the express written permission of NCCN.

PLEASE NOTE that use of this NCCN Content is governed by the End-User License Agreement, and you MAY NOT distribute this Content or use it with any artificial intelligence model or tool.
Printed by A. S. M. FAZLUL KARIM CHOWDHURY on 4/20/2026 3:38:59 AM. Copyright © 2026 National Comprehensive Cancer Network, Inc. All Rights Reserved.

PRINCIPLES OF SURGERY

Preoperative Assessment

- Perform labs, imaging, and multidisciplinary consult.
- Treat emergent situations prior to further investigative studies or interventions.
- Consider medical management to treat focal neurologic deficits, seizure, and pain (ie, dexamethasone, anti-epileptics, acetaminophen).
- Avoid medications that may alter the patient's neurologic examination or increase surgical risks (eg, narcotics).
- Patients should undergo neuroaxis imaging.
- Consider advanced imaging in cases where patients may benefit from it.
- Outside of emergent clinical presentations, multidisciplinary case discussion should be utilized for treatment planning and optimization of patient care. Treatment decision planning should include radiation oncology, neurosurgery, radiology, and oncology/neuro-oncology.
- Consider physical therapy/occupational therapy and sleep and swallow assessments to assist with comorbidity management.
- Consider referral to a child life social worker for family/patient support.

Surgical Procedure

- Alleviate symptoms related to increased intracranial pressure or tumor mass effect, increase survival, and decrease corticosteroid dose requirements.
- Obtain adequate and optimal tissue for a pathologic diagnosis and molecular genetic characterization.
- In pediatric diffuse high-grade gliomas, a meta-analysis has demonstrated an association between greater extent of resection and improved overall survival.[1]
- Nearly all diffuse high-grade gliomas recur. Re-resection at the time of recurrence may improve outcomes. As in adult patients with diffuse high-grade gliomas, tumor involvement in specific critical brain areas and poor PS score may be associated with unfavorable re-resection outcomes.

Postoperative Management

- Monitor for signs and symptoms of increased intracranial pressure. Either ventriculoperitoneal (VP) shunt or endoscopic third ventriculostomy (ETV) are acceptable CSF diversion techniques.
- Early consultation with radiation oncology and neuro-oncology is recommended.
- Consider anti-seizure medications for seizure prophylaxis.[2] Early consultation with neurology is recommended, in cases involving longstanding or multiple-recurrent seizures.
- Early physical therapy, occupational therapy, and speech therapy intervention are recommended in cases of motor dysfunction.
- Consider referral to a child life social worker for family/patient support.

[1] Hatoum R, Chen JS, Lavergne P, et al. Extent of tumor resection and survival in pediatric patients with high-grade gliomas: A systematic review and meta-analysis. JAMA Netw Open 2022;5:e2226551.
[2] Greenhalgh J, Weston J, Dendar Y, et al. Antiepileptic drugs as prophylaxis for postcraniotomy seizures. Cochrane Database Syst Rev 2020;4:CD007286.

Note: All recommendations are category 2A unless otherwise indicated.

Version 1.2026, 11/25/25 © 2025 National Comprehensive Cancer Network® (NCCN®), All rights reserved. NCCN Guidelines® and this illustration may not be reproduced in any form without the express written permission of NCCN.

PLEASE NOTE that use of this NCCN Content is governed by the End-User License Agreement, and you MAY NOT distribute this Content or use it with any artificial intelligence model or tool.
Printed by A. S. M. FAZLUL KARIM CHOWDHURY on 4/20/2026 3:38:59 AM. Copyright © 2026 National Comprehensive Cancer Network, Inc. All Rights Reserved.

PRINCIPLES OF RADIATION THERAPY MANAGEMENT

Pediatric Diffuse High-Grade Glioma (except diffuse midline glioma and diffuse intrinsic pontine glioma)

- **Adjuvant (dose, timing)**
  - **50.4–54 Gy with a cone-down to 59.4 to 60 Gy in 1.8 to 2.0 Gy fractions for newly diagnosed disease.**
    - **Simultaneous integrated boost (SIB) techniques can be considered to deliver 1.8 and 2.0 Gy x 30 fractions concurrently to 54 and 60 Gy.**
  - **Initiation of RT is recommended whenever a patient has recovered from surgery and within 8 weeks after surgical resection.**

- **Reirradiation (dose, timing)**
  - **The majority of data are from adult high-grade glioma studies of recurrent glioblastoma multiforme (GBM).**
  - **Studies have suggested improvements in progression-free survival (PFS), but limited overall survival gains.**
  - **Multiple dosing schedules have been reported for reirradiation and should be performed with a conformal technique.**
    - **30–35 Gy in 5–15 fractions (eg, 30 Gy in 5 fractions, or 35 Gy in 10 fractions)**
    - **54–60 Gy in 30 fractions (long interval from prior RT)**
    - **Stereotactic radiosurgery (SRS) with a median marginal dose of 16 Gy**

- **Principles of Radiation Therapy (include simulation, treatment planning, and normal tissue RT constraints)**
  - **Child life specialists, audio and video distraction techniques, and other pediatric-friendly interventions can improve pediatric tolerance of RT without anesthesia.**
  - **Proton therapy may be considered for patients with better prognoses (eg, *IDH1*-mutated tumors, 1p/19q-codeleted, younger age).**
  - **In most instances intensity-modulated RT (IMRT) allows reduction of risk or magnitude of side effects from treatment.**
  - **Patients should be placed supine with immobilization. CT simulation for treatment planning should include ≤0.25 cm slice thickness. Volumetric CT simulation for treatment planning is recommended.**
  - **Image-guided RT (IGRT) may be used to ensure daily setup accuracy.**
  - **Tumor volumes are best defined using pre- and postoperative MRI imaging using both post-contrast T1 volumetric and T2/FLAIR sequences to define gross tumor volume (GTV). Obtain RT treatment planning MRI to account for any postoperative evolution of tumor and/or surgical changes. Volumetric T2/FLAIR and DTI (for white matter tracts) are optional but can be helpful sequences to define GTV.**
  - **GTV1 includes the enhancing and non-enhancing areas of tumor both pre- and post-resection. GTV1 should take into account changes in brain anatomy post-resection and surgical tracts for deep tumors may be excluded if not involved pre-surgery.**
  - **GTV2 will include residual tumor post-resection. It will typically include the resection bed. For no residual tumor GTV1 = GTV2.**
  - **Clinical target volume (CTV) 1 is an isotropic 1- to 2-cm expansion of GTV1, with the larger margins along white matter tracts.**
  - **CTV2 is an isotropic expansion of 0.5–1 cm on GTV2.**
  - **PTV1/2 is an isotropic expansion that is institution-specific, but typically 3–5 mm, and dependent on frequency and modality of imaging, and size of the targets. Planning target volume (PTV) definition in proton therapy may be beam-specific or replaced by robustness testing.**
  - **PTV1 = 50.4–54 Gy**
  - **PTV2 = 59.4–60 Gy**
  - **Maximal PTV coverage should be balanced against normal tissue tolerances (PGLIO-D 3 of 3).**
  - **Accepted normal tissue constraints should be used, and although the prognosis of these patients is often poor, ALARA (as low as reasonably achievable) principles still apply to the lenses, retina, pituitary gland/hypothalamus, cochlea, lacrimal glands, hippocampi, temporal lobes, spinal cord, and uninvolved brain.**

Note: All recommendations are category 2A unless otherwise indicated.

Continued

Version 1.2026, 11/25/25 © 2025 National Comprehensive Cancer Network® (NCCN®), All rights reserved. NCCN Guidelines® and this illustration may not be reproduced in any form without the express written permission of NCCN.

PLEASE NOTE that use of this NCCN Content is governed by the End-User License Agreement, and you MAY NOT distribute this Content or use it with any artificial intelligence model or tool.
Printed by A. S. M. FAZLUL KARIM CHOWDHURY on 4/20/2026 3:38:59 AM. Copyright © 2026 National Comprehensive Cancer Network, Inc. All Rights Reserved.

PRINCIPLES OF RADIATION THERAPY MANAGEMENT

Diffuse Midline Glioma/Diffuse Intrinsic Pontine Glioma

- **Initiation of RT should be considered as soon as possible after diagnosis, given the highly effective nature of this modality for symptom management.**
- **Recommend using IMRT; 3D conformal RT is an acceptable option.**
- **54 Gy in 1.8 Gy fractions (30 total fractions) is recommended; higher doses are now considered non-standard.**
- **An option of hypofractionated RT (39 Gy in 3 Gy fractions [13 total fractions]) is emerging as an alternative treatment to standard fractionation, although data are limited and studies are ongoing to assess the benefit/safety of this approach. This is also being tested in the reirradiation setting.**
- **Palliative reirradiation of 20–30 Gy in 10–12 fractions has been shown to alleviate symptoms related to tumor progression.[1,2]**
- **Tumor volumes**
  - **GTV: Defined as the tumor best demonstrated on MRI. The MRI sequence that best defines the extent of disease should be used. The T2 sequence is usually the most appropriate image to use for GTV definition for these patients.**
  - **CTV: Shall include the GTV with a 1-cm margin in all directions, respecting anatomic barriers to spread.**
  - **PTV: Shall include the CTV with a 0.3- to 0.5-cm margin dependent on immobilization techniques. Exact margins will be left up to the discretion of the treating radiation oncologist and may not be uniform in all dimensions.**

Continued
References

Note: All recommendations are category 2A unless otherwise indicated.

Version 1.2026, 11/25/25 © 2025 National Comprehensive Cancer Network® (NCCN®), All rights reserved. NCCN Guidelines® and this illustration may not be reproduced in any form without the express written permission of NCCN.

PLEASE NOTE that use of this NCCN Content is governed by the End-User License Agreement, and you MAY NOT distribute this Content or use it with any artificial intelligence model or tool.
Printed by A. S. M. FAZLUL KARIM CHOWDHURY on 4/20/2026 3:38:59 AM. Copyright © 2026 National Comprehensive Cancer Network, Inc. All Rights Reserved.

PRINCIPLES OF RADIATION THERAPY MANAGEMENT[3-7]

NORMAL TISSUE CONSTRAINTS[a]

Organs at Risk (OAR)[b]	Pediatric Diffuse High-Grade Glioma Constraints
Eyes	D50% ≤10 Gy D10% ≤35 Gy
Lenses	As low as possible lenses constraint
Optic nerves and chiasm	D50% ≤54 Gy D0.1 cc <56 Gy
Pituitary gland/hypothalamus	Mean dose <25 Gy[c]
Hippocampi	Mean dose <30 Gy[c]
Temporal lobes	No more than 1 cc exceeding 60 Gy, Dmax[d] <65 Gy[c]
Cochlea	D50% <35 Gy when possible; (D50% <20 Gy preferred - single cochlea)[c]
Brainstem	• If photons are used: ▸ D0.1 cc <58.8 Gy ▸ Dmax[d] <60 Gy, D50% <56.7 Gy ▸ If primary is in the brain stem, no limit to D50% • If protons are used for a non-brainstem primary in patient with good prognosis: ▸ Dmax[d] <56.6 Gy ▸ D50% <52.4 Gy
Spinal cord (cervical spinal cord: cranial most 6 cm)	D50% ≤26 Gy D0.1 cc <54 Gy is preferred, but C1C2 cord V54<50% is acceptable
Uninvolved brain (Brain – PTV)	No more than 1% or 1 cc of the tissue outside of either PTV receiving more than 110% of the prescribed dose[e]

[a] The noted normal tissue constraints are per COG ACNS0831, ARAR0331, and ongoing studies (ACNS1723 and ACNS1821).
[b] In general all normal tissues should be as low as reasonably achievable even if the constraint is achieved (ALARA principle). If patient is on a separate clinical trial, ensure that protocol recommendations/normal tissue dose constraints are met.
[c] These constraints are only applicable if not compromising target coverage.
[d] Dmax is defined as 0.03 cc.
[e] Uninvolved brain is defined by the posterior fossa boost volume.

Note: All recommendations are category 2A unless otherwise indicated.

References

Version 1.2026, 11/25/25 © 2025 National Comprehensive Cancer Network® (NCCN®), All rights reserved. NCCN Guidelines® and this illustration may not be reproduced in any form without the express written permission of NCCN.

PLEASE NOTE that use of this NCCN Content is governed by the End-User License Agreement, and you MAY NOT distribute this Content or use it with any artificial intelligence model or tool.
Printed by A. S. M. FAZLUL KARIM CHOWDHURY on 4/20/2026 3:38:59 AM. Copyright © 2026 National Comprehensive Cancer Network, Inc. All Rights Reserved.

PRINCIPLES OF RADIATION THERAPY MANAGEMENT
REFERENCES

[1] Lu VM, Welby JP, Mahajan A, et al. Reirradiation for diffuse intrinsic pontine glioma: a systematic review and meta-analysis. Childs Nerv Syst 2019;35:739-746.
[2] Amsbaugh MJ, Mahajan A, Thall PF, et al. A phase 1/2 trial of reirradiation for diffuse intrinsic pontine glioma. Int J Radiat Oncol Biol Phys 2019;104:144-148.
[3] Hug EB, Pelak M, Frank SJ, et al. A review of particle therapy for skull base tumors: Modern considerations and future directions. Int J Part Ther 2021;8:168-178.
[4] Haas-Kogan D, Indelicato D, Paganetti H, et al. National Cancer Institute workshop on proton therapy for children: Considerations regarding brainstem injury. Int J Radiat Oncol Biol Phys 2018;101:152-168.
[5] Milano MT, Marks LB, Olch AJ, et al. Comparison of risks of late effects from radiation therapy in children versus adults: Insights from the QUANTEC, HyTEC, and PENTEC efforts. Int J Radiat Oncol Biol Phys 2024;119:387-400.
[6] Gentile MS, Yeap BY, Paganetti H, et al. Brainstem injury in pediatric patients with posterior fossa tumors treated with proton beam therapy and associated dosimetric factors. Int J Radiat Oncol Biol Phys 2018;100:719-729.
[7] Mahajan A, Stavinoha PL, Rongthong W, et al. Neurocognitive effects and necrosis in childhood cancer survivors treated with radiation therapy: A PENTEC comprehensive review. Int J Radiat Oncol Biol Phys 2024;119:401-416.

Note: All recommendations are category 2A unless otherwise indicated.

Version 1.2026, 11/25/25 © 2025 National Comprehensive Cancer Network® (NCCN®), All rights reserved. NCCN Guidelines® and this illustration may not be reproduced in any form without the express written permission of NCCN.

PLEASE NOTE that use of this NCCN Content is governed by the End-User License Agreement, and you MAY NOT distribute this Content or use it with any artificial intelligence model or tool.
Printed by A. S. M. FAZLUL KARIM CHOWDHURY on 4/20/2026 3:38:59 AM. Copyright © 2026 National Comprehensive Cancer Network, Inc. All Rights Reserved.

PRINCIPLES OF SYSTEMIC THERAPY[a,b,c,d]
(PARTICIPATION IN A CLINICAL TRIAL IS STRONGLY ENCOURAGED)

	Preferred	Other Recommended	Useful in Certain Circumstances
Adjuvant Therapy	**RT + concurrent Temozolomide followed by adjuvant Lomustine/ Temozolomide[1]**	**RT + concurrent Temozolomide followed by adjuvant Temozolomide[2]** **Age <3 years:** • Chemotherapy only ▸ Cisplatin/Cyclophosphamide/Etoposide/ Vincristine[3] ▸ Carboplatin/Temozolomide/Vincristine[4] • Targeted therapy only ▸ Targeted therapy including, but not limited to the following: – If *BRAF* V600E mutated: ▪ Dabrafenib/Trametinib[5] ▪ Vemurafenib[6] – If *NTRK* fusion-positive: ▪ Larotrectinib[7] ▪ Entrectinib[8] ▪ Repotrectinib[9] – If hypermutant tumor: ▪ Nivolumab[10,11] ▪ Pembrolizumab[e,12] – If *ALK*-rearrangement positive: ▪ Lorlatinib[13] ▪ Alectinib[14]	**RT ± concurrent Temozolomide[1,2] followed by adjuvant targeted therapy including, but not limited to the following:** **If *BRAF* V600E mutated:** • Dabrafenib/Trametinib[5] • Vemurafenib[6] **If *NTRK* fusion-positive:** • Larotrectinib[7] • Entrectinib[8] • Repotrectinib[9] **If hypermutant tumor:** • Nivolumab[10,11] • Pembrolizumab[e,12] **If *ALK*-rearrangement positive:** • Lorlatinib[13] • Alectinib[14]

[a] Regimens and recommendations on this page are for those patients who elect not to participate in clinical trials.
[b] Monitor (labs and/or imaging) as clinically indicated.
[c] An FDA-approved biosimilar is an appropriate substitute for any recommended systemic biologic therapy in the NCCN Guidelines.
[d] For DMG (pontine location) and DIPG: Clinical trials are preferred and standard RT alone may be considered.
[e] Pembrolizumab and berahyaluronidase alfa-pmph subcutaneous injection may be substituted for IV pembrolizumab. Pembrolizumab and berahyaluronidase alfa-pmph has different dosing and administration instructions compared to IV pembrolizumab.

Note: All recommendations are category 2A unless otherwise indicated.

References

Version 1.2026, 11/25/25 © 2025 National Comprehensive Cancer Network® (NCCN®), All rights reserved. NCCN Guidelines® and this illustration may not be reproduced in any form without the express written permission of NCCN.

PLEASE NOTE that use of this NCCN Content is governed by the End-User License Agreement, and you MAY NOT distribute this Content or use it with any artificial intelligence model or tool.
Printed by A. S. M. FAZLUL KARIM CHOWDHURY on 4/20/2026 3:38:59 AM. Copyright © 2026 National Comprehensive Cancer Network, Inc. All Rights Reserved.

PRINCIPLES OF SYSTEMIC THERAPY[a,b,c]
(PARTICIPATION IN A CLINICAL TRIAL IS STRONGLY ENCOURAGED)

	Preferred	Other Recommended	Useful in Certain Circumstances
Recurrent or Progressive Disease	**Targeted therapy including, but not limited to the following:** **If *BRAF* V600E mutated:** • Dabrafenib/Trametinib[5] • Vemurafenib[6] **If *NTRK*-fusion positive:** • Larotrectinib[7] • Entrectinib[8] • Repotrectinib[9] **If hypermutant tumor:** • Nivolumab[10,11] • Pembrolizumab[e,12] **If *ALK*-rearrangement positive:** • Lorlatinib[13] • Alectinib[14]	• Reirradiation if feasible • Targeted therapy including: ▸ If *H3* K27M-mutated: ◊ Dordaviprone[f,15]	**For palliation:** • Oral Etoposide[16] • Bevacizumab[17] • Nitrosoureas (Lomustine or Carmustine)[1]

[a] Regimens and recommendations on this page are for those patients who elect not to participate in clinical trials.
[b] Monitor (labs and/or imaging) as clinically indicated.
[c] An FDA-approved biosimilar is an appropriate substitute for any recommended systemic biologic therapy in the NCCN Guidelines.
[e] Pembrolizumab and berahyaluronidase alfa-pmph subcutaneous injection may be substituted for IV pembrolizumab. Pembrolizumab and berahyaluronidase alfa-pmph has different dosing and administration instructions compared to IV pembrolizumab.
[f] The FDA approval is based on adult patient data and includes very limited efficacy data in pediatric patients.

Note: All recommendations are category 2A unless otherwise indicated.

References

Version 1.2026, 11/25/25 © 2025 National Comprehensive Cancer Network® (NCCN®), All rights reserved. NCCN Guidelines® and this illustration may not be reproduced in any form without the express written permission of NCCN.

PLEASE NOTE that use of this NCCN Content is governed by the End-User License Agreement, and you MAY NOT distribute this Content or use it with any artificial intelligence model or tool.
Printed by A. S. M. FAZLUL KARIM CHOWDHURY on 4/20/2026 3:38:59 AM. Copyright © 2026 National Comprehensive Cancer Network, Inc. All Rights Reserved.

PRINCIPLES OF SYSTEMIC THERAPY
REFERENCES

[1] Jakacki RI, Cohen KJ, Buxton A, et al. Phase 2 study of concurrent radiotherapy and temozolomide followed by temozolomide and lomustine in the treatment of children with high-grade glioma: a report of the Children's Oncology Group ACNS0423 study. Neuro Oncol 2016;18:1442-1450.
[2] Cohen KJ, Pollack, IF, Zhou T, et al. Temozolomide in the treatment of high-grade gliomas in children: a report from the Children's Oncology Group Neuro Oncol 2011;13:317-323.
[3] Duffner P, Krischer JP, Burger PC, et al. Treatment of infants with malignant gliomas: the Pediatric Oncology Group experience J Neurooncol 1996;28:245-256.
[4] Espinoza JC, Haley K, Patel N, et al. Outcome of young children with high-grade glioma treated with irradiation-avoiding intensive chemotherapy regimens: Final report of the Head Start II and III trials Pediatr Blood Cancer 2016;63:1806-1813.
[5] Toll SA, Tran HN, Cotter J, et al. Sustained response of three pediatric BRAFV600E mutated high-grade gliomas to combined BRAF and MEK inhibitor therapy. Oncotarget 2019;10:555-557.
[6] Nicolaides T, Nazemi K, Crawford J, et al. Phase I study of vemurafenib in children with recurrent or progressive BRAF V600E mutant brain tumors: Pacific Pediatric Neuro-Oncology Consortium study (PNOC-002) Oncotarget 2020;11:1942-1952.
[7] Laetesh TW, DuBois SG, Mascarenhas L, et al. Larotrectinib for paediatric solid tumours harbouring NTRK gene fusions: phase 1 results from a multicentre, open-label, phase 1/2 study. Lancet Oncol 2018;19:705-714.
[8] Desai AV, Robinson GW, Gauvain K, et al. Entrectinib in children and young adults with solid or primary CNS tumors harboring NTRK, ROS1 or ALK aberrations (STARTRK-NG). Neuro Oncol 2022;24:1776-1789.
[9] Solomon BJ, Drilon A, Lin JJ, et al. Repotrectinib in patients (pts) with NTRK fusion-positive (NTRK+) advanced solid tumors, including NSCLC: Update from the phase I/II TRIDENT-1 trial [abstract]. Ann Oncol 2023;34:S787-S788.
[10] Bouffett E, Larouche V, Campbell BB, et al. Immune checkpoint inhibition for hypermutant glioblastoma multiforme resulting from germline biallelic mismatch repair deficiency. J Clin Oncol 2016;34:2206-2211.
[11] Larouche V, Atkinson A, Albrecht S, et al. Sustained complete response of recurrent glioblastoma to combined checkpoint inhibition in a young patient with constitutional mismatch repair deficiency Pediatr Blood Cancer 2018;65:e27389.
[12] Cacciotti C, Choi J, Alexandrescu S, et al. Immune checkpoint inhibition for pediatric patients with recurrent/refractory CNS tumors: a single institution experience J Neurooncol 2020;149:113-122.
[13] Bagchi A, Orr BA, Campagne O, et al. Lorlatinib in a child with ALK-fusion-positive high-grade glioma. N Engl J Med 2021;385:761-763.
[14] Doz F, Casanova M, Koh K-N, et al. Alectinib in children and adolescents with solid or CNS tumors harboring ALK-fusions: Data from the iMATRIX Alectinib Phase I/II open-label, multi-center study [abstract]. Cancer Res 2024;84(Suppl):Abstract CT039.
[15] Arrillaga-Romany I, Gardner SL, Odia Y, et al. ONC201 (Dordaviprone) in Recurrent H3 K27M-Mutant Diffuse Midline Glioma. J Clin Oncol 2024;42:1542-1552.
[16] Needle MN, Molloy PT, Geyer JR, et al. Phase II study of daily oral etoposide in children with recurrent brain tumors and other solid tumors Med Pediatr Oncol 1997;29:28-32.
[17] Grill J, Massimino M, Bouffet E, et al. Phase II, open-label, randomized, multicenter trial (HERBY) of bevacizumab in pediatric patients with newly diagnosed high-grade glioma. J Clin Oncol 2018;36:951-958.

Note: All recommendations are category 2A unless otherwise indicated.

Version 1.2026, 11/25/25 © 2025 National Comprehensive Cancer Network® (NCCN®), All rights reserved. NCCN Guidelines® and this illustration may not be reproduced in any form without the express written permission of NCCN.

PLEASE NOTE that use of this NCCN Content is governed by the End-User License Agreement, and you MAY NOT distribute this Content or use it with any artificial intelligence model or tool.
Printed by A. S. M. FAZLUL KARIM CHOWDHURY on 4/20/2026 3:38:59 AM. Copyright © 2026 National Comprehensive Cancer Network, Inc. All Rights Reserved.

INTRODUCTION TO PEDIATRIC MEDULLOBLASTOMA: CHILDREN AND ADOLESCENTS[1-4]

- **All patients with pediatric medulloblastoma should be treated by a multidisciplinary team with experience managing pediatric CNS tumors.[a] At this time, the pediatric medulloblastoma Guideline refers to children and adolescents ≥3 years of age and ≤21 years of age. Treatment in children <3 years is not covered in this guideline.**
- **Early referral to radiation oncology and pediatric oncology is recommended.**
- **Timely molecular testing is recommended.**

Epidemiology of Pediatric Medulloblastoma

- **Incidence of medulloblastoma among children and adolescents <19 years of age is 0.40 (95% CI, 0.38–0.42) per 100,000 population.**
- **Consists of at least four distinct molecular subtypes. The four most often recognized molecular subtypes include wingless (WNT), sonic hedgehog (SHH), Group 3,[b] and Group 4.[b]**
- **Incidence and subtype vary with age and sex. It is more common among younger children and males.**
- **5-year overall survival is 65%–70%.**
- **Prognostic features: Age at presentation (<3 years), presence of metastatic tumor, extent of resection, molecular subtype, and other molecular features, initial choice, and timing of therapy.**

Risk Factors

- **Inherited predispositions to cancer:**
  - **Li-Fraumeni syndrome: Germline *TP53* gene mutations and/or family history of breast cancer, sarcoma, leukemia, adrenocortical carcinoma, and choroid plexus carcinoma**
  - **Turcot syndrome/Lynch syndrome/CMMRD:**
    - **Associated with colon cancer, medulloblastoma, and high-grade glioma**
    - **Germline mutations in *APC*/FAP locus (more often associated with medulloblastoma), and MMR genes *MSH2*, *MSH6*, *MLH1*, and *PMS2***
  - **Gorlin syndrome [nevoid basal cell carcinoma syndrome (NBCCS)]:**
    - **Multiple basal cell carcinomas, jaw cysts, skeletal abnormalities, pits on palms and soles, and calcifications of dura**
    - **Germline *PTCH1* and *SUFU* mutations**
- **Germline mutations: *BRCA2, PALB2, GPR161, ELP1, CREBBP,* and *EP300***

[a] A multidisciplinary team that includes pediatric oncologists/neuro-oncologists, pediatric radiation oncologists, pathologists with expertise in neuropathology and molecular pathology, pediatric neuroradiologists, and pediatric neurosurgeons is strongly encouraged.
[b] Groups 3 and 4 have been combined and collectively referred to as “Non-WNT/non-SHH" medulloblastoma.

Note: All recommendations are category 2A unless otherwise indicated.

References

Version 1.2026, 11/25/25 © 2025 National Comprehensive Cancer Network® (NCCN®), All rights reserved. NCCN Guidelines® and this illustration may not be reproduced in any form without the express written permission of NCCN.

PLEASE NOTE that use of this NCCN Content is governed by the End-User License Agreement, and you MAY NOT distribute this Content or use it with any artificial intelligence model or tool.
Printed by A. S. M. FAZLUL KARIM CHOWDHURY on 4/20/2026 3:38:59 AM. Copyright © 2026 National Comprehensive Cancer Network, Inc. All Rights Reserved.

INTRODUCTION TO PEDIATRIC MEDULLOBLASTOMA: CHILDREN AND ADOLESCENTS[1-4]

Clinical Presentation

- **Most common symptoms include effects of increased intracranial pressure, such as headache, nausea, and vomiting.**
- **Other presenting symptoms include ataxia, cranial nerve deficits, loss of developmental milestones, and back pain.**

Treatment

- **Treatment for medulloblastoma includes surgery, RT, and chemotherapy.**
- **Goals of surgery include maximal safe resection, reduction of tumor-associated mass effect, relief of hydrocephalus, and obtaining adequate tissue for histologic and molecular classification.**
- **Referral for cancer predisposition evaluation is appropriate for patients with tumors harboring molecular features suggestive of germline predisposition to cancer or if clinical history is consistent with an inherited predisposition to cancer.**
- **If available, enrollment in molecular classification-based clinical trial is encouraged.**
- **Recommend referral to infertility risk/fertility preservation counseling for patients treated with chemotherapy.[5] Also see NCCN Guidelines for Adolescent and Young Adult (AYA) oncology as appropriate.**
- **Craniospinal radiation is not recommended for patients <3 years of age, but radiation-avoiding strategies may be used for patients <3 years of age per the treating physician's discretion.**

Note: All recommendations are category 2A unless otherwise indicated.

References

Version 1.2026, 11/25/25 © 2025 National Comprehensive Cancer Network® (NCCN®), All rights reserved. NCCN Guidelines® and this illustration may not be reproduced in any form without the express written permission of NCCN.

PLEASE NOTE that use of this NCCN Content is governed by the End-User License Agreement, and you MAY NOT distribute this Content or use it with any artificial intelligence model or tool.
Printed by A. S. M. FAZLUL KARIM CHOWDHURY on 4/20/2026 3:38:59 AM. Copyright © 2026 National Comprehensive Cancer Network, Inc. All Rights Reserved.

INTRODUCTION TO PEDIATRIC MEDULLOBLASTOMA: CHILDREN AND ADOLESCENTS
REFERENCES

[1] Northcott PA, Korshunov A, Witt H, et al. Medulloblastoma comprises four distinct molecular variants. J Clin Oncol 2011;10;29:1408-1414.
[2] Ostrom QT, Price M, Neff, C. CBTRUS Statistical Report: Primary Brain and Other Central Nervous System Tumors Diagnosed in the United States in 2015–2019. Neuro Oncol 2022;24(Suppl 5):v1-v95.
[3] Taylor MD, Northcott PA, Korshunov A, et al. Molecular subgroups of medulloblastoma: the current consensus. Acta Neuropathol 2012;123:465-472.
[4] Waszak SM, Northcott PA, Buchhalter I, et al. Spectrum and prevalence of genetic predisposition in medulloblastoma: a retrospective genetic study and prospective validation in a clinical trial cohort. Lancet Oncol 2018;19:785-798.
[5] Lee SJ, Schover LR, Partridge AH, et al. American Society of Clinical Oncology recommendations on fertility preservation in cancer patients. J Clin Oncol 2006;24:2917-2931.

Note: All recommendations are category 2A unless otherwise indicated.

Version 1.2026, 11/25/25 © 2025 National Comprehensive Cancer Network® (NCCN®), All rights reserved. NCCN Guidelines® and this illustration may not be reproduced in any form without the express written permission of NCCN.

PLEASE NOTE that use of this NCCN Content is governed by the End-User License Agreement, and you MAY NOT distribute this Content or use it with any artificial intelligence model or tool.
Printed by A. S. M. FAZLUL KARIM CHOWDHURY on 4/20/2026 3:38:59 AM. Copyright © 2026 National Comprehensive Cancer Network, Inc. All Rights Reserved.

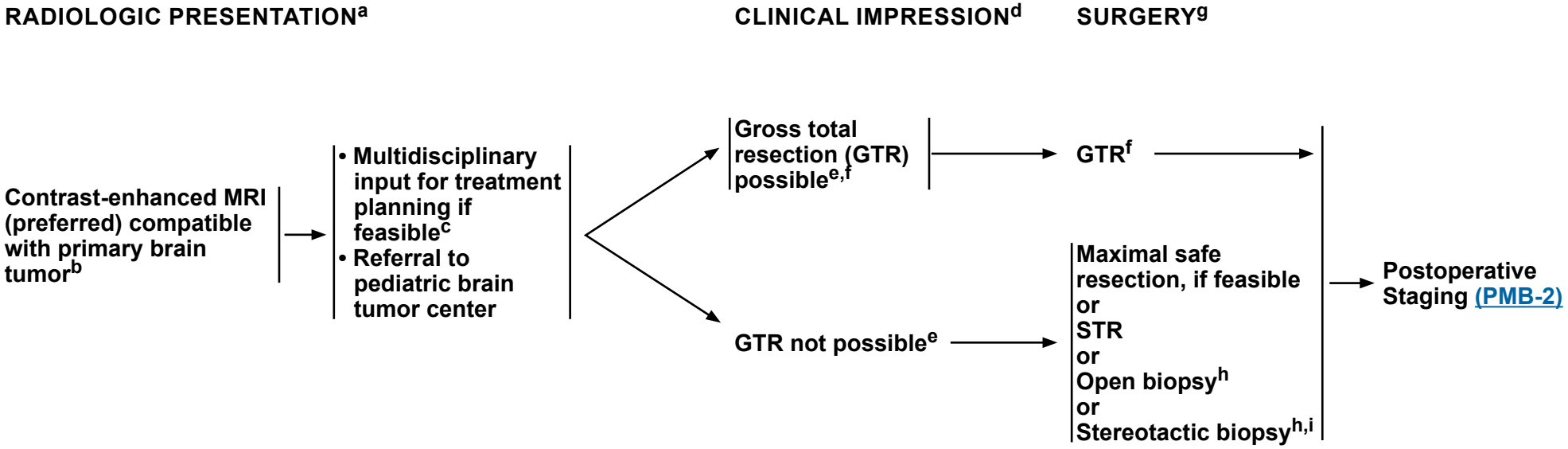

[a] Principles of Neuroimaging (PMB-A).
[b] Preoperative MRI (with and without gadolinium) should be obtained to avoid confusion with blood byproducts or postoperative changes. Brain and spine MRI with and without gadolinium is the recommended imaging modality for staging and response evaluation. Rapid sequence MRI is not a substitute for a full brain and spine MRI when staging or assessing for response evaluation. CT is not recommended for staging and response evaluation unless in the very rare cases where MRI is not feasible.
[c] Consider a multidisciplinary review in treatment planning, before surgery, and once pathology is available.
[d] Principles of Neuropathology (PMB-B).
[e] Endoscopic third ventriculostomy (ETV) or placement of ventriculoperitoneal (VP) shunt for management of hydrocephalus is acceptable if needed.
[f] Initial surgery should be performed with the goal of GTR while minimizing neurologic deficits incurred from surgery. Near total resection (NTR) (≤1.5 cm^2 residual) is acceptable in some settings. Less than NTR is also acceptable after review postoperatively by a multidisciplinary team.
[g] Principles of Surgery (PMB-C).
[h] Strongly recommend referring patient to a pediatric brain tumor center to be evaluated for possible further, more complete surgical resection.
[i] Stereotactic biopsy may be considered only if patient had gross leptomeningeal disease and no detectable primary site.

Note: All recommendations are category 2A unless otherwise indicated.

Version 1.2026, 11/25/25 © 2025 National Comprehensive Cancer Network® (NCCN®), All rights reserved. NCCN Guidelines® and this illustration may not be reproduced in any form without the express written permission of NCCN.

PLEASE NOTE that use of this NCCN Content is governed by the End-User License Agreement, and you MAY NOT distribute this Content or use it with any artificial intelligence model or tool.
Printed by A. S. M. FAZLUL KARIM CHOWDHURY on 4/20/2026 3:38:59 AM. Copyright © 2026 National Comprehensive Cancer Network, Inc. All Rights Reserved.

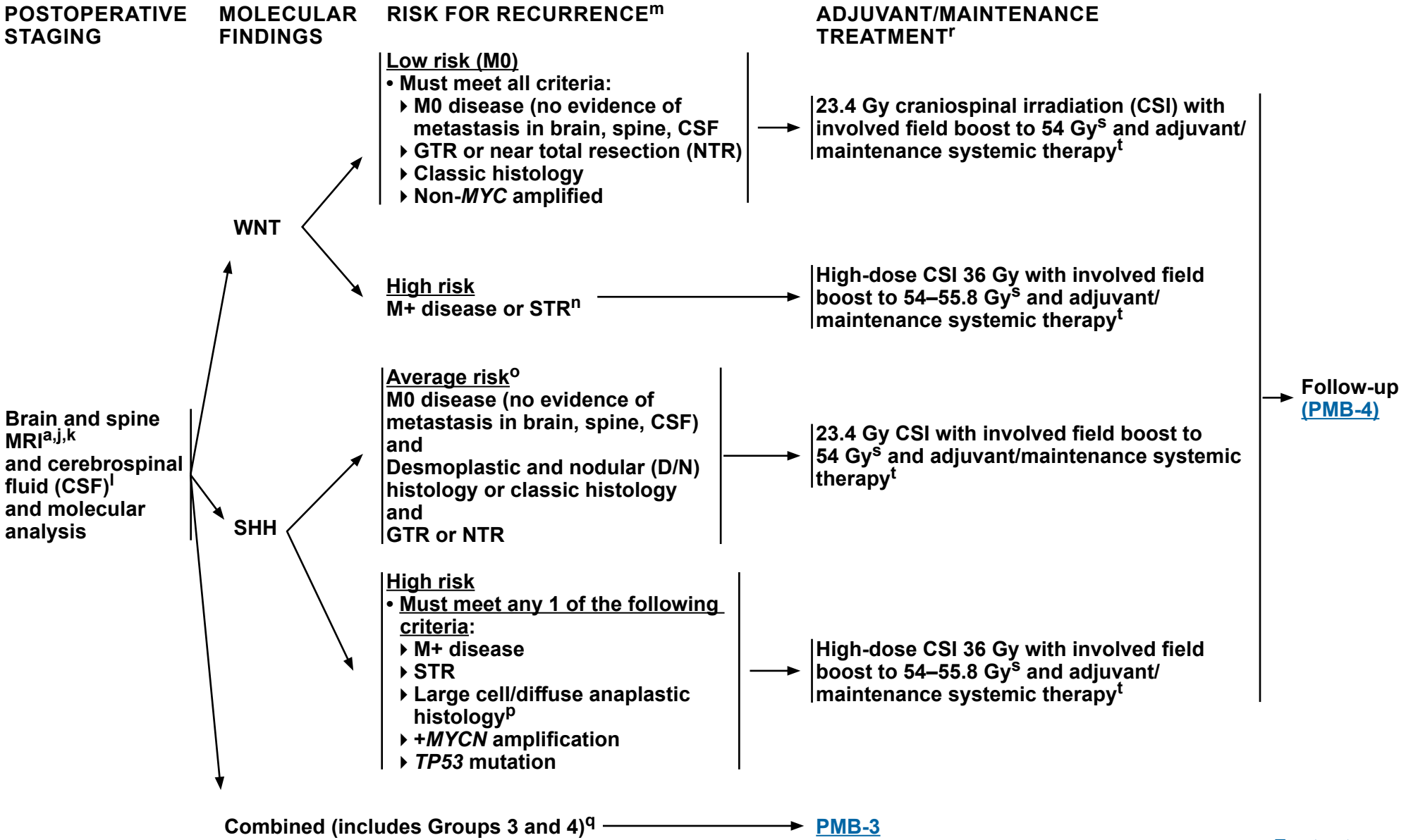

Footnotes on PMB-2A

Note: All recommendations are category 2A unless otherwise indicated.

Version 1.2026, 11/25/25 © 2025 National Comprehensive Cancer Network® (NCCN®), All rights reserved. NCCN Guidelines® and this illustration may not be reproduced in any form without the express written permission of NCCN.

PLEASE NOTE that use of this NCCN Content is governed by the End-User License Agreement, and you MAY NOT distribute this Content or use it with any artificial intelligence model or tool.
Printed by A. S. M. FAZLUL KARIM CHOWDHURY on 4/20/2026 3:38:59 AM. Copyright © 2026 National Comprehensive Cancer Network, Inc. All Rights Reserved.

FOOTNOTES FOR PMB-2

[a] Principles of Neuroimaging (PMB-A).
[j] Brain and spine MRI should be provided together to reduce anesthesia exposure. Diagnostic brain and spine MRI should be done for staging preoperatively. Postoperative imaging is required for the brain only and is ideally obtained within the first 24–72 hours (within 24 hours preferred).
[k] If spine MRI is not done prior to surgery, imaging should wait 10–14 days postoperatively to get an accurate diagnostic spine MRI for staging but preoperative spine MRI is strongly recommended.
[l] Lumbar puncture for CSF studies should be done ≥10 days postoperatively and before adjuvant treatment.
[m] Risk stratification in medulloblastoma is critical to treatment strategy.
[n] It is unclear whether having an STR alone is a high-risk factor for recurrence for WNT medulloblastoma. These patients may be considered average risk with further evidence.
[o] Higher risk because of molecular pathology should be treated with higher dose of RT and chemotherapy for higher risk.
[p] It is unclear whether large cell/anaplastic histology alone is a high-risk factor for recurrence.
[q] Groups 3 and 4 have been combined and collectively referred to as “Non-WNT/non-SHH" medulloblastoma.
[r] Radiation is not recommended for patients <3 years of age, but radiation-avoiding strategies may be used for patients >3 years of age per the treating physician’s discretion; this Guideline is for children receiving “radiation inclusive” treatment strategies.
[s] Principles of Radiation Therapy (PMB-D).
[t] Principles of Systemic Therapy (PMB-E).

Note: All recommendations are category 2A unless otherwise indicated.

Version 1.2026, 11/25/25 © 2025 National Comprehensive Cancer Network® (NCCN®), All rights reserved. NCCN Guidelines® and this illustration may not be reproduced in any form without the express written permission of NCCN.

PLEASE NOTE that use of this NCCN Content is governed by the End-User License Agreement, and you MAY NOT distribute this Content or use it with any artificial intelligence model or tool.
Printed by A. S. M. FAZLUL KARIM CHOWDHURY on 4/20/2026 3:38:59 AM. Copyright © 2026 National Comprehensive Cancer Network, Inc. All Rights Reserved.

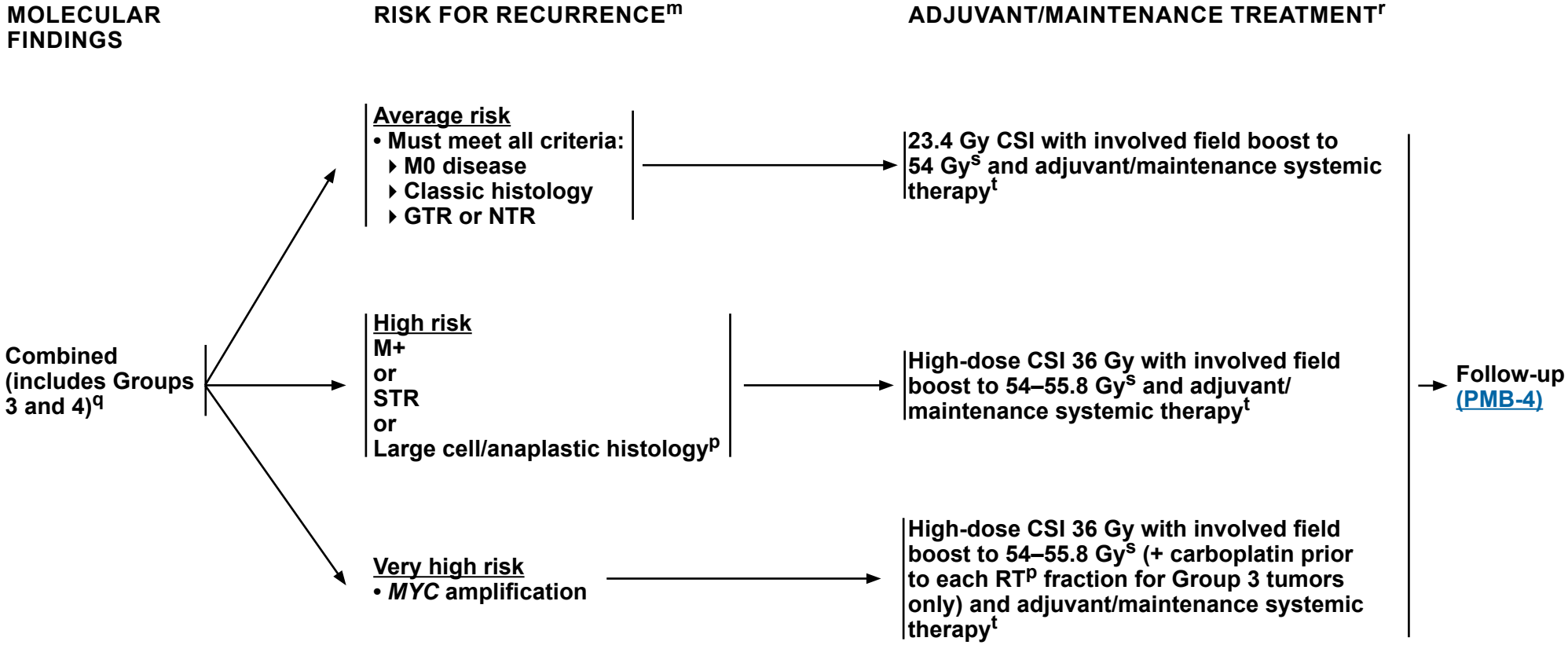

[m] Risk stratification in medulloblastoma is critical to treatment strategy.
[p] It is unclear whether large cell/anaplastic histology alone is a high-risk factor for recurrence.
[q] Groups 3 and 4 have been combined and collectively referred to as “Non-WNT/non-SHH" medulloblastoma.
[r] Radiation is not recommended for patients <3 years of age, but radiation-avoiding strategies may be used for patients >3 years of age per the treating physician’s discretion; this Guideline is for children receiving “radiation inclusive” treatment strategies.
[s] Principles of Radiation Therapy (PMB-D).
[t] Principles of Systemic Therapy (PMB-E).

Note: All recommendations are category 2A unless otherwise indicated.

Version 1.2026, 11/25/25 © 2025 National Comprehensive Cancer Network® (NCCN®), All rights reserved. NCCN Guidelines® and this illustration may not be reproduced in any form without the express written permission of NCCN.

PLEASE NOTE that use of this NCCN Content is governed by the End-User License Agreement, and you MAY NOT distribute this Content or use it with any artificial intelligence model or tool.
Printed by A. S. M. FAZLUL KARIM CHOWDHURY on 4/20/2026 3:38:59 AM. Copyright © 2026 National Comprehensive Cancer Network, Inc. All Rights Reserved.

FOLLOW-UP/SURVEILLANCE MAY INCLUDE[u]:

Low or average risk medulloblastoma (after completion of adjuvant/maintenance treatment)

- History and physical (H&P)
  - every 3–4 months for 2 years,
  - then every 6 months for 3 years,
  - then as clinically indicated
- Brain MRI
  - every 3–4 months for 2 years,
  - then every 6 months for 3 years,
  - then as clinically indicated
- Spine MRI
  - every 6 months for 2 years,
  - then as clinically indicated
- CSF
  - every 6 months for 2 years,
  - then as clinically indicated
- Complete blood count (CBC)
  - every 3–4 months for 2 years,
  - then every 6 months for 3 years,
  - then as clinically indicated
- Endocrine tests
  - at least annually for 5 years, then as clinically indicated
- Hearing test
  - every year for 5 years, then as clinically indicated
- Ophthalmic evaluation (assessment for vision, dry eye, and cataracts)
  - every year for 5 years, then as clinically indicated
- Neurocognitive testing
  - at 1 year,
  - then at 3 years,
  - then at 5 years,
  - then as clinically indicated
- Annual skin exam

High risk or very high risk medulloblastoma[u] (after completion of adjuvant/maintenance treatment)

- H&P
  - every 3–4 months for 2 years,
  - then every 6 months for 3 years,
  - then as clinically indicated
- Brain MRI
  - every 3–4 months for 2 years,
  - then every 6 months for 3 years,
  - then as clinically indicated
- Spine MRI
  - every 3–4 months for 2 years,
  - then every year for 3 years,
  - then as clinically indicated
- CSF
  - every 3–4 months for 2 years,
  - then as clinically indicated
- CBC
  - every 3–4 months for 2 years,
  - then every 6 months for 3 years,
  - then as clinically indicated
- Endocrine tests
  - at least annually for 5 years, then as clinically indicated
- Hearing test
  - every year for 5 years, then as clinically indicated
- Ophthalmic evaluation (assessment for vision, dry eye, and cataracts)
  - every year for 5 years, then as clinically indicated
- Neurocognitive testing
  - at 1 year,
  - then at 3 years,
  - then 5 years,
  - then as clinically indicated
- Annual skin exam

→ Recurrent disease or progressive disease (PMB-5)

[u] After 5 years, consider following the Children's Oncology Group (COG): Long-Term Follow-Up Guidelines for Survivors of Childhood, Adolescent, and Young Adult Cancers.

Note: All recommendations are category 2A unless otherwise indicated.

Version 1.2026, 11/25/25 © 2025 National Comprehensive Cancer Network® (NCCN®), All rights reserved. NCCN Guidelines® and this illustration may not be reproduced in any form without the express written permission of NCCN.

PLEASE NOTE that use of this NCCN Content is governed by the End-User License Agreement, and you MAY NOT distribute this Content or use it with any artificial intelligence model or tool.
Printed by A. S. M. FAZLUL KARIM CHOWDHURY on 4/20/2026 3:38:59 AM. Copyright © 2026 National Comprehensive Cancer Network, Inc. All Rights Reserved.

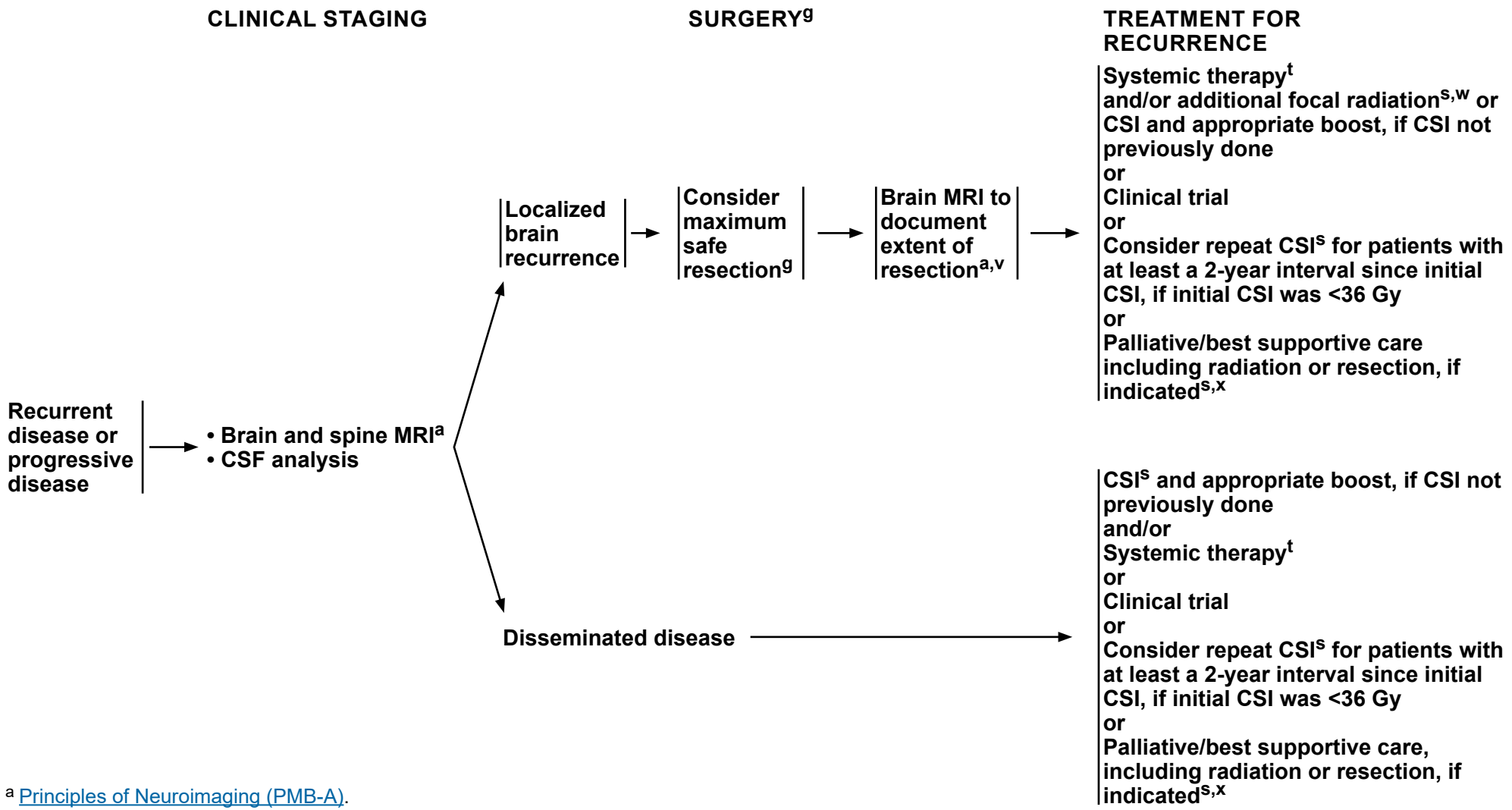

[a] Principles of Neuroimaging (PMB-A).
[g] Principles of Surgery (PMB-C).
[s] Principles of Radiation Therapy (PMB-D).
[t] Principles of Systemic Therapy (PMB-E).
[v] Postoperative follow-up is ideally between 24–48 hours after surgery.
[w] Multidisciplinary consult is needed to determine if radiation is recommended. Radiation may be considered for palliation or treatment for recurrence.
[x] Consider resection for palliation of symptoms where indicated.

Note: All recommendations are category 2A unless otherwise indicated.

Version 1.2026, 11/25/25 © 2025 National Comprehensive Cancer Network® (NCCN®), All rights reserved. NCCN Guidelines® and this illustration may not be reproduced in any form without the express written permission of NCCN.

PLEASE NOTE that use of this NCCN Content is governed by the End-User License Agreement, and you MAY NOT distribute this Content or use it with any artificial intelligence model or tool.
Printed by A. S. M. FAZLUL KARIM CHOWDHURY on 4/20/2026 3:38:59 AM. Copyright © 2026 National Comprehensive Cancer Network, Inc. All Rights Reserved.

PRINCIPLES OF NEUROIMAGING[a]

Conventional MRI is recommended for tumor diagnosis, surgical guidance, and therapeutic monitoring. It may be complemented by advanced neuroimaging techniques such as MR perfusion imaging, MR spectroscopy, and PET to enhance diagnostic capability, differentiate radiation necrosis from active neoplasm, and guide biopsy. Baseline imaging of the brain and spine is recommended before treatment; MRI is especially recommended for accurate staging for medulloblastoma. Imaging is always recommended to investigate the etiology of emergent signs and symptoms. The following pages list imaging modalities available and used in neuro-oncology to make treatment decisions.

[a] Some imaging modalities or techniques may not be available at all institutions.

Note: All recommendations are category 2A unless otherwise indicated.

Continued

Version 1.2026, 11/25/25 © 2025 National Comprehensive Cancer Network® (NCCN®), All rights reserved. NCCN Guidelines® and this illustration may not be reproduced in any form without the express written permission of NCCN.

PLEASE NOTE that use of this NCCN Content is governed by the End-User License Agreement, and you MAY NOT distribute this Content or use it with any artificial intelligence model or tool.
Printed by A. S. M. FAZLUL KARIM CHOWDHURY on 4/20/2026 3:38:59 AM. Copyright © 2026 National Comprehensive Cancer Network, Inc. All Rights Reserved.

PRINCIPLES OF NEUROIMAGING[a]

MRI[1-4] of the Brain and/or Spine (entire neural axis) (with and without IV contrast)

- **Benefits: Excellent soft-tissue contrast and depiction of neoplasms through a combination of standard, universally available pulse sequences; able to demonstrate characteristic imaging appearance of pediatric medulloblastoma to facilitate diagnosis and evaluate for metastatic disease; and confers no ionizing radiation.**
- **Limitations: Relatively long examinations and sensitive to patient motion, so younger children generally require deep sedation/anesthesia; implanted metallic devices can cause significant artifact; and some implants are unsafe in MRI environment.**
- **Pediatric medulloblastoma typically presents as a large, heterogeneous, posterior fossa mass that occupies either the fourth ventricle or cerebellar hemisphere. The mass characteristically demonstrates reduced diffusion due to high cellularity. Most cases demonstrate heterogeneous cyst formation or necrosis, with heterogeneous and variable enhancement. In the spine, medulloblastoma can demonstrate leptomeningeal dissemination.[5,6]**
- **Brain and spine MRI with and without gadolinium is the recommended imaging modality for initial staging and response evaluation for medulloblastoma.**
- **Rapid sequence MRI is not a substitute for a full brain and spine MRI when staging or assessing for response evaluation for medulloblastoma.**
- **CT is not recommended for staging and response evaluation for medulloblastoma unless in the very rare cases where MRI is not feasible.**
- **Basic MRI sequences of the brain should include: T2/FLAIR, DWI, GRE or SWI, T1-weighted images pre-contrast, as well as T1-weighted images in two planes post-contrast (one of which would ideally be acquired as a 3D sequence)[7,8] (see Table 1 [PGLIO-3A of 4]).**
  - **These should be utilized for initial preliminary diagnostic evaluation and immediate postoperative follow-up (ideally within 24–48 hours postoperative, if clinically feasible) to facilitate comparison of disease burden (measurable and non-measurable disease) on initial examination and extent of resection on the immediate postoperative scan.**
  - **2D acquisitions should be ≤4-mm slices; 3D acquisitions should be nearly isotropic.**
  - **T1 post-contrast sequences should be obtained as either 3D T1-weighted GRE or TSE acquisitions for planar reconstructions and/or volumetric analysis of tumors.**
- **Basic imaging of the spine is designed to evaluate for leptomeningeal disease and should include sagittal T2-W images, and post-contrast sagittal and axial T1-weighted images of the entire spine. Additional sequences such as high-resolution heavily T2-weighted images, 3D bSSFP sequence (CISS/FIESTA-C), and/or DWI may be helpful and should also be obtained when feasible[8] (see Table 2 [PGLIO-3B of 4])**
  - **These sequences should be utilized to evaluate for leptomeningeal spread of neoplasm.**
  - **Sagittal slices should be ≤3 mm and axial slices may be 3- to 4-mm slices in thickness.**
  - **Preoperative spine imaging should be performed at the time of brain imaging, because many children require sedation to tolerate the examination and to prevent potential confusion for blood products in the spinal canal in the postoperative setting.**
  - **Postoperative spine MRIs should be delayed to occur at least 10–14 days postoperatively, if evaluating for leptomeningeal spread of neoplasm to avoid confusion with blood products.**
- **For MRI contrast, Group II GBCAs are recommended for use given the potential of higher gadolinium retention with linear GBCAs.[7]**
- **Follow-up studies of the brain and spine should be performed at intervals defined by the treatment algorithms. More frequent imaging may be necessary if indicated by the treating physician in the event of clinical deterioration or evolving imaging findings that are concerning for recurrent or residual disease.**
  - **Longitudinal follow-up studies may be complemented by MR perfusion or MR spectroscopy, if those techniques are available, to assess response to therapy or to evaluate for progression, pseudoprogression, or radiation necrosis.**

[a] Some imaging modalities or techniques may not be available at all institutions.

Note: All recommendations are category 2A unless otherwise indicated.

Continued
References

Version 1.2026, 11/25/25 © 2025 National Comprehensive Cancer Network® (NCCN®), All rights reserved. NCCN Guidelines® and this illustration may not be reproduced in any form without the express written permission of NCCN.

PLEASE NOTE that use of this NCCN Content is governed by the End-User License Agreement, and you MAY NOT distribute this Content or use it with any artificial intelligence model or tool.
Printed by A. S. M. FAZLUL KARIM CHOWDHURY on 4/20/2026 3:38:59 AM. Copyright © 2026 National Comprehensive Cancer Network, Inc. All Rights Reserved.

PRINCIPLES OF NEUROIMAGING[a]

CT of the Brain (with contrast or with and without contrast):
- Can be used for rapid assessment in the acute setting and for the evaluation of acute intracranial hemorrhage, ventriculomegaly, and shunt-related complications.
- Recommended in those patients in whom an MRI is not available or contraindicated because of unsafe implants or foreign bodies.
- Noncontrast CT is sufficient to rule out acute intracranial abnormality. Patients should subsequently undergo MRI unless contraindicated or not available. In those cases, CT with contrast may be obtained to evaluate the mass, understanding it has limited sensitivity compared to MRI.[7]
- Benefits: Shorter acquisition time; generally no sedation is needed; ideal in acutely emergent or immediate postoperative settings; and sensitive to acute blood products and calcium.
- Limitations: Ionizing radiation; limited soft tissue contrast; limited evaluation of metastatic disease, and metal causes streak artifact, which limits evaluation.

MR Perfusion[7,9-11]: Measures cerebral blood volume and/or cerebral blood flow in neoplasms; choice of various techniques (DSC vs. DCE vs. ASL perfusion) will depend upon user availability and preference.
- May be helpful for grading neoplasms, assessing response to therapy, identifying malignant degeneration and pseudoprogression, distinguishing radiation necrosis from recurrent neoplasm, and choosing biopsy site.
- Limitations: Reliability degraded by adjacent metal, blood products, air, and bone/soft tissue interface; poor signal to noise (ASL imaging) and other general limitations of MRI are as previously listed.

MR Spectroscopy[7,11,12]: Assess metabolites of neoplasms (choice of single voxel vs. multivoxel spectroscopy will depend on user preference and availability).
- May be helpful for grading neoplasms, assessing response to therapy, identifying malignant degeneration and pseudoprogression, distinguishing radiation necrosis from recurrent neoplasm, and choosing biopsy site.
- Limitations: Complex acquisition technique and post-processing that benefits from expertise; long acquisition times; and reliability degraded by adjacent metal, blood products, and bone/soft tissue/air interfaces.

PET Studies: Assess tumor biology by using tracers with distinct mechanisms of uptake, allowing differentiation of different biological processes within the tumor.
- May be useful in tumor delineation, differentiating between neoplasm and radiation necrosis, tumor grading, or identifying a more aggressive focus for biopsy. In some studies, intensity of fluorodeoxyglucose (FDG)-PET uptake has been correlated with prognosis and survival in medulloblastoma.[13,14]
- Limited spatial resolution compared to brain CT and MRI; heterogenous availability of radioisotopes; and additional radiation exposure.

Supplemental Imaging for Preoperative Planning:
- Isotropic volumetric MRI to accurately localize the neoplasms by coregistering the data with intraoperative guidance software. It is often complemented with isotropic CT studies to improve localization.[7]
- Functional MRI studies can be used to depict spatial relationships between eloquent cortex (eg, regions of the brain primarily responsible for speech, vision, and motor and sensory function) and the neoplasms to serve as a road map and promote safe resections.[7]
- DTI with tractography may also be used to localize major white matter tracts underlying the eloquent cortex that could also compromise vital functions if injured during surgery.[7]
- Different deep learning and artificial intelligence (AI) techniques for imaging that assist in identifying different pediatric medulloblastoma types are still at an early stage. There is a possibility of enhancing the classification of medulloblastoma subtypes by merging data from textured images and the original histopathologic images. This evaluation that combines radiology and genomics could become significant in the future.[15]

[a] Some imaging modalities or techniques may not be available at all institutions.

References

Note: All recommendations are category 2A unless otherwise indicated.

Version 1.2026, 11/25/25 © 2025 National Comprehensive Cancer Network® (NCCN®), All rights reserved. NCCN Guidelines® and this illustration may not be reproduced in any form without the express written permission of NCCN.

PLEASE NOTE that use of this NCCN Content is governed by the End-User License Agreement, and you MAY NOT distribute this Content or use it with any artificial intelligence model or tool.
Printed by A. S. M. FAZLUL KARIM CHOWDHURY on 4/20/2026 3:38:59 AM. Copyright © 2026 National Comprehensive Cancer Network, Inc. All Rights Reserved.

PRINCIPLES OF NEUROIMAGING
REFERENCES

[1] Erker C, Tamrazi B, Poussaint TY, et al. Response assessment in paediatric high-grade glioma: recommendations from the Response Assessment in Pediatric Neuro-Oncology (RAPNO) working group. Lancet Oncol 2020;21:e317-e329.
[2] Cooney TM, Cohen KJ, Guimaraes CV, et al. Response assessment in diffuse intrinsic pontine glioma: recommendations from the Response Assessment in Pediatric Neuro-Oncology (RAPNO) working group. Lancet Oncol 2020;21:e330-e336.
[3] Jaspan T, Morgan PS, Warmuth-Metz M, et al. Response assessment in pediatric neuro-oncology: Implementation and expansion of the RANO criteria in a randomized phase II trial of pediatric patients with newly diagnosed high-grade gliomas. AJNR Am J Neuroradiol 2016;37:1581-1587.
[4] Ellingson BM, Bendszus M, Boxerman J, et al. Consensus recommendations for a standardized brain tumor imaging protocol in clinical trials. Neuro Oncol 2015;17:1188-1198.
[5] Dangouloff-Ros V, Varlet P, Levy R, et al. Imaging features of medulloblastoma: Conventional imaging, diffusion-weighted imaging, perfusion-weighted imaging, and spectroscopy: From general features to subtypes and characteristics. Neurochirurgie 2021;67:6-13.
[6] Reddy N, Ellison DW, Soares BP, et al. Pediatric posterior fossa medulloblastoma: The role of diffusion imaging in identifying molecular groups. J Neuroimaging 2020;30:503-511.
[7] Jaju A, Li Y, Dahmoush H, et al. Imaging of pediatric brain tumors: A COG Diagnostic Imaging Committee/SPR Oncology Committee/ASPNR White Paper. Pediatr Blood Cancer 2023;70 Suppl 4:e30147.
[8] Rogers SN, Udayasankar U, Pruthi S, et al. Imaging of pediatric spine and spinal cord tumors: A COG Diagnostic Imaging Committee/SPR Oncology Committee/ASPNR White Paper. Pediatr Blood Cancer 2023;70 Suppl 4:e30150.
[9] Wan B, Wang S, Tu M, et al. The diagnostic performance of perfusion MRI for differentiating glioma recurrence from pseudoprogression: A meta-analysis. Medicine (Baltimore) 2017;96:e6333.
[10] Barajas RF Jr, Chang JS, Segal MR, et al. Differentiation of recurrent glioblastoma multiforme from radiation necrosis after external beam radiation therapy with dynamic susceptibility-weighted contrast-enhanced perfusion MR imaging. Radiology 2009;253:486-496.
[11] van Dijken BRJ, van Laar PJ, Holtman GA, van der Hoorn A. Diagnostic accuracy of magnetic resonance imaging techniques for treatment response evaluation in patients with high-grade glioma, a systematic review and meta-analysis. Eur Radiol 2017;27:4129-4144.
[12] Zhang H, Ma L, Wang Q, et al. Role of magnetic resonance spectroscopy for the differentiation of recurrent glioma from radiation necrosis: a systematic review and meta-analysis. Eur J Radiol 2014;83:2181-2189.
[13] Gururangan S, Hwang E, Herndon JE II, et al. [18F]fluorodeoxyglucose-positron emission tomography in patients with medulloblastoma. Neurosurgery 2004;55:1280-1288; discussion 1288-1289.
[14] Tripathi M, Jain N, Jaimini A, et al. Demonstration of diffuse leptomeningeal metastasis in a treated case of medulloblastoma with F-18 FDG PET/CT. Clin Nucl Med 2009;34:530-532.
[15] Zhang M, Wong SW, Wright J et al. MRI radiogenomics of pediatric medulloblastoma: A multicenter study. Radiology 2022;304:406-416.

Note: All recommendations are category 2A unless otherwise indicated.

Version 1.2026, 11/25/25 © 2025 National Comprehensive Cancer Network® (NCCN®), All rights reserved. NCCN Guidelines® and this illustration may not be reproduced in any form without the express written permission of NCCN.

PLEASE NOTE that use of this NCCN Content is governed by the End-User License Agreement, and you MAY NOT distribute this Content or use it with any artificial intelligence model or tool.
Printed by A. S. M. FAZLUL KARIM CHOWDHURY on 4/20/2026 3:38:59 AM. Copyright © 2026 National Comprehensive Cancer Network, Inc. All Rights Reserved.

PRINCIPLES OF NEUROPATHOLOGY[1-20]

- **Medulloblastoma arises in posterior fossa, generally the cerebellum, and predominantly occurs within pediatric populations.**
- **All types of medulloblastomas are embryonal tumors, histologically composed of small, poorly differentiated cells with a high nuclear: cytoplasmic ratio, high levels of mitotic activity, and prominent apoptosis.**
- **All medulloblastomas are CNS WHO grade 4; however, some molecular groups and subgroups of medulloblastoma show a very good response to current therapeutic regimens and a high rate of cure.**
- **Medulloblastoma is now fundamentally categorized by molecular group based on the 2021 CNS WHO Classification (5th edition). However, morphologic patterns with clinicopathologic utility remain critical to recognize as they correlate well with molecular subtypes and may therefore predict molecular group(s) before molecular data are available, as well as support molecular characterization. To this end, IHC analysis is also of great utility, especially as these stains provide rapid screening for specific genetic alterations (eg, beta-catenin, p53, *INI1*/*SMARCB1*). Integration of morphologic, IHC, and molecular data is always required.**
- **Currently, five medulloblastoma molecular groups are recognized (2021 CNS WHO Classification, 5th edition):**
  - **WNT-activated**
  - **SHH-activated, *TP53*-wild-type**
  - **SHH-activated, *TP53*-mutant**
  - **Group 3**
  - **Group 4**
- **Group 3 and Group 4 have been combined and collectively referred to as “non-WNT/non-SHH medulloblastomas.” DNA methylation profiling supports the existence of eight robust non-WNT/non-SHH subgroups; among these are high-risk DNA methylation patterns associated with a poor prognosis.**
- **Exceptional cases of medulloblastomas that do not classify precisely with a known group based on molecular profiling may receive a diagnosis of "medulloblastoma, not elsewhere classified (NEC)." Examples include medulloblastomas with both WNT-activating and SHH-activating mutations that do not match well with a known methylation profile, medulloblastomas without driver mutations characteristic of a group that do not match a known methylation profile, and others. Though the expected prognoses of such tumors may be unclear, histology and molecular markers, including presence or absence of those associated with more aggressive behavior, may be suggestive.**
- **Per the 2021 CNS WHO Classification (5th edition), DNA methylation profiling is recommended for determining medulloblastoma group or subgroup status[a]; however, the findings should always be interpreted in conjunction with genetic profiling (*TP53* mutation, *MYC/MYCN* amplification, and germline testing for cancer predisposition syndromes), as well as histologic and IHC parameters. IHC for beta-catenin may be particularly helpful to demonstrate WNT-pathway activation in patients with low-risk, WNT-activated medulloblastoma.**
- **Timely molecular testing is important for diagnosis.**
- **Germline testing and genetic counseling is recommended.**

[a] Additional methods used for assigning molecular group include IHC, RNA-based gene expression profiling, and additional methylation-based analyses among others.

Note: All recommendations are category 2A unless otherwise indicated.

References

Version 1.2026, 11/25/25 © 2025 National Comprehensive Cancer Network® (NCCN®), All rights reserved. NCCN Guidelines® and this illustration may not be reproduced in any form without the express written permission of NCCN.

PLEASE NOTE that use of this NCCN Content is governed by the End-User License Agreement, and you MAY NOT distribute this Content or use it with any artificial intelligence model or tool.
Printed by A. S. M. FAZLUL KARIM CHOWDHURY on 4/20/2026 3:38:59 AM. Copyright © 2026 National Comprehensive Cancer Network, Inc. All Rights Reserved.

PRINCIPLES OF NEUROPATHOLOGY[1-20]

A summary of the recognized molecular groups is as follows:

WNT-activated
- Most common in children ages 7–14 years, also affects adult population
- 10% of medulloblastomas
- Classic histology
- Prognosis: Overall survival close to 100% in children
- Characterized by WNT pathway activation
  - *CTNNB1* mutation (90%)
- Germline mutations uncommon, but rare germline *CMMRD* and *APC* mutation

SHH-activated, *TP53*-wild-type
- Bimodal age distribution, infants and adults
- 20% of medulloblastomas
- D/N histology exclusive to SHH group, but classic histology also encountered
- Prognosis: intermediate; however, highly variable; overall >80% survival rate in absence of high-risk features (ie, metastatic disease, *MYCN* amplification)
- Frequent genetic mutations: *PTCH1, SUFU, SMO, MLL2, MYCN, LDB1, GLI1*
- *MYCN* amplification independently associated with a poor prognosis in non-infant children and adolescents
- Germline mutations common, frequently inactivating mutations in *PTCH1* (Gorlin syndrome)

SHH-activated, *TP53*-mutant
- Most common in children aged 4–17 years
- 10%–15% of SHH-activated medulloblastomas
- Large cell/anaplastic histology common
- Prognosis: 5-year overall survival of approximately 40%
- In non-infant children and adolescents with SHH-activated medulloblastoma, *TP53* mutation and *MYCN* amplification are associated with each other and with a very poor outcome worse than that of *TP53* mutation alone
- Defining molecular alterations are as those in SHH-activated, *TP53*-wild-type above; however, must definitionally co-occur with *TP53* mutation
- DNA methylation or transcriptome profiling demonstrate at least 4 provisional molecular subgroups among SHH-activated medulloblastomas (SHH-1, SHH-2, SHH-3, and SHH-4); SHH-activated and *TP53*-mutant medulloblastomas frequently belong to subgroup SHH-3
- >50% germline rather than somatic *TP53* alterations (Li-Fraumeni syndrome)

Group 3[b]
- Higher proportion in infants (40%), rare in adults
- 25% of medulloblastomas
- Mostly classic histology; however, most tumors with large cell/anaplastic histology are Group 3
- Prognosis: 20%–30% 5-year survival, high tendency of metastases (45%)
- *MYC* amplification, high genomic instability, and isodicentric 17q
- Generally not associated with germline mutations

Group 4[b]
- Peak incidence 5–15 years of age, 20%–25% of adult patients
- Largest subgroup (35% overall)
- Mostly classic histology
- Prognosis: intermediate, overall survival 75%–90%
- Amplifications in *MYCN* and *CDK6*, isodicentric 17q
- Generally not associated with germline mutations

[b] Group 3 and Group 4 are often collectively referred to as "non-WNT/non-SHH medulloblastomas." DNA methylation profiling supports the existence of eight robust non-WNT/non-SHH subgroups; among these are high-risk DNA methylation patterns associated with a poor prognosis.

Note: All recommendations are category 2A unless otherwise indicated.

References

Version 1.2026, 11/25/25 © 2025 National Comprehensive Cancer Network® (NCCN®), All rights reserved. NCCN Guidelines® and this illustration may not be reproduced in any form without the express written permission of NCCN.

PLEASE NOTE that use of this NCCN Content is governed by the End-User License Agreement, and you MAY NOT distribute this Content or use it with any artificial intelligence model or tool.
Printed by A. S. M. FAZLUL KARIM CHOWDHURY on 4/20/2026 3:38:59 AM. Copyright © 2026 National Comprehensive Cancer Network, Inc. All Rights Reserved.

PRINCIPLES OF NEUROPATHOLOGY
REFERENCES

[1] Medulloblastoma. Wesseling P, Pfister SM, Ellison DW, et al. In: WHO Classification of Tumours Editorial Board. Central nervous system tumours [Internet]. Lyon (France): International Agency for Research on Cancer; 2021. (WHO classification of tumours series, 5th ed; vol 6). Available from: https://tumourclassification.iarc.who.int/chapters/45.
[2] Cavalli FMG, Remke M, Rampasek L, et al. Intertumoral heterogeneity within medulloblastoma subgroups. Cancer Cell 2017;31:737-754.e6.
[3] Clifford SC, Lusher ME, Lindsey JC, et al. Wnt/Wingless pathway activation and chromosome 6 loss characterize a distinct molecular sub-group of medulloblastomas associated with a favorable prognosis. Cell Cycle 2006;5:2666-2670.
[4] Ellison DW, Dalton J, Kocak M, et al. Medulloblastoma: clinicopathological correlates of SHH, WNT, and non-SHH/WNT molecular subgroups. Acta Neuropathol 2011;121:381-396.
[5] Ellison DW, Kocak M, Dalton J,et al. Definition of disease-risk stratification groups in childhood medulloblastoma using combined clinical, pathologic, and molecular variables. J Clin Oncol 2011;29:1400-1407.
[6] Kool M, Korshunov A, Remke M, et al. Molecular subgroups of medulloblastoma: an international meta-analysis of transcriptome, genetic aberrations, and clinical data of WNT, SHH, Group 3, and Group 4 medulloblastomas. Acta Neuropathol 2012;123:473-484.
[7] Kool M, Jones DT, Jäger N, et al. ICGC PedBrain Tumor Project. Genome sequencing of SHH medulloblastoma predicts genotype-related response to smoothened inhibition. Cancer Cell 2014;25:393-405.
[8] Korshunov A, Sahm F, Okonechnikov K, et al. Desmoplastic/nodular medulloblastomas (DNMB) and medulloblastomas with extensive nodularity (MBEN) disclose similar epigenetic signatures but different transcriptional profiles. Acta Neuropathol 2019;137:1003-1015.
[9] Louis DN, Perry A, Burger P. International Society Of Neuropathology--Haarlem. International Society Of Neuropathology--Haarlem consensus guidelines for nervous system tumor classification and grading. Brain Pathol 2014;24:429-435.
[10] Northcott PA, Shih DJ, Remke M, et al. Rapid, reliable, and reproducible molecular sub-grouping of clinical medulloblastoma samples. Acta Neuropathol 2012;123:615-626.
[11] Northcott PA, Buchhalter I, Morrissy AS, et al. The whole-genome landscape of medulloblastoma subtypes. Nature 2017;547:311-317.
[12] Robinson G, Parker M, Kranenburg TA, et al. Novel mutations target distinct subgroups of medulloblastoma. Nature 2012;488:43-48.
[13] Schwalbe EC, Lindsey JC, Nakjang S, et al. Novel molecular subgroups for clinical classification and outcome prediction in childhood medulloblastoma: a cohort study. Lancet Oncol 2017;18:958-971.
[14] Tabori U, Baskin B, Shago M, et al. Universal poor survival in children with medulloblastoma harboring somatic TP53 mutations. J Clin Oncol 2010;28:1345-1350.
[15] Taylor MD, Northcott PA, Korshunov A, et al. Molecular subgroups of medulloblastoma: the current consensus. Acta Neuropathol 2012;123:465-472.
[16] Waszak SM, Northcott PA, Buchhalter I, et al. Spectrum and prevalence of genetic predisposition in medulloblastoma: a retrospective genetic study and prospective validation in a clinical trial cohort. Lancet Oncol 2018;19:785-798.
[17] Zhukova N, Ramaswamy V, Remke M, et al. Subgroup-specific prognostic implications of TP53 mutation in medulloblastoma. J Clin Oncol 2013;31:2927-2935.
[18] Northcott PA, Korshunov A, Witt H, et al. Medulloblastoma comprises four distinct molecular variants. J Clin Oncol 2011;29:1408-1414.
[19] Orr BA. Pathology, diagnostics, and classification of medulloblastoma. Brain Pathol 2020;30:664-678.
[20] Cotter JA, Hawkins C. Medulloblastoma: WHO 2021 and Beyond. Pediatr Dev Pathol 2022;25:23-33.

Note: All recommendations are category 2A unless otherwise indicated.

Version 1.2026, 11/25/25 © 2025 National Comprehensive Cancer Network® (NCCN®), All rights reserved. NCCN Guidelines® and this illustration may not be reproduced in any form without the express written permission of NCCN.

PLEASE NOTE that use of this NCCN Content is governed by the End-User License Agreement, and you MAY NOT distribute this Content or use it with any artificial intelligence model or tool.
Printed by A. S. M. FAZLUL KARIM CHOWDHURY on 4/20/2026 3:38:59 AM. Copyright © 2026 National Comprehensive Cancer Network, Inc. All Rights Reserved.

PRINCIPLES OF SURGERY[1-7]

General Principles

- There is general consensus that maximal safe surgical resection should be the routine initial treatment to relieve presenting symptoms, establish diagnosis, and maximize local control. Even when viewed by molecular subtype, GTR and NTR (≤1.5 cm^2 residual) produce roughly equivalent overall survival.
- Surgical management of obstructive hydrocephalus must be considered alongside relief of local mass effect and diagnostic considerations. Adjuvant treatment initiation should not be delayed, once surgical wound healing, hydrocephalus, and brainstem/cranial nerve dysfunction affecting airway protection are adequately addressed. Early physical therapy, occupational therapy, and speech therapy intervention are recommended for cases of posterior fossa syndrome, cerebellar ataxia, or brainstem dysfunction.

Preoperative Assessment

- Treat emergent situations prior to further investigative studies or interventions.
- Provide medical management to temporarily relieve local mass effect (ie, corticosteroids), focal neurologic deficits, or seizure (ie, anti-epileptics).
- Avoid medications that may alter the patient's neurologic examination (eg, narcotics) or increase surgical risks (eg, anticoagulants).
- Patients should undergo gadolinium-enhanced MRI of the full neural axis, preferably before surgery.

Surgical Procedure

- Alleviate symptoms related to local mass effect to increase survival.
- Obtain adequate tissue for histopathologic diagnosis and molecular genetic characterization.
- The goal of extent-of-resection should be GTR or at least NTR (≤1.5 cm^2 residual), if feasible in the context of minimizing postoperative neurologic deficits.
- Second-look surgery is recommended for patients with resectable residual disease.
- Re-resection at the time of recurrence may confer overall survival benefit in the setting of a single, focal posterior fossa recurrence.
- Biopsy of recurrent disease may identify actionable molecular findings, or rarely, a secondary malignancy.

Postoperative Management

- Monitor for signs and symptoms of increased intracranial pressure. Either ventriculoperitoneal (VP) shunt or endoscopic third ventriculostomy (ETV) are acceptable CSF diversion techniques.[8]
- Lumbar puncture for CSF studies should be done ≥10 days postoperatively and before adjuvant treatment.
- Early consultation with radiation oncology and neurooncology is recommended.
- Early physical therapy, occupational therapy, and speech therapy intervention are recommended in cases of posterior fossa syndrome, cerebellar ataxia, or brainstem dysfunction.
- Consider referral to a child life social worker for family/patient support.

Note: All recommendations are category 2A unless otherwise indicated.

References

Version 1.2026, 11/25/25 © 2025 National Comprehensive Cancer Network® (NCCN®), All rights reserved. NCCN Guidelines® and this illustration may not be reproduced in any form without the express written permission of NCCN.

PLEASE NOTE that use of this NCCN Content is governed by the End-User License Agreement, and you MAY NOT distribute this Content or use it with any artificial intelligence model or tool.
Printed by A. S. M. FAZLUL KARIM CHOWDHURY on 4/20/2026 3:38:59 AM. Copyright © 2026 National Comprehensive Cancer Network, Inc. All Rights Reserved.

PRINCIPLES OF SURGERY
REFERENCES

[1] Louis DN, Perry A, Wesseling P, et al. The 2021 WHO Classification of Tumors of the Central Nervous System: A summary. Neuro Oncol 2021;23:1231-1251.
[2] Rutkowski S, von Hoff K, Emser A, et al. Survival and prognostic factors of early childhood medulloblastoma: An international meta-analysis. J Clin Oncol 2010;28: 4961-4968.
[3] Schwalbe EC, Lindsey JC, Nakjang S, et al. Novel molecular subgroups for clinical classification and outcome prediction in childhood medulloblastoma: A cohort study. Lancet Oncol 2017;18:958-971.
[4] Thompson EM, Hielscher T, Bouffet E, et al. Prognostic value of medulloblastoma extent of resection after accounting for molecular subgroup: A retrospective integrated clinical and molecular analysis. Lancet Oncol 2016;17:484-495. Erratum in: Lancet Oncol 2022;23:e59.
[5] Ellison DW, Dalton J, Kocak M, et al. Medulloblastoma: Clinicopathological correlates of SHH, WNT, and non-SHH/WNT molecular subgroups. Acta Neuropathol 2011;121:381-396.
[6] Albright AL, Wisoff JH, Zeltzer PM, et al. Effects of medulloblastoma resections on outcome in children: a report from the Children's Cancer Group. Neurosurgery 1996;38:265-271.
[7] Zeltzer PM, Boyett JM, Finlay JL, et al. Metastasis stage, adjuvant treatment, and residual tumor are prognostic factors for medulloblastoma in children: conclusions from the Children's Cancer Group 921 randomized phase III study. J Clin Oncol 1999;17:832-845.
[8] Dewan MC, Lim J, Shannon CN, Wellons JC III. The durability of endoscopic third ventriculostomy and ventriculoperitoneal shunts in children with hydrocephalus following posterior fossa tumor resection: a systematic review and time-to-failure analysis. J Neurosurg Pediatr 2017;19:578-584.

Note: All recommendations are category 2A unless otherwise indicated.

Version 1.2026, 11/25/25 © 2025 National Comprehensive Cancer Network® (NCCN®), All rights reserved. NCCN Guidelines® and this illustration may not be reproduced in any form without the express written permission of NCCN.

PLEASE NOTE that use of this NCCN Content is governed by the End-User License Agreement, and you MAY NOT distribute this Content or use it with any artificial intelligence model or tool.
Printed by A. S. M. FAZLUL KARIM CHOWDHURY on 4/20/2026 3:38:59 AM. Copyright © 2026 National Comprehensive Cancer Network, Inc. All Rights Reserved.

PRINCIPLES OF RADIATION THERAPY MANAGEMENT[1,2]

General Principles

- Early referral to radiation oncology is recommended.
- Proton therapy should be considered for potential tissue sparing, if available in a timely manner.[3]
- In the context of avoiding delays in therapy or logistical consideration, photon therapy is an acceptable treatment modality for situations in which proton therapy is not available such as recurrence and logistical situations (such as travel delays).
- Optimizing normal tissue sparing is recommended regardless of modality that is used.
- Enrollment in clinical trials is encouraged.
- Avoid RT interruptions (total - 50 days).

CT Simulation/Tumor Volumes

- Restaging and/or planning MRIs are recommended if the interval since prior imaging has been >3 weeks.
- CT simulation for treatment planning should include ≤0.3 cm slice thickness.
- RT to start within 31–42 days of surgery (31–35 days preferred); up to 42 days is acceptable.
- GTV-primary
  - Any radiographic residual disease and the tumor bed as defined by combination of pre- and postoperative imaging and inclusive of any surfaces that may still harbor microscopic disease
- GTV-metastasis
  - Gross tumor as seen on T1 post contrast imaging or T2 in the brain or spine
  - In patients with diffuse or high disease burden in the brain and/or spine, the boost volume(s) for metastatic disease is at the treating physician's discretion
- CTV CSI: Includes the entire CSF space, defined as the MRI-defined thecal space + 1–1.5 cm inferior, usually at the bottom of S3 or S4
- CTV boost: GTV + 10–15 mm can be modified to limit extension at the level of brainstem 2–5 mm
- CTV metastasis: 5–10 mm
- PTV boost (and metastasis): 3–5 mm
- PTV CSI: 3–7 mm

[1] Michalski JM, Janss AJ, Vezina LG, et al. Children's Oncology Group Phase III trial of reduced-dose and reduced-volume radiotherapy with chemotherapy for newly diagnosed average-risk medulloblastoma. J Clin Oncol 2021;39:2685-2697.
[2] Leary SES, Packer RJ, Li Y, et al. Efficacy of carboplatin and isotretinoin in children with high-risk medulloblastoma: A randomized clinical trial from the Children's Oncology Group. JAMA Oncol 2021;7:1313-1321.
[3] Kahalley LS, Peterson R, Ris MD, et al. Superior intellectual outcomes after proton radiotherapy compared with photon radiotherapy for pediatric medulloblastoma. J Clin Oncol 2020;38:454-461.

Note: All recommendations are category 2A unless otherwise indicated.

Continued

Version 1.2026, 11/25/25 © 2025 National Comprehensive Cancer Network® (NCCN®), All rights reserved. NCCN Guidelines® and this illustration may not be reproduced in any form without the express written permission of NCCN.

PLEASE NOTE that use of this NCCN Content is governed by the End-User License Agreement, and you MAY NOT distribute this Content or use it with any artificial intelligence model or tool.
Printed by A. S. M. FAZLUL KARIM CHOWDHURY on 4/20/2026 3:38:59 AM. Copyright © 2026 National Comprehensive Cancer Network, Inc. All Rights Reserved.

PRINCIPLES OF RADIATION THERAPY MANAGEMENT[1,2]

Radiation Therapy Dose[a]

- **Low and average risk:**
  - **CSI 23.4 Gy in 13 fractions of 1.8 Gy**
  - **Tumor bed boost: 30.6 Gy in 17 fractions of 1.8 Gy (54 Gy total)**
- **High risk and very high risk**
  - **CSI 36 Gy in 20 fractions of 1.8 Gy**
  - **Tumor bed boost: 18–19.8 Gy in 10 fractions of 1.8 Gy (54–55.8 Gy total)**
  - **Metastasis: 45 Gy (spine), 50.4 Gy (below spinal cord), and 54 Gy (intracranial)**
  - **>5 spine lesions: Recommend spine RT to 39.6 Gy with boost to gross disease to 45–50.4 Gy based on spinal cord/cauda equina tolerance**
  - **The dose and volume to metastatic tumor is at the treating physician's discretion for patients with diffuse or high disease burden in the brain**

Craniospinal Radiation

- **Vertebral-body-sparing CSI is allowed for patients who have reached skeletal maturity**
- **Consider growth issues and toxicity for patients who have not reached skeletal maturity**
  - **If whole vertebral bodies are targeted in skeletally immature patients, they should be largely covered by 18 Gy isodose line**

Radiation Treatment at Relapse

- **If no prior RT or no prior CSI, then CSI with appropriate boost is per high-risk RT recommendations shown above**
- **>6 months since initial RT and any focal recurrence**
  - **Focal treatment recommended**
  - **SRS, fractionated SRS, and IMRT allowed**
- **Consider CSI for disseminated recurrence if interval since initial RT >1 year**
  - **CSI dose at discretion of treating physician, may consider twice-a-day (BID) regimen**

Footnote

[a] There are some data to suggest hyperfractionated CSI may reduce late effects, but administration can be challenging.

References

[1] Michalski JM, Janss AJ, Vezina LG, et al. Children's Oncology Group phase III trial of reduced-dose and reduced-volume radiotherapy with chemotherapy for newly diagnosed average-risk medulloblastoma. J Clin Oncol 2021;39:2685-2697.
[2] Leary SES, Packer RJ, Li Y, et al. Efficacy of carboplatin and isotretinoin in children with high-risk medulloblastoma: A randomized clinical trial from the Children's Oncology Group. JAMA Oncol 2021;7:1313-1321.

Note: All recommendations are category 2A unless otherwise indicated.

Continued

Version 1.2026, 11/25/25 © 2025 National Comprehensive Cancer Network® (NCCN®), All rights reserved. NCCN Guidelines® and this illustration may not be reproduced in any form without the express written permission of NCCN.

PLEASE NOTE that use of this NCCN Content is governed by the End-User License Agreement, and you MAY NOT distribute this Content or use it with any artificial intelligence model or tool.
Printed by A. S. M. FAZLUL KARIM CHOWDHURY on 4/20/2026 3:38:59 AM. Copyright © 2026 National Comprehensive Cancer Network, Inc. All Rights Reserved.

PRINCIPLES OF RADIATION THERAPY MANAGEMENT NORMAL TISSUE CONSTRAINTS[b,4,5]

Organs at Risk (OAR)[c]	Pediatric Medulloblastoma Constraints
Eyes	**Dmax[d] <45 Gy**
Lenses	**Dmax[d] <10 Gy**
Optic nerves and chiasm	**Dmax[d] <54 Gy**
Pituitary gland/hypothalamus	**Mean dose <25 Gy[e]**
Hippocampi	**Mean dose <30 Gy[e]**
Temporal lobes	**Dmax[d] <55 Gy[e]**
Cochlea	**Mean dose <30 Gy**
Brainstem • Definition of brainstem surface: The 3-mm rind of the brainstem contoured from midbrain to medulla • Definition of brainstem core: A 3-mm anisotropic contraction of the brainstem in all directions except superior-inferior	**• Photon** **▸ Dmax[d] <58 Gy** **▸ Mean dose <54 Gy** **• Proton** **▸ Absolute Dmax[d] <56.6 Gy** **▸ D10% <55.4 Gy** **▸ D50% <52.4 Gy** **▸ Core** **◊ Dmax[d] <56.1 Gy**
Spinal cord	**Dmax[d] <54 Gy is preferred, but C1 C2 cord V54<50% is acceptable** **D 1 cc <50.4 Gy**
Uninvolved brain (Brain – PTV)	**No more than 1% or 1 cc of the tissue outside of the PTV receiving more than 110% of the prescribed dose[f]**
Esophagus[g]	**Mean dose <30 Gy**
Heart (Left ventricle)[g]	**D50% <15 Gy**
Kidneys[g]	**V25% <12 Gy**

Footnotes

[b] The noted normal tissue constraints are per COG ACNS0831 and ARAR0331.

[c] In general all normal tissues should be as low as reasonably achievable even if the constraint is achieved (ALARA principle). If patient is on a separate clinical trial, ensure that protocol recommendations/normal tissue dose constraints are met.

[d] Dmax is defined as 0.03 cc.

[e] These are for standard-risk CSI (23.4 Gy). For high-risk CSI (36 Gy), these constraints are not applicable, but should be minimized without compromising target coverage.

[f] Uninvolved brain is defined by the posterior fossa boost volume.

[g] These limits may not be achievable in patients with high-risk features, but should be minimized to as low as possible.

References

[4] Gentile MS, et al. Int J Radiat Oncol Biol Phys 2018;100:719-729.
[5] Haas-Kogan D, et al. Int J Radiat Oncol Biol Phys 2018;101:152-168.

Note: All recommendations are category 2A unless otherwise indicated.

Version 1.2026, 11/25/25 © 2025 National Comprehensive Cancer Network® (NCCN®), All rights reserved. NCCN Guidelines® and this illustration may not be reproduced in any form without the express written permission of NCCN.

PLEASE NOTE that use of this NCCN Content is governed by the End-User License Agreement, and you MAY NOT distribute this Content or use it with any artificial intelligence model or tool.
Printed by A. S. M. FAZLUL KARIM CHOWDHURY on 4/20/2026 3:38:59 AM. Copyright © 2026 National Comprehensive Cancer Network, Inc. All Rights Reserved.

PRINCIPLES OF SYSTEMIC THERAPY[a,b,c,d]

	Low and Average Risk	High and Very High Risk
Adjuvant Therapy	**Chemoradiation (COG)[c]** • Weekly Vincristine with RT (COG)[1] **Maintenance chemotherapy (COG)[1,c]** • Cycle A: Cisplatin/Lomustine/Vincristine[1,2] • Cycle B: Cyclophosphamide/Vincristine[1] • Cadence of maintenance therapy: AABAABAAB[1,3] **Maintenance chemotherapy (St. Jude protocol)[c]** • Cisplatin/Cyclophosphamide/Vincristine[4]	**Chemoradiation (COG)[c]** • Weekly Vincristine with RT (COG)[5] OR • Weekly Vincristine (+ Carboplatin prior to each RT fraction for Group 3 tumors only)[5] **Maintenance chemotherapy (COG)[c]** • 6 cycles of chemotherapy as per ACNS0332[5] ▸ Cisplatin/Cyclophosphamide/Vincristine **Maintenance chemotherapy (St. Jude protocol)[c]** • Cisplatin/Cyclophosphamide/Vincristine[4]

[a] Monitor (labs and/or imaging) as clinically indicated.
[b] Monitor for toxicity, such as motor neuropathy with vincristine and ototoxicity with cisplatin.
[c] The COG and St. Jude's protocols should not be interchanged. If patients start on one protocol, then they should not be switched to another protocol.
[d] An FDA-approved biosimilar is an appropriate substitute for any recommended systemic biologic therapy in the NCCN Guidelines.

Note: All recommendations are category 2A unless otherwise indicated.

Continued
References

Version 1.2026, 11/25/25 © 2025 National Comprehensive Cancer Network® (NCCN®), All rights reserved. NCCN Guidelines® and this illustration may not be reproduced in any form without the express written permission of NCCN.

PLEASE NOTE that use of this NCCN Content is governed by the End-User License Agreement, and you MAY NOT distribute this Content or use it with any artificial intelligence model or tool.
Printed by A. S. M. FAZLUL KARIM CHOWDHURY on 4/20/2026 3:38:59 AM. Copyright © 2026 National Comprehensive Cancer Network, Inc. All Rights Reserved.

PRINCIPLES OF SYSTEMIC THERAPY[a,d]

	All Risk Categories
Recurrent or Progressive Disease	• TEMR (Temozolomide/Irinotecan) + Bevacizumab[e,f,6] • TOTEM (Temozolomide/Topotecan)[7] • Anti-angiogenic metronomic therapy (eg, MEMMAT regimen)[8,9,10,11] ▸ Celecoxib/Oral Cyclophosphamide/Intraventricular Etoposide/Oral Etoposide/Thalidomide + Bevacizumab • Carboplatin/Etoposide[12] • Clinical trial

[a] Monitor (labs and/or imaging) as clinically indicated.
[d] An FDA-approved biosimilar is an appropriate substitute for any recommended systemic biologic therapy in the NCCN Guidelines.
[e] The addition of Bevacizumab to Temozolomide/Irinotecan significantly reduced the risk of death and an event-free survival (EFS) event in children with recurrent medulloblastoma.
[f] For patients who recently had surgery, consider temporary deferral of initiation of Bevacizumab to allow for proper wound healing.

Note: All recommendations are category 2A unless otherwise indicated.

References

Version 1.2026, 11/25/25 © 2025 National Comprehensive Cancer Network® (NCCN®), All rights reserved. NCCN Guidelines® and this illustration may not be reproduced in any form without the express written permission of NCCN.

PLEASE NOTE that use of this NCCN Content is governed by the End-User License Agreement, and you MAY NOT distribute this Content or use it with any artificial intelligence model or tool.
Printed by A. S. M. FAZLUL KARIM CHOWDHURY on 4/20/2026 3:38:59 AM. Copyright © 2026 National Comprehensive Cancer Network, Inc. All Rights Reserved.

PRINCIPLES OF SYSTEMIC THERAPY
REFERENCES

[1] Michalski JM, Janss AJ, Vezina LG, et al. Children's Oncology Group phase III trial of reduced-dose and reduced-volume radiotherapy with chemotherapy for newly diagnosed average-risk medulloblastoma. J Clin Oncol 2021;39:2685-2697.
[2] Gajjar A, Chintagumpala M, Ashley D, et al. Risk-adapted craniospinal radiotherapy followed by high-dose chemotherapy and stem-cell rescue in children with newly diagnosed medulloblastoma (St Jude Medulloblastoma-96): long-term results from a prospective, multicentre trial. Lancet Oncol 2006;7:813-820.
[3] Packer RJ, Zhou T, Holmes E, et al. Survival and secondary tumors in children with medulloblastoma receiving radiotherapy and adjuvant chemotherapy: results of Children's Oncology Group trial A9961. Neuro Oncol 2013;15:97-103.
[4] Gajjar A, Robinson GW, Smith KS, et al. Outcomes by clinical and molecular features in children with medulloblastoma treated with risk-adapted therapy: Results of an international phase III trial (SJMB03). J Clin Oncol 2021;39:822-835.
[5] Leary SES, Packer RJ, Li Y, et al. Efficacy of carboplatin and isotretinoin in children with high-risk medulloblastoma: A randomized clinical trial from the Children's Oncology Group. JAMA Oncol 2021;7:1313-1321.
[6] Levy AS, Krailo M, Chi S, et al. Temozolomide with irinotecan versus temozolomide, irinotecan plus bevacizumab for recurrent medulloblastoma of childhood: Report of a COG randomized Phase II screening trial. Pediatr Blood Cancer 2021;68:e29031.
[7] Le Teuff G, Castaneda-Heredia A, Dufour C, et al; European consortium Innovative Therapies for Children with Cancer (ITCC). Phase II study of temozolomide and topotecan (TOTEM) in children with relapsed or refractory extracranial and central nervous system tumors including medulloblastoma with post hoc Bayesian analysis: A European ITCC study. Pediatr Blood Cancer 2020;67:e28032.
[8] Peyrl A, Chocholous M, Kieran MW, et al. Antiangiogenic metronomic therapy for children with recurrent embryonal brain tumors. Pediatr Blood Cancer 2012;59:511-517.
[9] Robison NJ, Campigotto F, Chi SN, et al. A phase II trial of a multi-agent oral antiangiogenic (metronomic) regimen in children with recurrent or progressive cancer. Pediatr Blood Cancer 2014;61:636-642.
[10] Slavc I, Mayr L, Stepien N, et al. Improved long-term survival of patients with recurrent medulloblastoma treated with a "MEMMAT-like" metronomic antiangiogenic approach. Cancers (Basel) 2022;14:5128.
[11] Winnicki C, Leblond P, Bourdeaut F, et al. Retrospective national "Real Life" experience of the SFCE with the metronomic MEMMAT and MEMMAT-like protocol. J Clin Med 2023;12:1415.
[12] Gaab C, Adolph JE, Tippelt S, et al. Local and systemic therapy of recurrent medulloblastomas in children and adolescents: Results of the P-HIT-REZ 2005 study. Cancers (Basel) 2022;14:471.

Note: All recommendations are category 2A unless otherwise indicated.

Version 1.2026, 11/25/25 © 2025 National Comprehensive Cancer Network® (NCCN®), All rights reserved. NCCN Guidelines® and this illustration may not be reproduced in any form without the express written permission of NCCN.

PLEASE NOTE that use of this NCCN Content is governed by the End-User License Agreement, and you MAY NOT distribute this Content or use it with any artificial intelligence model or tool.
Printed by A. S. M. FAZLUL KARIM CHOWDHURY on 4/20/2026 3:38:59 AM. Copyright © 2026 National Comprehensive Cancer Network, Inc. All Rights Reserved.

ABBREVIATIONS

3D	three-dimensional
ADC	apparent diffusion coefficient
AI	artificial intelligence
ALARA	as low as reasonably achievable
ASL	arterial spin labeling
AYA	adolescent and young adult
bSSFP	balanced steady-state free precession
CBC	complete blood count
CI	confidence interval
CMMRD	constitutional mismatch repair deficiency
CNS	central nervous system
COG	Children's Oncology Group
CSF	cerebrospinal fluid
CSI	craniospinal irradiation
CTV	clinical target volume
D/N	desmoplastic and nodular
DCE	dynamic contrast-enhanced
DIPG	diffuse intrinsic pontine glioma
DSC	dynamic susceptibility contrast-enhanced
DTI	diffusion tensor imaging
DVT	deep vein thrombosis
DWI	diffusion-weighted imaging
EFS	event-free survival
EPI	echo-planar imaging
ETV	endoscopic third ventriculostomy
FAP	familial adenomatous polyposis
FDG	fluorodeoxyglucose
FLAIR	fluid-attenuated inversion recovery
FOV	field of view
FSE	fast spin echo
GBCA	gadolinium-based contrast agent
GBM	glioblastoma multiforme
GRE	gradient echo
GTR	gross tumor resection
GTV	gross tumor volume
H&E	hematoxylin and eosin
H&P	history and physical
IGRT	image-guided radiation therapy
IHC	immunohistochemistry
IMRT	intensity-modulated radiation therapy
IR-GRE	inversion recovery gradient-recalled echo
MMR	mismatch repair
MR	magnetic resonance
NBCCS	nevoid basal cell carcinoma syndrome
NEC	not elsewhere classified
NF1	neurofibromatosis type 1
NGS	next-generation sequencing
NTR	near total resection
OAR	organ at risk
PFS	progression-free survival
PS	performance status
PTV	planning target volume
SE	spin echo
SHH	sonic hedgehog
SIB	simultaneous integrated boost
SRS	stereotactic radiosurgery
STIR	short tau inversion recovery
STR	subtotal resection
SWI	susceptibility-weighted imaging

Continued

Version 1.2026, 11/25/25 © 2025 National Comprehensive Cancer Network® (NCCN®), All rights reserved. NCCN Guidelines® and this illustration may not be reproduced in any form without the express written permission of NCCN.

PLEASE NOTE that use of this NCCN Content is governed by the End-User License Agreement, and you MAY NOT distribute this Content or use it with any artificial intelligence model or tool.
Printed by A. S. M. FAZLUL KARIM CHOWDHURY on 4/20/2026 3:38:59 AM. Copyright © 2026 National Comprehensive Cancer Network, Inc. All Rights Reserved.

ABBREVIATIONS

T1W	**T1-weighted imaging**
TKD	**tyrosine kinase domain**
TMB	**tumor mutational burden**
TSE	**turbo spin echo**
VP	**ventriculoperitoneal**
WNT	**wingless**

Version 1.2026, 11/25/25 © 2025 National Comprehensive Cancer Network® (NCCN®), All rights reserved. NCCN Guidelines® and this illustration may not be reproduced in any form without the express written permission of NCCN.

PLEASE NOTE that use of this NCCN Content is governed by the End-User License Agreement, and you MAY NOT distribute this Content or use it with any artificial intelligence model or tool.
Printed by A. S. M. FAZLUL KARIM CHOWDHURY on 4/20/2026 3:38:59 AM. Copyright © 2026 National Comprehensive Cancer Network, Inc. All Rights Reserved.

NCCN Categories of Evidence and Consensus	
Category 1	Based upon high-level evidence (≥1 randomized phase 3 trials or high-quality, robust meta-analyses), there is uniform NCCN consensus (≥85% support of the Panel) that the intervention is appropriate.
Category 2A	Based upon lower-level evidence, there is uniform NCCN consensus (≥85% support of the Panel) that the intervention is appropriate.
Category 2B	Based upon lower-level evidence, there is NCCN consensus (≥50%, but <85% support of the Panel) that the intervention is appropriate.
Category 3	Based upon any level of evidence, there is major NCCN disagreement that the intervention is appropriate.

All recommendations are category 2A unless otherwise indicated.

NCCN Categories of Preference	
Preferred	Interventions that are based on superior efficacy, safety, and evidence; and, when appropriate, affordability.
Other recommended	Other interventions that may be somewhat less efficacious, more toxic, or based on less mature data; or significantly less affordable for similar outcomes.
Useful in certain circumstances	Other interventions that may be used for selected patient populations (defined with recommendation).

All recommendations are considered appropriate.

Version 1.2026, 11/25/25 © 2025 National Comprehensive Cancer Network® (NCCN®), All rights reserved. NCCN Guidelines® and this illustration may not be reproduced in any form without the express written permission of NCCN.

PLEASE NOTE that use of this NCCN Content is governed by the End-User License Agreement, and you MAY NOT distribute this Content or use it with any artificial intelligence model or tool.
Printed by A. S. M. FAZLUL KARIM CHOWDHURY on 4/20/2026 3:38:59 AM. Copyright © 2026 National Comprehensive Cancer Network, Inc. All Rights Reserved.

Discussion

This discussion corresponds to the NCCN Guidelines for Pediatric Central Nervous System Cancers. Last updated on: November 25, 2025

Table of Contents

Overview 2

Guidelines Update Methodology 2

Literature Search Criteria 2

Sensitive/Inclusive Language Usage 2

Tumor Types 3

Principles of Management 3

WHO Classification of Pediatric CNS Tumors 3

Pediatric Diffuse High-Grade Gliomas 3

- Introduction 4
- Principles of Neuroimaging 5
- Principles of Neuropathology 8
- Principles of Surgery 9
- Principles of Radiation Therapy Management 9
- Principles of Systemic Therapy 10
- Brief Summary of NCCN Recommendations for Diffuse High-Grade Gliomas 14

Pediatric Medulloblastoma 15

- Introduction 15
- Principles of Neuroimaging 16
- Principles of Neuropathology 17
- Principles of Surgery 18
- Principles of Radiation Therapy Management 19
- Principles of Systemic Therapy 20
- Brief Summary of NCCN Recommendations for Medulloblastoma 21

Summary 22

References 23

Version 1.2026 © 2025 National Comprehensive Cancer Network© (NCCN©), All rights reserved. NCCN Guidelines® and this illustration may not be reproduced in any form without the express written permission of NCCN.

PLEASE NOTE that use of this NCCN Content is governed by the End-User License Agreement, and you MAY NOT distribute this Content or use it with any artificial intelligence model or tool.
Printed by A. S. M. FAZLUL KARIM CHOWDHURY on 4/20/2026 3:38:59 AM. Copyright © 2026 National Comprehensive Cancer Network, Inc. All Rights Reserved.

Overview

Pediatric central nervous system (CNS) cancers are fundamentally different than adult CNS cancers with regard to tumor type, histology, tumor location, molecular characteristics, and treatment options. Although pediatric tumors are rare, accounting for only 1% of all cancer diagnoses (adult and pediatric), they are the leading cause of disease-related death in children. CNS cancers are the second most common malignancy in children after leukemia and lymphoma combined.[1] They account for 26% of all pediatric tumors and are the leading cause of cancer-related death in children.[2] More than 4000 brain and spinal cord tumors are diagnosed each year in children and teens, and the incidence rate has remained steady in recent years.[1] According to the Central Brain Tumor Registry of the United States (CBTRUS) Statistical Report, the age-adjusted incidence rate of primary CNS tumors in children ≤19 years was 6.02 per 100,000 population between 2017 and 2021.[3] The most common malignant pediatric CNS tumors are gliomas and embryonal tumors, the latter consisting predominately of medulloblastomas.[4]

Guidelines Update Methodology

The complete details of the Development and Update of the NCCN Clinical Practice Guidelines in Oncology (NCCN Guidelines®) are available at www.NCCN.org.

Literature Search Criteria

Prior to the publication of the NCCN Guidelines® for Pediatric Central Nervous System Cancers, an electronic search of the PubMed database was performed to obtain key literature in the field of neuro-oncology published since the previous Guidelines update, using the following search terms: pediatric diffuse high-grade glioma and pediatric medulloblastoma. The PubMed database was chosen because it remains the most widely used resource for medical literature and indexes peer-reviewed biomedical literature.[5]

The search results were narrowed by selecting studies in humans published in English. Results were confined to the following article types: Clinical Trial; Clinical Trial, Phase II; Clinical Trial, Phase III; Clinical Trial, Phase IV; Practice Guideline; Guidelines; Randomized Controlled Trial; Meta-Analysis; Systematic Reviews; and Validation Studies. The data from key PubMed articles and articles from additional sources deemed as relevant to these Guidelines have been included in this version of the Discussion section. Recommendations for which high-level evidence is lacking are based on the Panel's review of lower-level evidence and expert opinion.

Sensitive/Inclusive Language Usage

NCCN Guidelines strive to use language that advances the goals of equity, inclusion, and representation.[6] NCCN Guidelines endeavor to use language that is person-first; not stigmatizing; anti-racist, anti-classist, anti-misogynist, anti-ageist, anti-ableist, and anti-weight biased; and inclusive of individuals of all sexual orientations and gender identities. NCCN Guidelines incorporate non-gendered language, instead focusing on organ-specific recommendations. This language is both more accurate and more inclusive and can help fully address the needs of individuals of all sexual orientations and gender identities. NCCN Guidelines will continue to use the terms *men*, *women*, *female*, and *male* when citing statistics, recommendations, or data from organizations or sources that do not use inclusive terms. Most studies do not report how sex and gender data are collected and use these terms interchangeably or inconsistently. If sources do not differentiate gender from sex assigned at birth or organs present, the information is presumed to predominantly represent cisgender individuals. NCCN encourages researchers to collect more specific data in future studies and organizations to use more inclusive and accurate language in their future analyses.

Version 1.2026 © 2025 National Comprehensive Cancer Network© (NCCN©), All rights reserved. NCCN Guidelines® and this illustration may not be reproduced in any form without the express written permission of NCCN.

PLEASE NOTE that use of this NCCN Content is governed by the End-User License Agreement, and you MAY NOT distribute this Content or use it with any artificial intelligence model or tool.
Printed by A. S. M. FAZLUL KARIM CHOWDHURY on 4/20/2026 3:38:59 AM. Copyright © 2026 National Comprehensive Cancer Network, Inc. All Rights Reserved.

Tumor Types

The NCCN Guidelines for Pediatric Central Nervous System Cancers focus on the comprehensive care of pediatric patients with malignant diseases of the CNS. These guidelines will be updated annually to include new information or treatment philosophies as they become available. However, because this field continually evolves, practitioners should use all available information to determine the best clinical options for their patients. The updated version of the Guidelines addresses diffuse high-grade gliomas and medulloblastoma in children and adolescents.

Principles of Management

Several important principles guide surgical management and treatment with radiation therapy (RT) and systemic therapy for children with CNS tumors, including tumor histology, patient age and performance status, location of the tumor in the brain, resectability of the tumor, and prior management. All patients with pediatric diffuse high-grade gliomas and medulloblastomas should be cared for by a multidisciplinary team with experience managing CNS tumors. The involvement of pediatric oncologists/neuro-oncologists, pediatric radiation oncologists, pathologists with expertise in neuropathology and molecular pathology, pediatric neuroradiologists, and pediatric neurosurgeons is strongly encouraged. Pathologic diagnosis is critical and may be difficult to accurately determine without sufficient tumor tissue. Review of the tumor tissue by an experienced neuropathologist is highly recommended. The information contained in the algorithms and principles of management sections are designed to help clinicians navigate the complex management of CNS tumors in pediatric patients.

WHO Classification of Pediatric CNS Tumors

Due to the unique nature of childhood tumors made clear by advancements in molecular analyses, pediatric tumors are now covered in separate sections of the published fifth edition of the World Health Organization (WHO) Classification of Tumors of the Central Nervous System (WHO CNS5) as well as in the inaugural WHO Classification of Pediatric Tumors.[7,8] These volumes reflect fundamental paradigm shifts affecting pediatric CNS tumor classification, including the use of a layered, integrated, diagnostic approach involving both histologic and molecular analyses; the inclusion of novel, molecularly defined tumor entities; the adaptation of tumor grading as a measure for differential aggressiveness within a tumor type rather than between tumor types; and the widespread introduction of novel molecular diagnostic tools for tumor classification.

Pediatric Diffuse High-Grade Gliomas

In WHO CNS5, gliomas are divided into distinct categories: adult-type diffuse gliomas (the majority of primary brain tumors in adults), pediatric-type diffuse low-grade gliomas (expected to have good prognoses), and pediatric-type diffuse high-grade gliomas (expected to have poor prognosis); circumscribed astrocytic gliomas (referring to their more concentrated growth pattern); glioneuronal and neuronal tumors; and ependymomas.[7]

The NCCN Guidelines for Pediatric Central Nervous System Cancers currently include recommendations for the management of the four types of pediatric-type diffuse high-grade gliomas recognized in WHO CNS5[7] and refer to children and adolescents ≤21 years of age:

- Diffuse hemispheric glioma, *H3* G34-mutant
- Diffuse pediatric-type high-grade glioma, *H3* wild-type and *IDH* wild-type
- Infant-type hemispheric glioma
- Diffuse midline glioma (DMG), *H3* K27-altered

Version 1.2026 © 2025 National Comprehensive Cancer Network© (NCCN©), All rights reserved. NCCN Guidelines® and this illustration may not be reproduced in any form without the express written permission of NCCN.

PLEASE NOTE that use of this NCCN Content is governed by the End-User License Agreement, and you MAY NOT distribute this Content or use it with any artificial intelligence model or tool.
Printed by A. S. M. FAZLUL KARIM CHOWDHURY on 4/20/2026 3:38:59 AM. Copyright © 2026 National Comprehensive Cancer Network, Inc. All Rights Reserved.

The first three are newly recognized tumor entities. Diffuse hemispheric glioma, *H3* G34-mutant is a malignant, infiltrative glioma of the cerebral hemispheres with a missense mutation in the *H3F3A* gene that results in a G34R/V substitution of histone H3. Diffuse pediatric-type high-grade glioma, *H3* wild-type and *IDH* wild-type represent a mixture of distinct molecular subtypes specified as being wild-type for both *H3* and *IDH* gene families. Infant-type hemispheric glioma is a novel tumor type typically occurring in newborns and very young children and is associated with fusion genes involving *ALK*, *ROS1*, *NTRK1/2/3*, or *MET.* While not a new entity, the nomenclature has changed from DMG, *H3* K27-mutant to DMG, *H3* K27-altered in order to include subtypes with a different mechanism for the loss of *H3* K27 trimethylation (eg, EZHIP protein overexpression).[7,8] These guidelines do not include recommendations for primary spinal cord tumors.

Introduction

Epidemiology

Pediatric diffuse high-grade glioma represents approximately 9.3% of all primary malignant and non-malignant brain and other CNS tumors diagnosed in children and adolescents ≤19 years.[4] Although incidence rates generally decrease with age from 0 to 19 years, the rate of high-grade glioma in the brain-stem, specifically, is highest for age groups 5 to 9 years (0.56 per 100,000 population).[4] The prognosis for aggressive diffuse high-grade gliomas is generally poor with 5-year survival rates of <20% despite the use of combined modality therapies of surgery, RT, and systemic therapy.[9] Prognosis and survival rates for diffuse high-grade gliomas depend on multiple factors including the age at presentation, tumor location, sex, extent of resection, histologic subtype, and genomic profile.[10] While diagnosis is more common in females, males typically have higher mortality rates from CNS tumors.[11]

Risk Factors

Although the cause of most pediatric CNS tumors is unknown, several genetic and environmental factors have been linked to an increased risk of primary brain tumor development in children. Certain inherited cancer predisposition syndromes, including neurofibromatosis type 1 (NF1), Li-Fraumeni syndrome, and Turcot syndrome/Lynch syndrome/constitutional mismatch repair deficiency (CMMRD), are associated with increased susceptibility to pediatric diffuse high-grade gliomas.[12-15] Exposure to high-dose ionizing radiation has also been linked to pediatric brain malignancies.[12,16,17] Ionizing radiation has more carcinogenic potential in children because they are more radiosensitive than adults and have more potential years of life to express the risk.[17] Estimated risk is higher for younger children, and the predicted latency between radiation exposure and brain tumor development is 7 to 9 years, with meningiomas and gliomas being the most common radiation-induced tumor types.[10-12,17]

Clinical Presentation

Presentation and symptoms depend largely on tumor location and patient age at the time of diagnosis.[18] The most common symptoms include effects of increased intracranial pressure, such as headaches that worsen over time, nausea, vomiting, and blurred vision. These may be caused by growth of the tumor, swelling in the brain, or blocked flow of cerebrospinal fluid (CSF).[1] Other presenting symptoms include seizure, hemiparesis, monoparesis, cranial nerve deficits, ataxia, hemisensory loss, dysphasia, aphasia, and memory impairment. Presenting symptoms among infants include increasing head circumference and loss of developmental milestones. School-age children may experience poor school performance, fatigue, and personality changes. Symptoms may occur gradually and worsen over time, or occur suddenly, such as with a seizure.[1]

Version 1.2026 © 2025 National Comprehensive Cancer Network© (NCCN©), All rights reserved. NCCN Guidelines® and this illustration may not be reproduced in any form without the express written permission of NCCN.

PLEASE NOTE that use of this NCCN Content is governed by the End-User License Agreement, and you MAY NOT distribute this Content or use it with any artificial intelligence model or tool.
Printed by A. S. M. FAZLUL KARIM CHOWDHURY on 4/20/2026 3:38:59 AM. Copyright © 2026 National Comprehensive Cancer Network, Inc. All Rights Reserved.

Treatment Overview

Treatment for pediatric diffuse high-grade glioma depends on many factors such as the type of tumor, its location and size, how far it has spread, and the age and overall health of the patient.[1] The main treatment paradigm includes surgery followed by systemic therapy with or without RT. The goals of surgery include the safe reduction of tumor-associated mass effect and obtaining adequate tissue for histologic and molecular classification. The location and size of the tumor and the general condition of the patient are important determinants of surgical outcome.[10,12,19,20] Cranial radiation may result in developmental impairments in young children; therefore, it is reasonable to defer or omit RT in children <3 years.[10] Despite surgery and adjuvant therapy, pediatric diffuse high-grade gliomas typically have a poor prognosis. Referral for cancer predisposition evaluation and/or genetic counseling should be considered.

Principles of Neuroimaging

Conventional MRI is recommended for tumor diagnosis, surgical guidance, and therapeutic monitoring. It may be complemented by advanced neuroimaging techniques such as MR perfusion imaging, MR spectroscopy, and PET to enhance diagnostic capability, differentiate radiation necrosis from active neoplasm, and guide biopsy. Some imaging modalities or techniques may not be available at all institutions. Imaging is always recommended to investigate the etiology of emergent signs and symptoms. Below is a list of imaging modalities used in neuro-oncology to make treatment decisions.

MRI of the Brain and/or Spine

Conventional MRI of the entire neural axis (with and without intravenous [IV] contrast) is the imaging modality of choice for the evaluation of pediatric diffuse high-grade gliomas.[21] MRI offers excellent soft tissue contrast and depiction of neoplasms through a combination of standard, universally available pulse sequences. An additional benefit of MRI is that there is no exposure of the patient to ionizing radiation. Pediatric diffuse high-grade gliomas typically show an infiltrative growth pattern and present as large, heterogeneous, poorly differentiated, intracranial masses with indistinct borders occupying most of one hemisphere.[10] They may demonstrate mass effect on surrounding structures, hemorrhage, increased perfusion, vasogenic edema, and a variable degree of contrast enhancement.[21] Higher grade components commonly enhance and demonstrate restricted diffusion, which is a key feature that reflects the high-grade nature of the tumor.[10] Rarely, high-grade pediatric gliomas may be well-circumscribed without the above-mentioned imaging features; hence, tissue biopsy is always recommended when possible. Limitations of MRI include the relatively long examination time, requirement of deep sedation/anesthesia for younger children, metal from surgery and implants causing artifacts, and unsafe nature of some implants in the MRI environment.

Compared to gray matter, pediatric diffuse high-grade gliomas may demonstrate iso- to hypointense T1 signal and hyperintense T2 signal with surrounding edema, which is apparent on fluid-attenuated inversion recovery (FLAIR) images. Different signal characteristics can be seen in the case of tumor hemorrhage, such as T1 hyperintense, T2 hypointense, and low signal on susceptibility-weighted imaging.[21] Therefore, basic MRI sequences of the brain should include T1-weighted images before contrast; T1-weighted images in two planes after contrast (one of which would ideally be acquired as a three-dimensional [3D] sequence); T2-weighted, T2-FLAIR, and diffusion-weighted imaging (DWI); and gradient echo or susceptibility-weighted (blood-sensitive) imaging. T2 hypointensity or reduced diffusion may indicate high cellularity.[22] These images should be utilized for preliminary diagnostic evaluation and immediate postoperative follow-up (ideally within 24–48 hours after surgery, if clinically feasible) to evaluate disease

Version 1.2026 © 2025 National Comprehensive Cancer Network© (NCCN©), All rights reserved. NCCN Guidelines® and this illustration may not be reproduced in any form without the express written permission of NCCN.

PLEASE NOTE that use of this NCCN Content is governed by the End-User License Agreement, and you MAY NOT distribute this Content or use it with any artificial intelligence model or tool.
Printed by A. S. M. FAZLUL KARIM CHOWDHURY on 4/20/2026 3:38:59 AM. Copyright © 2026 National Comprehensive Cancer Network, Inc. All Rights Reserved.

burden (measurable and non-measurable disease) on initial examination and extent of resection on immediate postoperative scan.[22-25]

Basic MRI imaging of the spine should include post-contrast sagittal and axial T1-weighted images of the entire neural axis; additional sequences such as heavily T2-weighted images and/or DWI may be considered. These images should be utilized to evaluate for leptomeningeal metastasis. Preoperative spine imaging should be performed at the time of brain imaging since many children require sedation to tolerate the examination. Baseline imaging of the brain and spine, especially by MRI, is recommended before treatment for high-grade gliomas.

Follow-up studies of the brain and spine should be performed at intervals defined by the treatment algorithms. More frequent imaging may be necessary in the event of clinical deterioration or evolving imaging findings concerning recurrent or residual disease. The Panel also recommends considering spine imaging in addition to brain MRI for restaging resected recurrent or progressive disease. Longitudinal follow-up studies may be complemented by MR perfusion or MR spectroscopy to assess response to therapy or to evaluate for progression, pseudo-progression, or radiation necrosis. Postoperative spine MRI evaluating for leptomeningeal spread of neoplasm should be delayed 2 to 3 weeks to avoid confusion with blood byproducts.

MR Perfusion

MR perfusion refers to a group of techniques that measure cerebral blood volume (CBV) and/or cerebral blood flow (CBF) in neoplasms. These techniques may be useful for grading, response assessment, identifying malignant degeneration and pseudo-progression, distinguishing radiation necrosis from recurrent neoplasm, and choosing biopsy site.[26-28] Limitations of MR perfusion include the degradation of reliability by adjacent metal, blood byproducts, air, and bone/soft tissue interface, and other general limitations of MRI as listed above. Generally, most high-grade gliomas show higher perfusion (increased CBV and/or CBF) than low-grade gliomas.[21,29]

Various MR perfusion techniques include dynamic susceptibility contrast-enhanced [DSC], dynamic contrast-enhanced [DCE], and arterial spin labeling [ASL] perfusion. The choice among these will depend upon user availability and preference. DSC perfusion is the most commonly used technique. Due to the need for power injectors and large-bore IV access, DSC is challenging to perform on infants but is feasible in young children.[21] Other limitations include calcification and hemorrhage-induced susceptibility within the tumor and contrast leakage due to breakdown of the blood-brain barrier.[21] DCE can be used as an alternative or complementary technique to DSC, although few studies have assessed its use in children.[30,31] The advantages of DCE over DSC are fewer artifacts, multiparametric characterization of tumor microvasculature, and the quantification of leakage to assess blood-brain barrier integrity[32]; however, DSC typically offers better blood volume estimation than DCE.[33]

ASL perfusion, which uses magnetically labeled water as contrast, has been shown to be effective in grading and choosing biopsy site in children with brain tumors.[34-36] ASL lacks contrast injection and high-flow injections making it advantageous for pediatric use. Other advantages include easier potential for CBF quantification, better image quality in younger children due to their immature sinus cavities, and the ability to repeat the test if the patient moves.[21,37] Limitations of ASL perfusion include a low signal-to-noise ratio, the need for greater magnetic field strength, and the fact that assessment is limited to CBF.[38]

MR Spectroscopy

MR spectroscopy is used to assess the metabolites of tissues including neoplasms and may be useful for grading, response assessment, identifying malignant degeneration and pseudo-progression,

Version 1.2026 © 2025 National Comprehensive Cancer Network© (NCCN©), All rights reserved. NCCN Guidelines® and this illustration may not be reproduced in any form without the express written permission of NCCN.

PLEASE NOTE that use of this NCCN Content is governed by the End-User License Agreement, and you MAY NOT distribute this Content or use it with any artificial intelligence model or tool.
Printed by A. S. M. FAZLUL KARIM CHOWDHURY on 4/20/2026 3:38:59 AM. Copyright © 2026 National Comprehensive Cancer Network, Inc. All Rights Reserved.

distinguishing radiation necrosis from recurrent neoplasm, and choosing biopsy site.[21,28,39] The choice between single voxel and multivoxel spectroscopy will depend on user preference and availability. The limitations of MR spectroscopy include the degradation of reliability by adjacent metal, blood byproducts, and bone/soft tissue/air interfaces; long and complex acquisitions; expertise in technique/post-processing; nonstandard acquisitions; nonstandard post-processing; and post-processing time.

A systematic review and meta-analysis comprising 455 patients across 18 studies showed that MR spectroscopy alone only has moderate diagnostic ability to differentiate glioma recurrence from radiation necrosis, and should therefore be combined with other techniques for this purpose.[39] Another systematic review and meta-analysis comparing the diagnostic accuracy of advanced MRI techniques to conventional MRI found that MR spectroscopy had the highest diagnostic accuracy for treatment response evaluation in patients with high-grade glioma, supporting its use for this purpose.[28]

CT of the Brain

MRI scans are used more often than CT scans for brain and spine imaging because they are more detailed and do not use radiation. However, there are some circumstances in which CT scan provides advantages over MRI. CT offers higher sensitivity to dystrophic calcification in neoplasms. It also provides greater detail of bone structures and therefore might show the effects of tumors on the skull.[1] CT also has a shorter acquisition time and sedation is generally not needed. Limitations of CT include limited soft tissue contrast; limited evaluation of metastatic disease; and metal-caused streak artifacts.

On CT, pediatric diffuse high-grade gliomas typically present as heterogeneous lesions with mass effect, poorly defined margins, and variable areas of hyperattenuation, which may reflect hemorrhage, necrosis, or surrounding edema. Contrast-enhanced CT features are variable.[21]

CT of the brain (without contrast or with and without contrast) is ideal for rapid assessment in the acute or immediate postoperative setting and for the evaluation of acute intracranial hemorrhage, ventriculomegaly, and shunt-related issues. CT is recommended when MRI is not available or in patients in whom an MRI is contraindicated because of unsafe implants or foreign bodies. However, CT is not recommended for staging and response evaluation for high-grade glioma except for the very rare cases where MRI is not feasible.

Brain PET Studies

Brain PET studies assess tumor biology by using tracers with distinct mechanisms of uptake, allowing distinction between biological processes within the tumor. PET is typically combined with anatomical imaging and may be useful in tumor delineation, differentiating between neoplasm and radiation necrosis, tumor grading, or identifying a more aggressive focus for biopsy. Since PET scan images are not as detailed as CT or MRI, they are used mostly as a complementary test to provide information about whether abnormal areas seen on other imaging tests are likely to be tumors.[40] PET is more likely to be helpful for identifying high-grade tumors than low-grade tumors.[40] Additional limitations of PET include availability of radioisotopes and radiation exposure to the patient.

Supplemental Imaging for Preoperative Planning

Isotropic volumetric MRI may be used for preoperative planning to accurately localize neoplasms by co-registering the data with intraoperative guidance software. This technique is often complemented with isotropic CT studies to improve localization. Functional MRI studies can be used to depict spatial relationships between eloquent cortex (eg, regions of the brain primarily responsible for speech, vision, and motor and sensory function) and the neoplasms to serve as a road map and

Version 1.2026 © 2025 National Comprehensive Cancer Network© (NCCN©), All rights reserved. NCCN Guidelines® and this illustration may not be reproduced in any form without the express written permission of NCCN.

PLEASE NOTE that use of this NCCN Content is governed by the End-User License Agreement, and you MAY NOT distribute this Content or use it with any artificial intelligence model or tool.
Printed by A. S. M. FAZLUL KARIM CHOWDHURY on 4/20/2026 3:38:59 AM. Copyright © 2026 National Comprehensive Cancer Network, Inc. All Rights Reserved.

promote safe resections. Diffusion tensor imaging (DTI) with tractography may also be used to localize major white matter tracts underlying the eloquent cortex that could also compromise vital functions if injured during surgery.

Principles of Neuropathology

There are fundamental molecular differences between pediatric and adult CNS tumors, most recently recognized in WHO CNS5.[7,8,21] In contrast to tumors in adults, tumors in children typically carry a much lower burden of genetic aberrations (except for hypermutant tumors), and are often driven by a single genetic driver event, such as a point mutation or translocation leading to an oncogenic fusion.[7,8] The NCCN Guidelines describe guiding principles for the diagnosis of pediatric CNS tumors according to the parameters of WHO CNS5.[7,8] A general workflow for processing of tissue and tumor characterization using histologic, immunohistochemical (IHC), and molecular data is covered in the algorithm. However, this is not meant to serve as an exhaustive algorithm for diagnosis and classification of the multitude of subtypes of pediatric diffuse high-grade gliomas that have presently been described.

Standard Histopathologic Examination and Classification

Integrated histopathologic and molecular characterization of gliomas per WHO CNS5 should be standard practice.[7] Molecular and genetic characterization complements standard histopathologic analysis, providing additional diagnostic and prognostic information that improves diagnostic accuracy and aids in treatment and clinical trial selection. Therefore, histologic and IHC examination should be performed on all tumors. Care should be taken to conserve tissue, and IHC studies for molecular markers may be skipped in lieu of submitting tissue directly for molecular studies in cases where the specimen is scant. Molecular alterations demonstrated by IHC may require confirmation by other techniques.

Molecular Characterization

Pediatric diffuse high-grade gliomas comprise a biologically diverse group of tumors. There is a high degree of histologic overlap and non-specificity of histologic features amongst the numerous recognized pathologic entities of pediatric tumors, which underscores the importance of molecular testing in pediatric tumor diagnostics. Molecular testing is required in many cases to distinguish high-grade tumors from lower grade counterparts, and uncovering alterations that have been demonstrated to be prognostically relevant.[41-46] In addition, clinical trial stratification is becoming increasingly dependent on molecular characterization. See Table 1 on PGLIO-B 3 of 4 in the algorithm for molecular alterations of significance in pediatric gliomas.

Considering the sheer number of genes of interest, in conjunction with the many types of recurrent alterations (including point mutations, insertion/deletions, copy number variations, and fusions), broad molecular testing is required for comprehensive classification of pediatric diffuse high-grade gliomas. Therefore, the Panel recommends including tests to detect copy number changes and gene fusions via next-generation sequencing (NGS) (including *ROS1, MET, NTRK1/2/3, ALK,* and *FGFR1/2/3*), RNA sequencing, or high-resolution copy number array. DNA methylation-based analysis may offer objective, more precise tumor classification; however, it should not be used as a first-line molecular test. In the pediatric population, dedicated germline testing should be strongly considered in the appropriate clinical context, recognizing that not all sequencing assays readily distinguish between germline and somatic variants.[47,48]

Limited Tissue Sample/Specimen

In cases where there is limited tissue available for processing, care should be taken to prioritize obtaining the following tests: hematoxylin and eosin (H&E) histology, limited IHC panel, NGS, and methylation

Version 1.2026 © 2025 National Comprehensive Cancer Network© (NCCN©), All rights reserved. NCCN Guidelines® and this illustration may not be reproduced in any form without the express written permission of NCCN.

PLEASE NOTE that use of this NCCN Content is governed by the End-User License Agreement, and you MAY NOT distribute this Content or use it with any artificial intelligence model or tool.
Printed by A. S. M. FAZLUL KARIM CHOWDHURY on 4/20/2026 3:38:59 AM. Copyright © 2026 National Comprehensive Cancer Network, Inc. All Rights Reserved.

profiling. The limited IHC panels should only use stains that would provide essential diagnostic information. In cases of particularly limited tissue, stains for mutations (such as *IDH1* R132H or *BRAF* V600E) already covered by NGS can be omitted if redundant.

Principles of Surgery

Surgical resection plays an important role in the primary treatment of non-pontine pediatric diffuse high-grade gliomas. The goals of surgery are maximal safe tumor resection, alleviation of symptoms related to increased intracranial pressure or tumor mass effect, increased survival, decreased need for corticosteroids, and obtaining adequate tissue for pathologic diagnosis and molecular characterization. The histology and location of the tumor, as well as the extent of possible resection, are significant prognostic factors that influence the decision for surgical management.[49] Surgical resection is not feasible for patients with DMG of the pons or most other brainstem tumors.

Preoperative Assessment

All patients being considered for surgery should undergo a preoperative assessment including laboratory work, imaging, and multidisciplinary consultation. Advanced imaging can be considered in cases where patients may benefit from it. Emergent situations should be treated prior to further investigative studies or interventions. Consider medical management to treat focal neurologic deficits, seizure, and pain. However, medications that may alter the patient's neurologic examination or increase surgical risks should be avoided. Outside of emergent clinical presentations, multidisciplinary case discussion should be utilized for treatment planning and optimization of patient care, including radiation oncology, neurosurgery, radiology, and oncology/neuro-oncology. Physical therapy/occupational therapy and sleep and swallow assessments can be considered to assist with comorbidity management, and referral to a child life social worker can be considered for family/patient support.

Surgical Procedure

Study-level and individual patient data meta-analyses have demonstrated an association between greater extent of resection and improved overall survival (OS) and progression-free survival (PFS) in patients with pediatric diffuse high-grade gliomas.[50-57] In the HIT-GBM study of 85 pediatric patients with malignant non-pontine gliomas, gross total resection (GTR) was the strongest predictor of OS and event-free survival (EFS).[56] In the HIT-GBM-C study, 5-year OS was significantly improved in patients with tumors that were completely resected prior to combination chemoradiotherapy (63%; N = 21) when compared to historical controls (17%; $P = .003$).[55] The Panel recommends maximal safe resection with the goal of image-verified complete resection whenever possible. In cases where complete resection is not feasible, subtotal resection (STR) for tissue diagnosis and debulking should be considered, especially if the patient exhibits symptoms due to mass effect. In cases where clinical benefit from cytoreduction is not feasible, biopsy is recommended.

Nearly all diffuse high-grade gliomas recur. Re-resection at the time of recurrence may improve outcomes, although evidence varies widely.[52,58] As in adult patients with diffuse high-grade gliomas, tumor involvement in specific critical brain areas and poor performance status may be associated with unfavorable re-resection outcomes.[58]

Postoperative Management

After surgical resection, patients should be monitored for signs and symptoms of increased intracranial pressure. Prophylaxis for seizures, infections, and venous thromboembolism can be considered.[59]

Principles of Radiation Therapy Management

RT plays an essential role in the adjuvant treatment of patients with pediatric diffuse high-grade gliomas who are ≥3 years.[60,61] Except in those with pontine DMGs, it is reasonable to defer or omit RT in patients <3

Version 1.2026 © 2025 National Comprehensive Cancer Network© (NCCN©), All rights reserved. NCCN Guidelines® and this illustration may not be reproduced in any form without the express written permission of NCCN.

PLEASE NOTE that use of this NCCN Content is governed by the End-User License Agreement, and you MAY NOT distribute this Content or use it with any artificial intelligence model or tool.
Printed by A. S. M. FAZLUL KARIM CHOWDHURY on 4/20/2026 3:38:59 AM. Copyright © 2026 National Comprehensive Cancer Network, Inc. All Rights Reserved.

years out of concern for long-term complications with brain development.[10,12,19,20] However, standard brain RT can be considered for patients <3 years, if no other options are feasible or the tumor did not respond to chemotherapy and/or additional systemic therapies. Child life specialists, audio and video distraction techniques, and other pediatric-friendly interventions are recommended to improve pediatric tolerance of RT without anesthesia. The dose of RT administered varies depending on the setting and pathology.

Following surgery, patients ≥3 years with pediatric diffuse high-grade gliomas (except for those with pontine DMG) are treated with RT combined with concurrent and/or adjuvant systemic therapy.[60,61] Initiation of RT is recommended whenever the patient has recovered from surgery and should begin within 8 weeks of resection. Intensity-modulated RT (IMRT) is used in most instances to allow reduction of risk or magnitude of side effects from treatment. Standard normal tissue constraints should be used, and although the prognosis of these patients is often poor, the as low as reasonably achievable (ALARA) principle still applies to the lenses, retina, pituitary gland/hypothalamus, cochlea, lacrimal glands, hippocampi, temporal lobes, spinal cord, and uninvolved brain. Proton therapy, which offers maximal sparing of normal tissue, may be considered for patients with better prognoses (eg, *IDH1*-mutated tumors, 1p19q-codeleted, younger age), since most of the data are derived from studies involving pediatric patients with low-grade glioma.[62-66]

The majority of studies on reirradiation are from adult high-grade glioma studies of recurrent glioblastoma multiforme (GBM) and have suggested improvements in PFS, but limited OS gains.[58,67-70] Multiple dosing schedules have been reported for reirradiation, including stereotactic radiosurgery (SRS).[58,68-71] One of the few pediatric studies conducted was a retrospective cohort study of 40 children with recurrent supratentorial high-grade glioma who had received at least one course of RT.[72] Of the 40 children, 14 received reirradiation and had improved median survival from the time of first disease progression when compared with the 26 patients who were not offered reirradiation (9.4 vs. 3.8 months; $P = .005$), suggesting that reirradiation can be effective for short-term disease control.

Patients with pontine DMG should begin RT as soon as possible after diagnosis, regardless of age, given the highly effective nature of this modality for symptom control.[20] Dose-escalated RT and concurrent or adjuvant systemic therapy have produced disappointing results in patients with pontine DMG, and therefore RT dose escalation beyond the standard RT doses is not recommended.[20,73-77] The Panel recommends using IMRT, but 3D conformal RT is also an acceptable option.[19] Hypofractionated RT has been evaluated as an alternative to standard fractionation in the first-line and reirradiation settings, although data are limited and studies are ongoing to assess the benefits and safety of this approach.[78-80] Although data have shown hypofractionated RT to be statistically noninferior to conventional RT,[81,82] larger, multi-institutional trials are needed to elucidate the optimal technique, dose, and fractionation for RT in the treatment of pediatric patients with pontine DMG. Patients with pontine DMG whose tumors progress or recur following initial RT have poor prognosis and limited treatment options. Palliative reirradiation has been shown to alleviate symptoms in these patients and improve quality of life.[83-85]

Principles of Systemic Therapy

Combined Modality Therapy

The Panel's preference for the use of RT with concurrent temozolomide followed by adjuvant temozolomide and lomustine for patients ≥3 years is supported by the results of the phase II COG ACNS0423 trial. This trial reported the results of 108 pediatric patients with high-grade gliomas who received RT with concurrent and adjuvant temozolomide plus lomustine for 6 cycles following maximal surgical resection.[60] The 3-year

Version 1.2026 © 2025 National Comprehensive Cancer Network© (NCCN©), All rights reserved. NCCN Guidelines® and this illustration may not be reproduced in any form without the express written permission of NCCN.

PLEASE NOTE that use of this NCCN Content is governed by the End-User License Agreement, and you MAY NOT distribute this Content or use it with any artificial intelligence model or tool.
Printed by A. S. M. FAZLUL KARIM CHOWDHURY on 4/20/2026 3:38:59 AM. Copyright © 2026 National Comprehensive Cancer Network, Inc. All Rights Reserved.

EFS and OS were significantly improved compared to the participants of the ACNS0126 study who received adjuvant temozolomide alone without lomustine (0.22 vs. 0.11; *P* = .019 and 0.28 vs. 0.19; *P* = .019, respectively).[60,61] The addition of lomustine also resulted in significantly better EFS and OS in participants without GTR (*P* = .019 and *P* =.00085, respectively). Although the addition of lomustine resulted in modest outcome benefits compared to temozolomide alone, survival rates remained low. Therefore, use of this regimen without lomustine is also an option for adjuvant therapy.[61]

Chemotherapy

It is reasonable to avoid RT in patients <3 years due to the risk of brain injury; therefore, chemotherapy alone is recommended for these patients. The chemotherapy regimens recommended by the Panel in this setting are cyclophosphamide; vincristine, cisplatin, and etoposide; and vincristine, carboplatin, and temozolomide.[86,87] A Pediatric Oncology Group study showed that high-grade gliomas in children <3 years are sensitive to chemotherapy.[86] In this study, 18 children <3 years with malignant gliomas were treated with postoperative cyclophosphamide and vincristine for two cycles. Of the 10 patients evaluated for neuroradiologic response, the partial response rate was 60% and the 5-year PFS rate was 43%. In the Head Start II and III trials, 32 children <6 years with newly diagnosed high-grade gliomas were treated with four cycles of induction chemotherapy with vincristine, carboplatin, and temozolomide followed by myeloablative chemotherapy and autologous hematopoietic cell transplantation.[87] The 5-year EFS and OS rates were 25% and 36%, respectively. Children <3 years had improved 5-year EFS and OS (44% and 63%, respectively) compared to older children (31% and 38% for children aged 36–71 months and 0% and 13% for children ≥72 months).

Targeted Therapy

Advances in molecular technology have enabled the development of molecular agents capable of targeting the biological drivers of pediatric diffuse high-grade gliomas.[88] These targeted therapies provide a means for treating pediatric patients without the involvement of cytotoxic chemotherapy and radiation. Evidence for the use of several targeted therapies in the treatment of patients with pediatric diffuse high-grade gliomas with various molecular signatures is discussed in further detail below.

BRAF V600E-Mutated Tumor

The *BRAF* V600E point mutation, which results in constitutive activation of the MEK/ERK pathway, is detected in approximately 10% to 15% of pediatric high-grade gliomas.[89-91] Many tumors that initially respond to *BRAF* inhibition eventually develop resistance due to reactivation of the MAPK pathway.[92,93] Combined therapy targeting *BRAF* and downstream MEK has shown success in several clinical trials in adults with cancer.[92-94] However, data on this regimen in the pediatric population are limited to case series and reports.[95,96] In one such case series, three pediatric patients with *BRAF* V600E–mutated high-grade gliomas exhibited clinical responses to combined BRAF/MEK blockade using dabrafenib and trametinib.[95] One patient who received the combination as maintenance therapy following resection and RT remained disease-free for 20 months, at which time disease progression was noted. The other two patients who were treated with the combined regimen at the time of disease progression or at initial diagnosis experienced a reduction in tumor size and stabilized disease for 32 and 23 months, respectively. None of the patients exhibited significant toxicities.

BRAF blockade with vemurafenib has also shown early success in treating patients with pediatric diffuse high-grade gliomas.[88,97,98] In the phase I trial of the Pediatric Neuro-Oncology Consortium study (PNOC-

Version 1.2026 © 2025 National Comprehensive Cancer Network© (NCCN©), All rights reserved. NCCN Guidelines® and this illustration may not be reproduced in any form without the express written permission of NCCN.

PLEASE NOTE that use of this NCCN Content is governed by the End-User License Agreement, and you MAY NOT distribute this Content or use it with any artificial intelligence model or tool.
Printed by A. S. M. FAZLUL KARIM CHOWDHURY on 4/20/2026 3:38:59 AM. Copyright © 2026 National Comprehensive Cancer Network, Inc. All Rights Reserved.

002), 19 pediatric patients with recurrent or progressive *BRAF* V600E–mutated high-grade gliomas were treated with vemurafenib for a median of 23 cycles.[88] One patient had a complete response, 5 patients had partial responses, and 13 patients experienced stabilized disease. Grade ≥3 adverse events included secondary keratoacanthoma, rash, and fever. The phase II part of the trial is currently ongoing (NCT01748149).

TRK Fusion-Positive Tumor

Gene fusions involving *NTRK1*, *NTRK2*, or *NTRK3* encode for TRK fusion proteins (ie, TRKA, TRKB, TRKC) that have increased kinase function and are implicated in the oncogenesis of many solid tumors.[99,100] The small-molecule TRK inhibitors larotrectinib and entrectinib have demonstrated activity in several trials of adults and children with various cancers.[101-104] In the multicenter phase I SCOUT trial, 24 pediatric and adolescent patients (aged 1 month to 21 years; median age, 4.5 years) with advanced solid or primary CNS tumors were treated with larotrectinib, regardless of TRK fusion status.[103] In patients with TRK fusion-positive tumors, the overall response rate (ORR) was 93% compared to 0% in patients without TRK fusion. In addition to a high ORR, larotrectinib was also well tolerated, with most patients experiencing only grade 1 adverse events and dose-limiting toxicity in one patient. The phase II part of this trial is currently ongoing (NCT02637687).

The phase I/II STARTRK-NG trial assessed the activity of entrectinib in 43 pediatric patients (aged <22 years) with solid tumors including primary CNS tumors, regardless of TRK fusion status.[102] In patients with TRK fusion-positive tumors, the ORR was 58% and the median duration of treatment was 11 months. The median duration of response was not reached. Treatment with entrectinib resulted in antitumor activity in patients with TRK fusion-positive tumors; however, it also led to dose-limiting toxicities in four patients (9%). The most common treatment-related adverse events were weight gain (49%) and bone fractures (21%). The phase II part of this trial is currently ongoing (NCT02650401).

Based on the TRIDENT trial, the FDA issued accelerated approval for repotrectinib, another *NTRK*-based regimen, for adult and pediatric patients ≥12 years with solid tumors that have an *NTRK* gene fusion, are locally advanced or metastatic or where surgical resection is likely to result in severe morbidity, and that have progressed following treatment or have no satisfactory alternative therapy.[105,106] An ongoing phase I/II CARE study is recruiting children and young adults with advanced or metastatic solid tumors to evaluate repotrectinib in combination with chemotherapy (NCT05004116). The Panel recommends repotrectinib as an option in both adjuvant and recurrent or progressive disease for diffuse high-grade gliomas.

ALK Rearrangement-Positive Tumor

The Panel included options for ALK rearrangement-positive, high-grade gliomas based on studies/case report for this hard-to-treat young population group. Alectinib and lorlatinib were tolerated in these small subgroups and showed clinically beneficial outcomes.[107,108] Both alectinib and lorlatinib are included as options in both adjuvant and recurrent or progressive disease for diffuse high-grade gliomas.

Hypermutant Tumor

The inherited cancer predisposition syndrome CMMRD often leads to the development of pediatric diffuse high-grade gliomas characterized by a higher mutational burden than typically seen in sporadically occurring brain tumors or other solid tumors.[109] The resultant hypermutant tumors may be amenable to immune checkpoint inhibition; however, evidence of their efficacy is currently limited to case reports and single-institution experiences.[109-111] In one such case report, two siblings with recurrent hypermutant pediatric diffuse high-grade gliomas were treated with the

Version 1.2026 © 2025 National Comprehensive Cancer Network© (NCCN©), All rights reserved. NCCN Guidelines® and this illustration may not be reproduced in any form without the express written permission of NCCN.

PLEASE NOTE that use of this NCCN Content is governed by the End-User License Agreement, and you MAY NOT distribute this Content or use it with any artificial intelligence model or tool.
Printed by A. S. M. FAZLUL KARIM CHOWDHURY on 4/20/2026 3:38:59 AM. Copyright © 2026 National Comprehensive Cancer Network, Inc. All Rights Reserved.

anti-programmed cell death protein 1 (PD-1) inhibitor nivolumab, which resulted in significant clinical and radiologic responses in both children following several months of treatment.[109] A retrospective chart review of 11 pediatric patients with recurrent or refractory CNS tumors treated with ipilimumab/nivolumab, nivolumab, or pembrolizumab showed that immune checkpoint inhibitors are reasonably well tolerated in pediatric patients and warrant further study in clinical trials.[111]

H3 K27M-Mutant Tumor

H3 K27M is an initiating oncogenic event in diffuse intrinsic pontine gliomas (DIPGs) and presents throughout the course of disease development and progression. A phase II clinical study of dordaviprone was conducted in recurrent glioblastoma and included a surgical cohort of patients >18 years, showed meaningful intratumoral concentrations, and may potentially be active in this subset of patients.[112] An integrated analysis of five open-label studies in 4 pediatric (<18 years) and 46 adult (≥18 years) patients with recurrent, non-pontine, and non-spinal *H3* K27M-mutant DMG showed an ORR of 20% with a 24-month OS of 34.7%.[113] Since the study was primarily in adult patients and there are very limited efficacy data in the pediatric population, the Panel decided to include dordaviprone as an “other recommended” option for patients with *H3* K27-mutated tumors.

Palliative Systemic Therapy for Recurrent or Progressive Disease

Despite aggressive primary management, most patients with pediatric diffuse high-grade gliomas will experience recurrence or disease progression.[109] Patients with recurrent or progressive disease have a median OS of <6 months, and no effective therapies currently exist.[109] The use of systemic therapy for the management of recurrent or progressive disease depends on the extent of disease and the patient’s condition. Targeted therapy based on the molecular composition of the tumor is recommended for patients with good performance status. This includes but is not limited to the following: checkpoint blockade for high tumor mutational burden (TMB) or personal or family history of CMMRD; RAF and MEK inhibition for tumors with *BRAF* V600E mutation, TRK inhibitors for tumors with *NTRK* gene fusion, and ALK inhibitors for *ALK* rearrangement-positive tumors.

Patients with poor performance status may receive palliative chemotherapy with oral etoposide,[114] bevacizumab (or a U.S. Food and Drug Administration [FDA]-approved biosimilar),[115] or single-agent nitrosoureas (lomustine or carmustine).[60] In a phase II trial, 28 children with recurrent brain and solid tumors received daily oral etoposide for 21 consecutive days with courses repeating every 28 days pending bone marrow recovery.[114] Three out of the four patients with medulloblastoma exhibited a partial response and two of the five patients with ependymoma had a response (one with a complete response and one with a partial response), demonstrating activity for etoposide in recurrent brain tumors. Toxicity was manageable with only one hospitalization for neutropenic fever and two patients who withdrew due to treatment-related adverse events (one with grade 4 thrombocytopenia and one with grade 2 mucositis).

The multicenter phase II HERBY trial evaluated the addition of bevacizumab to RT plus temozolomide for treatment of pediatric patients (N = 121; aged between 3 and 18 years) with newly diagnosed non-pontine high-grade gliomas.[115] Median EFS did not differ significantly between the treatment groups and the addition of bevacizumab did not reduce the risk of death. Adding bevacizumab to RT + temozolomide did not improve EFS in pediatric patients with newly diagnosed high-grade gliomas. Therefore, the Panel has reserved use of bevacizumab (or an FDA-approved biosimilar) as a single agent in the palliative setting for patients with recurrent or progressive disease.

Version 1.2026 © 2025 National Comprehensive Cancer Network© (NCCN©), All rights reserved. NCCN Guidelines® and this illustration may not be reproduced in any form without the express written permission of NCCN.

PLEASE NOTE that use of this NCCN Content is governed by the End-User License Agreement, and you MAY NOT distribute this Content or use it with any artificial intelligence model or tool.
Printed by A. S. M. FAZLUL KARIM CHOWDHURY on 4/20/2026 3:38:59 AM. Copyright © 2026 National Comprehensive Cancer Network, Inc. All Rights Reserved.

Brief Summary of NCCN Recommendations for Diffuse High-Grade Gliomas

Radiologic Presentation and Multidisciplinary Review

When a patient presents with a clinical and radiologic picture suggestive of pediatric diffuse high-grade gliomas, input from a multidisciplinary team is needed for treatment planning. The involvement of pediatric oncologists/neuro-oncologists, pediatric radiation oncologists, pathologists with expertise in neuropathology and molecular pathology, pediatric neuroradiologists, and pediatric neurosurgeons with specific expertise in the management of pediatric high-grade gliomas is strongly encouraged. Neurosurgical input is needed to determine the feasibility of maximal safe resection. A pathologic diagnosis is critical and may be difficult to accurately determine without sufficient tumor tissue obtained during biopsy. Review of the tumor tissue by an experienced neuropathologist is highly recommended.

Primary Treatment and Pathologic Diagnosis

For primary treatment of pediatric diffuse high-grade gliomas, the NCCN Guidelines recommend maximal safe resection with the goal of image-verified complete resection, whenever possible. If the patient is symptomatic because of mass tumor effect but complete resection is not feasible, then STR is recommended for tissue diagnosis and debulking. A postoperative MRI is recommended, ideally within 24 to 48 hours after surgery, to confirm extent of resection.[22-25] If a clinically beneficial cytoreduction is not feasible, then a stereotactic biopsy or open biopsy is recommended for pathologic analysis. Recommendations for molecular testing of diffuse high-grade glioma tumors are provided in the algorithm. The resulting information should be used to form a pathologic diagnosis. Detection of genetic alterations may also expand clinical trial options for the patient.

Adjuvant Therapy

The NCCN Panel recommends clinical trial enrollment whenever possible as the preferred treatment option for all pediatric patients with diffuse high-grade gliomas. Outside of a clinical trial, patients ≥3 years with pediatric diffuse high-grade gliomas, except DMG, *H3* K27-altered or other tumor with a pontine tumor location, can receive standard brain RT with concurrent and adjuvant temozolomide without lomustine or with lomustine (preferred).[60,61] Standard brain RT alone and standard brain RT with concurrent temozolomide and adjuvant targeted therapy based upon the molecular composition of the tumor are also options in this setting. Patients <3 years can receive systemic chemotherapy with either cyclophosphamide, vincristine, cisplatin, and etoposide[86] or vincristine, carboplatin, and temozolomide [87] to delay the need for RT or with adjuvant targeted therapy based upon the molecular composition of the tumor.

Patients with non-pontine DMG, *H3* K27-altered can receive either standard brain RT alone or standard brain RT with concurrent and adjuvant temozolomide alone or with lomustine. Patients with pontine located tumors, including DMG, *H3* K27-altered or pediatric diffuse high-grade glioma, *H3* wild-type, and *IDH* wild-type, should receive standard brain RT alone if clinical trial enrollment is not possible.

Follow-up and Recurrence

Most pediatric patients with diffuse high-grade gliomas eventually develop tumor recurrence or progression. Therefore, patients should be followed closely with brain MRI scans starting at 2 to 6 weeks post-irradiation, then every 2 to 3 months for 1 year, then every 3 to 6 months indefinitely after the completion of treatment for newly diagnosed disease. Pseudo-progression may occur within 6 to 9 months after RT and can be seen on MRI; therefore, pseudo-progression should be considered if MRI changes are noted in this period. Management of recurrent or progressive disease depends on the extent of disease and the patient's condition. The efficacy

Version 1.2026 © 2025 National Comprehensive Cancer Network© (NCCN©), All rights reserved. NCCN Guidelines® and this illustration may not be reproduced in any form without the express written permission of NCCN.

PLEASE NOTE that use of this NCCN Content is governed by the End-User License Agreement, and you MAY NOT distribute this Content or use it with any artificial intelligence model or tool.
Printed by A. S. M. FAZLUL KARIM CHOWDHURY on 4/20/2026 3:38:59 AM. Copyright © 2026 National Comprehensive Cancer Network, Inc. All Rights Reserved.

of current treatment options remains poor; therefore, enrollment in a clinical trial, whenever possible, is preferred for the management of recurrent or progressive disease. Surgical resection of locally recurrent disease is reasonable followed by an additional brain MRI scan. However, enrollment in a phase 0 or preoperative clinical trial should be considered before resection. If recurrent or progressive local disease is not resectable or if it is diffuse with multiple lesions, then surgery can still be considered for large symptomatic lesions. Re-resection at the time of recurrence may improve outcomes; however, tumor involvement in specific critical brain areas and poor performance status may be associated with unfavorable re-resection outcomes. In cases of poor performance status or where aggressive therapy is unlikely to provide meaningful survival benefit, palliative and best supportive care including family-centered care with attention on quality of life is recommended.

Preferred systemic therapy options for recurrent disease include but are not limited to dabrafenib/trametinib[95] or vemurafenib[88] for *BRAF* V600E-mutated tumors, larotrectinib[103] or entrectinib[102] for *TRK* fusion-positive tumors, nivolumab[109,110] or pembrolizumab[111] for hypermutant tumors, and lorlatinib or alectinib for *ALK* rearrangement-positive tumors. Reirradiation, if feasible, is an alternative option. Patients with poor performance status should receive palliative/best supportive care. Recommended regimens for palliation are oral etoposide,[114] bevacizumab (or an FDA-approved biosimilar),[115] or nitrosoureas (lomustine or carmustine).[60]

Pediatric Medulloblastoma

Introduction

Epidemiology

Medulloblastoma is one of the most common types of brain tumors in children, accounting for about 10% to 20% of all brain tumors (0.47 per 100,000 for children 0–14 years).[116] The prognosis for medulloblastoma, predominantly found in the cerebellum, is worse for patients <3 years or those with metastatic disease, suboptimal resection, and certain molecular subtypes. However, with advances in multimodality therapies approximately 75% children with medulloblastoma will have prolonged survival.[117] Pediatric medulloblastoma consists of at least four distinct molecular subtypes, which includes wingless (WNT), sonic hedgehog (SHH), Group 3, and Group 4.[118] Group 3 and 4 have been combined and are collectively referred to as “Non-WNT/non-SHH” medulloblastoma. Incidence of the different molecular subtypes of medulloblastoma can vary with age and sex and are detailed in this section.[118,119] Current therapeutic regimens are highly effective for certain molecular groups of medulloblastoma leading to a high rate of cure in these subgroups. WNT-activated tumors represent 10% of medulloblastoma and are most common in children aged 7 to 14 years with a good prognosis (long-term survival rates >90%). The SHH-activated, *TP53* wild-type or -mutant tumors represent 10% to 20% of medulloblastomas, and *TP53* mutations and/or *MYCN* amplification in this subtype is associated with poor prognosis. The WHO classifies SHH-activated/*TP53* wild-type and SHH-activated/*TP53*-mutant tumors as separate subtypes. *TP53* mutation and *MYCN* amplification are associated with each other and with a very poor outcome worse than that of *TP53* mutation alone.[120] Finally, Group 3 and 4 tumors represent about 25% to 35% of medulloblastomas, respectively. Even though they are combined, Group 3 tumors have a less favorable prognosis (5-year survival rates between 20%–30%) compared to Group 4 tumors (OS rates between 75%–90%).

Risk Factors/Genetic Predisposition

The risk factors for pediatric medulloblastoma are not well-known. However, certain genetic conditions and germline mutations are associated with a higher risk of developing medulloblastoma at a young age. These include Li-Fraumeni syndrome that occurs due to germline *TP53* mutations and/or family history of certain cancers; Turcot

Version 1.2026 © 2025 National Comprehensive Cancer Network© (NCCN©), All rights reserved. NCCN Guidelines® and this illustration may not be reproduced in any form without the express written permission of NCCN.

PLEASE NOTE that use of this NCCN Content is governed by the End-User License Agreement, and you MAY NOT distribute this Content or use it with any artificial intelligence model or tool.
Printed by A. S. M. FAZLUL KARIM CHOWDHURY on 4/20/2026 3:38:59 AM. Copyright © 2026 National Comprehensive Cancer Network, Inc. All Rights Reserved.

syndrome/Lynch syndrome/CMMRD that presents with mutations in *hMSH2*, *hMSH6*, *hMLH1*, and *hPMS2*; and Gorlin syndrome (nevoid basal cell carcinoma syndrome [NBCCS]).[121] Germline mutations in *APC*, *BRCA2*, *PALB2*, *GPR161*, *ELP1*, *CREBBP*, and *EP300* can also predispose children to develop pediatric medulloblastoma.[122] The WNT and SHH subgroups have the highest occurrence of these mutations and syndromes, with a much lower frequency of genetic alterations in Group 3 and 4 tumors. Individuals who should be referred to evaluation of cancer predisposition include those whose tumors harbor genetic alterations or with a clinical history suggestive of predisposition to inherited cancer. The Panel notes that genetic-associated risk factors may be updated in the future with emerging data and new discoveries in this field.

Clinical Presentation

The symptoms, which can develop in weeks or gradually over months, can be intermittent and subtle at first. The most common symptoms include consequences of increased intracranial pressure, such as headache, nausea, and vomiting. Prolonged elevated intracranial pressure can lead to papilledema and changes in vision.[18] Other presenting symptoms include ataxia, cranial nerve deficits, loss of developmental milestones, and back pain.

Treatment Overview

Treatment for medulloblastoma includes surgery, RT, and chemotherapy. The goals of surgery include maximal safe resection, to reduce tumor-associated mass effect, to provide relief from hydrocephalus, and to obtain adequate tissue for histologic and molecular classification. The Panel encourages enrollment in molecular classification-based clinical trials, if available. Postoperative staging should include molecular findings along with clinical factors to ascertain risk for recurrence that informs adjuvant therapy options. Given the younger age of diagnosis, the Panel recommends referring patients to infertility risk/fertility preservation counseling, especially for those who are or will be treated with chemotherapy. The Panel also suggests referring to the NCCN Guidelines for Adolescent and Young Adult (AYA) Oncology (available at www.NCCN.org). The Panel notes that treatment for children <3 years is not covered in this guideline.

Principles of Neuroimaging

The current guideline recommendations incorporate imaging followed by molecular subtyping to determine risk for recurrence and adjuvant/maintenance therapy. The Panel includes imaging modalities, among other tests, as suggested follow-up/surveillance tools after adjuvant therapy to monitor response and disease status. The recommendations for imaging medulloblastomas mostly follow that of diffuse high-grade gliomas. However, keeping in mind the challenges associated with certain molecular subtypes, there are certain key differences regarding tumor appearance on imaging and/or acquisition of high-quality images that are listed below:

- Pediatric medulloblastoma usually appears as a large, heterogeneous, posterior fossa mass that occupies either the fourth ventricle or cerebellar hemisphere. The mass characteristically demonstrates reduced diffusion due to high cellularity, with most cases exhibiting heterogeneous cyst formation or necrosis, with varying degrees of enhancement.

- Medulloblastoma associated with leptomeningeal dissemination in the spine is more evident on an MRI.[123] The Panel recommends obtaining sagittal T2-weighted images, and postcontrast sagittal and axial T1-weighted images of the entire spine. Additional sequences such as high-resolution heavily T2-weighted images, 3D bSSFP sequence (CISS/FIESTA-C), and/or DWI may be helpful and, when feasible,

Version 1.2026 © 2025 National Comprehensive Cancer Network© (NCCN©), All rights reserved. NCCN Guidelines® and this illustration may not be reproduced in any form without the express written permission of NCCN.

PLEASE NOTE that use of this NCCN Content is governed by the End-User License Agreement, and you MAY NOT distribute this Content or use it with any artificial intelligence model or tool.
Printed by A. S. M. FAZLUL KARIM CHOWDHURY on 4/20/2026 3:38:59 AM. Copyright © 2026 National Comprehensive Cancer Network, Inc. All Rights Reserved.

should also be obtained.[124] Furthermore, the apparent diffusion coefficient (ADC) value calculation using DWI, among other imaging features, may aid in predicting molecular subtypes and optimizing planning related to surgery.[125,126]

- FDG-PET/CT can be a useful imaging tool in evaluating pediatric medulloblastoma. A case study involving serial MRIs in a 20-year-old after radiation and adjuvant chemotherapy showed no disease progression even though the patient had declining functional abilities.[127] A follow-up FDG-PET/CT evaluation showed increased uptake along the length of the thecal sac suggesting metastatic disease, which was confirmed by spine MRI imaging with gadolinium contrast. In another study of patients with medulloblastoma (N = 22), increased FDG uptake correlated negatively with survival.[128] These studies suggest the potential utility of FDG-PET/CT in evaluating metastatic disease and prognosis.

- Deep learning and artificial intelligence (AI) techniques using imaging scans to predict the molecular subtypes are currently being investigated. While acknowledging that such studies are in very early stages of development, the Panel notes that there is a possibility of improving medulloblastoma classification by merging data from textured images and the original histopathologic images. A retrospective study across 12 international pediatric sites (N = 263) applied machine learning to MRI scans and constructed algorithms to predict the four major molecular subtypes with some success.[129] Another study found an increased frequency of equivocal findings on MRI in the SHH subtype compared to any other molecular subgroup.[130] Based on these and other ongoing studies, the Panel notes that evaluations combining radiology and genomics could become more clinically relevant in the future.

Principles of Neuropathology

All types of medulloblastomas are embryonal tumors composed of small, poorly differentiated cells with high nuclear:cytoplasmic ratio, increased mitotic activity, and prominent apoptosis. All medulloblastomas are CNS WHO grade 4 and categorized by molecular group based on the 2021 CNS WHO Classification (5th edition).[7] Morphologic patterns remain a critical clinicopathologic tool that can correlate well with molecular subtypes and in some cases even predict molecular findings. However, some observed morphologic patterns (for example: large cell/anaplastic histology) are subjective and depend on the pathologist's expertise; therefore, molecular characterization is now the gold standard for medulloblastoma classification. IHC analysis can provide rapid screening for specific genetic alterations (eg, β-catenin, p53, *INI1*/*SMARCB1*). Altogether, the Panel deems integration of morphologic, IHC, and molecular data as necessary for diagnosing and treating pediatric medulloblastomas. In addition, the Panel recommends germline testing and genetic counseling in all diagnosed cases of medulloblastoma.

Molecular Characterization

The well-established molecular subtypes of medulloblastoma include WNT-activated, SHH-activated/*TP53* wild-type, SHH-activated/*TP53*-mutant, and combined Groups 3 and 4, and are characterized by specific genetic alterations.[118,122,131-133] WNT-activated tumors are distinguished by *CTNNB1* mutation in 90% of cases and usually result in a positive nuclear β-catenin IHC and chromosome 6 loss, whereas germline mutations like *CMMRD* and *APC* are rare in this subtype. IHC for β-catenin may particularly be helpful to demonstrate WNT pathway activation in patients within the low-risk group within WNT-activated medulloblastoma. In SHH-activated/*TP53* wild-type tumors, frequent mutations, including those in *PTCH1* (Gorlin syndrome), *SUFU*, *SMO*, *MLL1*, *MYCN*, *LDB1*, and *GLI1*, occur. In contrast, DNA methylation changes appear more commonly in SHH-activated/*TP53*-mutant tumors.

Version 1.2026 © 2025 National Comprehensive Cancer Network© (NCCN©), All rights reserved. NCCN Guidelines® and this illustration may not be reproduced in any form without the express written permission of NCCN.

PLEASE NOTE that use of this NCCN Content is governed by the End-User License Agreement, and you MAY NOT distribute this Content or use it with any artificial intelligence model or tool.
Printed by A. S. M. FAZLUL KARIM CHOWDHURY on 4/20/2026 3:38:59 AM. Copyright © 2026 National Comprehensive Cancer Network, Inc. All Rights Reserved.

Group 3 and 4 tumors are generally not associated with germline mutations but *MYC* amplification and isodicentric 17q alterations can be found in select cases. The Panel notes that although DNA methylation profiling is robust for medulloblastoma subtyping, the data are yet to fully mature and therefore are not currently included in these guidelines. The Panel recommends that when DNA methylation analysis is performed, these findings should be integrated with genetic profiling that includes germline testing.

After in-depth discussion, the Panel decided that considering molecular features in the context of clinical findings is the best approach to risk-stratify patients. Factors considered as risk for recurrence, based on current evidence and Panel consensus, are described in the algorithm pages (PMB-2 and PMB-3). The Panel agrees that metastatic disease, STR, or *MYC* amplification will automatically classify a patient into the high-risk group irrespective of the molecular subgroup. However, the prognosis of patients with high-risk features may vary with different molecular characteristics. Furthermore, discerning molecular features can be important for enrolling patients into appropriate clinical trials. For V.1.2025, the intermediate risk category for Groups 3 and 4 tumors was removed since the Panel felt that this risk category is an ongoing area of investigation and does not have enough compelling evidence to be put in current clinical practice. Classifying a patient into a certain risk category can depend on age; for example: a 4-year old's relative risk with M0, GTR, *MYC* gain, large cell/anaplastic histology may be viewed differently from a 10-year old's relative risk with the same features. These nuances should be kept in mind and clinical judgement should be used to treat these patients. Diagnosis of large cell/anaplastic histology is subjective, especially in cases of mixed histology, and varies across different institutions. While noting that large cell/anaplastic histology usually occurs with some other clinical/histologic/molecular features, the Panel determined that diagnosis of large cell/anaplastic histology alone is not considered as a risk factor for recurrence. Additionally, *MYC* gain is different from *MYC* amplification, but the distinguishing features between the two are not clearly defined. The Panel contends that more data are needed to integrate the subtle differences between gains and amplifications into risk stratification. Finally, the Panel emphasized that the molecular classification and associated risk stratification, particularly for pediatric medulloblastoma, is an evolving field and will be updated based on ongoing studies and available data.

Principles of Surgery

The principles of surgery for medulloblastoma are largely similar to high-grade gliomas. One of the primary goals during surgery is to maintain the fine balance between maximal cytoreduction and preserving quality of life of the patient. Additional considerations for surgical resection of medulloblastoma are listed below.

- Initial surgery should be performed with the goal of GTR while minimizing neurologic deficits incurred from surgery. Near total resection (NTR) (≤1.5 cm^2 residual) is acceptable in some settings. Less than NTR is also acceptable after review postoperatively by a multidisciplinary team. A retrospective study that included 787 patients found that extent of resection in only Group 4 tumors was associated with poor survival, with the authors acknowledging that the reason behind this correlation is not clear.[117] Other studies have shown that extent of residual tumor is correlated with PFS in kids with no disseminated disease.[134,135]

- Medulloblastoma usually appears as a posterior fossa mass, but the nature of the mass may vary depending on the subtype. For example, the WNT medulloblastoma subtype is known to display intratumoral hemorrhage more frequently than the other molecular subtype.[136]

Version 1.2026 © 2025 National Comprehensive Cancer Network© (NCCN©), All rights reserved. NCCN Guidelines® and this illustration may not be reproduced in any form without the express written permission of NCCN.

PLEASE NOTE that use of this NCCN Content is governed by the End-User License Agreement, and you MAY NOT distribute this Content or use it with any artificial intelligence model or tool.
Printed by A. S. M. FAZLUL KARIM CHOWDHURY on 4/20/2026 3:38:59 AM. Copyright © 2026 National Comprehensive Cancer Network, Inc. All Rights Reserved.

- The Panel recommends obtaining adequate tissue for histopathologic diagnosis and molecular genetic characterization. Molecular findings after surgery are important for further risk stratification.

- For patients with resectable residual disease, the Panel contends considering if a second-look surgery is acceptable. Careful re-inspection of the area of resected tumor can reveal residual disease.[137] Re-resection at the time of recurrence may confer OS benefit in the setting of a single, focal posterior fossa recurrence.

- Any medulloblastoma that recurs after 3 to 5 years could be a second malignancy. Therefore, the Panel emphasizes the need to re-biopsy the tumor to distinguish between medulloblastoma and diffuse high-grade gliomas. Biopsy of recurrent disease may also identify actionable molecular findings, or rarely, a secondary malignancy.

- The Panel notes that CSF diversion techniques including ventriculoperitoneal shunt or endoscopic third ventriculostomy are acceptable.

Principles of Radiation Therapy Management

Radiation is an essential component of adjuvant therapy for all risk categories of medulloblastoma and improves survival for at least 20% of patients. Craniospinal irradiation (CSI) for primary disease is critical, regardless of molecular subtype, to achieve potential cure of medulloblastomas.[138,139] For high-risk subgroups, an elevated CSI dose is recommended whereas a lower dose is recommended for low-risk subgroups. Using a lower dose of radiation, thought to have the same therapeutic efficacy, while retaining neurocognitive outcomes has not shown benefit when the molecular subtypes are analyzed as one group.[140] It is yet to be determined whether lower doses can be still be effective for certain molecular subtypes of medulloblastoma (eg, WNT); this is a topic of investigation in some clinical trials, including NCT02724579 and NCT01878617. In the recurrent setting, reirradiation is primarily based on clinical judgment, and a higher dose can be used especially if the patient did not receive any radiation (an unusual scenario) as part of adjuvant treatment.

Certain chemotherapy agents are thought to act as radiosensitizers. In a randomized phase 3 trial, treatment with carboplatin during radiation improved EFS by 19% only in children with high-risk Group 3 medulloblastoma.[141] The authors did observe higher toxicities in patients who received carboplatin during RT, which were attributed to an intense treatment schedule. Nevertheless, this study emphasizes the importance of molecular stratification, which can provide information about which patient subgroup is most likely to benefit from certain treatments. Based on the study, the Panel recommends carboplatin prior to each RT fraction only for Group 3 tumors with very high risk of recurrence (*MYC* amplification).

A cohort study of patients with medulloblastoma showed that proton radiotherapy may be associated with more favorable intellectual outcomes, measured by global intelligence quotient (IQ), perceptual reasoning, and working memory scores, compared to photon radiotherapy.[142] The authors noted that modern photon radiotherapy techniques can result in intellectual benefits; however, they still favored proton radiotherapy. Photon radiotherapy is also associated with side effects.[143-145] The Panel notes that it is important to remain vigilant regarding potential radiotherapy-related morbidities, such as brainstem injury, as date matures for the modern techniques. Regardless of the type of therapy used, the Panel emphasizes the need for utilizing optimal normal tissue-sparing techniques during radiotherapy planning and administration.

Version 1.2026 © 2025 National Comprehensive Cancer Network© (NCCN©), All rights reserved. NCCN Guidelines® and this illustration may not be reproduced in any form without the express written permission of NCCN.

PLEASE NOTE that use of this NCCN Content is governed by the End-User License Agreement, and you MAY NOT distribute this Content or use it with any artificial intelligence model or tool.
Printed by A. S. M. FAZLUL KARIM CHOWDHURY on 4/20/2026 3:38:59 AM. Copyright © 2026 National Comprehensive Cancer Network, Inc. All Rights Reserved.

There is some concern about secondary malignancies due to RT; however, the Panel feels that such risk can be largely attributed to germline mutations, including *TP53*, that predispose individuals to certain cancers. Finally, the Panel encourages clinical trial enrollment; if a patient is enrolled in a clinical trial, the protocol recommendations and normal tissue dose constraints of the trial should be met.

Principles of Systemic Therapy

Adjuvant Chemoradiation Followed by Maintenance Chemotherapy

The therapy for all risk categories consists of chemoradiation followed by maintenance chemotherapy. The maintenance treatment schedule from the Children's Oncology Group (COG) or St. Jude protocol can be utilized. However, these protocols are not interchangeable. Toxicity should be monitored during treatment, including neuropathy associated with vincristine and ototoxicity associated with cisplatin. The Panel recommends slightly different chemoradiation regimens for low-/average-risk and high-/very-high-risk categories.

Low and Average Risk

A randomized phase III trial (N = 464 eligible and evaluable patients) conducted by the COG studied weekly vincristine with radiotherapy; after 6 weeks patients received maintenance chemotherapy that cycled between cisplatin/lomustine/vincristine and cisplatin/cyclophosphamide/vincristine.[140] All the molecular subtypes of medulloblastoma were represented in this study with Group 4 tumors comprising the largest subgroup. In all patients, outcomes including EFS and OS were comparable between posterior fossa and involved-field RT. However, the study showed that using low-dose CSI may not be as efficient as using standard-dose CSI. Another study conducted by investigators at St. Jude (N = 330) utilized a similar dosing strategy for CSI and primary chemotherapy, while maintenance consisted of vincristine/cisplatin/cyclophosphamide.[146] Group 4 tumors were the largest proportion of subtypes among the molecular subtypes in this study. In general, the outcomes of this trial were comparable to previously performed prospective studies. Based on these two studies, the Panel recommends weekly vincristine with RT (COG) that can be followed by maintenance therapy from either the COG or St. Jude trial as options for low-/average-risk disease.

High and Very High Risk

Studies have investigated potential radiosensitizing effects of carboplatin.[141,147] The addition of carboplatin during radiotherapy improved clinical outcomes in high-risk Group 3 tumors. Therefore, the Panel recommends carboplatin prior to each RT fraction for Group 3 tumors with very high risk for recurrence (*MYC* amplification). The Panel recommends using the St. Jude trial protocol or the ACNS0332 protocol (consisting of 6 cycles of chemotherapy including cisplatin, cyclophosphamide, and vincristine) as maintenance options for high- and very-high-risk disease.

Recurrent or Progressive Disease

Recurrent or progressive disease after first-line therapy is observed in approximately one-third of the patients and is associated with significantly lower survival rates of <10%. Given the low survival rates, recurrent/progressive medulloblastoma is thought of as high-risk disease. Therefore, a combination of systemic therapies based on existing data, described below, are options for aggressively treating recurrence/progressive disease. The Panel also encourages patients with recurrent or progressive disease to participate in clinical trials.

Temozolomide and Irinotecan + Bevacizumab (TEMR)

The addition of bevacizumab to temozolomide and irinotecan demonstrated a 3-month benefit to EFS (6 months without bevacizumab vs. 9 months with bevacizumab) in a phase II screening trial of patients

Version 1.2026 © 2025 National Comprehensive Cancer Network© (NCCN©), All rights reserved. NCCN Guidelines® and this illustration may not be reproduced in any form without the express written permission of NCCN.

PLEASE NOTE that use of this NCCN Content is governed by the End-User License Agreement, and you MAY NOT distribute this Content or use it with any artificial intelligence model or tool.
Printed by A. S. M. FAZLUL KARIM CHOWDHURY on 4/20/2026 3:38:59 AM. Copyright © 2026 National Comprehensive Cancer Network, Inc. All Rights Reserved.

with recurrent medulloblastoma or CNS primitive neuroectodermal tumor (PNET).[148] Both arms had similar toxicity profiles. Therefore, this regimen is included as an option to treat recurrent or progressive disease. The Panel notes that bevacizumab initiation can be delayed to ensure appropriate wound healing in patients who recently had surgery.

Temozolomide/Topotecan (TOTEM)

In a phase 2 basket trial, treatment with temozolomide/topotecan led to a 28% ORR in a small cohort of pediatric patients with recurrent/refractory medulloblastoma.[149] Hematologic toxicities were frequently observed in patients treated with temozolomide/topotecan.

MEMMAT Regimen

Metronomic antiangiogenic therapies are low doses of anticancer drugs that are administered on a regular basis over long periods of time.[150] Two potential advantages of such low-dose regimens include lowering side effects and readministering drugs previously given at high doses to circumvent tumor resistance.[150] A few phase II trials and a retrospective analysis showed the benefit of MEMMAT or “MEMMAT-like” regimens in treating pediatric medulloblastoma.[151,152] Phase II trials in pediatric patients with recurrent or progressive CNS tumors evaluated disease progression after treatment with these regimens for up to 7 months.[153,154] These trials showed acceptable toxicity profiles and promising clinical activity in a subset of patients.

Carboplatin/Etoposide

A phase II window-of-opportunity trial that included patients with recurrent medulloblastoma (n = 93) investigated the efficacy of three arms (non-randomized): carboplatin/etoposide, oral chemotherapy with temozolomide, and a documentation arm that included patients not treated with the two regimens.[155] Patients on the carboplatin/etoposide arm had better ORRs compared to those who received temozolomide (51.8% vs. 18.2%). The authors noted that both hematologic and non-hematologic toxicities were observed but were manageable. The clinical outcomes of this trial were comparable to trials that investigated TOTEM or temozolomide/irinotecan/bevacizumab.

Brief Summary of NCCN Recommendations for Medulloblastoma

Radiologic Presentation and Multidisciplinary Review

A contrast-enhanced MRI compatible with primary brain tumor is the preferred method to perform radiologic evaluation of medulloblastoma. The Panel recommends that multidisciplinary review be conducted once pathology reports are evaluated, and this should be performed before surgery.

Primary Treatment

The primary treatment consists of surgery followed by adjuvant therapy. The goals of surgery include GTR; if that is not possible then maximal safe resection is an option. The Panel strongly recommends referring the patient to a pediatric brain tumor center for evaluation of possible more complete surgical resection when open biopsy or STR are being considered. STR may be warranted only if the patient has gross leptomeningeal disease and no detectable primary site. Postoperative staging includes brain/spine MRI, CSF, and molecular analysis. Postoperative imaging is required for the brain only and is ideally obtained within the first 24–72 hours (within 24 hours preferred). If spine MRI is not performed prior to surgery, imaging should wait 10 to 14 days postoperatively to get an accurate image. The Panel notes that rapid-sequence MRI is not a substitute for a full brain and spine MRI when staging or assessing for response evaluation. Timely molecular testing of medulloblastoma is recommended, which informs risk stratification before adjuvant treatment.

Version 1.2026 © 2025 National Comprehensive Cancer Network© (NCCN©), All rights reserved. NCCN Guidelines® and this illustration may not be reproduced in any form without the express written permission of NCCN.

PLEASE NOTE that use of this NCCN Content is governed by the End-User License Agreement, and you MAY NOT distribute this Content or use it with any artificial intelligence model or tool.
Printed by A. S. M. FAZLUL KARIM CHOWDHURY on 4/20/2026 3:38:59 AM. Copyright © 2026 National Comprehensive Cancer Network, Inc. All Rights Reserved.

Adjuvant Therapy

Adjuvant treatment consists of chemoradiation followed by maintenance chemotherapy. CSI and chemotherapy recommendations differ for low-/average-risk and high-/very-high-risk disease.

Follow-up and Recurrence

The algorithm lists details of suggested follow-up tests and surveillance methods. This includes endocrine tests at least annually for 5 years to ensure institutions and doctors can best follow up with patients on an individualized basis. If thyroid-stimulating hormone (TSH) or growth failure is suspected, endocrine tests can be performed more frequently. The oncologist may also refer to an endocrinologist if any of the endocrine test results raise suspicion. Recurrent/progressive disease can be treated with combined chemotherapy regimens. The Panel encourages enrollment in clinical trials. Palliative/supportive care that includes radiation and additional resection are also included as options for recurrent/progressive disease.

Summary

Pediatric CNS cancers are the leading cause of cancer-related death in children. Referral for cancer predisposition evaluation and/or genetic counseling should be considered for patients with pediatric diffuse high-grade gliomas/medulloblastoma linked to certain inherited cancer predisposition syndromes. All patients should be cared for by a multidisciplinary team with experience managing pediatric CNS tumors. Advances in molecular profiling have expanded the use of targeted therapies in patients whose tumors harbor certain alterations in diffuse high-grade gliomas. However, nearly all patients will experience recurrent disease, which has limited treatment options. For medulloblastomas, the Panel notes that molecular subgrouping is an evolving field that will perhaps affect the clinical management of this disease. Subsequent versions of the Guidelines will address additional tumor types.

Version 1.2026 © 2025 National Comprehensive Cancer Network© (NCCN©), All rights reserved. NCCN Guidelines® and this illustration may not be reproduced in any form without the express written permission of NCCN.

PLEASE NOTE that use of this NCCN Content is governed by the End-User License Agreement, and you MAY NOT distribute this Content or use it with any artificial intelligence model or tool.
Printed by A. S. M. FAZLUL KARIM CHOWDHURY on 4/20/2026 3:38:59 AM. Copyright © 2026 National Comprehensive Cancer Network, Inc. All Rights Reserved.

References

1. American Cancer Society. Key statistics for brain and spinal cord tumors in children. 2022. Available at: https://www.cancer.org/cancer/brain-spinal-cord-tumors-children/about/key-statistics.html. Accessed April 26, 2022.

2. American Cancer Society. Cancer facts and figures 2022. Available at: https://www.cancer.org/latest-news/facts-and-figures-2022.html. Accessed April 26, 2022.

3. Price M, Ballard CAP, Benedetti JR, et al. CBTRUS Statistical Report: Pediatric Brain Tumor Foundation Childhood and Adolescent Primary Brain and Other Central Nervous System Tumors Diagnosed in the United States in 2017-2021. Neuro Oncol 2025;27:i1–i42. Available at: https://www.ncbi.nlm.nih.gov/pubmed/40971774.

4. Ostrom QT, Price M, Ryan K, et al. CBTRUS statistical report: Pediatric brain tumor foundation childhood and adolescent primary brain and other central nervous system tumors diagnosed in the united states in 2014-2018. Neuro Oncol 2022;24:iii1–iii38. Available at: https://www.ncbi.nlm.nih.gov/pubmed/36066969.

5. Pubmed overview. Available at: https://pubmed.ncbi.nlm.nih.gov/about/. Accessed June 18, 2024.

6. Freedman-Cass DA, Fischer T, Alpert AB, et al. The value and process of inclusion: Using sensitive, respectful, and inclusive language and images in NCCN Content. J Natl Compr Canc Netw 2023;21:434–441. Available at: https://www.ncbi.nlm.nih.gov/pubmed/37156485.

7. Louis DN, Perry A, Wesseling P, et al. The 2021 WHO classification of tumors of the central nervous system: A summary. Neuro Oncol 2021;23:1231–1251. Available at: https://www.ncbi.nlm.nih.gov/pubmed/34185076.

8. Pfister SM, Reyes-Mugica M, Chan JKC, et al. A summary of the inaugural WHO classification of pediatric tumors: transitioning from the optical into the molecular era. Cancer Discov 2022;12:331–355. Available at: https://www.ncbi.nlm.nih.gov/pubmed/34921008.

9. Coleman C, Stoller S, Grotzer M, et al. Pediatric hemispheric high-grade glioma: targeting the future. Cancer Metastasis Rev 2020;39:245–260. Available at: https://www.ncbi.nlm.nih.gov/pubmed/31989507.

10. Subramanian S, Ahmad T. Childhood brain tumors. StatPearls. Treasure Island (FL); 2024.

11. Ostrom QT, Patil N, Cioffi G, et al. CBTRUS statistical report: Primary brain and other central nervous system tumors diagnosed in the united states in 2013-2017. Neuro Oncol 2020;22:iv1–iv96. Available at: https://www.ncbi.nlm.nih.gov/pubmed/33123732.

12. Johnson KJ, Cullen J, Barnholtz-Sloan JS, et al. Childhood brain tumor epidemiology: a brain tumor epidemiology consortium review. Cancer Epidemiol Biomarkers Prev 2014;23:2716–2736. Available at: https://www.ncbi.nlm.nih.gov/pubmed/25192704.

13. Hottinger AF, Khakoo Y. Neurooncology of familial cancer syndromes. J Child Neurol 2009;24:1526–1535. Available at: https://www.ncbi.nlm.nih.gov/pubmed/19955345.

14. Stefanaki K, Alexiou GA, Stefanaki C, Prodromou N. Tumors of central and peripheral nervous system associated with inherited genetic syndromes. Pediatr Neurosurg 2012;48:271–285. Available at: https://www.ncbi.nlm.nih.gov/pubmed/23796843.

15. Das A, MacFarland SP, Meade J, et al. Clinical updates and surveillance recommendations for DNA replication repair deficiency syndromes in children and young adults. Clin Cancer Res 2024;30:3378–3387. Available at: https://www.ncbi.nlm.nih.gov/pubmed/38860976.

16. Braganza MZ, Kitahara CM, Berrington de Gonzalez A, et al. Ionizing radiation and the risk of brain and central nervous system tumors: a systematic review. Neuro Oncol 2012;14:1316–1324. Available at: https://www.ncbi.nlm.nih.gov/pubmed/22952197.

Version 1.2026 © 2025 National Comprehensive Cancer Network© (NCCN©), All rights reserved. NCCN Guidelines® and this illustration may not be reproduced in any form without the express written permission of NCCN.

PLEASE NOTE that use of this NCCN Content is governed by the End-User License Agreement, and you MAY NOT distribute this Content or use it with any artificial intelligence model or tool.
Printed by A. S. M. FAZLUL KARIM CHOWDHURY on 4/20/2026 3:38:59 AM. Copyright © 2026 National Comprehensive Cancer Network, Inc. All Rights Reserved.

17. Ostrom QT, Adel Fahmideh M, Cote DJ, et al. Risk factors for childhood and adult primary brain tumors. Neuro Oncol 2019;21:1357–1375. Available at: https://www.ncbi.nlm.nih.gov/pubmed/31301133.

18. Udaka YT, Packer RJ. Pediatric brain tumors. Neurol Clin 2018;36:533–556. Available at: https://www.ncbi.nlm.nih.gov/pubmed/30072070.

19. Vern-Gross TZ, Schreiber JE, Broniscer A, et al. Prospective evaluation of local control and late effects of conformal radiation therapy in children, adolescents, and young adults with high-grade glioma. Neuro Oncol 2014;16:1652–1660. Available at: https://www.ncbi.nlm.nih.gov/pubmed/24908655.

20. Pollack IF, Agnihotri S, Broniscer A. Childhood brain tumors: current management, biological insights, and future directions. J Neurosurg Pediatr 2019;23:261–273. Available at: https://www.ncbi.nlm.nih.gov/pubmed/30835699.

21. Goncalves FG, Viaene AN, Vossough A. Advanced magnetic resonance imaging in pediatric glioblastomas. Front Neurol 2021;12:733323. Available at: https://www.ncbi.nlm.nih.gov/pubmed/34858308.

22. Erker C, Tamrazi B, Poussaint TY, et al. Response assessment in paediatric high-grade glioma: Recommendations from the response assessment in pediatric neuro-oncology (RAPNO) working group. Lancet Oncol 2020;21:e317–e329. Available at: https://www.ncbi.nlm.nih.gov/pubmed/32502458.

23. Cooney TM, Cohen KJ, Guimaraes CV, et al. Response assessment in diffuse intrinsic pontine glioma: recommendations from the Response Assessment in Pediatric Neuro-Oncology (RAPNO) working group. Lancet Oncol 2020;21:e330–e336. Available at: https://www.ncbi.nlm.nih.gov/pubmed/32502459.

24. Jaspan T, Morgan PS, Warmuth-Metz M, et al. Response assessment in pediatric neuro-oncology: Implementation and expansion of the RANO criteria in a randomized phase II trial of pediatric patients with newly diagnosed high-grade gliomas. AJNR Am J Neuroradiol 2016;37:1581–1587. Available at: https://www.ncbi.nlm.nih.gov/pubmed/27127006.

25. Ellingson BM, Bendszus M, Boxerman J, et al. Consensus recommendations for a standardized brain tumor imaging protocol in clinical trials. Neuro Oncol 2015;17:1188–1198. Available at: https://www.ncbi.nlm.nih.gov/pubmed/26250565.

26. Barajas RF, Jr., Chang JS, Segal MR, et al. Differentiation of recurrent glioblastoma multiforme from radiation necrosis after external beam radiation therapy with dynamic susceptibility-weighted contrast-enhanced perfusion MR imaging. Radiology 2009;253:486–496. Available at: https://www.ncbi.nlm.nih.gov/pubmed/19789240.

27. Wan B, Wang S, Tu M, et al. The diagnostic performance of perfusion MRI for differentiating glioma recurrence from pseudoprogression: A meta-analysis. Medicine (Baltimore) 2017;96:e6333. Available at: https://www.ncbi.nlm.nih.gov/pubmed/28296759.

28. van Dijken BRJ, van Laar PJ, Holtman GA, van der Hoorn A. Diagnostic accuracy of magnetic resonance imaging techniques for treatment response evaluation in patients with high-grade glioma, a systematic review and meta-analysis. Eur Radiol 2017;27:4129–4144. Available at: https://www.ncbi.nlm.nih.gov/pubmed/28332014.

29. Dallery F, Bouzerar R, Michel D, et al. Perfusion magnetic resonance imaging in pediatric brain tumors. Neuroradiology 2017;59:1143–1153. Available at: https://www.ncbi.nlm.nih.gov/pubmed/28861622.

30. Vajapeyam S, Stamoulis C, Ricci K, et al. Automated processing of dynamic contrast-enhanced MRI: Correlation of advanced pharmacokinetic metrics with tumor grade in pediatric brain tumors. AJNR Am J Neuroradiol 2017;38:170–175. Available at: https://www.ncbi.nlm.nih.gov/pubmed/27633807.

31. Miyazaki K, Jerome NP, Collins DJ, et al. Demonstration of the reproducibility of free-breathing diffusion-weighted MRI and dynamic contrast enhanced MRI in children with solid tumours: a pilot study. Eur

Version 1.2026 © 2025 National Comprehensive Cancer Network© (NCCN©), All rights reserved. NCCN Guidelines® and this illustration may not be reproduced in any form without the express written permission of NCCN.

PLEASE NOTE that use of this NCCN Content is governed by the End-User License Agreement, and you MAY NOT distribute this Content or use it with any artificial intelligence model or tool.
Printed by A. S. M. FAZLUL KARIM CHOWDHURY on 4/20/2026 3:38:59 AM. Copyright © 2026 National Comprehensive Cancer Network, Inc. All Rights Reserved.

Radiol 2015;25:2641–2650. Available at: https://www.ncbi.nlm.nih.gov/pubmed/25773937.

32. Heye AK, Culling RD, Valdes Hernandez Mdel C, et al. Assessment of blood-brain barrier disruption using dynamic contrast-enhanced MRI. A systematic review. Neuroimage Clin 2014;6:262–274. Available at: https://www.ncbi.nlm.nih.gov/pubmed/25379439.

33. Anzalone N, Castellano A, Cadioli M, et al. Brain gliomas: Multicenter standardized assessment of dynamic contrast-enhanced and dynamic susceptibility contrast MR images. Radiology 2018;287:933–943. Available at: https://www.ncbi.nlm.nih.gov/pubmed/29361245.

34. Dangouloff-Ros V, Deroulers C, Foissac F, et al. Arterial spin labeling to predict brain tumor grading in children: Correlations between histopathologic vascular density and perfusion MR imaging. Radiology 2016;281:553–566. Available at: https://www.ncbi.nlm.nih.gov/pubmed/27257950.

35. Hales PW, d'Arco F, Cooper J, et al. Arterial spin labelling and diffusion-weighted imaging in paediatric brain tumours. Neuroimage Clin 2019;22:101696. Available at: https://www.ncbi.nlm.nih.gov/pubmed/30735859.

36. Yeom KW, Mitchell LA, Lober RM, et al. Arterial spin-labeled perfusion of pediatric brain tumors. AJNR Am J Neuroradiol 2014;35:395–401. Available at: https://www.ncbi.nlm.nih.gov/pubmed/23907239.

37. Deibler AR, Pollock JM, Kraft RA, et al. Arterial spin-labeling in routine clinical practice, part 1: Technique and artifacts. AJNR Am J Neuroradiol 2008;29:1228–1234. Available at: https://www.ncbi.nlm.nih.gov/pubmed/18372417.

38. Gupta PK, Saini J, Sahoo P, et al. Role of dynamic contrast-enhanced perfusion magnetic resonance imaging in grading of pediatric brain tumors on 3T. Pediatr Neurosurg 2017;52:298–305. Available at: https://www.ncbi.nlm.nih.gov/pubmed/28848203.

39. Zhang H, Ma L, Wang Q, et al. Role of magnetic resonance spectroscopy for the differentiation of recurrent glioma from radiation necrosis: a systematic review and meta-analysis. Eur J Radiol 2014;83:2181–2189. Available at: https://www.ncbi.nlm.nih.gov/pubmed/25452098.

40. American Cancer Society. Tests for brain and spinal cord tumors in children. 2022. Available at: https://www.cancer.org/cancer/brain-spinal-cord-tumors-children/detection-diagnosis-staging/how-diagnosed.html. Accessed July 25, 2022.

41. Ryall S, Zapotocky M, Fukuoka K, et al. Integrated molecular and clinical analysis of 1,000 pediatric low-grade gliomas. Cancer Cell 2020;37:569–583 e565. Available at: https://www.ncbi.nlm.nih.gov/pubmed/32289278.

42. Clarke M, Mackay A, Ismer B, et al. Infant high-grade gliomas comprise multiple subgroups characterized by novel targetable gene fusions and favorable outcomes. Cancer Discov 2020;10:942–963. Available at: https://www.ncbi.nlm.nih.gov/pubmed/32238360.

43. Guerreiro Stucklin AS, Ryall S, Fukuoka K, et al. Alterations in ALK/ROS1/NTRK/MET drive a group of infantile hemispheric gliomas. Nat Commun 2019;10:4343. Available at: https://www.ncbi.nlm.nih.gov/pubmed/31554817.

44. Johnson A, Severson E, Gay L, et al. Comprehensive genomic profiling of 282 pediatric low- and high-grade gliomas reveals genomic drivers, tumor mutational burden, and hypermutation signatures. Oncologist 2017;22:1478–1490. Available at: https://www.ncbi.nlm.nih.gov/pubmed/28912153.

45. Ellison DW, Hawkins C, Jones DTW, et al. cIMPACT-NOW update 4: diffuse gliomas characterized by MYB, MYBL1, or FGFR1 alterations or BRAF(V600E) mutation. Acta Neuropathol 2019;137:683–687. Available at: https://www.ncbi.nlm.nih.gov/pubmed/30848347.

46. Louis DN, Wesseling P, Aldape K, et al. cIMPACT-NOW update 6: new entity and diagnostic principle recommendations of the cIMPACT-

Version 1.2026 © 2025 National Comprehensive Cancer Network© (NCCN©), All rights reserved. NCCN Guidelines® and this illustration may not be reproduced in any form without the express written permission of NCCN.

PLEASE NOTE that use of this NCCN Content is governed by the End-User License Agreement, and you MAY NOT distribute this Content or use it with any artificial intelligence model or tool.
Printed by A. S. M. FAZLUL KARIM CHOWDHURY on 4/20/2026 3:38:59 AM. Copyright © 2026 National Comprehensive Cancer Network, Inc. All Rights Reserved.

Utrecht meeting on future CNS tumor classification and grading. Brain Pathol 2020;30:844–856. Available at: https://www.ncbi.nlm.nih.gov/pubmed/32307792.

47. Zhang J, Walsh MF, Wu G, et al. Germline mutations in predisposition genes in pediatric cancer. N Engl J Med 2015;373:2336–2346. Available at: https://www.ncbi.nlm.nih.gov/pubmed/26580448.

48. Akhavanfard S, Padmanabhan R, Yehia L, et al. Comprehensive germline genomic profiles of children, adolescents and young adults with solid tumors. Nat Commun 2020;11:2206. Available at: https://www.ncbi.nlm.nih.gov/pubmed/32371905.

49. Balogun JA, Rutka JT. Surgery of intracranial gliomas in children. Prog Neurol Surg 2018;30:204–217. Available at: https://www.ncbi.nlm.nih.gov/pubmed/29241176.

50. Pollack IF, Boyett JM, Yates AJ, et al. The influence of central review on outcome associations in childhood malignant gliomas: results from the CCG-945 experience. Neuro Oncol 2003;5:197–207. Available at: https://www.ncbi.nlm.nih.gov/pubmed/12816726.

51. Finlay JL, Boyett JM, Yates AJ, et al. Randomized phase III trial in childhood high-grade astrocytoma comparing vincristine, lomustine, and prednisone with the eight-drugs-in-1-day regimen. Childrens cancer group. J Clin Oncol 1995;13:112–123. Available at: https://www.ncbi.nlm.nih.gov/pubmed/7799011.

52. Silva da Costa MD, Camargo NC, Dastoli PA, et al. High-grade gliomas in children and adolescents: is there a role for reoperation? J Neurosurg Pediatr 2021;27:160–169. Available at: https://www.ncbi.nlm.nih.gov/pubmed/33307529.

53. McCrea HJ, Bander ED, Venn RA, et al. Sex, age, anatomic location, and extent of resection influence outcomes in children with high-grade glioma. Neurosurgery 2015;77:443–452; discussion 452–443. Available at: https://www.ncbi.nlm.nih.gov/pubmed/26083157.

54. Napieralska A, Krzywon A, Mizia-Malarz A, et al. High-grade gliomas in children-a multi-institutional polish study. Cancers (Basel) 2021;13. Available at: https://www.ncbi.nlm.nih.gov/pubmed/33923337.

55. Wolff JE, Driever PH, Erdlenbruch B, et al. Intensive chemotherapy improves survival in pediatric high-grade glioma after gross total resection: results of the HIT-GBM-C protocol. Cancer 2010;116:705–712. Available at: https://www.ncbi.nlm.nih.gov/pubmed/19957326.

56. Kramm CM, Wagner S, Van Gool S, et al. Improved survival after gross total resection of malignant gliomas in pediatric patients from the HIT-GBM studies. Anticancer Res 2006;26:3773–3779. Available at: https://www.ncbi.nlm.nih.gov/pubmed/17094400.

57. Hatoum R, Chen JS, Lavergne P, et al. Extent of tumor resection and survival in pediatric patients with high-grade gliomas: A systematic review and meta-analysis. JAMA Netw Open 2022;5:e2226551. Available at: https://www.ncbi.nlm.nih.gov/pubmed/35972743.

58. Birk HS, Han SJ, Butowski NA. Treatment options for recurrent high-grade gliomas. CNS Oncol 2017;6:61–70. Available at: https://www.ncbi.nlm.nih.gov/pubmed/28001091.

59. Greenhalgh J, Weston J, Dundar Y, et al. Antiepileptic drugs as prophylaxis for postcraniotomy seizures. Cochrane Database Syst Rev 2020;4:CD007286. Available at: https://www.ncbi.nlm.nih.gov/pubmed/32343399.

60. Jakacki RI, Cohen KJ, Buxton A, et al. Phase 2 study of concurrent radiotherapy and temozolomide followed by temozolomide and lomustine in the treatment of children with high-grade glioma: A report of the children's oncology group ACNS0423 study. Neuro Oncol 2016;18:1442–1450. Available at: https://www.ncbi.nlm.nih.gov/pubmed/27006176.

61. Cohen KJ, Pollack IF, Zhou T, et al. Temozolomide in the treatment of high-grade gliomas in children: a report from the children's oncology group. Neuro Oncol 2011;13:317–323. Available at: https://www.ncbi.nlm.nih.gov/pubmed/21339192.

Version 1.2026 © 2025 National Comprehensive Cancer Network© (NCCN©), All rights reserved. NCCN Guidelines® and this illustration may not be reproduced in any form without the express written permission of NCCN.

PLEASE NOTE that use of this NCCN Content is governed by the End-User License Agreement, and you MAY NOT distribute this Content or use it with any artificial intelligence model or tool.
Printed by A. S. M. FAZLUL KARIM CHOWDHURY on 4/20/2026 3:38:59 AM. Copyright © 2026 National Comprehensive Cancer Network, Inc. All Rights Reserved.

62. Chambrelant I, Eber J, Antoni D, et al. Proton therapy and gliomas: A systematic review. Radiation 2021;1:218–233. Available at: https://www.mdpi.com/2673-592X/1/3/19.

63. Mizumoto M, Oshiro Y, Yamamoto T, et al. Proton beam therapy for pediatric brain tumor. Neurol Med Chir (Tokyo) 2017;57:343–355. Available at: https://www.ncbi.nlm.nih.gov/pubmed/28603224.

64. Hug EB, Muenter MW, Archambeau JO, et al. Conformal proton radiation therapy for pediatric low-grade astrocytomas. Strahlenther Onkol 2002;178:10–17. Available at: https://www.ncbi.nlm.nih.gov/pubmed/11977386.

65. Greenberger BA, Pulsifer MB, Ebb DH, et al. Clinical outcomes and late endocrine, neurocognitive, and visual profiles of proton radiation for pediatric low-grade gliomas. Int J Radiat Oncol Biol Phys 2014;89:1060–1068. Available at: https://www.ncbi.nlm.nih.gov/pubmed/25035209.

66. Hauswald H, Rieken S, Ecker S, et al. First experiences in treatment of low-grade glioma grade I and II with proton therapy. Radiat Oncol 2012;7:189. Available at: https://www.ncbi.nlm.nih.gov/pubmed/23140402.

67. Skeie BS, Enger PO, Brogger J, et al. Gamma knife surgery versus reoperation for recurrent glioblastoma multiforme. World Neurosurg 2012;78:658–669. Available at: https://www.ncbi.nlm.nih.gov/pubmed/22484078.

68. Minniti G, Niyazi M, Alongi F, et al. Current status and recent advances in reirradiation of glioblastoma. Radiat Oncol 2021;16:36. Available at: https://www.ncbi.nlm.nih.gov/pubmed/33602305.

69. Ziu M, Goyal S, Olson JJ. Congress of neurological surgeons systematic review and evidence-based guidelines update on the role of radiation therapy in the management of progressive and recurrent glioblastoma in adults. J Neurooncol 2022;158:255–264. Available at: https://www.ncbi.nlm.nih.gov/pubmed/34748120.

70. Amelio D, Amichetti M. Radiation therapy for the treatment of recurrent glioblastoma: an overview. Cancers (Basel) 2012;4:257–280. Available at: https://www.ncbi.nlm.nih.gov/pubmed/24213239.

71. Shrieve DC, Alexander E, 3rd, Wen PY, et al. Comparison of stereotactic radiosurgery and brachytherapy in the treatment of recurrent glioblastoma multiforme. Neurosurgery 1995;36:275–282; discussion 282–274. Available at: https://www.ncbi.nlm.nih.gov/pubmed/7731507.

72. Tsang DS, Oliveira C, Bouffet E, et al. Repeat irradiation for children with supratentorial high-grade glioma. Pediatr Blood Cancer 2019;66:e27881. Available at: https://www.ncbi.nlm.nih.gov/pubmed/31207154.

73. Pollack IF, Stewart CF, Kocak M, et al. A phase II study of gefitinib and irradiation in children with newly diagnosed brainstem gliomas: a report from the pediatric brain tumor consortium. Neuro Oncol 2011;13:290–297. Available at: https://www.ncbi.nlm.nih.gov/pubmed/21292687.

74. Jennings MT, Sposto R, Boyett JM, et al. Preradiation chemotherapy in primary high-risk brainstem tumors: phase II study CCG-9941 of the children's cancer group. J Clin Oncol 2002;20:3431–3437. Available at: https://www.ncbi.nlm.nih.gov/pubmed/12177103.

75. Cohen KJ, Heideman RL, Zhou T, et al. Temozolomide in the treatment of children with newly diagnosed diffuse intrinsic pontine gliomas: a report from the children's oncology group. Neuro Oncol 2011;13:410–416. Available at: https://www.ncbi.nlm.nih.gov/pubmed/21345842.

76. Bradley KA, Zhou T, McNall-Knapp RY, et al. Motexafin-gadolinium and involved field radiation therapy for intrinsic pontine glioma of childhood: a children's oncology group phase 2 study. Int J Radiat Oncol Biol Phys 2013;85:e55–60. Available at: https://www.ncbi.nlm.nih.gov/pubmed/23092726.

77. Freeman CR, Krischer JP, Sanford RA, et al. Final results of a study of escalating doses of hyperfractionated radiotherapy in brain stem tumors in children: A pediatric oncology group study. Int J Radiat Oncol Biol Phys

Version 1.2026 © 2025 National Comprehensive Cancer Network© (NCCN©), All rights reserved. NCCN Guidelines® and this illustration may not be reproduced in any form without the express written permission of NCCN.

PLEASE NOTE that use of this NCCN Content is governed by the End-User License Agreement, and you MAY NOT distribute this Content or use it with any artificial intelligence model or tool.
Printed by A. S. M. FAZLUL KARIM CHOWDHURY on 4/20/2026 3:38:59 AM. Copyright © 2026 National Comprehensive Cancer Network, Inc. All Rights Reserved.

1993;27:197–206. Available at: https://www.ncbi.nlm.nih.gov/pubmed/8407392.

78. Gallitto M, Lazarev S, Wasserman I, et al. Role of radiation therapy in the management of diffuse intrinsic pontine glioma: A systematic review. Adv Radiat Oncol 2019;4:520–531. Available at: https://www.ncbi.nlm.nih.gov/pubmed/31360809.

79. Zaghloul MS, Eldebawy E, Ahmed S, et al. Hypofractionated conformal radiotherapy for pediatric diffuse intrinsic pontine glioma (DIPG): a randomized controlled trial. Radiother Oncol 2014;111:35–40. Available at: https://www.ncbi.nlm.nih.gov/pubmed/24560760.

80. Hu X, Fang Y, Hui X, et al. Radiotherapy for diffuse brainstem glioma in children and young adults. Cochrane Database Syst Rev 2016;2016:CD010439. Available at: https://www.ncbi.nlm.nih.gov/pubmed/27378212.

81. Zaghloul MS, Akoush H, Ahmed S, et al. Hypofractionated radiation for pediatric diffuse intrinsic pontine glioma (DIPG): Younger children have better survival. Int J Radiat Oncol Biol Phys 2018;101:1008–1009. Available at: https://www.sciencedirect.com/science/article/pii/S0360301618302001.

82. Zaghloul MS, Nasr A, Tolba M, et al. Hypofractionated radiation therapy for diffuse intrinsic pontine glioma: A noninferiority randomized study including 253 children. Int J Radiat Oncol Biol Phys 2022;113:360–368. Available at: https://www.ncbi.nlm.nih.gov/pubmed/35150788.

83. Freese C, Takiar V, Fouladi M, et al. Radiation and subsequent reirradiation outcomes in the treatment of diffuse intrinsic pontine glioma and a systematic review of the reirradiation literature. Pract Radiat Oncol 2017;7:86–92. Available at: https://www.ncbi.nlm.nih.gov/pubmed/28274399.

84. Lu VM, Welby JP, Mahajan A, et al. Reirradiation for diffuse intrinsic pontine glioma: a systematic review and meta-analysis. Childs Nerv Syst 2019;35:739–746. Available at: https://www.ncbi.nlm.nih.gov/pubmed/30879125.

85. Amsbaugh MJ, Mahajan A, Thall PF, et al. A phase 1/2 trial of reirradiation for diffuse intrinsic pontine glioma. Int J Radiat Oncol Biol Phys 2019;104:144–148. Available at: https://www.ncbi.nlm.nih.gov/pubmed/30610915.

86. Duffner PK, Krischer JP, Burger PC, et al. Treatment of infants with malignant gliomas: The pediatric oncology group experience. J Neurooncol 1996;28:245–256. Available at: https://www.ncbi.nlm.nih.gov/pubmed/8832466.

87. Espinoza JC, Haley K, Patel N, et al. Outcome of young children with high-grade glioma treated with irradiation-avoiding intensive chemotherapy regimens: Final report of the head start II and III trials. Pediatr Blood Cancer 2016;63:1806–1813. Available at: https://www.ncbi.nlm.nih.gov/pubmed/27332770.

88. Nicolaides T, Nazemi KJ, Crawford J, et al. Phase I study of vemurafenib in children with recurrent or progressive BRAF(V600E) mutant brain tumors: Pacific pediatric neuro-oncology consortium study (PNOC-002). Oncotarget 2020;11:1942–1952. Available at: https://www.ncbi.nlm.nih.gov/pubmed/32523649.

89. Gierke M, Sperveslage J, Schwab D, et al. Analysis of IDH1-R132 mutation, BRAF V600 mutation and KIAA1549-BRAF fusion transcript status in central nervous system tumors supports pediatric tumor classification. J Cancer Res Clin Oncol 2016;142:89–100. Available at: https://www.ncbi.nlm.nih.gov/pubmed/26115961.

90. Kleinschmidt-DeMasters BK, Aisner DL, Birks DK, Foreman NK. Epithelioid GBMs show a high percentage of BRAF V600E mutation. Am J Surg Pathol 2013;37:685–698. Available at: https://www.ncbi.nlm.nih.gov/pubmed/23552385.

91. Schindler G, Capper D, Meyer J, et al. Analysis of BRAF V600E mutation in 1,320 nervous system tumors reveals high mutation frequencies in pleomorphic xanthoastrocytoma, ganglioglioma and extra-cerebellar pilocytic astrocytoma. Acta Neuropathol 2011;121:397–405. Available at: https://www.ncbi.nlm.nih.gov/pubmed/21274720.

Version 1.2026 © 2025 National Comprehensive Cancer Network© (NCCN©), All rights reserved. NCCN Guidelines® and this illustration may not be reproduced in any form without the express written permission of NCCN.

PLEASE NOTE that use of this NCCN Content is governed by the End-User License Agreement, and you MAY NOT distribute this Content or use it with any artificial intelligence model or tool.
Printed by A. S. M. FAZLUL KARIM CHOWDHURY on 4/20/2026 3:38:59 AM. Copyright © 2026 National Comprehensive Cancer Network, Inc. All Rights Reserved.

92. Hatzivassiliou G, Song K, Yen I, et al. RAF inhibitors prime wild-type RAF to activate the MAPK pathway and enhance growth. Nature 2010;464:431–435. Available at: https://www.ncbi.nlm.nih.gov/pubmed/20130576.

93. Poulikakos PI, Zhang C, Bollag G, et al. RAF inhibitors transactivate RAF dimers and ERK signalling in cells with wild-type BRAF. Nature 2010;464:427–430. Available at: https://www.ncbi.nlm.nih.gov/pubmed/20179705.

94. Su F, Viros A, Milagre C, et al. RAS mutations in cutaneous squamous-cell carcinomas in patients treated with BRAF inhibitors. N Engl J Med 2012;366:207–215. Available at: https://www.ncbi.nlm.nih.gov/pubmed/22256804.

95. Toll SA, Tran HN, Cotter J, et al. Sustained response of three pediatric BRAF(V600E) mutated high-grade gliomas to combined BRAF and MEK inhibitor therapy. Oncotarget 2019;10:551–557. Available at: https://www.ncbi.nlm.nih.gov/pubmed/30728904.

96. Marks AM, Bindra RS, DiLuna ML, et al. Response to the BRAF/MEK inhibitors dabrafenib/trametinib in an adolescent with a BRAF V600E mutated anaplastic ganglioglioma intolerant to vemurafenib. Pediatr Blood Cancer 2018;65:e26969. Available at: https://www.ncbi.nlm.nih.gov/pubmed/29380516.

97. Robinson GW, Orr BA, Gajjar A. Complete clinical regression of a BRAF V600E-mutant pediatric glioblastoma multiforme after BRAF inhibitor therapy. BMC Cancer 2014;14:258. Available at: https://www.ncbi.nlm.nih.gov/pubmed/24725538.

98. Bautista F, Paci A, Minard-Colin V, et al. Vemurafenib in pediatric patients with BRAFV600E mutated high-grade gliomas. Pediatr Blood Cancer 2014;61:1101–1103. Available at: https://www.ncbi.nlm.nih.gov/pubmed/24375920.

99. Gatalica Z, Xiu J, Swensen J, Vranic S. Molecular characterization of cancers with NTRK gene fusions. Mod Pathol 2019;32:147–153. Available at: https://www.ncbi.nlm.nih.gov/pubmed/30171197.

100. Amatu A, Sartore-Bianchi A, Siena S. NTRK gene fusions as novel targets of cancer therapy across multiple tumour types. ESMO Open 2016;1:e000023. Available at: https://www.ncbi.nlm.nih.gov/pubmed/27843590.

101. Drilon A, Laetsch TW, Kummar S, et al. Efficacy of larotrectinib in TRK fusion-positive cancers in adults and children. N Engl J Med 2018;378:731–739. Available at: https://www.ncbi.nlm.nih.gov/pubmed/29466156.

102. Desai AV, Robinson GW, Gauvain K, et al. Entrectinib in children and young adults with solid or primary CNS tumors harboring NTRK, ROS1, or ALK aberrations (STARTRK-NG). Neuro Oncol 2022;24:1776–1789. Available at: https://www.ncbi.nlm.nih.gov/pubmed/35395680.

103. Laetsch TW, DuBois SG, Mascarenhas L, et al. Larotrectinib for paediatric solid tumours harbouring NTRK gene fusions: phase 1 results from a multicentre, open-label, phase 1/2 study. Lancet Oncol 2018;19:705–714. Available at: https://www.ncbi.nlm.nih.gov/pubmed/29606586.

104. Doebele RC, Drilon A, Paz-Ares L, et al. Entrectinib in patients with advanced or metastatic NTRK fusion-positive solid tumours: integrated analysis of three phase 1-2 trials. Lancet Oncol 2020;21:271–282. Available at: https://www.ncbi.nlm.nih.gov/pubmed/31838007.

105. FDA grants accelerated approval to repotrectinib for adult and pediatric patients with NTRK gene fusion-positive solid tumors. Available at: https://www.fda.gov/drugs/resources-information-approved-drugs/fda-grants-accelerated-approval-repotrectinib-adult-and-pediatric-patients-ntrk-gene-fusion-positive. Accessed July 12, 2024.

106. Solomon BJ, Drilon A, Lin JJ, et al. 1372P Repotrectinib in patients (pts) with NTRK fusion-positive (NTRK+) advanced solid tumors, including NSCLC: Update from the phase I/II TRIDENT-1 trial. Annals of Oncology 2023;34:S787–S788. Available at: https://doi.org/10.1016/j.annonc.2023.09.2405.

Version 1.2026 © 2025 National Comprehensive Cancer Network© (NCCN©), All rights reserved. NCCN Guidelines® and this illustration may not be reproduced in any form without the express written permission of NCCN.

PLEASE NOTE that use of this NCCN Content is governed by the End-User License Agreement, and you MAY NOT distribute this Content or use it with any artificial intelligence model or tool.
Printed by A. S. M. FAZLUL KARIM CHOWDHURY on 4/20/2026 3:38:59 AM. Copyright © 2026 National Comprehensive Cancer Network, Inc. All Rights Reserved.

107. Bagchi A, Orr BA, Campagne O, et al. Lorlatinib in a child with ALK-fusion-positive high-grade glioma. N Engl J Med 2021;385:761–763. Available at: https://www.ncbi.nlm.nih.gov/pubmed/34407349.

108. Doz F, Casanova M, Koh K-N, et al. Abstract CT039: Alectinib in children and adolescents with solid or CNS tumors harboring ALK-fusions: Data from the iMATRIX Alectinib Phase I/II open-label, multi-center study. Cancer Research 2024;84:CT039–CT039. Available at: https://doi.org/10.1158/1538-7445.AM2024-CT039.

109. Bouffet E, Larouche V, Campbell BB, et al. Immune checkpoint inhibition for hypermutant glioblastoma multiforme resulting from germline biallelic mismatch repair deficiency. J Clin Oncol 2016;34:2206–2211. Available at: https://www.ncbi.nlm.nih.gov/pubmed/27001570.

110. Larouche V, Atkinson J, Albrecht S, et al. Sustained complete response of recurrent glioblastoma to combined checkpoint inhibition in a young patient with constitutional mismatch repair deficiency. Pediatr Blood Cancer 2018;65:e27389. Available at: https://www.ncbi.nlm.nih.gov/pubmed/30160041.

111. Cacciotti C, Choi J, Alexandrescu S, et al. Immune checkpoint inhibition for pediatric patients with recurrent/refractory CNS tumors: a single institution experience. J Neurooncol 2020;149:113–122. Available at: https://www.ncbi.nlm.nih.gov/pubmed/32627129.

112. Arrillaga-Romany I, Odia Y, Prabhu VV, et al. Biological activity of weekly ONC201 in adult recurrent glioblastoma patients. Neuro Oncol 2020;22:94–102. Available at: https://www.ncbi.nlm.nih.gov/pubmed/31702782.

113. Arrillaga-Romany I, Gardner SL, Odia Y, et al. ONC201 (Dordaviprone) in Recurrent H3 K27M-Mutant Diffuse Midline Glioma. J Clin Oncol 2024;42:1542–1552. Available at: https://www.ncbi.nlm.nih.gov/pubmed/38335473.

114. Needle MN, Molloy PT, Geyer JR, et al. Phase II study of daily oral etoposide in children with recurrent brain tumors and other solid tumors. Med Pediatr Oncol 1997;29:28–32. Available at: https://www.ncbi.nlm.nih.gov/pubmed/9142202.

115. Grill J, Massimino M, Bouffet E, et al. Phase II, open-label, randomized, multicenter trial (HERBY) of bevacizumab in pediatric patients with newly diagnosed high-grade glioma. J Clin Oncol 2018;36:951–958. Available at: https://www.ncbi.nlm.nih.gov/pubmed/29412784.

116. Price M, Ballard C, Benedetti J, et al. CBTRUS statistical report: Primary brain and other central nervous system tumors diagnosed in the united states in 2017-2021. Neuro Oncol 2024;26:vi1–vi85. Available at: https://www.ncbi.nlm.nih.gov/pubmed/39371035.

117. Thompson EM, Hielscher T, Bouffet E, et al. Prognostic value of medulloblastoma extent of resection after accounting for molecular subgroup: a retrospective integrated clinical and molecular analysis. Lancet Oncol 2016;17:484–495. Available at: https://www.ncbi.nlm.nih.gov/pubmed/26976201.

118. Taylor MD, Northcott PA, Korshunov A, et al. Molecular subgroups of medulloblastoma: the current consensus. Acta Neuropathol 2012;123:465–472. Available at: https://www.ncbi.nlm.nih.gov/pubmed/22134537.

119. Kool M, Korshunov A, Remke M, et al. Molecular subgroups of medulloblastoma: an international meta-analysis of transcriptome, genetic aberrations, and clinical data of WNT, SHH, Group 3, and Group 4 medulloblastomas. Acta Neuropathol 2012;123:473–484. Available at: https://www.ncbi.nlm.nih.gov/pubmed/22358457.

120. Schwalbe EC, Lindsey JC, Nakjang S, et al. Novel molecular subgroups for clinical classification and outcome prediction in childhood medulloblastoma: a cohort study. Lancet Oncol 2017;18:958–971. Available at: https://www.ncbi.nlm.nih.gov/pubmed/28545823.

121. Carta R, Del Baldo G, Miele E, et al. Cancer predisposition syndromes and medulloblastoma in the molecular era. Front Oncol

Version 1.2026 © 2025 National Comprehensive Cancer Network© (NCCN©), All rights reserved. NCCN Guidelines® and this illustration may not be reproduced in any form without the express written permission of NCCN.

PLEASE NOTE that use of this NCCN Content is governed by the End-User License Agreement, and you MAY NOT distribute this Content or use it with any artificial intelligence model or tool.
Printed by A. S. M. FAZLUL KARIM CHOWDHURY on 4/20/2026 3:38:59 AM. Copyright © 2026 National Comprehensive Cancer Network, Inc. All Rights Reserved.

2020;10:566822. Available at: https://www.ncbi.nlm.nih.gov/pubmed/33194646.

122. Waszak SM, Northcott PA, Buchhalter I, et al. Spectrum and prevalence of genetic predisposition in medulloblastoma: a retrospective genetic study and prospective validation in a clinical trial cohort. Lancet Oncol 2018;19:785–798. Available at: https://www.ncbi.nlm.nih.gov/pubmed/29753700.

123. Dangouloff-Ros V, Varlet P, Levy R, et al. Imaging features of medulloblastoma: Conventional imaging, diffusion-weighted imaging, perfusion-weighted imaging, and spectroscopy: From general features to subtypes and characteristics. Neurochirurgie 2021;67:6–13. Available at: https://www.ncbi.nlm.nih.gov/pubmed/30170827.

124. Rogers SN, Udayasankar U, Pruthi S, et al. Imaging of pediatric spine and spinal cord tumors: A COG diagnostic imaging committee/SPR oncology committee/ASPNR white paper. Pediatr Blood Cancer 2023;70 Suppl 4:e30150. Available at: https://www.ncbi.nlm.nih.gov/pubmed/36562555.

125. Reddy N, Ellison DW, Soares BP, et al. Pediatric posterior fossa medulloblastoma: The role of diffusion imaging in identifying molecular groups. J Neuroimaging 2020;30:503–511. Available at: https://www.ncbi.nlm.nih.gov/pubmed/32529709.

126. Iv M, Zhou M, Shpanskaya K, et al. MR imaging-based radiomic signatures of distinct molecular subgroups of medulloblastoma. AJNR Am J Neuroradiol 2019;40:154–161. Available at: https://www.ncbi.nlm.nih.gov/pubmed/30523141.

127. Tripathi M, Jain N, Jaimini A, et al. Demonstration of diffuse leptomeningeal metastasis in a treated case of medulloblastoma with F-18 FDG PET/CT. Clin Nucl Med 2009;34:530–532. Available at: https://www.ncbi.nlm.nih.gov/pubmed/19617737.

128. Gururangan S, Hwang E, Herndon JE, 2nd, et al. [18F]fluorodeoxyglucose-positron emission tomography in patients with medulloblastoma. Neurosurgery 2004;55:1280–1288; discussion 1288–1289. Available at: https://www.ncbi.nlm.nih.gov/pubmed/15574210.

129. Zhang M, Wong SW, Wright JN, et al. MRI radiogenomics of pediatric medulloblastoma: A multicenter study. Radiology 2022;304:406–416. Available at: https://www.ncbi.nlm.nih.gov/pubmed/35438562.

130. Bennett J, Ashmawy R, Ramaswamy V, et al. The clinical significance of equivocal findings on spinal MRI in children with medulloblastoma. Pediatr Blood Cancer 2017;64. Available at: https://www.ncbi.nlm.nih.gov/pubmed/28205381.

131. Ellison DW, Dalton J, Kocak M, et al. Medulloblastoma: clinicopathological correlates of SHH, WNT, and non-SHH/WNT molecular subgroups. Acta Neuropathol 2011;121:381–396. Available at: https://www.ncbi.nlm.nih.gov/pubmed/21267586.

132. Zhukova N, Ramaswamy V, Remke M, et al. Subgroup-specific prognostic implications of TP53 mutation in medulloblastoma. J Clin Oncol 2013;31:2927–2935. Available at: https://www.ncbi.nlm.nih.gov/pubmed/23835706.

133. Northcott PA, Buchhalter I, Morrissy AS, et al. The whole-genome landscape of medulloblastoma subtypes. Nature 2017;547:311–317. Available at: https://www.ncbi.nlm.nih.gov/pubmed/28726821.

134. Albright AL, Wisoff JH, Zeltzer PM, et al. Effects of medulloblastoma resections on outcome in children: a report from the children's cancer group. Neurosurgery 1996;38:265–271. Available at: https://www.ncbi.nlm.nih.gov/pubmed/8869053.

135. Zeltzer PM, Boyett JM, Finlay JL, et al. Metastasis stage, adjuvant treatment, and residual tumor are prognostic factors for medulloblastoma in children: conclusions from the Children's Cancer Group 921 randomized phase III study. J Clin Oncol 1999;17:832–845. Available at: https://www.ncbi.nlm.nih.gov/pubmed/10071274.

136. Reisinger D, Gojo J, Kasprian G, et al. Predisposition of wingless subgroup medulloblastoma for primary tumor hemorrhage. Neurosurgery

Version 1.2026 © 2025 National Comprehensive Cancer Network© (NCCN©), All rights reserved. NCCN Guidelines® and this illustration may not be reproduced in any form without the express written permission of NCCN.

PLEASE NOTE that use of this NCCN Content is governed by the End-User License Agreement, and you MAY NOT distribute this Content or use it with any artificial intelligence model or tool.
Printed by A. S. M. FAZLUL KARIM CHOWDHURY on 4/20/2026 3:38:59 AM. Copyright © 2026 National Comprehensive Cancer Network, Inc. All Rights Reserved.

2020;86:478–484. Available at: https://www.ncbi.nlm.nih.gov/pubmed/31065705.

137. Patel P, Wallace D, Boop FA, et al. Reoperation for medulloblastoma prior to adjuvant therapy. Neurosurgery 2019;84:1050–1058. Available at: https://www.ncbi.nlm.nih.gov/pubmed/29660028.

138. Mynarek M, Goschzik T, Kool M, et al. MEDB-04. Young children with metastatic medulloblastoma: frequent requirement for radiotherapy in children with non-WNT/non-SHH medulloblastoma despite highly intensified chemotherapy – Results of the MET-HIT2000-BIS4 trial. Neuro-Oncology 2022;24:i104–i104. Available at: https://doi.org/10.1093/neuonc/noac079.379.

139. Cohen KJ, Munjapara V, Aguilera D, et al. A pilot study omitting radiation in the treatment of children with newly diagnosed WNT-activated medulloblastoma. Clin Cancer Res 2023;29:5031–5037. Available at: https://www.ncbi.nlm.nih.gov/pubmed/37498309.

140. Michalski JM, Janss AJ, Vezina LG, et al. Children's oncology group phase iii trial of reduced-dose and reduced-volume radiotherapy with chemotherapy for newly diagnosed average-risk medulloblastoma. J Clin Oncol 2021;39:2685–2697. Available at: https://www.ncbi.nlm.nih.gov/pubmed/34110925.

141. Leary SES, Packer RJ, Li Y, et al. Efficacy of carboplatin and isotretinoin in children with high-risk medulloblastoma: A randomized clinical trial from the children's oncology group. JAMA Oncol 2021;7:1313–1321. Available at: https://www.ncbi.nlm.nih.gov/pubmed/34292305.

142. Kahalley LS, Peterson R, Ris MD, et al. Superior intellectual outcomes after proton radiotherapy compared with photon radiotherapy for pediatric medulloblastoma. J Clin Oncol 2020;38:454–461. Available at: https://www.ncbi.nlm.nih.gov/pubmed/31774710.

143. Unnikrishnan S, Yip AT, Qian AS, et al. Neurocognitive outcomes in multiethnic pediatric brain tumor patients treated with proton versus photon radiation. J Pediatr Hematol Oncol 2023;45:e837–e846. Available at: https://www.ncbi.nlm.nih.gov/pubmed/37539987.

144. Eaton BR, Fong GW, Ingerski LM, et al. Intellectual functioning among case-matched cohorts of children treated with proton or photon radiation for standard-risk medulloblastoma. Cancer 2021;127:3840–3846. Available at: https://www.ncbi.nlm.nih.gov/pubmed/34255345.

145. Haas-Kogan D, Indelicato D, Paganetti H, et al. National cancer institute workshop on proton therapy for children: Considerations regarding brainstem injury. Int J Radiat Oncol Biol Phys 2018;101:152–168. Available at: https://www.ncbi.nlm.nih.gov/pubmed/29619963.

146. Gajjar A, Robinson GW, Smith KS, et al. Outcomes by clinical and molecular features in children with medulloblastoma treated with risk-adapted therapy: Results of an international phase III trial (SJMB03). J Clin Oncol 2021;39:822–835. Available at: https://www.ncbi.nlm.nih.gov/pubmed/33405951.

147. Jakacki RI, Burger PC, Zhou T, et al. Outcome of children with metastatic medulloblastoma treated with carboplatin during craniospinal radiotherapy: A children's oncology group phase I/II study. J Clin Oncol 2012;30:2648–2653. Available at: https://www.ncbi.nlm.nih.gov/pubmed/22665539.

148. Levy AS, Krailo M, Chi S, et al. Temozolomide with irinotecan versus temozolomide, irinotecan plus bevacizumab for recurrent medulloblastoma of childhood: Report of a COG randomized phase II screening trial. Pediatr Blood Cancer 2021;68:e29031. Available at: https://www.ncbi.nlm.nih.gov/pubmed/33844469.

149. Le Teuff G, Castaneda-Heredia A, Dufour C, et al. Phase II study of temozolomide and topotecan (TOTEM) in children with relapsed or refractory extracranial and central nervous system tumors including medulloblastoma with post hoc bayesian analysis: A european ITCC study. Pediatr Blood Cancer 2020;67:e28032. Available at: https://www.ncbi.nlm.nih.gov/pubmed/31595663.

150. Pasquier E, Kavallaris M, Andre N. Metronomic chemotherapy: new rationale for new directions. Nat Rev Clin Oncol 2010;7:455–465. Available at: https://www.ncbi.nlm.nih.gov/pubmed/20531380.

Version 1.2026 © 2025 National Comprehensive Cancer Network© (NCCN©), All rights reserved. NCCN Guidelines® and this illustration may not be reproduced in any form without the express written permission of NCCN.

PLEASE NOTE that use of this NCCN Content is governed by the End-User License Agreement, and you MAY NOT distribute this Content or use it with any artificial intelligence model or tool.
Printed by A. S. M. FAZLUL KARIM CHOWDHURY on 4/20/2026 3:38:59 AM. Copyright © 2026 National Comprehensive Cancer Network, Inc. All Rights Reserved.

151. Slavc I, Mayr L, Stepien N, et al. Improved long-term survival of patients with recurrent medulloblastoma treated with a "MEMMAT-like" metronomic antiangiogenic approach. Cancers (Basel) 2022;14:5128. Available at: https://www.ncbi.nlm.nih.gov/pubmed/36291912.

152. Winnicki C, Leblond P, Bourdeaut F, et al. Retrospective national “real life” experience of the SFCE with the metronomic MEMMAT and MEMMAT-like protocol. J Clin Med 2023;12:1415. Available at: https://www.ncbi.nlm.nih.gov/pubmed/36835950.

153. Peyrl A, Chocholous M, Sabel M, et al. Sustained survival benefit in recurrent medulloblastoma by a metronomic antiangiogenic regimen: A nonrandomized controlled trial. JAMA Oncol 2023;9:1688–1695. Available at: https://www.ncbi.nlm.nih.gov/pubmed/37883081.

154. Robison NJ, Campigotto F, Chi SN, et al. A phase II trial of a multi-agent oral antiangiogenic (metronomic) regimen in children with recurrent or progressive cancer. Pediatr Blood Cancer 2014;61:636–642. Available at: https://www.ncbi.nlm.nih.gov/pubmed/24123865.

155. Gaab C, Adolph JE, Tippelt S, et al. Local and systemic therapy of recurrent medulloblastomas in children and adolescents: Results of the P-HIT-REZ 2005 study. Cancers (Basel) 2022;14:471. Available at: https://www.ncbi.nlm.nih.gov/pubmed/35158738.

Version 1.2026 © 2025 National Comprehensive Cancer Network© (NCCN©), All rights reserved. NCCN Guidelines® and this illustration may not be reproduced in any form without the express written permission of NCCN.