National Comprehensive Cancer Network®

NCCN Clinical Practice Guidelines in Oncology (NCCN Guidelines®)

# Pediatric Soft Tissue Sarcoma

Version 1.2026 — February 17, 2026

**NCCN recognizes the importance of clinical trials and encourages participation when applicable and available. Trials should be designed to maximize inclusiveness and broad representative enrollment.**

Version 1.2026, 02/017/2026 © 2026 National Comprehensive Cancer Network® (NCCN®), All rights reserved. NCCN Guidelines® and this illustration may not be reproduced in any form without the express written permission of NCCN.

PLEASE NOTE that use of this NCCN Content is governed by the End-User License Agreement, and you MAY NOT distribute this Content or use it with any artificial intelligence model or tool.
Printed by A. S. M. FAZLUL KARIM CHOWDHURY on 4/20/2026 3:39:07 AM. Copyright © 2026 National Comprehensive Cancer Network, Inc. All Rights Reserved.



**Stephen Skapek, MD/Chair € ‡**
Duke Cancer Center/Duke Children's Hospital & Health Center

**Douglas Hawkins, MD/Vice Chair €**
Fred Hutchinson Cancer Center/Seattle Children's Hospital

**Alyaa Al-Ibraheemi, MD ≠**
Dana-Farber/Boston Children's Cancer and Blood Disorders Center

**Wendy Allen-Rhoades, MD, PhD €**
Mayo Clinic Comprehensive Cancer Center

**Raffi Avedian, MD ᵀ ¶**
Stanford Cancer Institute/Lucile Packard Children's Hospital

**Jill Beck, MD €**
Seattle Children's Hospital/Fred & Pamela Buffett Cancer Center

**Scott Borinstein, MD, PhD €**
Monroe Carell Jr. Children's Hospital at Vanderbilt/Vanderbilt-Ingram Cancer Center

**Barrett Cromeens, DO, PhD ¶**
Indiana University Melvin and Bren Simon Comprehensive Cancer Center/Riley Children's Health

**Douglas Fair, MD, MS €**
Huntsman Cancer Institute
at the University of Utah Primary Children's Hospital

**Ajay Gupta, MD € †**
Roswell Park Comprehensive Cancer Center/ Roswell Park Oishei Children's Cancer and Blood Disorders Program

**Jonathan Kaufman, MD † ¥**
Emory Winship Cancer Institute

**Margaret Kozak, MD §**
UT Southwestern Simmons Comprehensive Cancer Center/Children's Medical Center Dallas

**Theodore Laetsch, MD €**
Abramson Cancer Center at the University of Pennsylvania/Children's Hospital of Philadelphia

**Nicole Larrier, MD, MSc §**
Duke Cancer Institute/Duke Children's Hospial & Health Center

**Sara Mansfield, MD, MS ¶**
The Ohio State University Comprehensive Cancer Center - James Cancer Hospital and Solove Research Institute/Nationwide Children's Hospital

**Jonathan Metts, MD € †**
Moffitt Cancer Center

**Sarah Milgrom, MD §**
University of Colorado Cancer Center/Children's Hospital Colorado

**Lorenzo Nardo, MD, PhD ф ф**
UC Davis Comprehensive Cancer Center

**Alberto Pappo, MD €**
St. Jude Children's Research Hospital/The University of Tennessee Health Science Center

**Christine Pratilas, MD €**
Johns Hopkins Kimmel Cancer Center/Johns Hopkins Children's Center

**Raja Rabah, MD ≠**
University of Michigan Rogel Cancer Center/ C.S. Mott Children's Hospital

**Jennifer Reichek, MD, MSW € £**
Robert H. Lurie Comprehensive Cancer Center of Northwestern University/Ann & Robert H. Lurie Children's Hospital of Chicago

**Emily Slotkin, MD €**
Memorial Sloan Kettering Cancer Center

**Jonathan Swanson, MD, MBA € ф**
University of Wisconsin Carbone Cancer Center/American Family Children's Hospital

**Juan Vasquez, MD €**
Yale Cancer Center/Smilow Cancer Hospital/ Yale New Haven Children's Hospital

**Lauren Wessel, MD ᵀ ¶**
UCLA Jonsson Comprehensive Cancer Center/ UCLA Mattel Children's Hospital

**Kimberly Whelan, MD, MSPH € ‡**
O'Neal Comprehensive Cancer Center at UAB/ Children's of Alabama

**Janet Yoon, MD € †**
City of Hope National Medical Center

**NCCN**
**Cindy Hochstetler, PhD**
**Beth McCullough, RN, BS**
**Katie Stehman, PA-C, MMS**

ф Diagnostic radiology
‡ Hematology/ Hematology oncology
† Medical oncology
ϕ Nuclear medicine
ᵀ Orthopedics
¥ Patient advocacy
≠ Pathology
€ Pediatric oncology
§ Radiotherapy/ Radiation oncology
£ Supportive care including palliative, pain management, pastoral care, and oncology social work
¶ Surgery/Surgical oncology

NCCN Guidelines Panel Disclosures

PLEASE NOTE that use of this NCCN Content is governed by the End-User License Agreement, and you MAY NOT distribute this Content or use it with any artificial intelligence model or tool.
Printed by A. S. M. FAZLUL KARIM CHOWDHURY on 4/20/2026 3:39:07 AM. Copyright © 2026 National Comprehensive Cancer Network, Inc. All Rights Reserved.



# NCCN Guidelines Version 1.2026
# Pediatric Soft Tissue Sarcoma

NCCN Pediatric Soft Tissue Sarcoma Panel Members

**Pediatric Rhabdomyosarcoma**
Unidentified Mass for Which RMS is Likely (PRMS-1)
RMS Site-Specific Considerations (PRMS-2)
Risk Stratification (PRMS-10)
Very-Low-Risk/Low-Risk RMS (PRMS-11)
Intermediate-Risk RMS (PRMS-12)
High-Risk RMS (PRMS-13)
Recurrent or Progressive RMS (PRMS-14)
Surveillance for Patients With No Known Active Disease (PRMS-15)

**Principles of:**
- Imaging (PRMS-A)
- Pathologic Assessment (PRMS-B)
- Ancillary Techniques Useful in the Diagnosis of RMS (PRMS-C)
- Surgery (PRMS-D)
- Lymph Node Disease Assessment (PRMS-E)
- Radiation Therapy (PRMS-F)
- Systemic Therapy (PRMS-G)
- Survivorship (PRMS-H)

Staging and Clinical Group Tables (ST-1)
Abbreviations (ABBR-1)

Find an NCCN Member Institution: https://www.nccn.org/home/member-institutions.

**NCCN Categories of Evidence and Consensus:** All recommendations are category 2A unless otherwise indicated.

See NCCN Categories of Evidence and Consensus.

**NCCN Categories of Preference:** All recommendations are considered appropriate.

See NCCN Categories of Preference.

The NCCN Guidelines® are a statement of evidence and consensus of the authors regarding their views of currently accepted approaches to treatment. Any clinician seeking to apply or consult the NCCN Guidelines is expected to use independent medical judgment in the context of individual clinical circumstances to determine any patient's care or treatment. The National Comprehensive Cancer Network® (NCCN®) makes no representations or warranties of any kind regarding their content, use or application and disclaims any responsibility for their application or use in any way. The NCCN Guidelines are copyrighted by National Comprehensive Cancer Network®. All rights reserved. The NCCN Guidelines and the illustrations herein may not be reproduced in any form without the express written permission of NCCN. ©2026.

PLEASE NOTE that use of this NCCN Content is governed by the End-User License Agreement, and you MAY NOT distribute this Content or use it with any artificial intelligence model or tool.
Printed by A. S. M. FAZLUL KARIM CHOWDHURY on 4/20/2026 3:39:07 AM. Copyright © 2026 National Comprehensive Cancer Network, Inc. All Rights Reserved.



## WORKUP[a]

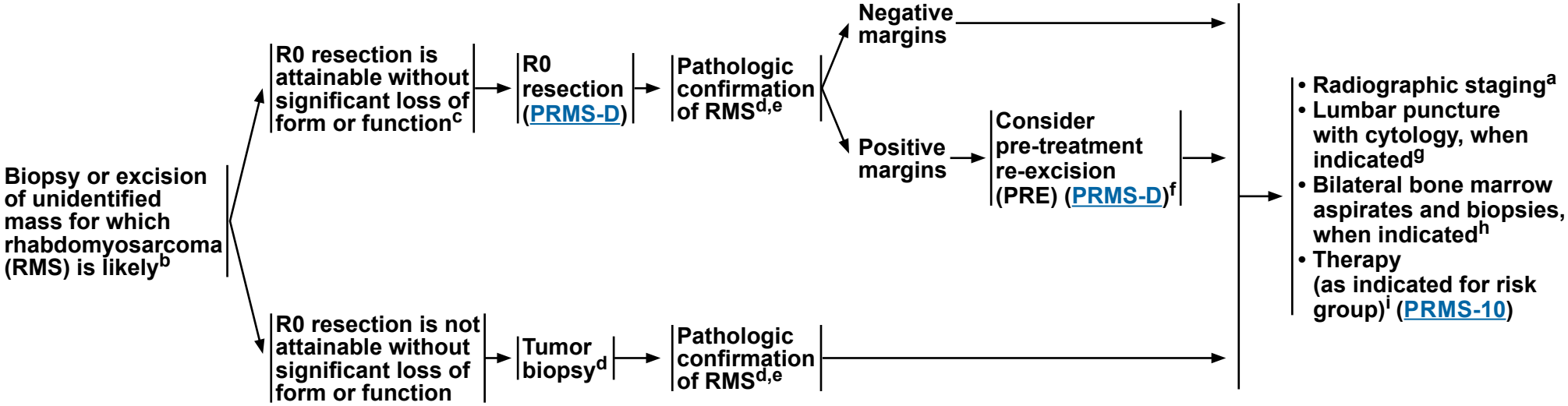


[a] Principles of Imaging.
[b] RMS Site-Specific Considerations (PRMS-2).
[c] Significant loss of form and function is subjective and decided as part of the multidisciplinary discussion. As a general rule, orbital exenteration, major excisions of the face, extremity amputation, rendering an extremity useless, major organ resection (ie, bladder/prostate resection, pneumonectomy), pelvic exenteration, or resection requiring permanent stool/urinary diversion should all be avoided. Craniofacial resection for anterior skull-base tumors of the nasal areas, paranasal sinuses, temporal fossa, and other such sites should be reserved for surgical teams who demonstrate expert performance in these areas.
[d] Principles of Pathologic Assessment.
[e] Germline testing is recommended in selected patients based upon histology and family history.
[f] PRE should be considered if there is: 1) gross residual tumor; 2) microscopically involved margins; or 3) uncertainty as to margins or residual disease. PRE is advisable and should be applied wherever feasible, unless the resulting disability is considered unacceptable (ie, resulting in loss of function or an unacceptable cosmetic result).
[g] Recommended for patients with parameningeal RMS.
[h] Recommended for: 1) patients with *FOXO1* gene fusion-negative RMS with N1 nodal disease and/or metastatic disease; and 2) all patients with *FOXO1* gene fusion-positive RMS.
[i] After induction chemotherapy, the primary site should be re-evaluated radiographically and local control should be discussed with a multidisciplinary approach including oncology, surgery, and radiation oncology. The discussion should weigh the morbidity of a delayed primary excision (DPE) in which an R0 resection without significant loss of form and function can be performed against the morbidity of a higher dose of local radiation therapy (RT).

**Note: All recommendations are category 2A unless otherwise indicated.**



Version 1.2026, 02/017/2026 © 2026 National Comprehensive Cancer Network® (NCCN®), All rights reserved. NCCN Guidelines® and this illustration may not be reproduced in any form without the express written permission of NCCN.

PLEASE NOTE that use of this NCCN Content is governed by the End-User License Agreement, and you MAY NOT distribute this Content or use it with any artificial intelligence model or tool.
Printed by A. S. M. FAZLUL KARIM CHOWDHURY on 4/20/2026 3:39:07 AM. Copyright © 2026 National Comprehensive Cancer Network, Inc. All Rights Reserved.



## RHABDOMYOSARCOMA SITE-SPECIFIC CONSIDERATIONS

**Head or neck mass (PRMS-3)**

**Soft tissue mass of the extremity (PRMS-4)**

**Soft tissue mass of the trunk (PRMS-5)**

**Mass of the vulva, vagina, or uterus fundus/cervix (PRMS-6)**

**Paratesticular mass (PRMS-7)**

**Bladder or prostate mass (PRMS-8)**

**Biliary/liver mass (PRMS-9)**

**Note: All recommendations are category 2A unless otherwise indicated.**



Version 1.2026, 02/017/2026 © 2026 National Comprehensive Cancer Network® (NCCN®), All rights reserved. NCCN Guidelines® and this illustration may not be reproduced in any form without the express written permission of NCCN.

PLEASE NOTE that use of this NCCN Content is governed by the End-User License Agreement, and you MAY NOT distribute this Content or use it with any artificial intelligence model or tool.
Printed by A. S. M. FAZLUL KARIM CHOWDHURY on 4/20/2026 3:39:07 AM. Copyright © 2026 National Comprehensive Cancer Network, Inc. All Rights Reserved.



## HEAD OR NECK MASS

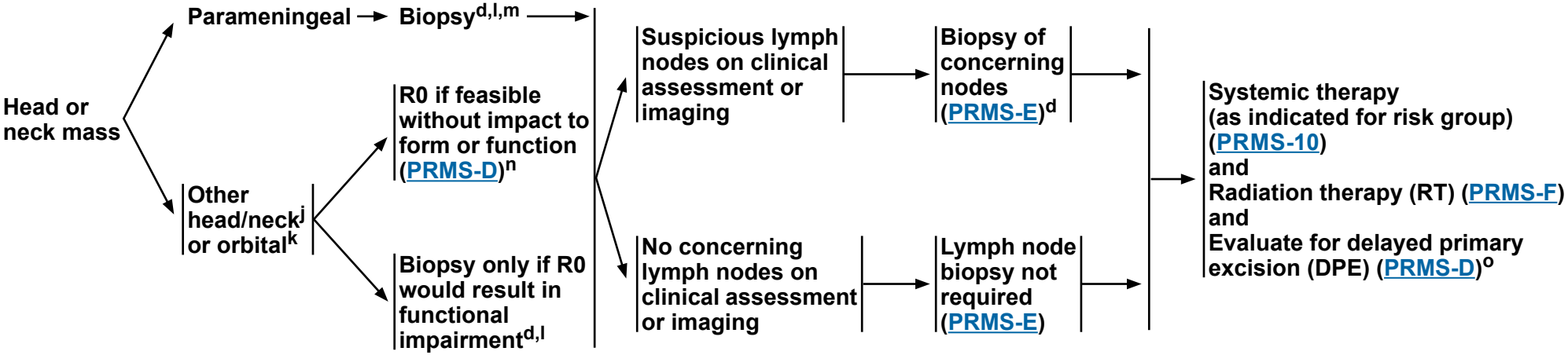


[d] Principles of Pathologic Assessment.
[j] Raney RB, et al. Pediatr Blood Cancer 2008;50:958-964.
[k] RMS of the orbit should not undergo exenteration, but biopsy is needed for diagnosis. Oberlin O, et al. J Clin Oncol 2001;19:197-204.
[l] Adequate biopsy is required and should provide sufficient tissue to establish the diagnosis and for further molecular genetic analysis.
[m] Lumbar puncture with cytology after diagnosis is confirmed.
[n] Narrow resection margins (<1 mm) are acceptable because of anatomical restrictions. Cosmetic and functional factors should always be considered.
[o] There are situations in which some may benefit from DPE. See Principles of Surgery.

**Note: All recommendations are category 2A unless otherwise indicated.**



Version 1.2026, 02/017/2026 © 2026 National Comprehensive Cancer Network® (NCCN®), All rights reserved. NCCN Guidelines® and this illustration may not be reproduced in any form without the express written permission of NCCN.

PLEASE NOTE that use of this NCCN Content is governed by the End-User License Agreement, and you MAY NOT distribute this Content or use it with any artificial intelligence model or tool.
Printed by A. S. M. FAZLUL KARIM CHOWDHURY on 4/20/2026 3:39:07 AM. Copyright © 2026 National Comprehensive Cancer Network, Inc. All Rights Reserved.



## SOFT TISSUE MASS OF THE EXTREMITY

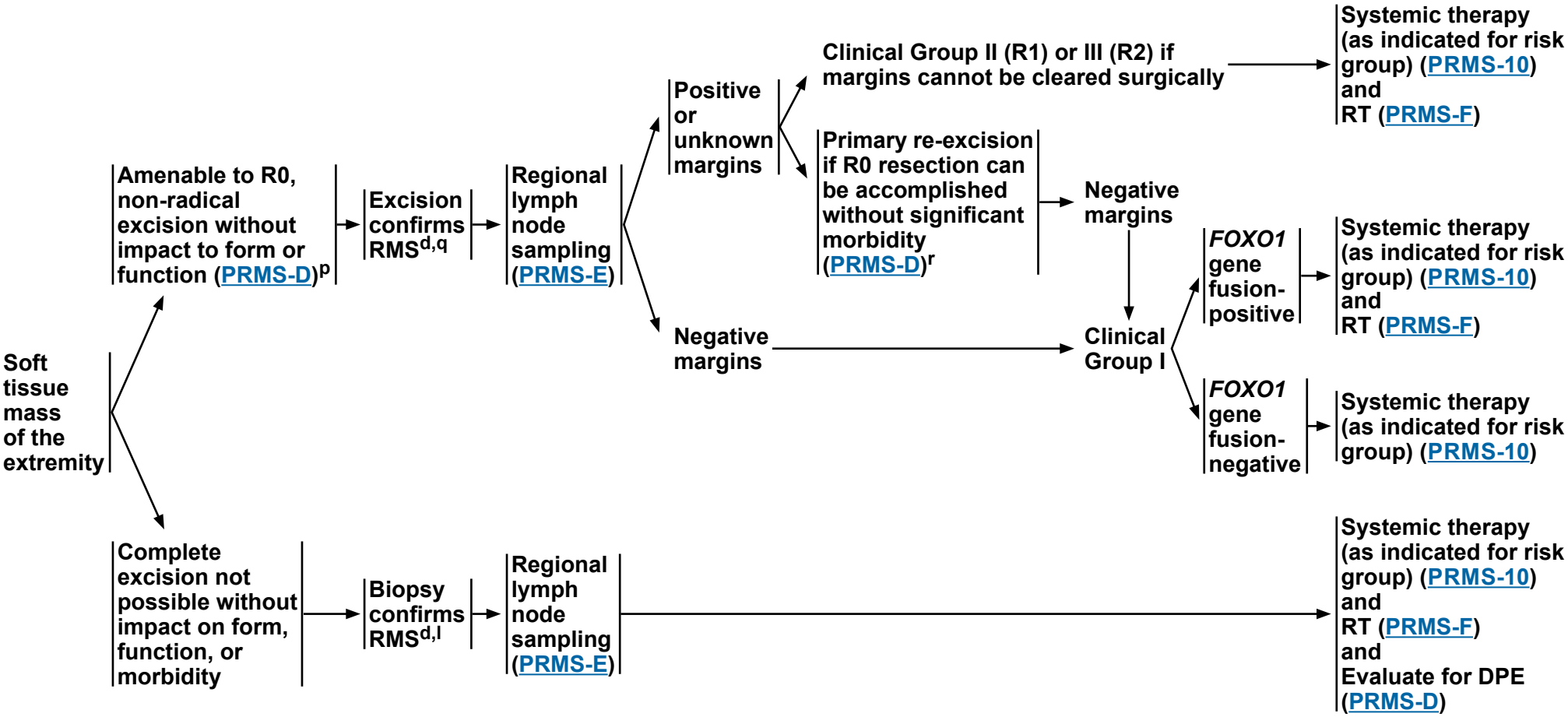


[d] Principles of Pathologic Assessment.
[l] Adequate biopsy is required and should provide sufficient tissue to establish the diagnosis and for further molecular genetic analysis.
[p] Initial primary resection is performed if there is a realistic expectation of achieving negative margins (R0 resection) and if cosmetic and functional outcomes are acceptable.
[q] Extremity tumors are often amenable to wide or radical resection while sparing the involved limb. Excision of an entire muscle from origin to insertion or resection of the entire compartment may not be required, depending on the size and invasiveness of the specific tumor.
[r] If there is suspicion or knowledge of residual tumor after the initial resection, PRE should be employed unless this would result in loss of form or function.

**Note: All recommendations are category 2A unless otherwise indicated.**



Version 1.2026, 02/017/2026 © 2026 National Comprehensive Cancer Network® (NCCN®), All rights reserved. NCCN Guidelines® and this illustration may not be reproduced in any form without the express written permission of NCCN.

PLEASE NOTE that use of this NCCN Content is governed by the End-User License Agreement, and you MAY NOT distribute this Content or use it with any artificial intelligence model or tool.
Printed by A. S. M. FAZLUL KARIM CHOWDHURY on 4/20/2026 3:39:07 AM. Copyright © 2026 National Comprehensive Cancer Network, Inc. All Rights Reserved.



## SOFT TISSUE MASS OF THE TRUNK

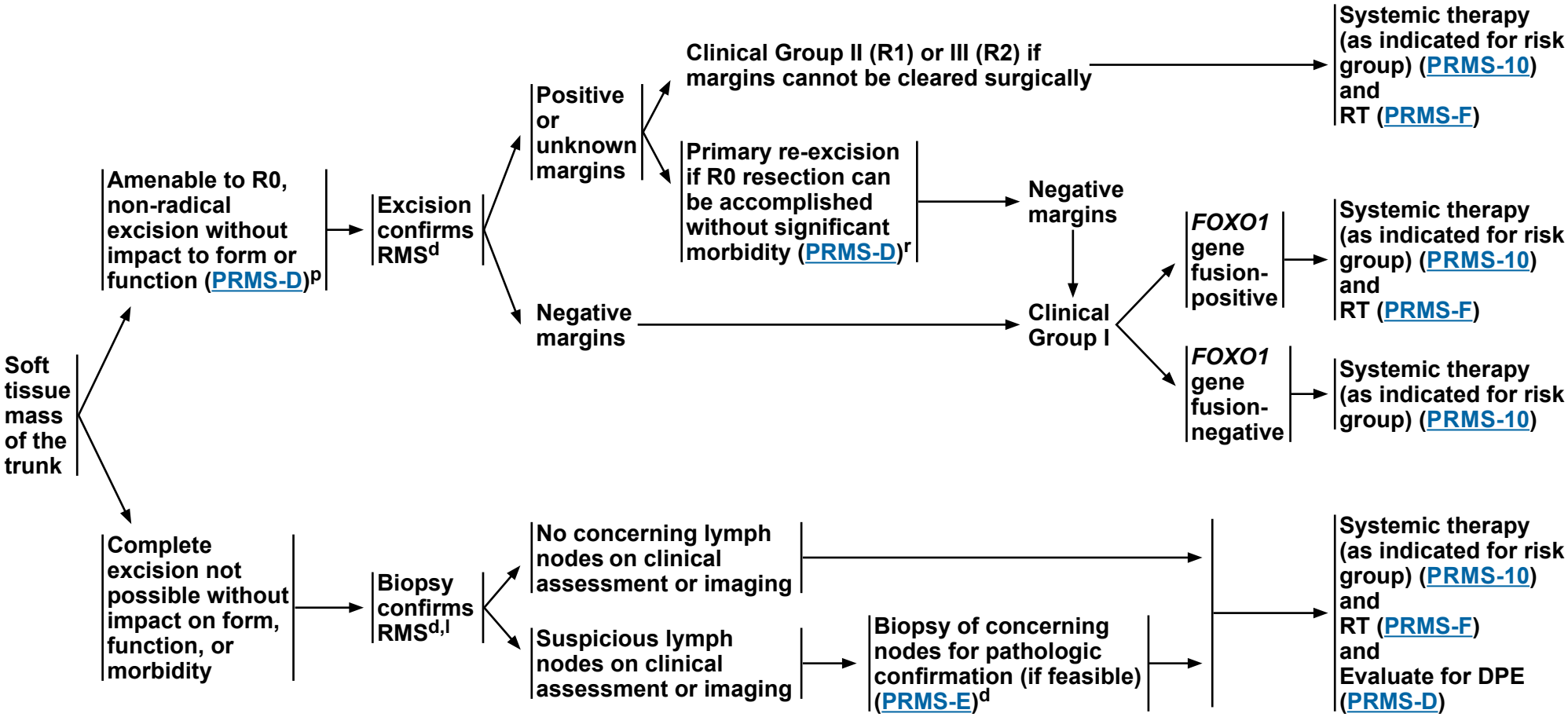


[d] Principles of Pathologic Assessment.
[l] Adequate biopsy is required and should provide sufficient tissue to establish the diagnosis and for further molecular genetic analysis.
[p] Initial primary resection is performed if there is a realistic expectation of achieving negative margins (R0 resection) and if cosmetic and functional outcomes are acceptable.
[r] If there is suspicion or knowledge of residual tumor after the initial resection, PRE should be employed unless this would result in loss of form or function.

**Note: All recommendations are category 2A unless otherwise indicated.**



Version 1.2026, 02/017/2026 © 2026 National Comprehensive Cancer Network® (NCCN®), All rights reserved. NCCN Guidelines® and this illustration may not be reproduced in any form without the express written permission of NCCN.

PLEASE NOTE that use of this NCCN Content is governed by the End-User License Agreement, and you MAY NOT distribute this Content or use it with any artificial intelligence model or tool.
Printed by A. S. M. FAZLUL KARIM CHOWDHURY on 4/20/2026 3:39:07 AM. Copyright © 2026 National Comprehensive Cancer Network, Inc. All Rights Reserved.



## MASS OF THE VULVA, VAGINA, OR UTERUS FUNDUS/CERVIX

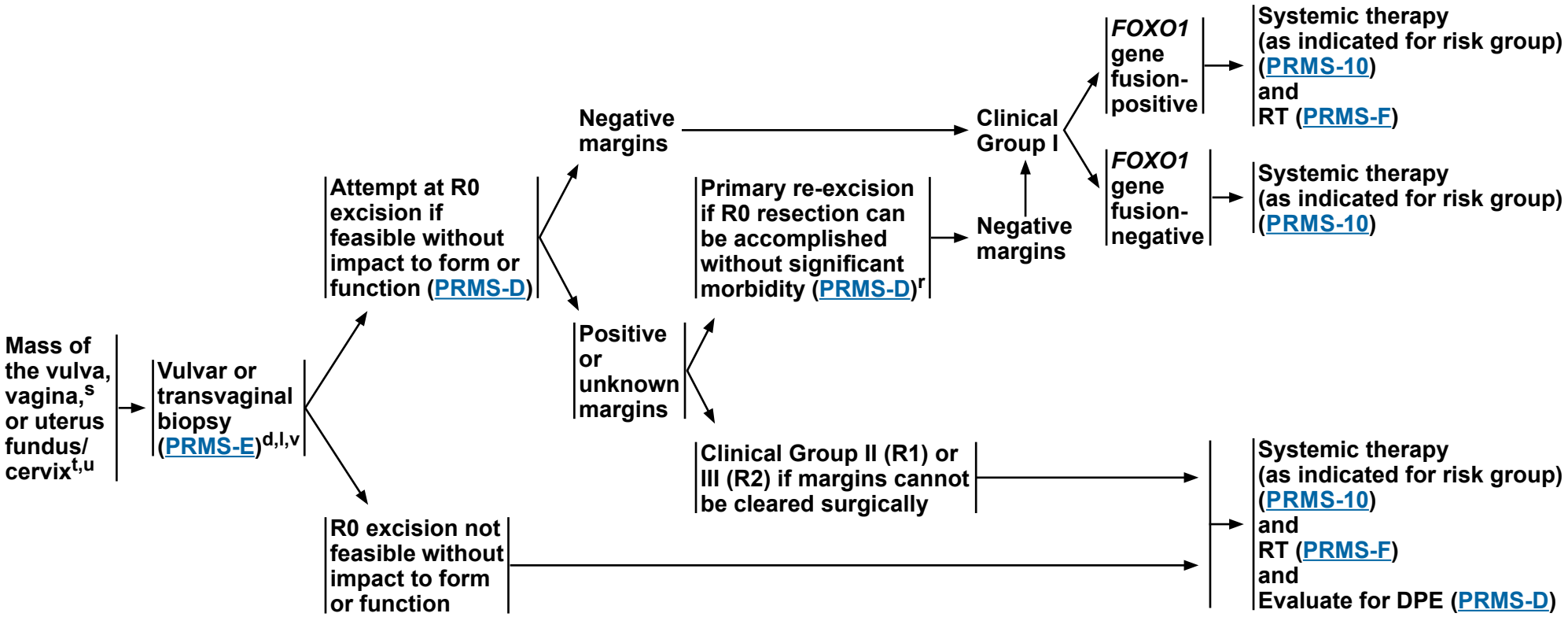


[d] Principles of Pathologic Assessment.
[l] Adequate biopsy is required and should provide sufficient tissue to establish the diagnosis and for further molecular genetic analysis.
[r] If there is suspicion or knowledge of residual tumor after the initial resection, PRE should be employed unless this would result in loss of form or function.
[s] Initial radical surgery is not indicated for some genitourinary RMS sites (ie, vulva, vagina). Conservative surgical intervention for vaginal RMS, with primary chemotherapy and RT [external beam RT (EBRT) or brachytherapy] for Group II or III disease, results in excellent 5-year survival rates. See Principles of Surgery.
[t] Initial radical hysterectomy may be considered for patients who do not desire future fertility after shared decision-making with their treating team. For patients who desire future fertility, recommend biopsy followed by local control with attempts at preserving fertility. Lautz TB, et al. Pediatr Blood Cancer 2023;70:e28601. See Principles of Surgery and Principles of Survivorship.
[u] Walterhouse DO, et al. Pediatr Blood Cancer 2011;57:76-83; Minard-Colin V, et al. Pediatr Blood Cancer 2018;65:e27096.
[v] Definitive local control can often be achieved by chemotherapy alone.

**Note: All recommendations are category 2A unless otherwise indicated.**



Version 1.2026, 02/017/2026 © 2026 National Comprehensive Cancer Network® (NCCN®), All rights reserved. NCCN Guidelines® and this illustration may not be reproduced in any form without the express written permission of NCCN.

PLEASE NOTE that use of this NCCN Content is governed by the End-User License Agreement, and you MAY NOT distribute this Content or use it with any artificial intelligence model or tool.
Printed by A. S. M. FAZLUL KARIM CHOWDHURY on 4/20/2026 3:39:07 AM. Copyright © 2026 National Comprehensive Cancer Network, Inc. All Rights Reserved.



## PARATESTICULAR MASS

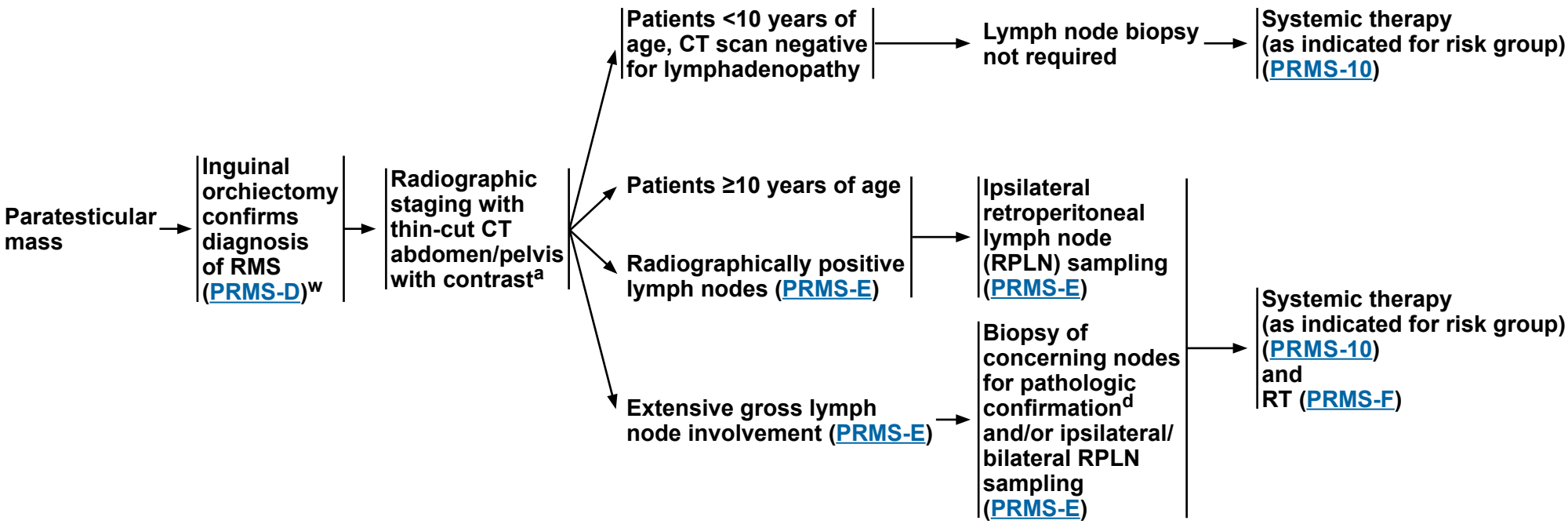


[a] Principles of Imaging.
[d] Principles of Pathologic Assessment.
[w] An inguinal approach and proximal spermatic cord control is required. Open biopsy or tumor spillage of any kind (as from a hydrocele) should be avoided since inguinal recurrence may follow. If biopsy is felt to be necessary prior to orchiectomy, then atraumatic high spermatic cord control should be performed, and the mobilized testis and cord should be completely isolated from the field while awaiting frozen section report. Any unprotected spillage should be considered Clinical Group IIa.

**Note: All recommendations are category 2A unless otherwise indicated.**



Version 1.2026, 02/017/2026 © 2026 National Comprehensive Cancer Network® (NCCN®), All rights reserved. NCCN Guidelines® and this illustration may not be reproduced in any form without the express written permission of NCCN.

PLEASE NOTE that use of this NCCN Content is governed by the End-User License Agreement, and you MAY NOT distribute this Content or use it with any artificial intelligence model or tool.
Printed by A. S. M. FAZLUL KARIM CHOWDHURY on 4/20/2026 3:39:07 AM. Copyright © 2026 National Comprehensive Cancer Network, Inc. All Rights Reserved.



## BLADDER OR PROSTATE MASS

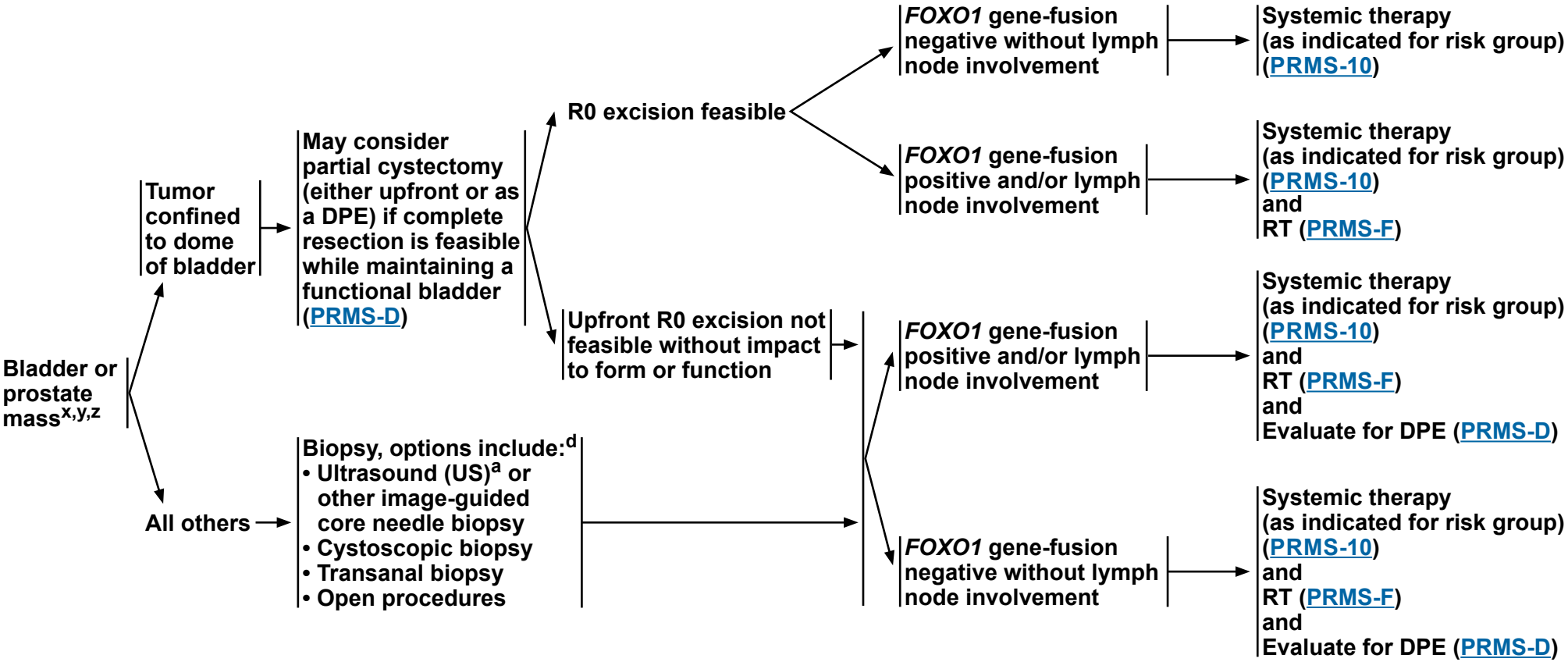


[a] Principles of Imaging.
[d] Principles of Pathologic Assessment.
[x] Bladder preservation is a major goal of therapy for patients with tumors arising in the bladder and/or prostate.
[y] It is uncommon that the primary tumor can be completely removed at presentation with preservation of bladder and urethral function. The initial operative procedure usually consists of a biopsy, which can be performed endoscopically, perineally, suprapubically, or through percutaneous core needle biopsy, but in rare cases may be by laparotomy or laparoscopy.
[z] Hays DM, et al. J Pediatr Hematol Oncol 1995;17:46-52; Lobe TE, et al. J Pediatr Surg 1996;31:1084-1087; Lautz TB, et al. Cancer 2021;127:275-283.

**Note: All recommendations are category 2A unless otherwise indicated.**



Version 1.2026, 02/017/2026 © 2026 National Comprehensive Cancer Network® (NCCN®), All rights reserved. NCCN Guidelines® and this illustration may not be reproduced in any form without the express written permission of NCCN.

PLEASE NOTE that use of this NCCN Content is governed by the End-User License Agreement, and you MAY NOT distribute this Content or use it with any artificial intelligence model or tool.
Printed by A. S. M. FAZLUL KARIM CHOWDHURY on 4/20/2026 3:39:07 AM. Copyright © 2026 National Comprehensive Cancer Network, Inc. All Rights Reserved.



## BILIARY/LIVER MASS

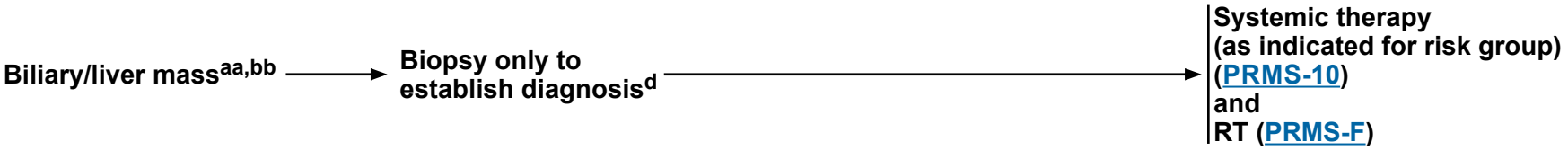


[d] Principles of Pathologic Assessment.
[aa] Tumors at this site respond relatively well with multimodal therapy without aggressive surgery. The primary role of surgery is for diagnosis and staging.
[bb] Biliary obstruction typically improves with chemotherapy. Therefore, invasive surgery to establish bile drainage is typically not necessary.

**Note: All recommendations are category 2A unless otherwise indicated.**



Version 1.2026, 02/017/2026 © 2026 National Comprehensive Cancer Network® (NCCN®), All rights reserved. NCCN Guidelines® and this illustration may not be reproduced in any form without the express written permission of NCCN.

PLEASE NOTE that use of this NCCN Content is governed by the End-User License Agreement, and you MAY NOT distribute this Content or use it with any artificial intelligence model or tool.
Printed by A. S. M. FAZLUL KARIM CHOWDHURY on 4/20/2026 3:39:07 AM. Copyright © 2026 National Comprehensive Cancer Network, Inc. All Rights Reserved.



**DIAGNOSIS** | **RISK STRATIFICATION[cc]**

**RMS**

**Very-low-risk**
- Stage 1, Group I, <10 y of age, tumor size ≤5 cm, *FOXO1* gene-fusion negative

**Low-risk**
- Stage 1, Group I–II, any age, *FOXO1* gene-fusion negative
- Stage 1, Group III (orbital), any age, *FOXO1* gene-fusion negative
- Stage 2, Group I–II, any age, *FOXO1* gene-fusion negative

→ PRMS-11

**Intermediate-risk**
- Stage 1, Group III (non-orbit), any age, *FOXO1* gene-fusion negative
- Stage 3, Group I–II, any age, *FOXO1* gene-fusion negative
- Stage 2–3, Group III, any age, *FOXO1* gene-fusion negative
- Stage 1–3, Group I–III, any age, *FOXO1* gene-fusion positive
- Stage 4, Group IV, <10 y of age, *FOXO1* gene-fusion negative

→ PRMS-12

**High-risk**
- Stage 4, Group IV, any age, *FOXO1* gene-fusion positive
- Stage 4, Group IV, ≥10 y of age, *FOXO1* gene-fusion negative

→ PRMS-13

[cc] Staging and Clinical Group Tables on ST-1.

**Note: All recommendations are category 2A unless otherwise indicated.**



Version 1.2026, 02/017/2026 © 2026 National Comprehensive Cancer Network® (NCCN®), All rights reserved. NCCN Guidelines® and this illustration may not be reproduced in any form without the express written permission of NCCN.

PLEASE NOTE that use of this NCCN Content is governed by the End-User License Agreement, and you MAY NOT distribute this Content or use it with any artificial intelligence model or tool.
Printed by A. S. M. FAZLUL KARIM CHOWDHURY on 4/20/2026 3:39:07 AM. Copyright © 2026 National Comprehensive Cancer Network, Inc. All Rights Reserved.



**VERY-LOW-RISK/LOW-RISK RMS** **TREATMENT[a]**

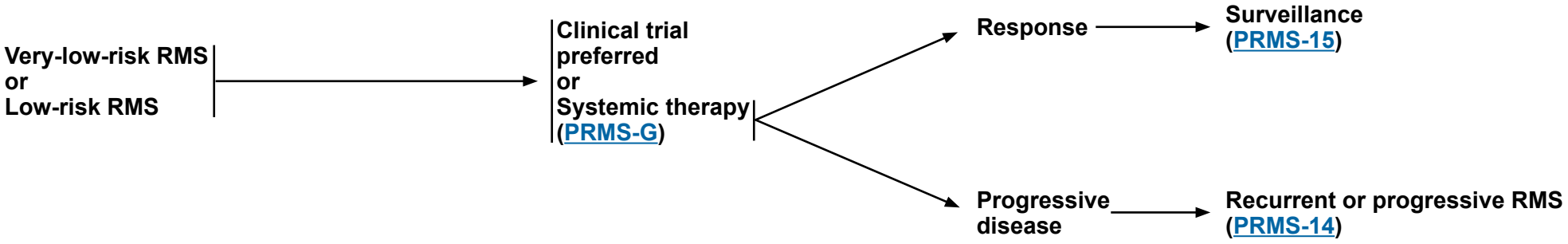


[a] Principles of Imaging.

**Note: All recommendations are category 2A unless otherwise indicated.**



Version 1.2026, 02/017/2026 © 2026 National Comprehensive Cancer Network® (NCCN®), All rights reserved. NCCN Guidelines® and this illustration may not be reproduced in any form without the express written permission of NCCN.

PLEASE NOTE that use of this NCCN Content is governed by the End-User License Agreement, and you MAY NOT distribute this Content or use it with any artificial intelligence model or tool.
Printed by A. S. M. FAZLUL KARIM CHOWDHURY on 4/20/2026 3:39:07 AM. Copyright © 2026 National Comprehensive Cancer Network, Inc. All Rights Reserved.



## INTERMEDIATE-RISK RMS TREATMENT[a]

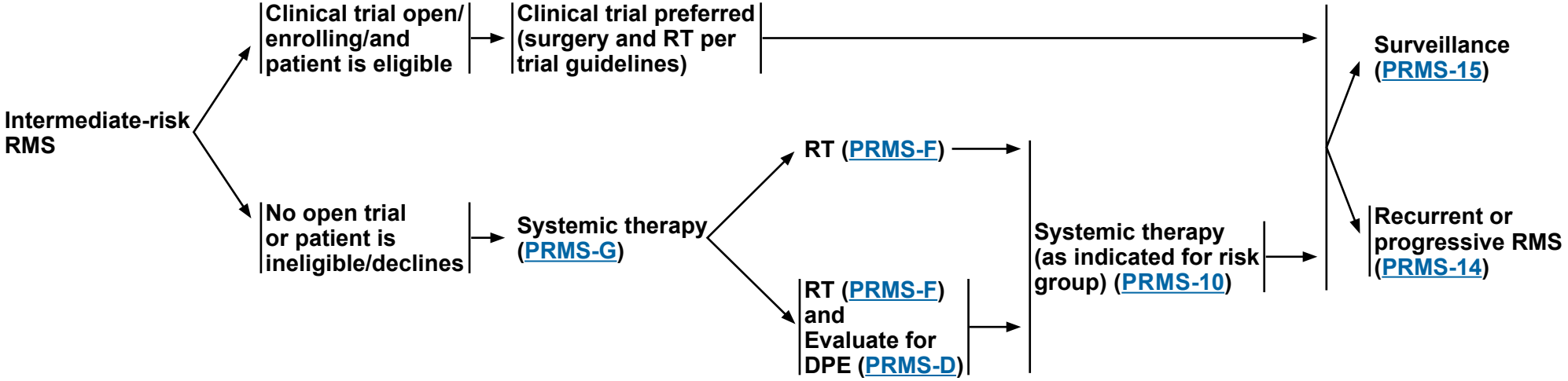


[a] Principles of Imaging.

**Note: All recommendations are category 2A unless otherwise indicated.**



Version 1.2026, 02/017/2026 © 2026 National Comprehensive Cancer Network® (NCCN®), All rights reserved. NCCN Guidelines® and this illustration may not be reproduced in any form without the express written permission of NCCN.

PLEASE NOTE that use of this NCCN Content is governed by the End-User License Agreement, and you MAY NOT distribute this Content or use it with any artificial intelligence model or tool.
Printed by A. S. M. FAZLUL KARIM CHOWDHURY on 4/20/2026 3:39:07 AM. Copyright © 2026 National Comprehensive Cancer Network, Inc. All Rights Reserved.



**HIGH-RISK RMS** **TREATMENT[a]**

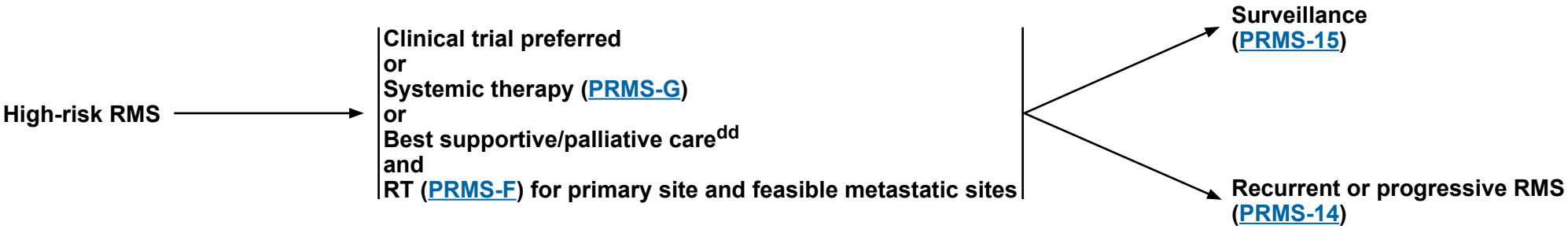


[a] Principles of Imaging.
[dd] If receiving best supportive/palliative care, follow-up (including imaging) should be tailored to the patient's clinical status.

**Note: All recommendations are category 2A unless otherwise indicated.**



Version 1.2026, 02/017/2026 © 2026 National Comprehensive Cancer Network® (NCCN®), All rights reserved. NCCN Guidelines® and this illustration may not be reproduced in any form without the express written permission of NCCN.

PLEASE NOTE that use of this NCCN Content is governed by the End-User License Agreement, and you MAY NOT distribute this Content or use it with any artificial intelligence model or tool.
Printed by A. S. M. FAZLUL KARIM CHOWDHURY on 4/20/2026 3:39:07 AM. Copyright © 2026 National Comprehensive Cancer Network, Inc. All Rights Reserved.



## RECURRENT OR PROGRESSIVE RMS

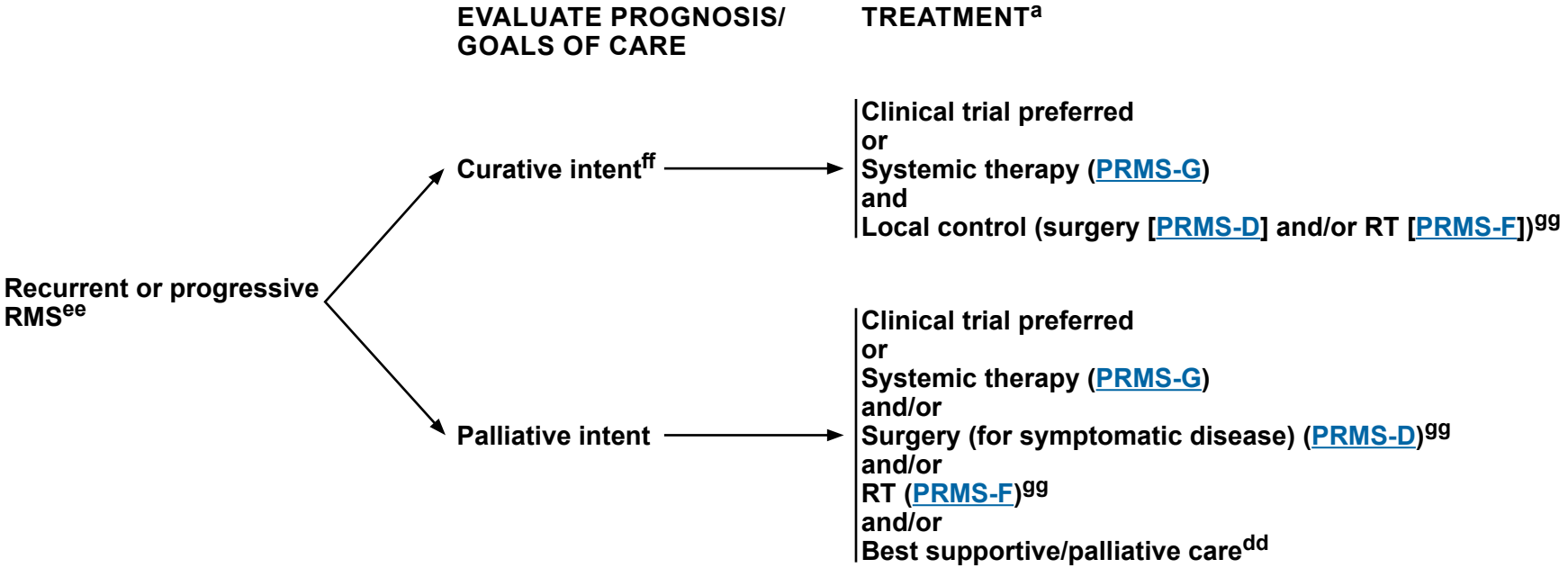


[a] Principles of Imaging.
[dd] If receiving best supportive/palliative care, follow-up (including imaging) should be tailored to the patient's clinical status.
[ee] Strongly recommend biopsy to confirm recurrence.
[ff] Consider for the minority of patients with local/regional recurrence, especially those with initially low-risk disease and those treated without RT in initial therapy.
[gg] If giving chemotherapy, consider 2–3 neoadjuvant cycles to assess response prior to local control.

**Note: All recommendations are category 2A unless otherwise indicated.**



Version 1.2026, 02/017/2026 © 2026 National Comprehensive Cancer Network® (NCCN®), All rights reserved. NCCN Guidelines® and this illustration may not be reproduced in any form without the express written permission of NCCN.

PLEASE NOTE that use of this NCCN Content is governed by the End-User License Agreement, and you MAY NOT distribute this Content or use it with any artificial intelligence model or tool.
Printed by A. S. M. FAZLUL KARIM CHOWDHURY on 4/20/2026 3:39:07 AM. Copyright © 2026 National Comprehensive Cancer Network, Inc. All Rights Reserved.



## SURVEILLANCE FOR PATIENTS WITH NO KNOWN ACTIVE DISEASE

- History and physical (H&P) every 3–6 mo for 2–3 y, then every 6–12 mo for years 4 and 5, then annually or as clinically indicated.
- Imaging:[a]
  - Primary site every 3–6 mo for 2–3 y, then every 6–12 mo for years 4 and 5, then annually or as clinically indicated.
  - Chest CT or chest x-ray every 3–6 mo for 2–3 y, then every 6–12 mo for years 4 and 5, then annually or as clinically indicated.
  - Include whole body FDG-PET imaging as clinically indicated.
- Follow off-treatment surveillance guidelines for patients treated on clinical trials.

→ Recurrent or progressive RMS → PRMS-14

[a] Principles of Imaging.

**Note: All recommendations are category 2A unless otherwise indicated.**



Version 1.2026, 02/017/2026 © 2026 National Comprehensive Cancer Network® (NCCN®), All rights reserved. NCCN Guidelines® and this illustration may not be reproduced in any form without the express written permission of NCCN.

PLEASE NOTE that use of this NCCN Content is governed by the End-User License Agreement, and you MAY NOT distribute this Content or use it with any artificial intelligence model or tool.
Printed by A. S. M. FAZLUL KARIM CHOWDHURY on 4/20/2026 3:39:07 AM. Copyright © 2026 National Comprehensive Cancer Network, Inc. All Rights Reserved.



## PRINCIPLES OF IMAGING[1-6]

| Imaging Modality Timing | |
|---|---|
| **Timing** | **Modality** |
| Initial Staging[a,b,c] | • MRI of primary site with and without contrast<br>• US (as clinically indicated)<br>• Chest CT (with contrast if the primary tumor is located in the hilar regions)[f]<br>• CT of primary site (as clinically indicated)[j]<br>• FDG-PET/CT or FDG-PET/MRI (whole body)<br>• Lymphoscintigraphy (as clinically indicated) |
| Localized Disease[d]<br>• Therapy period[e,f,g]<br>• Surveillance[g,h,i] (first 2 y off therapy) | • MRI of primary site with and without contrast<br>• CT with or without contrast (per institutional standards)<br>• FDG-PET/CT or FDG-PET/MRI (whole body) (as clinically indicated)<br>• Chest imaging:<br>▸ Chest CT (with contrast if the primary tumor is located in the hilar regions)[f] or chest x-ray[e] |
| Metastatic Disease<br>• Therapy period[e,f,g]<br>• Surveillance[g] (first 2 y off therapy) | • MRI of primary site with and without contrast<br>• Chest imaging<br>▸ For therapy period:<br>◊ Chest CT with contrast (preferred)<br>◊ FDG-PET/CT or FDG-PET/MRI (whole body) (as clinically indicated)<br>▸ For surveillance:<br>◊ Chest CT (with contrast if the primary tumor is located in the hilar regions)[f] or chest x-ray[e] or<br>◊ FDG-PET/CT or FDG-PET/MRI (whole body) (as clinically indicated) |

[a] Perform imaging before biopsy to avoid interpretation difficulties related to inflammatory changes.
[b] Treatment should be performed as close as possible to initial imaging staging, and imaging may be repeated if there is an interval of longer than 4–8 weeks.
[c] Children's Oncology Group (COG) protocols recommend regional draining node sampling in tumors of the trunk and extremities. In addition, RPLN sampling is recommended for paratesticular tumors in patients >10 years. See Principles of Lymph Node Disease Assessment.
[d] In case of low-risk tumor(s) in localized disease, follow-up imaging may be prescribed less intensively with intervals of 6–12 months or as clinically indicated.
[e] Patients with negative chest CT or indeterminate pulmonary nodules at staging (one to four nodules <5 mm or one nodule measuring 5–10 mm) may be followed with chest x-ray.
[f] CT with contrast if there is any clinical concern for hilar adenopathy; otherwise noncontrast CT may be sufficient if radiologist determines CT of diagnostic quality.
[g] Involved sites should be followed with the same imaging modality used at baseline with intervals of 3–6 months, as a shared decision between physician, patient, and caregiver.
[h] Primary site MRI imaging may be repeated every 4–6 months.
[i] Chest x-ray may be obtained every 4–6 months; if any suspicious finding is noted, further assessment with chest CT is recommended.
[j] Initial staging CT of primary site is done only if it is a presurgical planning request (CT angiography [CTA]) or to assess cortical bone disease extent.

**Note: All recommendations are category 2A unless otherwise indicated.**

References



Version 1.2026, 02/017/2026 © 2026 National Comprehensive Cancer Network® (NCCN®), All rights reserved. NCCN Guidelines® and this illustration may not be reproduced in any form without the express written permission of NCCN.

PLEASE NOTE that use of this NCCN Content is governed by the End-User License Agreement, and you MAY NOT distribute this Content or use it with any artificial intelligence model or tool.
Printed by A. S. M. FAZLUL KARIM CHOWDHURY on 4/20/2026 3:39:07 AM. Copyright © 2026 National Comprehensive Cancer Network, Inc. All Rights Reserved.



## PRINCIPLES OF IMAGING[1-6]

**General Principles:**
- Imaging using x-ray, CT, FDG-PET/CT, FDG-PET/MRI, or lymphoscintigraphy should be used. Follow the as low as reasonably achievable (ALARA) and Image Gently Campaign principles.
- Motion artifact can often be mitigated by using advanced scanning and reconstruction techniques (eg, motion correction software). After considering these motion mitigation techniques, anesthesia should be used only if there is a possibility of obtaining a non-diagnostic scan. In addition, anesthesia time should be limited to the minimum reasonable time.
- Gadolinium and iodine-based contrast agents should be used carefully when kidney function is decreased or there is a possibility of pregnancy.

**MRI:**
- Benefits:
  - High soft tissue contrast providing details regarding tumor location and its boundaries with surrounding anatomic structures to be used in surgical or radiation planning and for prognostication.
  - No ionizing radiation.
- Limitations:
  - Relatively limited availability and expensive. Perform FDG-PET/MRI if available.
  - Long acquisition time and sensitive to patient motion.
  - May be contraindicated if certain metallic devices/foreign bodies are present.
  - Complications related to gadolinium (allergy, nephrogenic systemic fibrosis, and unknown effects of gadolinium deposition in brain and bones).
  - MRI may be limited in assessing areas near metal (eg, metal clips, prosthesis).
- Acquisition:
  - Field of view should include both primary tumor and lymphatic draining station.
  - Both pre- and post-contrast sequences are optimal.
    - Pre-contrast sequences: T1 fat saturation (FS), T1 turbo spin echo (TSE), T2 FS, and diffusion-weighted imaging (DWI) in the axial plane; short tau inversion recovery (STIR) and T1 TSE in the coronal plane; and T2 FS in the sagittal plane.
    - Post-contrast: T1 FS in at least 2 planes.
  - Similar scanner, coils, and protocol should be used across multiple examinations in the same patients when possible.
  - Advanced techniques may be used to reduce scan time (eg, parallel imaging, radial k-space sampling).
  - Radiologist may modify imaging protocol according to specific clinical needs.

**Ultrasound:**
- Operator-dependent.
- Can complement but should not replace MRI.
- Is often the first imaging modality used in the assessment of soft tissue lesions due to the lack of ionizing radiation and easy accessibility.
- May provide additional information (eg, mass characterization cystic/solid/vascular) for small or superficial lesions or a paratesticular location.

**Note: All recommendations are category 2A unless otherwise indicated.**

References



Version 1.2026, 02/017/2026 © 2026 National Comprehensive Cancer Network® (NCCN®), All rights reserved. NCCN Guidelines® and this illustration may not be reproduced in any form without the express written permission of NCCN.

PLEASE NOTE that use of this NCCN Content is governed by the End-User License Agreement, and you MAY NOT distribute this Content or use it with any artificial intelligence model or tool.
Printed by A. S. M. FAZLUL KARIM CHOWDHURY on 4/20/2026 3:39:07 AM. Copyright © 2026 National Comprehensive Cancer Network, Inc. All Rights Reserved.



## PRINCIPLES OF IMAGING[1-6]

**Chest X-Ray:**
- Widely available, low ionizing radiation.
- Should be obtained in 2 views (posteroanterior and lateral).
- Sensitivity in detection of lung nodules is limited.
- Suspicious findings should be investigated with CT.

**CT:**
- Chest CT is ideal for assessment of pulmonary metastasis.
- Contrast-enhanced CT of the primary site may be warranted when MRI is contraindicated or in addition to MRI for the assessment of cortical bone involvement.
- CT angiography (CTA) may be necessary for surgical planning to evaluate specific vascular landmarks.
- Images should be reconstructed with a slice thickness of <5 mm (optimally 1 mm) and lung filter; maximum intensity projection (MIP) may help detect solid pulmonary nodules; coronal and sagittal reconstructions should also be carefully inspected.

**18-F FDG (Fluorodeoxyglucose) FDG-PET with CT or MRI for Attenuation Correction and Anatomic Localization:**
- Scan should be whole body acquisition, using pediatric FDG dose adjustment per institution protocol.
- Advanced techniques may be used to reduce scan time (eg, use of long axial field of view scanners when available).
- FDG-PET/CT or FDG-PET/MRI can be used for assessing primary tumor (may guide biopsy by visualization of areas with prominent metabolic activity), in-transit metastasis, and local and distal lymph nodes and metastases.
- FDG-PET/CT or FDG-PET/MRI may visualize bone lesions; however, when bone marrow evaluation is indicated it should not replace bone marrow aspirates and biopsies at staging.
- Given the high prevalence of high brown fat in the pediatric population, consider mitigation plans including warm blanket or pharmacologic means (eg, propranolol, diazepam).

**Lymphoscintigraphy:**
- Noninvasive scintigraphic assessment can be obtained with technetium-99m (Tc-99m) tilmanocept or Tc-99m filtered sulfur colloid.
- Single-photon emission CT (SPECT)/CT to improve anatomic localization may be performed.
- Addition of intraoperative methylene blue improves assessment of sentinel lymph nodes.

**Note: All recommendations are category 2A unless otherwise indicated.**

References



Version 1.2026, 02/017/2026 © 2026 National Comprehensive Cancer Network® (NCCN®), All rights reserved. NCCN Guidelines® and this illustration may not be reproduced in any form without the express written permission of NCCN.

PLEASE NOTE that use of this NCCN Content is governed by the End-User License Agreement, and you MAY NOT distribute this Content or use it with any artificial intelligence model or tool.
Printed by A. S. M. FAZLUL KARIM CHOWDHURY on 4/20/2026 3:39:07 AM. Copyright © 2026 National Comprehensive Cancer Network, Inc. All Rights Reserved.



## PRINCIPLES OF IMAGING
## REFERENCES

[1] Schoot RA, van Ewijk R, von Witzleben AA, et al. INternational Soft Tissue saRcoma ConsorTium (INSTRuCT) consensus statement: Imaging recommendations for the management of rhabdomyosarcoma. Eur J Radiol 2023;166:111012. Erratum in: Eur J Radiol 2023;168:111108.
[2] Vaarwerk B, Bisogno G, McHugh K, et al. Indeterminate pulmonary nodules at diagnosis in rhabdomyosarcoma: Are they clinically significant? A report from the European Paediatric Soft Tissue Sarcoma Study Group. J Clin Oncol 2019;37:723-730.
[3] Tateishi U, Hosono A, Makimoto A, et al. Comparative study of FDG PET/CT and conventional imaging in the staging of rhabdomyosarcoma. Ann Nucl Med 2009;23:155-161.
[4] McLean-Thomas L, Gao D, Trenbeath Z, et al. Equivocal end-of-therapy imaging findings do not predict a higher risk of local relapse after definitive radiotherapy in pediatric Ewing sarcoma and rhabdomyosarcoma. Pediatr Blood Cancer 2023;70:e29989.
[5] van Ewijk R, Chatziantoniou C, Adams M, et al. Quantitative diffusion-weighted MRI response assessment in rhabdomyosarcoma: an international retrospective study on behalf of the European paediatric Soft tissue sarcoma Study Group Imaging Committee. Pediatr Radiol 2023;53:2539-2551.
[6] Fetzko S, Fonseca A, Frances Wedekind M, et al. Is detection of relapse by surveillance imaging associated with longer survival in patients with rhabdomyosarcoma? J Pediatr Hematol Oncol 2022;44:305-312.

**Note: All recommendations are category 2A unless otherwise indicated.**



Version 1.2026, 02/017/2026 © 2026 National Comprehensive Cancer Network® (NCCN®), All rights reserved. NCCN Guidelines® and this illustration may not be reproduced in any form without the express written permission of NCCN.

PLEASE NOTE that use of this NCCN Content is governed by the End-User License Agreement, and you MAY NOT distribute this Content or use it with any artificial intelligence model or tool.
Printed by A. S. M. FAZLUL KARIM CHOWDHURY on 4/20/2026 3:39:07 AM. Copyright © 2026 National Comprehensive Cancer Network, Inc. All Rights Reserved.



## PRINCIPLES OF PATHOLOGIC ASSESSMENT

**Pathologic Assessment**

- It is essential to ensure that pathology workflows are structured to integrate histologic diagnosis, prognostic classification, and molecular profiling as needed for treatment purposes.
- Specimens obtained for tissue diagnosis must serve multiple objectives:
  - Establish the diagnosis.
  - Recognize features that determine prognosis and/or influence treatment.
  - Detect any features of underlying genetic syndromes.
  - Store materials for future patient care needs, tumor banking, research, or clinical trial enrollment.
- Tissue sample consideration for primary diagnosis (tumor or metastasis):[1-3]
  - Surgical resection if clinically indicated.
  - Incisional biopsy: >1 $cm^3$.
  - Tissue cores: at least 10 cores, ideally 20–30 mm in length obtained using a 16-gauge needle.
- A coordinated diagnostic sampling effort including pathologists, oncologists, surgeons, and radiologists is recommended.[2-3]
- The pathologic assessment should include evaluation of the following features, all of which should be specifically addressed in the pathology report:
  - Histologic subtype
  - Presence or absence of anaplasia
  - Therapy effect (if applicable)
  - Status of margins of excision
  - Status of lymph nodes (if available for examination) (incisional biopsy preferred) (See Principles of Lymph Node Disease Assessment)
  - Distant metastasis (if available for examination)
  - Stage (see ST-1)
  - Results of ancillary studies
- Histologic classification:
  - The International Classification of Rhabdomyosarcoma categorizes childhood RMS into histologic types that have prognostic relevance. Nonetheless, research indicates that the *FOXO1* fusion status is a stronger predictor of negative outcomes in children with RMS, making histologic classification less crucial for prognosis and risk assessment. Despite this, a consistent and accurate classification of histologic subtype remains significant for its broad applications.[4-6]
  - The current World Health Organization (WHO) classification for soft tissue and bone tumors recognizes 4 distinct subtypes of RMS:[7]
    - Embryonal
    - Alveolar
    - Spindle cell/sclerosing
    - Pleomorphic (more common in adults; most pleomorphic RMS in children are anaplastic embryonal RMS [ERMS]).

**Note: All recommendations are category 2A unless otherwise indicated.**

References



Version 1.2026, 02/017/2026 © 2026 National Comprehensive Cancer Network® (NCCN®), All rights reserved. NCCN Guidelines® and this illustration may not be reproduced in any form without the express written permission of NCCN.

PLEASE NOTE that use of this NCCN Content is governed by the End-User License Agreement, and you MAY NOT distribute this Content or use it with any artificial intelligence model or tool.
Printed by A. S. M. FAZLUL KARIM CHOWDHURY on 4/20/2026 3:39:07 AM. Copyright © 2026 National Comprehensive Cancer Network, Inc. All Rights Reserved.



## PRINCIPLES OF PATHOLOGIC ASSESSMENT
## REFERENCES

[1] Black JO, Al-Ibraheemi A, Arnold MA, et al. The pathologic diagnosis of pediatric soft tissue tumors in the era of molecular medicine: The Sarcoma Pediatric Pathology Research Interest Group perspective. Arch Pathol Lab Med 2024;148:107-116.
[2] Pinches RS, Clinton CM, Ward A, et al. Making the most of small samples: Optimization of tissue allocation of pediatric solid tumors for clinical and research use. Pediatr Blood Cancer 2020;67:e28326.
[3] Fisch AS, Church AJ. Special considerations in the molecular diagnostics of pediatric neoplasms. Clin Lab Med 2022;42:349-365.
[4] Coffin CM. The new International Rhabdomyosarcoma Classification, its progenitors, and consideration beyond morphology. Adv Anat Pathol 1997;4:1-16.
[5] Missiaglia E, Williamson D, Chisholm J, et al. PAX3/FOXO1 fusion gene status is the key prognostic molecular marker in rhabdomyosarcoma and significantly improves current risk stratification. J Clin Oncol 2012;30:1670-1677.
[6] Skapek SX, Anderson J, Barr FG, et al. PAX-FOXO1 fusion status drives unfavorable outcome for children with rhabdomyosarcoma: a children's oncology group report. Pediatr Blood Cancer 2013;60:1411-1417.
[7] WHO Classification of Tumours Editorial Board. Soft tissue and bone tumours [Internet]. Lyon (France): International Agency for Research on Cancer; 2020 [cited 2025 January 28]. (WHO classification of tumours series, 5th ed.; vol. 3). Available at: https://tumourclassification.iarc.who.int/chapters/33.

**Note: All recommendations are category 2A unless otherwise indicated.**



Version 1.2026, 02/017/2026 © 2026 National Comprehensive Cancer Network® (NCCN®), All rights reserved. NCCN Guidelines® and this illustration may not be reproduced in any form without the express written permission of NCCN.

PLEASE NOTE that use of this NCCN Content is governed by the End-User License Agreement, and you MAY NOT distribute this Content or use it with any artificial intelligence model or tool.
Printed by A. S. M. FAZLUL KARIM CHOWDHURY on 4/20/2026 3:39:07 AM. Copyright © 2026 National Comprehensive Cancer Network, Inc. All Rights Reserved.



## PRINCIPLES OF ANCILLARY TECHNIQUES USEFUL IN THE DIAGNOSIS OF RMS

- The diagnosis of RMS requires a combination of morphologic features combined with ancillary testing:
  - Hematoxylin and eosin stain.
  - Immunohistochemistry (IHC) stains: Desmin, myogenin, MYOD1.
    - Staining pattern for myogenin can help in subtyping RMS (eg, diffuse staining is typical for alveolar subtype).
    - Additional IHC stains may also be useful in confirming the subtype, including AP-2 beta, HMGA2, P-cadherin, and EGFR.[1,2]

- Molecular Genetic Testing Considerations:
  - The diagnosis of RMS has undergone significant evolution over the past decade. We now recognize that morphology is shaped by underlying molecular alterations.
    - Recurring genetic or molecular alterations are listed in Table 1.
  - Methods/technique:[a,3]
    - Conventional karyotyping.
    - Fluorescence in situ hybridization (FISH).
    - Reverse transcriptase polymerase chain reaction (RT-PCR).
    - Next-generation sequencing (NGS).
  - The choice of the most suitable technique depends on the specific tumor characteristics and clinical requirements. NGS could be advantageous, but the timing and suitability of NGS should be assessed on a case-by-case basis. NGS results can help determine if a patient is eligible for clinical trials, identify actionable mutations that were not previously targeted, select candidates who might benefit from immunotherapy, and identify inherited germline variants associated with developing RMS. Each molecular testing method has its limitations and potential for false-negative results. If negative results occur when a molecular aberration was clinically anticipated, it is advisable to consult with the testing laboratory, as retesting using a different method may be warranted.
    - *FOXO1* status should be assessed molecularly. FISH for *FOXO1* is sufficient.

[a] Molecular genetic analysis involves highly complex test methods. None of the methods are absolutely sensitive or provide results that are absolutely specific; test results must always be interpreted in the context of the clinical and pathologic features of the case. Testing should therefore be carried out by a pathologist with expertise in sarcoma diagnosis and molecular diagnostic techniques.

**Note: All recommendations are category 2A unless otherwise indicated.**

References



Version 1.2026, 02/017/2026 © 2026 National Comprehensive Cancer Network® (NCCN®), All rights reserved. NCCN Guidelines® and this illustration may not be reproduced in any form without the express written permission of NCCN.

PLEASE NOTE that use of this NCCN Content is governed by the End-User License Agreement, and you MAY NOT distribute this Content or use it with any artificial intelligence model or tool.
Printed by A. S. M. FAZLUL KARIM CHOWDHURY on 4/20/2026 3:39:07 AM. Copyright © 2026 National Comprehensive Cancer Network, Inc. All Rights Reserved.



## PRINCIPLES OF ANCILLARY TECHNIQUES USEFUL IN THE DIAGNOSIS OF RMS

**Table 1: Molecular Alterations in Rhabdomyosarcoma[4,5]**

| Tumor | Aberration | Gene(s) Involved |
|---|---|---|
| **Malignant Round Cell Tumors** | | |
| Gene Fusion-Negative RMS[b,6-9] | Complex alterations<br><br>Aneuploidy, often featuring whole chromosome gains of 8, 2, 11, 12, 13, and/or 20, along with frequent losses of chromosomes 10 and 15, loss of 3q | Mutations involve the RAS pathway (including *NRAS, KRAS, HRAS, NF1*)[16-18]<br><br>*FGFR4* copy gain[16,17]<br><br>*TP53* mutations, identified in approximately 10% of ERMS cases[c] |
| Gene Fusion-Positive RMS[9-12] | t(2;13)(q35;q14)[c]<br>t(1;13)(p36;q14)[c]<br>t(X;2)(q13;q35)[c]<br><15% fusion-negative<br><br>Amplifications of 2p24 and 12q13–q14[c] | *PAX3::FOXO1*[19]<br>*PAX7::FOXO1*<br>*PAX3::AFX*<br><br>Other PAX fusions:<br>*PAX3::INO80D, PAX3::NCOA2, PAX3::NCOA1*<br><br>*MYCN* and *CDK4*<br><br>Rarely associated with *TP53* mutations (<4%)[c] |
| **Spindle Cell/Sclerosing RMS (SCRMS)** | | |
| *MYOD1*-mutated SCRMS[13,14] | *MYOD1* p.L122R | *MYOD1*[18] |
| Infantile/Congenital SCRMS[15,16] | t(6;6)(q22.1;q24.1)<br>t(6;8)(q22.1;q13.3)<br>t(8;11)(q13.3;p15.3)<br>t(3;22)(q13.2;p12.1) | *VGLL2::CITED2*[20,21]<br>*VGLL2::NCOA2*[20-22]<br>*TEAD1::NCOA2*[22]<br>*EP300::VGLL3* |
| Well-Differentiated SCRMS | t(6;13)(p21.1;q14.11)<br>t(6;8)(p21.1;p13.3) | *SRF::FOXO1*[23]<br>*SRF::NCOA2*[22,23] |
| Intraosseous SCRMS[12] | t(12;22)(q13.12;q12.2)<br>t(12;16)(q13.12;p11.2)<br>t(2;8)(p14;q13.3) | *EWSR1::TFCP2*[24-26]<br>*FUS::TFCP2*[24]<br>*MEIS1::NCOA2*[22,27] |

[b] ERMS is associated with multiple heritable syndromes. See Table 2 (PRMS-C 3 of 5).
[c] Associated with poor outcome.

**Note: All recommendations are category 2A unless otherwise indicated.**

References



Version 1.2026, 02/017/2026 © 2026 National Comprehensive Cancer Network® (NCCN®), All rights reserved. NCCN Guidelines® and this illustration may not be reproduced in any form without the express written permission of NCCN.

PLEASE NOTE that use of this NCCN Content is governed by the End-User License Agreement, and you MAY NOT distribute this Content or use it with any artificial intelligence model or tool.
Printed by A. S. M. FAZLUL KARIM CHOWDHURY on 4/20/2026 3:39:07 AM. Copyright © 2026 National Comprehensive Cancer Network, Inc. All Rights Reserved.



## PRINCIPLES OF ANCILLARY TECHNIQUES USEFUL IN THE DIAGNOSIS OF RMS

| Table 2: Heritable Syndromes Associated with ERMS | |
|---|---|
| **Syndrome** | **Associated Gene(s)** |
| Li-Fraumeni[28] | *TP53* |
| *DICER1*-related[29,30] tumor predisposition | *DICER1* |
| Neurofibromatosis type 1 | *NF1* |
| Costello | *HRAS* |
| Noonan (and Noonan syndrome with multiple lentigines)[31] | *PTPN11, SOS1, RAF1, RIT1* (also *KRAS, NRAS, BRAF, MAP2K1*) |
| Other RASopathies (including mosaicism)[32] | *KRAS, HRAS* |
| Beckwith-Wiedemann syndrome/spectrum[33] | *IGF2, CDKN1C, H19, KCNQ1OT1* |

**Note: All recommendations are category 2A unless otherwise indicated.**

References



Version 1.2026, 02/017/2026 © 2026 National Comprehensive Cancer Network® (NCCN®), All rights reserved. NCCN Guidelines® and this illustration may not be reproduced in any form without the express written permission of NCCN.

PLEASE NOTE that use of this NCCN Content is governed by the End-User License Agreement, and you MAY NOT distribute this Content or use it with any artificial intelligence model or tool.
Printed by A. S. M. FAZLUL KARIM CHOWDHURY on 4/20/2026 3:39:07 AM. Copyright © 2026 National Comprehensive Cancer Network, Inc. All Rights Reserved.



## PRINCIPLES OF ANCILLARY TECHNIQUES USEFUL IN THE DIAGNOSIS OF RMS
## REFERENCES

[1] Rudzinski ER, Anderson JR, Lyden ER, et al. Myogenin, AP2β, NOS-1, and HMGA2 are surrogate markers of fusion status in rhabdomyosarcoma: a report from the soft tissue sarcoma committee of the children's oncology group. Am J Surg Pathol 2014;38:654-659.
[2] Grass B, Wachtel M, Behnke S, Leuschner I, Niggli FK, Schäfer BW. Immunohistochemical detection of EGFR, fibrillin-2, P-cadherin and AP2beta as biomarkers for rhabdomyosarcoma diagnostics. Histopathology 2009;54:873-879.
[3] Black JO, Al-Ibraheemi A, Arnold MA, et al. The pathologic diagnosis of pediatric soft tissue tumors in the era of molecular medicine: The Sarcoma Pediatric Pathology Research Interest Group perspective. Arch Pathol Lab Med 2024;148:107-116.
[4] Weber-Hall S, Anderson J, McManus A, et al. Gains, losses, and amplification of genomic material in rhabdomyosarcoma analyzed by comparative genomic hybridization. Cancer Res 1996;56:3220-3224.
[5] Bridge JA, Liu J, Qualman SJ, et al. Genomic gains and losses are similar in genetic and histologic subsets of rhabdomyosarcoma, whereas amplification predominates in embryonal with anaplasia and alveolar subtypes. Genes Chromosomes Cancer 2002;33:310-321.
[6] Robbins KM, Stabley DL, Holbrook J, et al. Paternal uniparental disomy with segmental loss of heterozygosity of chromosome 11 are hallmark characteristics of syndromic and sporadic embryonal rhabdomyosarcoma. Am J Med Genet A 2016;170:3197-3206.
[7] Vicha A, Jencova P, Novakova-Kodetova D, et al. Changes on chromosome 11p15.5 as specific marker for embryonal rhabdomyosarcoma?. Genes Chromosomes Cancer 2023;62:732-739.
[8] Dehner CA, Bell RC, Cao Y, et al. Loss of chromosome 3q Is a prognostic marker in fusion-negative rhabdomyosarcoma. JCO Precis Oncol 2023;7:e2300037.
[9] Skapek SX, Ferrari A, Gupta AA, et al. Rhabdomyosarcoma. Nat Rev Dis Primers 2019;5:1.
[10] Barr FG, Smith LM, Lynch JC, et al. Examination of gene fusion status in archival samples of alveolar rhabdomyosarcoma entered on the Intergroup Rhabdomyosarcoma Study-III trial: a report from the Children's Oncology Group. J Mol Diagn 2006;8:202-208.
[11] Sorensen PH, Lynch JC, Qualman SJ, et al. PAX3-FKHR and PAX7-FKHR gene fusions are prognostic indicators in alveolar rhabdomyosarcoma: a report from the children's oncology group. J Clin Oncol 2002;20:2672-2679.
[12] Barr FG, Duan F, Smith LM, et al. Genomic and clinical analyses of 2p24 and 12q13-q14 amplification in alveolar rhabdomyosarcoma: a report from the Children's Oncology Group. Genes Chromosomes Cancer 2009;48:661-672.
[13] Agaram NP, LaQuaglia MP, Alaggio R, et al. MYOD1-mutant spindle cell and sclerosing rhabdomyosarcoma: an aggressive subtype irrespective of age. A reappraisal for molecular classification and risk stratification. Mod Pathol 2019;32:27-36.
[14] Van Antwerp ME, Chen DG, Chang C, Prochownik EV. A point mutation in the MyoD basic domain imparts c-Myc-like properties. Proc Natl Acad Sci U S A 1992;89:9010-9014.
[15] Lundgren L, Angervall L, Stenman G, Kindblom LG. Infantile rhabdomyofibrosarcoma: a high-grade sarcoma distinguishable from infantile fibrosarcoma and rhabdomyosarcoma. Hum Pathol 1993;24:785-795.
[16] Agaram NP. Evolving classification of rhabdomyosarcoma. Histopathology 2022;80:98-108.
[17] Shern JF, Chen L, Chmielecki J, et al. Comprehensive genomic analysis of rhabdomyosarcoma reveals a landscape of alterations affecting a common genetic axis in fusion-positive and fusion-negative tumors. Cancer Discov 2014;4:216-231.
[18] Shern JF, Selfe J, Izquierdo E, et al. Genomic classification and clinical outcome in rhabdomyosarcoma: A report from an international consortium. J Clin Oncol 2021;39:2859-2871.
[19] Missiaglia E, Williamson D, Chisholm J, et al. PAX3/FOXO1 fusion gene status is the key prognostic molecular marker in rhabdomyosarcoma and significantly improves current risk stratification. J Clin Oncol 2012;30:1670-1677.
[20] Alaggio R, Zhang L, Sung YS, et al. A molecular study of pediatric spindle and sclerosing rhabdomyosarcoma: Identification of novel and recurrent VGLL2-related fusions in infantile cases. Am J Surg Pathol 2016;40:224-235.
[21] Cyrta J, Gauthier A, Karanian M, et al. Infantile rhabdomyosarcomas with VGLL2 rearrangement are not always an indolent disease: a study of 4 aggressive cases with clinical, pathologic, molecular, and radiologic findings. Am J Surg Pathol 2021;45:854-867.
[22] Mosquera JM, Sboner A, Zhang L, et al. Recurrent NCOA2 gene rearrangements in congenital/infantile spindle cell rhabdomyosarcoma. Genes Chromosomes Cancer 2013;52:538-550.

**Note: All recommendations are category 2A unless otherwise indicated.**



Version 1.2026, 02/017/2026 © 2026 National Comprehensive Cancer Network® (NCCN®), All rights reserved. NCCN Guidelines® and this illustration may not be reproduced in any form without the express written permission of NCCN.

PLEASE NOTE that use of this NCCN Content is governed by the End-User License Agreement, and you MAY NOT distribute this Content or use it with any artificial intelligence model or tool.
Printed by A. S. M. FAZLUL KARIM CHOWDHURY on 4/20/2026 3:39:07 AM. Copyright © 2026 National Comprehensive Cancer Network, Inc. All Rights Reserved.



## PRINCIPLES OF ANCILLARY TECHNIQUES USEFUL IN THE DIAGNOSIS OF RMS
## REFERENCES

[23] Karanian M, Pissaloux D, Gomez-Brouchet A, et al. SRF-FOXO1 and SRF-NCOA1 fusion genes delineate a distinctive subset of well-differentiated rhabdomyosarcoma. Am J Surg Pathol 2020;44:607-616.
[24] Chrisinger JSA, Wehrli B, Dickson BC, et al. Epithelioid and spindle cell rhabdomyosarcoma with FUS-TFCP2 or EWSR1-TFCP2 fusion: report of two cases. Virchows Arch 2020;477:725-732.
[25] Le Loarer F, Cleven AHG, Bouvier C, et al. A subset of epithelioid and spindle cell rhabdomyosarcomas is associated with TFCP2 fusions and common ALK upregulation. Mod Pathol 2020;33:404-419.
[26] Koutlas IG, Olson DR, Rawwas J. FET(EWSR1)-TFCP2 rhabdomyosarcoma: an additional example of this aggressive variant with predilection for the gnathic bones. Head Neck Pathol 2021;15:374-380.
[27] Smith BF, Doung YC, Beckett B, et al. Intraosseous spindle cell rhabdomyosarcoma with MEIS1::NCOA2 fusion - case report with substantial clinical follow-up and review of the literature. Cancer Invest 2023;41:704-712.
[28] Achatz MI, Villani A, Bertuch AA, et al. Update on cancer screening recommendations for individuals with Li-Fraumeni Syndrome. Clin Cancer Res 2025;31:1831-1840.
[29] Doros L, Yang J, Dehner L, et al. DICER1 mutations in embryonal rhabdomyosarcomas from children with and without familial PPB-tumor predisposition syndrome. Pediatr Blood Cancer 2012;59:558-560.
[30] Schultz KAP, MacFarland SP, Perrino MR, et al. Update on pediatric surveillance recommendations for PTEN hamartoma tumor syndrome, DICER1-related tumor predisposition, and tuberous sclerosis complex. Clin Cancer Res 2025;31:234-244.
[31] Perrino MR, Das A, Scollon SR, et al. Update on pediatric cancer surveillance recommendations for patients with neurofibromatosis type 1, Noonan syndrome, CBL syndrome, Costello syndrome, and related RASopathies. Clin Cancer Res 2024;30:4834-4843.
[32] Windrich J, Ney GM, Rosenberg PS, et al. Cancer in multilineage mosaic RASopathies due to pathogenic variants in HRAS or KRAS: A systematic review and meta-analysis. Clin Cancer Res 2024;30:5116-5121.
[33] Kalish JM, Becktell KD, Bougeard G, et al. Update on surveillance for Wilms tumor and hepatoblastoma in Beckwith-Wiedemann syndrome and other predisposition syndromes. Clin Cancer Res 2024;30:5260-5269.

**Note: All recommendations are category 2A unless otherwise indicated.**



Version 1.2026, 02/017/2026 © 2026 National Comprehensive Cancer Network® (NCCN®), All rights reserved. NCCN Guidelines® and this illustration may not be reproduced in any form without the express written permission of NCCN.

PLEASE NOTE that use of this NCCN Content is governed by the End-User License Agreement, and you MAY NOT distribute this Content or use it with any artificial intelligence model or tool.
Printed by A. S. M. FAZLUL KARIM CHOWDHURY on 4/20/2026 3:39:07 AM. Copyright © 2026 National Comprehensive Cancer Network, Inc. All Rights Reserved.



## PRINCIPLES OF SURGERY

### General Principles

- Local control with either primary tumor excision or RT of the primary tumor is a cornerstone of management in RMS. Thus, the approach to comprehensive care of these patients requires multidisciplinary discussion inclusive of oncologists, surgeons, and radiation oncologists.
- The basic principles of wide and complete resection of the primary tumor with a surrounding envelope of normal tissue should be followed at the initial and/or subsequent operations wherever possible and reasonable. Adequate margins of uninvolved tissue are required unless this involves sacrifice of normal tissue that either cannot be resected or would result in an unacceptable loss of function or is not technically feasible.
- Surgical excision should not be performed unless an R0 resection is believed to be possible without significant loss of form or function. While subjective, this should be discussed on a case-by-case basis and both short- and long-term complications and quality-of-life measures should be weighed while incorporating the patient's expectations, risk tolerance, and preferences. Generally unacceptable morbidity includes orbital exenteration, major excisions of the face, extremity amputation, rendering an extremity useless, major organ resection (bladder/prostate resection, pneumonectomy), pelvic exenteration, or resection requiring permanent stool/urinary diversion.
- The initial surgical procedure (a biopsy or excision as employed for benign tumor) may have been performed prior to establishing the diagnosis and may result in a situation in which there is: 1) gross residual tumor; 2) microscopically involved margins; or 3) uncertainty as to margins or residual tumor. Under these circumstances, the concept of PRE is advisable and should be applied wherever feasible, unless the resulting disability is considered unacceptable. This means wide re-excision of the previous operative site, including an adequate "envelope" of normal tissue, with careful marking and examination of all margins. Clinical Group assignment will be determined on the basis of pathology from the definitive operation prior to the start of multimodal therapy.
  - Outcomes for patients with Group I status, including when PRE is performed, are superior to outcomes of patients with Group II or III status, even with DPE with consideration of maintaining form and function.
- Debulking procedures do not improve outcomes and thus are not considered as part of surgical therapy.
- It is unclear what role excision of the biopsy tract has on outcome in RMS specifically. However, there are data to suggest that tumor cells can seed the biopsy tract and that this risk is higher in open biopsy tracts. Therefore, the biopsy tract should be excised if able. This consideration is greater in open tracts versus percutaneous approaches.
- All specimens should be oriented for pathology to determine margins. Narrow margins may be unavoidable in some sites such as in the head and neck. In these situations, the surgeon should take separate biopsies of the "normal" tissue around the margins of the resection cavity, and submit these separately for pathologic review.
- The surgical bed should be marked for potential future RT.
- In patients who did not undergo resection but have a residual mass following definitive chemotherapy and definitive RT, excision is not recommended.

### Biopsy

- Tumors in the head, neck, orbit, parameningeal, or some genitourinary sites (ie, vulva, vagina) are frequently not amenable to primary excision (excisional biopsy). These tumors should undergo biopsy only (incisional or core needle).
- Both open incisional biopsy and image-guided core needle (tru-cut) biopsies are appropriate.
- Endoscopic biopsies are appropriate for bladder, prostate, or vaginal tumors.
- Biopsy should provide enough tissue for histologic subtyping, fusion status, IHC, NGS, fusion testing, and, where possible, tissue for biobanking. See Principles of Pathologic Assessment.

**Note: All recommendations are category 2A unless otherwise indicated.**



Version 1.2026, 02/017/2026 © 2026 National Comprehensive Cancer Network® (NCCN®), All rights reserved. NCCN Guidelines® and this illustration may not be reproduced in any form without the express written permission of NCCN.

PLEASE NOTE that use of this NCCN Content is governed by the End-User License Agreement, and you MAY NOT distribute this Content or use it with any artificial intelligence model or tool.
Printed by A. S. M. FAZLUL KARIM CHOWDHURY on 4/20/2026 3:39:07 AM. Copyright © 2026 National Comprehensive Cancer Network, Inc. All Rights Reserved.



## PRINCIPLES OF SURGERY

**Site Specific**

- These sites are rarely amenable to upfront resection and biopsy is generally recommended: orbital, parameningeal, vulvar/vaginal, biliary, or bladder/prostate tumors. These tumors can rarely be excised without notable loss of form or function. Thus, upfront biopsy for diagnosis followed by systemic therapy is the initial approach.
- Paratesticular:
  - Resection should only occur by radical orchiectomy via inguinal approach. If prior scrotal resection with negative margins, hemiscrotectomy is no longer routinely recommended.
  - Hemiscrotectomy should only be performed when there is invasion of the scrotal skin.
    - Reflexive completion hemiscrotectomy is no longer recommended for patients who had a transscrotal biopsy or previous partial scrotal resection if there is no evidence of any further involvement of the scrotal skin.
- Vulva, Vagina, Uterus Fundus/Cervix:
  - Biopsy, staging, and chemotherapy should be the initial approach—not radical excision. Vulvar/vaginal sites can often be managed with chemotherapy alone or chemotherapy with RT (EBRT or brachytherapy) and typically do not need surgical intervention beyond biopsy. High-dose alkylating agents are options in select patients with a proven complete response from repeat biopsies.[1]
  - Some uterine tumors may be appropriately managed with upfront surgery (hysterectomy), allowing for Stage 1 Group 1 assignment, with potential for reduced adjuvant chemotherapy and omission of RT.
    - Initial radical hysterectomy may be considered for patients who do not desire future fertility after shared decision-making with the treating team. For patients who desire future fertility, recommend biopsy followed by local control with attempts at preserving fertility.[1]
  - Recommend including a pediatric adolescent gynecologist or reproductive infertility endocrinologist within the multidisciplinary team when discussing local control treatments.
- Biliary:
  - This site rarely needs radical surgery, as disease typically responds to multimodal therapy; thus, surgery is reserved for diagnosis and staging. This includes for patients with biliary obstruction, which also typically improves with chemotherapy.
- Extremity:
  - Only the involved compartment should be traversed for biopsy.
  - Incisions should be made along the axis of the involved compartment.
- Bladder/Prostate:
  - Biopsy, staging, and chemotherapy should be the initial approach rather than upfront cystectomy/prostatectomy.
  - In rare circumstances when the tumor only involves the dome of the bladder, partial cystectomy can be considered as long as bladder function is maintained.

[1] Lautz TB, et al. Pediatr Blood Cancer 2023;70:e28601.

**Note: All recommendations are category 2A unless otherwise indicated.**



Version 1.2026, 02/017/2026 © 2026 National Comprehensive Cancer Network® (NCCN®), All rights reserved. NCCN Guidelines® and this illustration may not be reproduced in any form without the express written permission of NCCN.

PLEASE NOTE that use of this NCCN Content is governed by the End-User License Agreement, and you MAY NOT distribute this Content or use it with any artificial intelligence model or tool.
Printed by A. S. M. FAZLUL KARIM CHOWDHURY on 4/20/2026 3:39:07 AM. Copyright © 2026 National Comprehensive Cancer Network, Inc. All Rights Reserved.



## PRINCIPLES OF LYMPH NODE DISEASE ASSESSMENT

**Lymph Node Disease Assessment at Diagnosis**

- Clinical and/or imaging evaluation of regional lymph nodes should be performed pretreatment and preoperatively and is an important part of pretreatment staging.
- Clinically or radiographically involved (>1 cm in short axis on CT/MRI, or FDG avid) nodes should be sampled for histologic evaluation.
  - In those patients with pathologically confirmed lymph nodes or clinically/radiographically involved nodes that are not assessed pathologically, treatment with RT to the regional nodal bed is required (PRMS-F).
- Positive lymph nodes outside of the regional basin should be classified as distant spread (Clinical Group IV, Stage 4).
- Nodal evaluation by open biopsy is recommended, preferably using sentinel node technique; however, core needle biopsy may be appropriate. If sentinel node evaluation is not available, then random regional lymph node sampling is the next most appropriate method of surgical evaluation for most sites.
- In general, prophylactic radical node dissection, as employed for some other malignancies, is not necessary in childhood RMS.
- Nodal sampling is strongly recommended for patients with known *FOXO1* gene fusion-positive disease or unknown *FOXO1* status and alveolar histology.
- Extremity tumors:
  - Systematic regional lymph node sampling is required even when there are no palpable involved nodes. Excisional biopsy, when feasible, is recommended.
    - ◊ If the nodes are clinically involved, biopsy of more proximal nodes should be performed before proceeding with sampling.
  - Tumors arising in the shoulder and hip girdle are considered to be extremity tumors.
- Paratesticular tumors:
  - RPLN sampling is required for all patients ≥10 years of age with paratesticular tumors and patients <10 years with clinically or radiographically involved lymph nodes (except when extensive lymph node involvement is identified by imaging studies). If there is extensive gross node involvement, then only confirmatory node biopsy is recommended and the patient's disease is classified as Clinical Group III.
  - Patients with positive nodes on CT scan should have staging ipsilateral template nerve-sparing RPLN dissection (RPLND) or ipsilateral infra-renal lymph node sampling of 7–12 nodes.[1] If all nodal disease is removed, the patient's disease is classified as Clinical Group II B or C.
  - Any positive node(s) on CT scan not completely removed places the patient's disease in Clinical Group III.
- Head and Neck:
  - The incidence of cervical node involvement varies in head and neck primaries.[2] Cervical lymph node biopsy is not required unless nodes are clinically involved. If so, a biopsy should be performed.

[1] Rogers TN, Seitz G, Fuchs J, et al. Surgical management of paratesticular rhabdomyosarcoma: A consensus opinion from the Children's Oncology Group, European paediatric Soft tissue sarcoma Study Group, and the Cooperative Weichteilsarkom Studiengruppe. Pediatr Blood Cancer 2021;68:e28938.
[2] Terwisscha van Scheltinga S, Schoot RA, Routh JC, et al. Lymph node staging and treatment in pediatric patients with soft tissue sarcomas: A consensus opinion from the Children's Oncology Group, European paediatric Soft Tissue Sarcoma Study Group, and the Cooperative Weichteilsarkom Studiengruppe. Pediatr Blood Cancer 2025;72:e31538.

**Note: All recommendations are category 2A unless otherwise indicated.**



Version 1.2026, 02/017/2026 © 2026 National Comprehensive Cancer Network® (NCCN®), All rights reserved. NCCN Guidelines® and this illustration may not be reproduced in any form without the express written permission of NCCN.

PLEASE NOTE that use of this NCCN Content is governed by the End-User License Agreement, and you MAY NOT distribute this Content or use it with any artificial intelligence model or tool.
Printed by A. S. M. FAZLUL KARIM CHOWDHURY on 4/20/2026 3:39:07 AM. Copyright © 2026 National Comprehensive Cancer Network, Inc. All Rights Reserved.



## PRINCIPLES OF LYMPH NODE DISEASE ASSESSMENT

**Regional Nodal Basins for RMS**[2]

- Extremity:
  - Lower Extremity – inguinal, femoral, popliteal nodes (rarely involved)
  - Upper Extremity – axillary, brachial, epitrochlear, infraclavicular nodes
- Genitourinary:
  - Bladder/Prostate – pelvic, retroperitoneal nodes at renal artery level or below
  - Cervix and Uterus Fundus – pelvic, retroperitoneal nodes at renal artery level or below
  - Paratesticular – pelvic, retroperitoneal nodes at renal artery level or below
  - Vagina – retroperitoneal, pelvic nodes at or below common iliacs nodes, inguinal nodes
  - Vulva – inguinal nodes
- Head and Neck:
  - Head/Neck – ipsilateral cervical, jugular, preauricular, occipital, supraclavicular nodes for laterally placed tumors (excluding scalp); may have bilateral adenopathy with centrally placed tumors
  - Orbit/Eyelid – ipsilateral jugular, preauricular, cervical nodes
- Intrathoracic:
  - internal mammary, mediastinal nodes
- Retroperitoneum/Pelvis:
  - pelvic, retroperitoneal nodes
- Trunk:
  - Abdominal Wall – inguinal, femoral nodes
  - Chest Wall – axillary, internal mammary, infraclavicular nodes
- Other:
  - Biliary/Liver – liver hilar nodes
  - Perianal/Perineal – inguinal, pelvic nodes; may be bilateral

[2] Terwisscha van Scheltinga S, Schoot RA, Routh JC, et al. Lymph node staging and treatment in pediatric patients with soft tissue sarcomas: A consensus opinion from the Children's Oncology Group, European paediatric Soft Tissue Sarcoma Study Group, and the Cooperative Weichteilsarkom Studiengruppe. Pediatr Blood Cancer 2025;72:e31538.

**Note: All recommendations are category 2A unless otherwise indicated.**



Version 1.2026, 02/017/2026 © 2026 National Comprehensive Cancer Network® (NCCN®), All rights reserved. NCCN Guidelines® and this illustration may not be reproduced in any form without the express written permission of NCCN.

PLEASE NOTE that use of this NCCN Content is governed by the End-User License Agreement, and you MAY NOT distribute this Content or use it with any artificial intelligence model or tool.
Printed by A. S. M. FAZLUL KARIM CHOWDHURY on 4/20/2026 3:39:07 AM. Copyright © 2026 National Comprehensive Cancer Network, Inc. All Rights Reserved.



## PRINCIPLES OF RADIATION THERAPY

**General:**
- Treatment with photons, electrons, or protons may all be appropriate, depending on the clinical circumstances.
- Advanced RT technologies may be used to spare important organs at risk (OARs) and decrease the risk for late normal tissue damage while still achieving the primary goal of local tumor control. Advanced technologies including intensity-modulated RT (IMRT)/volumetric modulated arc therapy (VMAT), image-guided RT (IGRT), or proton beam therapy may offer significant and clinically relevant advantages.
- Dose-sparing for OARs reflects best clinical practice, as it reduces the risk of complications from normal tissue damage. Achieving highly conformal dose distributions is especially important for patients who are being treated with curative intent or who have long life expectancies following therapy.[1]
- Since the advantages of these techniques include tightly conformal doses and steep gradients next to normal tissues, careful target delineation and treatment delivery verification are critical to avoid the risk of tumor geographic miss and subsequent decrease in tumor control.
- Initial and post-induction diagnostic imaging with contrast-enhanced CT, MRI, FDG-PET/CT or FDG-PET/MRI, US, and other imaging modalities facilitate target definition.
- Image guidance with photon and proton beam therapy is typically required to provide assurance of accurate daily delivery.

**Timing:**
- Typically, primary site RT starts at week 13.
- Patients who require emergency RT (eg, spinal cord compression, vision loss) may receive RT to their emergency site starting at week 1. The entire course of the emergency RT should be administered starting at week 1, rather than splitting the treatment and concluding the course at week 13.
- Patients who undergo DPE will still receive RT. DPE does not obviate the need for RT, but it may allow for a lower dose.
- Dactinomycin is held during RT.
- Typically, metastatic site RT is given after completion of standard chemotherapy. However, in some cases, metastatic sites may be irradiated concurrently with the primary site.

**Planning Considerations:**
- Patients should be simulated with appropriate immobilization.
- Four-dimensional (4D)-CT is recommended for targets that are subject to motion.
- Relevant CT and/or MRI studies performed at baseline and after induction chemotherapy should be fused to the CT simulation for target delineation.
- Primary site target volume definitions:
  - The initial gross tumor volume (GTV1) will include the prechemotherapy extent of disease as visualized on baseline diagnostic imaging, respecting pushing borders.
  - The boost GTV (GTV2) will include the post-induction chemotherapy extent of disease as visualized on pre-RT imaging.
  - The clinical target volumes (CTV1, CTV2) = GTV1 + 1 cm and GTV2 + 1 cm, respectively, confined to anatomical borders. For instance, the CTV should not extend into uninvolved lungs, kidneys, abdominal organs, or bones.
  - If the tumor is subject to motion, an internal target volume (ITV) should be utilized based on the 4D-CT.
  - The planning target volume (PTV) = CTV + 0.3–0.5 cm, depending on the institutional standard, immobilization method, and modality of in-room verification imaging.

**Note: All recommendations are category 2A unless otherwise indicated.**

References



Version 1.2026, 02/017/2026 © 2026 National Comprehensive Cancer Network® (NCCN®), All rights reserved. NCCN Guidelines® and this illustration may not be reproduced in any form without the express written permission of NCCN.

PLEASE NOTE that use of this NCCN Content is governed by the End-User License Agreement, and you MAY NOT distribute this Content or use it with any artificial intelligence model or tool.
Printed by A. S. M. FAZLUL KARIM CHOWDHURY on 4/20/2026 3:39:07 AM. Copyright © 2026 National Comprehensive Cancer Network, Inc. All Rights Reserved.



## PRINCIPLES OF RADIATION THERAPY

**Nodal Treatment:**
- Pathologically involved nodal basins should be irradiated. Uninvolved nodal basins should not be irradiated electively.
  - Radiographically suspicious (ie, enlarged) lymph nodes may be presumed to be involved and irradiated if biopsy is not feasible.
  - Consider irradiating FDG-avid lymph nodes if biopsy is not feasible.

**Metastatic Site RT:**[2-4]
- RT is recommended for metastatic sites, as feasible. Various doses and fractionation schedules (conventional, hypofractionation, stereotactic body RT [SBRT]) are acceptable, depending upon the site and clinical scenario.
- Whole lung irradiation (WLI) is recommended in patients with upfront pulmonary metastases. The WLI dose is 15 Gy in 10 fractions. Residual parenchymal lung metastases at the time of RT should be considered for either resection or a radiotherapy boost.

| RT Indications to the Primary Site Based on Resection and *FOXO1* Status | | |
|---|---|---|
| **Clinical Group** | **Clinical Distinction** | **RT Dosing** |
| **Group I** | *FOXO1* gene fusion-negative | No RT |
| | *FOXO1* gene fusion-positive[5] | 36 Gy |
| **Group II** | R1 | 36 Gy |
| | Node-positive | 41.4 Gy |
| **Group III** | Standard definitive RT | 50.4 Gy |
| | DPE, R0[6] | 36 Gy |
| | DPE, R1[6] | 41.4 Gy |
| | Orbit in complete response (CR), *FOXO1* gene fusion-negative[7] | 45 Gy |
| **Metastatic Sites (see above)** | | |
| **Group IV** | Refer to above clinical groups for primary tumor site RT indications. | |

**Site-Specific Considerations:**
- For orbit primaries, the entire orbit does not need to be irradiated, only the tumor volume with appropriate margins. The CTV will not extend outside of the bony orbit, providing there is no orbital bone erosion.
- For vaginal tumors, brachytherapy should be considered and may be preferred.[8]

**Note: All recommendations are category 2A unless otherwise indicated.**

References



Version 1.2026, 02/017/2026 © 2026 National Comprehensive Cancer Network® (NCCN®), All rights reserved. NCCN Guidelines® and this illustration may not be reproduced in any form without the express written permission of NCCN.

PLEASE NOTE that use of this NCCN Content is governed by the End-User License Agreement, and you MAY NOT distribute this Content or use it with any artificial intelligence model or tool.
Printed by A. S. M. FAZLUL KARIM CHOWDHURY on 4/20/2026 3:39:07 AM. Copyright © 2026 National Comprehensive Cancer Network, Inc. All Rights Reserved.



## PRINCIPLES OF RADIATION THERAPY
## REFERENCES

[1] Salerno KE, Ermoian RP. Pediatric normal tissue effects in the clinic (PENTEC): An extraordinary step forward for pediatric radiation oncology. Int J Radiat Oncol Biol Phys 2024;119:313-314.
[2] Casey DL, Murphy ES, Shen CJ, et al. Metastatic-site radiation therapy for Ewing sarcoma and rhabdomyosarcoma: Consensus guidelines from the National Pediatric Cancer Foundation. Pract Radiat Oncol 2025;15:180-186.
[3] Cameron AL, Elze MC, Casanova M, et al. The impact of radiation therapy in children and adolescents with metastatic rhabdomyosarcoma. Int J Radiat Oncol Biol Phys 2021;111:968-978.
[4] Ferrari A, Bergamaschi L, Chiaravalli S, et al. Metastatic rhabdomyosarcoma: Evidence of the impact of radiotherapy on survival. A retrospective single-center experience. Pediatr Blood Cancer 2022;69:e29853.
[5] Aye JM, Chi YY, Tian J, et al. Do children and adolescents with completely resected alveolar rhabdomyosarcoma require adjuvant radiation? A report from the Children's Oncology Group. Pediatr Blood Cancer 2020;67:e28243.
[6] Lautz TB, Chi YY, Li M, et al. Benefit of delayed primary excision in rhabdomyosarcoma: A report from the Children's Oncology Group. Cancer 2021;127:275-283. Erratum in: Cancer 2023;129:970.
[7] Ermoian RP, Breneman J, Walterhouse DO, et al. 45 Gy is not sufficient radiotherapy dose for Group III orbital embryonal rhabdomyosarcoma after less than complete response to 12 weeks of ARST0331 chemotherapy: A report from the Soft Tissue Sarcoma Committee of the Children's Oncology Group. Pediatr Blood Cancer 2017;64:10.1002/pbc.26540. Erratum in: Pediatr Blood Cancer 2018;65:e27058.
[8] Minard-Colin V, Walterhouse D, Bisogno G, et al. Localized vaginal/uterine rhabdomyosarcoma-results of a pooled analysis from four international cooperative groups. Pediatr Blood Cancer 2018;65:e27096.

**Note: All recommendations are category 2A unless otherwise indicated.**



Version 1.2026, 02/017/2026 © 2026 National Comprehensive Cancer Network® (NCCN®), All rights reserved. NCCN Guidelines® and this illustration may not be reproduced in any form without the express written permission of NCCN.

PLEASE NOTE that use of this NCCN Content is governed by the End-User License Agreement, and you MAY NOT distribute this Content or use it with any artificial intelligence model or tool.
Printed by A. S. M. FAZLUL KARIM CHOWDHURY on 4/20/2026 3:39:07 AM. Copyright © 2026 National Comprehensive Cancer Network, Inc. All Rights Reserved.



## PRINCIPLES OF SYSTEMIC THERAPY
## RHABDOMYOSARCOMA

**Very-Low-Risk/Low-Risk RMS (PRMS-G 1 of 6)**

**Intermediate-Risk RMS (PRMS-G 2 of 6)**

**High-Risk RMS (PRMS-G 3 of 6)**

**Recurrent or Progressive RMS (PRMS-G 4 of 6)**

**Note: All recommendations are category 2A unless otherwise indicated.**



Version 1.2026, 02/017/2026 © 2026 National Comprehensive Cancer Network® (NCCN®), All rights reserved. NCCN Guidelines® and this illustration may not be reproduced in any form without the express written permission of NCCN.

PLEASE NOTE that use of this NCCN Content is governed by the End-User License Agreement, and you MAY NOT distribute this Content or use it with any artificial intelligence model or tool.
Printed by A. S. M. FAZLUL KARIM CHOWDHURY on 4/20/2026 3:39:07 AM. Copyright © 2026 National Comprehensive Cancer Network, Inc. All Rights Reserved.



## PRINCIPLES OF SYSTEMIC THERAPY
## VERY-LOW-RISK/LOW-RISK RHABDOMYOSARCOMA

| | Preferred | Other Recommended |
|---|---|---|
| **Very-Low-Risk RMS** | Clinical trial | • VA (Vincristine/Dactinomycin) alone for 22 wks per EpSSG RMS 2005[1]<br>• Treat as low-risk RMS |
| **Low-Risk RMS** | Clinical trial | • VAC (Vincristine/Dactinomycin/Cyclophosphamide)[a] per COG ARST0331[b,2]<br>• VA per COG D9602[3] |

[a] Mesna may be used as clinically indicated.
[b] RT begins at week 13 for all patients, except those with Clinical Group 1 disease. Week 16 (cycle 6): Dactinomycin should be held if patient is undergoing RT.

**Note: All recommendations are category 2A unless otherwise indicated.**

References



Version 1.2026, 02/017/2026 © 2026 National Comprehensive Cancer Network® (NCCN®), All rights reserved. NCCN Guidelines® and this illustration may not be reproduced in any form without the express written permission of NCCN.

PLEASE NOTE that use of this NCCN Content is governed by the End-User License Agreement, and you MAY NOT distribute this Content or use it with any artificial intelligence model or tool.
Printed by A. S. M. FAZLUL KARIM CHOWDHURY on 4/20/2026 3:39:07 AM. Copyright © 2026 National Comprehensive Cancer Network, Inc. All Rights Reserved.



## PRINCIPLES OF SYSTEMIC THERAPY
## INTERMEDIATE-RISK RHABDOMYOSARCOMA

| VAC Backbone Regimens for Intermediate-Risk RMS | |
|---|---|
| **Agents** | **Cyclophosphamide Cumulative Dose** |
| VAC[a] per COG ARST0531[4] | 16.8 g/m$^2$ |
| VAC[a] per COG D9803 Arm A[5] | 30.8 g/m$^2$ |
| VAC[a] alternating with VI (Vincristine/Irinotecan) per COG ARST0531[4] | 8.4 g/m$^2$ |
| VAC[a] alternating with VI per COG ARST1431[6] ± maintenance (Oral Cyclophosphamide/Vinorelbine) | 8.4 g/m$^2$ ± 4.2 g/m$^2$ PO |

[a] Mesna may be used as clinically indicated.

**Note: All recommendations are category 2A unless otherwise indicated.**

References



Version 1.2026, 02/017/2026 © 2026 National Comprehensive Cancer Network® (NCCN®), All rights reserved. NCCN Guidelines® and this illustration may not be reproduced in any form without the express written permission of NCCN.

PLEASE NOTE that use of this NCCN Content is governed by the End-User License Agreement, and you MAY NOT distribute this Content or use it with any artificial intelligence model or tool.
Printed by A. S. M. FAZLUL KARIM CHOWDHURY on 4/20/2026 3:39:07 AM. Copyright © 2026 National Comprehensive Cancer Network, Inc. All Rights Reserved.



## PRINCIPLES OF SYSTEMIC THERAPY
## HIGH-RISK RHABDOMYOSARCOMA

| VAC Backbone Regimens for High-Risk RMS | |
|---|---|
| **Agents** | **Cyclophosphamide Cumulative Dose[d]** |
| VAC per COG ARST2031[7] ± maintenance (Oral Cyclophosphamide/Vinorelbine)[c] | 16.8 g/m$^2$ ± 4.2 g/m$^2$ PO |
| VAC[a] per COG D9803 Arm A[5] | 30.8 g/m$^2$ |
| VAC[a] alternating with VI per COG ARST0531[4] ± maintenance (Oral Cyclophosphamide/Vinorelbine) | 8.4 g/m$^2$ ± 4.2 g/m$^2$ PO |
| IVA[a] (Ifosfamide/Vincristine/Dactinomycin) per EpSSG RMS 2005[8] | |

[a] Mesna may be used as clinically indicated.
[c] Maintenance per COG ARST2031 was studied and showed benefit with IVA backbone and is a study question in the current open high-risk COG study (ARST2031) using a VAC backbone.[9]
[d] Higher dose of cyclophosphamide is associated with prolonged neutropenia resulting in increased risk of infection and sepsis. Patients with high-risk RMS and Oberlin risk factors (ORF) >2 have poorer prognosis.[10,11] Consider low- or intermediate-dose cumulative cyclophosphamide regimens (8.4–16.8 mg/m$^2$) in those patients with poor performance score and high ORF. Consider outpatient regimens utilizing oral mesna and outpatient IV fluids in coordination with goals of care. Concordant chemotherapy and/or RT may offer symptom relief.

References

**Note: All recommendations are category 2A unless otherwise indicated.**



Version 1.2026, 02/017/2026 © 2026 National Comprehensive Cancer Network® (NCCN®), All rights reserved. NCCN Guidelines® and this illustration may not be reproduced in any form without the express written permission of NCCN.

PLEASE NOTE that use of this NCCN Content is governed by the End-User License Agreement, and you MAY NOT distribute this Content or use it with any artificial intelligence model or tool.
Printed by A. S. M. FAZLUL KARIM CHOWDHURY on 4/20/2026 3:39:07 AM. Copyright © 2026 National Comprehensive Cancer Network, Inc. All Rights Reserved.



## PRINCIPLES OF SYSTEMIC THERAPY
## RECURRENT OR PROGRESSIVE RHABDOMYOSARCOMA

| Recurrent or Progressive RMS Regimens | | |
|---|---|---|
| **Preferred** | **Other Recommended** | **Useful in Certain Circumstances[h]** |
| • Clinical trial | • Cyclophosphamide/Doxorubicin alternating with Etoposide/Ifosfamide[a] per COG ARST0121[e,12]<br>• Cyclophosphamide/Temsirolimus/Vinorelbine per COG ARST0921[f,13]<br>• Cyclophosphamide/Topotecan[14]<br>• VDC (Vincristine/Doxorubicin/Cyclophosphamide) alternating with IE (Ifosfamide/Etoposide)[a] per COG ARST0121[e,12]<br>• VIT (Vincristine/Irinotecan/Temozolomide) per COG VIT0910[g,15] | • Oral Cyclophosphamide/Vinorelbine[16]<br>• Doxorubicin HCl liposome or Doxorubicin[17]<br>• Oral Etoposide[18]<br>• GEMDOX (Gemcitabine/Docetaxel)[19]<br>• Irinotecan/Regorafenib/Vincristine[20]<br>• Pazopanib[21] |

[a] Mesna may be used as clinically indicated.
[e] Preferred over the other regimens in this column for patients with favorable-risk disease (initially low-risk disease treated without RT, and non-metastatic recurrence).
[f] Not evaluated in patients with prior vinorelbine exposure.
[g] Not evaluated in patients with prior irinotecan exposure.
[h] Choice among these may be based on prior treatment and adverse effect profiles.

**Note: All recommendations are category 2A unless otherwise indicated.**

References



Version 1.2026, 02/017/2026 © 2026 National Comprehensive Cancer Network® (NCCN®), All rights reserved. NCCN Guidelines® and this illustration may not be reproduced in any form without the express written permission of NCCN.

PLEASE NOTE that use of this NCCN Content is governed by the End-User License Agreement, and you MAY NOT distribute this Content or use it with any artificial intelligence model or tool.
Printed by A. S. M. FAZLUL KARIM CHOWDHURY on 4/20/2026 3:39:07 AM. Copyright © 2026 National Comprehensive Cancer Network, Inc. All Rights Reserved.



## PRINCIPLES OF SYSTEMIC THERAPY
## RHABDOMYOSARCOMA
## REFERENCES

[1] Bergeron C, Jenney M, De Corti F, et al. Embryonal rhabdomyosarcoma completely resected at diagnosis: The European paediatric Soft tissue sarcoma Study Group RMS2005 experience. Eur J Cancer 2021;146:21-29.
[2] Walterhouse DO, Pappo AS, Meza JL, et al. Shorter-duration therapy using vincristine, dactinomycin, and lower-dose cyclophosphamide with or without radiotherapy for patients with newly diagnosed low-risk rhabdomyosarcoma: a report from the Soft Tissue Sarcoma Committee of the Children's Oncology Group. J Clin Oncol 2014; 32:3547-3552.
[3] Raney RB, Walterhouse DO, Meza JL, et al. Results of the Intergroup Rhabdomyosarcoma Study Group D9602 protocol, using vincristine and dactinomycin with or without cyclophosphamide and radiation therapy, for newly diagnosed patients with low-risk embryonal rhabdomyosarcoma: a report from the Soft Tissue Sarcoma Committee of the Children's Oncology Group. J Clin Oncol 2011;29:1312-1318.
[4] Hawkins DS, Chi YY, Anderson JR, et al. Addition of vincristine and irinotecan to vincristine, dactinomycin, and cyclophosphamide does not improve outcome for intermediate-risk rhabdomyosarcoma: A report from the children's oncology group. J Clin Oncol 2018;36:2770-2777.
[5] Arndt CA, Stoner JA, Hawkins DS, et al. Vincristine, actinomycin, and cyclophosphamide compared with vincristine, actinomycin, and cyclophosphamide alternating with vincristine, topotecan, and cyclophosphamide for intermediate-risk rhabdomyosarcoma: children's oncology group study D9803. J Clin Oncol 2009;27:5182-5188.
[6] Gupta AA, Xue W, Harrison DJ, et al. Addition of temsirolimus to chemotherapy in children, adolescents, and young adults with intermediate-risk rhabdomyosarcoma (ARST1431): a randomised, open-label, phase 3 trial from the Children's Oncology Group. Lancet Oncol 2024;25:912-921.
[7] Allen-Rhoades WA, Mascarenhas L, Xue W, et al. ARST2031: A study to compare early use of vinorelbine and maintenance therapy for patients with high risk rhabdomyosarcoma [abstract]. J Clin Oncol 2022;40:Abstract TPS11591.
[8] Bisogno G, Jenney M, Bergeron C, et al. Addition of dose-intensified doxorubicin to standard chemotherapy for rhabdomyosarcoma (EpSSG RMS 2005): a multicentre, open-label, randomised controlled, phase 3 trial. Lancet Oncol 2018;19:1061-1071.
[9] Schoot RA, Chisholm JC, Casanova M, et al. Metastatic rhabdomyosarcoma: Results of the European Paediatric Soft Tissue Sarcoma Study Group MTS 2008 study and pooled analysis with the concurrent BERNIE study. J Clin Oncol 2022;40:3730-3740.
[10] Oberlin O, Rey A, Lyden E, et al. Prognostic factors in metastatic rhabdomyosarcomas: results of a pooled analysis from United States and European cooperative groups. J Clin Oncol 2008;26:2384-2389.
[11] Heinz AT, Schönstein A, Ebinger M, et al. Significance of fusion status, Oberlin risk factors, local and maintenance treatment in pediatric and adolescent patients with metastatic rhabdomyosarcoma: Data of the European Soft Tissue Sarcoma Registry SoTiSaR. Pediatr Blood Cancer 2024;71:e30707.
[12] Mascarenhas L, Lyden ER, Breitfeld PP, et al. Risk-based treatment for patients with first relapse or progression of rhabdomyosarcoma: A report from the Children's Oncology Group. Cancer 2019;125:2602-2609.
[13] Mascarenhas L, Chi YY, Hingorani P, et al. Randomized phase II trial of bevacizumab or temsirolimus in combination with chemotherapy for first relapse rhabdomyosarcoma: A report from the Children's Oncology Group. J Clin Oncol 2019;37:2866-2874.
[14] Saylors RL 3rd, Stine KC, Sullivan J, et al. Cyclophosphamide plus topotecan in children with recurrent or refractory solid tumors: a Pediatric Oncology Group phase II study. J Clin Oncol 2001;19:3463-3469.
[15] Defachelles AS, Bogart E, Casanova M, et al. Randomized phase II trial of vincristine-irinotecan with or without temozolomide, in children and adults with relapsed or refractory rhabdomyosarcoma: A European Paediatric Soft Tissue Sarcoma Study Group and innovative therapies for children with cancer trial. J Clin Oncol 2021;39:2979-2990.
[16] Minard-Colin V, Ichante JL, Nguyen L, et al. Phase II study of vinorelbine and continuous low doses cyclophosphamide in children and young adults with a relapsed or refractory malignant solid tumour: good tolerance profile and efficacy in rhabdomyosarcoma--a report from the Société Française des Cancers et leucémies de l'Enfant et de l'adolescent (SFCE). Eur J Cancer 2012;48:2409-2416.
[17] Benjamin RS, Wiernik PH, Bachur NR. Adriamycin: a new effective agent in the therapy of disseminated sarcomas. Med Pediatr Oncol 1975;1:63-76.

**Note: All recommendations are category 2A unless otherwise indicated.**



Version 1.2026, 02/017/2026 © 2026 National Comprehensive Cancer Network® (NCCN®), All rights reserved. NCCN Guidelines® and this illustration may not be reproduced in any form without the express written permission of NCCN.

PLEASE NOTE that use of this NCCN Content is governed by the End-User License Agreement, and you MAY NOT distribute this Content or use it with any artificial intelligence model or tool.
Printed by A. S. M. FAZLUL KARIM CHOWDHURY on 4/20/2026 3:39:07 AM. Copyright © 2026 National Comprehensive Cancer Network, Inc. All Rights Reserved.



## PRINCIPLES OF SYSTEMIC THERAPY
## RHABDOMYOSARCOMA
## REFERENCES

[18] Kebudi R, Görgün O, Ayan I. Oral etoposide for recurrent/progressive sarcomas of childhood. Pediatr Blood Cancer 2004;42:320-324.
[19] Rapkin L, Qayed M, Brill P, et al. Gemcitabine and docetaxel (GEMDOX) for the treatment of relapsed and refractory pediatric sarcomas. Pediatr Blood Cancer 2012;59:854-858.
[20] Casanova M, Bautista F, Campbell-Hewson Q, et al. Regorafenib plus vincristine and irinotecan in pediatric patients with recurrent/refractory solid tumors: An innovative therapy for children with cancer study. Clin Cancer Res 2023;29:4341-4351.
[21] Kanamitsu K, Ishida H, Fujiwara K, et al. A case of alveolar rhabdomyosarcoma showing concurrent responsive bone marrow lesions and refractory pancreatic lesions to pazopanib monotherapy. Pediatr Blood Cancer 2020;67:e28323.

**Note: All recommendations are category 2A unless otherwise indicated.**



Version 1.2026, 02/017/2026 © 2026 National Comprehensive Cancer Network® (NCCN®), All rights reserved. NCCN Guidelines® and this illustration may not be reproduced in any form without the express written permission of NCCN.

PLEASE NOTE that use of this NCCN Content is governed by the End-User License Agreement, and you MAY NOT distribute this Content or use it with any artificial intelligence model or tool.
Printed by A. S. M. FAZLUL KARIM CHOWDHURY on 4/20/2026 3:39:07 AM. Copyright © 2026 National Comprehensive Cancer Network, Inc. All Rights Reserved.



## PRINCIPLES OF SURVIVORSHIP
## RHABDOMYOSARCOMA

- As the cure rate for soft tissue sarcomas continues to increase to nearly 75%,[1] there is growing focus on the long-term side effects that affect patients following the completion of therapy. NCCN defines cancer survivorship as starting "from the time of diagnosis, through the balance of life" (https://www.nccn.org/professionals/physician_gls/pdf/survivorship.pdf; adapted with permission from the National Coalition for Cancer Survivorship as shown in the National Cancer Institute's Office of Cancer Survivorship Definitions web page, available at https://cancercontrol.cancer.gov/ocs/definitions). The Children's Oncology Group (COG) has a similar definition and emphasis on survivorship (https://www.survivorshipguidelines.org).
- The National Academy of Medicine has recommended that all cancer survivors be provided with a survivorship care plan (SCP) once they complete treatment. These plans should be specific to the patient and based on the patient's cancer, their treatment, the age of the patient at the time of treatment, and the patient's comorbidities.
- While there is growing recognition of the importance of survivorship, despite long-standing recommendations from numerous bodies, most survivors of childhood cancer are not receiving even basic screenings for serious late effects.[2]
- Being knowledgeable about the potential late effects of treatment, discussing late effects with patients and caregivers, and creating a SCP for monitoring and screening is within the purview of the treating oncology team.
- It is outside the scope of the NCCN Guidelines for Pediatric Soft Tissue Sarcoma to comprehensively discuss all the potential late effects that a patient with a soft tissue sarcoma might experience. It is also not possible to use this document to create a tailored SCP. Nevertheless, we have provided some general information about late effects based on potential exposure, as well as quality resources that focus on survivorship and late effects—some of which can be used to create an SCP (https://www.survivorshipguidelines.org/pdf/2023/COG_LTFU_Guidelines_Comprehensive_v6.pdf; https://www.passportforcare.org/en). Additionally, there are risk prediction calculators through the Childhood Cancer Survivorship Study for the following conditions: breast cancer, cardiomyopathy (derived using SJLIFE data), cardiovascular risks, and kidney failure (https://ccss.stjude.org/resources/calculators.html).

**Oncofertility and Fertility Preservation:**

- Many regimens for the treatment for pediatric soft tissue sarcomas are partially or very gonadotoxic.[3] Evidence has demonstrated that survivors place a great importance on being able to conceive and have biologically related children,[4,5] and yet, many to most are not provided with adequate information regarding infertility risk and access to fertility preservation resources.[6,7] There are resources to adequately assess a patient's risk for infertility, and what fertility preservation options should be offered.[3,8-10] Additionally, there are risk prediction calculators through the Childhood Cancer Survivorship Study for Acute Ovarian Failure Risk and Primary Ovarian Insufficiency (https://ccss.stjude.org/resources/calculators.html).

**Note: All recommendations are category 2A unless otherwise indicated.**

References



Version 1.2026, 02/017/2026 © 2026 National Comprehensive Cancer Network® (NCCN®), All rights reserved. NCCN Guidelines® and this illustration may not be reproduced in any form without the express written permission of NCCN.

PLEASE NOTE that use of this NCCN Content is governed by the End-User License Agreement, and you MAY NOT distribute this Content or use it with any artificial intelligence model or tool.
Printed by A. S. M. FAZLUL KARIM CHOWDHURY on 4/20/2026 3:39:07 AM. Copyright © 2026 National Comprehensive Cancer Network, Inc. All Rights Reserved.



## PRINCIPLES OF SURVIVORSHIP
## RHABDOMYOSARCOMA

**Consequential Risks of Treatment:**

- Please note that there are many additional and consequential risks to pediatric cancer survivors irrespective of cancer type and therapy given, such as psychosocial, neurocognitive, financial hardship, etc.
  - Please see COG Long-Term Follow-Up for further guidance and recommendations.
- Chemotherapy:
  - Vincristine: peripheral sensory or motor neuropathy, vasospastic attacks (Raynaud's phenomenon).
  - Dactinomycin: no known late effects.
  - Cyclophosphamide: ovarian or testicular hormonal dysfunction, diminished ovarian reserve, impaired spermatogenesis, infertility, secondary leukemia, myelodysplasia, urinary tract toxicity, bladder malignancy.
  - Irinotecan: no known late effects.
  - Vinorelbine: no known late effects.
- Radiation:
  - All fields: subsequent benign or malignant neoplasm, dermatologic toxicity.
  - Brain/cranium: brain tumor (benign or malignant), neurocognitive deficits, clinical leukoencephalopathy, cerebrovascular complications, craniofacial abnormalities, chronic sinusitis.
  - Neuroendocrine axis: overweight/obesity, growth hormone deficiency, precocious puberty, hyperprolactinemia, central hypothyroidism, gonadotropin deficiency, central adrenal insufficiency.
  - Eye: cataracts, ocular toxicity, ototoxicity.
  - Oral cavity: xerostomia; salivary gland dysfunction, dental abnormalities, temporomandibular joint dysfunction, osteonecrosis of the jaw.
  - Neck/thyroid: thyroid nodules, thyroid cancer, hypothyroidism, hyperthyroidism, carotid artery disease, subclavian artery disease.
  - Breast: breast cancer, breast tissue hypoplasia.
  - Lungs: pulmonary toxicity, lung cancer.
  - Heart: cardiac toxicity.
  - Spleen: functional asplenia.
  - GI/hepatic system: esophageal stricture, impaired glucose metabolism/diabetes mellitus, dyslipidemia, hepatic toxicity, cholelithiasis, bowel obstruction, chronic enterocolitis, fistula, strictures, colorectal cancer.
  - Urinary tract: renal toxicity, urinary tract toxicity, bladder malignancy.
  - Male reproductive system: testicular hormonal dysfunction, impaired spermatogenesis.
  - Female reproductive system: ovarian hormone deficiencies, diminished ovarian reserve, uterine vascular insufficiency, vaginal fibrosis/stenosis.
  - Musculoskeletal system: musculoskeletal growth problems, scoliosis/kyphosis, radiation-induced fracture.

**Note: All recommendations are category 2A unless otherwise indicated.**



Version 1.2026, 02/017/2026 © 2026 National Comprehensive Cancer Network® (NCCN®), All rights reserved. NCCN Guidelines® and this illustration may not be reproduced in any form without the express written permission of NCCN.

PLEASE NOTE that use of this NCCN Content is governed by the End-User License Agreement, and you MAY NOT distribute this Content or use it with any artificial intelligence model or tool.
Printed by A. S. M. FAZLUL KARIM CHOWDHURY on 4/20/2026 3:39:07 AM. Copyright © 2026 National Comprehensive Cancer Network, Inc. All Rights Reserved.



## PRINCIPLES OF SURVIVORSHIP
## RHABDOMYOSARCOMA

**Consequential Risks of Treatment (continued):**

- Surgery:
  - Amputation: amputation-related complications.
  - Central venous catheter: thrombosis, vascular insufficiency, infection of retained cuff or line tract, post-thrombotic syndrome.
  - Cystectomy: cystectomy-related complications.
  - Enucleation: impaired cosmesis, poor prosthetic fit, orbital hypoplasia.
  - Hysterectomy: pelvic floor dysfunction, urinary incontinence, sexual dysfunction.
  - Laparotomy: adhesions, bowel obstruction.
  - Limb sparing procedure: complications related to limb-sparing procedure.
  - Nephrectomy: hydrocele (male), renal toxicity.
  - Neurosurgery-brain: neurocognitive deficits, motor and/or sensory deficits, seizures, hydrocephalus, shunt malformation, overweight/obesity, diabetes insipidus.
  - Neurosurgery-spinal cord: neurogenic bladder, urinary incontinence, neurogenic bowel, fecal incontinence, psychosexual dysfunction, scoliosis/kyphosis.
  - Oophoropexy: oophoropexy-related complications.
  - Oophorectomy: ovarian hormone deficiencies, diminished ovarian reserve, loss of ovarian follicular pool.
  - Orchiectomy: testicular hormonal dysfunction, impaired spermatogenesis.
  - Pelvic surgery/cystectomy: urinary incontinence, urinary tract obstruction, fecal incontinence, psychosexual dysfunction, sexual dysfunction, infertility.
  - Splenectomy: asplenia.
  - Thoracic surgery: pulmonary dysfunction, scoliosis/kyphosis.
  - Thyroidectomy: hypothyroidism.

**Genetic Predisposition Syndromes:**

- Many studies of individual genetic disease cohorts demonstrate that children with certain genetic syndromes develop RMS more frequently than those unaffected.[11] Cancer predisposition syndromes associated with RMS include Li-Fraumeni,[12] neurofibromatosis type 1,[13] *DICER1*-related,[14] Costello,[15] Noonan,[16] and other RASopathies, including mosaic RASopathies.[17]
- A recent study that examined a large, unselected cohort of pediatric patients with RMS found that 7.3% carried a cancer predisposition variant.[18] The chance of an individual patient having cancer predisposition syndrome is affected by the histologic type of RMS,[18] presence of anaplasia,[19] *FOXO1* fusion status,[18] age,[18,19] location,[20] and tumor somatic mutations.[18]
- Therefore, besides the family history of a patient, individual characteristics of the presentation and the tumor should be strongly considered, as germline testing may be warranted.

**Note: All recommendations are category 2A unless otherwise indicated.**

References



Version 1.2026, 02/017/2026 © 2026 National Comprehensive Cancer Network® (NCCN®), All rights reserved. NCCN Guidelines® and this illustration may not be reproduced in any form without the express written permission of NCCN.

PLEASE NOTE that use of this NCCN Content is governed by the End-User License Agreement, and you MAY NOT distribute this Content or use it with any artificial intelligence model or tool.
Printed by A. S. M. FAZLUL KARIM CHOWDHURY on 4/20/2026 3:39:07 AM. Copyright © 2026 National Comprehensive Cancer Network, Inc. All Rights Reserved.



## PRINCIPLES OF SURVIVORSHIP
## RHABDOMYOSARCOMA
## REFERENCES

[1] Howlader N, Noone AM, Krapcho M, et al. SEER Cancer Statistics Review, 1975-2018. National Cancer Institute; 2021. Available at: https://seer.cancer.gov/archive/csr/1975_2018. Accessed December 23, 2025.
[2] Yan AP, Chen Y, Henderson TO, et al. Adherence to surveillance for second malignant neoplasms and cardiac dysfunction in childhood cancer survivors: A childhood cancer survivor study. J Clin Oncol 2020;38:1711-1722.
[3] Bjornard K, Close A, Burns K, et al. Fertility preservation in pediatric solid tumors: A report from the Children's Oncology Group. Pediatr Blood Cancer 2024;71:e30960.
[4] Stein DM, Victorson DE, Choy JT, et al. Fertility preservation preferences and perspectives among adult male survivors of pediatric cancer and their parents. J Adolesc Young Adult Oncol 2014;3:75-82.
[5] Nahata L, Caltabellotta NM, Yeager ND, et al. Fertility perspectives and priorities among male adolescents and young adults in cancer survivorship. Pediatr Blood Cancer 2018;65:e27019.
[6] Partridge AH, Gelber S, Peppercorn J, et al. Web-based survey of fertility issues in young women with breast cancer. J Clin Oncol 2004;22:4174-4183.
[7] Benedict C, Thom B, N Friedman DN, et al. Young adult female cancer survivors' unmet information needs and reproductive concerns contribute to decisional conflict regarding posttreatment fertility preservation. Cancer 2016;122:2101-2109.
[8] Mulder RL, Font-Gonzalez A, Hudson MM, et al. Fertility preservation for female patients with childhood, adolescent, and young adult cancer: recommendations from the PanCareLIFE Consortium and the International Late Effects of Childhood Cancer Guideline Harmonization Group. Lancet Oncol 2021;22:e45-e56.
[9] Mulder RL, Font-Gonzalez A, Green DM, et al. Fertility preservation for male patients with childhood, adolescent, and young adult cancer: recommendations from the PanCareLIFE Consortium and the International Late Effects of Childhood Cancer Guideline Harmonization Group. Lancet Oncol 2021;22:e57-e67.
[10] Meacham LR, Burns K, Orwig KE, Levine J. Standardizing risk assessment for treatment-related gonadal insufficiency and infertility in childhood adolescent and young adult cancer: The Pediatric Initiative Network risk stratification system. J Adolesc Young Adult Oncol 2020;9:662-666.
[11] Zimmerman R, Schimmenti L, Spector L. A catalog of genetic syndromes in childhood cancer. Pediatr Blood Cancer 2015;62:2071-2075.
[12] Diller L, Sexsmith E, Gottlieb A, et al. Germline p53 mutations are frequently detected in young children with rhabdomyosarcoma. J Clin Invest 1995;95:1606-1611.
[13] Yang P, Grufferman S, Khoury MJ, et al. Association of childhood rhabdomyosarcoma with neurofibromatosis type I and birth defects. Genet Epidemiol 1995;12:467-474.
[14] Doros L, Yang J, Dehner L, et al. DICER1 mutations in embryonal rhabdomyosarcomas from children with and without familial PPB-tumor predisposition syndrome. Pediatr Blood Cancer 2012;59:558-560.
[15] Estep AL, Tidyman WE, Teitell MA, et al. HRAS mutations in Costello syndrome: detection of constitutional activating mutations in codon 12 and 13 and loss of wild-type allele in malignancy. Am J Med Genet A 2006;140:8-16.
[16] Kratz CP, Rapisuwon S, Reed H, et al. Cancer in Noonan, Costello, cardiofaciocutaneous and LEOPARD syndromes. Am J Med Genet C Semin Med Genet 2011;157C:83-89.
[17] Windrich J, Ney GM, Rosenberg PS, et al. Cancer in multilineage mosaic RASopathies due to pathogenic variants in HRAS or KRAS: A systematic review and meta-analysis. Clin Cancer Res 2024;30:5116-5121.
[18] Li H, Sisoudiya SD, Martin-Giacalone BA, et al. Germline cancer predisposition variants in pediatric rhabdomyosarcoma: A report from the Children's Oncology Group. J Natl Cancer Inst 2021;113:875-883.
[19] Fair D, Maese L, Chi YY, et al. TP53 germline pathogenic variant frequency in anaplastic rhabdomyosarcoma: A Children's Oncology Group report. [published online ahead of print May 17, 2023]. Pediatr Blood Cancer. doi: 10.1002/pbc.30413.
[20] Stewart CJR, Charles A, Foulkes WD. Gynecologic manifestations of the DICER1 syndrome. Surg Pathol Clin 2016;9:227-241.

**Note: All recommendations are category 2A unless otherwise indicated.**



Version 1.2026, 02/017/2026 © 2026 National Comprehensive Cancer Network® (NCCN®), All rights reserved. NCCN Guidelines® and this illustration may not be reproduced in any form without the express written permission of NCCN.

PLEASE NOTE that use of this NCCN Content is governed by the End-User License Agreement, and you MAY NOT distribute this Content or use it with any artificial intelligence model or tool.
Printed by A. S. M. FAZLUL KARIM CHOWDHURY on 4/20/2026 3:39:07 AM. Copyright © 2026 National Comprehensive Cancer Network, Inc. All Rights Reserved.



## RHABDOMYOSARCOMA STAGING AND CLINICAL GROUP TABLES[1,2]

| Stage | Sites | S | N | M |
|---|---|---|---|---|
| 1 | • Orbit<br>• Head and neck (excluding parameningeal)<br>• GU: non-bladder, non-prostate | a or b | N0, N1, or Nx | M0 |
| 2 | • Parameningeal<br>• Bladder/prostate<br>• Extremity<br>• Other (including trunk, retroperitoneum) | a | N0 or Nx | M0 |
| 3 | • Parameningeal<br>• Bladder/prostate<br>• Extremity<br>• Other (including trunk, retroperitoneum) | a | N1 | M0 |
| | | b | N0, N1, or Nx | M0 |
| 4 | • All | a or b | N0, N1, or Nx | M1 |

Tumor Size (S):
- a: ≤5 cm in diameter
- b: >5 cm in diameter

Regional Nodes (N):
- N0: Regional nodes not clinically involved
- N1: Regional nodes clinically involved as defined as ≥1 cm measured in short axis on CT or MRI
- Nx: Clinical status of regional nodes unknown (especially sites that preclude lymph node evaluation)

Metastases (M):
- M0: No distant metastases
- M1: Distant metastases present

Note: The presence of positive cytology in pleural fluid, abdominal fluid, or CSF and the presence of implants on pleural or peritoneal are considered evidence of metastasis.

| Clinical Group | Definition |
|---|---|
| Group I | • Localized disease, completely resected<br>Note: Gross inspection and microscopic confirmation of complete resection is required.<br>Note: Regional nodes cannot be involved. |
| Group II | • Localized disease, grossly resected with microscopic residual disease, or<br>• Regional disease, grossly resected with or without microscopic residual disease<br>a. Localized disease, grossly resected tumor with microscopic residual disease, regional nodes not involved.<br>b. Regional disease with involved nodes, completely resected with no microscopic residual (including most distal node is histologically negative).<br>c. Regional disease with involved nodes, grossly resected with evidence of microscopic residual and/or histologic involvement of the most distal regional node in the dissection. |
| Group III | • Localized or regional disease, biopsy only or incomplete resection with gross residual disease |
| Group IV | • Distant metastatic disease present at onset<br>• Although not limited to these, the following are considered evidence of metastatic disease:<br>▸ 1) The presence of positive cytology in CSF<br>▸ 2) Positive cytology in pleural or abdominal fluids, or<br>▸ 3) The presence of implants on pleural or peritoneal surfaces.<br>Note: Regional lymph node involvement and adjacent organ infiltration are not considered metastatic disease.<br>Note: The presence of a pleural effusion or ascites without positive cytologic evaluation is not considered evidence of metastatic disease. |

[1] Adapted with permission from: Crane JN, Xue W, Qumseya A, et al. Clinical group and modified TNM stage for rhabdomyosarcoma: A review from the Children's Oncology Group. Pediatr Blood Cancer. 2022;69:e29644.
[2] Adapted with permission from: Haduong JH, Heske CM, Allen-Rhoades W, et al. An update on rhabdomyosarcoma risk stratification and the rationale for current and future Children's Oncology Group clinical trials. Pediatr Blood Cancer. 2022;69:e29511.

**Note: All recommendations are category 2A unless otherwise indicated.**



Version 1.2026, 02/017/2026 © 2026 National Comprehensive Cancer Network® (NCCN®), All rights reserved. NCCN Guidelines® and this illustration may not be reproduced in any form without the express written permission of NCCN.

PLEASE NOTE that use of this NCCN Content is governed by the End-User License Agreement, and you MAY NOT distribute this Content or use it with any artificial intelligence model or tool.
Printed by A. S. M. FAZLUL KARIM CHOWDHURY on 4/20/2026 3:39:07 AM. Copyright © 2026 National Comprehensive Cancer Network, Inc. All Rights Reserved.



## ABBREVIATIONS

| | |
|---|---|
| 4D-CT | four-dimensional computed tomography |
| ALARA | as low as reasonably achievable |
| COG | Children's Oncology Group |
| CR | complete response |
| CTA | computed tomography angiography |
| CTV | clinical target volume |
| DPE | delayed primary excision |
| DWI | diffusion-weighted imaging |
| EBRT | external beam radiation therapy |
| ERMS | embryonal rhabdomyosarcoma |
| FDG | fluorodeoxyglucose |
| FISH | fluorescence in situ hybridization |
| FS | fat saturation |
| GTV | Gross tumor volume |
| H&P | history and physical |
| IGRT | image-guided radiation therapy |
| IHC | immunohistochemistry |
| IMRT | intensity-modulated radiation therapy |
| ITV | internal target volume |
| OAR | organs at risk |
| ORF | Oberlin risk factors |
| MIP | maximum intensity projection |
| NGS | next-generation sequencing |
| PRE | pre-treatment re-excision |
| PTV | planning target volume |
| RMS | rhabdomyosarcoma |
| RPLN | retroperitoneal lymph node |
| RT-PCR | reverse transcriptase polymerase chain reaction |
| SBRT | stereotactic body radiation therapy |
| SCP | survivorship care plan |
| SCRMS | spindle cell/sclerosing rhabdomyosarcoma |
| SPECT | single-photon emission computed tomography |
| STIR | short tau inversion recovery |
| Tc-99m | technetium-99m |
| TSE | turbo spin echo |
| VMAT | volumetric modulated arc therapy |
| WLI | whole lung irradiation |



Version 1.2026, 02/017/2026 © 2026 National Comprehensive Cancer Network® (NCCN®), All rights reserved. NCCN Guidelines® and this illustration may not be reproduced in any form without the express written permission of NCCN.

PLEASE NOTE that use of this NCCN Content is governed by the End-User License Agreement, and you MAY NOT distribute this Content or use it with any artificial intelligence model or tool.
Printed by A. S. M. FAZLUL KARIM CHOWDHURY on 4/20/2026 3:39:07 AM. Copyright © 2026 National Comprehensive Cancer Network, Inc. All Rights Reserved.



| NCCN Categories of Evidence and Consensus | |
|---|---|
| **Category 1** | Based upon high-level evidence (≥1 randomized phase 3 trials or high-quality, robust meta-analyses), there is uniform NCCN consensus (≥85% support of the Panel) that the intervention is appropriate. |
| **Category 2A** | Based upon lower-level evidence, there is uniform NCCN consensus (≥85% support of the Panel) that the intervention is appropriate. |
| **Category 2B** | Based upon lower-level evidence, there is NCCN consensus (≥50%, but <85% support of the Panel) that the intervention is appropriate. |
| **Category 3** | Based upon any level of evidence, there is major NCCN disagreement that the intervention is appropriate. |

All recommendations are category 2A unless otherwise indicated.

| NCCN Categories of Preference | |
|---|---|
| **Preferred** | Interventions that are based on superior efficacy, safety, and evidence; and, when appropriate, affordability. |
| **Other recommended** | Other interventions that may be somewhat less efficacious, more toxic, or based on less mature data; or significantly less affordable for similar outcomes. |
| **Useful in certain circumstances** | Other interventions that may be used for selected patient populations (defined with recommendation). |

All recommendations are considered appropriate.

**Note: All recommendations are category 2A unless otherwise indicated.**



Version 1.2026, 02/017/2026 © 2026 National Comprehensive Cancer Network® (NCCN®), All rights reserved. NCCN Guidelines® and this illustration may not be reproduced in any form without the express written permission of NCCN.

PLEASE NOTE that use of this NCCN Content is governed by the End-User License Agreement, and you MAY NOT distribute this Content or use it with any artificial intelligence model or tool.
Printed by A. S. M. FAZLUL KARIM CHOWDHURY on 4/20/2026 3:39:07 AM. Copyright © 2026 National Comprehensive Cancer Network, Inc. All Rights Reserved.



DISCUSSION UNDER DEVELOPMENT

Version 1.2026 © 2026 National Comprehensive Cancer Network© (NCCN©), All rights reserved. NCCN Guidelines® and this illustration may not be reproduced in any form without the express written permission of NCCN.