National Comprehensive Cancer Network®

NCCN Clinical Practice Guidelines in Oncology (NCCN Guidelines®)

Wilms Tumor (Nephroblastoma)

Version 2.2025 — June 11, 2025

NCCN.org

NCCN recognizes the importance of clinical trials and encourages participation when applicable and available. Trials should be designed to maximize inclusiveness and broad representative enrollment.

Continue

Version 2.2025, 6/11/2025 © 2025 National Comprehensive Cancer Network® (NCCN®), All rights reserved. NCCN Guidelines® and this illustration may not be reproduced in any form without the express written permission of NCCN.

PLEASE NOTE that use of this NCCN Content is governed by the End-User License Agreement, and you MAY NOT distribute this Content or use it with any artificial intelligence model or tool.
Printed by A. S. M. FAZLUL KARIM CHOWDHURY on 4/20/2026 3:41:05 AM. Copyright © 2026 National Comprehensive Cancer Network, Inc. All Rights Reserved.

***Frank Balis, MD/Chair € Σ**
Abramson Cancer Center
at the University of Pennsylvania

***Daniel M. Green, MD/Vice Chair €**
St. Jude Children's Research Hospital/
The University of Tennessee
Health Science Center

***Amy Armstrong, MD € ‡**
Siteman Cancer Center at Barnes-
Jewish Hospital and Washington
University School of Medicine

Jamie Aye, MD €
O'Neal Comprehensive Cancer Center at UAB

***Daniel Benedetti, MD, MA €**
Vanderbilt-Ingram Cancer Center

Brandon Brown, MD, BS €
The University of Texas
MD Anderson Cancer Center

Erin Brown, MD ¶
UC Davis Comprehensive Cancer Center

Shelly Cook, MD ≠
University of Wisconsin Carbone Cancer Center

Ami Desai, MD, MSCE ‡ €
The UChicago Medicine
Comprehensive Cancer Center

Jasreman Dhillon, MD ≠
Moffitt Cancer Center

Douglas Fair, MD, MS €
Huntsman Cancer Institute
at the University of Utah

Daniel M. Geynisman, MD ‡
Fox Chase Cancer Center

Susan Hiniker, MD §
Stanford Cancer Institute

***Kelly Horst, MD ф**
Mayo Clinic Comprehensive Cancer Center

Rama Jasty-Rao, MD €
University of Michigan Rogel Cancer Center

Marissa Just, MD €
Indiana University Melvin and Bren Simon
Comprehensive Cancer Center

Kathleen Kieran, MD, MSc, MME ω
Fred Hutchinson Cancer Center

***Chi Lin, MD, PhD §**
Fred & Pamela Buffett Cancer Center

Iain MacEwan, MD §
UC San Diego Moores Cancer Center

Julian Martinez-Agosto, MD, PhD €
UCLA Jonsson Comprehensive Cancer Center

Elizabeth Mullen, MD €
Dana-Farber/Brigham and
Women's Cancer Center

Erin S. Murphy, MD §
Case Comprehensive Cancer Center/
University Hospitals Seidman Cancer Center
and Cleveland Clinic Taussig Cancer Institute

Navin Pinto, MD € ‡
University of Colorado Cancer Center/
Children's Hospital Colorado

Mark Ranalli, MD €
The Ohio State University Comprehensive
Cancer Center - James Cancer Hospital
and Solove Research Institute

***Daniel Rhee, MD, MPH € ¶**
Johns Hopkins Kimmel Cancer Center

Denise Rokitka, MD, MPH €
Roswell Park Comprehensive Cancer Center

***Amy Walz, MD €**
Robert H. Lurie Comprehensive Cancer
Center of Northwestern University

Jonathan Wickiser, MD € ‡
UT Southwestern Simmons
Comprehensive Cancer Center

Janet Yoon, MD ‡ €
City of Hope National Medical Center

Matthew Zapala, MD, PhD §
UCSF Helen Diller Family
Comprehensive Cancer Center

NCCN
Sarah Montgomery, BA
Bailee Sliker, PhD

ф Diagnostic radiology
‡ Hematology/Hematology oncology
≠ Pathology
€ Pediatric oncology
Σ Pharmacology
§ Radiotherapy/Radiation oncology
¶ Surgery/Surgical oncology
ω Urology
* Discussion Section Writing Committee

NCCN Guidelines Panel Disclosures

Continue

Version 2.2025, 6/11/2025 © 2025 National Comprehensive Cancer Network® (NCCN®), All rights reserved. NCCN Guidelines® and this illustration may not be reproduced in any form without the express written permission of NCCN.

PLEASE NOTE that use of this NCCN Content is governed by the End-User License Agreement, and you MAY NOT distribute this Content or use it with any artificial intelligence model or tool.
Printed by A. S. M. FAZLUL KARIM CHOWDHURY on 4/20/2026 3:41:05 AM. Copyright © 2026 National Comprehensive Cancer Network, Inc. All Rights Reserved.

National Comprehensive Cancer Network®

NCCN Guidelines Version 2.2025
Wilms Tumor (Nephroblastoma)

NCCN Wilms Tumor (Nephroblastoma) Panel Members
Summary of the Guidelines Updates

Introduction to Wilms Tumor (INTRO-1)
Presentation, Initial Evaluation, and Initial Treatment (WILMS-1)
Treatment for Renal Tumor (WILMS-2)
Unilateral FHWT, Primary Nephrectomy (WILMS-3)
Unilateral FHWT Renal Tumor, Initially Unresectable With No Predisposing Condition (WILMS-5)
Localized Unilateral Renal Tumor With Predisposing Condition (WILMS-6)
Metastatic Unilateral Renal Tumor With Predisposing Condition (WILMS-7)
Localized Bilateral Renal Tumors With or Without Predisposing Condition (WILMS-8)
Metastatic Bilateral Renal Tumors With or Without Predisposing Condition (WILMS-9)
Unilateral Wilms Tumor With Focal or Diffuse Anaplasia (WILMS-10)
Unilateral Wilms Tumor With Diffuse Anaplasia, Initially Unresectable, No Predisposing Condition (WILMS-11)
Unilateral Wilms Tumor With Focal or Diffuse Anaplasia and Predisposing Condition (WILMS-12)
Bilateral Wilms Tumor With Focal or Diffuse Anaplasia With or Without Predisposing Condition (WILMS-13)

Principles of Abdominal Mass Evaluation (WILMS-A)
Principles of Imaging (WILMS-B)
Principles of Pathology (WILMS-C)
Principles of Surgery (WILMS-D)
Principles of Biopsy (WILMS-E)
Initial and Final Risk Assessment for FHWT (WILMS-F)
Principles of Chemotherapy (WILMS-G)
Principles of Radiation Therapy (WILMS-H)
Principles of Cancer Risk Assessment and Counseling (WILMS-I)
Follow-Up After Completion of Treatment and Monitoring for Late Effects (WILMS-J)

Children's Oncology Group (COG) Staging of Wilms Tumor (ST-1)

Abbreviations (ABBR-1)

Find an NCCN Member Institution: https://www.nccn.org/home/member-institutions.

NCCN Categories of Evidence and Consensus: All recommendations are category 2A unless otherwise indicated.

See NCCN Categories of Evidence and Consensus.

The NCCN Guidelines® are a statement of evidence and consensus of the authors regarding their views of currently accepted approaches to treatment. Any clinician seeking to apply or consult the NCCN Guidelines is expected to use independent medical judgment in the context of individual clinical circumstances to determine any patient's care or treatment. The National Comprehensive Cancer Network® (NCCN®) makes no representations or warranties of any kind regarding their content, use or application and disclaims any responsibility for their application or use in any way. The NCCN Guidelines are copyrighted by National Comprehensive Cancer Network®. All rights reserved. The NCCN Guidelines and the illustrations herein may not be reproduced in any form without the express written permission of NCCN. ©2025.

PLEASE NOTE that use of this NCCN Content is governed by the End-User License Agreement, and you MAY NOT distribute this Content or use it with any artificial intelligence model or tool.
Printed by A. S. M. FAZLUL KARIM CHOWDHURY on 4/20/2026 3:41:05 AM. Copyright © 2026 National Comprehensive Cancer Network, Inc. All Rights Reserved.

Updates in Version 2.2025 of the NCCN Guidelines for Wilms Tumor (Nephroblastoma) from Version 2.2025 include:

MS-1
• The discussion section has been updated to reflect the changes in the algorithm.

Updates in Version 1.2025 of the NCCN Guidelines for Wilms Tumor (Nephroblastoma) from Version 2.2024 include:

Global Changes
• References updated throughout the Guidelines.

INTRO-1
• Statement added: WT is largely a disease of children, though adults may occasionally present with high-risk disease. Treatment for adults with WT is similar to treatment for pediatric patients; thus, referral or partnership with a pediatric oncologist familiar with the treatment of WT is recommended.
• Clinical presentation, bullet 6 modified: WT is associated with genetic predisposing conditions in 10% to 15% of cases, *with some reports suggesting >30% of cases,* such as Denys-Drash syndrome (male pseudohermaphroditism and glomerulopathy); WAGR syndrome (WT, aniridia, genitourinary abnormalities, and range of intellectual disability); ~~and~~ Beckwith-Wiedemann syndrome (macroglossia, hemihyperplasia, gigantism, and umbilical hernia)*; Perlman syndrome; Frasier syndrome; Sotos syndrome; Simpson-Golabi-Behmel syndrome; Bloom syndrome; Li-Fraumeni syndrome; and trisomy 18. See WILMS-I (2 of 5).*

INTRO-2
• Treatment, bullet 8 modified: Recommend referral to infertility risk/fertility preservation counseling for patients treated with chemotherapy; strongly encourage prior to treatment with regimen M, regimen I, *revised regimen UH-1, revised regimen UH-2,* or whole abdominal irradiation (WAI).

WILMS-2
• Footnote g added: Limited data exist for patients with unilateral multifocal tumors; thus, the NCCN Panel recommends that either approach is reasonable.
• Footnote f modified: "Conditions that predispose to the development of WT include genetic disorders such as *Denys-Drash*, WAGR, *Beckwith-Wiedemann*, Frasier, and Perlman syndromes; contralateral nephrogenic rests in children <12 months. Ten percent to 33% of WT *occurs* in children with predisposing conditions..." (Also for WILMS-11)

WILMS-3
• Footnote s modified: A retrospective analysis of the biology suggests patients with VLR FHWT and 11p15 LOH or LOI may not be suitable for reduction of therapy (observation without adjuvant chemotherapy). *Deintensification strategy may not be suitable for patients with any adverse biomarker (including 1q gain or combined LOH at 1p and 16q).*
• Footnote u modified: Radiation therapy (RT) to the primary site is often given 10 to 14 days after surgery. We recognize the concern for overlapping fields if the abdomen and lung are treated at different times and recommend planning for possible abdominal and lung fields with initial abdominal RT planning, even if lung RT ultimately not given, to ~~avoid potential of~~ *minimize the degree of* overlapping fields. *Some degree of overlap between the fields is expected in order to cover the target.* Local stage III refers to staging of the primary tumor regardless of metastases. (Also for WILMS-4, WILMS-5B, WILMS-6A, WILMS-7A, WILMS-8, WILMS-9, WILMS-9B, WILMS-10, WILMS-11, WILMS-12, and WILMS-13)

WILMS-10
• Unilateral WT with focal anaplasia, primary nephrectomy, Stage IV, adjuvant chemotherapy regimen revised: Revised Regimen ~~UH-2~~ *UH-1*

WILMS-12
• Unilateral WT with focal anaplasia and predisposing condition, post-partial or total nephrectomy, Stage IV, adjuvant chemotherapy regimen revised: Switch to Revised Regimen ~~UH-2~~ *UH-1*

CONTINUED

Version 2.2025, 6/11/2025 © 2025 National Comprehensive Cancer Network® (NCCN®), All rights reserved. NCCN Guidelines® and this illustration may not be reproduced in any form without the express written permission of NCCN.

PLEASE NOTE that use of this NCCN Content is governed by the End-User License Agreement, and you MAY NOT distribute this Content or use it with any artificial intelligence model or tool.
Printed by A. S. M. FAZLUL KARIM CHOWDHURY on 4/20/2026 3:41:05 AM. Copyright © 2026 National Comprehensive Cancer Network, Inc. All Rights Reserved.

Updates in Version 1.2025 of the NCCN Guidelines for Wilms Tumor (Nephroblastoma) from Version 2.2024 include:

WILMS-13
- Bilateral WT with focal anaplasia with or without predisposing condition, post-partial or total nephrectomy, Stage IV, adjuvant chemotherapy regimen revised: Switch to Revised Regimen ~~UH-2~~ *UH-1*

WILMS-C (2 of 2)
- New section added: Focal Anaplasia
  - Bullet added: A clearly defined focus of anaplasia within the primary intrarenal tumor
  - Bullet added: Anaplasia must be confined to the renal parenchyma
  - Bullet added: Anaplasia must not be present within vascular spaces
  - Bullet added: Absence of severe nuclear pleomorphism and hyperchromasia (marked/severe nuclear unrest) in a non-anaplastic tumor
  - Bullet added: 1 or 2 foci of anaplasia, none >15 mm
- New section added: Diffuse Anaplasia
  - Bullet added: Non-localized (multifocal) anaplasia
  - Bullet added: Anaplasia beyond the tumor capsule
  - Bullet added: Anaplastic cells in intrarenal vessels, extrarenal vessels, renal sinus, extracapsular invasive sites, or metastatic deposits
  - Bullet added: Focal anaplasia with marked nuclear unrest in the remaining tumor
  - Bullet added: Anaplasia not clearly demarcated from non-anaplastic tumor
  - Bullet added: Anaplasia present in a biopsy or other incomplete tumor sample

WILMS-D (1 of 4)
- General principles, bullet 2
  - Sub-bullet 2 modified: Contralateral kidney exploration is ~~no longer routinely performed~~ *not recommended* for unilateral WT. ~~unless~~ *Biopsy should be considered for* concerning~~,~~ but indeterminate~~,~~ lesion(s) ~~are~~ seen on CT/MRI scan.
  - Sub-bullet 3 modified: Assess retroperitoneal adenopathy, *preoperative* tumor rupture, and ascites.
  - Sub-bullet 4 modified: Assess tumor involvement of *ipsilateral* renal veins or IVC.
- General principles, bullet 3
  - Sub-bullet 4 modified: Assess risk of morbidity or mortality, *intraoperative hemorrhage,* gross tumor spill, or residual tumor.
- Footnote b added: Thoracoabdominal incision can be considered but is rarely required.

WILMS-D (2 of 4)
- Surgical management: abdominal cavity
  - Bullet 2 modified: ~~Explore/~~ Biopsy*, as indicated, any abnormalities of* liver~~,~~ *or* peritoneal surfaces~~,~~ and *evaluate* vessels for tumor extension.

CONTINUED

Version 2.2025, 6/11/2025 © 2025 National Comprehensive Cancer Network® (NCCN®), All rights reserved. NCCN Guidelines® and this illustration may not be reproduced in any form without the express written permission of NCCN.

PLEASE NOTE that use of this NCCN Content is governed by the End-User License Agreement, and you MAY NOT distribute this Content or use it with any artificial intelligence model or tool.
Printed by A. S. M. FAZLUL KARIM CHOWDHURY on 4/20/2026 3:41:05 AM. Copyright © 2026 National Comprehensive Cancer Network, Inc. All Rights Reserved.

Updates in Version 1.2025 of the NCCN Guidelines for Wilms Tumor (Nephroblastoma) from Version 2.2024 include:

WILMS-D (3 of 4)

- Summary of Surgical Approach in Unilateral Tumors in Patients with Predisposing Conditions
  - Predisposing syndromes include: WAGR, Perlman syndrome, ~~and~~ Denys-Drash syndrome*, Beckwith-Wiedemann syndrome, Frasier syndrome, Sotos syndrome, Simpson-Golabi-Behmel syndrome, Bloom syndrome, Li-Fraumeni syndrome, and trisomy 18.*
- Summary of Surgical Approach to Bilateral WT
  - Bullet 2, sub-bullet 1 modified: ~~Possible criteria for successful~~ *Favorable imaging findings for performing* NSS:
    - ◊ Sub-sub-bullet removed: Small tumor size
    - ◊ Sub-sub-bullet modified: Peripheral or polar location~~ of the mass~~*, not involving renal hilum*
    - ◊ Sub-sub-bullet added: Planned resection spares one-third or more of normal kidney
    - ◊ Sub-sub-bullet added: No tumor invasion into the renal sinus, segmental vasculature, or collecting system
    - ◊ Sub-sub-bullet modified: Lack of invasion or encasement of *main* renal vessels
    - ◊ Sub-sub-bullet added: Distinct interface between tumor and renal parenchyma
  - Sub-bullet removed: Relative contraindications to NSS:
    - ◊ Sub-sub-bullet removed: Central location
    - ◊ Sub-sub-bullet removed: Proximity to the renal vessels
  - Bullet 4 sub-bullet 2 modified: If operating after chemotherapy, ~~enucleation is safe~~ *resection with a rim of normal parenchyma or enucleation (marginal resection removing tumor with an intact capsule) can be performed.*
  - Bullet 4, sub-bullet 3 added: Assessment of preoperative imaging may underestimate proportion of bilateral WT amenable to NSS, and surgeons should decide intraoperatively if NSS is feasible after complete mobilization of the kidney and tumor.
  - Bullet 4, sub-bullet 4 modified: *Unilateral nephrectomy and contralateral NSS* ~~Total nephrectomy is indicated for patients with bilateral WT if~~ *may be indicated if bilateral* partial nephrectomy is not feasible after 12 weeks of chemotherapy.

WILMS-G (1 of 4)

- Chemotherapy regimens
  - Bullet 4 modified: Regimen M: 9 doses of vincristine, 5 doses of dactinomycin, 5 doses of doxorubicin (cumulative dose 150 mg/m^2), 4 cycles of 5 daily doses of cyclophosphamide *(cumulative dose 8,800 mg/m^2)*, and 4 cycles of 5 daily doses of etoposide over 24 weeks. Dactinomycin and doxorubicin are given together, and cyclophosphamide and etoposide are given together. This regimen starts at week 7 for tumors requiring augmentation of therapy based on molecular markers or response of lung metastases to 6 weeks of DD4A.
  - Bullet 5 modified: Regimen I: 9 doses of vincristine, 4 doses of doxorubicin (cumulative dose 180 mg/m^2), 7 cycles of 3 ~~to~~ *or* 5 daily doses of cyclophosphamide *(cumulative dose 11,880 mg/m^2)*, and 3 cycles of 5 daily doses of etoposide. Doxorubicin and 3 daily doses of cyclophosphamide are given together, and 5 daily doses of cyclophosphamide and etoposide are given together. This regimen starts at week 7 for tumors requiring augmentation of therapy based on histology.
  - Bullet 6 added: Revised Regimen UH-1: 15 doses of vincristine, 5 doses of doxorubicin (cumulative dose 225 mg/m^2), 5 single doses of cyclophosphamide (total cumulative dose 14,800 mg/m^2), 5 cycles of 4 doses of cyclophosphamide, 5 doses of carboplatin, and 5 cycles of 4 doses of etoposide for stage IV WT with focal anaplasia.
  - Bullet 7 modified: Revised Regimen UH-2: 19 doses of vincristine, 5 doses of doxorubicin *(cumulative dose 225 mg/m^2)*, 5 doses of cyclophosphamide *(total cumulative dose 14,800 mg/m^2)*, 5 cycles of 4 daily doses of cyclophosphamide, 5 doses of carboplatin, 5 cycles of 4 daily doses of etoposide, *and* 2 cycles of 5 daily doses of irinotecan. This regimen is used for stage II–IV WT with diffuse anaplasia~~ and for stage IV Wilms tumor with focal anaplasia.~~

CONTINUED

Version 2.2025, 6/11/2025 © 2025 National Comprehensive Cancer Network® (NCCN®), All rights reserved. NCCN Guidelines® and this illustration may not be reproduced in any form without the express written permission of NCCN.

PLEASE NOTE that use of this NCCN Content is governed by the End-User License Agreement, and you MAY NOT distribute this Content or use it with any artificial intelligence model or tool.
Printed by A. S. M. FAZLUL KARIM CHOWDHURY on 4/20/2026 3:41:05 AM. Copyright © 2026 National Comprehensive Cancer Network, Inc. All Rights Reserved.

Updates in Version 1.2025 of the NCCN Guidelines for Wilms Tumor (Nephroblastoma) from Version 2.2024 include:

WILMS-G (2 of 4)
- Chemotherapy toxicity, bullet 5 modified: 0.8% of patients experience severe hepatopathy, including sinusoidal obstruction syndrome, which presents with abdominal distension, ascites, hepatomegaly, elevated transaminases, and bilirubin and thrombocytopenia. Severe hepatopathy occurred most often after a course of vincristine and dactinomycin, but radiation to the liver also contributes *to this level of hepatopathy*. Treatment could be safety reintroduced in the vast majority of patients after recovery.
- Supportive care, bullet 2 modified: Colony-stimulating factors (filgrastim or pegfilgrastim) are not necessary after doses of myelosuppressive agents in Regimens EE4A, DD4A, and VAD, but should be considered for cycles of cyclophosphamide and etoposide, and cyclophosphamide, doxorubicin, vincristine and cycles of cyclophosphamide, carboplatin, and etoposide in Regimen M; Regimen I; *Revised Regimen UH-1;* and *Revised* Regimen UH-2.
- Footnote a modified: ~~An FDA-approved biosimilar is an appropriate substitute for filgrastim and pegfilgrastim.~~ *An FDA-approved biosimilar is an appropriate substitute for any recommended systemic biologic therapy in the NCCN Guidelines.*

WILMS-G (3 of 4)
- Footnote b added: This difference was not statistically significant.

WILMS-H (1 of 5)
- Flank radiation, bullet 4 modified: Delivery of RT *has traditionally been done with 3D conformal photons, although IMRT and proton therapy are options at experienced centers* ~~is recommended with photons for flank, whole abdomen, and whole lung~~. Shielding of the contralateral kidney should be considered in the flank area. Boost modality should be more conformal with three-dimensional conformal RT (3D-CRT), intensity-modulated RT (IMRT), or protons.

WILMS-H (2 of 5)
- WLI, Bullet 3, sub-bullet 1 modified: Anteroposterior/posteroanterior (AP/PA) ~~or~~*,* IMRT, *or protons*.
- Section removed: Radiation Doses
  - Sub-bullet removed: Flank (10.8 Gy at 1.8 Gy per fraction) for local stage III
  - Sub-bullet removed: Whole abdomen (10.5 Gy at 1.5 Gy per fraction)
  - Sub-bullet removed: Whole lung (12 Gy at 1.5 Gy per fraction or 10.5 Gy at 1.5 Gy per fraction if <12 mo)
  - Sub-bullet removed: LN irradiation (10.8 Gy at 1.8 Gy per fraction) for resected LN metastases and focal boost (to 19.8 Gy at 1.8 Gy per fraction) for unresected LN metastases.
- Gross Residual Tumor, Sub-bullet removed: Boost irradiation 10.8 Gy in 6 fractions for a total dose of 21.6 Gy

WILMS-H (3 of 5)
- New page added

WILMS-H (4 of 5)
- New page added

WILMS-J (1 of 2)
- Chemotherapy
  - Regimen added: Regimen: UH-1 (revised)
    - Sub-bullet added: Chemotherapy agents: vincristine, doxorubicin, cyclophosphamide, carboplatin, etoposide
    - Sub-bullet added: Potential late effects: Peripheral neuropathy, cardiac toxicity, subsequent leukemia, testicular or ovarian hormonal dysfunction, infertility, urinary tract toxicity, renal toxicity, bladder malignancy
  - Regimen modified: Regimen: UH-2 *(revised)*
    - Chemotherapy agent added: irinotecan
    - Potential late effect removed: ototoxicity

CONTINUED

Version 2.2025, 6/11/2025 © 2025 National Comprehensive Cancer Network® (NCCN®), All rights reserved. NCCN Guidelines® and this illustration may not be reproduced in any form without the express written permission of NCCN.

PLEASE NOTE that use of this NCCN Content is governed by the End-User License Agreement, and you MAY NOT distribute this Content or use it with any artificial intelligence model or tool.
Printed by A. S. M. FAZLUL KARIM CHOWDHURY on 4/20/2026 3:41:05 AM. Copyright © 2026 National Comprehensive Cancer Network, Inc. All Rights Reserved.

INTRODUCTION TO WILMS TUMOR

All patients with suspected Wilms tumor (WT) should receive comprehensive care by a multidisciplinary team with experience in managing renal tumors led by a pediatric oncologist.

WT is largely a disease of children, though adults may occasionally present with high-risk disease. Treatment for adults with WT is similar to treatment for pediatric patients; thus, referral or partnership with a pediatric oncologist familar with the treatment of WT is recommended.

NCCN recommendations have been developed to be inclusive of individuals of all sexual and gender identities to the greatest extent possible. On this page, the terms male and female refer to sex assigned at birth.

Epidemiology of Wilms Tumor

- WT accounts for 5% of childhood cancers and is the most common primary renal tumor in children (accounts for >90% of renal tumors in patients <20 years). Five-year survival for these patients is >90% with appropriate treatment. However, outcome of some groups, particularly those with diffuse anaplastic WT (DAWT), remains poor.
  - Incidence of WT is highest among African American children, followed by white children, and children of Asian descent have the lowest incidence.[1] More than 75% of WT present between 1–5 years (most commonly 3 years).[2]
- Most patients have a solitary tumor at presentation. However, 5%–13% have bilateral tumors, and 10% have multifocal tumors in a single kidney.[3-6]
  - For unilateral tumors, the median age at diagnosis is 35 months for males, and 42 months for females.[1]
  - For bilateral tumors, the median age at diagnosis is 23 months for males, and 28.5 months for females.[1]

Clinical Presentation

- Most patients present with abdominal distention and/or presence of an abdominal mass (83%) with or without abdominal pain (37%), fever (23%), hematuria (21%–25%), and hypertension (20%–25%). Less common symptoms include: varicocele, hernia, enlarged testicle, congestive heart failure, hypoglycemia, Cushing syndrome, pleural effusion, and acute abdomen.
- A healthy-appearing child with an abdominal mass is more likely to have WT, whereas a child with neuroblastoma tends to be ill-appearing at presentation.
- Calcification of the tumor appears in approximately 5%–10% of WTs, versus approximately 60%–70% of neuroblastomas.
- Almost 10% of patients with WT have coagulopathy (acquired von Willebrand disease).[7-9]
- Most common sites of hematogenous metastases include: lung (81%), lung and liver (15%), and other (4%).[10] Spread to regional lymph nodes (LNs) also occurs.
- WT is associated with genetic predisposing conditions in 10% to 15% of cases, with some reports suggesting >30% of cases, such as Denys-Drash syndrome (male pseudohermaphroditism and glomerulopathy); WAGR syndrome (WT, aniridia, genitourinary abnormalities, and range of intellectual disability); Beckwith-Wiedemann syndrome (macroglossia, hemihyperplasia, gigantism, and umbilical hernia); Perlman syndrome; Frasier syndrome; Sotos syndrome; Simpson-Golabi-Behmel syndrome; Bloom syndrome; Li-Fraumeni syndrome; and trisomy 18. See WILMS-I (2 of 5).[11-15]
- Aniridia is present in 1% of children with WT, and hemihyperplasia appears in 2%–3% of patients with WT.[15-17]
- Genitourinary malformations (ie, cryptorchidism, hypospadias, fused [horseshoe] kidneys) are found in 5% of patients with WT.[17,18]
- If a predisposing condition is present, routine screening for WT is recommended with physical exam (PE) and renal ultrasound (US) every 3 months until 7 years of age (ie, all of year 6).[19,20]
- Compared with children with unilateral disease, children with multifocal/bilateral disease present at a younger age and are often identified as part of a surveillance program for patients with a predisposing condition.[19,20]

Note: All recommendations are category 2A unless otherwise indicated.

Version 2.2025, 6/11/2025 © 2025 National Comprehensive Cancer Network® (NCCN®), All rights reserved. NCCN Guidelines® and this illustration may not be reproduced in any form without the express written permission of NCCN.

PLEASE NOTE that use of this NCCN Content is governed by the End-User License Agreement, and you MAY NOT distribute this Content or use it with any artificial intelligence model or tool.
Printed by A. S. M. FAZLUL KARIM CHOWDHURY on 4/20/2026 3:41:05 AM. Copyright © 2026 National Comprehensive Cancer Network, Inc. All Rights Reserved.

INTRODUCTION TO WILMS TUMOR

Treatment

- **Treatment for WT ranges from observation after surgery only, to intensive chemotherapy, radiation, and surgery, depending on whether the WT is unilateral or bilateral, local stage, presence of metastases, patient age, tumor weight, biologic risk factors, histology, and clinical response to therapy.**
- **Consult pediatric oncologic surgeon or urologist when renal tumor is discovered. Second opinion consultations and referral to tertiary care centers should be considered for complex surgeries.**
- **Imaging studies, pathology, and tumor genetic testing results that are used to determine stage and risk group should be performed in consultation with experienced specialists.**
- **Consulting a radiation oncologist is recommended at time of suspected or confirmed diagnosis of WT.**
- **Studies of long-term survivors show these therapies are effective; however, judicious use of available therapies is necessary to maximize cure while minimizing long-term toxicities.**
- **Appropriate assignment of therapy to balance these goals employs an evolving system of risk stratification.**
- **Referral for cancer predisposition consultation is recommended when available for all patients with WT and strongly encouraged for patients with multifocal or bilateral WT.[21]**
- **Recommend referral to infertility risk/fertility preservation counseling for patients treated with chemotherapy; strongly encourage prior to treatment with regimen M, regimen I, revised regimen UH-1, revised regimen UH-2, or whole abdominal irradiation (WAI).[22-24]**

Note: All recommendations are category 2A unless otherwise indicated.

Version 2.2025, 6/11/2025 © 2025 National Comprehensive Cancer Network® (NCCN®), All rights reserved. NCCN Guidelines® and this illustration may not be reproduced in any form without the express written permission of NCCN.

PLEASE NOTE that use of this NCCN Content is governed by the End-User License Agreement, and you MAY NOT distribute this Content or use it with any artificial intelligence model or tool.
Printed by A. S. M. FAZLUL KARIM CHOWDHURY on 4/20/2026 3:41:05 AM. Copyright © 2026 National Comprehensive Cancer Network, Inc. All Rights Reserved.

INTRODUCTION TO WILMS TUMOR
REFERENCES

[1] Steliarova-Foucher E, Colombet M, Ries LAG, et al. International incidence of childhood cancer, 2001-10: a population-based registry study. Lancet Oncol 2017;18:719-731.
[2] Howlader N, Noone AM, Krapcho M, et al. SEER Cancer Statistics Review, 1975-2017, based on November 2019 SEER data submission, posted to the SEER web site, April 2020. Bethesda, MD: National Cancer Institute; 2020.
[3] D'Angio GJ. National Wilms' Tumor Study, Seattle, WA: NWTS Data and Statistical Center: 1991 [Informational Bulletin #19].
[4] Breslow NE, Churchill G, Nesmith B, et al. Clinicopathologic features and prognosis for Wilms' tumor patients with metastases at diagnosis. Cancer 1986;58:2501-2511.
[5] Hadley GP, Jacobs C. The clinical presentation of Wilms' tumour in black children. S Afr Med J 1990;77:565-567.
[6] Ehrlich P, Chi YY, Chintagumpala MM, et al. Results of the first prospective multi-institutional treatment study in children with bilateral Wilms tumor (AREN0534): A report from the Children's Oncology Group. Ann Surg 2017;266:470-478.
[7] Green DM. Diagnosis and management of malignant solid tumors in infants and children. 1985. Martinus Nijhoff Publishing, Boston, MA.
[8] Coppes MJ, Zandvoort SW, Sparling CR, et al. Acquired von Willebrand disease in Wilms' tumor patients. J Clin Oncol 1992;10:422-427.
[9] Baxter PA, Nuchtern JG, Guillerman RP, et al. Acquired von Willebrand syndrome and Wilms tumor: not always benign. Pediatr Blood Cancer 2009;52:392-394.
[10] Ehrlich PF, Ferrer FA, Ritchey ML, et al. Hepatic metastasis at diagnosis in patients with Wilms tumor is not an independent adverse prognostic factor for stage IV Wilms tumor: a report from the Children's Oncology Group/National Wilms Tumor Study Group. Ann Surg 2009;250:642-648.
[11] Turner JT, Brzezinski J, Dome JS. Wilms tumor predisposition. 2003 Dec 19 [updated 2022 Mar 4]. In: Adam MP, Everman DB, Mirzaa GM, et al, eds. GeneReviews® [Internet]. Seattle (WA): University of Washington, Seattle; 1993-2022. Available from: https://www.ncbi.nlm.nih.gov/books/NBK1294.
[12] Grundy P, Coppes M. An overview of the clinical and molecular genetics of Wilms' tumor. Med Pediatr Oncol 1996;27:394-397.
[13] Blakely ML, Ritchey ML. Controversies in the management of Wilms tumor. Semin Pediatr Surg 2001;10:127-131.
[14] Douglass EC, Look AT, Webber B, et al. Hyperdiploidy and chromosomal rearrangements define the anaplastic variant of Wilms' tumor. J Clin Oncol 1986;4:975-981.
[15] Riccardi VM, Hittner HM, Francke U, et al. The aniridia-Wilms' tumor association: The critical role of chromosome band 11p13. Cancer Genet 1980;2:131-137.
[16] Palmer N, Evans AE. The association of aniridia and Wilms' tumor: methods of surveillance and diagnosis. Med Pediatr Oncol 1983;11:73-75.
[17] Pendergrass TW. Congenital anomalies in children with Wilms' tumor: a new survey. Cancer 1976;37:403-409.
[18] Breslow NE, Beckwith JB. Epidemiological features of Wilms' tumor: results of the National Wilms' Tumor Study. J Natl Cancer Inst 1982;68:429-436.
[19] Brioude F, Kalish JM, Mussa A, et al. Expert consensus document: Clinical and molecular diagnosis, screening and management of Beckwith-Wiedemann syndrome: an international consensus statement. Nat Rev Endocrinol 2018;14:229-249.
[20] Kalish JM, Doros L, Helman LJ, et al. Surveillance recommendations for children with overgrowth syndromes and predisposition to Wilms tumors and hepatoblastoma. Clin Cancer Res 2017;23:e115-e122.
[21] Hol JA, Kuiper RP, van Dijk F, et al. Prevalence of (epi)genetic predisposing factors in a 5-year unselected national Wilms tumor cohort: a comprehensive clinical and genomic characterization. J Clin Oncol 2022;40:1892-1902.
[22] Practice Committee of the American Society for Reproductive Medicine. Fertility preservation in patients undergoing gonadotoxic therapy or gonadectomy: a committee opinion. Fertil Steril 2019;112:1022-1033.
[23] Lee SJ, Schover LR, Partridge AH, et al. American Society of Clinical Oncology recommendations on fertility preservation in cancer patients. J Clin Oncol 2006;24:2917-2931.
[24] van der Perk MEM, Cost NG, Bos AME, et al. White paper: Oncofertility in pediatric patients with Wilms tumor. Int J Cancer 2022;151:843-858.

Note: All recommendations are category 2A unless otherwise indicated.

Version 2.2025, 6/11/2025 © 2025 National Comprehensive Cancer Network® (NCCN®), All rights reserved. NCCN Guidelines® and this illustration may not be reproduced in any form without the express written permission of NCCN.

PLEASE NOTE that use of this NCCN Content is governed by the End-User License Agreement, and you MAY NOT distribute this Content or use it with any artificial intelligence model or tool.
Printed by A. S. M. FAZLUL KARIM CHOWDHURY on 4/20/2026 3:41:05 AM. Copyright © 2026 National Comprehensive Cancer Network, Inc. All Rights Reserved.

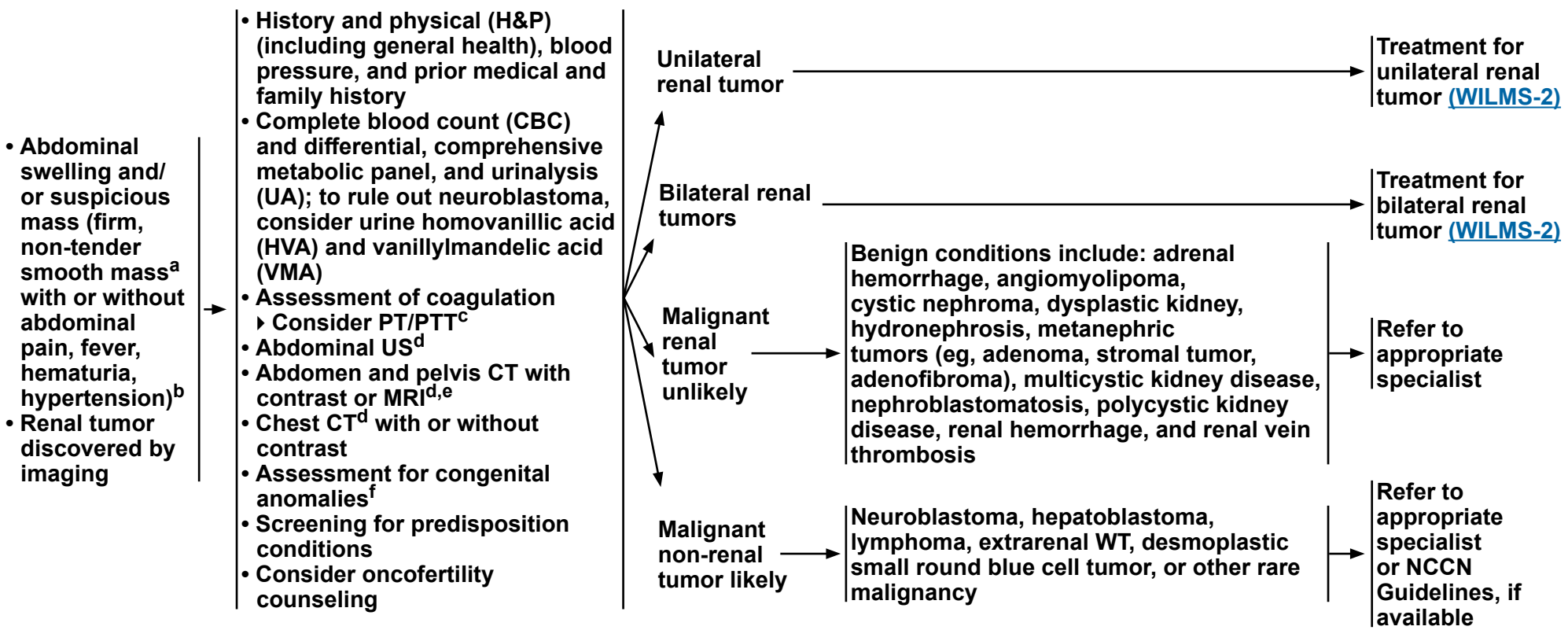

[a] Avoid vigorous or frequent palpation.
[b] Principles of Abdominal Mass Evaluation (WILMS-A).
[c] Consider screening for acquired von Willebrand disease if prothrombin time/partial thromboplastin time (PT/PTT) is abnormal.
[d] Principles of Imaging (WILMS-B).
[e] CT with multiplanar reconstruction or MRI with contrast is recommended; MRI may be used when bilateral disease is suspected, as it may help to distinguish between nephrogenic rests and WT.
[f] Conditions that predispose to the development of WT include genetic disorders such as Denys-Drash, WAGR, Beckwith-Wiedemann, Frasier, and Perlman syndromes; contralateral nephrogenic rests in children <12 months. Ten percent to 33% of WT occurs in children with predisposing conditions. Children with known predisposing conditions should be screened for WT with PE and abdominal US every 3 months until 7 years of age (ie, all of year 6). See Principles of Cancer Risk Assessment and Counseling (WILMS-I).

Note: All recommendations are category 2A unless otherwise indicated.

Version 2.2025, 6/11/2025 © 2025 National Comprehensive Cancer Network® (NCCN®), All rights reserved. NCCN Guidelines® and this illustration may not be reproduced in any form without the express written permission of NCCN.

PLEASE NOTE that use of this NCCN Content is governed by the End-User License Agreement, and you MAY NOT distribute this Content or use it with any artificial intelligence model or tool.
Printed by A. S. M. FAZLUL KARIM CHOWDHURY on 4/20/2026 3:41:05 AM. Copyright © 2026 National Comprehensive Cancer Network, Inc. All Rights Reserved.

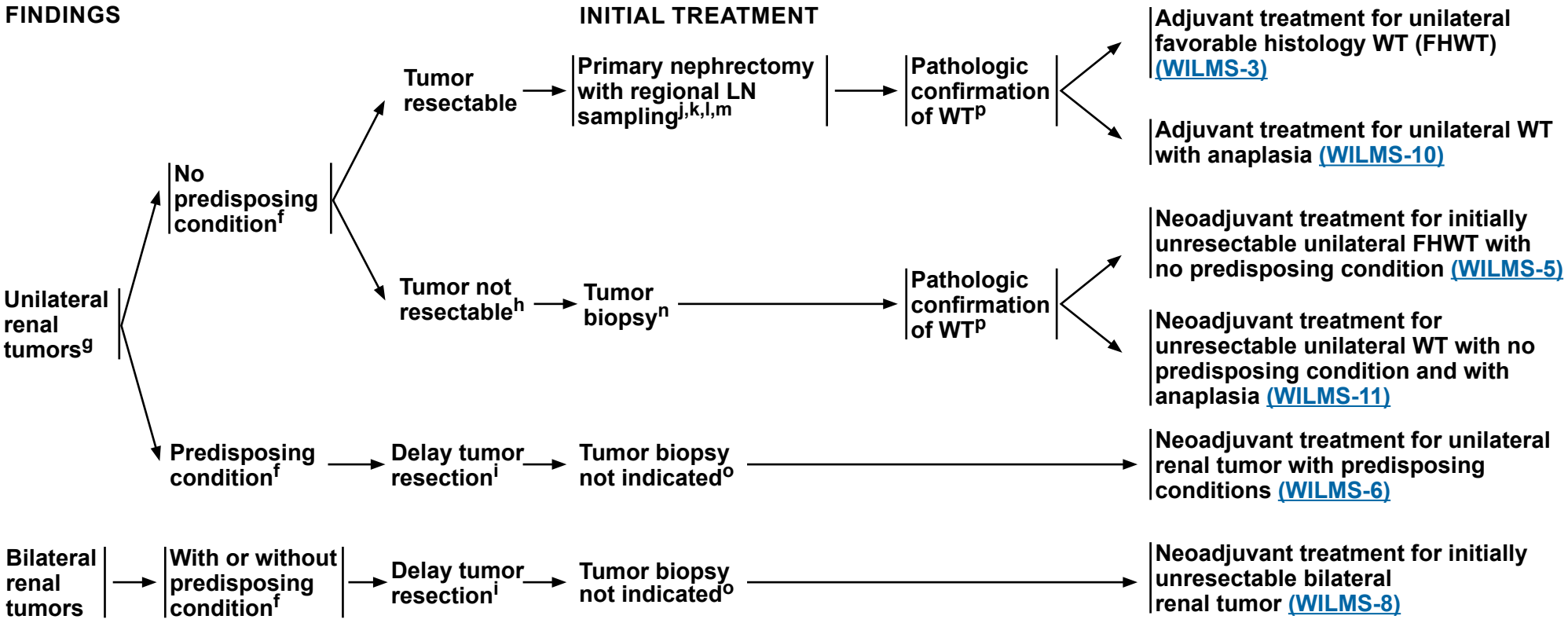

[f] Conditions that predispose to the development of WT include genetic disorders such as Denys-Drash, WAGR, Beckwith-Wiedemann, Frasier, and Perlman syndromes; contralateral nephrogenic rests in children <12 months. Ten percent to 33% of WT occurs in children with predisposing conditions. Children with known predisposing conditions should be screened for WT with PE and abdominal US every 3 months until 7 years of age (ie, all of year 6). See Principles of Cancer Risk Assessment and Counseling (WILMS-I).

[g] Limited data exist for patients with unilateral multifocal tumors; thus, the NCCN Panel recommends that either approach is reasonable.

[h] Renal tumors may be unresectable at diagnosis because of tumor size, tumor thrombus extending above the hepatic veins, bilateral tumors, involvement of surrounding organs, or pulmonary function compromise from extensive metastatic disease.

[i] For tumors <2 cm, consider close surveillance given the challenge of differentiating WT from proliferating nephrogenic rests.

[j] Nephrectomy and regional LN sampling are recommended as initial therapy for resectable tumors. LN sampling MUST be performed for adequate staging; recommend obtaining a minimum of >5 (nodes) from areas in renal hilum anatomically expected to represent nodes associated with kidney.

[k] Principles of Pathology (WILMS-C).

[l] Principles of Surgery (WILMS-D).

[m] COG Staging of Wilms Tumor (ST-1).

[n] Biopsy is strongly recommended for diagnosis and so that molecular biomarker testing can be done earlier and used for treatment decisions. See Principles of Biopsy (WILMS-E).

[o] Initial biopsy is not recommended for children with imaging findings of bilateral renal tumors, or unilateral tumor and known predisposing condition, but biopsy should be considered for children in those categories who also are >10 years of age, or with concern for pathology other than WT.

[p] For FHWT, perform molecular analysis to identify loss of heterozygosity (LOH) of 1p, 16q, 11p, and 1q gain. If tumor is not WT, refer to appropriate specialist or NCCN Guidelines, if available.

Note: All recommendations are category 2A unless otherwise indicated.

Version 2.2025, 6/11/2025 © 2025 National Comprehensive Cancer Network® (NCCN®), All rights reserved. NCCN Guidelines® and this illustration may not be reproduced in any form without the express written permission of NCCN.

PLEASE NOTE that use of this NCCN Content is governed by the End-User License Agreement, and you MAY NOT distribute this Content or use it with any artificial intelligence model or tool.
Printed by A. S. M. FAZLUL KARIM CHOWDHURY on 4/20/2026 3:41:05 AM. Copyright © 2026 National Comprehensive Cancer Network, Inc. All Rights Reserved.

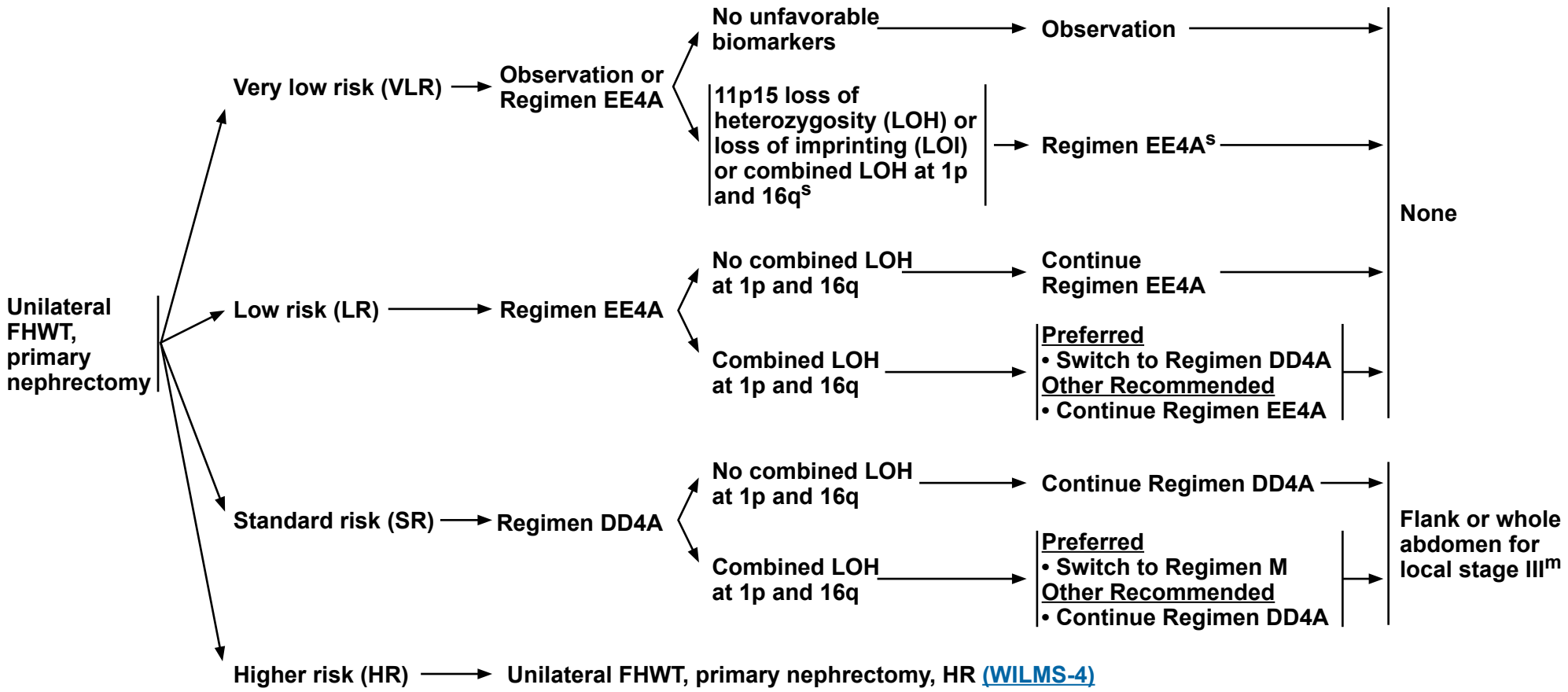

[m] COG Staging of Wilms Tumor (ST-1).
[q] Initial and Final Risk Assessment for FHWT (WILMS-F).
[r] Principles of Chemotherapy (WILMS-G).
[s] A retrospective analysis of the biology suggests patients with VLR FHWT and 11p15 LOH or LOI may not be suitable for reduction of therapy (observation without adjuvant chemotherapy). Deintensification strategy may not be suitable for patients with any adverse biomarker (including 1q gain or combined LOH at 1p and 16q).
[t] Principles of Radiation Therapy (WILMS-H).
[u] Radiation therapy (RT) to the primary site is often given 10 to 14 days after surgery. We recognize the concern for overlapping fields if the abdomen and lung are treated at different times and recommend planning for possible abdominal and lung fields with initial abdominal RT planning, even if lung RT ultimately not given, to minimize the degree of overlapping fields. Some degree of overlap between the fields is expected in order to cover the target. Local stage III refers to staging of the primary tumor regardless of metastases.

Note: All recommendations are category 2A unless otherwise indicated.

Version 2.2025, 6/11/2025 © 2025 National Comprehensive Cancer Network® (NCCN®), All rights reserved. NCCN Guidelines® and this illustration may not be reproduced in any form without the express written permission of NCCN.

PLEASE NOTE that use of this NCCN Content is governed by the End-User License Agreement, and you MAY NOT distribute this Content or use it with any artificial intelligence model or tool.
Printed by A. S. M. FAZLUL KARIM CHOWDHURY on 4/20/2026 3:41:05 AM. Copyright © 2026 National Comprehensive Cancer Network, Inc. All Rights Reserved.

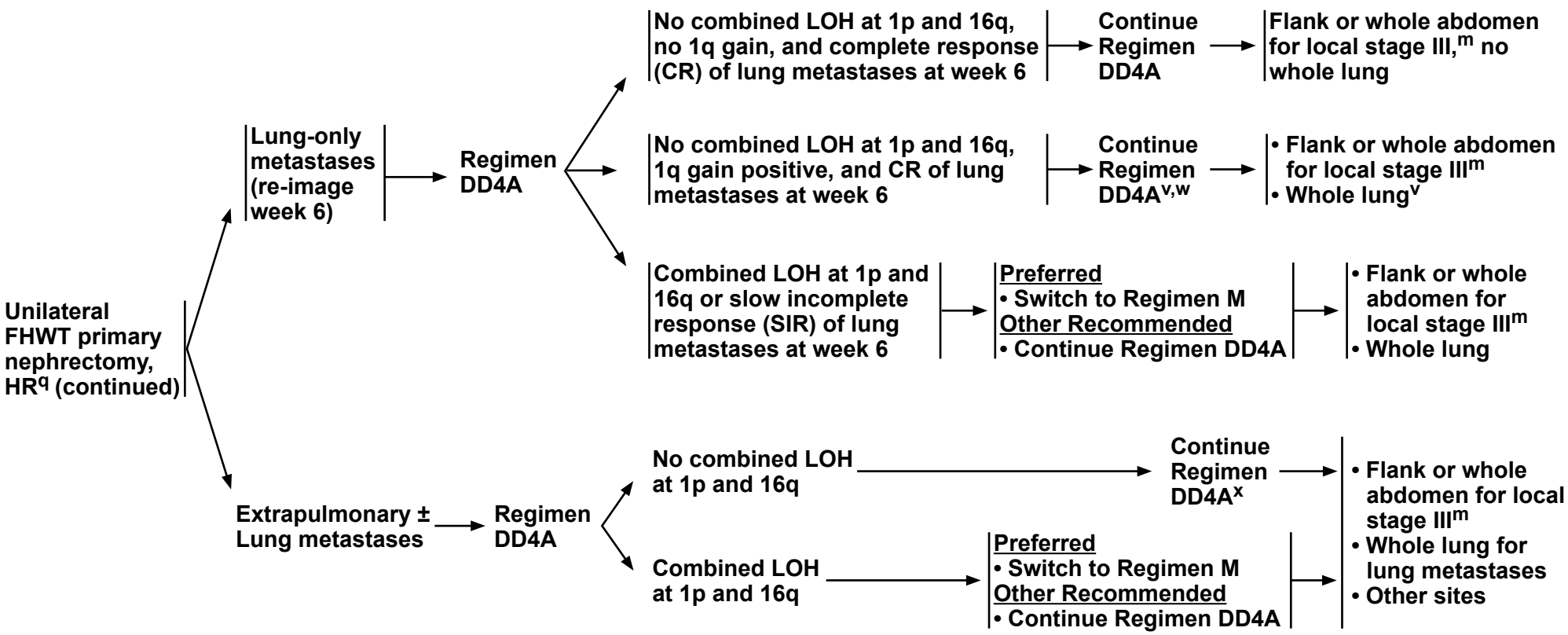

[m] COG Staging of Wilms Tumor (ST-1).
[q] Initial and Final Risk Assessment for FHWT (WILMS-F).
[r] Principles of Chemotherapy (WILMS-G).
[t] Principles of Radiation Therapy (WILMS-H).
[u] RT to the primary site is often given 10 to 14 days after surgery. We recognize the concern for overlapping fields if the abdomen and lung are treated at different times and recommend planning for possible abdominal and lung fields with initial abdominal RT planning, even if lung RT ultimately not given, to minimize the degree of overlapping fields. Some degree of overlap between the fields is expected in order to cover the target. Local stage III refers to staging of the primary tumor regardless of metastases.

[v] Patients with 1q gain, no combined LOH, and CR of lung metastases at week 6 should continue on Regimen DD4A but should have whole lung irradiation (WLI). Omission of WLI for patients with CR of lung metastases at week 6 and 1q gain is not recommended because of lower event-free survival (EFS; 57%).
[w] Intensification of chemotherapy for this group has not been studied, but can be considered.
[x] Patients with extrapulmonary metastases were switched to Regimen M on AREN0533 trial, but when compared to outcomes with DD4A on NWTS-5, a significant benefit was not demonstrated (4-year EFS 76% for Regimen M vs. 65% for DD4A [P = .26]; 4-year overall survival (OS) 89% for Regimen M vs. 86.5% for DD4A) (Benedetti DJ, et al. Cancer 2024;130:947-961).

Note: All recommendations are category 2A unless otherwise indicated.

Version 2.2025, 6/11/2025 © 2025 National Comprehensive Cancer Network® (NCCN®), All rights reserved. NCCN Guidelines® and this illustration may not be reproduced in any form without the express written permission of NCCN.

PLEASE NOTE that use of this NCCN Content is governed by the End-User License Agreement, and you MAY NOT distribute this Content or use it with any artificial intelligence model or tool.
Printed by A. S. M. FAZLUL KARIM CHOWDHURY on 4/20/2026 3:41:05 AM. Copyright © 2026 National Comprehensive Cancer Network, Inc. All Rights Reserved.

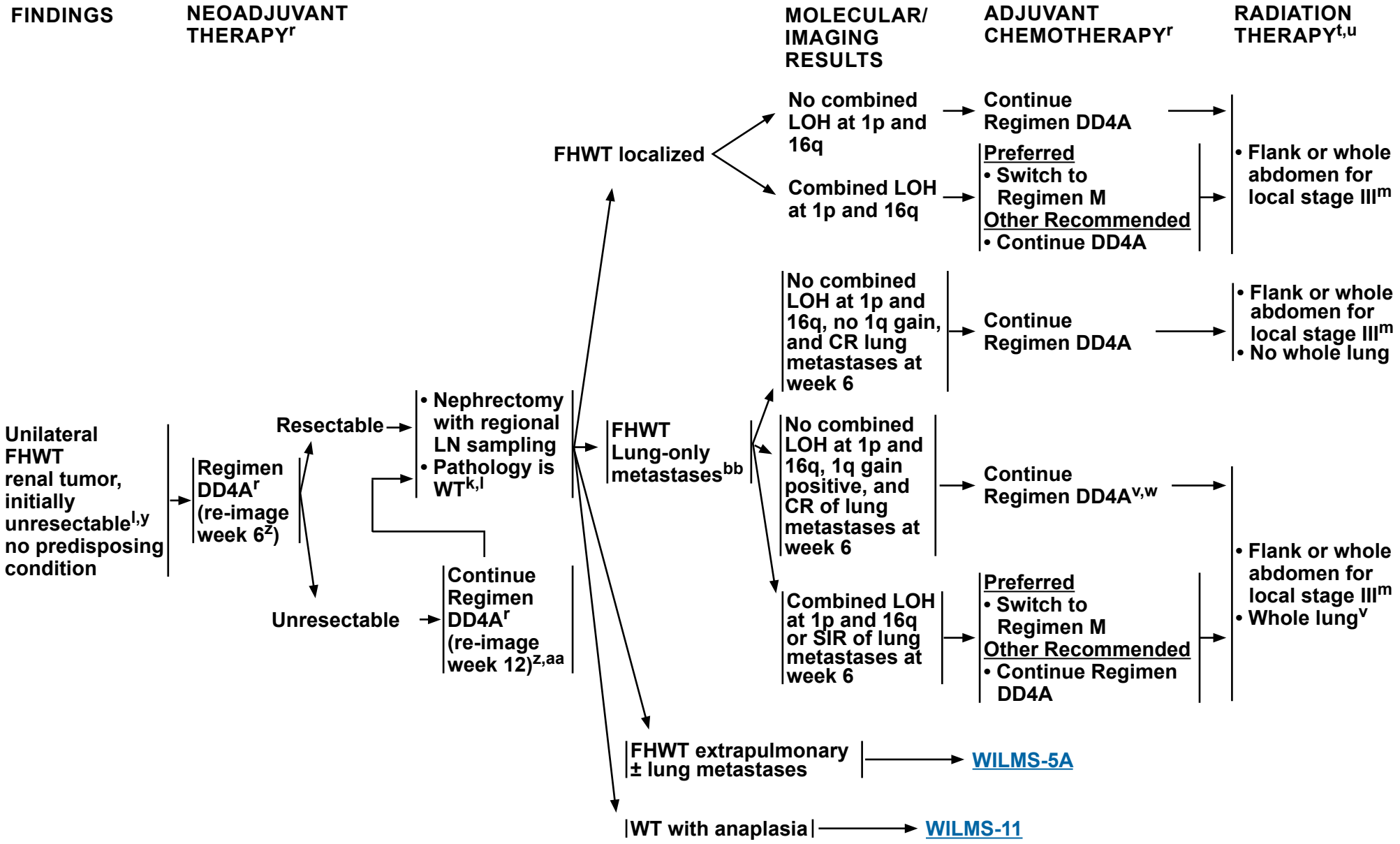

Footnotes on WILMS-5B

Note: All recommendations are category 2A unless otherwise indicated.

Version 2.2025, 6/11/2025 © 2025 National Comprehensive Cancer Network® (NCCN®), All rights reserved. NCCN Guidelines® and this illustration may not be reproduced in any form without the express written permission of NCCN.

PLEASE NOTE that use of this NCCN Content is governed by the End-User License Agreement, and you MAY NOT distribute this Content or use it with any artificial intelligence model or tool.
Printed by A. S. M. FAZLUL KARIM CHOWDHURY on 4/20/2026 3:41:05 AM. Copyright © 2026 National Comprehensive Cancer Network, Inc. All Rights Reserved.

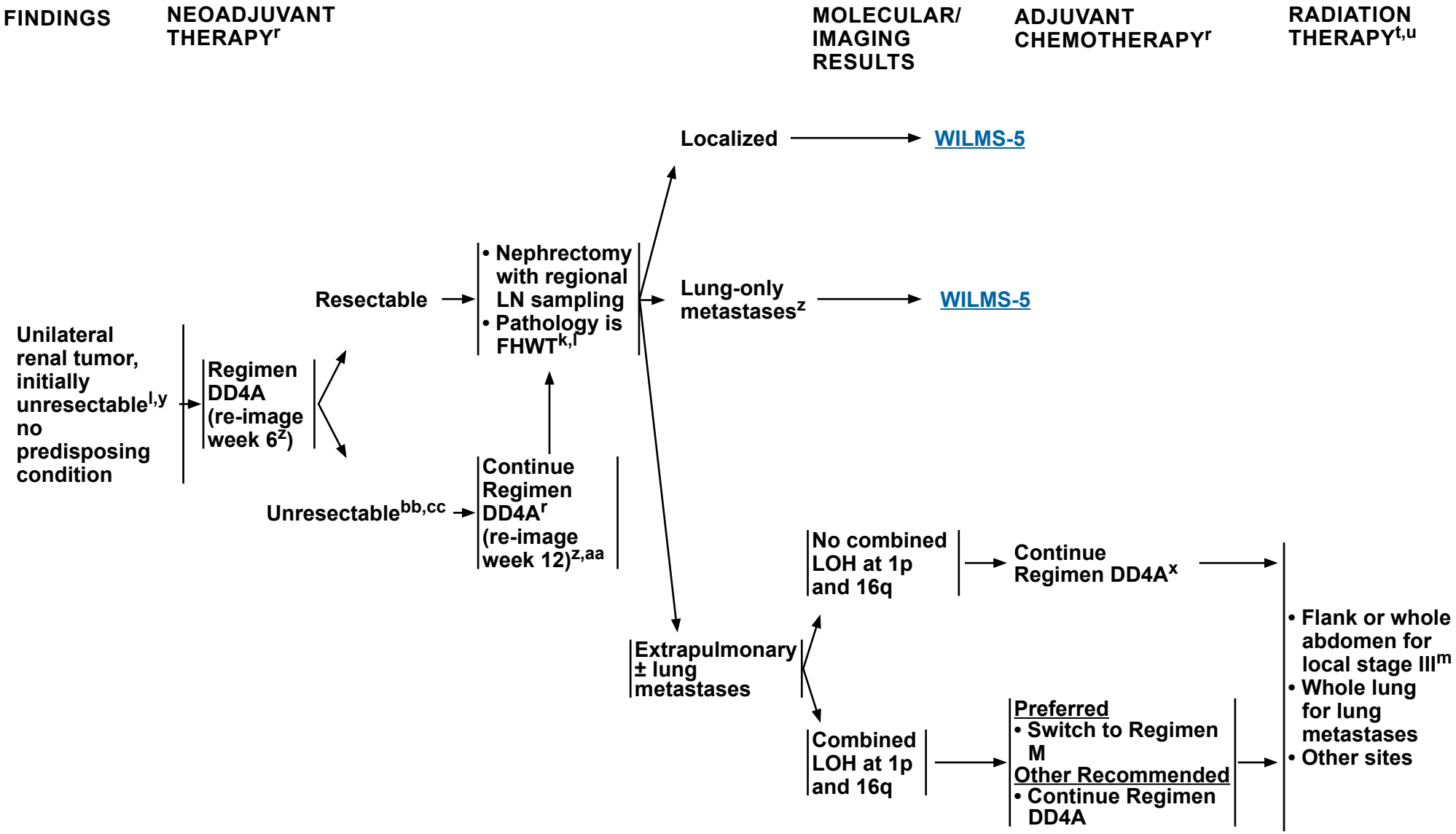

Footnotes on WILMS-5B

Note: All recommendations are category 2A unless otherwise indicated.

Version 2.2025, 6/11/2025 © 2025 National Comprehensive Cancer Network® (NCCN®), All rights reserved. NCCN Guidelines® and this illustration may not be reproduced in any form without the express written permission of NCCN.

PLEASE NOTE that use of this NCCN Content is governed by the End-User License Agreement, and you MAY NOT distribute this Content or use it with any artificial intelligence model or tool.
Printed by A. S. M. FAZLUL KARIM CHOWDHURY on 4/20/2026 3:41:05 AM. Copyright © 2026 National Comprehensive Cancer Network, Inc. All Rights Reserved.

FOOTNOTES

[k] Principles of Pathology (WILMS-C).
[l] Principles of Surgery (WILMS-D).
[m] COG Staging of Wilms Tumor (ST-1).
[r] Principles of Chemotherapy (WILMS-G).
[t] Principles of Radiation Therapy (WILMS-H).
[u] RT to the primary site is often given 10 to 14 days after surgery. We recognize the concern for overlapping fields if the abdomen and lung are treated at different times and recommend planning for possible abdominal and lung fields with initial abdominal RT planning, even if lung RT ultimately not given, to minimize the degree of overlapping fields. Some degree of overlap between the fields is expected in order to cover the target. Local stage III refers to staging of the primary tumor regardless of metastases.
[v] Patients with 1q gain, no combined LOH, and CR of lung metastases at week 6 should continue on Regimen DD4A but should have WLI. Omission of WLI for patients with CR of lung metastases at week 6 and 1q gain is not recommended because of lower EFS (57%).
[w] Intensification of chemotherapy for this group has not been studied, but can be considered.
[x] Patients with extrapulmonary metastases were switched to Regimen M on AREN0533 trial, but when compared to outcomes with DD4A on NWTS-5, a significant benefit was not demonstrated (4-year EFS 76% for Regimen M vs. 65% for DD4A [P = .26]; 4-year OS 89% for Regimen M vs. 86.5% for DD4A) (Benedetti DJ, et al. Cancer 2024;130:947-961).
[y] Upfront biopsy with delayed nephrectomy should be limited to specific circumstances where upfront nephrectomy is contraindicated. See Principles of Surgery (WILMS-D).
[z] Repeat imaging of lungs before general anesthesia.
[aa] Tumors should be resected by 12 weeks at the latest (total nephrectomy), because continued significant tumor shrinkage was not seen after this point in treatment.
[bb] In patients who only have metastases in the lungs, assess response of lung metastases at 6 weeks of chemotherapy to determine need for WLI.
[cc] If imaging shows tumor progression (increase in size), nephrectomy OR rebiopsy (to evaluate for anaplasia or rhabdomyomatous changes) should be performed.

Note: All recommendations are category 2A unless otherwise indicated.

Version 2.2025, 6/11/2025 © 2025 National Comprehensive Cancer Network® (NCCN®), All rights reserved. NCCN Guidelines® and this illustration may not be reproduced in any form without the express written permission of NCCN.

PLEASE NOTE that use of this NCCN Content is governed by the End-User License Agreement, and you MAY NOT distribute this Content or use it with any artificial intelligence model or tool.
Printed by A. S. M. FAZLUL KARIM CHOWDHURY on 4/20/2026 3:41:05 AM. Copyright © 2026 National Comprehensive Cancer Network, Inc. All Rights Reserved.

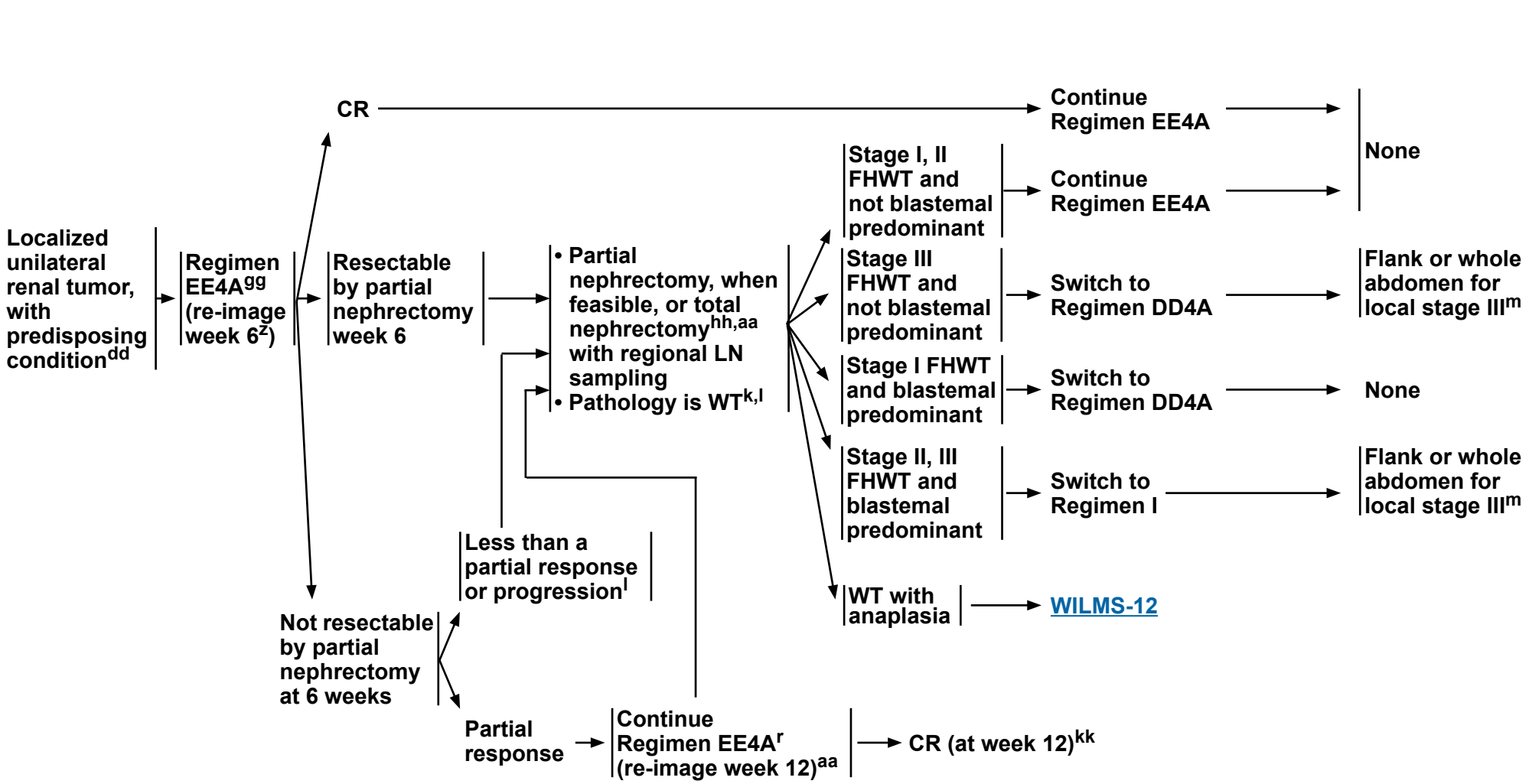

Footnotes on WILMS-6A

Note: All recommendations are category 2A unless otherwise indicated.

Version 2.2025, 6/11/2025 © 2025 National Comprehensive Cancer Network® (NCCN®), All rights reserved. NCCN Guidelines® and this illustration may not be reproduced in any form without the express written permission of NCCN.

PLEASE NOTE that use of this NCCN Content is governed by the End-User License Agreement, and you MAY NOT distribute this Content or use it with any artificial intelligence model or tool.
Printed by A. S. M. FAZLUL KARIM CHOWDHURY on 4/20/2026 3:41:05 AM. Copyright © 2026 National Comprehensive Cancer Network, Inc. All Rights Reserved.

FOOTNOTES

[k] Principles of Pathology (WILMS-C).
[l] Principles of Surgery (WILMS-D).
[m] COG Staging of Wilms Tumor (ST-1).
[r] Principles of Chemotherapy (WILMS-G).
[t] Principles of Radiation Therapy (WILMS-H).
[u] RT to the primary site is often given 10 to 14 days after surgery. We recognize the concern for overlapping fields if the abdomen and lung are treated at different times and recommend planning for possible abdominal and lung fields with initial abdominal RT planning, even if lung RT ultimately not given, to minimize the degree of overlapping fields. Some degree of overlap between the fields is expected in order to cover the target. Local stage III refers to staging of the primary tumor regardless of metastases.
[z] Repeat imaging of lungs before general anesthesia.
[aa] Tumors should be resected by week 12 at the latest (partial or total nephrectomy), because continued significant tumor shrinkage was not seen after that point in treatment.
[dd] Upfront biopsy or resection is discouraged.
[ee] Neoadjuvant chemotherapy is not a criterion for upstaging to stage III in this population.
[ff] If biopsied, a tumor is considered to be stage III for determination of chemotherapy regimen, but biopsy alone does not upstage a tumor to stage III for determining whether to give radiation.
[gg] If patient had biopsy upfront (not recommended), start with Regimen VAD.
[hh] Indications for complete nephrectomy for unilateral WT (with predisposing condition) are described in Principles of Surgery (WILMS-D).
[ii] Molecular biomarkers were not used to direct therapy in the AREN0534 trial.
[jj] Use of biomarkers from post-chemotherapy tumor has not been established to correlate with outcome, nor has it been used to direct therapy in a prospective trial. Outcomes of the AREN0534 study were excellent despite this. Regimen M was not studied in this population.
[kk] Refer to CR pathway at the top for treatment recommendations.

Note: All recommendations are category 2A unless otherwise indicated.

Version 2.2025, 6/11/2025 © 2025 National Comprehensive Cancer Network® (NCCN®), All rights reserved. NCCN Guidelines® and this illustration may not be reproduced in any form without the express written permission of NCCN.

PLEASE NOTE that use of this NCCN Content is governed by the End-User License Agreement, and you MAY NOT distribute this Content or use it with any artificial intelligence model or tool.
Printed by A. S. M. FAZLUL KARIM CHOWDHURY on 4/20/2026 3:41:05 AM. Copyright © 2026 National Comprehensive Cancer Network, Inc. All Rights Reserved.

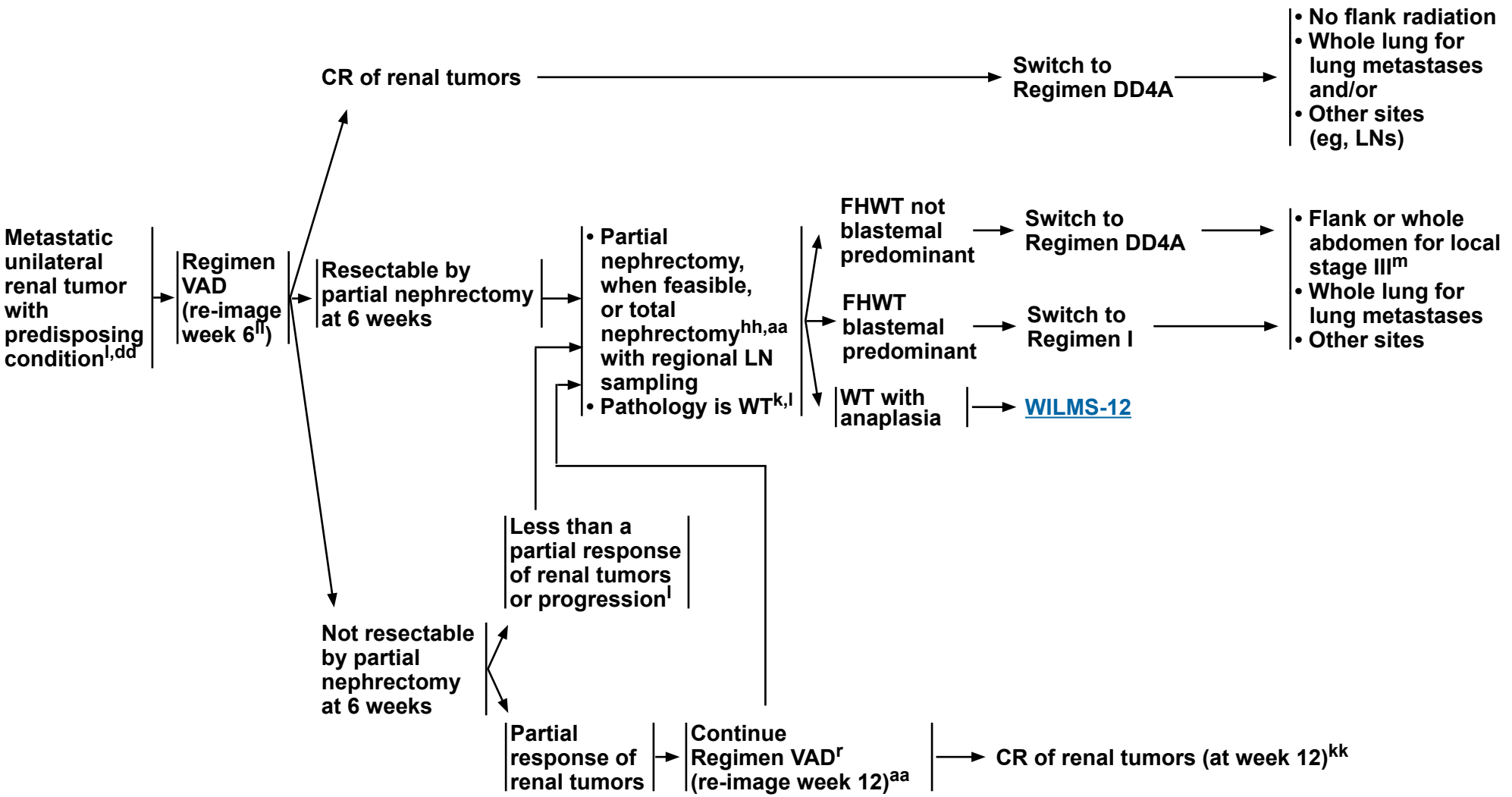

Footnotes on WILMS-7A

Note: All recommendations are category 2A unless otherwise indicated.

Version 2.2025, 6/11/2025 © 2025 National Comprehensive Cancer Network® (NCCN®), All rights reserved. NCCN Guidelines® and this illustration may not be reproduced in any form without the express written permission of NCCN.

PLEASE NOTE that use of this NCCN Content is governed by the End-User License Agreement, and you MAY NOT distribute this Content or use it with any artificial intelligence model or tool.
Printed by A. S. M. FAZLUL KARIM CHOWDHURY on 4/20/2026 3:41:05 AM. Copyright © 2026 National Comprehensive Cancer Network, Inc. All Rights Reserved.

FOOTNOTES

[k] Principles of Pathology (WILMS-C).
[l] Principles of Surgery (WILMS-D).
[m] COG Staging of Wilms Tumor (ST-1).
[r] Principles of Chemotherapy (WILMS-G).
[t] Principles of Radiation Therapy (WILMS-H).
[u] RT to the primary site is often given 10 to 14 days after surgery. We recognize the concern for overlapping fields if the abdomen and lung are treated at different times and recommend planning for possible abdominal and lung fields with initial abdominal RT planning, even if lung RT ultimately not given, to minimize the degree of overlapping fields. Some degree of overlap between the fields is expected in order to cover the target. Local stage III refers to staging of the primary tumor regardless of metastases.
[aa] Tumors should be resected by week 12 at the latest (partial or total nephrectomy), because continued significant tumor shrinkage was not seen after that point in treatment.
[dd] Upfront biopsy or resection is discouraged.
[ee] Neoadjuvant chemotherapy is not a criterion for upstaging to stage III in this population.
[ff] If biopsied, a tumor is considered to be stage III for determination of chemotherapy regimen, but biopsy alone does not upstage a tumor to stage III for determining whether to give radiation.
[hh] Indications for complete nephrectomy for unilateral WT (with predisposing condition) are described in Principles of Surgery (WILMS-D).
[ii] Molecular biomarkers were not used to direct therapy in the AREN0534 trial.
[jj] Use of biomarkers from post-chemotherapy tumor has not been established to correlate with outcome, nor has it been used to direct therapy in a prospective trial. Outcomes of the AREN0534 study were excellent despite this. Regimen M was not studied in this population.
[kk] Refer to CR pathway at the top for treatment recommendations.
[ll] Re-image primary and metastatic sites.

Note: All recommendations are category 2A unless otherwise indicated.

Version 2.2025, 6/11/2025 © 2025 National Comprehensive Cancer Network® (NCCN®), All rights reserved. NCCN Guidelines® and this illustration may not be reproduced in any form without the express written permission of NCCN.

PLEASE NOTE that use of this NCCN Content is governed by the End-User License Agreement, and you MAY NOT distribute this Content or use it with any artificial intelligence model or tool.
Printed by A. S. M. FAZLUL KARIM CHOWDHURY on 4/20/2026 3:41:05 AM. Copyright © 2026 National Comprehensive Cancer Network, Inc. All Rights Reserved.

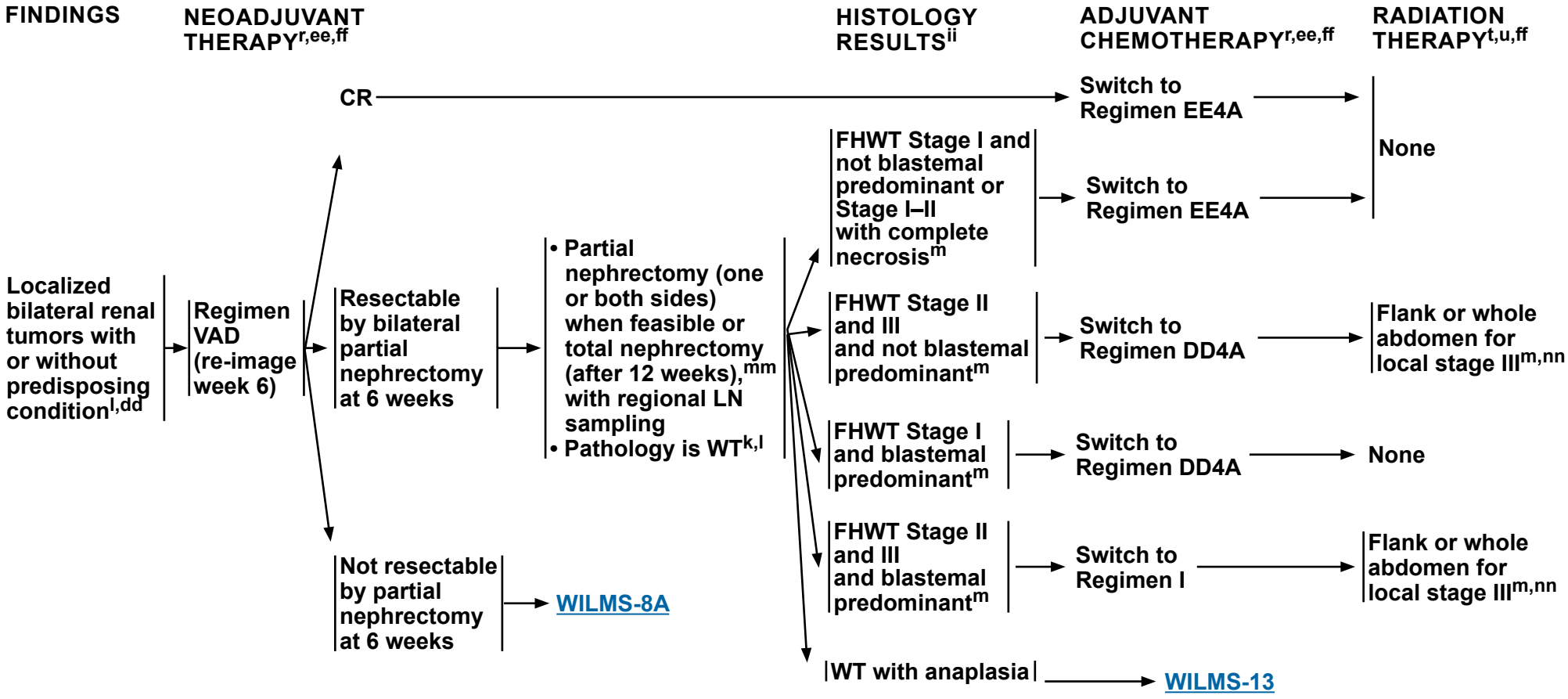

[k] Principles of Pathology (WILMS-C).
[l] Principles of Surgery (WILMS-D).
[m] COG Staging of Wilms Tumor (ST-1).
[r] Principles of Chemotherapy (WILMS-G).
[t] Principles of Radiation Therapy (WILMS-H).
[u] RT to the primary site is often given 10 to 14 days after surgery. We recognize the concern for overlapping fields if the abdomen and lung are treated at different times and recommend planning for possible abdominal and lung fields with initial abdominal RT planning, even if lung RT ultimately not given, to minimize the degree of overlapping fields. Some degree of overlap between the fields is expected in order to cover the target. Local stage III refers to staging of the primary tumor regardless of metastases.

[dd] Upfront biopsy or resection is discouraged.
[ee] Neoadjuvant chemotherapy is not a criterion for upstaging to stage III in this population.
[ff] If biopsied, a tumor is considered to be stage III for determination of chemotherapy regimen, but biopsy alone does not upstage a tumor to stage III for determining whether to give radiation.
[ii] Molecular biomarkers were not used to direct therapy in the AREN0534 trial.
[mm] Total nephrectomy is indicated in patients with bilateral WT if partial nephrectomy is not feasible after 12 weeks of chemotherapy.
[nn] Stage III that is upstaged because of biopsy alone will not receive RT.

Note: All recommendations are category 2A unless otherwise indicated.

Version 2.2025, 6/11/2025 © 2025 National Comprehensive Cancer Network® (NCCN®), All rights reserved. NCCN Guidelines® and this illustration may not be reproduced in any form without the express written permission of NCCN.

PLEASE NOTE that use of this NCCN Content is governed by the End-User License Agreement, and you MAY NOT distribute this Content or use it with any artificial intelligence model or tool.
Printed by A. S. M. FAZLUL KARIM CHOWDHURY on 4/20/2026 3:41:05 AM. Copyright © 2026 National Comprehensive Cancer Network, Inc. All Rights Reserved.

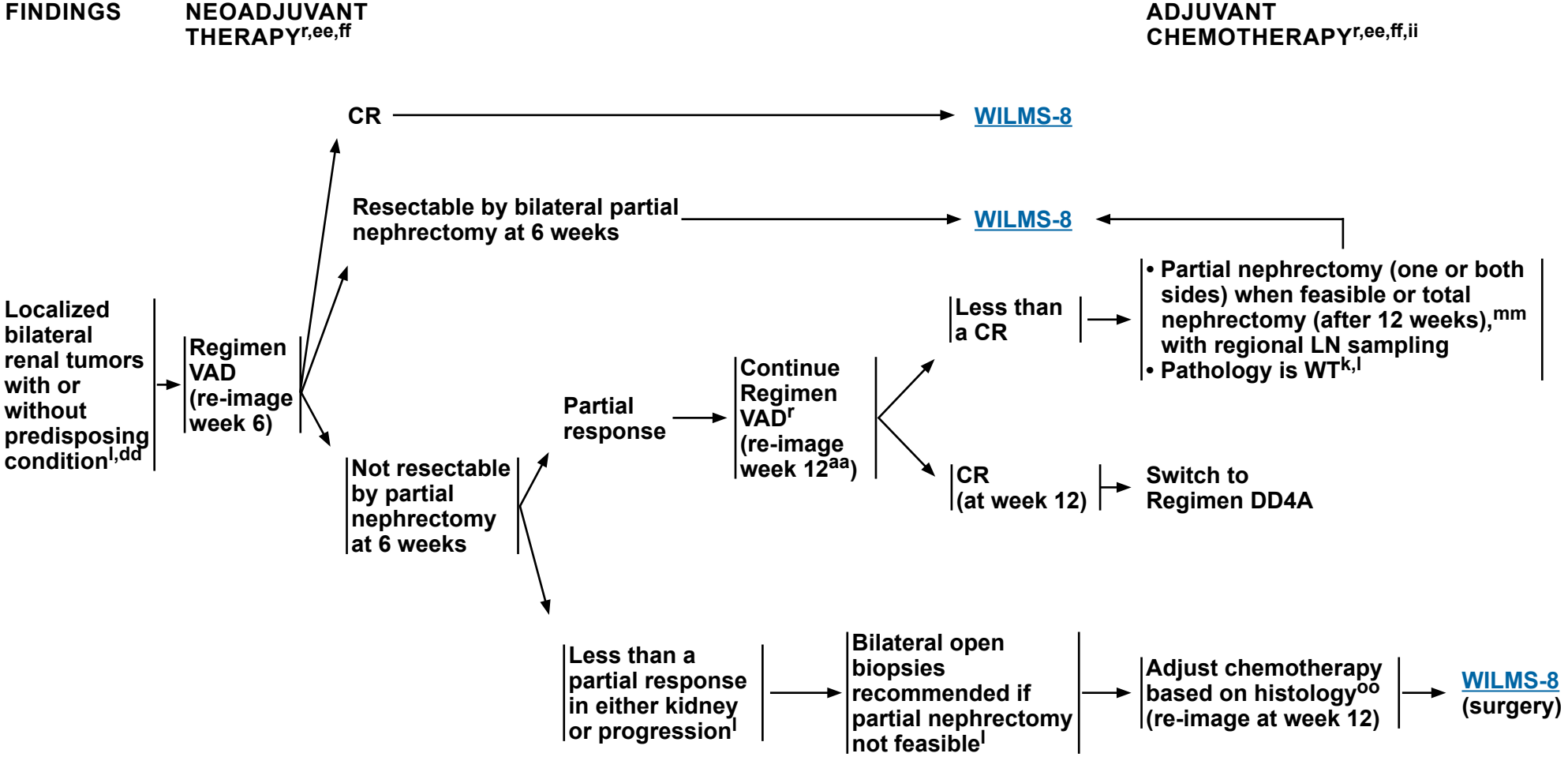

Footnotes on WILMS-8B

Note: All recommendations are category 2A unless otherwise indicated.

Version 2.2025, 6/11/2025 © 2025 National Comprehensive Cancer Network® (NCCN®), All rights reserved. NCCN Guidelines® and this illustration may not be reproduced in any form without the express written permission of NCCN.

PLEASE NOTE that use of this NCCN Content is governed by the End-User License Agreement, and you MAY NOT distribute this Content or use it with any artificial intelligence model or tool.
Printed by A. S. M. FAZLUL KARIM CHOWDHURY on 4/20/2026 3:41:05 AM. Copyright © 2026 National Comprehensive Cancer Network, Inc. All Rights Reserved.

FOOTNOTES

[k] Principles of Pathology (WILMS-C).
[l] Principles of Surgery (WILMS-D).
[r] Principles of Chemotherapy (WILMS-G).
[aa] Tumors should be resected by week 12 at the latest (partial or total nephrectomy), because continued significant tumor shrinkage was not seen after that point in treatment.
[dd] Upfront biopsy or resection is discouraged.
[ee] Neoadjuvant chemotherapy is not a criterion for upstaging to stage III in this population.
[ff] If biopsied, a tumor is considered to be stage III for determination of chemotherapy regimen, but biopsy alone does not upstage a tumor to stage III for determining whether to give radiation.
[ii] Molecular biomarkers were not used to direct therapy in the AREN0534 trial.
[mm] Total nephrectomy is indicated in patients with bilateral WT if partial nephrectomy is not feasible after 12 weeks of chemotherapy.
[oo] If 6-week biopsy reveals blastemal predominant (all stages), then use Regimen I and re-evaluate at 12 weeks; otherwise continue Regimen VAD for 6 weeks and re-evaluate at 12 weeks. Revised Regimen UH-2 if week 6 biopsy shows anaplasia (WILMS-10).

Note: All recommendations are category 2A unless otherwise indicated.

Version 2.2025, 6/11/2025 © 2025 National Comprehensive Cancer Network® (NCCN®), All rights reserved. NCCN Guidelines® and this illustration may not be reproduced in any form without the express written permission of NCCN.

PLEASE NOTE that use of this NCCN Content is governed by the End-User License Agreement, and you MAY NOT distribute this Content or use it with any artificial intelligence model or tool.
Printed by A. S. M. FAZLUL KARIM CHOWDHURY on 4/20/2026 3:41:05 AM. Copyright © 2026 National Comprehensive Cancer Network, Inc. All Rights Reserved.

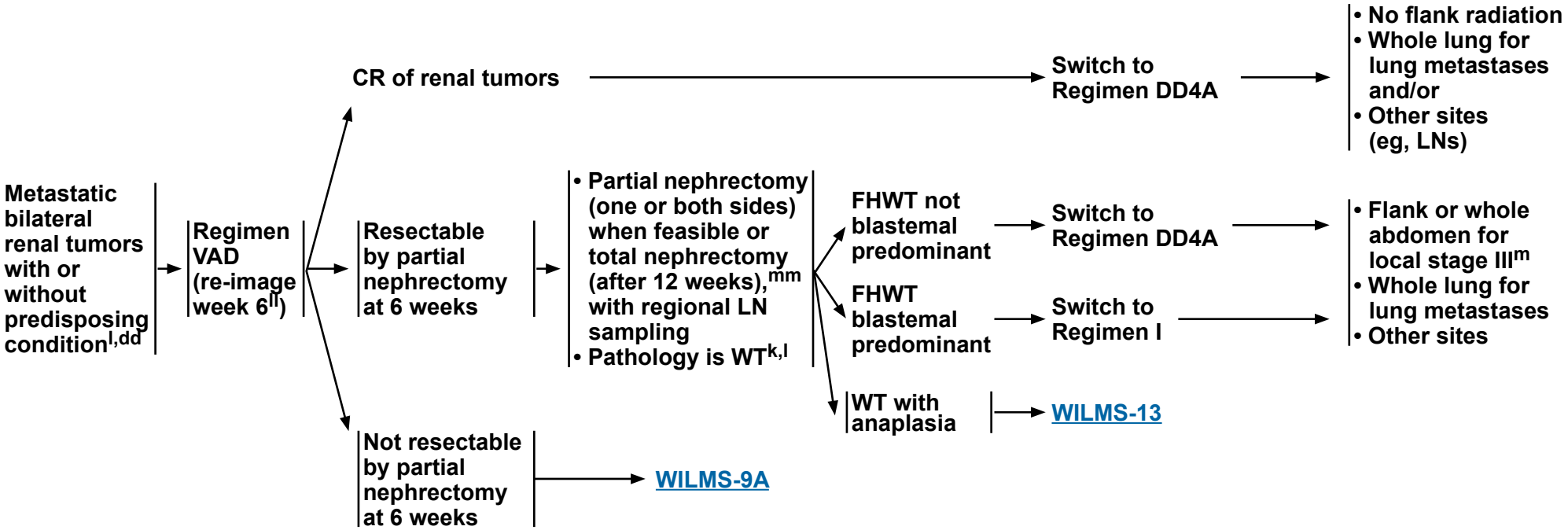

[k] Principles of Pathology (WILMS-C).
[l] Principles of Surgery (WILMS-D).
[m] COG Staging of Wilms Tumor (ST-1).
[r] Principles of Chemotherapy (WILMS-G).
[t] Principles of Radiation Therapy (WILMS-H).
[u] RT to the primary site is often given 10 to 14 days after surgery. We recognize the concern for overlapping fields if the abdomen and lung are treated at different times and recommend planning for possible abdominal and lung fields with initial abdominal RT planning, even if lung RT ultimately not given, to minimize the degree of overlapping fields. Some degree of overlap between the fields is expected in order to cover the target. Local stage III refers to staging of the primary tumor regardless of metastases.

[dd] Upfront biopsy or resection is discouraged.
[ee] Neoadjuvant chemotherapy is not a criterion for upstaging to stage III in this population.
[ff] If biopsied, a tumor is considered to be stage III for determination of chemotherapy regimen, but biopsy alone does not upstage a tumor to stage III for determining whether to give radiation.
[ii] Molecular biomarkers were not used to direct therapy in the AREN0534 trial.
[ll] Re-image primary and metastatic sites.
[mm] Total nephrectomy is indicated in patients with bilateral WT if partial nephrectomy is not feasible after 12 weeks of chemotherapy.

Note: All recommendations are category 2A unless otherwise indicated.

Version 2.2025, 6/11/2025 © 2025 National Comprehensive Cancer Network® (NCCN®), All rights reserved. NCCN Guidelines® and this illustration may not be reproduced in any form without the express written permission of NCCN.

PLEASE NOTE that use of this NCCN Content is governed by the End-User License Agreement, and you MAY NOT distribute this Content or use it with any artificial intelligence model or tool.
Printed by A. S. M. FAZLUL KARIM CHOWDHURY on 4/20/2026 3:41:05 AM. Copyright © 2026 National Comprehensive Cancer Network, Inc. All Rights Reserved.

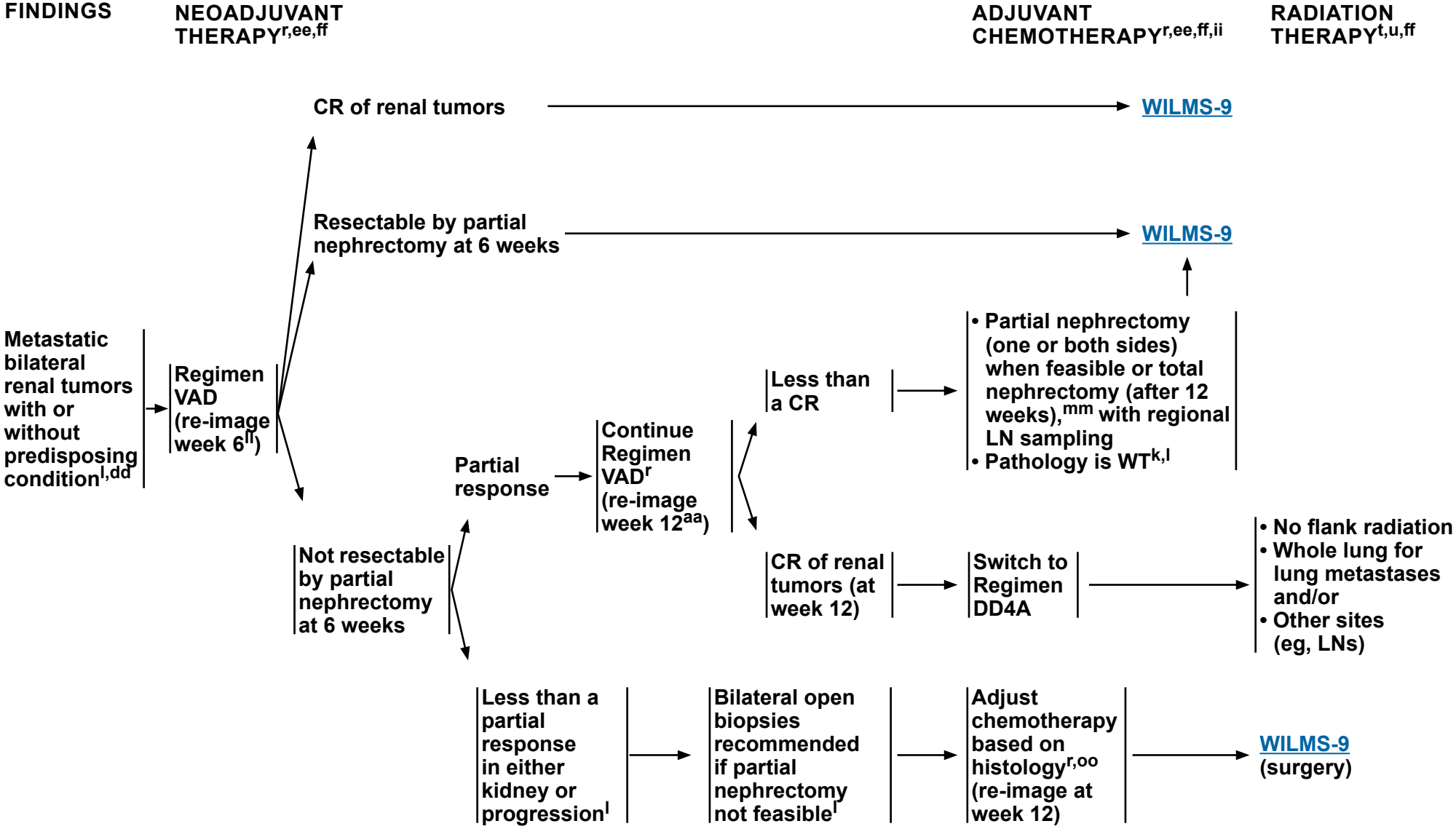

Footnotes on WILMS-9B

Note: All recommendations are category 2A unless otherwise indicated.

Version 2.2025, 6/11/2025 © 2025 National Comprehensive Cancer Network® (NCCN®), All rights reserved. NCCN Guidelines® and this illustration may not be reproduced in any form without the express written permission of NCCN.

PLEASE NOTE that use of this NCCN Content is governed by the End-User License Agreement, and you MAY NOT distribute this Content or use it with any artificial intelligence model or tool.
Printed by A. S. M. FAZLUL KARIM CHOWDHURY on 4/20/2026 3:41:05 AM. Copyright © 2026 National Comprehensive Cancer Network, Inc. All Rights Reserved.

FOOTNOTES

[k] Principles of Pathology (WILMS-C).
[l] Principles of Surgery (WILMS-D).
[r] Principles of Chemotherapy (WILMS-G).
[t] Principles of Radiation Therapy (WILMS-H).
[u] RT to the primary site is often given 10 to 14 days after surgery. We recognize the concern for overlapping fields if the abdomen and lung are treated at different times and recommend planning for possible abdominal and lung fields with initial abdominal RT planning, even if lung RT ultimately not given, to minimize the degree of overlapping fields. Some degree of overlap between the fields is expected in order to cover the target. Local stage III refers to staging of the primary tumor regardless of metastases.
[aa] Tumors should be resected by week 12 at the latest (partial or total nephrectomy), because continued significant tumor shrinkage was not seen after that point in treatment.
[dd] Upfront biopsy or resection is discouraged.
[ee] Neoadjuvant chemotherapy is not a criterion for upstaging to stage III in this population.
[ff] If biopsied, a tumor is considered to be stage III for determination of chemotherapy regimen, but biopsy alone does not upstage a tumor to stage III for determining whether to give radiation.
[ii] Molecular biomarkers were not used to direct therapy in the AREN0534 trial.
[ll] Re-image primary and metastatic sites.
[mm] Total nephrectomy is indicated in patients with bilateral WT if partial nephrectomy is not feasible after 12 weeks of chemotherapy.
[oo] If 6-week biopsy reveals blastemal predominant (all stages), then use Regimen I and re-evaluate at 12 weeks; otherwise continue Regimen VAD for 6 weeks and re-evaluate at 12 weeks. Revised Regimen UH-2 if week 6 biopsy shows anaplasia (WILMS-10).

Note: All recommendations are category 2A unless otherwise indicated.

Version 2.2025, 6/11/2025 © 2025 National Comprehensive Cancer Network® (NCCN®), All rights reserved. NCCN Guidelines® and this illustration may not be reproduced in any form without the express written permission of NCCN.

PLEASE NOTE that use of this NCCN Content is governed by the End-User License Agreement, and you MAY NOT distribute this Content or use it with any artificial intelligence model or tool.
Printed by A. S. M. FAZLUL KARIM CHOWDHURY on 4/20/2026 3:41:05 AM. Copyright © 2026 National Comprehensive Cancer Network, Inc. All Rights Reserved.

FINDINGS	STAGE[m]	ADJUVANT CHEMOTHERAPY[r]	RADIATION THERAPY[t,u]
Unilateral WT with focal anaplasia, primary nephrectomy	Stage I–III	Regimen DD4A[pp]	Flank for stage I or II and flank or whole abdomen for stage III[m]
	Stage IV	Revised Regimen UH-1	• Flank for local stage I or II and flank or whole abdomen for local stage III[m] • Whole lung for lung metastases • Other sites
Unilateral WT with diffuse anaplasia, primary nephrectomy	Stage I	Regimen DD4A	Flank radiation
	Stage II–IV	Revised Regimen UH-2	• Flank for local stage II and flank or whole abdomen for local stage III[m,qq] • Whole lung for lung metastases • Other sites

[m] COG Staging of Wilms Tumor (ST-1).
[r] Principles of Chemotherapy (WILMS-G).
[t] Principles of Radiation Therapy (WILMS-H).
[u] RT to the primary site is often given 10 to 14 days after surgery. We recognize the concern for overlapping fields if the abdomen and lung are treated at different times and recommend planning for possible abdominal and lung fields with initial abdominal RT planning, even if lung RT ultimately not given, to minimize the degree of overlapping fields. Some degree of overlap between the fields is expected in order to cover the target. Local stage III refers to staging of the primary tumor regardless of metastases.
[pp] Intensification of therapy may be warranted for stage III focal anaplastic WT (FAWT) based on inferior outcomes of the AREN0321 study [Armstrong AE, et al. J Clin Oncol 2023;41(Suppl):Abstract 10005].
[qq] A higher dose of radiation for stage III DAWT lowers the risk of local recurrence (Daw NC, et al. Activity of vincristine and irinotecan in diffuse anaplastic wilms tumor and therapy outcomes of stage II to IV disease: results of the children's oncology group AREN0321 study. J Clin Oncol 2020;38:1558-1568).

Note: All recommendations are category 2A unless otherwise indicated.

Version 2.2025, 6/11/2025 © 2025 National Comprehensive Cancer Network® (NCCN®), All rights reserved. NCCN Guidelines® and this illustration may not be reproduced in any form without the express written permission of NCCN.

PLEASE NOTE that use of this NCCN Content is governed by the End-User License Agreement, and you MAY NOT distribute this Content or use it with any artificial intelligence model or tool.
Printed by A. S. M. FAZLUL KARIM CHOWDHURY on 4/20/2026 3:41:05 AM. Copyright © 2026 National Comprehensive Cancer Network, Inc. All Rights Reserved.

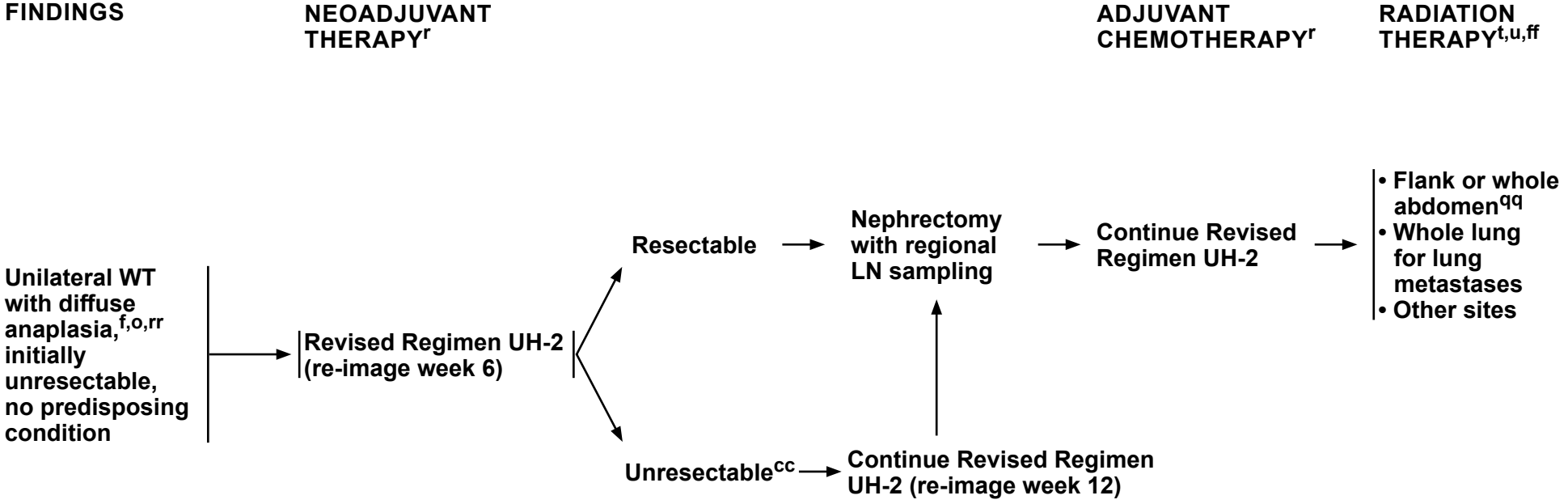

[f] Conditions that predispose to the development of WT include genetic disorders such as Denys-Drash, WAGR, Beckwith-Wiedemann, Frasier, and Perlman syndromes; contralateral nephrogenic rests in children <12 months. Ten percent to 33% of WT occurs in children with predisposing conditions. Children with known predisposing conditions should be screened for WT with PE and abdominal US every 3 months until 7 years of age (ie, all of year 6). See Principles of Cancer Risk Assessment and Counseling (WILMS-I).

[o] Initial biopsy is not recommended for children with imaging findings of bilateral renal tumors, or unilateral tumor and known predisposing condition, but biopsy should be considered for children in those categories who also are >10 years of age, or with concern for pathology other than WT.

[r] Principles of Chemotherapy (WILMS-G).

[t] Principles of Radiation Therapy (WILMS-H).

[u] RT to the primary site is often given 10 to 14 days after surgery. We recognize the concern for overlapping fields if the abdomen and lung are treated at different times and recommend planning for possible abdominal and lung fields with initial abdominal RT planning, even if lung RT ultimately not given, to minimize overlapping fields. Some degree of overlap between the fields is expected in order to cover the target. Local stage III refers to staging of the primary tumor regardless of metastases.

[cc] If imaging shows tumor progression (increase in size), nephrectomy OR rebiopsy (to evaluate for anaplasia or rhabdomyomatous changes) should be performed.

[qq] A higher dose of radiation for stage III DAWT lowers the risk of local recurrence (Daw NC, et al. Activity of vincristine and irinotecan in diffuse anaplastic wilms tumor and therapy outcomes of stage II to IV disease: results of the children's oncology group AREN0321 study. J Clin Oncol 2020;38:1558-1568).

[rr] Anaplasia noted on a biopsy is considered to be diffuse.

Note: All recommendations are category 2A unless otherwise indicated.

Version 2.2025, 6/11/2025 © 2025 National Comprehensive Cancer Network® (NCCN®), All rights reserved. NCCN Guidelines® and this illustration may not be reproduced in any form without the express written permission of NCCN.

PLEASE NOTE that use of this NCCN Content is governed by the End-User License Agreement, and you MAY NOT distribute this Content or use it with any artificial intelligence model or tool.
Printed by A. S. M. FAZLUL KARIM CHOWDHURY on 4/20/2026 3:41:05 AM. Copyright © 2026 National Comprehensive Cancer Network, Inc. All Rights Reserved.

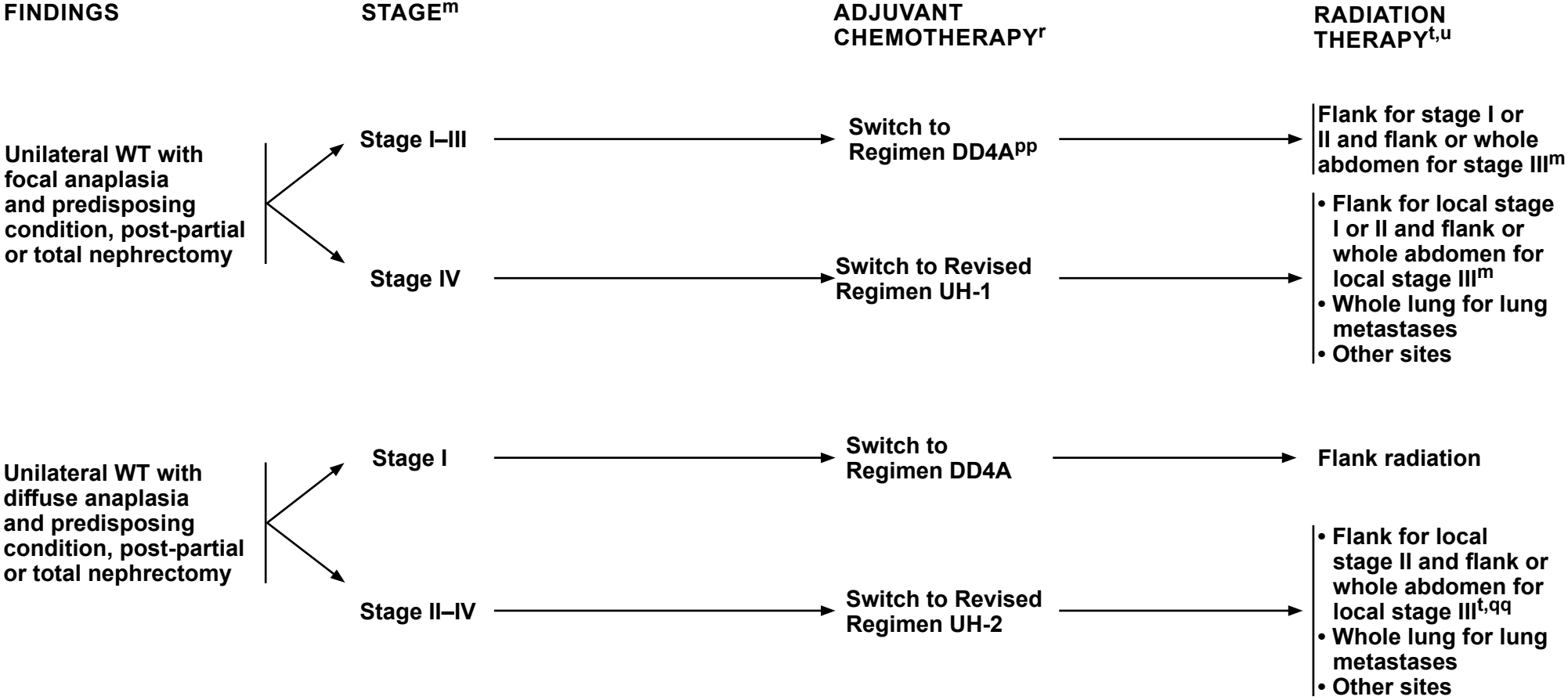

[m] COG Staging of Wilms Tumor (ST-1).
[r] Principles of Chemotherapy (WILMS-G).
[t] Principles of Radiation Therapy (WILMS-H).
[u] RT to the primary site is often given 10 to 14 days after surgery. We recognize the concern for overlapping fields if the abdomen and lung are treated at different times and recommend planning for possible abdominal and lung fields with initial abdominal RT planning, even if lung RT ultimately not given, to minimize overlapping fields. Some degree of overlap between the fields is expected in order to cover the target. Local stage III refers to staging of the primary tumor regardless of metastases.
[pp] Intensification of therapy may be warranted for stage III FAWT based on inferior outcomes of the AREN0321 study [Armstrong AE, et al. J Clin Oncol 2023;41(Suppl): Abstract 10005].
[qq] A higher dose of radiation for stage III DAWT lowers the risk of local recurrence (Daw NC, et al. Activity of vincristine and irinotecan in diffuse anaplastic wilms tumor and therapy outcomes of stage II to IV disease: results of the children's oncology group AREN0321 study. J Clin Oncol 2020;38:1558-1568).

Note: All recommendations are category 2A unless otherwise indicated.

Version 2.2025, 6/11/2025 © 2025 National Comprehensive Cancer Network® (NCCN®), All rights reserved. NCCN Guidelines® and this illustration may not be reproduced in any form without the express written permission of NCCN.

PLEASE NOTE that use of this NCCN Content is governed by the End-User License Agreement, and you MAY NOT distribute this Content or use it with any artificial intelligence model or tool.
Printed by A. S. M. FAZLUL KARIM CHOWDHURY on 4/20/2026 3:41:05 AM. Copyright © 2026 National Comprehensive Cancer Network, Inc. All Rights Reserved.

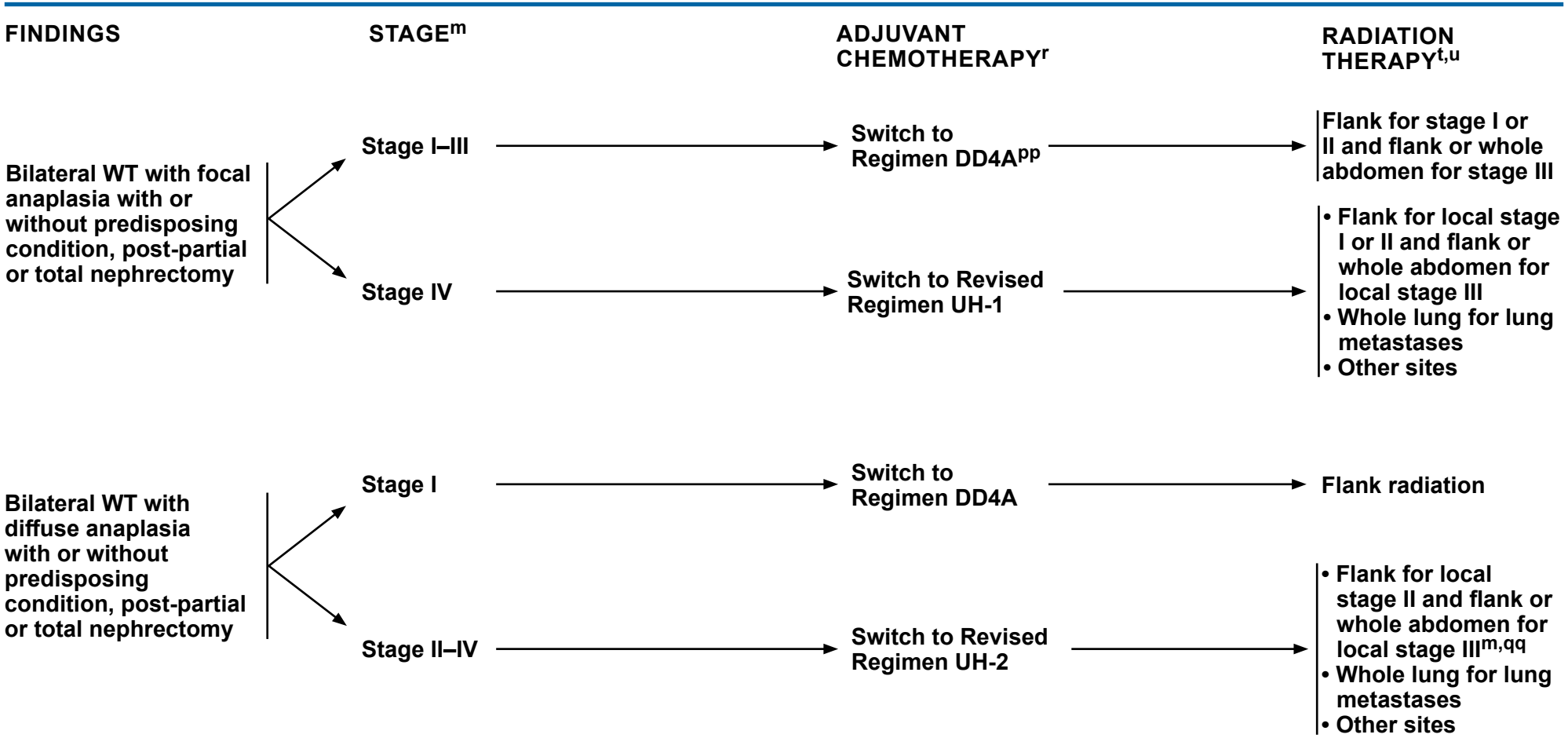

[m] COG Staging of Wilms Tumor (ST-1).
[r] Principles of Chemotherapy (WILMS-G).
[t] Principles of Radiation Therapy (WILMS-H).
[u] RT to the primary site is often given 10 to 14 days after surgery. We recognize the concern for overlapping fields if the abdomen and lung are treated at different times and recommend planning for possible abdominal and lung fields with initial abdominal RT planning, even if lung RT ultimately not given, to minimize overlapping fields. Some degree of overlap between the fields is expected in order to cover the target. Local stage III refers to staging of the primary tumor regardless of metastases
[pp] Intensification of therapy may be warranted for stage III FAWT based on inferior outcomes of the AREN0321 study [Armstrong AE, et al. J Clin Oncol 2023;41(Suppl): Abstract 10005].
[qq] A higher dose of radiation for stage III DAWT lowers the risk of local recurrence (Daw NC, et al. Activity of vincristine and irinotecan in diffuse anaplastic wilms tumor and therapy outcomes of stage II to IV disease: results of the children's oncology group AREN0321 study. J Clin Oncol 2020;38:1558-1568).

Note: All recommendations are category 2A unless otherwise indicated.

Version 2.2025, 6/11/2025 © 2025 National Comprehensive Cancer Network® (NCCN®), All rights reserved. NCCN Guidelines® and this illustration may not be reproduced in any form without the express written permission of NCCN.

PLEASE NOTE that use of this NCCN Content is governed by the End-User License Agreement, and you MAY NOT distribute this Content or use it with any artificial intelligence model or tool.
Printed by A. S. M. FAZLUL KARIM CHOWDHURY on 4/20/2026 3:41:05 AM. Copyright © 2026 National Comprehensive Cancer Network, Inc. All Rights Reserved.

PRINCIPLES OF ABDOMINAL MASS EVALUATION

Initial Evaluation (complete H&P exam, including laboratory and blood pressure assessment)

- Evaluate prior medical and family history.
- Identify any congenital anomalies.
- Note location and size of abdominal mass. Palpate abdomen gently to avoid tumor rupture.
- Mass may be smooth and non-tender; assess for bilateral lesions.
- Varicocele secondary to obstruction of the spermatic vein, ascites, and lower extremity edema may be associated with presence of tumor in inferior vena cava (IVC).
- Perform CBC with differential, comprehensive metabolic panel, coagulation panel, UA noting the presence or absence of protein and white or red blood cells, and urine VMA/HVA to evaluate for neuroblastoma.
- A healthy-appearing child with abdominal distention is more likely to have WT, whereas a child with neuroblastoma tends to be ill-appearing at presentation.
- Extension of a tumor thrombus into the right atrium may increase the risk for pulmonary emboli.

Differential Diagnosis

Benign Conditions

- Adrenal hemorrhage
- Angiomyolipoma
- Complex renal cysts from pyelonephritis
- Cystic nephroma
- Dysplastic kidney
- Hydronephrosis
- Metanephric tumors (adenoma, stromal tumor, adenofibroma)
- Multicystic kidney disease
- Nephroblastomatosis
- Polycystic kidney disease
- Renal hemorrhage
- Renal vein thrombosis

Malignant Conditions

- Burkitt lymphoma
- Clear cell sarcoma of the kidney (CCSK)
- Congenital mesoblastic nephroma
- Ewing sarcoma
- Hepatoblastoma
- Nephroblastoma (WT)
- Neuroblastoma
- Rare renal tumors, including renal sarcoma, primitive neuroectodermal tumors (PNETs), *DICER1*-associated sarcoma, desmoplastic small round cell tumors (DSRCTs), renal neuroblastoma, and perivascular epithelioid cell tumors (PEComas)
- Renal cell carcinoma (including renal medullary carcinoma)
- Rhabdoid tumor of the kidney
- Rhabdomyosarcoma

Note: All recommendations are category 2A unless otherwise indicated.

Version 2.2025, 6/11/2025 © 2025 National Comprehensive Cancer Network® (NCCN®), All rights reserved. NCCN Guidelines® and this illustration may not be reproduced in any form without the express written permission of NCCN.

PLEASE NOTE that use of this NCCN Content is governed by the End-User License Agreement, and you MAY NOT distribute this Content or use it with any artificial intelligence model or tool.
Printed by A. S. M. FAZLUL KARIM CHOWDHURY on 4/20/2026 3:41:05 AM. Copyright © 2026 National Comprehensive Cancer Network, Inc. All Rights Reserved.

PRINCIPLES OF IMAGING

General Principles

- Imaging is essential for diagnosis, staging, and surveillance of renal tumors. Ultimately tumor staging remains surgical, but as therapies continue to evolve, preoperative imaging evaluation is becoming more important for staging.[1,2]

Goals of Imaging

- Differentiate primary renal tumors from primary extra-renal tumors.
- Evaluate the involved and contralateral kidney.
- Assess for the presence of two kidneys and determine the location of the tumor (renal fossa vs. ectopic).
- Define extent of tumor in preparation for resection and RT.
- Assess patency of the renal vein and IVC. Assess for tumor thrombus extending through the renal vein and IVC (can occur in 10% of cases), and determine extent of thrombus in the IVC and/or renal vein, if present.
- Evaluate abdomen and lungs for presence of metastatic spread.
- Provide surveillance in high-risk populations and following therapy.

Imaging: US

- First-line modality for the assessment of abdominal masses in the pediatric population given the lack of radiation and the ability to perform the US without sedation.
- Allows determination of origin of abdominal mass from the kidney given that renal masses typically distort the renal parenchyma with a “claw sign” surrounding the mass.
- Identifies contralateral kidney, liver evaluation, and presence or absence of tumor extension into the renal vein or IVC.

Imaging: CT/MRI

- Abdomen CT or MRI is recommended after US to better evaluate the overall extent and involvement of the renal mass.[3] However, both modalities may require some level of sedation, especially MRI, and should be performed after an initial assessment with US.
- Pelvis CT or MRI may also be performed if the mass is assumed to extend to the pelvis.
- Abdomen CT and MRI have been shown to be equivalent in the initial assessment of WT.[4]
- If abdomen CT is performed, portal venous phase timing is recommended and multiphase imaging is not required.[5]
- Prior to CT and MRI scan, renal function should be assessed by determining an estimated glomerular filtration rate (GFR).[a]
- CT or MRI imaging of the abdomen and pelvis should assess for:
  - Volume of tumor
  - Evidence of tumor rupture
  - Evidence of tumor thrombus extension into the renal vein or IVC
  - Symmetric excretion of contrast
- CT of the chest is also recommended to assess for pulmonary metastases. If concerned with mediastinal/thoracic hilar involvement, contrast may be helpful. While CT and MRI are equivalent for the abdomen, chest CT is superior to chest MRI for evaluation of lung metastases. Perform chest CT prior to anesthesia to avoid atelectasis.

Post-Treatment Surveillance[6,7]

- Chest and abdominal imaging every 3 months for 2 years, then every 6 months for 2 years
- Chest x-ray and abdominal US may be used in place of cross-sectional imaging with chest CT and abdomen CT or MRI

[a] https://edge.sitecorecloud.io/americancoldf5f-acrorgf92a-productioncb02-3650/media/ACR/Files/Clinical/Contrast-Manual/ACR-Manual-on-Contrast-Media.pdf

[1] Chung EM, Graeber AR, Conran RM. Renal Tumors of Childhood: Radiologic-Pathologic Correlation Part 1. The 1st Decade: From the Radiologic Pathology Archives. Radiographics 2016;36:499-522.
[2] Saltzman AF, Carrasco A, Weinman J, et al. Initial imaging for pediatric renal tumors: An opportunity for improvement. J Urol 2018;199:1330-1336.
[3] McDonald K, Duffy P, Chowdhury T, McHugh K. Added value of abdominal cross-sectional imaging (CT or MRI) in staging Wilms’ tumours. Clin Radiol 2013;68:16-20.
[4] Servaes S, Khanna G, Naranjo A, et al. Comparison of diagnostic performance of CT and MRI for abdominal staging of pediatric renal tumors: A report from the Children’s Oncology Group. Pediatr Radiol 2015;45:166-172.
[5] Brisse HJ, Smets AM, Kaste SC, Owens CM. Imaging in unilateral Wilms tumour. Pediatr Radiol 2008;38:18-29.
[6] Brok J, Lopez-Yurda M, Tinteren HV, et al. Relapse of Wilms' tumour and detection methods: A retrospective analysis of the 2001 Renal Tumour Study Group-International Society of Paediatric Oncology Wilms' tumour protocol database. Lancet Oncol 2018;19:1072-1081.
[7] Mullen EA, Chi YY, Hibbitts E, et al. Impact of surveillance imaging modality on survival after recurrence in patients with favorable-histology Wilms Tumor: a report from the Children's Oncology Group. J Clin Oncol 2018;36:3396-3403.

Note: All recommendations are category 2A unless otherwise indicated.

Version 2.2025, 6/11/2025 © 2025 National Comprehensive Cancer Network® (NCCN®), All rights reserved. NCCN Guidelines® and this illustration may not be reproduced in any form without the express written permission of NCCN.

PLEASE NOTE that use of this NCCN Content is governed by the End-User License Agreement, and you MAY NOT distribute this Content or use it with any artificial intelligence model or tool.
Printed by A. S. M. FAZLUL KARIM CHOWDHURY on 4/20/2026 3:41:05 AM. Copyright © 2026 National Comprehensive Cancer Network, Inc. All Rights Reserved.

PRINCIPLES OF PATHOLOGY

Gross Examination

- Most tumors are unifocal.
- Multifocal tumors in a single kidney (7%)
- Bilateral primary tumors (5%–10%)
- Solitary, rounded, multinodular masses sharply demarcated from adjacent kidney by a fibrous capsule
- Cut surface – pale gray/tan, soft, or firm (stromal components)
- Preoperative chemotherapy induces necrosis.

Histopathology of FHWT

- FHWT implies the absence of focal or diffuse anaplasia.
- Undifferentiated blastemal cells
  - Blastemal cells are small, closely packed cells that have round to oval nuclei with scant cytoplasm. They have evenly distributed coarse chromatin, small nucleoli, and are mitotically active. Blastemal-predominant tumors (66% of tumor) are aggressive, invasive, and present with advanced stage, but are responsive to chemotherapy.
- Cells that are differentiated towards epithelial and stromal lineages
  - Epithelial cells are arranged in early tubular forms resembling primitive, rosette-like structures, which mimic tubular and glomerular elements. Epithelial lineage-predominant tumors are associated with a low risk of progression or recurrence after treatment, but frequently have a poor response to chemotherapy.
  - Stromal patterns include:
    - ◊ Smooth muscle and fibroblastic differentiation
    - ◊ Spindle cells in a myxoid background
    - ◊ Skeletal muscle, adipose tissue, cartilage, bone, ganglion cells, and neuroglial tissue with heterologous stromal differentiation
- Completely necrotic cells
- The most characteristic pattern is the triphasic pattern, in which blastema, epithelial, and stromal lineages are all present. However, biphasic and monophasic patterns also exist, and heterologous non-renal elements also occur. The tumor corresponds to stages of normal/abnormal nephrogenesis.
- An additional important microscopic characteristic of WT is the presence of a peritumoral fibrous capsule that demarcates the tumor from adjacent renal parenchyma.
- Chemotherapy-induced changes include necrosis, foamy macrophages, hemosiderin deposits, and fibrosis. Chemotherapy induces maturation of blastemal, epithelial, and stromal components with striated muscle differentiation being the most common. At times there is an excellent response to chemotherapy and the tumor is totally necrotic.[1]

[1] Vujanić GM, Parsons LN, D'Hooghe E, et al. Pathology of Wilms' tumour in International Society of Paediatric Oncology (SIOP) and Children's Oncology Group (COG) renal tumour studies: Similarities and differences. Histopathology 2022;80:1026-1037.

Note: All recommendations are category 2A unless otherwise indicated.

Version 2.2025, 6/11/2025 © 2025 National Comprehensive Cancer Network® (NCCN®), All rights reserved. NCCN Guidelines® and this illustration may not be reproduced in any form without the express written permission of NCCN.

PLEASE NOTE that use of this NCCN Content is governed by the End-User License Agreement, and you MAY NOT distribute this Content or use it with any artificial intelligence model or tool.
Printed by A. S. M. FAZLUL KARIM CHOWDHURY on 4/20/2026 3:41:05 AM. Copyright © 2026 National Comprehensive Cancer Network, Inc. All Rights Reserved.

PRINCIPLES OF PATHOLOGY (CONTINUED)

Focal Anaplasia[2]
- A clearly defined focus of anaplasia within the primary intrarenal tumor
- Anaplasia must be confined to the renal parenchyma
- Anaplasia must not be present within vascular spaces
- Absence of severe nuclear pleomorphism and hyperchromasia (marked/severe nuclear unrest) in a non-anaplastic tumor
- 1 or 2 foci of anaplasia, none >15 mm[1]

Diffuse Anaplasia[2]
- Non-localized (multifocal) anaplasia
- Anaplasia beyond the tumor capsule
- Anaplastic cells in intrarenal vessels, extrarenal vessels, renal sinus, extracapsular invasive sites, or metastatic deposits
- Focal anaplasia with marked nuclear unrest in the remaining tumor
- Anaplasia not clearly demarcated from non-anaplastic tumor
- Anaplasia present in a biopsy or other incomplete tumor sample

Molecular Markers
- Unfavorable biomarkers include 1q gain and/or LOH in 1p and 16q. There are fewer data for using 11p15 LOH or LOI as unfavorable biomarkers. There are no data for using chromosome 17p13 to direct therapy.
- FHWTs almost never exhibit *TP53* gene mutations.
  - *TP53* positivity in absence of anaplasia may represent progression events closely linked to development of anaplasia.

Pattern of Spread
- WTs extend locally into the perirenal soft tissues, renal vein, and vena cava.
- WTs metastasize to the lungs, regional LNs, and the liver.
- WTs rarely metastasize to bone and brain tissues, which differentiates WT from other kidney cancers, clear cell sarcomas, or rhabdoid tumors.

[1] Vujanić GM, Parsons LN, D'Hooghe E, et al. Pathology of Wilms' tumour in International Society of Paediatric Oncology (SIOP) and Children's Oncology Group (COG) renal tumour studies: Similarities and differences. Histopathology 2022;80:1026-1037.
[2] Srigley JR, Amin MB, Rubin MA, Tsuzuki T, eds. WHO classification of tumours: Urinary and male genital tumours. Lyon, France: International Agency for Research on Cancer; 2022.

Note: All recommendations are category 2A unless otherwise indicated.

Version 2.2025, 6/11/2025 © 2025 National Comprehensive Cancer Network® (NCCN®), All rights reserved. NCCN Guidelines® and this illustration may not be reproduced in any form without the express written permission of NCCN.

PLEASE NOTE that use of this NCCN Content is governed by the End-User License Agreement, and you MAY NOT distribute this Content or use it with any artificial intelligence model or tool.
Printed by A. S. M. FAZLUL KARIM CHOWDHURY on 4/20/2026 3:41:05 AM. Copyright © 2026 National Comprehensive Cancer Network, Inc. All Rights Reserved.

PRINCIPLES OF SURGERY

General Principles

- Decisions about complex surgery should be discussed with surgeons/urologists with experience managing such issues as complex venous tumor thrombi or nephron-sparing surgery (NSS).
- Surgical exploration cannot be replaced by imaging, although CT[1] or MRI of the abdomen is recommended prior to surgery.
  - Determine size and extent of tumor.
  - Contralateral kidney exploration is not recommended for unilateral WT. Biopsy should be considered for concerning but indeterminate lesion(s) seen on CT/MRI scan.
  - Assess retroperitoneal adenopathy, preoperative tumor rupture, and ascites.
  - Assess tumor involvement of ipsilateral renal veins or IVC.
  - Assess for ureteral involvement by imaging, palpation; consider cystoscopy if gross hematuria on presentation, or for suspicious findings on preoperative imaging, such as hydronephrosis or nonfunctioning kidney.[2]
- Evaluate resectability prior to surgery by imaging.
  - Extension of tumor thrombus above hepatic veins
  - Tumor extension to contiguous structures
  - Evaluate whether the patient is at risk for pulmonary compromise secondary to pulmonary metastases or tumor embolus.
  - Assess risk of morbidity or mortality, intraoperative hemorrhage, gross tumor spill, or residual tumor.
  - Patients at risk for long-term renal failure, including patients with a predisposing condition, may benefit from an NSS approach.[3-6]
- Perform transabdominal or a thoracoabdominal[b] exposure with transperitoneal approach (preferred surgical approaches) and abdominal exploration, unilateral radical ureteronephrectomy with LN sampling.[4]
- Adequate LN sampling is necessary for staging.[7,8] Although there is no consensus about the minimal number of LNs to obtain from these different locations, a suggested minimum is 5 nodes from areas in the renal hilum, pericaval, and para-aortic regions, which are anatomically expected to represent nodes associated with the kidney.[a,4,9]
- Palpate ureter prior to transecting to assess for ureteral tumor extension.[2]
- Primary resection provides necessary biologic information for risk stratification and selection of appropriate therapy.
  - Minimize treatment for patients at low risk.
  - Improve survival in patients at higher risk.
- A preoperative disruption of the tumor capsule is termed preoperative *rupture*; any intraoperative cut across the tumor is termed *spillage*.

Locations of Suggested Lymph Node Sampling[b]

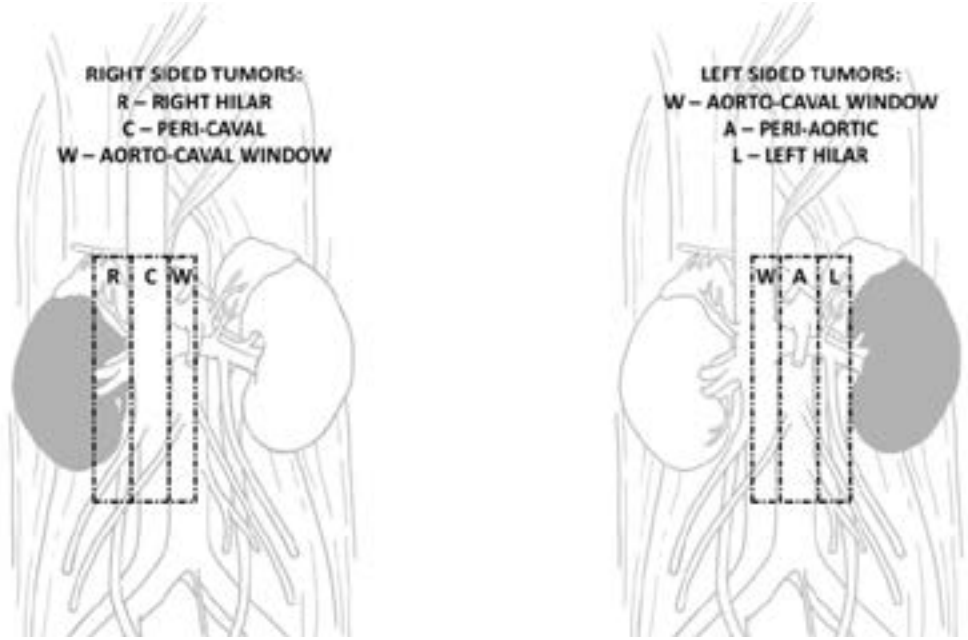

[b] Aldrink JH, Romao R, Ehrlich PF, et al. Critical elements of radical nephroureterectomy for pediatric unilateral renal tumor. Semin Pediatr Surg 2023;32:151339. With permission from Elsevier.

[a] For patients who are enrolled on a clinical trial, review nodal sampling requirements in the protocol.
[b] Thoracoabdominal incision can be considered but is rarely required.

Note: All recommendations are category 2A unless otherwise indicated.

Continued
References

Version 2.2025, 6/11/2025 © 2025 National Comprehensive Cancer Network® (NCCN®), All rights reserved. NCCN Guidelines® and this illustration may not be reproduced in any form without the express written permission of NCCN.

PLEASE NOTE that use of this NCCN Content is governed by the End-User License Agreement, and you MAY NOT distribute this Content or use it with any artificial intelligence model or tool.
Printed by A. S. M. FAZLUL KARIM CHOWDHURY on 4/20/2026 3:41:05 AM. Copyright © 2026 National Comprehensive Cancer Network, Inc. All Rights Reserved.

PRINCIPLES OF SURGERY (CONTINUED)

Contraindications to Primary Resection
- High risk of renal failure for those with germline *WT1* mutations (Denys-Drash, WAGR) or bilateral WT. Overall risk of long-term renal failure in patients with unilateral, nonsyndromic WT is <1%.[3,10,11]
- Unacceptable anesthesia risk due to disease burden
  - Massive pulmonary disease or tumor embolus
  - Very large abdominal tumors causing pulmonary compromise
- Surgeon judgment: Operation would lead to significant morbidity/mortality, tumor spill, or residual tumor
- Solitary kidney
- IVC tumor thrombus above the level of the hepatic veins is an absolute contraindication; extension of thrombus to the retrohepatic cava is a relative contraindication
- Bilateral tumors or unilateral disease in patients with a predisposing condition

Goals of Surgery for Unilateral WT
- Complete clearance of all disease
- Accurate LN staging
- Complete pathologic evaluation
- Resection without tumor spillage

Surgical Management: Abdominal Cavity
- Open peritoneal cavity and reflect colon.
- Biopsy, as indicated, any abnormalities of liver or peritoneal surfaces and evaluate vessels for tumor extension.
- Palpate ureter prior to transection.[2]
- Mobilize primary tumor and ligate ureter as low as possible.
- Expose/dissect/ligate renal vessels.
- Perform LN sampling from renal hilum, pericaval/para-aortic regions.[4,9] Involved or suspicious LNs should be removed, but a formal LN dissection is not necessary.
- Radical nephrectomy is completed en bloc; however, the adrenal gland does not require removal if uninvolved with the tumor.[12]
- Assure careful handling of the tumor to avoid tumor spillage.[13-19]

Surgical Management: Pulmonary Nodules
- Consider assessing at diagnosis for confirmation of metastatic disease.
  - Nodules may be involved with disease in 46%–85% of patients.
- After 6 weeks of chemotherapy, consider resection of persistent, surgically accessible, pulmonary lesions to guide decisions about adjuvant therapy, such as need for intensification and/or need for whole lung irradiation (WLI).
- A surgeon may be needed for managing pulmonary metastases:
  - At presentation: If there are concerns about whether the pulmonary lesions are metastases, they should be biopsied. As many as 33% of small lesions may not be metastases.
  - At the end of 2 cycles or 6 weeks of chemotherapy: If concerns remain about the pulmonary lesion(s), a biopsy should be performed prior to proceeding with pulmonary radiation.
  - Inaccurate initial assignment of lung nodules may result in incorrect assessment of treatment response.
- Provide salvage therapy following chemotherapy and radiotherapy.
  - In order to avoid intensive salvage regimens, any new pulmonary lesions should be confirmed histologically.

Note: All recommendations are category 2A unless otherwise indicated.

Continued
References

Version 2.2025, 6/11/2025 © 2025 National Comprehensive Cancer Network® (NCCN®), All rights reserved. NCCN Guidelines® and this illustration may not be reproduced in any form without the express written permission of NCCN.

PLEASE NOTE that use of this NCCN Content is governed by the End-User License Agreement, and you MAY NOT distribute this Content or use it with any artificial intelligence model or tool.
Printed by A. S. M. FAZLUL KARIM CHOWDHURY on 4/20/2026 3:41:05 AM. Copyright © 2026 National Comprehensive Cancer Network, Inc. All Rights Reserved.

PRINCIPLES OF SURGERY (CONTINUED)

Summary of Surgical Approach in Unilateral Tumors in Patients with Predisposing Conditions

- Predisposing syndromes include: WAGR, Perlman syndrome, Denys-Drash syndrome, Beckwith-Wiedemann syndrome, Frasier syndrome, Sotos syndrome, Simpson-Golabi-Behmel syndrome, Bloom syndrome, Li-Fraumeni syndrome, and trisomy 18.[20]
- NSS should be prioritized.
- When doing NSS, surgeons should sample LNs.
- In the unilateral predisposed setting, less than partial response at 6 weeks of chemotherapy required total nephrectomy in the AREN0534 trial.[21] Although in AREN0534, radical nephrectomy may have been recommended for unilateral tumors in patients with predisposing conditions who had less than a partial response, the decision about radical versus partial nephrectomy is also based on the anatomic feasibility for partial nephrectomy and less than a partial response is not a contraindication against attempted partial nephrectomy or continuing pre-surgical chemotherapy to week 12.
- Total nephrectomy is indicated[21]:
  - For patients with unilateral WT who are at high risk for bilateral WT for whom a partial nephrectomy is not feasible after 6 weeks of chemotherapy and with less than a partial response to chemotherapy; or
  - If partial nephrectomy is not feasible after 12 weeks of chemotherapy.
- If metachronous tumor, treat second occurrences of WT by repeating initial chemotherapy regimens (WILMS-6).

Summary of Surgical Approach to Bilateral WT

- Do not biopsy upon presentation of bilateral WT.
- Use standardized 3-drug neoadjuvant chemotherapy (VAD, WILMS-G) followed by bilateral NSS to preserve renal function.
  - Favorable imaging findings for performing NSS:[22,23,24,25]
    - Peripheral or polar location, not involving renal hilum
    - Planned resection spares one-third or more of normal kidney
    - No tumor invasion into the renal sinus, segmental vasculature, or collecting system
    - Lack of invasion or encasement of main renal vessels
    - Distinct interface between tumor and renal parenchyma
- Week 6 re-evaluation:
  - Perform surgery if bilateral NSS is possible.
  - For less than a partial response to chemotherapy, consider bilateral open biopsies to assess reasons for non-responsiveness, such as anaplasia or rhabdomyomatous differentiation.
  - Continue chemotherapy if patient has some response but is not a candidate for NSS.
- Surgery should be performed within 12 weeks of starting neoadjuvant therapy.
  - Aim for bilateral NSS, if possible.
  - If operating after chemotherapy, resection with a rim of normal parenchyma or enucleation (marginal resection removing tumor with an intact capsule) can be performed.
  - Assessment of preoperative imaging may underestimate proportion of bilateral WT amenable to NSS, and surgeons should decide intraoperatively if NSS is feasible after complete mobilization of the kidney and tumor.
  - Unilateral nephrectomy and contralateral NSS may be indicated if bilateral partial nephrectomy is not feasible after 12 weeks of chemotherapy.
- If disease recurrence, repeat NSS.

Note: All recommendations are category 2A unless otherwise indicated.

References

Version 2.2025, 6/11/2025 © 2025 National Comprehensive Cancer Network® (NCCN®), All rights reserved. NCCN Guidelines® and this illustration may not be reproduced in any form without the express written permission of NCCN.

PLEASE NOTE that use of this NCCN Content is governed by the End-User License Agreement, and you MAY NOT distribute this Content or use it with any artificial intelligence model or tool.
Printed by A. S. M. FAZLUL KARIM CHOWDHURY on 4/20/2026 3:41:05 AM. Copyright © 2026 National Comprehensive Cancer Network, Inc. All Rights Reserved.

PRINCIPLES OF SURGERY
REFERENCES

[1] Khanna G, Rosen N, Anderson JR, et al. Evaluation of diagnostic performance of CT for detection of tumor thrombus in children with Wilms tumor: a report from the Children's Oncology Group. Pediatr Blood Cancer 2012;58:551-555.
[2] Ritchey M, Daley S, Shamberger RC, Ehrlich P, et al. Ureteral extension in Wilms' tumor: a report from the National Wilms' Tumor Study Group (NWTSG). J Pediatr Surg 2008;43:1625-1629.
[3] Breslow NE, Collins AJ, Ritchey ML, et al. End stage renal disease in patients with Wilms tumor: results from the National Wilms Tumor Study Group and the United States Renal Data System. J Urol 2005;174:1972-1975.
[4] Aldrink JH, Heaton TE, Dasgupta R, et al. Update on Wilms tumor. J Pediatr Surg 2019;54:390-397.
[5] Qureshi SS, Bhagat M, Kazi M, et al. Standardizing lymph nodal sampling for Wilms tumor: a feasibility study with outcomes. J Pediatr Surg 2020;55:2668-2675.
[6] Kieran K, Ehrlich PF. Current surgical standards of care in Wilms tumor. Urol Oncol 2016;34:13-23.
[7] Saltzman AF, Smith DE, Gao D, et al. How many lymph nodes are enough? Assessing the adequacy of lymph node yield for staging in favorable histology Wilms' tumor. J Pediatr Surg 2019;54:2331-2335.
[8] Saltzman AF, Smith DE, Gao D, Cost NG. Lymph node yield in pediatric, adolescent and young adult renal cell carcinoma - How many are enough? J Pediatr Surg 2020;10:2030-2034.
[9] Kuusk T, De Bruijn R, Brouwer OR, et al. Lymphatic drainage from renal tumors in vivo: A prospective sentinel node study using SPECT/CT imaging. J Urol 2018;199:1426-1432.
[10] Høgsholt S, Asdahl PH, Rechnitzer C, et al. Kidney disease in very long-term survivors of Wilms tumor: A nationwide cohort study with sibling controls. Cancer Med 2023;12:1330-1338.
[11] Green DM, Wang M, Krasin MJ, et al. Long-term renal function after treatment for unilateral, nonsyndromic Wilms tumor. A report from the St. Jude Lifetime Cohort Study. Pediatr Blood Cancer 2020;67:e28271.
[12] Kieran K, Anderson JR, Dome JS, et al. Is adrenalectomy necessary during unilateral nephrectomy for Wilms Tumor? A report from the Children's Oncology Group. J Pediatr Surg 2013;48:1598-1603.
[13] Gow K, Barnhart DC, Hamilton TE, et al. Primary nephrectomy and intraoperative tumor spill: report from the Children's Oncology Group (COG) Renal Tumors Committee. J Pediatr Surg 2013;48:34-38.
[14] D'Angio GJ, Breslow N, Beckwith JB, et al. The treatment of Wilms' tumor: results of the National Wilms' Tumor Study. Cancer 1976;38:633-646.
[15] D'Angio GJ. Editorial: SIOP (International Society of Paediatric Oncology) and the management of Wilms' tumor. J Clin Oncol 1983;1:595-596.
[16] Kalapurakal JA, Li SM, Breslow NE, et al. Intraoperative spillage of favorable histology Wilms tumor cells: influence of irradiation and chemotherapy on abdominal recurrence. A report from the National Wilms Tumor Study Group. Int J Rad Oncol Biol Phys 2010;76:201-206.
[17] Jereb B, Burgers JM, Tournade MF, et al. Radiotherapy in the SIOP (International Society of Pediatric Oncology) nephroblastoma studies: a review. Med Pediatr Oncol 1994;22:221-227.
[18] Lemerle J, Vourte PA, Tournade MF, et al. Effectiveness of preoperative chemotherapy in Wilms' tumor: results of an International Society of Pediatric Oncology (SIOP) clinical trial. J Clin Oncol 1983;1:604-609.
[19] Tournade MF, Com-Nougue C, de Kraker J, et al. Optimal duration of preoperative therapy in unilateral and nonmetastatic Wilms' tumor in children older than 6 months: results of the Ninth International Society of Pediatric Oncology Wilms' Tumor Trial and Study. J Clin Oncol 2001;19:488-500.
[20] Scott RH, Stiller CA, Walker L, Rahman N. Syndromes and constitutional chromosomal abnormalities associated with Wilms tumour. J Med Genet 2006;43:705-715.
[21] Ehrlich PF, Chi YY, Chintagumpala MM, et al. Results of treatment for patients with multicentric or bilaterally predisposed unilateral Wilms tumor (AREN0534): A report from the Children's Oncology Group. Cancer 2020;126:3516-3525.
[22] Cost NG, Lubahn JD, Granberg CF, et al. Pathological review of Wilms tumor nephrectomy specimens and potential implications for nephron sparing surgery in Wilms tumor. J Urol 2012;188:1506-10.
[23] Ferrer FA, Rosen N, Herbst K, et al. Image based feasibility of renal sparing surgery for very low risk unilateral Wilms tumors: a report from the Children's Oncology Group. J Urol 2013;190:1846-51.
[24] Glick RD, Romao RL, Pachl M, et al. Current surgical approaches to pediatric renal tumors. Pediatr Blood Cancer 2024:e31118.
[25] Wilcox Vanden Berg RN, Bierman EN, Van Noord M, et al. Nephron-sparing surgery for Wilms tumor: A systematic review. Urol Oncol 2016;34:24-32.

Note: All recommendations are category 2A unless otherwise indicated.

Version 2.2025, 6/11/2025 © 2025 National Comprehensive Cancer Network® (NCCN®), All rights reserved. NCCN Guidelines® and this illustration may not be reproduced in any form without the express written permission of NCCN.

PLEASE NOTE that use of this NCCN Content is governed by the End-User License Agreement, and you MAY NOT distribute this Content or use it with any artificial intelligence model or tool.
Printed by A. S. M. FAZLUL KARIM CHOWDHURY on 4/20/2026 3:41:05 AM. Copyright © 2026 National Comprehensive Cancer Network, Inc. All Rights Reserved.

PRINCIPLES OF BIOPSY

- **Routine pre-nephrectomy biopsy for resectable renal tumors is contraindicated due to the risk of recurrence from tumor spill. Further, tumor biopsy will automatically upstage the local stage to III, which in turn mandates additional cardiotoxic chemotherapy (doxorubicin) and RT (for treatment of those with unilateral tumor without a predisposing condition).**
- **The only situation in which a pre-treatment biopsy is recommended is when the tumor is deemed unresectable in patients with a unilateral tumor without a predisposing condition. If a biopsy is thus considered, there are two possible options: 1) an open posterior approach—done to avoid intra-abdominal spill; or 2) percutaneous core needle biopsies (fine-needle aspirates are not recommended). In both instances, sufficient tissue must be obtained so that all necessary tests may be performed. Identification of anaplasia may be difficult by either biopsy technique.**
- **If surgical exploration is performed with intent to resect but the tumor is deemed unresectable, then open biopsy should be performed.**

Note: All recommendations are category 2A unless otherwise indicated.

Version 2.2025, 6/11/2025 © 2025 National Comprehensive Cancer Network® (NCCN®), All rights reserved. NCCN Guidelines® and this illustration may not be reproduced in any form without the express written permission of NCCN.

PLEASE NOTE that use of this NCCN Content is governed by the End-User License Agreement, and you MAY NOT distribute this Content or use it with any artificial intelligence model or tool.
Printed by A. S. M. FAZLUL KARIM CHOWDHURY on 4/20/2026 3:41:05 AM. Copyright © 2026 National Comprehensive Cancer Network, Inc. All Rights Reserved.

INITIAL AND FINAL RISK ASSESSMENT FOR FHWT

- **Risk-based therapy is determined by tumor stage, histologic classification, molecular markers, and, when indicated, initial response to chemotherapy. Risk stratification is used to assign the most appropriate therapy to patients, with a goal of maximizing good outcome while balancing risk of toxicity of therapies. Risk stratification has evolved through multiple large collaborative clinical trials. Current risk stratification includes consideration of tumor histology, histopathologic and surgical stage, tumor biology (LOH of 1p and 16q), presence of metastatic or bilateral disease, and clinical factors such as patient age, known predisposing conditions, and response of pulmonary lesions to initial therapy. Additional tumor biomarkers have been associated with increased risk of relapse (LOH and LOI of 1p and 16q, 1q gain), but alteration of therapy has not yet been studied.**
- **Cytogenetic and molecular testing are recommended for all newly diagnosed FHWT to assess for unfavorable biomarkers, including chromosome 1q gain and/or LOH in chromosomes 1p and 16q.[1,2] There are fewer data for using 11p15 LOH or LOI as unfavorable biomarkers. There are no data for using chromosome 17p13 to direct therapy. Results from molecular testing can be obtained in 2 weeks.**
- **Initial risk is based on age, clinical, radiographic, surgical, and pathologic findings.**
- **Final risk is based on initial risk plus LOH at 1p and 16q, and response of lung metastases at week 6.**

Patient Age	Tumor Weight	Stage	Initial Risk Group	LOH 1p/16q	Lung Metastases Response	Extra-Pulmonary Metastases	Final Risk Group
<2 years	<550 g	I	Very Low	Any	N/A	N/A	Very Low (WILMS-3)
Any	≥550 g	I	Low	No	N/A	N/A	Low (WILMS-3)
≥2 years	Any	I	Low	No	N/A	N/A	Low (WILMS-3)
Any	Any	II	Low	No	N/A	N/A	Low (WILMS-3)
Any	≥550 g	I	Low	Yes	N/A	N/A	Standard (WILMS-3)
≥2 years	Any	I	Low	Yes	N/A	N/A	Standard (WILMS-3)
Any	Any	II	Low	Yes	N/A	N/A	Standard (WILMS-3)
Any	Any	III	Standard	No	N/A	N/A	Standard (WILMS-3)
Any	Any	IV	Higher	No	Complete	No	Standard (WILMS-3)
Any	Any	III	Standard	Yes	N/A	N/A	Higher (WILMS-4)
Any	Any	IV	Higher	Yes	Any	Any	Higher (WILMS-4)
Any	Any	IV	Higher	Any	Partial	Any	Higher (WILMS-4)
Any	Any	IV	Higher	Any	Any	Yes	Higher (WILMS-4)
Any	Any	V	Bilateral	Any	Any	Any	Bilateral (WILMS-8)

[1] Gratias EJ, Dome JS, Jennings LJ, et al. Association of chromosome 1q gain with inferior survival in favorable-histology Wilms tumor: a report from the Children's Oncology Group. J Clin Oncol 2016;34:3189-3194.
[2] Grundy PE, Breslow NE, Li S, et al. Loss of heterozygosity for chromosomes 1p and 16q is an adverse prognostic factor in favorable-histology Wilms tumor: a report from the National Wilms Tumor Study Group. J Clin Oncol 2005;23:7312-7321.

Note: All recommendations are category 2A unless otherwise indicated.

Version 2.2025, 6/11/2025 © 2025 National Comprehensive Cancer Network® (NCCN®), All rights reserved. NCCN Guidelines® and this illustration may not be reproduced in any form without the express written permission of NCCN.

PLEASE NOTE that use of this NCCN Content is governed by the End-User License Agreement, and you MAY NOT distribute this Content or use it with any artificial intelligence model or tool.
Printed by A. S. M. FAZLUL KARIM CHOWDHURY on 4/20/2026 3:41:05 AM. Copyright © 2026 National Comprehensive Cancer Network, Inc. All Rights Reserved.

PRINCIPLES OF CHEMOTHERAPY

General Principles

- The administration of adjuvant, and in some cases neoadjuvant, chemotherapy in combination with surgery ± radiation markedly improves survival for WT.[1-6]
- Selection of the appropriate chemotherapy regimen is based on tumor histology, stage, tumor weight, the patient's age, response of lung metastases (when present) to chemotherapy, and molecular markers, which together determine the risk group (see Initial and Final Risk Assessment for FHWT [WILMS-F]).
- Adjuvant chemotherapy should be started within 7 to 14 days of up-front nephrectomy and the timing should be coordinated with radiation, if it is required, to avoid co-administration of full doses of dactinomycin or doxorubicin with radiation. Dactinomycin and doxorubicin can be administered at full doses prior to the start of radiation.
- Neoadjuvant chemotherapy is administered for unresectable tumors or tumors for which NSS is indicated (see Principles of Surgery [WILMS-D]) to reduce the size of the tumor(s).
  - Re-image after 6 weeks of neoadjuvant chemotherapy to determine whether the tumor(s) is/are resectable.
  - The postoperative adjuvant chemotherapy regimen is determined by tumor histology, stage, and molecular markers.

Chemotherapy Regimens

- EE4A: 13 doses of vincristine and 7 doses of dactinomycin administered over 18 weeks.[7,8]
- DD4A: 15 doses of vincristine, 5 doses of dactinomycin, and 4 doses of doxorubicin (cumulative dose 150 mg/m^2) administered over 24 weeks with alternating doses of dactinomycin and doxorubicin.[1,2]
- VAD: 6–12 doses of vincristine, 2–4 doses of dactinomycin, and 2–4 doses of doxorubicin (cumulative dose 70–140 mg/m^2) administered over 6–12 weeks used only in the neoadjuvant setting for patients who are candidates for NSS. In this regimen dactinomycin and doxorubicin are given together.[9]
- Regimen M: 9 doses of vincristine, 5 doses of dactinomycin, 5 doses of doxorubicin (cumulative dose 150 mg/m^2), 4 cycles of 5 daily doses of cyclophosphamide (cumulative dose 8,800 mg/m^2), and 4 cycles of 5 daily doses of etoposide over 24 weeks. Dactinomycin and doxorubicin are given together, and cyclophosphamide and etoposide are given together. This regimen starts at week 7 for tumors requiring augmentation of therapy based on molecular markers or response of lung metastases to 6 weeks of DD4A.[10,11]
- Regimen I: 9 doses of vincristine, 4 doses of doxorubicin (cumulative dose 180 mg/m^2), 7 cycles of 3 or 5 daily doses of cyclophosphamide (cumulative dose 11,880 mg/m^2), and 3 cycles of 5 daily doses of etoposide. Doxorubicin and 3 daily doses of cyclophosphamide are given together, and 5 daily doses of cyclophosphamide and etoposide are given together. This regimen starts at week 7 for tumors requiring augmentation of therapy based on histology.[9,11,12]
- Revised Regimen UH-1: 15 doses of vincristine, 5 doses of doxorubicin (cumulative dose 225 mg/m^2), 5 single doses of cyclophosphamide (total cumulative dose 14,800 mg/m^2), 5 cycles of 4 doses of cyclophosphamide, 5 doses of carboplatin, and 5 cycles of 4 doses of etoposide for stage IV WT with focal anaplasia.[13]
- Revised Regimen UH-2: 19 doses of vincristine, 5 doses of doxorubicin (cumulative dose 225 mg/m^2), 5 doses of cyclophosphamide (total cumulative dose 14,800 mg/m^2), 5 cycles of 4 daily doses of cyclophosphamide, 5 doses of carboplatin, 5 cycles of 4 daily doses of etoposide, and 2 cycles of 5 daily doses of irinotecan. This regimen is used for stage II–IV WT with diffuse anaplasia.[13]

Continued
References

Note: All recommendations are category 2A unless otherwise indicated.

Version 2.2025, 6/11/2025 © 2025 National Comprehensive Cancer Network® (NCCN®), All rights reserved. NCCN Guidelines® and this illustration may not be reproduced in any form without the express written permission of NCCN.

PLEASE NOTE that use of this NCCN Content is governed by the End-User License Agreement, and you MAY NOT distribute this Content or use it with any artificial intelligence model or tool.
Printed by A. S. M. FAZLUL KARIM CHOWDHURY on 4/20/2026 3:41:05 AM. Copyright © 2026 National Comprehensive Cancer Network, Inc. All Rights Reserved.

PRINCIPLES OF CHEMOTHERAPY[a]

Chemotherapy Toxicity

- The types of acute and long-term toxicities and the severity of the toxicities from the treatment regimens used for WT previously described are dependent on the number and types of anticancer drugs included in the regimen. More intensive regimens with more drugs are used to treat tumors in higher risk groups. The greater risk of toxicities from these regimens is balanced by a lower risk of relapse. Treatment for relapse is intensive with drugs that have increased acute and late toxicities; survival after relapse remains unsatisfactory.
- Doxorubicin—which is included in Regimens DD4A, VAD, M, I, and UH-2—can cause myocardial damage, correlated to the cumulative dose of the drug. Although the cumulative dose of doxorubicin on these regimens is 150 to 250 mg/m^2, younger children, especially children assigned female at birth, are more susceptible to doxorubicin cardiotoxicity. An echocardiogram to assess cardiac function should be performed prior to the first dose of doxorubicin and then prior to exceeding a cumulative dose of 200 mg/m^2 and at the end of treatment to monitor cardiac function.
- Cyclophosphamide and etoposide—which are included in Regimens M, I, and Revised Regimen UH-2—increase the risk of acute toxicities, such as myelosuppression, and of long-term effects, including infertility and secondary cancers later in life. The cumulative dose of cyclophosphamide is lower in Regimen M (8.8 g/m^2) than in Regimen I (11.88 g/m^2). The cumulative dose of etoposide is ≤2 g/m^2 in Regimens M and I. Cumulative doses >4 g/m^2 cyclophosphamide equivalent dose are associated with a risk of oligospermia and azoospermia.[14-16]
- The UH-1 and UH-2 Regimens used to treat anaplastic WT are the most toxic regimens used to treat WT. Several toxicity-related deaths occurred in patients treated with UH-1, but there were no toxic deaths on the revised UH-2 Regimen.[17]
- 0.8% of patients experience severe hepatopathy, including sinusoidal obstruction syndrome, which presents with abdominal distension, ascites, hepatomegaly, elevated transaminases, and bilirubin and thrombocytopenia. Severe hepatopathy occurred most often after a course of vincristine and dactinomycin, but radiation to the liver also contributes to this level of hepatopathy. Treatment could be safety reintroduced in the vast majority of patients after recovery.[18]

Dose Modifications

- Infants do not tolerate chemotherapy drugs that have been dosed based on body surface area (BSA). Dosing based on body weight rather than BSA using the 30-Rule (BSA dose divided by 30 and multiplied by the body weight) is better tolerated. Recently, a uniform method of infant dosing of chemotherapy drugs was devised and implemented using BSA-banded infant dosing tables for patients with a BSA <0.6 m^2.[19]
- For 6 weeks after WLI or WAI, the doses of dactinomycin and doxorubicin should be reduced by 50% to ameliorate radiation recall reactions.

Supportive Care

- The addition of dexrazoxane can be considered for all children receiving doxorubicin. If the planned cumulative dose of doxorubicin will exceed 150 mg/m^2, dexrazoxane should be administered prior to each dose of doxorubicin to ameliorate cardiotoxicity. Dexrazoxane dosing is given as a 10:1 dose ratio of dexrazoxane:doxorubicin.
- Colony-stimulating factors (filgrastim or pegfilgrastim)[a] are not necessary after doses of myelosuppressive agents in Regimens EE4A, DD4A, and VAD, but should be considered for cycles of cyclophosphamide and etoposide, and cyclophosphamide, doxorubicin, vincristine and cycles of cyclophosphamide, carboplatin, and etoposide in Regimen M; Regimen I; Revised Regimen UH-1; and Revised Regimen UH-2.

[a] An FDA-approved biosimilar is an appropriate substitute for any recommended systemic biologic therapy in the NCCN Guidelines.

Note: All recommendations are category 2A unless otherwise indicated.

Continued
References

Version 2.2025, 6/11/2025 © 2025 National Comprehensive Cancer Network® (NCCN®), All rights reserved. NCCN Guidelines® and this illustration may not be reproduced in any form without the express written permission of NCCN.

PLEASE NOTE that use of this NCCN Content is governed by the End-User License Agreement, and you MAY NOT distribute this Content or use it with any artificial intelligence model or tool.
Printed by A. S. M. FAZLUL KARIM CHOWDHURY on 4/20/2026 3:41:05 AM. Copyright © 2026 National Comprehensive Cancer Network, Inc. All Rights Reserved.

PRINCIPLES OF CHEMOTHERAPY

Treatment Augmentation for FHWT

- **Treatment was augmented from Regimen DD4A to Regimen M at week 7 of therapy on the most recent series of Children's Oncology Group (COG) FHWT clinical trials for[3,4,10,11,20,21]:**
  - **Patients with stage III or IV FHWT with LOH at 1p and 16q**
  - **Patients with stage IV FHWT and lung metastases only who did not achieve a CR after 6 weeks of Regimen DD4A**
  - **Patients with stage IV FHWT and extrapulmonary metastases**
- **Regimen M includes 4 cycles of cyclophosphamide and etoposide.**
- **Event-free survival (EFS) for patients with stage III or IV tumors that express LOH at 1p and 16q treated with Regimen M was improved compared to a historical control group from NWTS-5, but the stage distribution differed between the two groups and overall survival (OS) was not significantly better with Regimen M.**
- **Patients with extrapulmonary metastases treated with Regimen M on the AREN0533 trial had higher 4-year EFS than patients treated with DD4A on the NWTS-5 trial[b] (76% vs. 64%; *P* = .26), but OS was the same.[22]**
- **Treatment was augmented from neoadjuvant VAD or EE4A to Regimen I at week 7 of therapy on COG trial AREN0534 for blastemal-predominant histology in the post-neoadjuvant resected specimen based on the higher risk of relapse with this histology in European clinical trials.[23]**
- **Regimen M resulted in 4-year EFS and OS of 88.5% and 95.4% for patients with SIR of lung metastases.[3,4,10,20,21] These outcomes should be balanced against the increased risk of toxicities and limitations of using a historical control as a comparator.[3,4,10,20,21]**

[b] This difference was not statistically significant.

Note: All recommendations are category 2A unless otherwise indicated.

Version 2.2025, 6/11/2025 © 2025 National Comprehensive Cancer Network® (NCCN®), All rights reserved. NCCN Guidelines® and this illustration may not be reproduced in any form without the express written permission of NCCN.

PLEASE NOTE that use of this NCCN Content is governed by the End-User License Agreement, and you MAY NOT distribute this Content or use it with any artificial intelligence model or tool.
Printed by A. S. M. FAZLUL KARIM CHOWDHURY on 4/20/2026 3:41:05 AM. Copyright © 2026 National Comprehensive Cancer Network, Inc. All Rights Reserved.

PRINCIPLES OF CHEMOTHERAPY
REFERENCES

[1] Fernandez CV, Perlman EJ, Mullen EA, et al. Clinical outcome and biological predictors of relapse after nephrectomy only for very low-risk Wilms tumor: A report from Children's Oncology Group AREN0532. Ann Surg 2017;265:835-840.
[2] Fernandez CV, Mullen EA, Chi YY, et al. Outcome and prognostic factors in stage III favorable-histology Wilms tumor; A report from the Children's Oncology Group Study AREN0532. J Clin Oncol 2018;36:254-261.
[3] Dome JS, Mullen EA, Bix DB, et al. Impact of the first generation of Children's Oncology Group clinical trials on clinical practice for Wilms tumor. J Natl Compr Canc Netw 2021;19:978-985.
[4] Green DM. Letter to the editor: impact of the first generation of Children's Oncology Group clinical trials on clinical practice for Wilms tumor. J Natl Compr Canc Netw 2022;20:xlvi-xlvii.
[5] Daw NC, Chi YY, Kim Y, et al. Treatment of stage I anaplasic Wilms' tumour: a report from the Children's Oncology Group AREN0321 study. Eur J Cancer 2019;118:58-66.
[6] Dome JS, Cofon CA, Perlman EJ, et al. Treatment of anaplastic histology Wilms' tumor: results from the fifth National Wilms' Tumor Study. J Clin Oncol 2006;24:2352-2358.
[7] Green DM, Breslow NE, Beckwith JB, et al. Comparison between single-dose and divided-dose administration of dactinomycin and doxorubicin for patients with Wilms' Tumor: a report from the National Wilms' Tumor Study Group. J Clin Oncol 1998;16:237-245.
[8] Green DM, Breslow NE, Beckwith JB, et al. Effect of duration of treatment on treatment outcome and cost of the treatment for Wilms' tumor: a report from the National Wilms' Tumor Study Group. J Clin Oncol 1998;16:3744-3751.
[9] Ehrlich PF, Chi YY, Chintagumpala MM, et al. Results of the first prospective multi-institutional treatment study in children with bilateral Wilms tumor (AREN0534): A report from the Children's Oncology Group. Ann Surg 2017;266:470-478. Erratum in: Ann Surg 2018;267:e64.
[10] Dix DB, Seibel NL, Chi YY, et al. Treatment of stage IV favorable histology Wilms tumor with lung metastases: A report from the Children's Oncology Group AREN0533 Study. J Clin Oncol 2018;36:1564-1570.
[11] Dix DB, Fernandez CV, Chi YY, et al. Augmentation of therapy for combined loss of heterozygosity 1p and 16q in favorable histology Wilms tumor: A Children's Oncology Group AREN0532 and AREN0533 study report. J Clin Oncol 2019;37:2769-2777.
[12] Seibel NL, Chi YY, Perlman EJ, et al. Impact of cyclophosphamide and etoposide on outcome of clear cell sarcoma of the kidney treated on the National Wilms Tumor Study-5 (NWTS-5). Pediatr Blood Cancer 2019;66:e27450.
[13] Dome JS, Cotton CA, Perlman EJ, et al. Treatment of anaplastic histology Wilms' tumor: results from the fifth National Wilms' Tumor Study. J Clin Oncol 2006;24:2352-2358.
[14] Green DM, Liu W, Kutteh WH, et al. Cumulative alkylating agent exposure and semen parameters in adult survivors of childhood cancer: A report from the St Jude Lifetime Cohort Study. Lancet Oncol 2014;15:1215-1223.
[15] Meachem LR, Burns K, Orwig KE, Levine J. Standardizing risk assessment for treatment-related gonadal insufficiency and infertility in childhood adolescent and young adult cancer: The pediatric initiative network risk stratification system. J Adolesc Young Adult Oncol 2020:9;662-666.
[16] Green DM, Nolan VG, Goodman PJ, et al. The cyclophosphamide equivalent dose as an approach for quantifying alkylating agent exposure: a report from the Childhood Cancer Survivor Study. Pediatr Blood Cancer 2014;61:53-67
[17] Daw NC, Chi YY, Kalapurakal JA, et al. Activity of vincristine and irinotecan in diffuse anaplastic Wilms tumor and therapy outcomes of stage II to IV disease: results of the Children's Oncology Group AREN0321 Study. J Clin Oncol 2020;38:1558-1568.
[18] Oosterom N, Gooskens SLM, Renfro LA, et al. Severe Hepatopathy in National Wilms Tumor Studies 3-5: Prevalence, Clinical Features, and Outcomes After Reintroduction of Chemotherapy. J Clin Oncol 2023;41:4247-4256.
[19] Balis FM, Womer RB, Berg S, et al. Dosing anticancer drugs in infants: Current approach and recommendations from the Children's Oncology Group's Chemotherapy Standardization Task Force. Pediatr Blood Cancer 2017;64:e26636.
[20] Dome JS. Reply to DM Green. Am J Clin Oncol 2018;36:3179-3180.
[21] Dome JS, Mullen EA, Dix DB, et al. Author's reply to the letter to the editor by Daniel M. Green. J Natl Compr Canc Netw 2022;20:xlvii-xlviii.
[22] Benedetti DJ, Varela CR, Renfro LA, et al. Treatment of children with favorable histology Wilms tumor with extrapulmonary metastases: A report from the COG studies AREN0533 and AREN03B2 and NWTSG study NWTS-5. Cancer 2024;130:947-961.
[23] van den Heuvel-Eibrink MM, van Tinteren H, Bergeron C, et al. Outcome of localised blastemal-type Wilms tumour patients treated according to intensified treatment in the SIOP WT 2001 protocol, a report of the SIOP Renal Tumour Study Group (SIOP-RTSG). Eur J Cancer 2015;51:498-506.

Note: All recommendations are category 2A unless otherwise indicated.

Version 2.2025, 6/11/2025 © 2025 National Comprehensive Cancer Network® (NCCN®), All rights reserved. NCCN Guidelines® and this illustration may not be reproduced in any form without the express written permission of NCCN.

PLEASE NOTE that use of this NCCN Content is governed by the End-User License Agreement, and you MAY NOT distribute this Content or use it with any artificial intelligence model or tool.
Printed by A. S. M. FAZLUL KARIM CHOWDHURY on 4/20/2026 3:41:05 AM. Copyright © 2026 National Comprehensive Cancer Network, Inc. All Rights Reserved.

PRINCIPLES OF RADIATION THERAPY

NCCN recommendations have been developed to be inclusive of individuals of all sexual and gender identities to the greatest extent possible. On this page, the terms male and female refer to sex assigned at birth.

- **Consulting a radiation oncologist is recommended at time of diagnosis of WT.[a,b]**

Radiotherapy Timing

- **RT should be started by day 10 after definitive surgery (preferred) but no later than day 14, if surgery is designated as day 0. A later radiation start is linked to increased risk of abdominal recurrence in some studies.[1-3]**
- **Consider patient factors when deciding about the timing of RT (eg, age of patient, need to assess response of lung metastases to chemotherapy), when giving whole abdomen and whole lung RT.**

Flank Radiation

- **Indications[a,b]: Discussion with the surgeon about at-risk areas is necessary for all patients and particularly in the setting of intraoperative spillage, whether focal or diffuse (as determined by the surgeon). If focal spill is confirmed to be localized and contained within a flank field, then flank RT is recommended. See ST-1 for staging criteria. Local stage III refers to staging at the primary tumor regardless of metastases.**
- **Target volume: Contour the preoperative tumor on presentation imaging (either CT or MRI). Add a 1-cm clinical target volume (CTV) expansion while respecting anatomical barriers. If this target would create a dose gradient along the vertebral body, contour the adjacent vertebral bodies. Add a 5- to 10-mm planning target volume (PTV) margin.**
- **Flank + para-aortic nodal volume: Traditional para-aortic fields include the entire chain from the crus of the diaphragm to the bottom of L5. CTV should include all enlarged nodes on preoperative imaging. Add a 5- to 10-mm PTV margin.**
  - **Indication: If LNs are positive, an additional boost is given to unresected nodes.**
- **Delivery of RT has traditionally been done with 3D conformal photons, although IMRT and proton therapy are options at experienced centers. Shielding of the contralateral kidney should be considered in the flank area. Boost modality should be more conformal with three-dimensional conformal RT (3D-CRT), intensity-modulated RT (IMRT), or protons.**
- **Testicular shielding should be used for most males.**

Whole Abdominal Irradiation (WAI)

- **Indications[a,b]: Discussion with the surgeon about at-risk areas is necessary for all patients and particularly in the setting of both intraoperative spillage (whether focal or diffuse) and preoperative rupture (as determined by the surgeon). If preoperative rupture has occurred, then WAI is recommended. See ST-1 for staging criteria.**
- **Target volume: The CTV shall encompass the entire peritoneal cavity that includes the dome of the diaphragm superiorly and extends inferiorly to the pelvic diaphragm. A four-dimensional (4D)-CT should be used to determine diaphragm motion. Final PTV expansion should be similar to the traditional field borders listed below.**
- **Traditional field borders:**
  - **Superior: 1 cm above dome of diaphragm**
  - **Inferior: Bottom of obturator foramen (femoral heads should be blocked)**
  - **Lateral: 1 cm beyond lateral abdominal walls**

[a] Recommend fertility counseling for female patients receiving flank RT and/or WAI, which may cause impairment of fertility.
[b] For patients with unilateral renal tumor with predisposing conditions or bilateral renal tumors, a local stage III due to biopsy only may not need RT.

Note: All recommendations are category 2A unless otherwise indicated.

Continued
References

Version 2.2025, 6/11/2025 © 2025 National Comprehensive Cancer Network® (NCCN®), All rights reserved. NCCN Guidelines® and this illustration may not be reproduced in any form without the express written permission of NCCN.

PLEASE NOTE that use of this NCCN Content is governed by the End-User License Agreement, and you MAY NOT distribute this Content or use it with any artificial intelligence model or tool.
Printed by A. S. M. FAZLUL KARIM CHOWDHURY on 4/20/2026 3:41:05 AM. Copyright © 2026 National Comprehensive Cancer Network, Inc. All Rights Reserved.

PRINCIPLES OF RADIATION THERAPY (CONTINUED)

Supplemental, "Boost" Irradiation

- **Indications: Supplemental irradiation is required after flank RT or WAI for gross residual tumor. Treatment technique: Conformal techniques are preferred (3D-CRT, IMRT, or protons).**
- **Target volume: 3D imaging data should be acquired with the patient in the treatment position to define a gross tumor volume (GTV), CTV, PTV, and critical structures. 4D imaging should be considered.**
  - **GTV is the postoperative residual tumor and should be based on imaging performed for treatment planning and postoperative diagnostic CT/MRI.**
  - **CTV will be an anatomically confined margin of 0.5 cm surrounding the GTV.**
  - **PTV will be a geometrically expanded margin surrounding the CTV. The PTV margin will be chosen by the local institution, ranging from 0.5–1 cm.**

Whole Lung Irradiation (WLI)

- **Indications: WLI is recommended in patients with lung metastases and other extra-thoracic metastases (such as liver, bone, or brain), LN metastases in the hilum and/or mediastinum, or cytology-positive pleural effusion regardless of response to chemotherapy.**
  WLI can be delayed to week 6 in select patients with FHWT who only have metastases in the lungs and do not have 1q gain or combined LOH at 1p and 16q. WLI can be omitted if there is a CR to chemotherapy and the tumor did not have 1q gain or combined LOH at 1p and 16q.
- **Target volume: The CTV is the entire pleural surface of lung on CT simulation. Add a 5- to 10-mm PTV.**
- **Technique:**
  - **Anteroposterior/posteroanterior (AP/PA), IMRT,[4-6] or protons.[7]**
  - **If possible, 4D imaging for motion assessment with creation of internal target volume (ITV) is recommended.**
- **If treating, or potentially treating, whole lung and abdomen/flank, consider planning the entire treatment up front.**

Note: All recommendations are category 2A unless otherwise indicated.

Continued
References

Version 2.2025, 6/11/2025 © 2025 National Comprehensive Cancer Network® (NCCN®), All rights reserved. NCCN Guidelines® and this illustration may not be reproduced in any form without the express written permission of NCCN.

PLEASE NOTE that use of this NCCN Content is governed by the End-User License Agreement, and you MAY NOT distribute this Content or use it with any artificial intelligence model or tool.
Printed by A. S. M. FAZLUL KARIM CHOWDHURY on 4/20/2026 3:41:05 AM. Copyright © 2026 National Comprehensive Cancer Network, Inc. All Rights Reserved.

PRINCIPLES OF RADIATION THERAPY (CONTINUED)

Table 1: Radiation Doses[c,8]

Treatment Site	Clinical Presentation	Indications for RT-Wilms Tumor	Dose	Supplemental RT
Flank	Local Stage III	FHWT	10.8 Gy at 1.8 Gy/ fraction	Residual tumor = 10.8 Gy
	Stages I, II, III	Focal anaplasia	10.8 Gy at 1.8 Gy/ fraction	Residual tumor = 10.8 Gy Patients ≥16 y = 19.8 Gy
	Stages I, II	Diffuse anaplasia	10.8 Gy at 1.8 Gy/ fraction	Residual tumor = 10.8 Gy Patients ≥16 y = 19.8 Gy
	Stage III	Diffuse anaplasia	19.8 Gy	Residual tumor = 10.8 Gy
WAI	Local Stage III	FHWT	10.5 Gy at 1.5 Gy/ fraction	
	Abdominal Stage III— • Preoperative tumor rupture • Peritoneal metastases found at initial surgery • A large intraoperative tumor spill outside the tumor bed as determined by the surgeon/treating institution	FHWT, focal anaplasia, or diffuse anaplasia	10.5 Gy at 1.5 Gy/ fraction	Residual tumor = 10.8 Gy or 10.5 Gy Patients ≤12 months with stage III who require WAI will have their total dose limited to 10.5 Gy
	Abdominal Stage III— • Diffuse unresectable peritoneal implants	FHWT, focal anaplasia, or diffuse anaplasia	21 Gy	Patients ≤12 months with stage III who require WAI will have their total dose limited to 10.5 Gy

[c] The noted radiation doses for anaplastic WT are per the AREN0321 study.

Note: All recommendations are category 2A unless otherwise indicated.

Continued
References

Version 2.2025, 6/11/2025 © 2025 National Comprehensive Cancer Network® (NCCN®), All rights reserved. NCCN Guidelines® and this illustration may not be reproduced in any form without the express written permission of NCCN.

PLEASE NOTE that use of this NCCN Content is governed by the End-User License Agreement, and you MAY NOT distribute this Content or use it with any artificial intelligence model or tool.
Printed by A. S. M. FAZLUL KARIM CHOWDHURY on 4/20/2026 3:41:05 AM. Copyright © 2026 National Comprehensive Cancer Network, Inc. All Rights Reserved.

PRINCIPLES OF RADIATION THERAPY (CONTINUED)

Table 2: Radiation Doses[d]

Treatment Site - Metastases	Clinical Presentation - Metastases	Indications for RT-Wilms Tumor	Dose	Supplemental Information
WLI	Lung metastases	Lung metastases	10.5 Gy at 1.5 Gy per fraction	Age <12 months
			12 Gy at 1.5 Gy per fraction	Age >12 months
LN Irradiation	LN metastases	Resected LN metastases	10.8 Gy at 1.8 Gy per fraction	
		Unresected LN metastases	10.8 Gy at 1.8 Gy per fraction	• Followed by focal boost to 19.8 Gy at 1.8 Gy per fraction
Whole Brain Irradiation	Brain metastases	Brain metastases	21.6 Gy in 12 fractions	• 21.6 Gy in 12 fractions whole brain followed by local boost of 10.8 Gy in 6 fractions (<5 lesions) • In patients with >5 lesions, whole brain RT to a dose of 30.6 Gy is recommended. When the whole brain dose is 30.6 Gy, no further boost is required.
Liver Irradiation	One liver metastasis	Focal radiation	19.8 Gy in 11 fractions	
	>1 or diffuse metastases	Whole liver	19.8 Gy in 11 fractions	

NORMAL TISSUE DOSE CONSTRAINTS[e]

Organs at Risk (OAR)	DVH Metric	Dose (Gy)
Kidney (whole)	D100%	<14.4
Kidney (partial)	D50%	<19.8
Liver (whole)	D100%	<23.4
Liver (partial)	D50%	<30.6
Lung Bilateral (whole)	D100%	<15.0
Lung Bilateral (partial)	D20%	<20.0
Heart (whole)	D100%	<30.0
Spinal cord (maximum dose)	D0.03cc	<45.0

[d] The noted radiation doses are per the AREN0321 study.
[e] The noted normal tissue constraints are per ongoing clinical trial AREN1921.

Note: All recommendations are category 2A unless otherwise indicated.

References

Version 2.2025, 6/11/2025 © 2025 National Comprehensive Cancer Network® (NCCN®), All rights reserved. NCCN Guidelines® and this illustration may not be reproduced in any form without the express written permission of NCCN.

PLEASE NOTE that use of this NCCN Content is governed by the End-User License Agreement, and you MAY NOT distribute this Content or use it with any artificial intelligence model or tool.
Printed by A. S. M. FAZLUL KARIM CHOWDHURY on 4/20/2026 3:41:05 AM. Copyright © 2026 National Comprehensive Cancer Network, Inc. All Rights Reserved.

PRINCIPLES OF RADIATION THERAPY
REFERENCES

[1] D'Angio GJ, Tefft M, Breslow N, Meyer JA. Radiation therapy of Wilms' tumor: Results according to dose, field, post-operative timing and histology. Int J Radiat Oncol Biol Phys 1978;4:769-780.
[2] Kalapurakal JA, Li SM, Breslow NE, et al; National Wilms' Tumor Study Group. Influence of radiation therapy delay on abdominal tumor recurrence in patients with favorable histology Wilms' tumor treated on NWTS-3 and NWTS-4: a report from the National Wilms' Tumor Study Group. Int J Radiat Oncol Biol Phys 2003;57:495-499.
[3] Stokes CL, Stokes WA, Kalapurakal JA, et al. Timing of radiation therapy in pediatric Wilms tumor: a report from the National Cancer Database. Int J Radiat Oncol Biol Phys 2018;101:453-461.
[4] Kalapurakal JA, Lee B, Bautista J, et al. Cardiac-sparing whole lung intensity modulated radiation therapy in children with Wilms Tumor. Final report on technique and abdominal field matching to maximize normal tissue protection. Pract Radiat Oncol 2019;9:e62-e73.
[5] Kalapurakal JA, Zhang Y, Kepka A, et al. Cardiac-sparing whole lung IMRT in children with lung metastasis. Int J Radiat Oncol Biol Phys 2013;85:761-767.
[6] Kalapurakal JA, Gopalakrishnan M, Walterhouse DO, et al. Cardiac-sparing whole lung IMRT in patients with pediatric tumors and lung metastasis: final report of a prospective multicenter clinical trial. Int J Radiat Oncol Biol Phys 2019;103:28-37.
[7] Cunningham DA, Breen WG, Johnson J, et al. Proton whole-lung irradiation: Initial report of outcomes. Int J Radiat Oncol Biol Phys 2023;115:866-872.
[8] Daw NC, Chi Y, Kalapurakal JA, et al. Activity of vincristine and irinotecan in diffuse anaplastic wilms tumor and therapy outcomes of stage II to IV disease: Results of the children's oncology Group AREN0321 study. J Clin Oncol 2020;38:1558-1568.

Note: All recommendations are category 2A unless otherwise indicated.

Version 2.2025, 6/11/2025 © 2025 National Comprehensive Cancer Network® (NCCN®), All rights reserved. NCCN Guidelines® and this illustration may not be reproduced in any form without the express written permission of NCCN.

PLEASE NOTE that use of this NCCN Content is governed by the End-User License Agreement, and you MAY NOT distribute this Content or use it with any artificial intelligence model or tool.
Printed by A. S. M. FAZLUL KARIM CHOWDHURY on 4/20/2026 3:41:05 AM. Copyright © 2026 National Comprehensive Cancer Network, Inc. All Rights Reserved.

PRINCIPLES OF CANCER RISK ASSESSMENT AND COUNSELING

- **Principles of Cancer Risk Assessment and Counseling: See NCCN Guidelines for Genetic/Familial High-Risk Assessment: Breast, Ovarian, Pancreatic, and Prostate (EVAL-A)**
- **Pedigree: First-, Second-, and Third-Degree Relatives of Proband: See NCCN Guidelines for Genetic/Familial High-Risk Assessment: Breast, Ovarian, Pancreatic, and Prostate (EVAL-B)**
- **Genetic testing should be considered for all patients with WT; however, the highest risk of underlying cancer predisposition is in individuals with bilateral and/or multifocal, early-onset (age <2 years), and/or familial WT as well as patients with multiple nephrogenic rests or clinical features of WT predisposing conditions.[1-3] Consider germline testing for patients with physical findings consistent with predisposing conditions. In settings where counseling and testing for all children is not available, decision-support algorithms such as the MIPOGG tool can be used to prioritize children for genetic testing.[4,5]**

- **Most common somatic variants in WT are:**
  - ***CTNNB1, DROSHA, WT1, WTX (AMER-1), DGCR8, SIX1, BCORL1, MLLT1, MYCN,* and *SIX2*; *TP53* is associated with anaplastic WT.[6]**
  - ***WT1*, a tumor suppressor gene found on chromosome 11p13, is implicated in the development of WT. *WT1* codes a transcription factor crucial for normal kidney/genitourinary function (5%–10% of cases).[7-16]**
  - ***WT2*, a tumor suppressor gene found on chromosome 11p15, is also implicated in the development of WT.**
- **Additional genes recurrently mutated in the germline of patients with WT include:[4,6,17,18]**
  - ***REST, TRIM28, FBXW7, NYNRIN, KDM3B, XPO5,* and *DICER1***
- **Congenital malformations**
  - **Aniridia**
  - **Cryptorchidism**
  - **Hemihyperplasia**
  - **Horseshoe kidney (patients are twice as likely to develop WT)**
  - **Hypospadias**
  - **Renal duplication**
  - **Renal ectopia**
  - **Renal hypoplasia**
  - **Ureteral duplication**
- **Surveillance recommendations for WT predisposing conditions (WILMS-I 2 of 5 and WILMS-I 3 of 5)[16,19]**
  - **The Pediatric Cancer Working Group of the American Association for Cancer Research recommends renal US every 3 months until 7 years (ie, all of year 6).**

Familial WT (Nephroblastoma)

- ***FWT1/FWT2* (familial WT) gene mutations account for about 1%–2% of WT cases. These mutations are autosomal dominant (AD) with variable penetrance. They have no association with the *WT1* mutation. *FWT1* is found on chromosome 17q, whereas *FWT2* is found on chromosome 19q.[20-23]**

Continued
References

Note: All recommendations are category 2A unless otherwise indicated.

Version 2.2025, 6/11/2025 © 2025 National Comprehensive Cancer Network® (NCCN®), All rights reserved. NCCN Guidelines® and this illustration may not be reproduced in any form without the express written permission of NCCN.

PLEASE NOTE that use of this NCCN Content is governed by the End-User License Agreement, and you MAY NOT distribute this Content or use it with any artificial intelligence model or tool.
Printed by A. S. M. FAZLUL KARIM CHOWDHURY on 4/20/2026 3:41:05 AM. Copyright © 2026 National Comprehensive Cancer Network, Inc. All Rights Reserved.

PRINCIPLES OF CANCER RISK ASSESSMENT AND COUNSELING

Predisposing conditions associated with higher risk for WT[a,19,24,25]

Syndrome	Gene	Inheritance	Description
Denys-Drash syndrome[26,27] (OMIM: 194080)	*WT1*; locus 11p13	Autosomal dominant (AD)	Disorders of sexual development (DSD), mesangial sclerosis, renal failure, and usually 46 XY karyotype[28]
WAGR/WAGR syndrome with obesity (WAGRO), which are contiguous gene deletion syndromes[29,30] (OMIM: 194072, 612469)	*WT1*; locus 11p13		Aniridia, genitourinary abnormalities, obesity, and range of intellectual disability
Perlman syndrome[25,31] (OMIM: 267000)	*DIS3L2*	Autosomal recessive (AR)	Affected children are large at birth, are hypotonic, and show organomegaly, characteristic facial dysmorphisms (inverted V-shaped upper lip, prominent forehead, deep-set eyes, broad and flat nasal bridge, and low-set ears), renal anomalies (nephromegaly and hydronephrosis), frequent neurodevelopmental delay, and high neonatal mortality

[a] Patients with these syndromes should have surveillance for WT with renal US, including the adrenal glands, every 3 months until 7 years (ie, all of year 6).

Note: All recommendations are category 2A unless otherwise indicated.

Continued
References

Version 2.2025, 6/11/2025 © 2025 National Comprehensive Cancer Network® (NCCN®), All rights reserved. NCCN Guidelines® and this illustration may not be reproduced in any form without the express written permission of NCCN.

PLEASE NOTE that use of this NCCN Content is governed by the End-User License Agreement, and you MAY NOT distribute this Content or use it with any artificial intelligence model or tool.
Printed by A. S. M. FAZLUL KARIM CHOWDHURY on 4/20/2026 3:41:05 AM. Copyright © 2026 National Comprehensive Cancer Network, Inc. All Rights Reserved.

PRINCIPLES OF CANCER RISK ASSESSMENT AND COUNSELING

NCCN recommendations have been developed to be inclusive of individuals of all sexual and gender identities to the greatest extent possible. On this page, the terms male and female refer to sex assigned at birth.

Predisposing conditions associated with a moderate to low risk for WT[a,25]

Syndrome	Gene	Inheritance	Description
Beckwith-Wiedemann syndrome[1,32,33] (OMIM: 130650)	*CDKNIC*; locus 11p15.5	AD, uniparental disomy, epimutations	Gigantism, omphalocele, macroglossia, genitourinary abnormalities, ear pits and creases, hypoglycemia, and hemihyperplasia; present in about 5% of children with WT[20,34]
Frasier syndrome[35,36] (OMIM: 136680)	*WT1*; locus 11p13	AD	DSD, progressive glomerular nephropathy, patients present with normal female external genitalia, streak gonads, XY karyotype, and frequently develop gonadoblastoma
Bohring-Opitz syndrome[37,38] (OMIM: 605039)	*ASXL1*	AD	Malformation syndrome characterized by severe intrauterine growth retardation, poor feeding, profound mental retardation, trigonocephaly, prominent metopic suture, exophthalmos, nevus flammeus of the face, upslanting palpebral fissures, hirsutism, and flexion of the elbow and wrists with deviation of the wrists and metacarpophalangeal joints
MULIBREY (MUscle, LIver, BRain, EYes) Nanism syndrome[39] (OMIM: 253250)	*TRIM37*	AR	Growth disorder with prenatal onset, including occasional progressive cardiomyopathy, characteristic facial features, failure of sexual maturation, insulin resistance with type 2 diabetes, and an increased risk for WT
Li Fraumeni syndrome[40] (OMIM: 151623)	*TP53*	AD	Broad cancer predisposing conditions associated with anaplastic WT in young patients
Trisomy 18 syndrome[41] (Edwards syndrome)	Trisomy of chromosome 18		Growth retardation, psychomotor delays, intellectual disabilities, and a variety of major and minor malformations

[a] Patients with these syndromes should have surveillance for WT with renal US, including the adrenal glands, every 3 months until 7 years (ie, all of year 6).

Note: All recommendations are category 2A unless otherwise indicated.

References

Version 2.2025, 6/11/2025 © 2025 National Comprehensive Cancer Network® (NCCN®), All rights reserved. NCCN Guidelines® and this illustration may not be reproduced in any form without the express written permission of NCCN.

PLEASE NOTE that use of this NCCN Content is governed by the End-User License Agreement, and you MAY NOT distribute this Content or use it with any artificial intelligence model or tool.
Printed by A. S. M. FAZLUL KARIM CHOWDHURY on 4/20/2026 3:41:05 AM. Copyright © 2026 National Comprehensive Cancer Network, Inc. All Rights Reserved.

PRINCIPLES OF CANCER RISK ASSESSMENT AND COUNSELING - REFERENCES

[1] Fiala EM, Ortiz MV, Kennedy JA, et al. 11p15.5 epimutations in children with Wilms tumor and hepatoblastoma detected in peripheral blood. Cancer 2020;126:3114-3121.
[2] Hol JA, Kuiper RP, van Dijk F, et al. Prevalence of (epi)genetic predisposing factors in a 5-year unselected national Wilms tumor cohort: A comprehensive clinical and genomic characterization. J Clin Oncol 2022;40:1892-1902.
[3] Cullinian N, Villani A, Mourad S, et al. An eHealth decision-support tool to prioritize referral practices for genetic evaluation of patients with Wilms tumor. Int J Cancer 2020;146:1010-1017.
[4] Turner JT, Brzezinski J, Dome JS. Wilms tumor predisposition. 2003 Dec 19 [updated 2022 Mar 4]. In: Adam MP, Everman DB, Mirzaa GM, et al, eds. GeneReviews® [Internet]. Seattle (WA): University of Washington, Seattle; 1993-2022. Available from: https://www.ncbi.nlm.nih.gov/books/NBK1294.
[5] Goudie C, Witkowski L, Cullinan N, et al. Performance of the McGill interactive pediatric OncoGenetic guidelines for identifying cancer predisposition syndromes. JAMA Oncol 2021;7:1806-1814.
[6] Gadd S, Huff V, Walz AL, et al. A children's oncology group and TARGET initiative exploring the genetic landscape of Wilms tumor. Nat Genet 2017;49:1487-1494.
[7] Riccardi VM, Hittner HM, Francke U, et al. The aniridia-Wilms' tumor association: The critical role of chromosome band 11p13. Cancer Genet 1980;2:131-137.
[8] Palmer N, Evans AE. The association of aniridia and Wilms' tumor: methods of surveillance and diagnosis. Med Pediatr Oncol 1983;11:73-75.
[9] Pendergrass TW. Congenital anomalies in children with Wilms' tumor: a new survey. Cancer 1976;37:403-408.
[10] Breslow NE, Beckwith JB. Epidemiological features of Wilms' tumor: results of the National Wilms' Tumor Study. J Natl Cancer Inst 1982;68:429-436.
[11] Gutjahr P. Progress and controversies in modern treatment of Wilms' tumor. World J Urol 1995;13:209-212.
[12] Charlton J, Irtan S, Bergeron C, et al. Bilateral Wilms tumour: a review of clinical and molecular features. Expert Rev Mol Med 2017;19:e8.
[13] Gadd S, Huff V, Huang CC, et al. Clinically relevant subsets identified by gene expression patterns support a revised ontogenic model of Wilms tumor: a Children's Oncology Group study. Neoplasia 2012;14:742-756.
[14] Gessler M, Poutska A, Cavenee W, et al. Homozygous deletion in Wilms' tumors of zinc-finger gene identified by chromosome jumping. Nature 1990;343:774-778.
[15] Bonetta L, Kuetin SE, Huang A, et al. Wilms' tumor locus on 11p13 defined by multiple CpG island-associated transcripts. Science 1990;250:994-997.
[16] Srinivasan AS, Saade-Lemus S, Servaes SE, et al. Imaging surveillance for children with predisposition to renal tumors. Pediatr Radiol 2019;49:1453-1462.
[17] Mahamdallie SS, Hanks S, Karlin KL, et al. Mutations in the transcriptional repressor REST predispose to Wilms tumor. Nat Genet. 2015;47:1471-1474. Erratum in: Nat Genet 2016;48:473.
[18] Mahamdallie S, Yost S, Poyastro-Pearson E, et al. Identification of new Wilms tumour predisposition genes: an exome sequencing study. Lancet Child Adolesc Health 2019;3:322-331.
[19] Kalish JM, Doros L, Helman LJ, et al. Surveillance recommendations for children with overgrowth syndromes and predisposition to Wilms tumors and hepatoblastoma. Clin Cancer Res 2017;23:e115-e122.
[20] Koufos A, Grundy P, Morgan K, et al. Familial Wiedemann-Beckwith syndrome to 11p15.5. Am J Hum Genet 1989;44:711-719.
[21] Grundy P, Koufos A, Morgan K, et al. Familial predisposition to Wilms' tumour does not map to the short arm of chromosome 11. Nature 1988;336:374-376.
[22] Rahman N, Arbour L, Tonin P, et al. Evidence for a familial Wilms' tumour gene (FWT1) on chromosome 17q12-q21. Nat Genet 1996;13:461-463.
[23] McDonald JM, Douglass EC, Fisher R, et al. Linkage of familial Wilms' tumor predisposition to chromosome 19 and a two-locus model for the etiology of familial tumors. Cancer Res 1998;58:1387-1390.
[24] Turner JT, Hill DA, Dome JS. Revisiting the threshold for cancer genetics referral in patients with Wilms tumor. J Clin Oncol. 2022;40:1853-1860.
[25] Scott RH, Stiller CA, Walker L, Rahman N. Syndromes and constitutional chromosomal abnormalities associated with Wilms tumour. J Med Genet 2006;43:705-715.

Continued

Note: All recommendations are category 2A unless otherwise indicated.

Version 2.2025, 6/11/2025 © 2025 National Comprehensive Cancer Network® (NCCN®), All rights reserved. NCCN Guidelines® and this illustration may not be reproduced in any form without the express written permission of NCCN.

PLEASE NOTE that use of this NCCN Content is governed by the End-User License Agreement, and you MAY NOT distribute this Content or use it with any artificial intelligence model or tool.
Printed by A. S. M. FAZLUL KARIM CHOWDHURY on 4/20/2026 3:41:05 AM. Copyright © 2026 National Comprehensive Cancer Network, Inc. All Rights Reserved.

PRINCIPLES OF CANCER RISK ASSESSMENT AND COUNSELING - REFERENCES

[26] Hillen LM, Kamsteeg EJ, Schoots J, et al. Refining the diagnosis of congenital nephrotic syndrome on long-term stored tissue: c.1097G>A (p.(Arg366His)) WT1 mutation causing Denys Drash Syndrome. Fetal Pediatr Pathol 2016;35:112-119.
[27] Heathcott RW, Morison IM, Gubler MC, et al. A review of the phenotypic variation due to the Denys-Drash syndrome-associated germline WT1 mutation R362X. Hum Mutat 2002;19:462.
[28] Breslow NE, Collins AJ, Ritchey ML, et al. End stage renal disease in patients with Wilms tumor: Results from the National Wilms Tumor Study Group and the United States Renal Data System. J Urol 2005;174:1972-1975.
[29] Han JC, Liu QR, Jones M, et al. Brain-derived neurotrophic factor and obesity in the WAGR syndrome. N Engl J Med. 2008;359:918-927. Erratum in: N Engl J Med 2008;359:1414.
[30] Duffy KA, Trout KL, Gunckle JM,et al. Results from the WAGR Syndrome Patient Registry: Characterization of WAGR spectrum and recommendations for care management. Front Pediatr 2021;9:733018.
[31] Astuti D, Morris MR, Cooper WN, et al. Germline mutations in DIS3L2 cause the Perlman syndrome of overgrowth and Wilms tumor susceptibility. Nat Genet 2012;44:277-284.
[32] Wang KH, Kupa J, Duffy KA, Kalish JM. Diagnosis and management of Beckwith-Wiedemann syndrome. Front Pediatr 2020;7:562.
[33] Liu EK, Suson KD. Syndromic Wilms tumor: a review of predisposing conditions, surveillance and treatment. Transl Androl Urol 2020;9:2370-2381.
[34] Shuman C, Beckwith JB, Weksberg R. Beckwith-Wiedemann Syndrome. 2000 Mar 3 [updated 2016 Aug 11]. In: Adam MP, Everman DB, Mirzaa GM, et al, eds. GeneReviews® [Internet]. Seattle (WA): University of Washington, Seattle; 1993–2023. Available from: https://www.ncbi.nlm.nih.gov/books/NBK1394/
[35] Barbaux S, Niaudet P, Gubler MC, et al. Donor splice-site mutations in WT1 are responsible for Frasier syndrome. Nat Genet 1997;17:467-470.
[36] Barbosa AS, Hadjiathanasiou CG, Theodoridis C, et al. The same mutation affecting the splicing of WT1 gene is present on Frasier syndrome patients with or without Wilms' tumor. Hum Mutat 1999;13:146-153
[37] Russell B, Tan WH, Graham JM Jr. Bohring-Opitz Syndrome. 2018 Feb 15. In: Adam MP, Ardinger HH, Pagon RA, et al, eds. GeneReviews® [Internet]. Seattle (WA): University of Washington, Seattle; 1993-2021. Available from: https://www.ncbi.nlm.nih.gov/books/NBK481833.
[38] Hoischen A, van Bon BW, Rodríguez-Santiago B, et al. De novo nonsense mutations in ASXL1 cause Bohring-Opitz syndrome. Nat Genet 2011;43:729-731.
[39] Hämäläinen RH, Mowat D, Gabbett MT, et al. Wilms' tumor and novel TRIM37 mutations in an Australian patient with mulibrey nanism. Clin Genet 2006;70:473-479.
[40] Oh L, Hafsi H, Hainaut P, Ariffin H. p53, stem cell biology and childhood blastomas. Curr Opin Oncol 2019;31:84-91.
[41] Sergi C, Kos M. Bilateral Wilms' tumor in Trisomy 18 syndrome: Case report and critical review of the literature. Ann Clin Lab Sci 2018;48:369-372.

Note: All recommendations are category 2A unless otherwise indicated.

Version 2.2025, 6/11/2025 © 2025 National Comprehensive Cancer Network® (NCCN®), All rights reserved. NCCN Guidelines® and this illustration may not be reproduced in any form without the express written permission of NCCN.

PLEASE NOTE that use of this NCCN Content is governed by the End-User License Agreement, and you MAY NOT distribute this Content or use it with any artificial intelligence model or tool.
Printed by A. S. M. FAZLUL KARIM CHOWDHURY on 4/20/2026 3:41:05 AM. Copyright © 2026 National Comprehensive Cancer Network, Inc. All Rights Reserved.

FOLLOW-UP AFTER COMPLETION OF TREATMENT AND MONITORING FOR LATE EFFECTS

Monitoring for Late Effects and Survivorship

- **Given the high cure rate of WT, there is an increased focus on the late effects and survivorship issues that face a patient after therapy. The NCCN Guidelines for Survivorship defines cancer survivorship starting "from the time of diagnosis, through the balance of life." See NCCN Guidelines for Survivorship.**
- **There are two important facts about the survivorship plan for patients after they complete treatment: 1) every patient needs a plan; and 2) the plan needs to be tailored to each patient based on their cancer, cancer treatment, age of treatment, and other comorbidities.**
- **Being knowledgeable about the potential late effects, discussing these with patients and caregivers, and creating a survivorship plan for monitoring and screening is in the purview of the treating oncology team.**
- **It is outside the scope of the NCCN Guidelines for Wilms Tumor to comprehensively discuss all the potential late effects that a patient with WT might experience, but we have provided some general statements about late effects that patients with WT might face (these are organized by potential exposure). We have provided quality resources that focus on survivorship and late effects.**

Chemotherapy

- **Regimen: EE4A**
  - **Chemotherapy agents: vincristine, dactinomycin**
  - **Potential late effect: Peripheral neuropathy**
- **Regimen: DD4A**
  - **Chemotherapy agents: vincristine, dactinomycin, doxorubicin**
  - **Potential late effects: Peripheral neuropathy, cardiac toxicity, subsequent leukemia**
- **Regimen: M or I**
  - **Chemotherapy agents: vincristine, dactinomycin, doxorubicin, cyclophosphamide, etoposide**
  - **Potential late effects: Peripheral neuropathy, cardiac toxicity, subsequent leukemia, testicular or ovarian hormonal dysfunction, infertility, urinary tract toxicity, renal toxicity, bladder malignancy**
- **Regimen: UH-1 (revised)**
  - **Chemotherapy agents: vincristine, doxorubicin, cyclophosphamide, carboplatin, etoposide**
  - **Potential late effects: Peripheral neuropathy, cardiac toxicity, subsequent leukemia, testicular or ovarian hormonal dysfunction, infertility, urinary tract toxicity, renal toxicity, bladder malignancy**
- **Regimen: UH-2 (revised)**
  - **Chemotherapy agents: vincristine, doxorubicin, cyclophosphamide, carboplatin, etoposide, irinotecan**
  - **Potential late effects: Peripheral neuropathy, cardiac toxicity, subsequent leukemia, testicular or ovarian hormonal dysfunction, infertility, urinary tract toxicity, renal toxicity, bladder malignancy**

References

Note: All recommendations are category 2A unless otherwise indicated.

Version 2.2025, 6/11/2025 © 2025 National Comprehensive Cancer Network® (NCCN®), All rights reserved. NCCN Guidelines® and this illustration may not be reproduced in any form without the express written permission of NCCN.

PLEASE NOTE that use of this NCCN Content is governed by the End-User License Agreement, and you MAY NOT distribute this Content or use it with any artificial intelligence model or tool.
Printed by A. S. M. FAZLUL KARIM CHOWDHURY on 4/20/2026 3:41:05 AM. Copyright © 2026 National Comprehensive Cancer Network, Inc. All Rights Reserved.

FOLLOW-UP AFTER COMPLETION OF TREATMENT AND MONITORING FOR LATE EFFECTS

RADIATION

- **A traditional whole abdominal radiation field for WT includes both abdominal radiation (top of diaphragm to iliac crest) AND pelvis radiation.**
- **Most flank radiation fields do not extend beyond the iliac crest; however, depending on the size of the tumor, the field may extend into the pelvis. If the hemi-abdominal field extends below the iliac crest, exposure to pelvic fields should be considered in assessing risk for late effects. Additionally, hemi-abdominal fields will be unilateral (medial border along contralateral vertebral bodies) and must be considered in assessing risk for late effects.**
- **Abdominal radiation**
  - **Potential late effects: Cardiac toxicity, functional asplenia, esophageal stricture, impaired glucose metabolism/diabetes mellitus, dyslipidemia, hepatic toxicity, cholelithiasis, bowel obstruction, chronic enterocolitis, fistula, strictures, colorectal cancer, and renal toxicity**
- **Pelvic radiation**
  - **Potential late effects: Urinary tract toxicity, bladder malignancy, ovarian hormone deficiencies, diminished ovarian reserve (DOR), infertility, uterine vascular insufficiency, and vaginal fibrosis/stenosis[1,2,3]**
- **Lung radiation**
  - **Potential late effects: Subclavian artery disease, breast cancer, breast tissue hypoplasia, pulmonary toxicity, lung cancer, and cardiac toxicity. There is potential for synergistic (increased) late effects in patients who are exposed to both alkylators and irradiation.**

SURGERY

- **Nephrectomy**
  - **Potential late effects: Hydrocele (male), renal toxicity**

GENERAL

- **Please note that there are many risks to pediatric patients with cancer regardless of cancer type and therapy given, such as psychosocial, cognitive, and financial hardship.**
- **Please see COG Long Term Follow Up (LTFU) Guidelines for further guidance and recommendations.**

[1] van der Perk MEM, Cost NG, Bos AME, et al. White paper: Oncofertility in pediatric patients with Wilms tumor. Int J Cancer. 2022;151:843-858.
[2] Mulder RL, Font-Gonzalez A, Hudson MM, et al; PanCareLIFE Consortium. Fertility preservation for female patients with childhood, adolescent, and young adult cancer: recommendations from the PanCareLIFE Consortium and the International Late Effects of Childhood Cancer Guideline Harmonization Group. Lancet Oncol 2021;22:e45-e56.
[3] Mulder RL, Font-Gonzalez A, Green DM, et al; PanCareLIFE Consortium. Fertility preservation for male patients with childhood, adolescent, and young adult cancer: recommendations from the PanCareLIFE Consortium and the International Late Effects of Childhood Cancer Guideline Harmonization Group. Lancet Oncol 2021 ;22:e57-e67.

Note: All recommendations are category 2A unless otherwise indicated.

Version 2.2025, 6/11/2025 © 2025 National Comprehensive Cancer Network® (NCCN®), All rights reserved. NCCN Guidelines® and this illustration may not be reproduced in any form without the express written permission of NCCN.

PLEASE NOTE that use of this NCCN Content is governed by the End-User License Agreement, and you MAY NOT distribute this Content or use it with any artificial intelligence model or tool.
Printed by A. S. M. FAZLUL KARIM CHOWDHURY on 4/20/2026 3:41:05 AM. Copyright © 2026 National Comprehensive Cancer Network, Inc. All Rights Reserved.

CHILDREN'S ONCOLOGY GROUP (COG) STAGING OF WILMS TUMOR[1]

COG Staging of Wilms Tumor	
Stage I	**Tumor limited to kidney, completely resected. The renal capsule is intact. The tumor was not ruptured or biopsied prior to removal. The vessels of the renal sinus are not involved. There is no evidence of tumor at or beyond the margins of resection.** ***Note:*** **For a tumor to qualify for certain therapeutic protocols as Stage I, regional lymph nodes must be examined microscopically.**
Stage II	**The tumor is completely resected and there is no evidence of tumor at or beyond the margins of resection. The tumor extends beyond kidney, as is evidenced by any one of the following criteria:** • **There is regional extension of the tumor (ie, penetration of the renal capsule, or extensive invasion of the soft tissue of the renal sinus, as discussed below).** • **Blood vessels within the nephrectomy specimen outside the renal parenchyma, including those of the renal sinus, contain tumor.** ***Note:*** **Rupture or spillage confined to the flank, including biopsy of the tumor, is no longer included in Stage II and is now included in Stage III.**
Stage III	**Residual nonhematogenous tumor present following surgery, and confined to abdomen. Any one of the following may occur:** • **Lymph nodes within the abdomen or pelvis are involved by tumor. (Lymph node involvement in the thorax, or other extra-abdominal sites is a criterion for stage IV.)** • **The tumor has penetrated through the peritoneal surface.** • **Tumor implants are found on the peritoneal surface.** • **Gross or microscopic tumor remains postoperatively (eg, tumor cells are found at the margin of surgical resection on microscopic examination).** • **The tumor is not completely resectable because of local infiltration into vital structures.** • **Tumor spillage occurring either before or during surgery.** • **The tumor was biopsied (whether tru-cut, open or fine needle aspiration) before removal.** • **Tumor is removed in greater than one piece (eg, tumor cells are found in a separately excised adrenal gland; a tumor thrombus within the renal vein is removed separately from the nephrectomy specimen).** ***Note:*** **Extension of the primary tumor within vena cava into thoracic vena cava and heart is considered Stage III, rather than Stage IV even though outside the abdomen.**
Stage IV	**Hematogenous metastases (eg, lung, liver, bone, brain), or lymph node metastases outside the abdominopelvic region are present. (The presence of tumor within the adrenal gland is not interpreted as metastasis and staging depends on all other staging parameters present).**
Stage V	**Bilateral renal involvement by tumor is present at diagnosis. An attempt should be made to stage each side according to the above criteria on the basis of the extent of disease.**

[1] Adapted from Wilms Tumor and Other Childhood Kidney Tumors Treatment (PDQ®)–Health Professional Version. National Cancer Institute. Accessed February 2, 2023. Available at: https://www.cancer.gov/types/kidney/hp/wilms-treatment-pdq.

Note: All recommendations are category 2A unless otherwise indicated.

Version 2.2025, 6/11/2025 © 2025 National Comprehensive Cancer Network® (NCCN®), All rights reserved. NCCN Guidelines® and this illustration may not be reproduced in any form without the express written permission of NCCN.

PLEASE NOTE that use of this NCCN Content is governed by the End-User License Agreement, and you MAY NOT distribute this Content or use it with any artificial intelligence model or tool.
Printed by A. S. M. FAZLUL KARIM CHOWDHURY on 4/20/2026 3:41:05 AM. Copyright © 2026 National Comprehensive Cancer Network, Inc. All Rights Reserved.

ABBREVIATIONS

3D-CRT	three-dimensional conformal radiation therapy
4D-CT	four-dimensional computed tomography
AD	autosomal dominant
AP/PA	anteroposterior/posteroanterior
AR	autosomal recessive
BSA	body surface area
CBC	complete blood count
CCSK	clear cell sarcoma of the kidney
COG	Children's Oncology Group
CR	complete response
CTV	clinical target volume
DAWT	diffuse anaplastic Wilms tumor
DOR	diminished ovarian reserve
DSD	disorders of sexual development
DSRCT	desmoplastic small round cell tumor
EFS	event-free survival
FAWT	focal anaplastic Wilms tumor
FHWT	favorable histology Wilms tumor
GFR	glomerular filtration rate
GTV	gross tumor volume
H&P	history and physical
HR	higher risk
HVA	homovanillic acid
IMRT	intensity-modulated radiation therapy
IVC	inferior vena cava
ITV	internal target volume
LN	lymph node
LOH	loss of heterozygosity
LOI	loss of imprinting
LR	low risk
MULIBREY	MUscle, LIver, BRain, EYes
NSS	nephron-sparing surgery
OMIM	Online Mendelian Inheritance in Man
OS	overall survival
PE	physical exam
PEComa	perivascular epithelioid cell tumor
PNET	primitive neuroectodermal tumor
PT	prothrombin time
PTT	partial thromboplastin time
PTV	planning target volume
SIR	slow incomplete response
SR	standard risk
UA	urinalysis
VLR	very low risk
VMA	vanillylmandelic acid
WAGR	Wilms tumor, Aniridia, Genitourinary abnormalities, and a Range of Intellectual Disability
WAGRO	WAGR syndrome with obesity
WAI	whole abdomen irradiation
WLI	whole lung irradiation
WT	Wilms tumor

Version 2.2025, 6/11/2025 © 2025 National Comprehensive Cancer Network® (NCCN®), All rights reserved. NCCN Guidelines® and this illustration may not be reproduced in any form without the express written permission of NCCN.

PLEASE NOTE that use of this NCCN Content is governed by the End-User License Agreement, and you MAY NOT distribute this Content or use it with any artificial intelligence model or tool.
Printed by A. S. M. FAZLUL KARIM CHOWDHURY on 4/20/2026 3:41:05 AM. Copyright © 2026 National Comprehensive Cancer Network, Inc. All Rights Reserved.

NCCN Categories of Evidence and Consensus	
Category 1	Based upon high-level evidence (≥1 randomized phase 3 trials or high-quality, robust meta-analyses), there is uniform NCCN consensus (≥85% support of the Panel) that the intervention is appropriate.
Category 2A	Based upon lower-level evidence, there is uniform NCCN consensus (≥85% support of the Panel) that the intervention is appropriate.
Category 2B	Based upon lower-level evidence, there is NCCN consensus (≥50%, but <85% support of the Panel) that the intervention is appropriate.
Category 3	Based upon any level of evidence, there is major NCCN disagreement that the intervention is appropriate.

All recommendations are category 2A unless otherwise indicated.

Version 2.2025, 6/11/2025 © 2025 National Comprehensive Cancer Network® (NCCN®), All rights reserved. NCCN Guidelines® and this illustration may not be reproduced in any form without the express written permission of NCCN.

PLEASE NOTE that use of this NCCN Content is governed by the End-User License Agreement, and you MAY NOT distribute this Content or use it with any artificial intelligence model or tool.
Printed by A. S. M. FAZLUL KARIM CHOWDHURY on 4/20/2026 3:41:05 AM. Copyright © 2026 National Comprehensive Cancer Network, Inc. All Rights Reserved.

Discussion

This discussion corresponds to the NCCN Guidelines for Wilms Tumor (Nephroblastoma). Last updated: June 11, 2025.

Table of Contents

Overview **MS-2**

Guidelines Update Methodology **MS-2**

Literature Search Criteria **MS-2**

Sensitive/Inclusive Language Usage **MS-2**

Clinical Presentation and Initial Evaluation **MS-3**

Genetic Predisposition Conditions MS-4

Initial Treatment **MS-6**

Pathology and Staging MS-7

Further Treatment Recommendations for Individual Settings **MS-8**

Overview MS-8

Treatment of Unilateral FHWT MS-8

Treatment of Unilateral FHWT, Primary Nephrectomy MS-8

Initially Unresectable Unilateral Renal Tumor With No Predisposing Condition MS-12

Localized Unilateral Renal Tumor With a Predisposing Condition MS-14

Metastatic Unilateral Renal Tumor With a Predisposing Condition MS-15

Treatment of Bilateral FHWT MS-16

Treatment of Localized and Metastatic Bilateral Renal Tumors With or Without a Predisposing Condition MS-16

Treatment of Unilateral and Bilateral Anaplastic WT MS-19

Unilateral WT With Focal or Diffuse Anaplasia, Primary Nephrectomy or Post-partial or Total Nephrectomy With Predisposing Condition MS-20

Unilateral WT With Diffuse Anaplasia, Initially Unresectable, No Predisposing Condition MS-20

Bilateral WT With Focal or Diffuse Anaplasia With or Without Predisposing Condition, Post-partial or Total Nephrectomy MS-21

Follow-Up After Completion of Treatment and Monitoring for Late Effects **MS-21**

Summary **MS-22**

References **MS-23**

Version 2.2025 © 2025 National Comprehensive Cancer Network© (NCCN©), All rights reserved. NCCN Guidelines® and this illustration may not be reproduced in any form without the express written permission of NCCN.

PLEASE NOTE that use of this NCCN Content is governed by the End-User License Agreement, and you MAY NOT distribute this Content or use it with any artificial intelligence model or tool.
Printed by A. S. M. FAZLUL KARIM CHOWDHURY on 4/20/2026 3:41:05 AM. Copyright © 2026 National Comprehensive Cancer Network, Inc. All Rights Reserved.

Overview

Wilms tumor (WT, also known as nephroblastoma) is the most common primary kidney tumor in children. In the United States, approximately 650 children are diagnosed with WT each year.[1] WT accounts for >90% of primary kidney tumors in patients <20 years and for 5% of all childhood cancers. Most children (75%) present with WT between 1 and 5 years of age, most commonly at 3 years.[1,2] The incidence of WT is highest among African American children, followed by white children, and then Asian children.[3-6] WT can generally be separated into two histology types: favorable histology (FHWT) and anaplastic histology, with a majority of patients having favorable histology. These histologic features direct therapy with anaplastic tumors having been shown to be more resistant to the chemotherapy regimens used to treat FHWT.[7,8] Five-year survival is >90% for children with all stages of FHWT who receive appropriate treatment, but survival remains poor for children with higher stage diffuse anaplastic WT.[7,9-13] Additionally, bilateral tumors or multifocal tumors in a single kidney can occur in approximately 5% to 13% of patients and 10% of patients, respectively, and tend to be more prevalent in individuals with genetic predisposition syndromes.[14] For unilateral tumors, the median age at diagnosis is 35 months for males and 42 months for females, while the median age at diagnosis is 23 months for males and 28.5 months for females for bilateral tumors.[3]

The NCCN Clinical Practice Guidelines (NCCN Guidelines®) for Wilms Tumor (Nephroblastoma) were first published in 2021 and recently were updated to include recommendations for anaplastic tumors along with FHWT. These guidelines outline therapeutic measures for these conditions that should be closely followed to maximize the potential for cure and to avoid unnecessary side effects, complications, and late toxicities.

Guidelines Update Methodology

The complete details of the Development and Update of the NCCN Guidelines® are available at www.NCCN.org.

Literature Search Criteria

Prior to the update of the NCCN Guidelines® for Wilms Tumor (Nephroblastoma), an electronic search of the PubMed database was performed to obtain key literature in Wilms Tumor since the previous Guidelines update, using the following search terms: Wilms tumor and nephroblastoma. The PubMed database was chosen as it remains the most widely used resource for medical literature and indexes peer-reviewed biomedical literature.

The search results were narrowed by selecting studies in humans published in English. Results were confined to the following article types: Clinical Trial, Phase II; Clinical Trial, Phase III; Clinical Trial, Phase IV; Guideline; Practice Guideline; Meta-Analysis; Randomized Controlled Trial; Systematic Reviews; and Validation Studies.

The data from key PubMed articles as well as articles from additional sources deemed as relevant to these Guidelines as discussed by the Panel have been included in this version of the Discussion section. Recommendations for which high-level evidence is lacking are based on the Panel's review of lower-level evidence and expert opinion.

Sensitive/Inclusive Language Usage

NCCN Guidelines strive to use language that advances the goals of equity, inclusion, and representation. NCCN Guidelines endeavor to use language that is person-first; not stigmatizing; anti-racist, anti-classist, anti-misogynist, anti-ageist, anti-ableist, and anti-weight-biased; and inclusive of individuals of all sexual orientations and gender identities. NCCN Guidelines incorporate non-gendered language, instead focusing

Version 2.2025 © 2025 National Comprehensive Cancer Network© (NCCN©), All rights reserved. NCCN Guidelines® and this illustration may not be reproduced in any form without the express written permission of NCCN.

PLEASE NOTE that use of this NCCN Content is governed by the End-User License Agreement, and you MAY NOT distribute this Content or use it with any artificial intelligence model or tool.
Printed by A. S. M. FAZLUL KARIM CHOWDHURY on 4/20/2026 3:41:05 AM. Copyright © 2026 National Comprehensive Cancer Network, Inc. All Rights Reserved.

on organ-specific recommendations. This language is both more accurate and more inclusive and can help fully address the needs of individuals of all sexual orientations and gender identities. NCCN Guidelines will continue to use the terms men, women, female, and male when citing statistics, recommendations, or data from organizations or sources that do not use inclusive terms. Most studies do not report how sex and gender data are collected and use these terms interchangeably or inconsistently. If sources do not differentiate gender from sex assigned at birth or organs present, the information is presumed to predominantly represent cisgender individuals. NCCN encourages researchers to collect more specific data in future studies and organizations to use more inclusive and accurate language in their future analyses.

Clinical Presentation and Initial Evaluation

Most children present with signs suggesting the presence of a kidney condition, including abdomen swelling and/or a suspicious mass (generally firm, non-tender, smooth) (83%) with or without abdomen pain (37%), fever (23%), hematuria (21%–25%), and hypertension (20%–25%). Less common symptoms include: varicocele, hernia, enlarged testicle, congestive heart failure, hypoglycemia, Cushing syndrome, pleural effusion, and acute abdomen. Children may also be asymptomatic with the abdomen mass being discovered either by a caretaker during routine activities like bathing or during examination by a pediatrician, as these tumors can grow large in size prior to causing any symptoms. A second method of detection is through planned radiologic screening for children who have been identified as having a genetic predisposition condition and/or congenital anomaly. Tumors discovered on routine imaging are typically small and asymptomatic. There are other rare presentations that are found incidentally at surgery for another cause (eg, trauma, appendicitis). A healthy-appearing child with abdominal distension is more likely to have WT, whereas an ill-appearing child with an abdomen mass may have neuroblastoma. Left-sided kidney tumors may be mistaken for splenomegaly on clinical examination while right-sided tumors may be mistaken for hepatomegaly. Calcification of the tumor can also occur, but is less common in WT, appearing in approximately 5% to 10% of cases versus approximately 60% to 70% of neuroblastomas. It is important to note that the abdominal mass should not be vigorously or frequently palpated to avoid rupturing the tumor.

Initial testing recommended for children with a suspicious abdomen mass includes: history and physical examination including blood pressure measurement along with assessment for congenital anomalies and screening for genetic predisposition conditions if relevant (see *Genetic Predisposition Conditions* below). Blood tests, including a complete blood count (CBC) with differential and a comprehensive metabolic panel, should be performed along with urinalysis (UA) and evaluation of urine homovanillic acid (HVA) and vanillylmandelic acid (VMA) to rule out neuroblastoma. An assessment of coagulation with consideration of screening for prothrombin time/partial thromboplastin time (PT/PTT) should also be performed with further workup for von Willebrand disease if PT/PTT is abnormal as almost 10% of patients with WT have an acquired form of this disease.[15-17] Imaging, including abdominal ultrasound (US), CT, or MRI of abdomen/pelvis with intravenous contrast as well as non-sedated chest CT with or without contrast (see *Initial Evaluation* in the algorithm) are also part of the initial evaluation. Oncofertility counseling should also be considered at this time.

The goal of imaging at diagnosis is to differentiate tumors of primary kidney origin from extra-kidney tumors and from benign kidney conditions; imaging will also determine whether a child has unilateral or bilateral kidney disease and whether metastatic disease is present (see *Principles of Imaging* in the algorithm). It is also important to assess for ascites, which may raise concern for tumor rupture. Abdominal US is typically the first imaging modality utilized, because it is usually easily obtained, can be

Version 2.2025 © 2025 National Comprehensive Cancer Network© (NCCN©), All rights reserved. NCCN Guidelines® and this illustration may not be reproduced in any form without the express written permission of NCCN.

PLEASE NOTE that use of this NCCN Content is governed by the End-User License Agreement, and you MAY NOT distribute this Content or use it with any artificial intelligence model or tool.
Printed by A. S. M. FAZLUL KARIM CHOWDHURY on 4/20/2026 3:41:05 AM. Copyright © 2026 National Comprehensive Cancer Network, Inc. All Rights Reserved.

performed without sedation, does not expose the patient to radiation, and can most often quickly ascertain both the presence of a mass and organ of origin.[18,19] Abdominal and pelvic CT with contrast or MRI with and without contrast is then often used to evaluate the extent and involvement of the kidney mass identified on US.[20,21] CT should include standard coronal and sagittal reconstructions. When bilateral disease is suspected, MRI is the preferred modality because it may help to distinguish between nephrogenic rests and WT (see *Principles of Imaging* in the algorithm). If a diagnosis of WT, or any malignant kidney tumor is suspected, further imaging assessments for metastatic disease should be performed. Chest CT with and without contrast should be conducted for the evaluation of pulmonary nodules, which are the most common site of metastatic disease. The chest CT should be performed without sedation, as sedation increases dependent atelectasis, which can obscure lung nodules.

The differential diagnosis for children with abdominal swelling and/or a suspicious mass includes WT, kidney tumors other than WT, extra-kidney tumors, and benign kidney conditions (see *Principles of Abdominal Mass Evaluation* in the algorithm). Kidney tumors other than WT include clear cell sarcoma of the kidney (CCSK), congenital mesoblastic nephroma, renal cell carcinoma (including renal medullary carcinoma), rhabdoid tumor of the kidney, kidney sarcoma, primitive neuroectodermal tumors (PNETs), *DICER1*-associated sarcoma, desmoplastic small round cell tumors (DSRCT), lymphoma, kidney neuroblastoma, and perivascular epithelioid cell tumors (PEComas). Other intrabdominal malignancies that would produce a flank mass include Burkitt lymphoma, Ewing sarcoma, extrarenal WT, hepatoblastoma, neuroblastoma, rhabdomyosarcoma, malignant germ cell tumors, or other rare malignancies. Patients with nephroblastomatosis are at risk for WT development and those with cystic nephroma are at risk for transformation to kidney sarcoma. Benign kidney conditions need to be ruled out, including adrenal hemorrhage, angiomyolipoma, dysplastic kidney, hydronephrosis, metanephric tumors (ie, adenoma, stromal tumor, adenofibroma), multicystic kidney disease, polycystic kidney disease, renal hemorrhage, and renal vein thrombosis. Referral to appropriate specialists or consultation of the appropriate NCCN Guidelines is recommended where applicable. All patients with suspected WT should receive comprehensive care by a multidisciplinary team with experience in managing kidney tumors led by a pediatric oncologist. Additionally, while WT is largely a disease of children, adults may occasionally present with WT. Treatment for adults with WT is similar to treatment for pediatric patients; thus, referral or partnership with a pediatric oncologist familiar with the treatment of WT is recommended.

Genetic Predisposition Conditions

Genetic conditions predisposing children to develop WT may be present in 10% to 15% of cases, with some reports suggesting that this number may even be as high as 30%.[22-25] The highest risk of underlying cancer predisposition to WT is in individuals with bilateral/multifocal WT, those with early-onset disease (<2 years of age), and/or those with familial WT as well as those with multiple nephrogenic rests or clinical features of WT predisposing conditions.[26-28] Genetic testing and cancer predisposition consultation should be considered for all patients with WT, especially for those with multifocal or bilateral WT, but if counseling and testing is not available for all children, decision-support algorithms such as the MIPOGG tool can be used for prioritization.[29]

Congenital anomalies, such as aniridia (1% of children with WT), genitourinary abnormalities (eg, cryptorchidism, hypospadias, fused [horseshoe] kidneys) (5%), and hemihyperplasia (2%–3%) may suggest the presence of certain genetic predisposition conditions that are associated with a higher risk of WT.[30-33] These predisposing conditions include: Denys-Drash syndrome (features disorders of sexual development, mesangial sclerosis, renal failure, and usually 46 XY karyotype), WAGR/WAGR syndrome with obesity (WT, aniridia,

Version 2.2025 © 2025 National Comprehensive Cancer Network© (NCCN©), All rights reserved. NCCN Guidelines® and this illustration may not be reproduced in any form without the express written permission of NCCN.

PLEASE NOTE that use of this NCCN Content is governed by the End-User License Agreement, and you MAY NOT distribute this Content or use it with any artificial intelligence model or tool.
Printed by A. S. M. FAZLUL KARIM CHOWDHURY on 4/20/2026 3:41:05 AM. Copyright © 2026 National Comprehensive Cancer Network, Inc. All Rights Reserved.

genitourinary abnormalities, range of developmental delay), and Perlman syndrome (features the description of children being large at birth, hypotonic, and showing organomegaly, characteristic facial dysmorphisms, kidney anomalies, and frequent neurodevelopmental delays).[34-40] Children with Denys-Drash syndrome have up to a 90% risk of developing WT depending on their specific *WT1* variant; Perlman syndrome, approximately a 75% risk; and WAGR syndrome, approximately a 50% risk. Beckwith-Wiedemann syndrome, Frasier syndrome, Bohring-Opitz syndrome, MULIBREY (MUscle, LIver, BRain, EYes) Nanism syndrome, Li Fraumeni syndrome, and trisomy 18 syndrome (also known as Edwards syndrome) are also predisposing conditions that are associated with a low to moderate risk for WT, and descriptions of the characteristics of these conditions can be found in the *Principles of Cancer Risk Assessment and Counseling* section of the algorithm. Approximately 10% of children with Beckwith-Wiedemann syndrome will develop WT, but the risk varies with the genetic alteration. Children with Beckwith-Wiedemann syndrome who have germline hypermethylation of 11p15 have the highest risk (24%) of developing WT. Other syndromes with a >1% risk include: Simpson-Golabi-Behmel syndrome at 5% to 10%, Bloom syndrome at 3%, mosaic variegated aneuploidy syndrome (BUB1B or TRIP13) at >25%, Bohring-Opitz syndrome (ASXL1) at 7%, and Sotos syndrome at <3%.

Variants in *WT1*, a gene located within 11p13 that codes a transcription factor essential for normal kidney/genitourinary function, are implicated in the development of WT.[14,22,30-33,41-44] *WT1* variants are found in WAGR syndrome and Denys-Drash syndrome, with Denys-Drash syndrome demonstrating an autosomal dominant inheritance pattern. *WT1* variants are also associated with Frasier syndrome. Similarly, *WT2*, a gene located within 11p15 that results in overexpression of IGF2, is implicated in WT development. *WT2* is associated with Beckwith-Wiedemann syndrome along with *CDKN1C*. Perlman syndrome is associated with *DIS3L2* gene mutations and demonstrates an autosomal recessive inheritance pattern. *ASXL1*, *TRIM37*, and *TP53* are associated with Bohring-Opitz syndrome, MULIBREY Nanism syndrome, and Li-Fraumeni syndrome, respectively.[38] Additionally, familial WT gene mutations (*FWT1/FWT2,* which are on chromosomes 17q and 19q, respectively) are rare (1%–2% of WT), are autosomal dominant with variable penetrance, and are not associated with the *WT1* mutation.[45-48] For children with WT, their siblings will rarely get WT (<1%).

Other genes that have been found to be recurrently mutated in the germline of patients with WT include: *REST*, *TRIM28*, *FBXW7*, *NYNRIN*, *KDM3B*, *XPO5*, and *DICER1*.[49-51] *CTNNB1, DROSHA*, *WT1, AMER-1 (WTX)*, *DGCR8*, *SIX1*, *BCORL1*, *MLLT1*, *MYCN*, and *SIX2* are other common somatic variants in WT.[41] *TP53* is also included in this list and is associated with anaplastic WT.[41]

It is important to note that the presence of a genetic predisposition syndrome does not mean that a child will develop WT. Germline testing should be considered for children with physical findings consistent with a predisposition condition. The American Association for Cancer Research (AACR) recommends screening in all children with a >1% risk of developing WT, and the Pediatric Working Group of the AACR recommends renal US every 3 months until 7 years of age (ie, all of year 6); thus, the NCCN Panel recommends surveillance, including physical examination and abdomen US, following this schedule.[23,52-55] The goal is to identify and treat the WT at an early stage when the tumor is small and asymptomatic; this may hopefully be accomplished by partial nephrectomy, preserving renal tissue. Children who present at a younger age are more likely to have multifocal/bilateral disease than children without a predisposition syndrome and often have been identified as part of a surveillance program.[23,53]

Version 2.2025 © 2025 National Comprehensive Cancer Network© (NCCN©), All rights reserved. NCCN Guidelines® and this illustration may not be reproduced in any form without the express written permission of NCCN.

PLEASE NOTE that use of this NCCN Content is governed by the End-User License Agreement, and you MAY NOT distribute this Content or use it with any artificial intelligence model or tool.
Printed by A. S. M. FAZLUL KARIM CHOWDHURY on 4/20/2026 3:41:05 AM. Copyright © 2026 National Comprehensive Cancer Network, Inc. All Rights Reserved.

Initial Treatment

Most children present with resectable disease in one kidney, and upfront unilateral nephrectomy and regional lymph node (LN) sampling is recommended for these children.[11] It is critical that LN sampling be performed for adequate staging with a recommended minimum of 5 nodes being obtained from areas in the renal hilum that are anatomically expected to represent nodes associated with the kidney.[56] The preferred surgical approaches are transabdominal or thoracoabdominal exposure with transperitoneal approach to avoid tumor spillage.[57-60] Any tumor spillage or signs of preoperative tumor rupture must be documented to guide therapy.[61] Patients with spillage or rupture are classified as stage III.[62]

The surgical goals for unilateral WT include removal of all disease without disrupting the tumor(s) capsule(s) (ie, no gross tumor spill), accurate LN staging, and complete pathologic evaluation (see *Principles of Surgery* in the algorithm).[56,63-66] Primary resection also provides necessary biologic information for risk stratification and the selection of appropriate further adjuvant therapy, as testing is done on the surgical tissue specimens to confirm the diagnosis, assess for certain molecular markers (eg, loss of heterozygosity [LOH]), and determine histology (eg, anaplasia).[12,67] This ultimately aids in minimizing treatment for patients at low risk and improving survival for patients at higher risk (see *Pathology and Staging* below for more information).

If a unilateral renal tumor is found and is not resectable, a tumor biopsy is necessary (unless the patient has a predisposing condition) so that diagnosis and molecular biomarker testing can be performed early to aid in guiding appropriate neoadjuvant treatment. The evaluation of resectability includes assessment of the following: number and extent of tumors; and whether the patient is at risk for pulmonary compromise, gross tumor spill, or long-term kidney failure. Tumors may also be unresectable at diagnosis due to tumor extension to contiguous structures, solitary kidney, tumor thrombus extending above the hepatic veins, the presence of bilateral tumors, involvement of surrounding organs, or pulmonary function compromise from extensive metastatic disease, and/or risk for significant morbidity or mortality.[62] Metastases are not typically a contraindication to surgery.

An open posterior biopsy or a percutaneous core needle biopsy are the two options that should be considered. Fine-needle aspiration (FNA) is not recommended. An open biopsy should be performed if surgical exploration is performed with the intent to resect but the tumor is deemed unresectable. There are limitations to information that can be obtained through biopsy, and it is critical to note that biopsy will automatically upstage the local stage to stage III, which will require additional chemotherapy and radiation therapy (RT). Unless a rim of capsule or normal tissue is included in the sample, a core or needle biopsy cannot distinguish between nephrogenic rests and WT. It is important to know that anaplastic histology is often not identified in patients who had core needle or open wedge resection biopsy; however, anaplastic histology is identified when evaluating tissue specimens from nephrectomy.[68]

For unilateral renal tumors in the presence of a predisposing condition as well as bilateral renal tumors with or without predisposing conditions, tumor resections should be delayed and neoadjuvant treatment should be initiated. Neoadjuvant chemotherapy is recommended to shrink the tumors before surgery in children with suspected bilateral WT, those with initially unresectable unilateral tumors, or those with predisposing conditions and either localized or metastatic unilateral renal tumors.[69,70] For tumors in these categories that are <2 cm, close surveillance should be considered given the challenge of differentiating WT from proliferating nephrogenic rests, which are benign foci of embryonal kidney cells and are precursors of WT. Tumor biopsy is also not indicated for children with a unilateral

Version 2.2025 © 2025 National Comprehensive Cancer Network© (NCCN©), All rights reserved. NCCN Guidelines® and this illustration may not be reproduced in any form without the express written permission of NCCN.

PLEASE NOTE that use of this NCCN Content is governed by the End-User License Agreement, and you MAY NOT distribute this Content or use it with any artificial intelligence model or tool.
Printed by A. S. M. FAZLUL KARIM CHOWDHURY on 4/20/2026 3:41:05 AM. Copyright © 2026 National Comprehensive Cancer Network, Inc. All Rights Reserved.

renal tumor and a predisposing condition or for children with bilateral renal tumors to avoid tumor spread and automatic upstaging of the tumor to local stage III; however, biopsy should be considered for children in those categories who are >10 years of age or with a concern for pathology other than WT. Multifocal unilateral WTs are uncommon (7%), therefore, the Panel recommends that proceeding with either primary nephrectomy or neoadjuvant therapy are reasonable approaches. For more information on further treatment recommendations for individual settings of WT, see the corresponding section below.

Pathology and Staging

Accurate confirmation and histologic staging of WT is necessary for appropriate treatment of patients. Confirmation of WT diagnosis and determination of local stage occur after surgery; imaging is useful but may overstage or understage disease.[18-20,71] Two major histopathologic types of WT exist and can be found at the time of biopsy or surgery: FHWT and anaplasia. FHWT implies the absence of focal or diffuse anaplasia and is characterized by undifferentiated blastemal cells as well as cells that have differentiated towards epithelial and stromal lineages. The most characteristic pattern is the triphasic pattern where blastema, epithelial, and stromal lineages are all present, but biphasic and monophasic patterns also exist. Tumors that are predominantly blastemal (66% of the tumor) are aggressive and invasive but are generally responsive to chemotherapy. Conversely, anaplastic WT generally has large, atypical multipolar mitotic figures as well as nuclei that are greatly enlarged and hyperchromatic.[72] These tumors can be classified as either diffuse or focal anaplasia with focality being determined by a localized or completely excised area with anaplastic features. A peritumoral fibrous capsule that demarcates the tumor from adjacent renal parenchyma is an additional critical microscopic characteristic of WT. Chemotherapy can induce changes in histology, leading to either reductions or increases in certain elements as well as maturation of blastemal, epithelial, and stromal components with striated muscle differentiation being the most common.[73] Blastemal predominance after neoadjuvant chemotherapy is considered a high-risk histology group and may require more intensive treatment.

Surgical tissue is also used to evaluate molecular markers. Unfavorable biomarkers include 1q gain and LOH in 1p and 16q, and LOH or loss of imprinting (LOI) in 11p. Use of 11p15 LOH or LOI as unfavorable biomarkers applies only to patients with very-low-risk disease. No clinical evidence exists to use chromosome 17p13 to direct therapy. *TP53* mutations are common in anaplastic tumors but almost never occur in FHWT and have been shown to be a potential adverse prognostic factor in patients with stage III/IV disease when combined with anaplastic features.[74] More information can be found in the *Principles of Pathology* section in the algorithm.

In North America, the Children's Oncology Group (COG) staging system for WT is used (see *Children's Oncology Group [COG] Staging of Wilms Tumor* in the algorithm) with WTs being staged both locally (reflecting abdominal spread of the tumor) and overall. Local stage refers to the staging of the primary tumor, regardless of metastases (eg, stage IV with local stage III) and is used to determine the need for RT (flank or whole abdomen irradiation [WAI]).[71] WT can extend locally to perirenal soft tissues, renal vein, and vena cava. The most common sites of hematogenous metastases include: lung (81%), lung and liver (15%), and other sites (4%); spread to regional LNs also occurs.[75] However, WT rarely metastasizes to bone and brain, unlike CCSK or other kidney cancers. Patients with any evidence of metastatic disease seen on imaging are categorized as stage IV. Abdominal staging can be stage I (limited to renal parenchyma); stage II (demonstrating invasion into renal pelvis or renal capsule); or stage III (with tumor outside the capsule, remaining in the abdomen, including finding of positive margins, confirmation of preoperative rupture or intraoperative tumor spill, positive

Version 2.2025 © 2025 National Comprehensive Cancer Network© (NCCN©), All rights reserved. NCCN Guidelines® and this illustration may not be reproduced in any form without the express written permission of NCCN.

PLEASE NOTE that use of this NCCN Content is governed by the End-User License Agreement, and you MAY NOT distribute this Content or use it with any artificial intelligence model or tool.
Printed by A. S. M. FAZLUL KARIM CHOWDHURY on 4/20/2026 3:41:05 AM. Copyright © 2026 National Comprehensive Cancer Network, Inc. All Rights Reserved.

LNs, or tumor without upfront resection). Stage V WT refers to bilateral involvement, in which each kidney tumor is staged independently. Staging is critical to overall risk stratification and therapy assignment, for both chemotherapy and RT.

Further Treatment Recommendations for Individual Settings

Overview

Treatment for WT can range from surgery only to intensive chemotherapy, surgery, and RT, depending on whether the WT is unilateral or bilateral, local stage, presence of metastases, patient's age, tumor weight, biologic risk factors, histology, and clinical response to therapy. Risk stratification is used to determine the most appropriate therapy to minimize both risk of recurrence and long-term toxicity from treatment.[67,76,77] The goals of treatment are to maximize cure and avoid relapse while appropriately risk-stratifying patients. Tumor histology, histopathologic and surgical stage, molecular markers (such as 1q gain, LOH of 1p and 16q), presence of metastatic and/or bilateral disease, and clinical factors—including age of the child, presence or absence of predisposition syndromes, and response of pulmonary lesions to neoadjuvant chemotherapy—are all used in risk stratification. Other factors indicating need for more intensive therapy include: unfavorable/anaplastic histology, higher stage, unfavorable molecular biomarkers, and incomplete lung nodule response to neoadjuvant chemotherapy at week 6. Discussions on potential toxicities of treatment as well as potential modifications can be found within the *Principles of Chemotherapy* and *Principles of Radiation Therapy* sections in the algorithm. Potential long-term effects of treatment are further discussed below in the section on *Follow-up After Completion of Treatment and Monitoring for Late Effects*. Multidisciplinary evaluation with surgeons, pediatric oncologists, and radiation oncologists is recommended prior to treatment.

Treatment of Unilateral FHWT

Treatment of Unilateral FHWT, Primary Nephrectomy

The NCCN recommendations for treatment of children with FHWT are based on clinical trial data from the COG, and older National Wilms Tumor Study (NWTS) Group (NWTSG) trials, that have been used to identify treatment regimens that can increase survival and decrease relapse, morbidity, and long-term adverse events.[78] The clinical trials performed in Europe by the International Society of Pediatric Oncology (SIOP) have typically used neoadjuvant therapy followed by surgery even if the tumor was initially resectable. By treating for presumed diagnosis, SIOP accepts that a percentage of patients will be misdiagnosed as having WT (ie, false positive) or that this may lead to inadequate staging as LN positivity and extension beyond the kidney capsule may not be identified after pre-nephrectomy chemotherapy, which could be prognostically significant. NWTSG/COG have stressed the importance of determining tumor histology and molecular markers up front. COG treatment regimens are determined in part by stage and molecular markers in the tumor at diagnosis. As discussed earlier, most children with WT have unilateral disease and upfront nephrectomy with regional LN sampling is recommended, followed by adjuvant chemotherapy or radiation, which are based on an assessment of the risk group after surgery.

Risk stratification has evolved using data from large collaborative clinical trials. Initial risk assessment is based on age and clinical, radiographic, surgical, and pathologic findings. Final risk assessment is based on the initial risk factors plus presence or absence of unfavorable molecular biomarkers and the response of the lung metastases at week 6, if applicable. Excellent outcomes have been achieved for all stages of FHWT, including those patients with higher stage disease, unfavorable biomarkers, and adverse clinical factors, such as incomplete response of lung metastases; these patients are stratified to more intensive therapy with additional chemotherapy agents and RT. The presence of specific

Version 2.2025 © 2025 National Comprehensive Cancer Network© (NCCN©), All rights reserved. NCCN Guidelines® and this illustration may not be reproduced in any form without the express written permission of NCCN.

PLEASE NOTE that use of this NCCN Content is governed by the End-User License Agreement, and you MAY NOT distribute this Content or use it with any artificial intelligence model or tool.
Printed by A. S. M. FAZLUL KARIM CHOWDHURY on 4/20/2026 3:41:05 AM. Copyright © 2026 National Comprehensive Cancer Network, Inc. All Rights Reserved.

molecular biomarkers, such as LOH of 1p and 16q, 1q gain, and LOH and LOI of 11p15 identified in tumor tissue, are associated with increased risk of relapse after initial therapy. Cytogenetic and molecular testing—for 1q gain and/or LOH of 1p and 16q—is recommended for all children with newly diagnosed FHWT.[10,79,80] To date, only augmentation of therapy for combined LOH of 1p and 16 has been studied in a prospective clinical trial. However, the presence of certain unfavorable biomarkers clearly identifies children with potential increased risk when treated with therapy deintensification (patients classified with very-low-risk WT found to have LOH of 11p15, or patients with stage IV disease and rapid complete response [RCR] of pulmonary metastases found to have 1q gain). Therefore, clinicians should assess for all of these biomarkers in all children with FHWT. Other molecular markers may be reported after testing; however, at this time, data do not support the use of other markers for risk stratification. The use of specific molecular markers for risk-based assessment is evolving based on clinical trial data.[81]

Patients with FHWT are categorized as: 1) very low risk; 2) low risk; 3) standard risk; 4) higher risk; and 5) bilateral. Final risk assessment includes tumor biology and response of pulmonary nodules to initial therapy; final risk assessment is used when deciding whether to continue the initial chemotherapy or switch to more intensive (augmented) chemotherapy (see *Initial and Final Risk Assessment for FHWT* in the algorithm). Patients with very-low-risk, low-risk, and standard-risk FHWT were studied in the NWTS-5 and AREN0532 trials.[82,83] Patients with higher-risk FHWT were studied in AREN0533.[84] Clinical trial data from NWTS-5, AREN0532, and AREN0533 are used to support the NCCN recommendations for children with unilateral renal tumors who do not have predisposing conditions.[81]

Very Low Risk

Children with resectable unilateral WT typically receive upfront nephrectomy followed by adjuvant therapy.[85] However, clinical trial results suggested that adjuvant therapy could be omitted in children who were deemed at very low risk after upfront nephrectomy.[86] The NWTS-5 trial assessed upfront nephrectomy followed by observation only in 77 children at very low risk after surgery.[83] These children were deemed at very low risk because they were <2 years of age, their tumor weight was <550 grams, and they had stage I disease. These 77 children who only had surgery were compared with 111 children who had surgery plus adjuvant chemotherapy with EE4A. The estimated 5-year event-free survival (EFS) for observation was 84% (95% CI, 73%–91%); it was 97% (95% CI, 92%–99%; $P = .002$) for EE4A. The children who relapsed after surgery alone were successfully treated with more intensive therapy than EE4A (addition of doxorubicin and RT). The estimated 5-year overall survival (OS) for surgery only was 98% (95% CI, 87%–99%); it was 99% (95% CI, 94%–99%) for EE4A ($P = .70$). At 8 years, the OS was still excellent (98.7%).

Data suggested that certain molecular markers in the tumors could be used to identify children who might be at higher risk after surgery alone; adjuvant chemotherapy could be used to decrease the risk of relapse in this subset.[80] The AREN0532 study assessed observation alone after upfront nephrectomy in children at very low risk after surgery.[82] The trial assessed whether observation only after surgery alone was associated with an acceptable level of survival and whether certain tumor molecular markers were associated with increased risk of relapse. The goal was to avoid adjuvant chemotherapy with EE4A, if feasible, and thus decrease toxicity. For the 116 children observed after surgery alone, OS was 100%; the estimated 4-year EFS was 89.7% (95% CI, 84.1%–95.2%). Tumors with 11p15 LOH or LOI were associated with a 20% to 25% risk of recurrence, whereas the relapse risk was only 3% in tumors without 11p15

Version 2.2025 © 2025 National Comprehensive Cancer Network© (NCCN©), All rights reserved. NCCN Guidelines® and this illustration may not be reproduced in any form without the express written permission of NCCN.

PLEASE NOTE that use of this NCCN Content is governed by the End-User License Agreement, and you MAY NOT distribute this Content or use it with any artificial intelligence model or tool.
Printed by A. S. M. FAZLUL KARIM CHOWDHURY on 4/20/2026 3:41:05 AM. Copyright © 2026 National Comprehensive Cancer Network, Inc. All Rights Reserved.

LOH or LOI. One patient who relapsed had combined LOH of 1p and 16q in addition to 11p15 LOH.

Based on these results, the Panel suggests that children with FHWT fitting the criteria of the COG very-low-risk group can either be observed without adjuvant therapy or receive adjuvant chemotherapy with EE4A after nephrectomy.[82,83] EE4A is recommended for children with very-low-risk clinical features but with unfavorable prognostic molecular markers (11p15 LOH or LOI or combined LOH at 1p and 16q). Observation only after surgery is recommended for children without these unfavorable biomarkers. Postoperative RT is not recommended for stage I disease. It should be noted that deintensification of therapy may not be suitable for patients with 1q gain as presence of 1q gain has generally been associated with inferior survival. However, this is a rare circumstance and more data are still needed.

Low Risk

The NWTS-5 trial showed that certain unfavorable tumor molecular markers were associated with poorer relapse-free survival (RFS) in children with stage I and II FHWT.[80] When treated with adjuvant EE4A, children with stage I or II FHWT with combined LOH at 1p and 16q had a 4-year RFS of 74.9% versus 91.2% for those without these markers (*P* = .001). The AREN0532 and AREN0533 trials showed that intensifying (ie, augmenting) adjuvant therapy to DD4A improved relapse-free, but not overall, survival for patients with stage I or II FHWT with combined LOH at 1p and 16q compared with historical controls from NWTS-5.[81]

For patients with stage I or II FHWT plus combined LOH 1p and 16q, the estimated 4-year EFS was 68.8% (95% CI, 55.2%–82.3%) with EE4A on NWTS-5 and 87.3% (95% CI, 75.1%–99.5%) with DD4A on AREN0532 (*P* = .042).[81] All four relapses occurred in patients with stage II FHWT who received DD4A. For patients with stage I or II FHWT and LOH at 1p and 16q, the estimated 4-year OS was 91.6% (95% CI, 83.6%–99.6%) with EE4A on NWTS-5 and 100% with DD4A on AREN0532 (*P* = .096).[81] It is important to note that the AREN0532 and AREN0533 trials were not sufficiently powered to detect statistical differences in OS with augmented therapy (DD4A), because combined LOH 1p and 16q occurs at low frequencies (4.27% [49/1147]) in patients with stage I or II FHWT. The impact of intensification for a finding of 1q gain has not been studied.

Thus, the Panel recommends that children with FHWT at low risk after surgery receive adjuvant therapy with regimen EE4A (see *Unilateral FHWT, Primary Nephrectomy* in the algorithm).[81] If tumors have combined LOH at 1p and 16p, a switch to DD4A is preferred while EE4A can be continued for children with tumors that do not have these unfavorable biomarkers. Postoperative RT is not recommended for local stage I and II disease.

Standard Risk and Higher Risk

The NWTS-5 trial showed that certain unfavorable tumor molecular markers were associated with poorer RFS in children with stage III or IV FHWT.[80] When treated with adjuvant DD4A, children with stage III or IV FHWT with combined LOH at 1p and 16q had a 4-year RFS of 65.9% versus 83% for those without these unfavorable biomarkers (*P* = .01). AREN0533 showed that augmenting adjuvant therapy to regimen M at week 7 improved RFS for 51 patients with stage III or IV FHWT plus combined LOH 1p and 16q compared with historical controls from NWTS-5.[81,82,84] For patients with stage III WT plus combined LOH 1p and 16q treated with regimen M, the estimated 4-year EFS was 87.1% (95% CI, 75.1%–99.1%) and the estimated 4-year OS was 93.6% (95% CI, 84.6%–100%). For patients with stage IV WT plus combined LOH 1p and 16q treated with regimen M, the estimated 4-year EFS was 95.0% (95% CI, 84.9%–100%) and the estimated 4-year OS was 100%. Four relapses and two second malignancies occurred in patients with stage III or IV FHWT treated with regimen M.

Version 2.2025 © 2025 National Comprehensive Cancer Network© (NCCN©), All rights reserved. NCCN Guidelines® and this illustration may not be reproduced in any form without the express written permission of NCCN.

PLEASE NOTE that use of this NCCN Content is governed by the End-User License Agreement, and you MAY NOT distribute this Content or use it with any artificial intelligence model or tool.
Printed by A. S. M. FAZLUL KARIM CHOWDHURY on 4/20/2026 3:41:05 AM. Copyright © 2026 National Comprehensive Cancer Network, Inc. All Rights Reserved.

For patients with stage III or IV FHWT plus combined LOH 1p and 16q treated with DD4A, the estimated 4-year EFS was 61.3% (95% CI, 44.9%–77.6%) for NWTS-5 and 90.2% (95% CI, 81.7%–98.6%) with regimen M on AREN0532 and AREN0533 (*P* = .001).[81] For patients with stage III or IV FHWT plus combined LOH 1p and 16q, the estimated 4-year OS was 86.0% (95% CI, 74.5%–97.5%) with DD4A on NWTS-5 and 96.1% (95% CI, 90.5%–100%) with regimen M on AREN0532 and AREN0533 (*P* = .087).[81] Some clinicians have concerns regarding the comparability of historical control data that were used to justify augmenting therapy with regimen DD4A or M due to the historical control group that was used.[87,88]

Because combined LOH 1p and 16q occurs at low frequencies (6.01% [82/1364]) in patients with stage III or IV FHWT, the AREN0532 and AREN0533 trials were not powered to detect statistical differences in OS with augmented therapy. A different molecular marker, 1q gain, occurs more frequently and is associated with inferior survival; 1q gain has been assessed in several studies, including patients with stage IV FHWT.[10,79,84,89] The marker, 1q gain, identifies patients with isolated lung metastases (ie, lung-only metastases) at higher risk who should receive whole lung irradiation (WLI) even if their lung metastases have completely responded to the initial 6 weeks of treatment with regimen DD4A.[84] However, lung RT can be omitted in patients with lung-only metastases and no unfavorable markers (ie, no 1q gain, no combined LOH 1p and 16q) who have a complete response (CR) of their lung metastases after the initial 6 weeks of treatment with regimen DD4A. Although 1q gain has been identified as an adverse prognostic factor, no prospective studies have been done to show that intensification of therapy is more effective. The impact of 1q gain is greatest in higher risk disease; it is up to the clinician and family to consider risks and benefits of intensification with known treatment regimens. 1q gain can be used to identify patients who are not appropriate for deintensification of therapy, such as patients with rapid CR of lung nodules. Those with rapid CR and 1q gain have a high risk of relapse if they are not treated with RT and DD4A (ie, EFS of 57%).

Regimen M may cause morbidity (eg, enhanced myelosuppression) and late effects including secondary leukemia (caused by cyclophosphamide and etoposide) and infertility (caused by cyclophosphamide).[84,90,91] However, regimens to treat relapse are also associated with late effects, such as cardiomyopathy, second malignancy, and renal insufficiency. In patients who have stage III FHWT and who relapse, the cure rate is ≤50%. Thus, clinicians need to balance the possibility of late effects with regimen M versus the possibility of relapse without regimen M and also side effects associated with these subsequent regimens. The NCCN Panel recommends referral for infertility risk/fertility preservation counseling for all patients treated with chemotherapy; counseling is strongly encouraged before treatment with regimen M or WAI.

DD4A is recommended by the Panel for patients with stage III FHWT classified as standard risk after the initial risk assessment.[81] The results of molecular testing from diagnostic tissue are used to determine the final risk assessment and to select further therapy. Switching to augmented therapy with regimen M is recommended for patients with combined LOH of 1p and 16q who are at increased risk while those without combined LOH at 1p and 16q can continue on treatment with DD4A. Flank RT or WAI is recommended for patients with local stage III, with WAI indicated for the subset of patients with preoperative rupture, peritoneal tumor implants, and diffuse intraoperative tumor spillage. If RT is being considered, the timing of RT should be coordinated with chemotherapy to avoid the coadministration of full doses of dactinomycin or doxorubicin with WAI.

DD4A is also recommended as initial therapy for patients with stage IV FHWT classified as higher risk with either lung-only metastases or extrapulmonary metastases (EPM) with or without lung metastases. After

Version 2.2025 © 2025 National Comprehensive Cancer Network© (NCCN©), All rights reserved. NCCN Guidelines® and this illustration may not be reproduced in any form without the express written permission of NCCN.

PLEASE NOTE that use of this NCCN Content is governed by the End-User License Agreement, and you MAY NOT distribute this Content or use it with any artificial intelligence model or tool.
Printed by A. S. M. FAZLUL KARIM CHOWDHURY on 4/20/2026 3:41:05 AM. Copyright © 2026 National Comprehensive Cancer Network, Inc. All Rights Reserved.

6 weeks of treatment with DD4A, results of molecular testing and imaging are used to determine the final risk assessment and to select further therapy. If patients have lung-only metastases with no combined LOH at 1q and 16q, no 1q gain, and RCR of lung metastases at week 6, continuation of DD4A is recommended. Continuation of DD4A is also recommended for those patients who have lung-only metastases with no combined LOH at 1p and 16q, are 1q gain positive, and have RCR of lung metastases at week 6. Intensification of treatment for patients with no combined LOH at 1p and 16q, 1q gain positive, and RCR of lung metastases at week 6 can be considered; however, this has not been studied. Switching to augmented therapy with regimen M is recommended for patients with combined LOH of 1p and 16q or lung metastases that have slow incomplete response (SIR) after 6 weeks of chemotherapy. In patients with EPM with or without lung metastases and no combined LOH at 1p and 16q continuation of DD4A is recommended while a switch to regimen M is preferred if patients have combined LOH at 1p and 16q. A recent study that compares outcomes of patients with EPM from the AREN0533 and NWTS-5 studies revealed that the 4-year EFS in patients treated with regimen M was 76% (95% CI, 64.6–89.4) versus 64.9% (95% CI, 51.7–82.2) (P = .26) in patients treated with DD4A.[92] No differences in OS were observed; therefore, the Panel does not recommend regimen M in the EPM without LOH setting but recommended a switch to regimen M in patients with combined LOH at 1p and 16q.

Postoperative flank RT or WAI is recommended for patients with local stage III disease. Local stage III refers to staging at the primary site regardless of metastases (see *Children's Oncology Group [COG] Staging of Wilms Tumor* in the algorithm). WAI is indicated for the subset of local stage III patients with preoperative rupture, peritoneal tumor implants, and diffuse intraoperative tumor spillage. WLI is recommended for patients with tumors that do not have combined LOH at 1p and 16q, but are 1q gain positive, and who had an RCR of lung metastases at week 6 as omission of WLI for patients with RCR of lung metastases at week 6 and 1q gain is not recommended due to lower EFS (57%).[84] Additionally, WLI in patients that have combined LOH at 1p and 16q or SIR of lung metastases is recommended while WLI along with RT to other metastatic sites should be done for patients with EPM with lung metastases. Studies show that starting RT >14 days after surgery is associated with an increased risk of abdomen recurrence in patients without metastases.[93] Thus, the NCCN Panel recommends that RT should start by day 10 after surgery but no later than day 14.[94,95] However, patient factors should be considered when deciding about the timing of adjuvant RT, including age and need to assess the response of lung metastases to chemotherapy when giving WAI and WLI. If RT is being considered, the timing of RT should be coordinated with chemotherapy to avoid the coadministration of full doses of dactinomycin or doxorubicin with WAI or WLI (see *Principles of Chemotherapy* in the algorithm). Dactinomycin or doxorubicin can be administered at full doses before starting RT. Additionally, the Panel recognizes the concern for overlapping fields if the abdomen and lungs are treated at different times and recommend planning for possible abdomen and lung fields with initial abdomen RT planning, even if lung RT is ultimately not given, to minimize the degree of overlapping fields. Some degree of overlap between the fields is expected in order to cover the target. [57,96]

Initially Unresectable Unilateral Renal Tumor With No Predisposing Condition

Clinical trial data from NWTS-5, AREN0532, and AREN0533 are used to support the NCCN recommendations for children with unilateral renal tumors that are initially unresectable if there are no predisposing conditions. Details about these trials and regimen M are provided in the previous section (see *Standard Risk and Higher Risk* in this Discussion). Neoadjuvant therapy is selected using recommendations for local stage III disease.

Version 2.2025 © 2025 National Comprehensive Cancer Network© (NCCN©), All rights reserved. NCCN Guidelines® and this illustration may not be reproduced in any form without the express written permission of NCCN.

PLEASE NOTE that use of this NCCN Content is governed by the End-User License Agreement, and you MAY NOT distribute this Content or use it with any artificial intelligence model or tool.
Printed by A. S. M. FAZLUL KARIM CHOWDHURY on 4/20/2026 3:41:05 AM. Copyright © 2026 National Comprehensive Cancer Network, Inc. All Rights Reserved.

As mentioned previously, a tumor biopsy should first be performed for diagnosis and for molecular biomarker testing. If there is pathologic confirmation of WT upon biopsy, neoadjuvant therapy with DD4A is recommended for children with unilateral renal tumors that are initially unresectable if there are no predisposing conditions.[80,81] At week 6 of DD4A treatment, the primary tumor is reimaged with repeat imaging of the lungs (if metastases were present initially). If contrast or non-contrast chest CT is performed, it is important to emphasize that this should be obtained prior to anesthesia to minimize atelectasis, which may obscure metastatic pulmonary nodules. If the tumor is resectable at week 6, patients should undergo nephrectomy with regional LN sampling. If the tumor remains unresectable, continue with DD4A. Chemotherapy should be continued for a total of 12 weeks if the patient has some response at week 6 but is not deemed a candidate for surgery. However, surgery is recommended for all patients at a maximum of week 12 of neoadjuvant chemotherapy based on clinical trial data showing that continuing chemotherapy beyond 12 weeks usually does not yield continued tumor shrinkage.[70,97] Conversely, if imaging shows tumor progression after neoadjuvant treatment, defined as an increase in size, nephrectomy or rebiopsy to evaluate for anaplasia or rhabdomyomatous changes should be performed.

Upon confirmation of FHWT in the surgical specimen, molecular and imaging results are used to determine the final risk category and to select further therapy. Patients either continue regimen DD4A or switch to regimen M, depending on the risk assessment. Augmented therapy with regimen M is recommended for patients who are at increased risk, including those with: 1) localized FHWT and combined LOH at 1p and 16q; or 2) FHWT with combined LOH at 1p and 16q and metastases only in the lung that have SIR to neoadjuvant chemotherapy. Otherwise, continuation of DD4A is recommended. Intensification of chemotherapy can be considered in patients with no combined LOH at 1p and 16q, 1q gain, and RCR of lung metastases at week 6, but it has not been studied. For patients with EPM with or without lung metastases and no combined LOH at 1p and 16q, continuation of DD4A is recommended while switching to regimen M is recommended for those patients whose diseases possesses LOH at 1p and 16q in this setting, similar to the recommendations for high-risk resectable unilateral renal tumor with no predisposing conditions above. If pathology indicates WT with anaplasia, see *Treatment of Unilateral and Bilateral Anaplastic WT* below.

Postoperative flank RT or WAI is recommended for patients with local stage III disease. WLI is recommended in patients whose lung metastases responded to 6 weeks of neoadjuvant chemotherapy but who also have 1q gain or in patients with combined LOH at 1p and 16q or SIR of lung metastases at week 6. WLI is recommended for patients with tumors that do not have combined LOH at 1p and 16q, but are 1q gain positive, and had an RCR of lung metastases at week 6 as omission of WLI for patients with RCR of lung metastases at week 6 and 1q gain led to a lower EFS (57%).[84] WLI should also be considered in patients with EPM with lung metastases along with radiation to other metastatic sites. The NCCN Panel recommends that RT should start by day 10 after surgery but no later than day 14.[94,95] However, patient factors should be considered when deciding about the timing of adjuvant RT, including age and need to assess the response of lung metastases to chemotherapy when giving WAI and WLI. If RT is being considered, the timing of RT should be coordinated with chemotherapy to avoid the coadministration of full doses of dactinomycin or doxorubicin with WAI or WLI (see *Principles of Chemotherapy* in the algorithm). Dactinomycin or doxorubicin can be administered at full doses before starting RT. Additionally, the Panel recognizes the concern for overlapping fields if the abdomen and lung are treated at different times and recommends planning for possible abdomen and lung fields with initial abdomen RT planning, even if lung RT is ultimately not given, to minimize the degree of overlapping fields. Some

Version 2.2025 © 2025 National Comprehensive Cancer Network© (NCCN©), All rights reserved. NCCN Guidelines® and this illustration may not be reproduced in any form without the express written permission of NCCN.

PLEASE NOTE that use of this NCCN Content is governed by the End-User License Agreement, and you MAY NOT distribute this Content or use it with any artificial intelligence model or tool.
Printed by A. S. M. FAZLUL KARIM CHOWDHURY on 4/20/2026 3:41:05 AM. Copyright © 2026 National Comprehensive Cancer Network, Inc. All Rights Reserved.

degree of overlap between the fields is expected in order to cover the target.

Localized Unilateral Renal Tumor With a Predisposing Condition

The AREN0534 trial assessed neoadjuvant therapy with EE4A (or VAD if an upfront biopsy was done) for 6 weeks followed by either surgery or continuation of EE4A (or VAD) for an additional 6 weeks in 34 evaluable children who had localized unilateral kidney tumor and who were predisposed to develop metachronous disease because of hemihyperplasia or a genetic predisposition syndrome, such as Beckwith-Wiedemann syndrome.[98] The trial also included children with multiple tumors in one kidney (multicentric) and children <12 months of age with a unilateral kidney tumor and contralateral nephrogenic rest(s) (of any size).[98] Patients with a localized unilateral renal tumor received neoadjuvant therapy with VAD if an upfront biopsy showed FHWT. Molecular biomarkers were not used to direct therapy in this trial.

Goals of AREN0534 included performing surgery by week 12, improving the EFS (compared with NWTS-5), and decreasing the need for total nephrectomy by using nephron-sparing surgery (NSS) to preserve as much kidney function as possible, because these children are at risk for end-stage kidney failure.[98] Surgery was done after either 6 weeks or 12 weeks of neoadjuvant chemotherapy based on the response at 6 weeks; continuing chemotherapy beyond 12 weeks usually does not yield continued tumor shrinkage.[70,97] If there was a less than partial response at week 6, a total nephrectomy was performed before continuing chemotherapy based upon histology. Of the 32 patients who underwent surgery, 15 had surgery at week 6 and 17 had surgery at week 12. Open kidney biopsy was allowed in order to determine the histology before continuing with neoadjuvant chemotherapy. By 12 weeks of neoadjuvant chemotherapy, most patients had a partial response (62% [21/34]) or stable disease (32% [11/34]); 2 patients had a CR; there was no progressive disease. Surgery included partial or total nephrectomy with regional LN sampling followed by determination of the pathology. A total nephrectomy was done if patients had a less than partial response to neoadjuvant chemotherapy at week 6. Partial nephrectomies were done in 63% (20/32) of patients.

After surgery, risk assessment was completed using histology results and stage to select further therapy including adjuvant chemotherapy with or without RT.[98] Use of molecular biomarkers to direct therapy was not included in AREN0534; however, outcomes were excellent despite not augmenting chemotherapy for the presence of unfavorable biomarkers. The 4-year EFS was 94% (95% CI, 85.2%–100%) and the 4-year OS was 100%. Patients with stage I or II FHWT without blastemal-predominant histology are at lower risk of relapse after surgery; therefore, they continued receiving less intensive adjuvant therapy with EE4A and did not receive adjuvant RT.[98] Patients with blastemal-predominant histology following neoadjuvant chemotherapy are at greater risk of relapse after surgery; therefore, they switched to more intensive adjuvant therapy with DD4A or regimen I, depending on the stage.[98,99]

Concordant with these results, the Panel recommends neoadjuvant therapy with the EE4A regimen for children with a localized unilateral renal tumor and a predisposing condition. As mentioned previously, upfront biopsy or resection is discouraged in this setting, but if an upfront biopsy was performed, then the VAD regimen is to be used as neoadjuvant therapy. Neoadjuvant chemotherapy is not a criterion for upstaging to stage III in this population. If biopsied, a tumor is considered stage III for determining chemotherapy regimen, but biopsy alone does not upstage a tumor to stage III for determining whether to give RT. At week 6 of EE4A (or VAD), the tumor is reimaged, with repeat imaging of the lungs being done before general anesthesia, and further treatment is dictated depending on the response. Patients with a CR will continue EE4A (or

Version 2.2025 © 2025 National Comprehensive Cancer Network© (NCCN©), All rights reserved. NCCN Guidelines® and this illustration may not be reproduced in any form without the express written permission of NCCN.

PLEASE NOTE that use of this NCCN Content is governed by the End-User License Agreement, and you MAY NOT distribute this Content or use it with any artificial intelligence model or tool.
Printed by A. S. M. FAZLUL KARIM CHOWDHURY on 4/20/2026 3:41:05 AM. Copyright © 2026 National Comprehensive Cancer Network, Inc. All Rights Reserved.

VAD). If the tumor is resectable by partial nephrectomy at week 6, a partial nephrectomy when feasible or total nephrectomy with regional LN sampling is recommended. NSS should be prioritized. A total nephrectomy is indicated for patients with unilateral WT who are at high risk for bilateral WT for whom a partial nephrectomy is not feasible after 6 weeks of chemotherapy and with less than a partial response to chemotherapy or for patients for whom a partial nephrectomy is not feasible after 12 week of chemotherapy.[98] After pathology confirms that patients have FHWT, histology (ie, whether blastemal-predominant or not) and staging are used to select further therapy (see *Children's Oncology Group [COG] Staging of Wilms Tumor* in the algorithm). If pathology shows stage I or II FHWT that is not blastemal-predominant, then EE4A is continued while a switch to DD4A is recommended if pathology shows stage III FHWT with no blastemal predominance or stage I FHWT with blastemal predominance. A switch to Regimen I is recommended for patients with stage II–III FHWT and blastemal predominance. Augmented therapy with regimen I is recommended for patients with blastemal-predominant histology and stage II or III FHWT, because they are at the greatest risk of relapse. Regimen M has not been studied in this population. Use of molecular biomarkers to direct therapy has not been studied in this setting; outcomes on AREN0534 were excellent despite not augmenting chemotherapy for the presence of unfavorable biomarkers. If anaplasia is found on pathology, see *Treatment of Unilateral and Bilateral Anaplastic WT* below. For patients with a partial response at week 6 but their disease is still not resectable, continuation of EE4A (or VAD) for a total of 12 weeks is recommended. Resection of the tumor should then occur by no later than week 12 as significant continued tumor shrinkage beyond this point has not been observed.[70,97] If there is a less than partial response at week 6 or at week 12, partial or total nephrectomy with regional LN sampling is recommended as above.[100] The decision to do a partial versus total nephrectomy is based on tumor size, location in the kidney, extension into the kidney collecting system, and other factors. For those with a CR at week 12 of EE4A, refer to the CR pathway dictated earlier in this treatment recommendation.

RT is not recommended for patients who have had a CR at week 6 to regimen EE4A. Similarly, RT is not recommended for those with stage I or II FHWT that are not blastemal-predominant or stage I FHWT with blastemal predominance. Flank RT or WAI is recommended for local stage III with or without blastemal predominance. The patient's age and other factors are considered when deciding about the timing of RT. The NCCN Panel recommends that RT should start by day 10 after surgery but no later than day 14, and planning for possible abdominal and lung fields is recommended to minimize the degree of overlap. However, some degree of overlap is expected in order to cover the target. See *Principles of Radiation Therapy* in the algorithm for more information.

Metastatic Unilateral Renal Tumor With a Predisposing Condition

The AREN0534 study also assessed VAD for 6 weeks followed by either surgery or continuation of VAD for an additional 6 weeks in children who had metastatic unilateral renal tumor and who were predisposed to develop metachronous bilateral disease because of hemihyperplasia or a genetic syndrome, such as Beckwith-Wiedemann syndrome.[53,98,101] One of the 32 patients who underwent surgery had stage IV disease. Additional details about AREN0534 are provided in the previous section (see *Localized Unilateral Renal Tumor with a Predisposing Condition* in this Discussion). After surgery, risk assessment was performed using histology results and stage to select adjuvant therapy, including RT.[98] Use of molecular biomarkers to direct therapy was not included on AREN0534; however, outcomes were excellent despite not augmenting chemotherapy for the presence of unfavorable biomarkers. Patients without blastemal-predominant histology are at lower risk of relapse after surgery; therefore, they switched from VAD to adjuvant therapy with DD4A and adjuvant RT for local stage III disease.[98] Patients with blastemal-predominant histology

Version 2.2025 © 2025 National Comprehensive Cancer Network© (NCCN©), All rights reserved. NCCN Guidelines® and this illustration may not be reproduced in any form without the express written permission of NCCN.

PLEASE NOTE that use of this NCCN Content is governed by the End-User License Agreement, and you MAY NOT distribute this Content or use it with any artificial intelligence model or tool.
Printed by A. S. M. FAZLUL KARIM CHOWDHURY on 4/20/2026 3:41:05 AM. Copyright © 2026 National Comprehensive Cancer Network, Inc. All Rights Reserved.

after neoadjuvant chemotherapy are at greater risk of relapse after surgery; therefore, they switched to more intensive adjuvant therapy with regimen I and adjuvant RT for local stage III disease.[98,99]

Thus, the Panel recommends neoadjuvant therapy with the VAD regimen for children with a predisposing condition and a unilateral renal tumor that has metastasized.[98] Upfront biopsy or resection is also discouraged in this setting. Neoadjuvant chemotherapy is not a criterion for upstaging to stage III in this population. If the tumor was biopsied, however, the tumor is considered to be stage III for determination of chemotherapy regimen postoperatively, but biopsy alone does not upstage a tumor to stage III for determining whether to give radiation. At week 6 of VAD, the primary tumor and metastatic sites should be reimaged and further treatment is dictated by the response. Patients whose renal tumors have a CR to VAD are recommended to switch to regimen DD4A. In patients whose tumors are now resectable by partial nephrectomy after week 6 of VAD, partial nephrectomy when feasible or total nephrectomy with regional LN sampling is recommended. Indications for complete nephrectomy can be found in the above section or in *Principles of Surgery* within the algorithm. After pathology confirms that patients have WT, histology (ie, whether blastemal-predominant or not) is used to select further therapy. If pathology indicates FHWT but no blastemal predominance, then switching to DD4A is recommended while a switch to regimen I is recommended for patients with FHWT with blastemal predominance. Augmented therapy with regimen I is recommended for patients with blastemal-predominant histology after neoadjuvant therapy, because they are at greater risk of relapse. Regimen M has not been studied in this population. If WT with anaplasia is shown on pathology, see *Treatment of Unilateral and Bilateral Anaplastic WT* below. For patients who do not have resectable disease by partial nephrectomy at 6 weeks and have less than a partial response of renal tumors or progression, the same process is followed. If patients have a partial response of renal tumors, then continuation of VAD is recommended with reimaging at week 12. Tumors should be resected by week 12 at the latest (partial or total nephrectomy), because significant tumor shrinkage is rarely observed beyond that point in treatment.[70,97] The decision to do a partial versus total nephrectomy is based on tumor size, location in the kidney, extension into the kidney collecting system, and other factors. If a CR is observed at week 12, refer to the CR pathways discussed above.

WLI for lung metastases and/or radiation to other sites (eg, LNs), without flank radiation, is recommended for patients with a CR. All other patients should receive flank radiation or WAI for local stage III disease, WLI for lung metastases, and radiation to other sites as needed. The Panel recommends that RT should start 10 days after surgery but no later than day 14; the patient's age and other factors are considered when deciding about the timing of RT. Local stage III refers to the staging at the primary tumor, regardless of metastases, and is used to determine the need for flank RT or WAI (see *Principles of Radiation Therapy* in the algorithm). Biopsy alone does not upstage a tumor to stage III for determining whether to give RT. Neoadjuvant chemotherapy is also not a criterion for upstaging to stage III in this setting. Omission of WLI based on the response of lung metastases at week 6 of neoadjuvant chemotherapy has not been studied in this group of patients.

Treatment of Bilateral FHWT

Treatment of Localized and Metastatic Bilateral Renal Tumors With or Without a Predisposing Condition

Children with bilateral WT have a greater incidence of predisposition syndromes and a greater risk for developing metachronous tumors after treatment, probably because of an increased incidence of nephrogenic rests.[14,22,98] Children who present at a younger age are more likely to have multifocal/bilateral disease and their tumors are often identified as part of a surveillance program.[23,53] When compared with unilateral WT, children

Version 2.2025 © 2025 National Comprehensive Cancer Network© (NCCN©), All rights reserved. NCCN Guidelines® and this illustration may not be reproduced in any form without the express written permission of NCCN.

PLEASE NOTE that use of this NCCN Content is governed by the End-User License Agreement, and you MAY NOT distribute this Content or use it with any artificial intelligence model or tool.
Printed by A. S. M. FAZLUL KARIM CHOWDHURY on 4/20/2026 3:41:05 AM. Copyright © 2026 National Comprehensive Cancer Network, Inc. All Rights Reserved.

with bilateral WT have decreased survival because of understaging and an increased incidence of anaplastic histology.[100] The treatment goal for children with bilateral WT is to improve survival and preserve as much kidney function as possible by using less intensive chemotherapy and NSS, if feasible. Unfortunately, the incidence of end-stage kidney disease is higher (12%) in children with bilateral WT compared with unilateral WT (0.6%).[36,102] In patients with small lesions suspicious for bilateral WT, it may be difficult to distinguish nephrogenic rests from WT using CT imaging and percutaneous biopsies; MRI may be useful in this setting.

The AREN0534 trial assessed neoadjuvant therapy with VAD for 6 weeks followed by either surgery or continuation of VAD for an additional 6 weeks in 189 evaluable children with bilateral FHWT.[100] This trial also assessed treatment in children with unilateral WT and a predisposing syndrome. For more information, on this trial or treatments in these settings, see *Localized Unilateral Renal Tumor with Predisposing Condition* or *Metastatic Unilateral Renal Tumor with Predisposing Condition* above. Surgery was done at either 6 weeks or 12 weeks after neoadjuvant chemotherapy based on the response at 6 weeks; continuing chemotherapy beyond 12 weeks usually does not yield continued tumor shrinkage.[70,97] If there was a less than partial response at week 6, open biopsies in both kidneys were done to determine the histology before continuing with VAD. However, bilateral kidney tumors in children that are not WT are very uncommon. By 12 weeks, most patients had a partial response to neoadjuvant chemotherapy. Surgery was done with the goal of preserving as much kidney function as possible, if feasible, and included 1) a partial nephrectomy on one or both sides; or 2) a total nephrectomy with regional LN sampling on one side and a contralateral partial nephrectomy. Data show that use of partial nephrectomy preserves kidney function in patients with bilateral WT.[103] Most patients (84%) had undergone surgery by 12 weeks; 61% of patients needed a complete nephrectomy in at least one kidney.

Histology results and stage were used to select further therapy including RT and/or adjuvant chemotherapy. To determine adjuvant therapy, risk assessment was performed using the kidney with the highest stage. Patients with complete necrosis after neoadjuvant chemotherapy or with stage I FHWT without blastemal-predominant histology are at lower risk of relapse after surgery; therefore, they received EE4A, which is less intensive adjuvant chemotherapy. Patients with blastemal-predominant histology are at greater risk of relapse after surgery; therefore, they received more intensive adjuvant therapy.[99,100] For 11 children with bilateral FHWT and blastemal-predominant histology on AREN0534, the 4-year EFS was 81.8% (95% CI, 42.3%–100%) and the 4-year OS was 91% (95% CI, 64.1%–100%).[100] For 140 children with bilateral FHWT but without blastemal-predominant histology on AREN0534, the 4-year EFS was 83.18% (95% CI, 73.2%–92.96%) and the 4-year OS was 97.7% (95% CI, 93.90%–100%).[100] On the older NWTS-5 trial, 4-year EFS was 65% for patients with bilateral FHWT.[7]

Based on these results, the Panel recommends neoadjuvant therapy with the VAD regimen for children with localized bilateral renal tumors with or without a predisposing condition. Neoadjuvant chemotherapy is not a criterion for upstaging to stage III in this population. Upfront biopsy or resection is discouraged in this setting, but if a biopsy was performed, the tumor is considered stage III for determination of chemotherapy regimen but does not upstage a tumor to stage III for radiation determination. Surgery is done at either 6 weeks or 12 weeks after neoadjuvant chemotherapy based on the response; data show that continuing chemotherapy beyond 12 weeks usually does not yield continued tumor shrinkage.[70,97] NSS is reserved for patients with bilateral disease, those who have a genetic predisposition, those with a solitary or horseshoe kidney, or those at other higher risk for kidney failure.[104-107] Thus, either 1) a partial nephrectomy on both sides; or 2) a total nephrectomy and a contralateral partial nephrectomy, is recommended to preserve as much

Version 2.2025 © 2025 National Comprehensive Cancer Network© (NCCN©), All rights reserved. NCCN Guidelines® and this illustration may not be reproduced in any form without the express written permission of NCCN.

PLEASE NOTE that use of this NCCN Content is governed by the End-User License Agreement, and you MAY NOT distribute this Content or use it with any artificial intelligence model or tool.
Printed by A. S. M. FAZLUL KARIM CHOWDHURY on 4/20/2026 3:41:05 AM. Copyright © 2026 National Comprehensive Cancer Network, Inc. All Rights Reserved.

kidney function as possible, if feasible. In either case, regional LN sampling should be performed (see *Principles of Surgery* in the algorithm for more information about the surgical approach to bilateral WT). At week 6 of VAD, the tumors are reimaged and depending on the response, patients 1) have no surgery if there was a CR to VAD; 2) have either unilateral or bilateral partial nephrectomies with regional LN sampling if the tumors are now resectable; or 3) continue with VAD for a total of 12 weeks if the tumors are still unresectable but a partial response was observed. If there is a less than partial response or progression at week 6, open biopsies of both kidneys are recommended to determine the histology before continuing with chemotherapy, which should be adjusted based on histology. If the biopsy reveals blastemal predominance (all stages), then Regimen I should be used, otherwise, VAD should be continued. If the biopsy shows anaplasia, see *Treatment of Unilateral and Bilateral Anaplastic WT* later in this discussion. Re-evaluation and surgery are then recommended at week 12.

Patients who had a CR at week 6 of VAD should be switched to EE4A. If a patient has surgery after 6 weeks of VAD and pathology confirms that patients have FHWT, staging and histology (ie, blastemal predominance) are used to select further therapy. Use of molecular biomarkers to direct therapy has not been studied in this setting. Switching to regimen EE4A is recommended for patients with stage I FHWT without blastemal-predominant histology or for those with stage I–II FHWT with complete necrosis. Conversely, switching to regimen DD4A is recommended for patients with stage II or III FHWT without blastemal-predominant histology or for those with stage I FHWT with blastemal-predominant histology. Augmented therapy with regimen I is recommended for patients with stage II or III FHWT with blastemal-predominant histology, because they are at greatest risk. If pathology shows WT with anaplasia, see *Treatment of Unilateral and Bilateral Anaplastic WT* later in this Discussion. Patients who had a CR after 12 weeks of VAD should be switched to DD4A while those with less than a CR should undergo partial nephrectomy as discussed earlier. A total nephrectomy with regional LN sampling is indicated in patients with bilateral WT if a partial nephrectomy is not feasible at this point.

No RT is needed for patients with a CR to neoadjuvant chemotherapy or for those with resectable disease that showed FHWT stage I with or without blastemal predominance or stage I–II with complete necrosis. Flank radiation or WAI for local stage III is recommended for all other patients, with WAI indicated for the subset of patients with preoperative rupture, peritoneal tumor implants, and diffuse intraoperative tumor spillage. However, stage III that is upstaged because of biopsy alone will not receive RT. The Panel recommends that RT should start at day 10 after surgery but no later than day 14; the patient's age and other factors should be considered when deciding about the timing of RT. The concern for overlapping fields is acknowledged by the Panel, which recommends planning for possible abdominal and lung fields to minimize the degree of overlap. Some degree of overlap is expected to cover the target.

For children with bilateral renal tumors and metastatic disease with or without a predisposing condition, the Panel recommends neoadjuvant therapy with the VAD regimen based upon the aforementioned results of the AREN0534 trial.[100] Neoadjuvant chemotherapy does not upstage to local stage III in this population. Upfront biopsy or resection is discouraged in this setting, but if performed, the tumor is considered to be local stage III for determination of chemotherapy but not for the determination of whether to give radiotherapy. At week 6 of VAD, the tumor is reimaged (both primary and metastatic sites) and further treatment is dependent on response. Patients with a CR of renal tumors after 6 weeks of VAD should switch to DD4A. If the tumor is resectable by partial nephrectomy after 6 weeks of VAD, patients should undergo partial nephrectomy (one or both sides) with regional LN sampling. If pathology indicates FHWT that is not

Version 2.2025 © 2025 National Comprehensive Cancer Network© (NCCN©), All rights reserved. NCCN Guidelines® and this illustration may not be reproduced in any form without the express written permission of NCCN.

PLEASE NOTE that use of this NCCN Content is governed by the End-User License Agreement, and you MAY NOT distribute this Content or use it with any artificial intelligence model or tool.
Printed by A. S. M. FAZLUL KARIM CHOWDHURY on 4/20/2026 3:41:05 AM. Copyright © 2026 National Comprehensive Cancer Network, Inc. All Rights Reserved.

blastemal-predominant, then a switch to DD4A is recommended while a switch to Regimen I is recommended if the tumor is FHWT with blastemal predominance. If pathology shows WT with anaplasia, see *Treatment of Unilateral or Bilateral Anaplastic WT* below. Augmented therapy with regimen I is recommended for patients with blastemal-predominant histology because they are at greater risk of relapse. Use of molecular biomarkers to direct therapy has not been studied in this setting. If tumors are still not resectable after 6 weeks of VAD but a partial response was observed, continuation of VAD for another 6 weeks is recommended. If re-imaging at week 12 shows less than CR, then partial nephrectomy (one or both sides) when feasible or total nephrectomy with regional LN sampling should occur to determine histopathology and patients should then follow the same protocol as outlined above. Surgery is done at either 6 weeks or 12 weeks after neoadjuvant chemotherapy based on data showing that continuing chemotherapy beyond 12 weeks usually does not yield continued tumor shrinkage.[70,97] NSS is recommended to preserve as much kidney function as possible, if feasible, including: 1) a partial nephrectomy at one or both sides; or 2) a total nephrectomy and a partial nephrectomy on the contralateral side. In either case, regional LN sampling should be performed. If a CR is observed at week 12 of VAD, then patients should be switched to DD4A. Conversely, if a less than partial response in either kidney or progression is observed at week 6 of VAD, then bilateral open biopsies are recommended if partial nephrectomy is still not feasible. Chemotherapy should be adjusted based on histology. Regimen I should be used in this instance if the biopsy reveals blastemal predominance regardless of stage while VAD can be used otherwise. Re-evaluation in both circumstances should be done at week 12. If anaplasia is discovered upon biopsy, see *Treatment of Unilateral and Bilateral Anaplastic WT* below.

Patients with a CR of renal tumors after 6 weeks of neoadjuvant chemotherapy do not need flank RT. However, WLI for lung metastases and/or radiation to other metastatic sites, such as LNs, are recommended. Flank radiation or WAI for local stage III disease along with WLI and radiation to other metastatic sites should be given to patients with FHWT with or without blastemal predominance in this setting. The Panel recommends that RT should start by day 10 after surgery but no later than day 14; the patient's age and other factors should be considered when deciding about the timing of RT. Local stage III refers to the staging at the primary tumor, regardless of metastases, and is used to determine the need for flank RT or WAI (see *Principles of Radiation Therapy* in the algorithm). Overlapping fields are recognized as a concern if the abdomen and lung are treated at different times; thus, the Panel recommends planning for possible abdominal and lung fields with initial abdominal RT planning to minimize overlap. Some degree of overlap between fields is to be expected in order to cover the target.

Treatment of Unilateral and Bilateral Anaplastic WT

Anaplasia has been associated with unfavorable outcomes in WT and can be divided into focal and diffuse subtypes. Updates to the definitions of these subtypes in 1996 spurred retrospective studies that revealed that patients with focal anaplasia have significantly better outcomes than those with diffuse anaplasia, raising the issue of optimal treatments for these different subtypes.[108,109] The AREN0321 trial sought to address this and demonstrated an improvement in outcomes in eight patients with stage I focal anaplastic WT and 10 patients with stage I diffuse anaplastic WT treated with DD4A plus flank radiation.[110] EFS and OS were each 100% as compared to an updated analysis of 27 patients from the NWTS-5 study, where EFS and OS were 70.0% and 81.5%, respectively.[110] Treatment of children with focal anaplasia, especially those with stages II to IV anaplastic WT, with regimen DD4A on NWTS-5 also showed excellent outcomes.[111] A recent study indicated that patients with advanced stage IV focal anaplastic disease have improved survival with the use of revised regimen UH-1, but this was also associated with an increased risk of

Version 2.2025 © 2025 National Comprehensive Cancer Network© (NCCN©), All rights reserved. NCCN Guidelines® and this illustration may not be reproduced in any form without the express written permission of NCCN.

PLEASE NOTE that use of this NCCN Content is governed by the End-User License Agreement, and you MAY NOT distribute this Content or use it with any artificial intelligence model or tool.
Printed by A. S. M. FAZLUL KARIM CHOWDHURY on 4/20/2026 3:41:05 AM. Copyright © 2026 National Comprehensive Cancer Network, Inc. All Rights Reserved.

toxicity. Additionally, this same study also suggests that a potential increase in intensity of treatment could be warranted for stage III focal anaplastic WT based on inferior outcomes observed in the AREN0321 study.[112 113]

Evaluation of the UH-1 regimen in stage II–IV diffuse anaplastic WT in the AREN0321 trial indicated that the 4-year EFS, RFS, and OS rates for the 66 enrolled patients with stage II–IV disease were 67.7%, 72.9%, and 73.7%, respectively, as compared to 57.5%, 57.5%, and 59.2% in the NWTS-5 study.[13] Patients in this study with stage IV measurable disease were also able to receive the addition of vincristine and irinotecan (the regimen together was deemed UH-2) with 1 patient achieving a CR while 10 patients achieved a partial response out of 14 patients.[13] Both regimens UH-1 and UH-2 were modified due to the frequency of nonhematologic toxicities to what is now called revised regimen UH-1 and revised regimen UH-2 to reduce the cumulative doses of doxorubicin, cyclophosphamide, and etoposide to levels similar to those used in regimen I.[13] No differences were observed in EFS between the original and revised UH-1 and -2 regimens.[13] Moreover, patients treated with revised UH-2 seemed to do better than those who received revised UH-1, but the number of patients was small.[13] Additionally, the AREN0321 trial for patients with diffuse anaplasia also indicated potential dosing changes to RT for these patients with 10.8 Gy to the flank being recommended for patients with stage I and II disease due to excellent local control rates.[13] For stage III diffuse anaplasia, 19.8 Gy to the flank and 10.5 Gy to the whole abdomen followed by 9 Gy to the flank is the supported regimen with a reduced local relapse rate compared to that observed in the NWTS-5 study (6.4% vs. 14.8%). However, this was not statistically significant.[13]

Studies, such as the AREN1921 trial (NCT04322318), are currently ongoing with the goal of alleviating the toxicities of the UH-1 and UH-2 regimens and their revised forms in patients who are high risk through the use of the new UH-3 regimen (vincristine, doxorubicin, cyclophosphamide, carboplatin, etoposide, and irinotecan).

Unilateral WT With Focal or Diffuse Anaplasia, Primary Nephrectomy or Post-partial or Total Nephrectomy With Predisposing Condition

Based on the results of the AREN0321 trial discussed above, the NCCN Panel recommends DD4A for stage I–III focal anaplastic disease; however, intensification of therapy may be warranted for stage III disease based on the inferior outcomes observed in the AREN0321 study. For stage IV focal anaplastic disease, revised regimen UH-1 is recommended. Radiation therapy of the flank for stage I or II is recommended while flank or WAI is recommended for stage III. WLI for lung metastases or radiation to other metastatic sites is also recommended for stage IV disease.

For diffuse anaplasia in this setting, DD4A should be used for stage I disease along with flank radiation. The revised UH-2 regimen is recommended for patients with stage II–IV diffuse anaplastic WT along with flank radiation for local stage II and flank or whole abdomen radiation for local stage III disease. The higher dose of radiation for stage III diffuse anaplastic WT lowers the risk of local recurrence as noted above. Addition of WLI for lung metastases and radiation to other metastatic sites is also noted for appropriate patients. RT to the primary site should be conducted within 10 to 14 days after surgery. Overlapping fields may be a concern; thus, the Panel recommends planning for possible abdominal and lung fields with initial abdominal planning even if lung RT is not ultimately given to minimize overlap. Some degree of overlap is to be expected to cover the target.

Unilateral WT With Diffuse Anaplasia, Initially Unresectable, No Predisposing Condition

As mentioned earlier in this discussion, a tumor biopsy is strongly recommended as initial treatment for patients with unilateral renal tumors that are initially unresectable in the absence of predisposing conditions.

Version 2.2025 © 2025 National Comprehensive Cancer Network© (NCCN©), All rights reserved. NCCN Guidelines® and this illustration may not be reproduced in any form without the express written permission of NCCN.

PLEASE NOTE that use of this NCCN Content is governed by the End-User License Agreement, and you MAY NOT distribute this Content or use it with any artificial intelligence model or tool.
Printed by A. S. M. FAZLUL KARIM CHOWDHURY on 4/20/2026 3:41:05 AM. Copyright © 2026 National Comprehensive Cancer Network, Inc. All Rights Reserved.

Anaplasia that presents on a biopsy is considered diffuse. In patients who present with unilateral WT with diffuse anaplasia that is initially unresectable with no predisposing conditions, revised regimen UH-2 is recommended. Re-imaging should be performed after 6 weeks and, if the tumor is now resectable, patients should undergo nephrectomy with regional LN sampling followed by continuation of revised regimen UH-2 along with flank radiation or WAI. WLI for lung metastases as well as radiation to other metastatic sites should be included in patients with metastases. A higher dose of radiation is recommended for stage III disease as noted above due to the lower risk of local recurrence. RT to the primary site should be conducted within 10 to 14 days after surgery. Overlapping fields may be a concern; thus, the Panel recommends planning for possible abdomen and lung fields with initial abdominal planning even if lung RT is not ultimately given to minimize overlap. Some degree of overlap is to be expected to cover the target. If the tumor is unresectable after 6 weeks, revised regimen UH-2 should be continued. Re-imaging should occur at week 12 followed by nephrectomy as further clinical benefit beyond this point has not been observed. However, if re-imaging at week 6 shows tumor progression as defined by an increase in size, nephrectomy with regional LN sampling should be performed.

Bilateral WT With Focal or Diffuse Anaplasia With or Without Predisposing Condition, Post-partial or Total Nephrectomy

Similar treatment regimens are recommended for patients with bilateral WT with either focal or diffuse anaplasia with or without predisposing conditions, post-partial or total nephrectomy to those observed with unilateral anaplastic WT based upon the previously discussed AREN0321 trial.[13,110,112] The Panel recommends a switch to DD4A if a patient has stage I–III focal anaplastic disease or stage I diffuse anaplastic disease. Flank radiation for stage I or II and flank or WAI for stage III focal anaplastic disease is recommended while flank radiation should be used for stage I bilateral diffuse anaplasia. Intensification of chemotherapy treatment may be warranted for stage III focal anaplastic disease based on inferior outcomes observed based on a recent analysis.[112] Conversely, for patients with stage IV focal anaplastic disease, a switch to revised regimen UH-1 is recommended while a switch to the revised regimen UH-2 is recommended for stage II–IV diffuse anaplasia. Radiation to the flank for local stage II diffuse anaplastic disease and flank or WAI for local stage III is also recommended. A higher RT dose is recommended for stage III diffuse disease as the risk of local recurrence was shown to be reduced as discussed previously.[112] WLI or radiation to other metastatic sites is recommended for metastatic disease. The Panel recommends that RT should start 10 days after surgery but no later than day 14. Overlapping fields may be a concern; thus, the Panel recommends planning for possible abdominal and lung fields with initial abdominal planning even if lung RT is not ultimately given to minimize overlap. Some degree of overlap is to be expected to cover the target.

Follow-Up After Completion of Treatment and Monitoring for Late Effects

Post-treatment imaging surveillance should evaluate the chest and abdomen and may consist of CT, MRI, US, or chest x-ray, which is most often done every 3 months for 2 years and then every 6 months for an additional 2 years.[114,115] If patients with FHWT relapse after initial treatment, prognosis depends on the number of drugs administered with initial chemotherapy and whether or not RT was given with the initial treatment.[116,117] In addition, regimens to treat relapse are associated with late effects, which are further discussed below. Current studies, including the AREN1921 trial, are investigating additional treatment regimens for relapsed FHWT, specifically looking at the use of UH-3 in standard-risk relapsed FHWT (those receiving 2 drugs at initial treatment without RT) and the use of regimen ICE(ifosfamide, carboplatin, etoposide)/cyclophosphamide/topotecan) in patients with high- and very-

Version 2.2025 © 2025 National Comprehensive Cancer Network© (NCCN©), All rights reserved. NCCN Guidelines® and this illustration may not be reproduced in any form without the express written permission of NCCN.

PLEASE NOTE that use of this NCCN Content is governed by the End-User License Agreement, and you MAY NOT distribute this Content or use it with any artificial intelligence model or tool.
Printed by A. S. M. FAZLUL KARIM CHOWDHURY on 4/20/2026 3:41:05 AM. Copyright © 2026 National Comprehensive Cancer Network, Inc. All Rights Reserved.

high-risk relapsed FHWT (those receiving ≥3 drugs at initial treatment plus RT).

Overall, the cure rate for WT is high; thus, there is an increased focus on issues related to survivorship and late effects of treatment. In cancer survivorship cohorts, with patients surviving many decades after diagnosis of WT, it has been shown that patients treated with historic regimens have an increased incidence (65%) of chronic health problems, and, 25 years after treatment, the incidence of severe conditions was found to be 24%.[76] While a complete overview of all of the potential late effects that a patient with WT may experience is outside the scope of these Guidelines, the Panel has noted some general statements based on therapy type that should be considered. Related to chemotherapy, potential late effects are dependent on the regimen received. Peripheral neuropathy is common among all regimens, with cardiac toxicity and subsequent leukemia being associated with DD4A, regimen M or I, and revised regimens UH-1 and UH-2. Infertility is also a common late effect for regimen M, regimen I, revised regimen UH-1, and revised regimen UH-2, which should be considered in relation to the age of the patient. The NCCN Panel recommends referral for infertility risk/fertility preservation counseling for all patients treated with these chemotherapy regimens as well as patients receiving WAI.[118,119] Patients treated with RT also have an increased risk for second malignancies. Additional effects of radiation are dependent on the location in which the RT is received. The development of end-stage kidney disease is among other long-term risks of both RT and surgery. The risk of long-term kidney failure after treatment is only 0.6% in most patients with unilateral FHWT.[36] However, the incidence of end-stage kidney disease is higher (12%) in children with bilateral WT.[36,120-122] Furthermore, psychosocial, cognitive, and financial hardship should also be considered in pediatric patients who have had cancer. Please see *Follow-up After Completion of Treatment and Monitoring for Late Effects* in the algorithm for more detailed information.

Summary

The NCCN Guidelines for Wilms Tumor (Nephroblastoma) provide an evidence- and consensus-based framework for the diagnosis, treatment, and management of FHWT and anaplastic WT. Although 5-year survival rates for FHWT are high with many patients being cured with surgery and/or chemotherapy, survival rates for children with advanced diffuse anaplasia are still low, warranting the need for greater research into therapeutic options for this particular disease subtype. Ongoing trials, such as AREN1921, aim to further elucidate effective and less toxic chemotherapy options for patients with diffuse anaplastic WT. Additionally, the open AREN2231 trial aims to further refine risk stratification for patients with unilateral FHWT, seeking to reduce therapy toxicity for patients with excellent outcomes with current standard therapy, and to improve survival through intensification for patients whose outcomes remain poor with current standard therapy. The NCCN Panel continues to encourage patients to participate in well-designed clinical trials if appropriate and applicable.

Version 2.2025 © 2025 National Comprehensive Cancer Network© (NCCN©), All rights reserved. NCCN Guidelines® and this illustration may not be reproduced in any form without the express written permission of NCCN.

PLEASE NOTE that use of this NCCN Content is governed by the End-User License Agreement, and you MAY NOT distribute this Content or use it with any artificial intelligence model or tool.
Printed by A. S. M. FAZLUL KARIM CHOWDHURY on 4/20/2026 3:41:05 AM. Copyright © 2026 National Comprehensive Cancer Network, Inc. All Rights Reserved.

References

1. Howlader N, Noone AM, Krapcho M, et al. SEER Cancer Statistics Review, 1975-2018, based on November 2020 SEER data submission, posted to the SEER web site, April 2021. Bethesda, MD: National Cancer Institute. Available at: https://seer.cancer.gov/csr/1975_2018/.

2. Breslow N, Olshan A, Beckwith JB, Green DM. Epidemiology of Wilms tumor. Med Pediatr Oncol 1993;21:172-181. Available at: https://www.ncbi.nlm.nih.gov/pubmed/7680412.

3. Steliarova-Foucher E, Colombet M, Ries LAG, et al. International incidence of childhood cancer, 2001-10: a population-based registry study. Lancet Oncol 2017;18:719-731. Available at: https://www.ncbi.nlm.nih.gov/pubmed/28410997.

4. Breslow N, Olshan A, Beckwith JB, et al. Ethnic variation in the incidence, diagnosis, prognosis, and follow-up of children with Wilms' tumor. J Natl Cancer Inst 1994;86:49-51. Available at: https://www.ncbi.nlm.nih.gov/pubmed/8271283.

5. Apple A, Lovvorn HN, 3rd. Wilms tumor in Sub-Saharan Africa: Molecular and social determinants of a global pediatric health disparity. Front Oncol 2020;10:606380. Available at: https://www.ncbi.nlm.nih.gov/pubmed/33344257.

6. Hadley LG, Rouma BS, Saad-Eldin Y. Challenge of pediatric oncology in Africa. Semin Pediatr Surg 2012;21:136-141. Available at: https://www.ncbi.nlm.nih.gov/pubmed/22475119.

7. Dome JS, Cotton CA, Perlman EJ, et al. Treatment of anaplastic histology Wilms' tumor: results from the fifth National Wilms' Tumor Study. J Clin Oncol 2006;24:2352-2358. Available at: https://www.ncbi.nlm.nih.gov/pubmed/16710034.

8. Perlman EJ. Pediatric renal tumors: practical updates for the pathologist. Pediatr Dev Pathol 2005;8:320-338. Available at: https://www.ncbi.nlm.nih.gov/pubmed/16010493.

9. Irtan S, Ehrlich PF, Pritchard-Jones K. Wilms tumor: "State-of-the-art" update, 2016. Semin Pediatr Surg 2016;25:250-256. Available at: https://www.ncbi.nlm.nih.gov/pubmed/27955727.

10. Gratias EJ, Dome JS, Jennings LJ, et al. Association of chromosome 1q gain with inferior survival in favorable-histology Wilms tumor: A report from the Children's Oncology Group. J Clin Oncol 2016;34:3189-3194. Available at: https://www.ncbi.nlm.nih.gov/pubmed/27400937.

11. Dome JS, Graf N, Geller JI, et al. Advances in Wilms tumor treatment and biology: Progress through international collaboration. J Clin Oncol 2015;33:2999-3007. Available at: https://www.ncbi.nlm.nih.gov/pubmed/26304882.

12. Dome JS, Perlman EJ, Graf N. Risk stratification for Wilms tumor: current approach and future directions. Am Soc Clin Oncol Educ Book 2014:215-223. Available at: https://www.ncbi.nlm.nih.gov/pubmed/24857079.

13. Daw NC, Chi YY, Kalapurakal JA, et al. Activity of vincristine and irinotecan in diffuse anaplastic Wilms tumor and therapy outcomes of stage II to IV disease: Results of the Children's Oncology Group AREN0321 study. J Clin Oncol 2020;38:1558-1568. Available at: https://www.ncbi.nlm.nih.gov/pubmed/32134700.

14. Charlton J, Irtan S, Bergeron C, Pritchard-Jones K. Bilateral Wilms tumour: a review of clinical and molecular features. Expert Rev Mol Med 2017;19:e8. Available at: https://www.ncbi.nlm.nih.gov/pubmed/28716159.

15. Charlebois J, Rivard GE, St-Louis J. Management of acquired von Willebrand syndrome. Transfus Apher Sci 2018;57:721-723. Available at: https://www.ncbi.nlm.nih.gov/pubmed/30401518.

16. Baxter PA, Nuchtern JG, Guillerman RP, et al. Acquired von Willebrand syndrome and Wilms tumor: not always benign. Pediatr Blood Cancer 2009;52:392-394. Available at: https://www.ncbi.nlm.nih.gov/pubmed/19006222.

Version 2.2025 © 2025 National Comprehensive Cancer Network© (NCCN©), All rights reserved. NCCN Guidelines® and this illustration may not be reproduced in any form without the express written permission of NCCN.

PLEASE NOTE that use of this NCCN Content is governed by the End-User License Agreement, and you MAY NOT distribute this Content or use it with any artificial intelligence model or tool.
Printed by A. S. M. FAZLUL KARIM CHOWDHURY on 4/20/2026 3:41:05 AM. Copyright © 2026 National Comprehensive Cancer Network, Inc. All Rights Reserved.

17. Coppes MJ, Zandvoort SW, Sparling CR, et al. Acquired von Willebrand disease in Wilms' tumor patients. J Clin Oncol 1992;10:422-427. Available at: https://www.ncbi.nlm.nih.gov/pubmed/1311024.

18. Chung EM, Graeber AR, Conran RM. Renal tumors of childhood: Radiologic-pathologic correlation part 1. The 1st decade: From the radiologic pathology archives. Radiographics 2016;36:499-522. Available at: https://www.ncbi.nlm.nih.gov/pubmed/26963460.

19. McDonald K, Duffy P, Chowdhury T, McHugh K. Added value of abdominal cross-sectional imaging (CT or MRI) in staging of Wilms' tumours. Clin Radiol 2013;68:16-20. Available at: https://www.ncbi.nlm.nih.gov/pubmed/22892244.

20. Servaes S, Khanna G, Naranjo A, et al. Comparison of diagnostic performance of CT and MRI for abdominal staging of pediatric renal tumors: a report from the Children's Oncology Group. Pediatr Radiol 2015;45:166-172. Available at: https://www.ncbi.nlm.nih.gov/pubmed/25135711.

21. Brisse HJ, Smets AM, Kaste SC, Owens CM. Imaging in unilateral Wilms tumour. Pediatr Radiol 2008;38:18-29. Available at: https://www.ncbi.nlm.nih.gov/pubmed/18038168.

22. Turner J, Brzezinski J, Dome J. Wilms tumor predisposition [Updated 2022 Mar 24]. In: Adam MP, Ardinger HH, Pagon RA eds. GeneReviews® [Internet]. Seattle, WA: University of Washington, Seattle; 2003 Available at: https://www.ncbi.nlm.nih.gov/books/NBK1294/.

23. Kalish JM, Doros L, Helman LJ, et al. Surveillance recommendations for children with overgrowth syndromes and predisposition to Wilms tumors and hepatoblastoma. Clin Cancer Res 2017;23:e115-e122. Available at: https://www.ncbi.nlm.nih.gov/pubmed/28674120.

24. Hol JA, Kuiper RP, van Dijk F, et al. Prevalence of (epi)genetic predisposing factors in a 5-year unselected national Wilms tumor cohort: A comprehensive clinical and genomic characterization. J Clin Oncol 2022;40:1892-1902. Available at: https://www.ncbi.nlm.nih.gov/pubmed/35230882.

25. Stoltze UK, Hildonen M, Hansen TVO, et al. Germline (epi)genetics reveals high predisposition in females: a 5-year, nationwide, prospective Wilms tumour cohort. J Med Genet 2023;60:842-849. Available at: https://www.ncbi.nlm.nih.gov/pubmed/37019617.

26. Fiala EM, Ortiz MV, Kennedy JA, et al. 11p15.5 epimutations in children with Wilms tumor and hepatoblastoma detected in peripheral blood. Cancer 2020;126:3114-3121. Available at: https://www.ncbi.nlm.nih.gov/pubmed/32320050.

27. Hol JA, Jongmans MCJ, Sudour-Bonnange H, et al. Clinical characteristics and outcomes of children with WAGR syndrome and Wilms tumor and/or nephroblastomatosis: The 30-year SIOP-RTSG experience. Cancer 2021;127:628-638. Available at: https://www.ncbi.nlm.nih.gov/pubmed/33146894.

28. Cullinan N, Villani A, Mourad S, et al. An eHealth decision-support tool to prioritize referral practices for genetic evaluation of patients with Wilms tumor. Int J Cancer 2020;146:1010-1017. Available at: https://www.ncbi.nlm.nih.gov/pubmed/31286500.

29. Goudie C, Witkowski L, Cullinan N, et al. Performance of the McGill Interactive Pediatric OncoGenetic Guidelines for Identifying Cancer Predisposition Syndromes. JAMA Oncol 2021;7:1806-1814. Available at: https://www.ncbi.nlm.nih.gov/pubmed/34617981.

30. Breslow NE, Beckwith JB. Epidemiological features of Wilms' tumor: results of the National Wilms' Tumor Study. J Natl Cancer Inst 1982;68:429-436. Available at: https://www.ncbi.nlm.nih.gov/pubmed/6278194.

31. Pendergrass TW. Congenital anomalies in children with Wilms' tumor: a new survey. Cancer 1976;37:403-408. Available at: https://www.ncbi.nlm.nih.gov/pubmed/174803.

32. Riccardi VM, Hittner HM, Francke U, et al. The aniridia-Wilms tumor association: The critical role of chromosome band 11p13. Cancer Genetics and Cytogenetics 1980;2:131-137. Available at: https://www.sciencedirect.com/science/article/pii/0165460880900564.

Version 2.2025 © 2025 National Comprehensive Cancer Network© (NCCN©), All rights reserved. NCCN Guidelines® and this illustration may not be reproduced in any form without the express written permission of NCCN.

PLEASE NOTE that use of this NCCN Content is governed by the End-User License Agreement, and you MAY NOT distribute this Content or use it with any artificial intelligence model or tool.
Printed by A. S. M. FAZLUL KARIM CHOWDHURY on 4/20/2026 3:41:05 AM. Copyright © 2026 National Comprehensive Cancer Network, Inc. All Rights Reserved.

33. Palmer N, Evans AE. The association of aniridia and Wilms' tumor: methods of surveillance and diagnosis. Med Pediatr Oncol 1983;11:73-75. Available at: https://www.ncbi.nlm.nih.gov/pubmed/6300626.

34. Hillen LM, Kamsteeg EJ, Schoots J, et al. Refining the diagnosis of congenital nephrotic syndrome on Long-term Stored Tissue: c.1097G>A (p.(Arg366His)) WT1 mutation causing Denys Drash syndrome. Fetal Pediatr Pathol 2016;35:112-119. Available at: https://www.ncbi.nlm.nih.gov/pubmed/26882358.

35. Heathcott RW, Morison IM, Gubler MC, et al. A review of the phenotypic variation due to the Denys-Drash syndrome-associated germline WT1 mutation R362X. Hum Mutat 2002;19:462. Available at: https://www.ncbi.nlm.nih.gov/pubmed/11933209.

36. Breslow NE, Collins AJ, Ritchey ML, et al. End stage renal disease in patients with Wilms tumor: results from the National Wilms Tumor Study Group and the United States Renal Data System. J Urol 2005;174:1972-1975. Available at: https://www.ncbi.nlm.nih.gov/pubmed/16217371.

37. Astuti D, Morris MR, Cooper WN, et al. Germline mutations in DIS3L2 cause the Perlman syndrome of overgrowth and Wilms tumor susceptibility. Nat Genet 2012;44:277-284. Available at: https://www.ncbi.nlm.nih.gov/pubmed/22306653.

38. Scott RH, Stiller CA, Walker L, Rahman N. Syndromes and constitutional chromosomal abnormalities associated with Wilms tumour. J Med Genet 2006;43:705-715. Available at: https://www.ncbi.nlm.nih.gov/pubmed/16690728.

39. Han JC, Liu QR, Jones M, et al. Brain-derived neurotrophic factor and obesity in the WAGR syndrome. N Engl J Med 2008;359:918-927. Available at: https://www.ncbi.nlm.nih.gov/pubmed/18753648.

40. Duffy KA, Trout KL, Gunckle JM, et al. Results from the WAGR Syndrome Patient Registry: Characterization of WAGR spectrum and recommendations for care management. Front Pediatr 2021;9:733018. Available at: https://www.ncbi.nlm.nih.gov/pubmed/34970513.

41. Gadd S, Huff V, Huang CC, et al. Clinically relevant subsets identified by gene expression patterns support a revised ontogenic model of Wilms tumor: a Children's Oncology Group Study. Neoplasia 2012;14:742-756. Available at: https://www.ncbi.nlm.nih.gov/pubmed/22952427.

42. Gutjahr P. Progress and controversies in modern treatment of Wilms' tumors. World J Urol 1995;13:209-212. Available at: https://www.ncbi.nlm.nih.gov/pubmed/8528293.

43. Gessler M, Poustka A, Cavenee W, et al. Homozygous deletion in Wilms tumours of a zinc-finger gene identified by chromosome jumping. Nature 1990;343:774-778. Available at: https://www.ncbi.nlm.nih.gov/pubmed/2154702.

44. Bonetta L, Kuehn SE, Huang A, et al. Wilms tumor locus on 11p13 defined by multiple CpG island-associated transcripts. Science 1990;250:994-997. Available at: https://www.ncbi.nlm.nih.gov/pubmed/2173146.

45. McDonald JM, Douglass EC, Fisher R, et al. Linkage of familial Wilms' tumor predisposition to chromosome 19 and a two-locus model for the etiology of familial tumors. Cancer Res 1998;58:1387-1390. Available at: https://www.ncbi.nlm.nih.gov/pubmed/9537236.

46. Rahman N, Arbour L, Tonin P, et al. Evidence for a familial Wilms' tumour gene (FWT1) on chromosome 17q12-q21. Nat Genet 1996;13:461-463. Available at: https://www.ncbi.nlm.nih.gov/pubmed/8696342.

47. Grundy P, Koufos A, Morgan K, et al. Familial predisposition to Wilms' tumour does not map to the short arm of chromosome 11. Nature 1988;336:374-376. Available at: https://www.ncbi.nlm.nih.gov/pubmed/2848199.

48. Koufos A, Grundy P, Morgan K, et al. Familial Wiedemann-Beckwith syndrome and a second Wilms tumor locus both map to 11p15.5. Am J Hum Genet 1989;44:711-719. Available at: https://www.ncbi.nlm.nih.gov/pubmed/2539717.

Version 2.2025 © 2025 National Comprehensive Cancer Network© (NCCN©), All rights reserved. NCCN Guidelines® and this illustration may not be reproduced in any form without the express written permission of NCCN.

PLEASE NOTE that use of this NCCN Content is governed by the End-User License Agreement, and you MAY NOT distribute this Content or use it with any artificial intelligence model or tool.
Printed by A. S. M. FAZLUL KARIM CHOWDHURY on 4/20/2026 3:41:05 AM. Copyright © 2026 National Comprehensive Cancer Network, Inc. All Rights Reserved.

49. Gadd S, Huff V, Walz AL, et al. A Children's Oncology Group and TARGET initiative exploring the genetic landscape of Wilms tumor. Nat Genet 2017;49:1487-1494. Available at: https://www.ncbi.nlm.nih.gov/pubmed/28825729.

50. Mahamdallie S, Yost S, Poyastro-Pearson E, et al. Identification of new Wilms tumour predisposition genes: an exome sequencing study. Lancet Child Adolesc Health 2019;3:322-331. Available at: https://www.ncbi.nlm.nih.gov/pubmed/30885698.

51. Mahamdallie SS, Hanks S, Karlin KL, et al. Mutations in the transcriptional repressor REST predispose to Wilms tumor. Nat Genet 2015;47:1471-1474. Available at: https://www.ncbi.nlm.nih.gov/pubmed/26551668.

52. Srinivasan AS, Saade-Lemus S, Servaes SE, et al. Imaging surveillance for children with predisposition to renal tumors. Pediatr Radiol 2019;49:1453-1462. Available at: https://www.ncbi.nlm.nih.gov/pubmed/31620846.

53. Brioude F, Kalish JM, Mussa A, et al. Expert consensus document: Clinical and molecular diagnosis, screening and management of Beckwith-Wiedemann syndrome: an international consensus statement. Nat Rev Endocrinol 2018;14:229-249. Available at: https://www.ncbi.nlm.nih.gov/pubmed/29377879.

54. Liu EK, Suson KD. Syndromic Wilms tumor: a review of predisposing conditions, surveillance and treatment. Transl Androl Urol 2020;9:2370-2381. Available at: https://www.ncbi.nlm.nih.gov/pubmed/33209710.

55. Scott RH, Walker L, Olsen OE, et al. Surveillance for Wilms tumour in at-risk children: pragmatic recommendations for best practice. Arch Dis Child 2006;91:995-999. Available at: https://www.ncbi.nlm.nih.gov/pubmed/16857697.

56. Qureshi SS, Bhagat M, Kazi M, et al. Standardizing lymph nodal sampling for Wilms tumor: A feasibility study with outcomes. J Pediatr Surg 2020;55:2668-2675. Available at: https://www.ncbi.nlm.nih.gov/pubmed/32854922.

57. Kalapurakal JA, Li SM, Breslow NE, et al. Intraoperative spillage of favorable histology wilms tumor cells: influence of irradiation and chemotherapy regimens on abdominal recurrence. A report from the National Wilms Tumor Study Group. Int J Radiat Oncol Biol Phys 2010;76:201-206. Available at: https://www.ncbi.nlm.nih.gov/pubmed/19395185.

58. D'Angio GJ. SIOP (International Society of Paediatric Oncology) and the management of Wilms' tumor. J Clin Oncol 1983;1:595-596. Available at: https://www.ncbi.nlm.nih.gov/pubmed/6321672.

59. D'Angio GJ, Evans A, Breslow N, et al. The treatment of Wilms' tumor: results of the Second National Wilms' Tumor Study. Cancer 1981;47:2302-2311. Available at: https://www.ncbi.nlm.nih.gov/pubmed/6164480.

60. D'Angio GJ, Evans AE, Breslow N, et al. The treatment of Wilms' tumor: Results of the national Wilms' tumor study. Cancer 1976;38:633-646. Available at: https://www.ncbi.nlm.nih.gov/pubmed/184912.

61. Shamberger RC, Guthrie KA, Ritchey ML, et al. Surgery-related factors and local recurrence of Wilms tumor in National Wilms Tumor Study 4. Ann Surg 1999;229:292-297. Available at: https://www.ncbi.nlm.nih.gov/pubmed/10024113.

62. Khanna G, Rosen N, Anderson JR, et al. Evaluation of diagnostic performance of CT for detection of tumor thrombus in children with Wilms tumor: a report from the Children's Oncology Group. Pediatr Blood Cancer 2012;58:551-555. Available at: https://www.ncbi.nlm.nih.gov/pubmed/21674767.

63. Gow KW, Barnhart DC, Hamilton TE, et al. Primary nephrectomy and intraoperative tumor spill: report from the Children's Oncology Group (COG) renal tumors committee. J Pediatr Surg 2013;48:34-38. Available at: https://www.ncbi.nlm.nih.gov/pubmed/23331790.

64. Kieran K, Ehrlich PF. Current surgical standards of care in Wilms tumor. Urol Oncol 2016;34:13-23. Available at: https://www.ncbi.nlm.nih.gov/pubmed/26122713.

Version 2.2025 © 2025 National Comprehensive Cancer Network© (NCCN©), All rights reserved. NCCN Guidelines® and this illustration may not be reproduced in any form without the express written permission of NCCN.

PLEASE NOTE that use of this NCCN Content is governed by the End-User License Agreement, and you MAY NOT distribute this Content or use it with any artificial intelligence model or tool.
Printed by A. S. M. FAZLUL KARIM CHOWDHURY on 4/20/2026 3:41:05 AM. Copyright © 2026 National Comprehensive Cancer Network, Inc. All Rights Reserved.

65. Aldrink JH, Heaton TE, Dasgupta R, et al. Update on Wilms tumor. J Pediatr Surg 2019;54:390-397. Available at: https://www.ncbi.nlm.nih.gov/pubmed/30270120.

66. Zhuge Y, Cheung MC, Yang R, et al. Improved survival with lymph node sampling in Wilms tumor. J Surg Res 2011;167:e199-203. Available at: https://www.ncbi.nlm.nih.gov/pubmed/21324394.

67. Nelson MV, van den Heuvel-Eibrink MM, Graf N, Dome JS. New approaches to risk stratification for Wilms tumor. Curr Opin Pediatr 2021;33:40-48. Available at: https://www.ncbi.nlm.nih.gov/pubmed/33394739.

68. Hamilton TE, Green DM, Perlman EJ, et al. Bilateral Wilms' tumor with anaplasia: lessons from the National Wilms' Tumor Study. J Pediatr Surg 2006;41:1641-1644. Available at: https://www.ncbi.nlm.nih.gov/pubmed/17011261.

69. Lemerle J, Voute PA, Tournade MF, et al. Effectiveness of preoperative chemotherapy in Wilms' tumor: results of an International Society of Paediatric Oncology (SIOP) clinical trial. J Clin Oncol 1983;1:604-609. Available at: https://www.ncbi.nlm.nih.gov/pubmed/6321673.

70. Tournade MF, Com-Nougue C, de Kraker J, et al. Optimal duration of preoperative therapy in unilateral and nonmetastatic Wilms' tumor in children older than 6 months: results of the Ninth International Society of Pediatric Oncology Wilms' Tumor Trial and Study. J Clin Oncol 2001;19:488-500. Available at: https://www.ncbi.nlm.nih.gov/pubmed/11208843.

71. Gow KW, Roberts IF, Jamieson DH, et al. Local staging of Wilms' tumor--computerized tomography correlation with histological findings. J Pediatr Surg 2000;35:677-679. Available at: https://www.ncbi.nlm.nih.gov/pubmed/10813321.

72. Beckwith JB, Palmer NF. Histopathology and prognosis of Wilms tumors: results from the First National Wilms' Tumor Study. Cancer 1978;41:1937-1948. Available at: https://www.ncbi.nlm.nih.gov/pubmed/206343.

73. Vujanic GM, Parsons LN, D'Hooghe E, et al. Pathology of Wilms' tumour in International Society of Paediatric Oncology (SIOP) and Children's oncology group (COG) renal tumour studies: Similarities and differences. Histopathology 2022;80:1026-1037. Available at: https://www.ncbi.nlm.nih.gov/pubmed/35275409.

74. Ooms AH, Gadd S, Gerhard DS, et al. Significance of TP53 mutation in Wilms tumors with diffuse anaplasia: A report from the Children's Oncology Group. Clin Cancer Res 2016;22:5582-5591. Available at: https://www.ncbi.nlm.nih.gov/pubmed/27702824.

75. Ehrlich PF, Ferrer FA, Ritchey ML, et al. Hepatic metastasis at diagnosis in patients with Wilms tumor is not an independent adverse prognostic factor for stage IV Wilms tumor: a report from the Children's Oncology Group/National Wilms Tumor Study Group. Ann Surg 2009;250:642-648. Available at: https://www.ncbi.nlm.nih.gov/pubmed/19730241.

76. Termuhlen AM, Tersak JM, Liu Q, et al. Twenty-five year follow-up of childhood Wilms tumor: a report from the Childhood Cancer Survivor Study. Pediatr Blood Cancer 2011;57:1210-1216. Available at: https://www.ncbi.nlm.nih.gov/pubmed/21384541.

77. Wong KF, Reulen RC, Winter DL, et al. Risk of adverse health and social outcomes up to 50 years after Wilms tumor: The British Childhood Cancer Survivor Study. J Clin Oncol 2016;34:1772-1779. Available at: https://www.ncbi.nlm.nih.gov/pubmed/27022116.

78. Hudson MM, Mertens AC, Yasui Y, et al. Health status of adult long-term survivors of childhood cancer: a report from the Childhood Cancer Survivor Study. JAMA 2003;290:1583-1592. Available at: https://www.ncbi.nlm.nih.gov/pubmed/14506117.

79. Cone EB, Dalton SS, Van Noord M, et al. Biomarkers for Wilms tumor: A systematic review. J Urol 2016;196:1530-1535. Available at: https://www.ncbi.nlm.nih.gov/pubmed/27259655.

Version 2.2025 © 2025 National Comprehensive Cancer Network© (NCCN©), All rights reserved. NCCN Guidelines® and this illustration may not be reproduced in any form without the express written permission of NCCN.

PLEASE NOTE that use of this NCCN Content is governed by the End-User License Agreement, and you MAY NOT distribute this Content or use it with any artificial intelligence model or tool.
Printed by A. S. M. FAZLUL KARIM CHOWDHURY on 4/20/2026 3:41:05 AM. Copyright © 2026 National Comprehensive Cancer Network, Inc. All Rights Reserved.

80. Grundy PE, Breslow NE, Li S, et al. Loss of heterozygosity for chromosomes 1p and 16q is an adverse prognostic factor in favorable-histology Wilms tumor: a report from the National Wilms Tumor Study Group. J Clin Oncol 2005;23:7312-7321. Available at: https://www.ncbi.nlm.nih.gov/pubmed/16129848.

81. Dix DB, Fernandez CV, Chi YY, et al. Augmentation of therapy for combined loss of heterozygosity 1p and 16q in favorable histology Wilms tumor: A Children's Oncology Group AREN0532 and AREN0533 study report. J Clin Oncol 2019;37:2769-2777. Available at: https://www.ncbi.nlm.nih.gov/pubmed/31449468.

82. Fernandez CV, Perlman EJ, Mullen EA, et al. Clinical outcome and biological predictors of relapse after nephrectomy only for very low-risk Wilms tumor: A report from Children's Oncology Group AREN0532. Ann Surg 2017;265:835-840. Available at: https://www.ncbi.nlm.nih.gov/pubmed/27811504.

83. Shamberger RC, Anderson JR, Breslow NE, et al. Long-term outcomes for infants with very low risk Wilms tumor treated with surgery alone in National Wilms Tumor Study-5. Ann Surg 2010;251:555-558. Available at: https://www.ncbi.nlm.nih.gov/pubmed/20142733.

84. Dix DB, Seibel NL, Chi YY, et al. Treatment of stage IV favorable histology Wilms tumor with lung metastases: A report from the Children's Oncology Group AREN0533 study. J Clin Oncol 2018;36:1564-1570. Available at: https://www.ncbi.nlm.nih.gov/pubmed/29659330.

85. Farber S, D'Angio G, Evans A, Mitus A. Clinical studies on actinomycin D with special reference to Wilms' tumor in children. Ann N Y Acad Sci 1960;89:421-425. Available at: https://www.ncbi.nlm.nih.gov/pubmed/13698160.

86. Green DM, Breslow NE, Beckwith JB, et al. Treatment outcomes in patients less than 2 years of age with small, stage I, favorable-histology Wilms' tumors: a report from the National Wilms' Tumor Study. J Clin Oncol 1993;11:91-95. Available at: https://www.ncbi.nlm.nih.gov/pubmed/8380295.

87. Green DM. Augmentation of therapy for combined loss of heterozygosity 1p and 16q in favorable histology Wilms tumor. J Clin Oncol 2020;38:772-773. Available at: https://www.ncbi.nlm.nih.gov/pubmed/31951492.

88. Green DM. Treatment of stage IV favorable histology Wilms tumor With lung metastases. J Clin Oncol 2018:JCO1800101. Available at: https://www.ncbi.nlm.nih.gov/pubmed/30212293.

89. Gratias EJ, Jennings LJ, Anderson JR, et al. Gain of 1q is associated with inferior event-free and overall survival in patients with favorable histology Wilms tumor: a report from the Children's Oncology Group. Cancer 2013;119:3887-3894. Available at: https://www.ncbi.nlm.nih.gov/pubmed/23983061.

90. Le Deley MC, Leblanc T, Shamsaldin A, et al. Risk of secondary leukemia after a solid tumor in childhood according to the dose of epipodophyllotoxins and anthracyclines: a case-control study by the Societe Francaise d'Oncologie Pediatrique. J Clin Oncol 2003;21:1074-1081. Available at: https://www.ncbi.nlm.nih.gov/pubmed/12637473.

91. Green DM, Liu W, Kutteh WH, et al. Cumulative alkylating agent exposure and semen parameters in adult survivors of childhood cancer: a report from the St Jude Lifetime Cohort Study. Lancet Oncol 2014;15:1215-1223. Available at: https://www.ncbi.nlm.nih.gov/pubmed/25239573.

92. Benedetti DJ, Varela CR, Renfro LA, et al. Treatment of children with favorable histology Wilms tumor with extrapulmonary metastases: A report from the COG studies AREN0533 and AREN03B2 and NWTSG study NWTS-5. Cancer 2024;130:947-961. Available at: https://www.ncbi.nlm.nih.gov/pubmed/37933882.

93. Stokes CL, Stokes WA, Kalapurakal JA, et al. Timing of radiation therapy in pediatric Wilms tumor: A report from the National Cancer Database. Int J Radiat Oncol Biol Phys 2018;101:453-461. Available at: https://www.ncbi.nlm.nih.gov/pubmed/29559286.

Version 2.2025 © 2025 National Comprehensive Cancer Network© (NCCN©), All rights reserved. NCCN Guidelines® and this illustration may not be reproduced in any form without the express written permission of NCCN.

PLEASE NOTE that use of this NCCN Content is governed by the End-User License Agreement, and you MAY NOT distribute this Content or use it with any artificial intelligence model or tool.
Printed by A. S. M. FAZLUL KARIM CHOWDHURY on 4/20/2026 3:41:05 AM. Copyright © 2026 National Comprehensive Cancer Network, Inc. All Rights Reserved.

94. Kalapurakal JA, Li SM, Breslow NE, et al. Influence of radiation therapy delay on abdominal tumor recurrence in patients with favorable histology Wilms' tumor treated on NWTS-3 and NWTS-4: a report from the National Wilms' Tumor Study Group. Int J Radiat Oncol Biol Phys 2003;57:495-499. Available at: https://www.ncbi.nlm.nih.gov/pubmed/12957262.

95. D'Angio GJ, Tefft M, Breslow N, Meyer JA. Radiation therapy of Wilms' tumor: results according to dose, field, post-operative timing and histology. Int J Radiat Oncol Biol Phys 1978;4:769-780. Available at: https://www.ncbi.nlm.nih.gov/pubmed/213410.

96. Jereb B, Burgers JM, Tournade MF, et al. Radiotherapy in the SIOP (International Society of Pediatric Oncology) nephroblastoma studies: a review. Med Pediatr Oncol 1994;22:221-227. Available at: https://www.ncbi.nlm.nih.gov/pubmed/8107651.

97. Shamberger RC, Haase GM, Argani P, et al. Bilateral Wilms' tumors with progressive or nonresponsive disease. J Pediatr Surg 2006;41:652-657; discussion 652-657. Available at: https://www.ncbi.nlm.nih.gov/pubmed/16567171.

98. Ehrlich PF, Chi YY, Chintagumpala MM, et al. Results of treatment for patients with multicentric or bilaterally predisposed unilateral Wilms tumor (AREN0534): A report from the Children's Oncology Group. Cancer 2020;126:3516-3525. Available at: https://www.ncbi.nlm.nih.gov/pubmed/32459384.

99. Vujanic GM, Sandstedt B, Harms D, et al. Revised International Society of Paediatric Oncology (SIOP) working classification of renal tumors of childhood. Med Pediatr Oncol 2002;38:79-82. Available at: https://www.ncbi.nlm.nih.gov/pubmed/11813170.

100. Ehrlich P, Chi YY, Chintagumpala MM, et al. Results of the first prospective multi-institutional treatment study in children with bilateral Wilms tumor (AREN0534): A report from the Children's Oncology Group. Ann Surg 2017;266:470-478. Available at: https://www.ncbi.nlm.nih.gov/pubmed/28795993.

101. Porteus MH, Narkool P, Neuberg D, et al. Characteristics and outcome of children with Beckwith-Wiedemann syndrome and Wilms' tumor: a report from the National Wilms Tumor Study Group. J Clin Oncol 2000;18:2026-2031. Available at: https://www.ncbi.nlm.nih.gov/pubmed/10811666.

102. Hamilton TE, Ritchey ML, Haase GM, et al. The management of synchronous bilateral Wilms tumor: a report from the National Wilms Tumor Study Group. Ann Surg 2011;253:1004-1010. Available at: https://www.ncbi.nlm.nih.gov/pubmed/21394016.

103. Davidoff AM, Interiano RB, Wynn L, et al. Overall survival and renal function of patients with synchronous bilateral Wilms tumor undergoing surgery at a single institution. Ann Surg 2015;262:570-576. Available at: https://www.ncbi.nlm.nih.gov/pubmed/26366536.

104. Ritchey ML, Shamberger RC, Haase G, et al. Surgical complications after primary nephrectomy for Wilms' tumor: report from the National Wilms' Tumor Study Group. J Am Coll Surg 2001;192:63-68; quiz 146. Available at: https://www.ncbi.nlm.nih.gov/pubmed/11192924.

105. Ehrlich PF, Anderson JR, Ritchey ML, et al. Clinicopathologic findings predictive of relapse in children with stage III favorable-histology Wilms tumor. J Clin Oncol 2013;31:1196-1201. Available at: https://www.ncbi.nlm.nih.gov/pubmed/23382471.

106. Ritchey ML, Kelalis PP, Breslow N, et al. Surgical complications after nephrectomy for Wilms' tumor. Surg Gynecol Obstet 1992;175:507-514. Available at: https://www.ncbi.nlm.nih.gov/pubmed/1333095.

107. Davidoff AM, Giel DW, Jones DP, et al. The feasibility and outcome of nephron-sparing surgery for children with bilateral Wilms tumor. The St Jude Children's Research Hospital experience: 1999-2006. Cancer 2008;112:2060-2070. Available at: https://www.ncbi.nlm.nih.gov/pubmed/18361398.

108. Faria P, Beckwith JB, Mishra K, et al. Focal versus diffuse anaplasia in Wilms tumor--new definitions with prognostic significance: a report from

Version 2.2025 © 2025 National Comprehensive Cancer Network© (NCCN©), All rights reserved. NCCN Guidelines® and this illustration may not be reproduced in any form without the express written permission of NCCN.

PLEASE NOTE that use of this NCCN Content is governed by the End-User License Agreement, and you MAY NOT distribute this Content or use it with any artificial intelligence model or tool.
Printed by A. S. M. FAZLUL KARIM CHOWDHURY on 4/20/2026 3:41:05 AM. Copyright © 2026 National Comprehensive Cancer Network, Inc. All Rights Reserved.

the National Wilms Tumor Study Group. Am J Surg Pathol 1996;20:909-920. Available at: https://www.ncbi.nlm.nih.gov/pubmed/8712292.

109. Vujanic GM, Harms D, Sandstedt B, et al. New definitions of focal and diffuse anaplasia in Wilms tumor: the International Society of Paediatric Oncology (SIOP) experience. Med Pediatr Oncol 1999;32:317-323. Available at: https://www.ncbi.nlm.nih.gov/pubmed/10219330.

110. Daw NC, Chi YY, Kim Y, et al. Treatment of stage I anaplastic Wilms' tumour: a report from the Children's Oncology Group AREN0321 study. Eur J Cancer 2019;118:58-66. Available at: https://www.ncbi.nlm.nih.gov/pubmed/31325873.

111. Green DM, Beckwith JB, Breslow NE, et al. Treatment of children with stages II to IV anaplastic Wilms' tumor: a report from the National Wilms' Tumor Study Group. J Clin Oncol 1994;12:2126-2131. Available at: https://www.ncbi.nlm.nih.gov/pubmed/7931483.

112. Armstrong AE, Daw NC, Renfro LA, et al. Treatment of focal anaplastic Wilms tumor: A report from the Children's Oncology Group AREN0321 and AREN03B2 studies. Cancer 2025;131:e35713. Available at: https://www.ncbi.nlm.nih.gov/pubmed/39803937.

113. Armstrong AE, Daw NC, Renfro LA, et al. Treatment of focal anaplastic Wilms tumor (FAWT): A report from the Children's Oncology Group (COG) AREN0321 and AREN03B2 studies. Journal of Clinical Oncology 2023;41:10005-10005. Available at: https://ascopubs.org/doi/abs/10.1200/JCO.2023.41.16_suppl.10005.

114. Brok J, Lopez-Yurda M, Tinteren HV, et al. Relapse of Wilms' tumour and detection methods: a retrospective analysis of the 2001 Renal Tumour Study Group-International Society of Paediatric Oncology Wilms' tumour protocol database. Lancet Oncol 2018;19:1072-1081. Available at: https://www.ncbi.nlm.nih.gov/pubmed/29960848.

115. Mullen EA, Chi YY, Hibbitts E, et al. Impact of surveillance imaging modality on survival after recurrence in patients with favorable-histology Wilms tumor: A report from the Children's Oncology Group. J Clin Oncol 2018;36:JCO1800076. Available at: https://www.ncbi.nlm.nih.gov/pubmed/30335557.

116. Malogolowkin M, Cotton CA, Green DM, et al. Treatment of Wilms tumor relapsing after initial treatment with vincristine, actinomycin D, and doxorubicin. A report from the National Wilms Tumor Study Group. Pediatr Blood Cancer 2008;50:236-241. Available at: https://www.ncbi.nlm.nih.gov/pubmed/17539021.

117. Green DM, Cotton CA, Malogolowkin M, et al. Treatment of Wilms tumor relapsing after initial treatment with vincristine and actinomycin D: a report from the National Wilms Tumor Study Group. Pediatr Blood Cancer 2007;48:493-499. Available at: https://www.ncbi.nlm.nih.gov/pubmed/16547940.

118. Practice Committee of the American Society for Reproductive Medicine. Electronic address aao. Fertility preservation in patients undergoing gonadotoxic therapy or gonadectomy: a committee opinion. Fertil Steril 2019;112:1022-1033. Available at: https://www.ncbi.nlm.nih.gov/pubmed/31843073.

119. Lee SJ, Schover LR, Partridge AH, et al. American Society of Clinical Oncology recommendations on fertility preservation in cancer patients. J Clin Oncol 2006;24:2917-2931. Available at: https://www.ncbi.nlm.nih.gov/pubmed/16651642.

120. Lange JM, Takashima JR, Peterson SM, et al. Breast cancer in female survivors of Wilms tumor: a report from the national Wilms tumor late effects study. Cancer 2014;120:3722-3730. Available at: https://www.ncbi.nlm.nih.gov/pubmed/25348097.

121. Breslow NE, Takashima JR, Whitton JA, et al. Second malignant neoplasms following treatment for Wilm's tumor: a report from the National Wilms' Tumor Study Group. J Clin Oncol 1995;13:1851-1859. Available at: https://www.ncbi.nlm.nih.gov/pubmed/7636528.

122. Paulino AC, Wen BC, Brown CK, et al. Late effects in children treated with radiation therapy for Wilms' tumor. Int J Radiat Oncol Biol Phys

Version 2.2025 © 2025 National Comprehensive Cancer Network© (NCCN©), All rights reserved. NCCN Guidelines® and this illustration may not be reproduced in any form without the express written permission of NCCN.

PLEASE NOTE that use of this NCCN Content is governed by the End-User License Agreement, and you MAY NOT distribute this Content or use it with any artificial intelligence model or tool.
Printed by A. S. M. FAZLUL KARIM CHOWDHURY on 4/20/2026 3:41:05 AM. Copyright © 2026 National Comprehensive Cancer Network, Inc. All Rights Reserved.

2000;46:1239-1246. Available at:
https://www.ncbi.nlm.nih.gov/pubmed/10725637.

Version 2.2025 © 2025 National Comprehensive Cancer Network© (NCCN©), All rights reserved. NCCN Guidelines® and this illustration may not be reproduced in any form without the express written permission of NCCN.