Acta Cytologica

Nongynecologic Cytopathology

Acta Cytologica 2024;68:160–170
DOI: 10.1159/000538465

Received: January 13, 2024
Accepted: March 12, 2024
Published online: March 24, 2024

A Novel Validated Real-World Dataset for the Diagnosis of Multiclass Serous Effusion Cytology according to the International System and Ground-Truth Validation Data

Esraa Abd-Almoniem[a] Nadia Abd-Alsabour[b] Samar Elsheikh[a] Rasha R. Mostafa[a] Yasmine Fathy Elesawy[a]

[a]Department of Anatomic Pathology, Kasr Alainy Faculty of Medicine, Cairo University, Giza, Egypt;
[b]Department of Computer Science, Faculty of Graduate Studies for Statistical Research, Cairo University, Giza, Egypt

Keywords
Serous effusion cytology · Multiclass classification · VGG16 · Ground-truth validation data · Random forest

Abstract
Introduction: The application of artificial intelligence (AI) algorithms in serous fluid cytology is lacking due to the deficiency in standardized publicly available datasets. Here, we develop a novel public serous effusion cytology dataset. Furthermore, we apply AI algorithms on it to test its diagnostic utility and safety in clinical practice. ***Methods:*** The work is divided into three phases. Phase 1 entails building the dataset based on the multitiered evidence-based classification system proposed by the International System (TIS) of serous fluid cytology along with ground-truth tissue diagnosis for malignancy. To ensure reliable results of future AI research on this dataset, we carefully consider all the steps of the preparation and staining from a real-world cytopathology perspective. In phase 2, we pay special consideration to the image acquisition pipeline to ensure image integrity. Then we utilize the power of transfer learning using the convolutional layers of the VGG16 deep learning model for feature extraction. Finally, in phase 3, we apply the random forest classifier on the constructed dataset. ***Results:*** The dataset comprises 3,731 images distributed among the four TIS diagnostic categories. The model achieves 74% accuracy in this multiclass classification problem. Using a one-versus-all classifier, the fallout rate for images that are misclassified as negative for malignancy despite being a higher risk diagnosis is 0.13. Most of these misclassified images (77%) belong to the atypia of undetermined significance category in concordance with real-life statistics. ***Conclusion:*** This is the first and largest publicly available serous fluid cytology dataset based on a standardized diagnostic system. It is also the first dataset to include various types of effusions and pericardial fluid specimens. In addition, it is the first dataset to include the diagnostically challenging atypical categories. AI algorithms applied on this novel dataset show reliable results that can be incorporated into actual clinical practice with minimal risk of missing a diagnosis of malignancy. This work provides a foundation for researchers to develop and test further AI algorithms for the diagnosis of serous effusions.

© 2024 S. Karger AG, Basel

karger@karger.com
www.karger.com/acy

© 2024 S. Karger AG, Basel

Correspondence to:
Esraa Abd-Almoniem, esraaesmat@kasralainy.edu.eg

Downloaded from http://karger.com/acy/article-pdf/68/2/160/4230269/000538465.pdf by Zhejiang University user on 06 July 2024

Introduction

Serous effusions can result from both neoplastic and nonneoplastic disease processes. Due to their relative ease of sampling and high diagnostic sensitivity, serous effusion cytology examination is usually the initial step in the diagnostic workup [1]. The process of screening effusion slides is time-consuming and, accordingly, prone to errors [2]. Thus, automating this process using artificial intelligence (AI) algorithms can enhance laboratory efficiency and improve patients' outcomes [3].

In order to implement AI algorithms into routine clinical practice in cytology, it is critical to develop reliable datasets in the literature to allow robust algorithm development. Most literature and datasets in implementing machine learning in cytology are focused on cervical cytology [4–8]. The literature dealing with effusion cytology is limited and cannot be generalized in the routine clinical setting. One of the most notable shortcomings in the literature addressing serous fluid cytology automation is that the datasets are locally prepared and are not publicly available [9–21]. In addition, these datasets do not follow a clinically reproducible diagnostic system and are not accompanied by ground-truth validation data. Besides, in many instances, these datasets are designed to include only specific regions of interest on the slides [9–26].

In medical images, feature extraction is a crucial step to train an AI algorithm [27]. In cytopathology, this task tends to be very complex, especially with the presence of out of focus images, multiple planes, 3D clusters, artifacts, and background details [28]. Features can be handcrafted to include specific regions of interest. This process is extensively complex and expert-dependent. In addition, it carries the risk of excluding diagnostically important information, for instance, tumor diathesis in the background [1, 26–28]. Another approach is using convolutional neural networks (CNNs). CNNs are a specific type of deep learning that are capable of learning features from the input data [27]. In CNNs, the convolutional layer is formed of filters that are passed over the input image pixels to capture a specific set of features that are then summarized by a pooling layer to generate essential feature maps necessary for the classification task [28, 29].

Despite the advantages of deep learning, it generally needs large amount of data to train [27]. In medical images, obtaining such large amounts of data can be a hurdle since data are subject to privacy regulations and its use must be approved by ethics boards [30]. This is in contrast to natural image datasets that can include millions of images. For this reason, transfer learning is an excellent approach in the applications of AI on medical images. Transfer learning can be used on small amounts of data in which features learned on a large dataset can be transferred to the smaller dataset [31]. Zhang et al. [32] showed that features learned from natural images can be transferred to biological data. In the literature, one of the most well-studied and highest performing transfer learning models in pathology and cytology is the VGG16 that is pretrained on the ImageNet database [14, 16, 17, 33, 34]. The VGG16 is a relatively extensive network with a total of 138 million parameters. The number of filters of the VGG16 increases gradually as the model gets deeper from 64 filters in the initial layers to 512 filters in the final convolutional layers, thus incorporating the most important features of convolution neural networks [34].

The extracted features can then be passed to a classification algorithm. For image classification, many algorithms exist including neural networks, random forest of decision trees, and support vector machines [29]. Neural networks generally need large data to train for best performance [27]. In contrast, random forests and support vector machines can perform very well on smaller amounts of data [29]. Unlike support vector machines, random forest is an inherently multiclass classifier, making it an ideal candidate for the classification of serous effusion cytology dataset into the TIS diagnostic categories [1, 27, 29].

Random forests are a combination of multiple decision trees. Decision trees can be visualized as a flowchart of decisions. Input data is split into a set of questions that make up the decision nodes in the tree, acting as a means to split the data (for example, if the nucleus is hyperchromatic, is the cell likely malignant [MAL] or benign?). Each question helps the classifier to arrive at a final decision. Observations that fit the criteria will follow the (yes) branch and those that do not will follow the alternate path. Decision trees seek to find the best split to subset the data. Thus, they can be used as classification algorithm to classify data (for example, benign or MAL). Decision trees, however, are prone to overfitting. They can learn the training data very well and become unable to generalize to the testing data. This problem is solved by combining multiple decision trees to form the random forest algorithm. The strength of the random forest algorithm lies in the feature randomness. Feature randomness generates a random subset of features, which ensures low correlation among decision trees, thus creating an uncorrelated forest of decision trees. This is a key difference between decision trees and random forests. While decision trees consider all the possible feature splits, random forests only select a subset of those features. By accounting for all the potential variability in the data, the risk of overfitting, bias, and overall variance can be reduced, resulting in more precise predictions [29].

Downloaded from http://karger.com/acy/article-pdf/68/2/160/4230269/000538465.pdf by Zhejiang University user on 06 July 2024

The Proposed Work

The work in this paper is divided into three phases. Phase 1 is creating a new public serous effusion cytology dataset based on the multitiered classification system proposed by the International System (TIS) of serous fluid cytology. We carefully consider the sequence of the steps that go into the specimen preparation and provide a detailed description of these steps to ensure the generalizability to future research that will be conducted on this dataset. Phase 2 is utilizing CNNs for feature extraction on the constructed dataset and interpreting these features from a diagnostically meaningful clinical perspective. Phase 3 is applying a random forest classifier, a robust machine learning multiclass classifier, to obtain multitiered diagnostic results on this dataset. We give special emphasis on clinically focused statistical analysis to test the utility of including the results in a routine daily workflow.

Material and Methods

Phase 1: Preparation of the Dataset

Diagnostic Criteria

Diagnoses are included based on strict criteria proposed by the International System (TIS) of serous fluid cytology [1]. The diagnostic categories are negative for malignancy (NFM), atypia of undetermined significance (AUS), suspicious for malignancy (SFM), and MAL. In our institution, the diagnosis of AUS is rendered when the morphologic changes are questionable but are more likely to be reactive. In addition, the adjacent cell block of these cases is either inconclusive or not performed due to insufficient material and/or poor sample preservation. These cases are signed out as AUS for clinical and radiological correlation, in addition to recommending repeat sampling with a sufficient volume of fluid (50–75 mL) if clinically feasible [35, 36].

Ground-Truth Validation

All cases have ground-truth validation either in the form of tissue diagnosis, clinical history, and/or radiologic findings. The NFM cases are confirmed by the lack of clinical and/or radiologic evidence of malignancy and the presence of a clinical explanation for the effusion (for example, infection, renal or liver disease). In cases of AUS, the follow-up of cases showing high likelihood of degenerative changes is established by the absence of clinical history or radiologic findings of malignancy and the presence of negative cytology sample after the atypia diagnosis. The SFM and MAL cases have a corresponding confirmatory tissue diagnosis with the immunohistochemistry when needed.

Building the Dataset in an Image-Based Approach

In this work, we construct the dataset using an image-based approach, not a patient-based approach. This entails obtaining multiple images from a single patient's slide, and each image (i.e., in one 40× microscopic field) is assigned a diagnostic category based on the TIS criteria. In some cases, a single slide can harbor different morphologies. For example, if the overall diagnosis of a patient according to the TIS is positive for malignancy, a single slide can harbor normal mesothelial cells and cells that can fit in the categories of AUS and SFM, in addition to the MAL cells that render the final diagnosis [1, 26].

Fluid Type, Staining, and Preparation

The dataset is built using various fluid types including pleural, ascitic, and pericardial fluid. In addition, we explicitly include only Papanicolaou-stained slides that are no longer than 7 months old. All slides are prepared using conventional method of cytology preparation. The preparation and staining procedures are outlined in the online supplementary material (for all online suppl. material, see https://doi.org/10.1159/000538465).

Phase 2: Image Acquisition and Features

Image Acquisition

All images are examined by the light microscope (Model Olympus BX51) and photographed by a microscopic camera (YW 500, USB 2.0, 1/2.8" CMOS sensor, resolution 5 million pixels, and pixel size 2.2 × 2.2 μm) with software S-EYE 1.3.2.297@2016. The work is performed on a Dell XPS 13 7390 with an Intel® Core™ i7-10710U CPU at 1.10 GHz and 1.61 GHz and a 64-bit operating system using Windows 11. The images are taken with a ×40 magnification lens in PNG format.

Feature Extraction

We extract features from the image as a whole using transfer learning. We use the VGG16 model [34] that was pretrained on the ImageNet database [37] as a feature extractor. We remove the fully connected classification layer and use the convolutional layers for feature extraction.

Phase 3: Classification

In this work, we use the random forest of decision trees as a classifier. To avoid the risk of overfitting in this work, we use five-fold cross-validation; in which the training data are randomly split into 5 folds, and then the model is trained on the 4 folds, while the remaining fold is left to test the model. This is repeated on all the five folds to obtain the best parameters for the model [29]. The data are first split into training and testing datasets, and the training dataset is used for cross-validation. Each model is repeated 50 times with 5-fold cross-validation. We then rerun the experiments using the one versus rest (OVR) classifier using the NFM category against the rest of the categories.

Results

Phase 1: Dataset

The final dataset comprises 3,731 instances (1,184 NFM, 850 AUS, 837 SFM, and 860 MAL), including 29 pleural, 13 ascitic, and, 5 pericardial fluid cases. The breakdown of the cases, number of images, and their respective diagnoses are visualized in Tables 1, 2, respectively. Sample images from the prepared serous fluid cytology dataset are shown in Figure 1.

Downloaded from http://karger.com/acy/article-pdf/68/2/160/4230269/000538465.pdf by Zhejiang University user on 06 July 2024

Table 1. Breakdown of cases with corresponding cytologic diagnosis and number of images for each diagnostic category

	Pleural fluid	Ascitic fluid	Pericardial fluid	Total number of images
NFM	898	135	151	1,184
AUS	364	174	312	850
SFM	514	291	32	837
Positive for malignancy	511	279	70	860

Phase 2: Feature Extraction

The VGG16 model with its pretrained weights is downloaded from the Keras Application Programming Interface [38]. To utilize the model as a feature extractor, the top classification layers (three fully connected layers) are excluded, and the convolutional and pooling layers are included only as feature extractor. The total number of parameters is 14,714,688; all of which are set to be non-trainable parameters. To visualize the produced filter responses, a truncated version of the model is performed at each block to analyze the learned features as the model progresses deeper. Images from each category are used as an example to study such features. Figure 2 shows samples of the filter responses obtained for a sample image from each diagnostic category.

Phase 3: Classification

Features extracted from the VGG16 are used for training. Random Forest is used as the classifier algorithm, using five-fold cross-validation and random state of 42 to ensure reproducibility. After training using fivefold cross-validation, the model with the best parameters is obtained and saved for the test dataset. The model achieved 74% accuracy in this multiclass classification problem. Highest precision is achieved with the MAL category (83%) and the NFM category (77%). The classification report and the confusion matrix are shown in Figure 3a and b, respectively.

Misclassifications

Of the 172 MAL images in the test set, 1 is misclassified as NFM, 24 images are misclassified as SFM, and 4 images are misclassified as AUS. Of the 168 SFM images, 21 images are classified as MAL, 28 images are classified as AUS, and 14 are misclassified as NFM. Of the 170 AUS images, 5 images are misclassified as MAL, 51 images are misclassified as NFM, and 29 images are misclassified as SFM.

OVR Class-Specific Metrics

The NFM is tested against the remaining categories using OVR classifier. The fallout rate is 0.13. Out of the 510 images from the categories (AUS, SFM, MAL); 66 images were misclassified as NFM (12.9%); most of which (77%) belong to the AUS category.

Discussion

This is the first and largest publicly available dataset that includes the International System (TIS) of serous fluid cytology diagnostic categories and includes various types of fluid cytology in a single dataset. It is also the first dataset that includes pericardial fluid specimens. The dataset is constructed to be suitable for multiclass classification of serous fluid cytology images into one of four TIS classes (NFM, AUS, SFM, and MAL) [1].

Among the novelties of this work is the inclusion of the atypical diagnostic categories, AUS and SFM, in addition to images with artifacts. It is well known that degenerative atypical changes and other artifacts are inherent to effusion cytology [1] and cause significant diagnostic challenge. Studies in the current literature approach dataset preparation in two ways. Most of the studies excluded these categories altogether and included only the benign and MAL cells [9, 10, 12, 14–16, 18–22, 24, 25]. In the few studies that included atypical cells, the ultimate goal was to place these cells into benign or MAL classes [11, 13, 17]. Both approaches have dangerous implications for patient care. These intermediate categories have been specifically placed to ensure that patients get the ancillary studies needed to yield a definitive diagnosis and ensure that malignancy is not missed. Forcing the algorithm to classify cells as only benign or MAL can cause misdiagnosis that can be detrimental in clinical practice. Another major contribution of this work

Downloaded from http://karger.com/acy/article-pdf/68/2/160/4230269/000538465.pdf by Zhejiang University user on 06 July 2024

Table 2. Cytologic and corresponding tissue diagnoses for SFM and MAL categories

Specimen type	Cytologic diagnosis	Tissue diagnosis
Pleural fluid	MAL/SFM	Metastatic adenocarcinoma of colon, lung, unknown origin, and mesothelioma
Ascitic fluid	MAL/SFM	Metastatic adenocarcinoma from the colon, ovary, and breast
Pericardial fluid	MAL	Metastatic adenocarcinoma of breast origin

SFM, suspicious for malignancy; MAL, malignant.

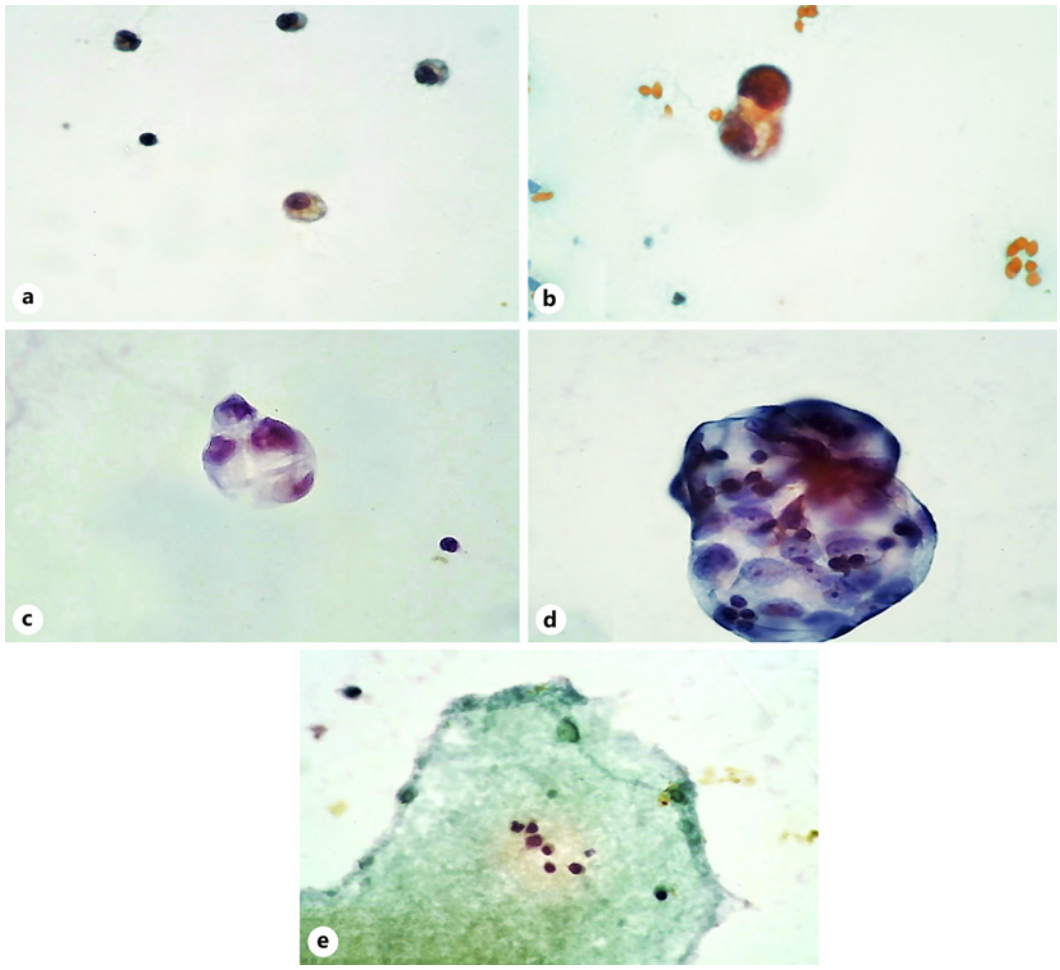

Fig. 1. a Sample image from the negative for malignancy (NFM) category. Mesothelial cells have bland cytologic features and are admixed with various inflammatory cells. **b** Sample image from the atypia of undetermined significance (AUS) category. Cells show slight nuclear membrane irregularities and nuclear enlargement. There is no frank anaplasia, hyperchromatic nuclei, or striking pleomorphism that would warrant a diagnosis of malignancy. **c** Sample image from the suspicious for malignancy (SFM) category. In this image, there is a cluster of cells showing hyperchromatic nuclei and pleomorphism. The low cellularity and the presence of slight degeneration would justify the diagnosis of SFM. **d** Image from the malignant (MAL) category. Cells are forming a 3D cluster and show pleomorphism, hyperchromatic nuclei, and prominent nucleoli. **e** Image showing staining artifact intentionally included in the dataset to represent real-world challenges.

Downloaded from http://karger.com/acy/article-pdf/68/2/160/4230269/000538465.pdf by Zhejiang University user on 06 July 2024

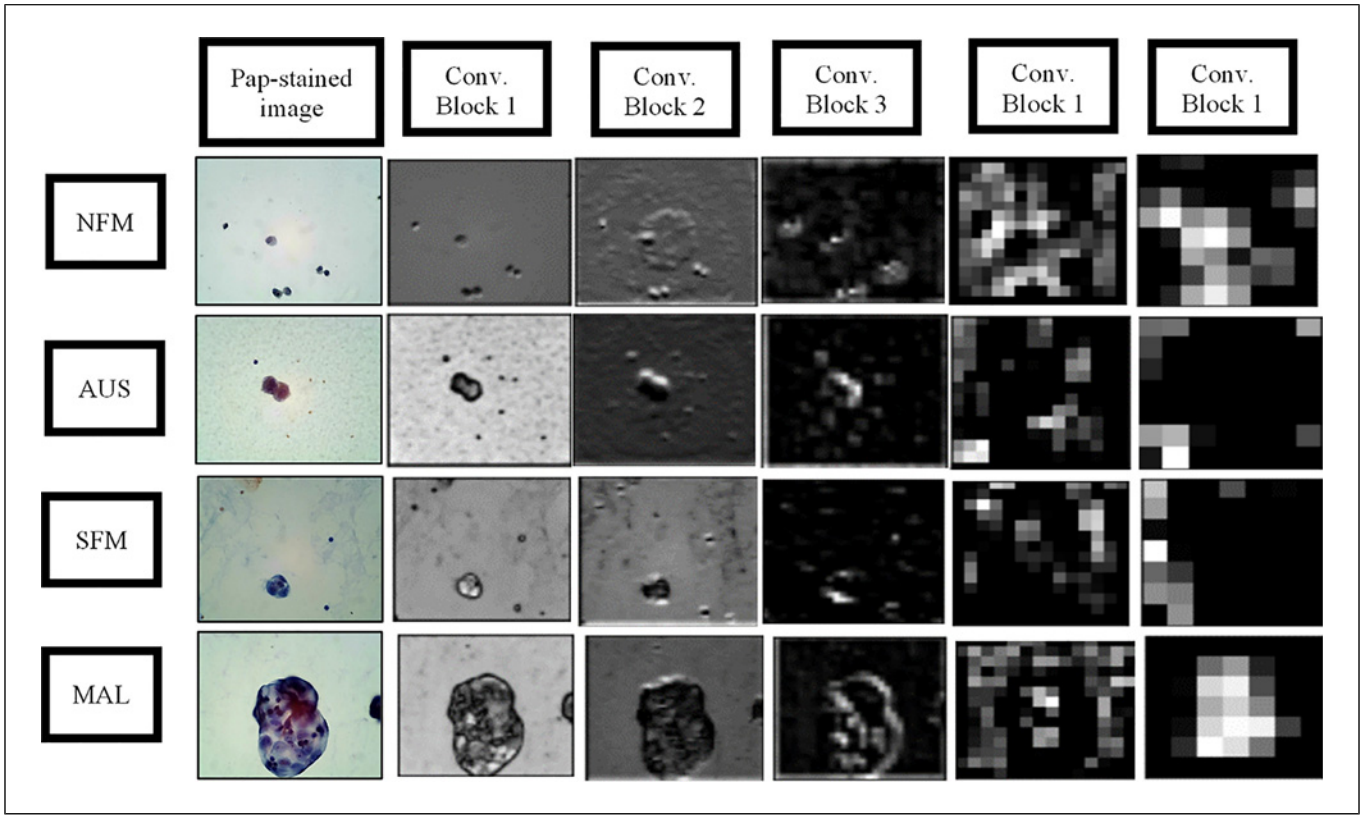

Fig. 2. Sample images from each diagnostic category with the corresponding samples of filter responses at each convolutional block. Initial convolutional layers capture low-level details of the image, and deeper layers capture more complex features. NFM, negative for malignancy; AUS, atypia of undetermined significance; SFM, suspicious for malignancy; MAL, malignant.

	precision	recall	f1-score	support
NFM	0.77	0.92	0.83	237
AUS	0.65	0.50	0.57	170
SFM	0.65	0.62	0.64	168
MAL	0.83	0.83	0.83	172
accuracy			0.74	747
macro avg	0.73	0.72	0.72	747
weighted avg	0.73	0.74	0.73	747

a

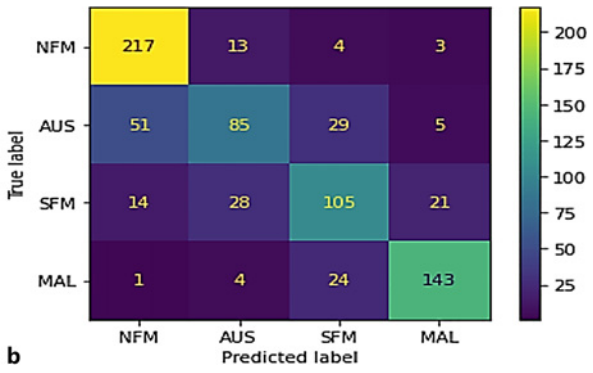

b

Fig. 3. a Classification report. **b** Confusion matrix. NFM, negative for malignancy; AUS, atypia of undetermined significance; SFM, suspicious for malignancy; MAL, malignant.

Downloaded from http://karger.com/acy/article-pdf/68/2/160/4230269/000538465.pdf by Zhejiang University user on 06 July 2024

is the vigorous consideration of ground-truth validation for all cases. This was intentional to avoid variability in the interobserver agreement and to provide higher confidence in the rendered diagnosis [1].

We used an image-based approach in building this dataset rather than a patient-based approach. We used this approach to be in line with the clear goal of teaching the algorithm to extract the morphological characteristics. This is in contrast to the work of Teramoto et al. [14], which used image-based classification in addition to case-based classification. The authors integrated the results from cell evaluation across positions and specimens to obtain a comprehensive diagnosis. For this, malignancy probability was calculated by their model, and the maximum value was considered the overall probability for that case. In this work, we did not base this dataset on an overall patient-based diagnosis. This is because in clinical practice, a combination of decisions is utilized to render a final diagnosis, not a numeric probability value. These decisions include cytomorphology features (qualitatively and quantitatively) in addition to the pathologist's expertise and the clinical context. An example of this scenario is shown in the diagnosis of AUS. In this case, the number of microscopic areas or cells that show degenerative changes and would justify the diagnosis of AUS is not defined. This overall decision is, in many instances, left to the pathologist's discretion and experience. Another goal of the current work is to help create a system that can analyze images and flag them accordingly in their corresponding category, analogous to morphological analyzers utilized in hematopathology [39]. If the system flags an image as abnormal, a pathologist's confirmation will be needed, depending on the urgency of the flagged abnormality (MAL > SFM > AUS). Otherwise, the system can continue screening.

To make sure this dataset can be used for future works on a universal scale, we paid very close attention to the technical aspects of preparation and staining. In contrast to works that used hematoxylin and eosin-stained slides for the preparation of their datasets [15, 17, 21], we explicitly included only Papanicolaou-stained slide. This is because Papanicolaou stain is the most universal cytology staining owing to its remarkable diagnostic properties [40]. Hematoxylin and eosin stain, on the other hand, is not ideal for cytopathology practice because it contains Mayer's hematoxylin that is not feasible for cytology staining [41, 42]. Another notable finding in the current datasets is that they were prepared from old archived Papanicolaou stained slides. For instance, Barwad et al. [12] used Papanicolaou stained slides from 2-year-old archives. The problem with that approach is that Papanicolaou stains fade over time [43], so using old slides can hinder the quality of the obtained images. We also avoided using liquid-based cytology in this work since it can lead to the loss of markedly useful diagnostic background information including debris and inflammation [44, 45].

Since computer-aided diagnostic systems for medical images require a high degree of precision, we paid very close attention to the image acquisition pipeline to ensure that the images captured are a faithful representation of the actual specimen [46]. Specific importance is given to image compression. In this work, we use the PNG format which is a lossless image compression format. Despite occupying more memory size, lossless data compression ensures the complete preservation of data, making it ideal for medical image analysis, where data integrity is vital for an accurate interpretation [46]. This is in contrast to datasets in the current literature that use images captured in JPEG format [11, 14, 16, 19, 33, 47]. Although JPEG format is excellent in terms of storage size, it is a lossy compression format that selectively discards information, leading to smaller size with a trade-off in quality [34]. Another advantage of using a lossless image compression format is that it minimizes the data loss that inevitably occurs when resizing images to fit into deep learning models [48].

For the feature extraction step, we use transfer learning using the CNNs of the VGG16 that is pretrained on the ImageNet natural image dataset [34, 37]. We avoided explicit highlighting of specific regions of interest to avoid missing important diagnostic data, including cellularity quantization, background debris, hemorrhage, and real-world preparation artifacts [1, 26]. We choose the VGG16 specifically because (1) it uses a tiny 3 × 3 receptive field with a 1-pixel stride. This small receptive field allows more nonlinear activation layers to accompany the convolution layers, thus improving the decision functions and allowing the network to converge quickly. (2) The utilization of a small convolutional filter reduces the network's tendency to overfit during training exercises. (3) A 3 × 3 filter is the optimal size because a smaller size cannot capture left-right and up-down information [46]. Thus, VGG16 is the smallest possible model to understand an image's spatial features. (4) Consistent 3 × 3 convolutions make the network easy to manage [34]. After feature extraction, we visually analyze the convolutional filter responses for different diagnostic categories to gain an insight about the nature of the extracted features. Visual analysis of the extracted features shows that initial layers capture low level image representations (edges, contours. . .), intermediate layers capture texture

Downloaded from http://karger.com/acy/article-pdf/68/2/160/4230269/000538465.pdf by Zhejiang University user on 06 July 2024

information, and deeper layers capture higher level information that are visually incomprehensible but mathematically useful for further classification.

For the classification task, we used the random forest of decision trees as the classifier. We choose the random forest because (1) random forest is an inherently multiclass classifier; thus, it is ideal for this work's multiclass problem (NFM, AUS, SFM, and MAL) [49]. (2) Random forest is a powerful classifier that can be trained using small amount of data; this is in contrast to neural networks, which need huge amount of data to be trained. (3) Random forests showed high performance in medical image classification problems in the literature [41]. (4) Random forest is known to have good performance with noisy data [50, 51]. (5) In serous fluid cytology, random forest was used successfully in a number of works [13, 25, 52]. In this work, we combine the advantages of CNNs utilizing transfer learning for feature extraction and traditional machine learning for classification. A closely similar approach has been successfully implemented in a number of studies with increasing performance of classification rather than using deep learning as a sole classifier [33, 53].

We achieved overall classification accuracy of 74%. Analysis of the misclassified results shows very close resemblance to actual clinical scenarios. For instance, in the MAL category, the misclassification rate for the SFM category was 13%. SFM and MAL categories are very closely related in terms of cytologic findings, and the final diagnosis is often based on the overall findings of the whole case, including various staining techniques, overall cellularity, and clinical history. In the SFM category, a large number of images were misclassified as AUS; which again in concordance with the TIS and the justification of placing separate diagnostic categories for the AUS and SFM. In real life, degenerative changes are a true challenge, and cases placed in the intermediate categories can extensively overlap. In this dataset, image-based classification is conducted utilizing only cytologic features. Thus, the overlap between the SFM/MAL and SFM/AUS categories is acceptable [1]. Another consideration when analyzing the classification results is the overall patient's safety associated with using these algorithms in actual clinical practice. In this study, although misclassifications occurred, a significant number of these misclassifications were among the AUS, SFM, and MAL categories. These misclassifications are acceptable from a clinical point of view since they all point to the necessity of further ancillary testing and ensure no missed MAL diagnoses [1].

In contrast, images that are incorrectly predicted as NFM and should have been placed in one of the other categories carry a significant risk of missing a MAL diagnosis. This is because if NFM diagnosis is made, no ancillary testing will be conducted. Thus, it is extremely important to minimize this particular misclassification. For this reason, we conducted an OVR classifier, testing the NFM category against the remaining categories. Using a one-versus-all classifier, the fallout rate for images that are misclassified as NFM despite being a higher risk diagnosis is 0.13. Most of the misclassified images (77%) belong to the AUS. In the actual clinical setting, the AUS category is reserved for borderline cases when NFM diagnosis is more likely; however, cells show degenerative changes that render an atypical diagnosis more appropriate [1]. Thus, these results resemble real-life clinical scenarios. Of the misclassified images, only one is actually a MAL image. Analysis of this image shows significant obscuring artifact that may have resulted in this misclassification. We believe that increasing the number of instances in the future would avoid this misclassification. In addition, in this work, we used an image-based classification and not case-based classification. In practice, the final diagnosis is rendered after thorough evaluation of the specimen with re-smearing and re-staining in addition to combination of the clinical context and the overall pathologist's expertise in differentiating degenerative changes and true atypia [1].

Conclusion and Future Work

In this work, we built the first and largest real-world serous fluid dataset based on the 2020 International System (TIS) of serous fluid cytology. It includes representative images of all types of serous fluids and is the first dataset that incorporates pericardial fluid specimens. We considered many rigorous factors when constructing this dataset to reflect the real-world diagnostic challenges. We used a hybrid model based on the pretrained VGG16 for feature extraction, followed by the random forest classifier with 74% accuracy. The results show that experiments on this dataset can be transferred to clinical practice without compromising patient's safety.

Although we believe there are novel contributions from this work to the literature, we acknowledge that many aspects could be improved. First, increasing the

Downloaded from http://karger.com/acy/article-pdf/68/2/160/4230269/000538465.pdf by Zhejiang University user on 06 July 2024

number of instances in the dataset can provide higher classification accuracy and sensitivity. For this reason, the dataset will be continuously updated in concordance with the preset preparation guidelines. Second, we acknowledge that lymphoma diagnosis was not included in this work. We chose to focus on epithelial and mesothelial cell abnormalities in this work. This is an area that clearly needs improvement and should be included in future work. Finally, we did not include the nondiagnostic category because it is a diagnosis of exclusion and is based on the correlation between clinical, pathologic, radiologic data in addition to close communication between the pathologist and the clinician to be rendered. Since the goal of this work is the identification of cytomorphology, this category is not included for the time being.

Statement of Ethics

This study protocol was reviewed and approved by the Research Ethics Committee of Cairo University Faculty of Medicine, approval number MD-2-2022. This consent protocol was reviewed, and the need for written and informed consent was waived by the Research Ethics Committee of Cairo University Faculty of Medicine (Code: MD-2-2022).

Conflict of Interest Statement

The authors declare that there are no competing financial interests associated with this work.

Funding Sources

No funding was used for this study.

Author Contributions

E.A.-A. collected and refined the data, wrote the code, conducted the experimental analysis, and wrote the manuscript draft. N.A.-A. verified codes, performed experimental and statistical analysis, and refined in detail the manuscript. S.E., R.R.M., and Y.F.E. supervised data collection, verified correct diagnoses according to TIS guidelines, and shared in refining the manuscript.

Data Availability Statement

The constructed dataset is publicly available on ResearchGate, https://www.researchgate.net/publication/378976550_Serous_fluid_cytology_dataset#fullTextFileContent and https://drive.google.com/drive/folders/1EWgEXXC8iPfDKRkh6qYaSo5ESZLpUNbf?usp=drive_link. The excel sheet and the code are available from the corresponding author on a reasonable request.

References

1 Pinto D, Chandra A, Crothers BA, Kurtycz DF, Schmitt F. The International system for reporting serous fluid cytopathology – diagnostic categories and clinical management. J Am Soc Cytopathol. 2020;9(6):469–77. doi: 10.1016/j.jasc.2020.05.015.

2 Elsheikh TM, Austin RM, Chhieng DF, Miller FS, Moriarty AT, Renshaw AA, et al. American society of cytopathology workload recommendations for automated pap test screening: developed by the productivity and quality assurance in the era of automated screening task force. Diagn Cytopathol. 2013;41(2):174–8. doi: 10.1002/dc.22817.

3 Victória Matias A, Atkinson Amorim JG, Buschetto Macarini LA, Cerentini A, Casimiro Onofre AS, De Miranda Onofre FB, et al. What is the state of the art of computer vision-assisted cytology? A Systematic Literature Review. Comput Med Imaging Graph. 2021;91:101934. doi: 10.1016/j.compmedimag.2021.101934.

4 Phoulady HA, Mouton PR. A new cervical cytology dataset for nucleus detection and image classification (Cervix93) and methods for cervical nucleus detection. arXiv. 2018. preprint arXiv:1811.09651.

5 Araújo FH, Silva RR, Ushizima DM, Rezende MT, Carneiro CM, Campos Bianchi AG, et al. Deep learning for cell image segmentation and ranking. Comput Med Imaging Graph. 2019;72:13–21. doi: 10.1016/j.compmedimag.2019.01.003.

6 Hussain E, Mahanta LB, Borah H, Das CR. Liquid based-cytology Pap smear dataset for automated multi-class diagnosis of pre-cancerous and cervical cancer lesions. Data Brief. 2020;30:105589. doi: 10.1016/j.dib.2020.105589.

7 Rezende MT, Silva R, Bernardo FDO, Tobias AH, Oliveira PH, Machado TM, et al. Cric searchable image database as a public platform for conventional pap smear cytology data. Sci Data. 2021;8(1):151. doi: 10.1038/s41597-021-00933-8.

8 Liang Y, Tang Z, Yan M, Chen J, Liu Q, Xiang Y. Comparison detector for cervical cell/clumps detection in the limited data scenario. Neurocomputing. 2021;437:195–205.

9 Chen F, Xie J, Zhang H, Xia D. A technique based on wavelet and morphology transform to recognize the cancer cell in pleural effusion. Proceedings international workshop on medical imaging and augmented reality. IEEE; 2001. p. 199–203. doi: 10.1109/MIAR.2001.930286.

10 Alayón S, Estévez JI, Sigut J, Sánchez JL, Toledo P. An evolutionary Michigan recurrent fuzzy system for nuclei classification in cytological images using nuclear chromatin distribution. J Biomed Inform. 2006;39(6):573–88. doi: 10.1016/j.jbi.2006.03.001.

11 Martínez VE, Rodríguez AF, Remolina JF, Álvarez OM. Recognition system for mesothelials cells classification. World Congress On Medical Physics and Biomedical Engineering, September 7-12, 2009, Munich, Germany: vol. 25/5 information and communication in medicine, telemedicine and e-health. Springer Berlin Heidelberg; 2009. p. 263–6. doi: 10.1007/978-3-642-03904-1_73.

12 Barwad A, Dey P, Susheilia S. Artificial neural network in diagnosis of metastatic carcinoma in effusion cytology. Cytometry B Clin Cytom. 2012;82(2):107–11. doi: 10.1002/cyto.b.20632.

13 Vargason TJ, Cohn J, Rios D, Schultz O, Cleary J, Lau D, Qiao X. A clinical decision support system for malignant pleural effusion analysis. Justice & well-being studies faculty scholarship. 2016. https://orb.binghamton.edu/multigenerational_fac/1.

Downloaded from http://karger.com/acy/article-pdf/68/2/160/4230269/000538465.pdf by Zhejiang University user on 06 July 2024

14 Teramoto A, Yamada A, Kiriyama Y, Tsukamoto T, Yan K, Zhang L, et al. Automated classification of benign and malignant cells from lung cytological images using deep convolutional neural network. Inform Med Unlocked. 2019;16:100205. doi: 10.1016/j.imu.2019.100205.
15 Aboobacker S, Vijayasenan D, David SS, Suresh PK, Sreeram S. A deep learning model for the automatic detection of malignancy in effusion cytology. 2020 IEEE international conference on signal processing, communications and computing (ICSPCC). IEEE; 2020. p. 1–5. doi: 10.1109/ICSPCC50002.2020.9259490.
16 Teramoto A, Tsukamoto T, Yamada A, Kiriyama Y, Imaizumi K, Saito K, et al. Deep learning approach to classification of lung cytological images: two-step training using actual and synthesized images by progressive growing of generative adversarial networks. PLoS One. 2020;15(3):e0229951. doi: 10.1371/journal.pone.0229951.
17 Su F, Sun Y, Hu Y, Yuan P, Wang X, Wang Q, et al. Development and validation of a deep learning system for ascites cytopathology interpretation. Gastric Cancer. 2020; 23(6):1041–50. doi: 10.1007/s10120-020-01093-1.
18 Sanyal P, Paul S, Rana V, Kulhari K. A machine learning model for screening of body fluid cytology smears. bioRxiv. 2021. doi: 10.1101/2021.07.20.453010.
19 Teramoto A, Kiriyama Y, Tsukamoto T, Sakurai E, Michiba A, Imaizumi K, et al. Weakly supervised learning for classification of lung cytological images using attention-based multiple instance learning. Sci Rep. 2021;11(1):20317. doi: 10.1038/s41598-021-99246-4Teramoto.
20 UÇAn M, Kaya B, Kaya M. Comparison of deep learning models for body cavity fluid cytology images classification. 2022 International Conference on data analytics for business and industry (ICDABI). IEEE; 2022. p. 151–5. doi: 10.1109/ICDABI56818.2022.10041518.
21 Xie X, Fu CC, Lv L, Ye Q, Yu Y, Fang Q, et al. Deep convolutional neural network-based classification of cancer cells on cytological pleural effusion images. Mod Pathol. 2022; 35(5):609–14. doi: 10.1038/s41379-021-00987-4.
22 Win KY, Choomchuay S, Hamamoto K. K mean clustering based automated segmentation of overlapping cell nuclei in pleural effusion cytology images. 2017 International Conference on Advanced Technologies for Communications (ATC). IEEE; 2017. p. 265–9.
23 Win KY, Choomchuay S, Hamamoto K. Automated segmentation and isolation of touching cell nuclei in cytopathology smear images of pleural effusion using distance transform watershed method. Second International Workshop on pattern recognition. SPIE; 2017; Vol. 10443. p. 126–30.
24 Win KY, Choomchuay S, Hamamoto K, Raveesunthornkiat M. Artificial neural network based nuclei segmentation on cytology pleural effusion images. 2017 International Conference on Intelligent Informatics and Biomedical Sciences (ICIIBMS). IEEE; 2017. p. 245–9.
25 Win KY, Choomchuay S, Hamamoto K, Raveesunthornkiat M, Rangsirattanakul L, Pongsawat S. Computer aided diagnosis system for detection of cancer cells on cytological pleural effusion images. BioMed Res Int. 2018;2018:6456724. doi: 10.1155/2018/6456724.
26 Mills SE. Histology for pathologists essay: Wolters Kluwer; 2020.
27 Szeliski R. Computer vision: algorithms and applications. Springer Nature; 2022.
28 Merchant FA, Castleman KR. Microscope image processing. Elsevier Academic Press; 2023.
29 Bisong E. Building Machine Learning and deep learning models on Google Cloud Platform: a comprehensive guide for beginners essay: Apress; 2019.
30 Adnan M, Kalra S, Cresswell JC, Taylor GW, Tizhoosh HR. Federated learning and differential privacy for medical image analysis. Sci Rep. 2022;12(1):1953. doi: 10.1038/s41598-022-05539-7.
31 Goodfellow I, Bengio Y, Courville A. Deep learning. MIT press; 2016.
32 Zhang W, Li R, Zeng T, Sun Q, Kumar S, Ye J, et al. Deep model based transfer and multi-task learning for biological image analysis. Proceedings of the 21th ACM SIGKDD International Conference on Knowledge Discovery and Data Mining; 2015. p. 1475–84.
33 Tsukamoto T, Teramoto A, Yamada A, Kiriyama Y, Sakurai E, Michiba A, et al. Comparison of fine-tuned deep convolutional neural networks for the automated classification of lung cancer cytology images with integration of additional classifiers. Asian Pac J Cancer Prev. 2022;23(4): 1315–24. doi: 10.31557/APJCP.2022.23.4.1315.
34 Simonyan K, Zisserman A. Very deep convolutional networks for large-scale image recognition. arXiv. 2014. preprint arXiv: 1409.1556. https://arxiv.org/pdf/1409.1556.pdf%E3%80%82.
35 Rooper LM, Ali SZ, Olson MT. A minimum fluid volume of 75 mL is needed to ensure adequacy in a pleural effusion: a retrospective analysis of 2540 cases. Cancer Cytopathol. 2014;122(9):657–65. doi: 10.1002/cncy.21452.
36 Thomas SC, Davidson LRR, McKean ME. An investigation of adequate volume for the diagnosis of malignancy in pleural fluids. Cytopathology. 2011;22(3):179–83. https://doi.org/10.1111/j.1365-2303.2010.00786.x.
37 Deng J, Dong W, Socher R, Li LJ, Li K, Fei-Fei L. Imagenet: a large-scale hierarchical image database. 2009 IEEE conference on computer vision and pattern recognition. IEEE; 2009. p. 248–55.
38 Chollet, Francois and others. Keras applications. 2015. https://keras.io/api/applications.
39 Kratz A, Lee SH, Zini G, Riedl JA, Hur M, Machin S; International Council for Standardization in Haematology. Digital morphology analyzers in hematology: ICSH review and recommendations. Int J Lab Hematol. 2019;41(4):437–47. doi: 10.1111/ijlh.13042.
40 Dey P. Routine staining in cytology laboratory. Basic and advanced laboratory techniques in histopathology and cytology; 2018; p. 133–8.
41 Jörundsson E, Lumsden JH, Jacobs RM. Rapid staining techniques in cytopathology: a review and comparison of modified protocols for hematoxylin and eosin, Papanicolaou and Romanowsky stains. Vet Clin Pathol. 1999; 28(3):100–8. doi: 10.1111/j.1939-165x.1999.tb01057.x.
42 Morrison LE, Lefever MR, Lewis HN, Kapadia MJ, Bauer DR. Conventional histological and cytological staining with simultaneous immunohistochemistry enabled by invisible chromogens. Lab Invest. 2022; 102(5):545–53. doi: 10.1038/s41374-021-00714-2.
43 Hua HY, Wei CY, Mantoo S. Reviving the faded pap stained slides–experience with use of optical clearing agent. Pathology. 2017;49: S77–8. doi: 10.1016/j.pathol.2016.12.203.
44 Dadhich H, Toi PC, Siddaraju N, Sevvanthi K. A comparative analysis of conventional cytopreparatory and liquid based cytological techniques (Sure Path) in evaluation of serous effusion fluids. Diagn Cytopathol. 2016; 44(11):874–9. doi: 10.1002/dc.23567.
45 Baykus N, Özekinci S, Erdem ZB, Vurgun E, Yildiz FR. Comparison of morphological similarities and differences between liquid-based cytology and conventional techniques of serous effusion cytology specimens. Acta Cytol. 2022;66(2):159–64. doi: 10.1159/000521052.
46 Gonzalez RC, Woods RE. Digital image processing essay: Pearson; 2019.
47 Teramoto A, Tsukamoto T, Kiriyama Y, Fujita H. Automated classification of lung cancer types from cytological images using deep convolutional neural networks. BioMed Res Int. 2017;2017:4067832. doi: 10.1155/2017/4067832.
48 Luke JJ, Joseph R, Balaji M. Impact of image size on accuracy and generalization of convolutional neural networks. Int J Res Anal Rev.(IJRAR). 2019;6(1):70–80.
49 Gall J, Razavi N, Van Gool L. An introduction to random forests for multi-class object detection. Outdoor and large-scale real-world scene analysis: 15th International Workshop on Theoretical Foundations of Computer Vision, Dagstuhl Castle, Germany, June 26-July 1, 2011. Revised selected papers. Berlin Heidelberg: Springer; 2012. p. 243–63.

Downloaded from http://karger.com/acy/article-pdf/68/2/160/4230269/000538465.pdf by Zhejiang University user on 06 July 2024

50 Khatami A, Araghi S, Babaei T. Evaluating the performance of different classification methods on medical X-ray images. SN Appl Sci. 2019;1(10):1154–7. doi: 10.1007/s42452-019-1174-0.
51 Breiman L. Random forests. Mach Learn. 2001; 45(1):5–32. doi: 10.1023/a:1010933404324.
52 Baykal E, Dogan H, Ercin ME, Ersoz S, Ekinci M. Transfer learning with pre-trained deep convolutional neural networks for serous cell classification. Multimed Tools Appl. 2020;79(21–22): 15593–611. doi: 10.1007/s11042-019-07821-9.
53 Khozeimeh F, Sharifrazi D, Izadi NH, Joloudari JH, Shoeibi A, Alizadehsani R, et al. RF-CNN-F: random forest with convolutional neural network features for coronary artery disease diagnosis based on cardiac magnetic resonance. Sci Rep. 2022;12(1): 11178. doi: 10.1038/s41598-022-15374-5.

Downloaded from http://karger.com/acy/article-pdf/68/2/160/4230269/000538465.pdf by Zhejiang University user on 06 July 2024