formed partly by the base of the coracoid process. This notch is converted into a foramen by the superior transverse ligament, and serves for the passage of the suprascapular nerve; sometimes the ligament is ossified. The adjacent part of the superior border affords attachment to the Omohyoideus. The **axillary border**

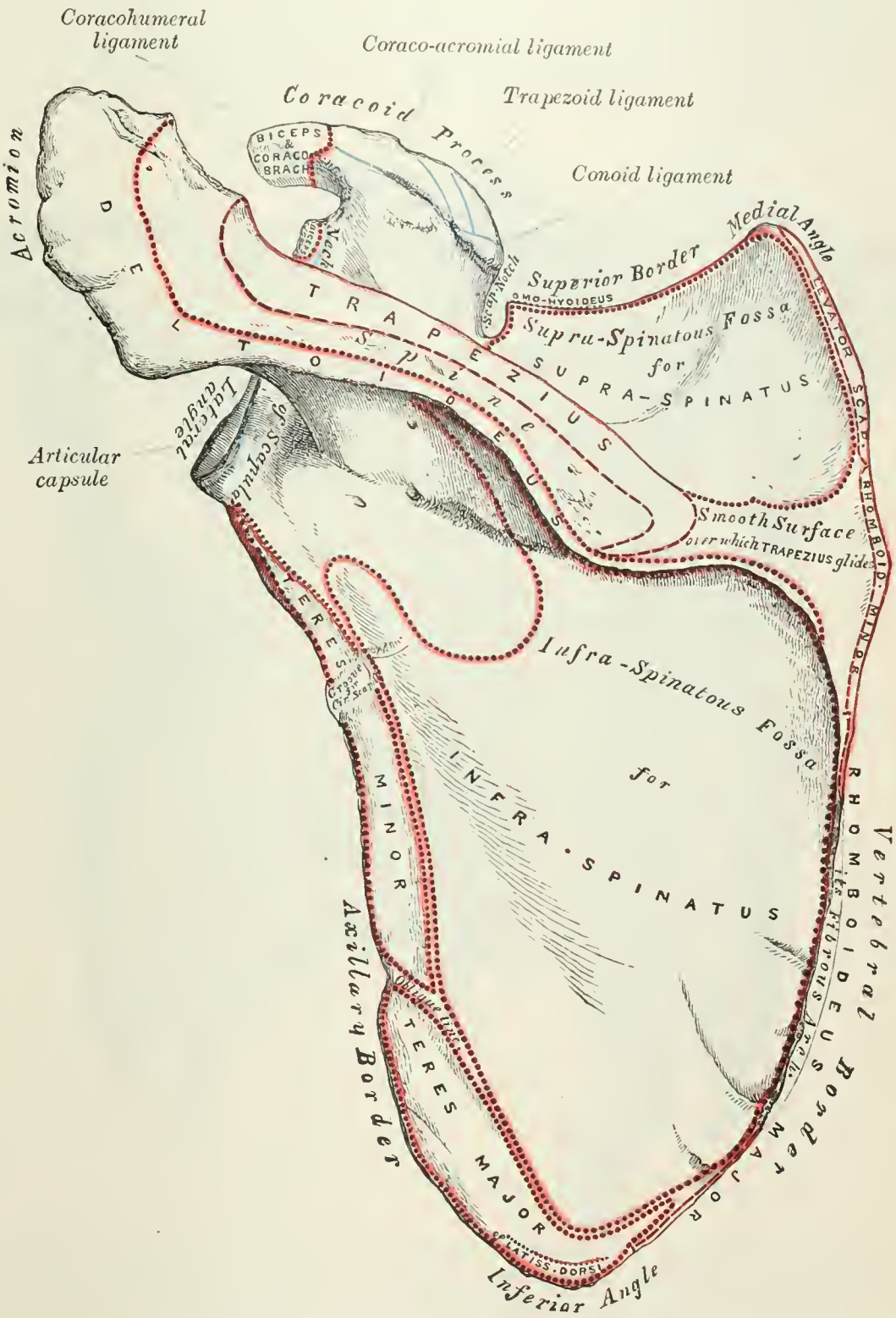

Fig. 203.—Left scapula. Dorsal surface.

is the thickest of the three. It begins above at the lower margin of the glenoid cavity, and inclines obliquely downward and backward to the inferior angle. Immediately below the glenoid cavity is a rough impression, the **infraglenoid tuberosity**, about 2.5 cm. in length, which gives origin to the long head of the Triceps brachii; in front of this is a longitudinal groove, which extends as far as the