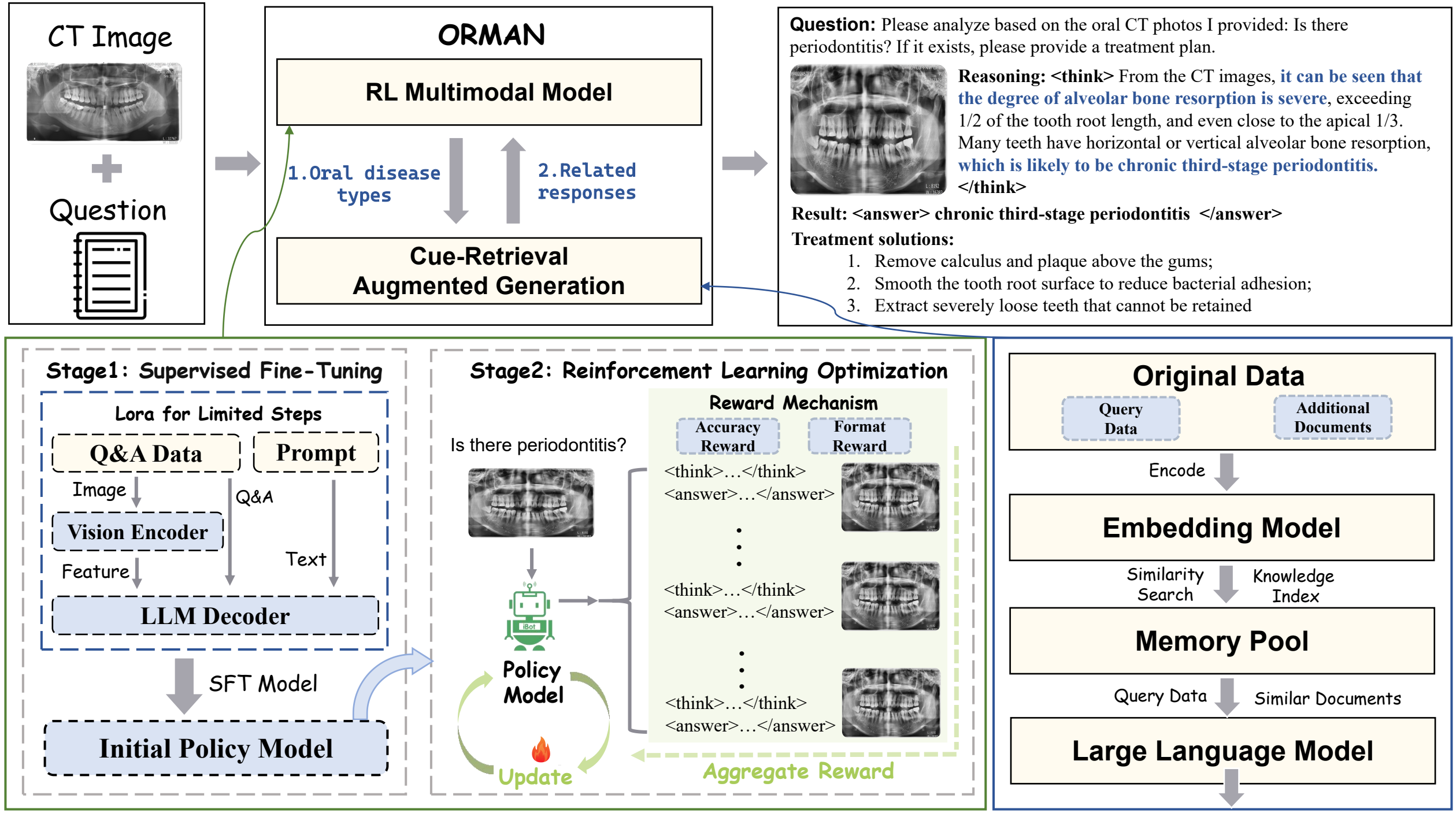
CT Image
Question
ORMAN
RL Multimodal Model
1.Oral disease types
2.Related responses
Cue-Retrieval Augmented Generation
Question: Please analyze based on the oral CT photos I provided: Is there periodontitis? If it exists, please provide a treatment plan.
Reasoning: <think> From the CT images, it can be seen that the degree of alveolar bone resorption is severe, exceeding 1/2 of the tooth root length, and even close to the apical 1/3. Many teeth have horizontal or vertical alveolar bone resorption, which is likely to be chronic third-stage periodontitis. </think>
Result: <answer> chronic third-stage periodontitis </answer>
Treatment solutions:
1. Remove calculus and plaque above the gums;
2. Smooth the tooth root surface to reduce bacterial adhesion;
3. Extract severely loose teeth that cannot be retained
Stage1: Supervised Fine-Tuning
Lora for Limited Steps
Q&A Data
Prompt
Image
Q&A
Vision Encoder
Text
Feature
LLM Decoder
SFT Model
Initial Policy Model
Stage2: Reinforcement Learning Optimization
Reward Mechanism
Accuracy Reward
Format Reward
Is there periodontitis?
<think>…</think>
<answer>…</answer>
Policy Model
Update
Aggregate Reward
Original Data
Query Data
Additional Documents
Encode
Embedding Model
Similarity Search
Knowledge Index
Memory Pool
Query Data
Similar Documents
Large Language Model