a.

GastroAgent Overall Pipeline

Input & Tasks

Real-world Medical Data

Multiple and Single Image Conversarion

Long-tail Disease

Open-world General and Medical Data

LLaVA-COT

LLaVA-Med

GastroAgent

GastroMLLM

Wasserstein GastroFlow

step$_1$—step$_n$

Modal Recognition

Anatomy Identification

Disease Diagnosis

Long-tail Disease Diagnosis

Processing Core

Input
Endoscopic Image(x) Question (q) Candidate Set (c)

MLLM Path

GastroMLLM → Logits/Probabilities P_{MLLM} → Entropy Calculator H_{norm}

H_{norm}

P_{MLLM}

Adaptive Weight Controller

Weight α

Weight $1-\alpha$

Logit Fusion $(\sum)$

Final Prediction

$$P_{\text{final}} = \alpha \cdot P_{\text{MLLM}} + (1-\alpha) \cdot P_{\text{Flow}}$$

Few-shot Path

Wasserstein GastroFlow → Distances → Probability Converter → Probabilities P_{Flow}

MLLM Reasoning & Decision

GastroMLLM

In the provided image, there is no clear indication of any malfunctioning, congestion, enlargement, or any other abnormality of the pylorus. The image appears to <answer>C: normal pylorus</answer>

Extract Answer option → C: normal pylorus

Few-shot Learning Framework

Wasserstein GastroFlow

step$_1$—step$_n$

Wasserstein Distance

Retrieve Reference Image

Query Image

Distance Matching

Disease Label: Ulcerative colitis

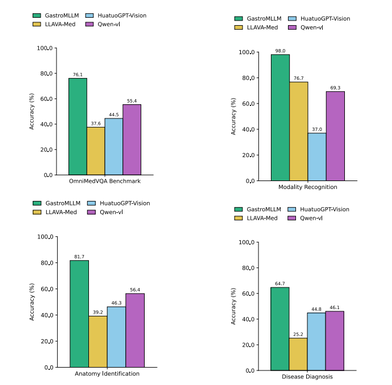

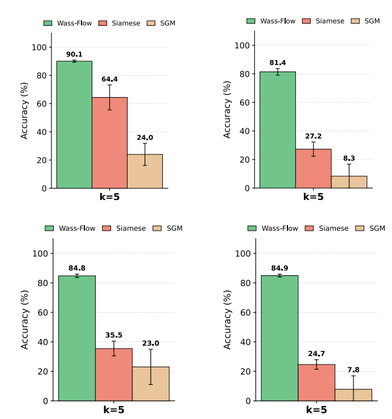

b.

Benchmarking diagnostic generalization in real-world Datasets

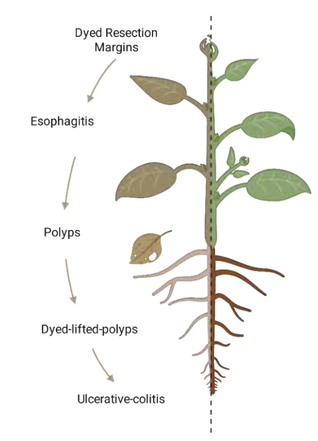

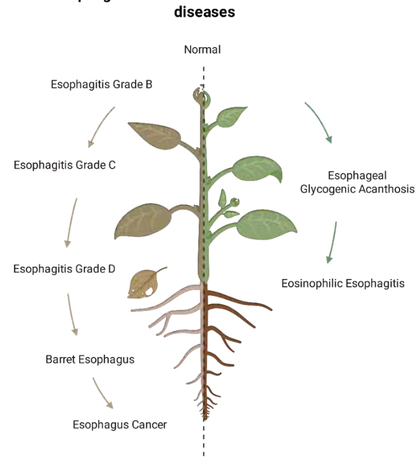

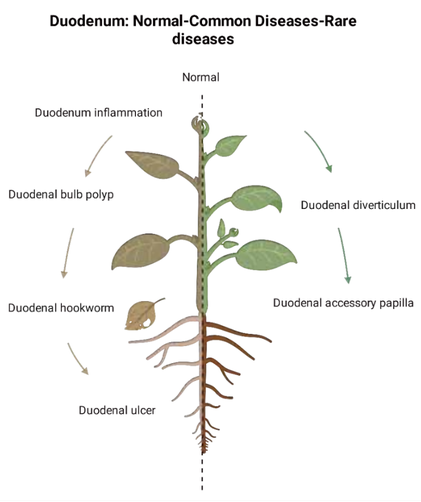

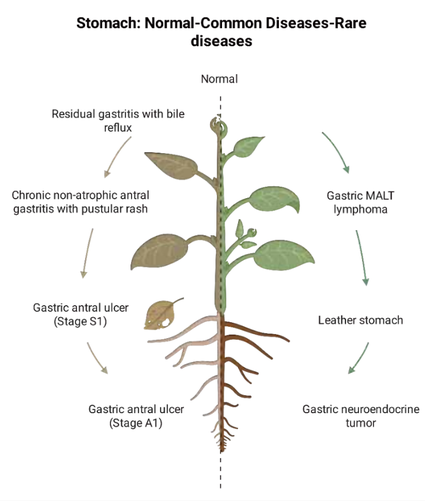

c.

Clinical Assessment: AI vs. Human Experts

GastroAgent's Performance Against Medical Professionals across Multiple Regions & Cases

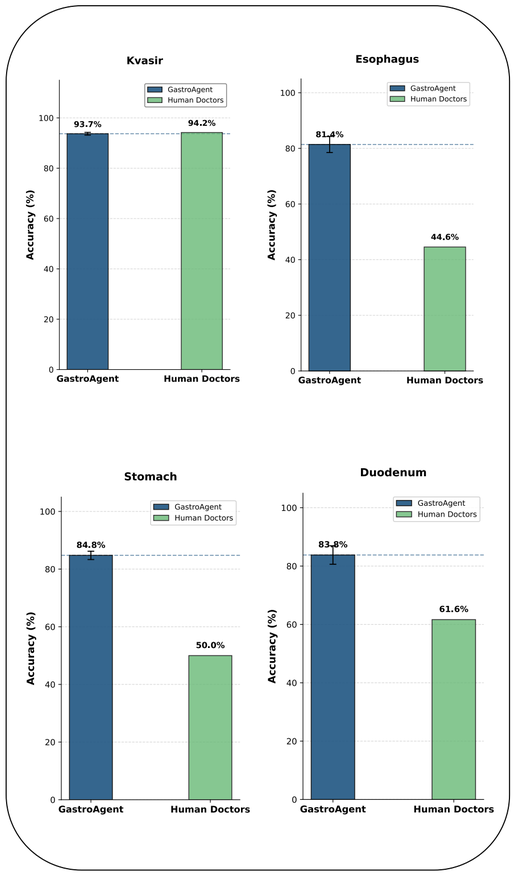

Eosinophilic esophagitis

✅ **AI(GastroAgent):** Correct Diagnosis
❌ **Human Experts(6 Human Doctors):** Wrong Diagnosis

Gastric neuroendocrine tumors

✅ **AI(GastroAgent):** Correct Diagnosis
❌ **Human Experts(6 Human Doctors):** Wrong Diagnosis

Duodenal accessory papilla

✅ **AI(GastroAgent):** Correct Diagnosis
❌ **Human Experts(5 Human Doctors):** Wrong Diagnosis