Can You Have Normal Testosterone and Still Have Androgen-Sensitive Hair Loss?

The short answer is yes — and understanding why requires looking beyond a single blood test result. Hair loss can be androgen-sensitive even when testosterone levels appear entirely normal on routine laboratory panels. This is one of the most common sources of confusion for patients and, at times, for clinicians as well. A reassuring lab value can create a false sense of certainty, delaying diagnosis and early intervention.

This document explains why serum testosterone is an incomplete picture, why the pattern and timing of hair loss carry significant diagnostic weight, and what a more thorough assessment looks like. It is written for both patients who want to understand what is happening and for clinicians who want a clear, accessible summary to share.

Why Normal Testosterone Does Not Rule It Out

When patients receive a blood test result showing testosterone within the normal reference range, it is natural to conclude that hormones are not involved in their hair loss. This conclusion, while understandable, misses a critical dimension of hair follicle biology. The relationship between androgens and hair follicles is not simply about how much testosterone is circulating in the bloodstream — it is about how sensitive individual follicles are to androgen signaling, regardless of the circulating level.

Hair follicles express androgen receptors, and the density and sensitivity of those receptors varies considerably between individuals and between different regions of the scalp. A follicle with a high density of androgen receptors in the frontal or crown region can respond robustly to androgen stimulation even when serum testosterone sits comfortably within the normal range. This local sensitivity is genetically determined and is not captured by a standard blood panel.

Additionally, serum testosterone represents only one point in a complex hormonal cascade. Testosterone is converted locally within the follicle by the enzyme 5-alpha reductase into dihydrotestosterone (DHT), which binds to androgen receptors with significantly greater affinity than testosterone itself. The efficiency of this local conversion — not merely the starting testosterone level — is what determines the androgenic signal reaching the follicle. A person with normal total testosterone can still generate elevated local DHT within scalp follicles, particularly in genetically susceptible regions.

> ⓘ Blood tests reflect what is circulating systemically. They do not directly measure what is happening at the follicle level — which is where androgen sensitivity actually resides.

There is also the matter of free versus bound testosterone. Total testosterone includes testosterone that is bound to sex hormone-binding globulin (SHBG) and albumin, and is largely biologically inactive. Free testosterone — the unbound fraction — is what tissues can actually use. Two patients with identical total testosterone readings can have meaningfully different levels of bioavailable hormone depending on their SHBG concentrations. Standard panels that report only total testosterone may miss this distinction entirely.

Why Pattern Matters More Than One Number

Clinical pattern recognition is often the most reliable diagnostic tool available for androgen-sensitive hair loss — more informative, in many cases, than a single laboratory value. The location, shape, and progression of thinning across the scalp convey information that serum results cannot. Clinicians trained in trichology and dermatology rely heavily on pattern assessment for this reason, and the major classification systems for hair loss are built around pattern, not around hormone levels.

In men, the Norwood-Hamilton scale describes a characteristic progression that begins at the temples and frontal hairline, advances across the crown, and can ultimately converge into a single broad area of thinning or baldness. This distribution is not random — it reflects the differential sensitivity of follicles in androgen-sensitive scalp regions compared with the occipital and parietal areas, which tend to remain stable. When this pattern is present, it constitutes strong clinical evidence of androgenetic alopecia regardless of what the testosterone result shows.

In women, the Ludwig scale captures a different but equally recognizable pattern: diffuse thinning that tends to be most prominent at the crown and central parting, with relative preservation of the frontal hairline. Women may also show patterns that overlap with the male type, particularly in cases where androgen exposure is higher. The key point is that these patterns are diagnostically meaningful in their own right. A normal hormone panel does not negate a pattern that is clinically convincing.

Frontal Hairline Recession

A hallmark of male-pattern androgenetic alopecia, often appearing first at the temples and progressing centrally.

Crown and Vertex Thinning

Progressive miniaturization at the top of the scalp, seen in both men and women with androgen-sensitive follicles.

Diffuse Central Thinning

The hallmark female pattern: a widening central parting with preservation of the frontal hairline and density loss behind it.

Follicular Miniaturization

Under dermoscopy, progressively smaller, thinner hair shafts replace terminal hairs — a direct sign of androgenic signaling.

Dermoscopy adds another layer of precision. Under magnification, androgen-sensitive follicles show a characteristic progression of miniaturization — terminal hairs are gradually replaced by shorter, finer, depigmented vellus hairs. This finding, visible at the scalp surface with a handheld dermoscope, provides direct evidence of the androgenic process occurring at the follicular level. It can be present even when all standard blood tests return within normal limits.

How This Misunderstanding Delays Appropriate Action

The assumption that a normal testosterone result means hormones are irrelevant to hair loss is one of the most consequential misconceptions in this field. It delays diagnosis, delays treatment, and — perhaps most significantly — allows a progressive condition to advance during a window when early intervention could have preserved more hair density and follicular health.

Hair follicles do not regenerate once they are lost. The miniaturization process in androgenetic alopecia is gradual and, for a period, reversible or at least interruptible. Follicles in the early miniaturization phase can often respond to appropriate treatment. Follicles that have been miniaturized for years, or that have been replaced entirely by fibrous tissue, are considerably harder to recover. Every year of diagnostic delay is a year of follicular loss that cannot be undone.

When a patient receives a normal testosterone result and is told — explicitly or implicitly — that hormones are not a concern, they may disengage from further investigation. They may attribute their hair loss to stress, nutritional factors, or inevitable aging, and choose not to pursue pattern-specific treatment. In some cases, clinicians who are unfamiliar with follicular biology may reinforce this interpretation. The result is a missed window for early and effective management.

> A reassuring lab value can feel like a clean bill of health. In the context of androgen-sensitive hair loss, it is more accurately understood as one incomplete data point in a clinical picture that requires broader evaluation.

This is not a criticism of laboratory testing — blood panels serve important purposes in the workup. The problem arises when a single normal result is treated as the final word rather than as one piece of a diagnostic puzzle. A thorough clinician uses the blood test to inform the picture, not to replace pattern examination, family history, timing, and scalp assessment.

Men and Women Can Both Be Affected

Androgen-sensitive hair loss is frequently discussed in the context of men, and male-pattern baldness is widely recognized in popular culture. What is less well understood is that the same underlying biology affects women as well — sometimes with equally significant impact on density and appearance, and often without obvious hormonal abnormalities on routine blood tests.

Female androgenetic alopecia is more common than many patients and primary care clinicians appreciate. It is estimated to affect a substantial proportion of women, with prevalence increasing after menopause. The presentation typically differs from the male pattern — the dramatic receding hairline and vertex baldness seen in men are less common in women — but the underlying mechanism, follicular sensitivity to androgens, is shared. Women affected by this condition often report that their hair has gradually become thinner overall, that the parting appears wider, or that the scalp is more visible than it used to be.

Crucially, women with female-pattern hair loss often do not have dramatically elevated androgens on routine panels. Total testosterone, DHEA-S, and free androgen index may all fall within laboratory reference ranges. This does not mean androgens are not involved — it means that the follicles are responding to circulating androgen levels that are entirely normal for a woman, but are sufficient to drive miniaturization in those who are genetically predisposed. The follicular sensitivity, not the hormone level, is the governing factor.

Women Without Obvious Hormonal Abnormalities

Many women with androgenetic alopecia have entirely normal androgen panels. The diagnosis rests on pattern recognition and family history, not on an elevated hormone result.

Post-Menopausal Presentation

Declining estrogen after menopause shifts the androgen-estrogen balance, often unmasking or accelerating androgen-sensitive hair thinning in genetically susceptible women.

Overlap With PCOS and Hyperandrogenism

Some women do have elevated androgens — as in polycystic ovary syndrome — and these cases warrant a more thorough endocrine workup. But many do not, and their diagnosis remains clinically valid regardless.

There is a subset of women in whom a more thorough endocrine evaluation is clearly warranted — those with signs of hyperandrogenism such as hirsutism, acne, menstrual irregularity, or rapid-onset hair loss. In these cases, polycystic ovary syndrome, adrenal disorders, or other endocrine conditions should be actively investigated. However, the absence of these features does not eliminate androgenetic alopecia from the differential diagnosis. A woman with gradual, pattern-consistent thinning and a family history of hair loss can carry a confident clinical diagnosis without an abnormal lab value.

What a Better Assessment Looks Like

A thorough evaluation for androgen-sensitive hair loss moves beyond the serum testosterone result and integrates several complementary sources of information. No single component gives the complete picture; the strength of the assessment comes from combining them thoughtfully. The following framework reflects the approach that is most likely to yield a clinically useful and actionable conclusion.

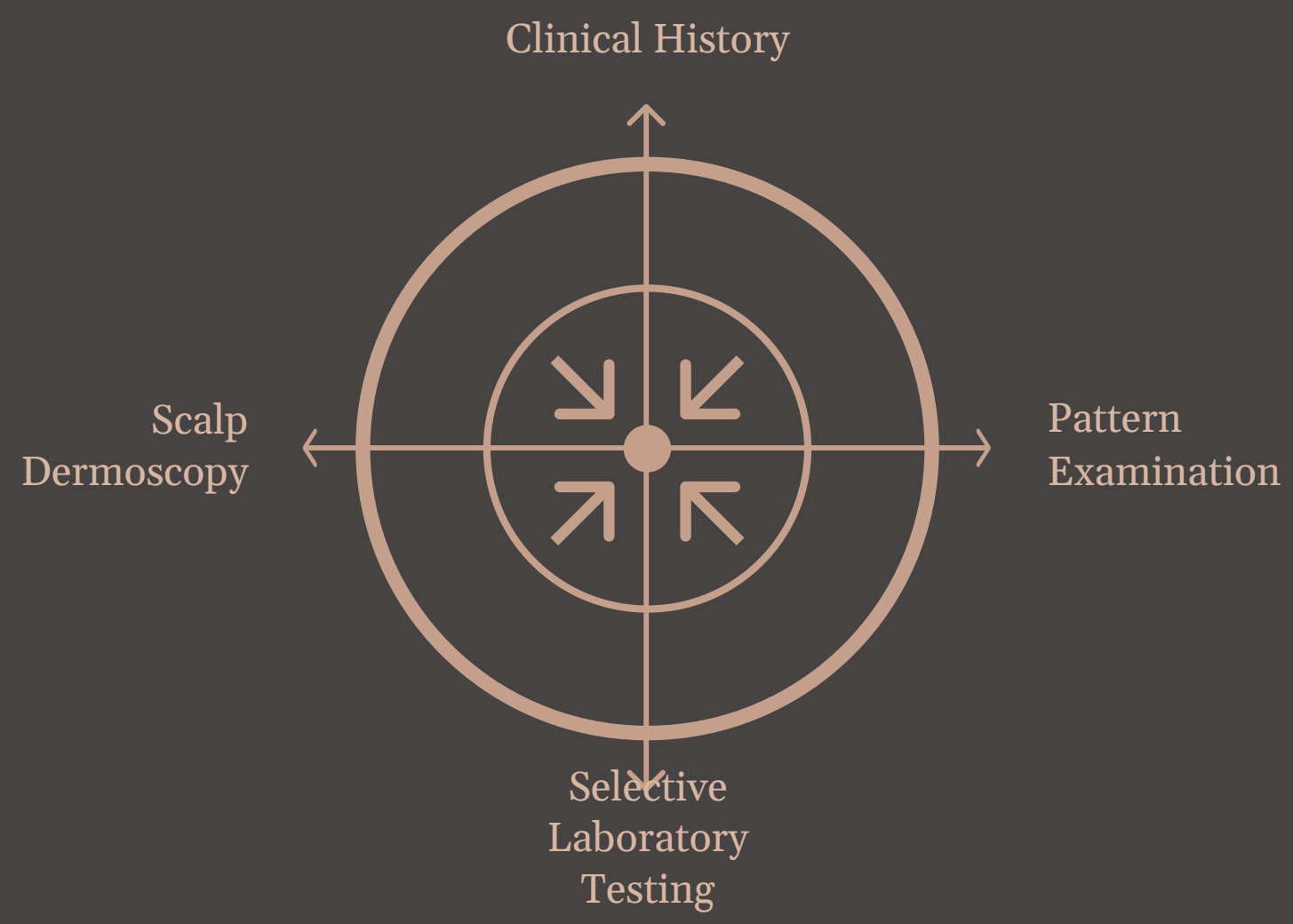

The clinical history is the foundation. A detailed history should capture when the hair loss began, how rapidly it has progressed, whether it is diffuse or localized, whether there has been a triggering event such as illness, surgery, significant weight loss, or emotional stress, and what the family history looks like on both maternal and paternal sides. Timing matters: gradual, progressive thinning over years suggests androgenetic alopecia, while acute, dramatic shedding is more consistent with telogen effluvium, which has different drivers and a different management pathway.

Pattern-based physical examination follows. A skilled examiner assesses the distribution of thinning across the scalp, notes the texture and caliber of remaining hairs, identifies areas of density loss and relative preservation, and looks for signs of scalp inflammation or scarring that might suggest a different diagnosis. The hairline, crown, temples, and occipital region are all assessed. This examination, combined with the history, often generates a confident working diagnosis without requiring any laboratory input at all.

Selective laboratory testing is ordered where it adds meaningful value — not reflexively in every case. In men with a classic pattern presentation and a strong family history, extensive hormonal testing may not change the management plan. In women, in cases of rapid progression, or when signs of hyperandrogenism are present, a targeted panel is appropriate: total and free testosterone, SHBG, DHEA-S, prolactin, thyroid function, and iron studies (ferritin in particular) are commonly included. The choice of tests should be guided by clinical reasoning, not by protocol.

Dermoscopy — the use of a dermatoscope to examine the scalp at magnification — adds precision to the examination. The presence of hair shaft diameter variability greater than 20%, the appearance of vellus or miniaturized hairs in characteristically sensitive regions, perifollicular discoloration, and yellow dots are all dermoscopic features associated with androgenetic alopecia. This tool bridges the gap between clinical impression and histological confirmation in many cases.

The Role of DHT: The Androgen That Actually Drives Follicle Miniaturization

To understand why testosterone alone is an incomplete measure, it helps to understand the biochemical pathway that actually drives androgen-sensitive hair loss. The key molecule is not testosterone itself — it is dihydrotestosterone, or DHT, a more potent androgen produced locally within hair follicles through the action of the enzyme 5-alpha reductase.

DHT binds to androgen receptors within the dermal papilla cells of the hair follicle with an affinity approximately five times greater than testosterone. Once bound, it alters the signaling environment of the follicle, progressively shortening the anagen (growth) phase of the hair cycle and prolonging the telogen (resting) phase. Over successive cycles, the follicle produces shorter, finer, less pigmented hairs — a process called miniaturization. Eventually, if the process continues unchecked, the follicle may cease producing a cosmetically visible hair altogether.

Testosterone → DHT Conversion

5-alpha reductase (types I and II) converts testosterone to DHT within the follicle. Type II predominates in scalp follicles and is the primary target of medications like finasteride and dutasteride.

Why Serum DHT Isn't Always Tested

Serum DHT measurement is not routinely ordered because intrafollicular DHT levels — the relevant figure — are not captured by a blood draw. Scalp biopsy or indirect evidence (the pattern itself) is often more informative than serum DHT.

Two isoforms of 5-alpha reductase exist: type I and type II. Type II is the predominant form in scalp follicles and is the primary target of pharmacological intervention. Finasteride, the most widely used oral treatment for androgenetic alopecia in men, is a selective type II 5-alpha reductase inhibitor. Dutasteride inhibits both types and achieves a greater reduction in scalp DHT. The efficacy of these agents — which do not dramatically alter serum testosterone — further illustrates that it is the local DHT environment, not circulating testosterone, that governs the androgenic process at the follicle.

It is worth noting that serum DHT can be measured, and in some clinical contexts it is informative. However, because the relevant androgenic activity occurs within the follicle itself, serum DHT does not always accurately reflect local conditions. A patient with normal serum DHT can still have high local DHT activity within scalp follicles, particularly if they have efficient 5-alpha reductase activity or highly sensitive androgen receptors in those follicles. The clinical pattern, again, often tells the story more clearly than the number on the lab report.

Frequently Asked Questions

The following questions reflect common points of confusion raised by patients seeking to understand androgen-sensitive hair loss. Each answer is grounded in current understanding of follicular biology and clinical practice.

1

Can you lose hair with normal testosterone?

Yes — this is one of the most important things to understand about androgenetic alopecia. Hair follicle sensitivity to androgens is genetically determined and does not require elevated serum testosterone. Normal testosterone can still drive follicle miniaturization in a person with sensitive follicles, particularly through local conversion to DHT.

2

Do normal hormone results rule out androgen sensitivity?

No. A normal hormone panel reduces the probability of certain endocrine disorders, but it does not rule out androgenetic alopecia. The diagnosis is primarily clinical, based on pattern and history. Many patients with confirmed androgenetic alopecia — including those who respond well to androgen-blocking treatments — have entirely normal baseline hormone results.

3

Is DHT measured in every case?

Not routinely. Serum DHT is not a standard component of hair loss workups in most clinical settings. This is partly because serum levels do not always reflect intrafollicular activity, and partly because the clinical diagnosis can usually be established without it. DHT measurement may be included in more detailed endocrine evaluations, particularly where treatment monitoring is relevant.

4

Why do pattern and timing matter so much?

Because they are direct clinical evidence of the biological process occurring at the scalp. A characteristic pattern of thinning — in the right distribution, progressing in the right direction, in a person with a positive family history — is strong evidence of androgenetic alopecia independent of any laboratory finding. Timing helps distinguish androgenetic alopecia from other causes of hair loss that may require different management.

If you are unsure whether your hair loss fits a recognizable pattern, a consultation with a dermatologist or trichologist who performs scalp dermoscopy is the most direct path to a clear answer.

Key Takeaways for Patients and Clinicians

For anyone navigating androgen-sensitive hair loss — whether as a patient seeking answers or as a clinician building a management plan — a few core principles help clarify the path forward. These takeaways distill the essential points of this document into actionable guidance.

A normal testosterone result is not the final word

Serum testosterone reflects systemic circulating levels, not follicular sensitivity. Do not allow a reassuring lab result to foreclose further evaluation if the clinical picture — pattern, timing, family history — is consistent with androgenetic alopecia.

The pattern is diagnostic information in its own right

A characteristic distribution of hair loss, confirmed by physical examination and ideally supported by dermoscopy, constitutes strong clinical evidence. Pattern-based diagnosis is validated by decades of clinical and histological research.

Early intervention preserves more options

Androgen-sensitive hair loss is progressive. Follicles in early miniaturization respond better to treatment than follicles that have been miniaturizing for years. The diagnostic workup should be timely, not deferred because the lab result looks normal.

Women are affected too — often without obvious hormonal abnormalities

Female androgenetic alopecia is common and frequently presents with normal androgen panels. A woman with a convincing clinical pattern does not require an abnormal hormone result to receive an appropriate diagnosis and management plan.

A broad view produces better outcomes

The best assessments integrate history, pattern examination, selective laboratory testing, and scalp dermoscopy. Each element contributes something the others cannot provide. Relying on any single component — especially a single number — risks missing the diagnosis.

Recommended Further Reading

The topics covered in this document connect to a broader body of information about androgen biology, hair follicle physiology, and the clinical management of hair loss. The following guides are recommended as logical next steps depending on your specific questions and situation.



The Androgen Guide

A comprehensive overview of how androgens work, how they are measured, and how they interact with hair follicles across different individuals. Essential reading for anyone who wants to understand the hormonal landscape of hair loss beyond the basics covered here.

Diffuse Thinning in Women

A detailed exploration of the causes and clinical presentations of diffuse hair thinning in women — including androgenetic alopecia, telogen effluvium, and nutritional factors. Covers the diagnostic approach specific to women, including when a more thorough endocrine workup is appropriate.

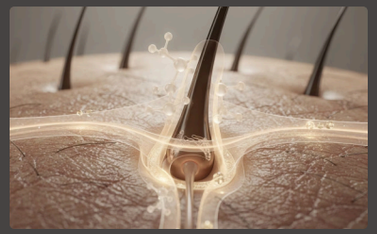

DHT and Androgenetic Alopecia

A focused guide on dihydrotestosterone — its production, its role in follicle miniaturization, the evidence base for DHT-blocking treatments, and what to expect from pharmacological intervention. Particularly useful for patients considering or already using finasteride or dutasteride.

Understanding the biology behind your hair loss is the first step toward making informed decisions about management. A well-informed patient — one who understands why a normal testosterone result does not close the diagnostic question — is better positioned to advocate for a thorough evaluation and timely, appropriate care.