Final Grade
Last attempt with a grade 20 / 20

ATTEMPT 11/11 (SUBMITTED 12/29/25, 12:43 AM)
RECEIPT: CP-1A6GC2WEAC5E9AFNAFI4ASEAAC5C

20 / 20

1 MULTIPLE CHOICE 1 / 1

Giannuzzi demilunes are typical for:

- (A) mixed acini
- (B) serous acini
- (C) mucous acini
- (D) intraepithelial glands
- (E) endocrine glands

2 MULTIPLE CHOICE 1 / 1

Which of the following cells is NOT localized in connective tissue?

- (A) none is correct
- (B) macrophages
- (C) eosinophilic leucocytes
- (D) plasma cells
- (E) fibroblasts

3 MULTIPLE CHOICE 1 / 1

Which of the following statements regarding conductive cardiomyocytes is NOT correct?

- (A) They are smaller than contractile cardiomyocytes
- (B) They are bigger than contractile cardiomyocytes
- (C) They are stained lighter in HE stain than contractile cardiomyocytes
- (D) They have fewer contractile fibrils compared to contractile cardiomyocytes
- (E) Their plasmalemma does not form a T-system

4 MULTIPLE CHOICE 1 / 1

Neurons with typical pyramid shape soma are the:

- (A) Giant cells of Betz
- (B) Spinal cord motor neurons
- (C) Purkinje cells
- (D) Martinotti cells
- (E) Granule cells

5 MULTIPLE CHOICE 0 / 1

What is the shape of the nucleus of a neutrophilic myelocyte?

- (A) kidney-shaped
- (B) flat
- (C) serrated
- (D) with many segments
- (E) none of above

6 MULTIPLE CHOICE 1 / 1

Which component of the axon may contain Nissl's granulations?

- (A) The axonal hillock
- (B) The initial axonal segment
- (C) The axonal terminal
- (D) All of the listed
- (E) None of the listed

7 MULTIPLE CHOICE 1 / 1

What are the main types of lymphocytes?

- (A) "NK-cells, T-lymphocytes, B-lymphocytes"
- (B) "T-lymphocytes, B-lymphocytes"
- (C) "NK-cells, B-lymphocytes"
- (D) "NK-cells, T-lymphocytes"
- (E) memory cells and lymphocytes

8 MULTIPLE CHOICE 1 / 1

What is the name of the outer layer of the blastocyst?

- (A) Trophoblast
- (B) Ембриобласт
- (C) Epiblast
- (D) Hypoblast
- (E) Gamete

9 MULTIPLE CHOICE 1 / 1

The intraembryonic intermediate mesoderm forms:

- (A) Gonads
- (B) Skeletal muscles
- (C) Dermis (skin)
- (D) Lungs
- (E) Cardiomyocytes

10 MULTIPLE CHOICE 1 / 1

Which of the processes listed is NOT a stage of the fertilization?

- (A) Acrosomal reaction
- (B) Cortical reaction
- (C) Gametes' mebranes fusion
- (D) Capacitation
- (E) Gastrulation

11 MULTIPLE CHOICE 1 / 1

Gastrulation begins with formation of:

- (A) Primitive streak
- (B) Notochord
- (C) Hypoblast
- (D) Trophoblast
- (E) Neural tube

12 MULTIPLE CHOICE 1 / 1

The amniotic cavity is formed by cells of the:

- (A) Epiblast
- (B) Hypoblast
- (C) Extraembryonic mesoderm
- (D) Cytotrophoblast
- (E) Syncytiotrophoblast

13 MULTIPLE CHOICE 1 / 1

On which developmental day is the closure of the posterior neuropore of the neural tube?

- (A) Day 27
- (B) Day 20
- (C) Day 24
- (D) Day 30
- (E) Day 33

14 MULTIPLE CHOICE 1 / 1

Primary villi result from the proliferation of:

- (A) Cytotrophoblast
- (B) Syncytiotrophoblast
- (C) Epiblast
- (D) Hypoblast
- (E) None of the answers is true

15 JUMBLED SENTENCE 5 / 5

Match the listed descriptions to the corresponding tissues from the drop-down menu:
1/ It is characterized by a close cell apposition and presence at a free surface. => **epithelial tissue**
2/ It allows rapid response to external stimuli. => **nerve tissue**
3/ It is composed of cells called chondrocytes and a highly specialized ECM. => **cartilaginous tissue**
4/ It contains large amounts of contractile proteins. => **muscle tissue**
5/ It is characterized by a mineralized ECM. => **bone tissue**

16 MULTIPLE CHOICE 1 / 1

Plasmalemmal proteins originate from which of the listed organelles:

- (A) Rough ER
- (B) Smooth ER
- (C) Golgi
- (D) Lysosome
- (E) Peroxisome

17 MULTIPLE CHOICE 1 / 1

What type of cell junction is the desmosome:

- (A) Cell-cell
- (B) Cell-matrix
- (C) Both cell-cell and cell-matrix
- (D) Neither cell-cell nor cell-matrix

18 MULTIPLE CHOICE 1 / 1

Which cytoskeleton is associated with the desmosome:

- (A) Intermediate filament
- (B) Actin filament
- (C) Microtubule
- (D) All of them
- (E) None of them

19 MULTIPLE CHOICE 1 / 1

Which of the following cytoskeletal elements is important for the nucleus:

- (A) Intermediate filaments
- (B) Actin filaments
- (C) Microtubules
- (D) All are important
- (E) None are important

20 MULTIPLE CHOICE 1 / 1

The structures depicted by arrows are cisterna of:

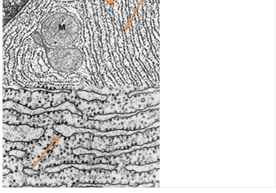

(A) Nucleus

(B) Smooth endoplasmic reticulum

(C) Mitochondrion

(D) Rough endoplasmic reticulum

21 **MULTIPLE CHOICE** 1 / 1

Which cytoskeleton is associated with the focal adhesion:

(A) Actin filament

(B) Microtubule

(C) Intermediate filament

(D) All of them

(E) None of them

22 **MULTIPLE CHOICE** 1 / 1

Identify the indicated structures:

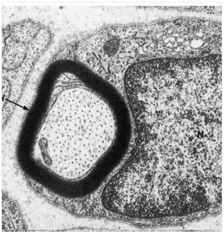

(A) Axon with a myelin sheath

(B) Unmyelinated nerve fibers with a Schwann's sheath

(C) Autophagolysosome

(D) Axodendritic synapse

23 **MULTIPLE CHOICE** 1 / 1

Identify the indicated cells:

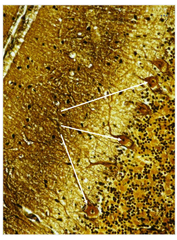

(A) Multipolar stellate cells from spinal cord.

(B) Fibrous astrocytes

(C) Multipolar piriform neurons from cerebellar cortex

(D) Pseudounipolar neurons from spinal ganglion.

24 **MULTIPLE CHOICE** 1 / 1

Identify the indicated tissue:

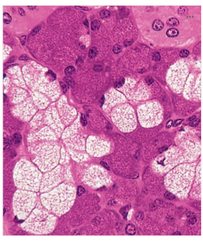

(A) Endocrine epithelium in the form of ovoid aggregates, fascicles and anastomosing cellular cordons

(B) Simple tubular mucous glands.

(C) Hyaline cartilage.

(D) Complex tubulo-acinous seromucous gland.

25 **MULTIPLE CHOICE** 1 / 1

Identify the indicated tissue:

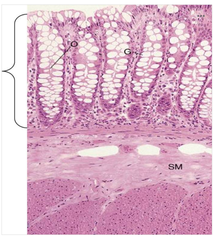

(A) Simple columnar epithelium with a brush border – small intestine

(B) Endocrine epithelium, organized in follicles – thyroid gland

(C) Squamous stratified nonkeratinized epithelium – esophagus

(D) Simple tubular mucous glands – large intestine

26 **MULTIPLE CHOICE** 1 / 1

Identify the indicated tissue:

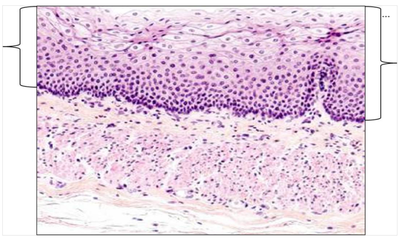

(A) Pseudostratified ciliated columnar epithelium

(B) Stratified squamous nonkeratinized epithelium

(C) Transitional (polymorph) epithelium

(D) Simple cuboidal (isoprismatic) epithelium