Final Grade
Last attempt was 1 year ago

ATTEMPT 05 (SUBMITTED 12/20/21, 1:55 PM) ▸
MODE: TRAINING/REVIEW

1 MULTIPLE CHOICE — CORRECT

What is the average lifespan of lymphocytes?

- Over 2 Decades or a few decades
- 24 days
- 10-12 hours
- 5-15 days
- 2-3 days

2 MULTIPLE CHOICE — 0/1

Which of the following glands is purely serous?

- pituitary gland
- parotid gland
- mammary gland
- adrenal/thyroid gland
- sublingual gland

3 MULTIPLE CHOICE — CORRECT

Which of the following statements regarding cardiomyocytes is NOT correct?

- They have a better developed endoplasmic reticulum than rhabdomyocytes
- Their mitochondria occupy a larger portion of their cell mass than in rhabdomyocytes
- They have a greater supply of glycogen than rhabdomyocytes
- They have a less developed endoplasmic reticulum than rhabdomyocytes
- They are multinucleated/ syncytial

4 MULTIPLE CHOICE — CORRECT

"Which one of the following cells is NOT part of the reticular connective tissue, located in the red bone marrow?"

- Neutrophil cells
- Reticulocytes
- Erythroblasts
- Lymphoblasts
- Hematopoietic stem cells

5 MULTIPLE CHOICE — CORRECT

From which embryonic layer originates the smooth muscle tissue?

- Mesenchyme
- Ectoderm
- There is no correct answer
- Endoderm
- Neuralate and endoderm

6 MULTIPLE CHOICE — CORRECT

Pneumatogs in the tissues are derived from which of the following blood cells?

- monocyte
- eosinophilic granulocytes
- neutrophilic granulocytes
- basophilic granulocytes
- RBC cells

7 MULTIPLE CHOICE — CORRECT

Which gland will participate in myelin formation in the PNS?

- Schwann cell
- Oligodendrocyte
- Ependymal cell
- Astrocytes-antitoxin
- Fibrous astrocyte

8 MULTIPLE CHOICE — CORRECT

All of the following statements regarding hematopoiesis are TRUE, EXCEPT:

- Hematopoiesis is a bone marrow, extra-medullary, and extra-vascular process
- Hematopoiesis occurs in three the other circulatory in the yolk sac
- The Extravascular hematopoiesis are rare in adult
- Stem cells in red bone marrow circulate in the veins
- The circulatory, scanned in rarity tissues are referred to as pluripotent

9 MULTIPLE CHOICE — CORRECT

Which cytoskeleton is associated with the hemidesmosome

- Intermediate filament
- Actin filament
- Microtubule
- All of them
- None of them

10 MULTIPLE CHOICE — CORRECT

Which of the following answers is TRUE?
A genetic defect in the Usher protein (USH1) is linked to which of the following disorders?

- Down syndrome
- Hutchinson- Gilford syndrome
- Waardenburg syndrome
- Marfan's syndrome
- Usher syndrome
- None of the answers is correct

11 MULTIPLE CHOICE — CORRECT

Which cytoskeleton is associated with the adherent junction

- Actin filament
- Microtubule
- Intermediate filament
- All of them
- None of them

12 MULTIPLE CHOICE — CORRECT

Fluorescent proteins originate from which of the listed organelles

- Rough ER
- Golgi
- Lysosome
- Peroxisome

13 MULTIPLE CHOICE — CORRECT

Lysosome are involved in all of the following EXCEPT:

- ER stress
- Endocytosis
- Vesicle formation
- Intracellular traffic
- Cell- cell's

14 MULTIPLE CHOICE — CORRECT

The second meiotic division during oogenesis begins:

- Before birth
- During birth
- During puberty
- At the time of ovulation
- None of the answers is true

15 MULTIPLE CHOICE — 0/1

How long after ejaculation is the maximum fertile time for most sperm?

- 3 hours
- 6 hours
- 12 hours
- 24 hours
- 24 hours

16 MULTIPLE CHOICE — CORRECT

What is the name of the outer layer of the blastocyst?

- trophoblast
- endoplasmic
- epiblast
- Hypoblast
- Gastrula

17 MULTIPLE CHOICE — CORRECT

Which of the ones pellucida proteins acts as a receptor for spermatozoa binding?

- gp1
- gp2
- gp3
- All listed proteins
- None of the listed proteins

18 MULTIPLE CHOICE — CORRECT

In which cavity are located the ovarian cysts during the second week of development?

- Trophoblastic lacunae
- Extra-embo yolk sac
- amnion
- Extra-embryonic coelo
- None of the answers is true

19 MULTIPLE CHOICE — CORRECT

Approximately how long after fertilization occurs the first cleavage of the zygote?

- 36 hours
- 48 hours
- 60 hours
- 80 hours
- 72 hours

20 MULTIPLE CHOICE — CORRECT

The amniotic cavity is formed by cells of the

- Epiblast
- Hypoblast
- Extraembryonic mesoderm
- Cytotrophoblast
- Syncytiotrophoblast

21 JUMBLED SENTENCE — CORRECT

Match the listed descriptors to the corresponding tissues from the drop down menu:
1) It is characterized by a close cell apposition and adhesion. These cells lay in **epithelial tissue**
2) It is composed of cells called chondrocytes and it is avascular. **Cartilaginous tissue**
3) It is composed of cells called chondroblasts and it highly vascularized CT. **Cartilaginous tissue**
4) It is composed of cells called osteoblasts and osteocytes. **Bone tissue**
5) It is characterized by a mineralized ECM. **Bone tissue**

22 MULTIPLE CHOICE — CORRECT

Identify the indicated structures:

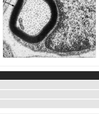

- Myelin sheath and axon cylinder
- Lymphocytes on a Blood cells (Lymphocyte) Smear
- Autophagolysosome
- Residential lymphocyte

23 MULTIPLE CHOICE — CORRECT

Identify the indicated cells



- Multipolar cholinergic cells from spinal cord
- Fibrous astrocytes
- Bipolar cellular neurons from vestibular cortex
- Pseudounipolar neurons from spinal ganglion

24 MULTIPLE CHOICE — CORRECT

Identify the indicated cells



- Multipolar cholinergic cells from spinal cord
- Fibrous astrocytes
- Multipolar pirifiform neurons from vestibular cortex
- Neuroglioglia

25 MULTIPLE CHOICE — CORRECT

Identify the indicated structures

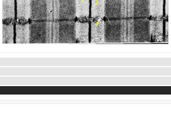

- Bilirubin of a sacromere
- Polycyclic membrane
- Free protein DNA
- Triad of sarcoplasmic reticulum

26 MULTIPLE CHOICE — CORRECT

Identify the indicated layer:



- Stratum basale
- Stratum spinosum
- Stratum granulosum
- Stratum corneum/ Keratinized