Final Grade
Last updated: 2018-11-28 0:00

ATTEMPT 1/1 (SUBMITTED 12/24/21, 7:15 PM on 12/24/21, 7:15 PM)

1 MULTIPLE CHOICE

Which segment of the gland may contain fecoid granulation?

- The second follicle
- The initial proximal segment
- The second terminal
- All of the listed
- [redacted]

2 MULTIPLE CHOICE

According to the shape of the secretory portion of the exocrine gland, they are classified as:

- Acinar
- Unicellular
- Tubular
- Venous
- Vesicular

3 MULTIPLE CHOICE

Which one of the following statements is NOT true regarding the adipose tissue?

- It is implicated in the immunological defence of the organism
- It has an important endocrine function
- It contains unilocular or multilocular adipocytes
- It has an important metabolic function
- It can be found in the subcutis or around the internal organs

4 MULTIPLE CHOICE

What is the normal percentage of the immature cells of the circulating leukocytes in healthy adults?

- 3-5 %
- 60-70 %
- 1-2 %
- 30-40 %
- 1-3 %

5 MULTIPLE CHOICE

The mesenchyme is an embryonic:

- Connective tissue
- Muscle tissue
- Nerve tissue
- Epithelial tissue
- None of listed

6 MULTIPLE CHOICE

Which of the following glial cells participate in the movement of cerebrospinal fluid?

- Ependymal cells
- Protoplasmic astrocytes
- Oligodendrocytes
- Satellite cells
- Protoplasmic astrocytes

8 MULTIPLE CHOICE

All of the following answers are true EXCEPT:
The glycocalyx is composed of:

- Glycolipids
- Glycoproteins
- Proteins
- Polysaccharides
- Lipoproteins

9 MULTIPLE CHOICE

Which of the following nucleoproteins is TRUE?
The diameter of core filaments is approximately:

- 100-150 nm
- 50-51 nm
- 1-2 nm
- 3-4 nm
- 10-11 nm

10 MULTIPLE CHOICE

Identify the depicted organelle:

- Smooth endoplasmic reticulum
- Mitochondrion
- Microtubule
- Lamp complex

11 MULTIPLE CHOICE

Which of the following answers is TRUE?
A genetic defect in the motor protein DYNEIN is linked to which of the following disorders?

- Down syndrome
- Kartagener syndrome
- Cancers Fitz-Ehrlich
- Gaucher syndrome
- None of the answers is correct

12 MULTIPLE CHOICE

Ribosomes attach to which organelle:

- Golgi app
- Smooth ER
- Lamp complex
- Nuclear membrane
- Mitochondria

13 MULTIPLE CHOICE

What type of cell junction is the desmosome:

- Gap jun
- Lock-stitch
- Both adhesion and remains
- Neither cell-cell nor cell-matrix

14 MULTIPLE CHOICE

Which of the following statement is TRUE?

- Chromatin cells form the base part of the plasmina
- Chromatin cells form the middle part of the plasmina
- Chromatin cells form the apical part of the plasmina
- Chromatin cells form the whole plasmina
- All statements were true

15 MULTIPLE CHOICE

From which component of the blastocyst can be isolated stem cells capable of organ regeneration in humans?

- Trophoblast
- Embryoblast
- Blastocystic cavity
- Blastomere
- Gametes

16 MULTIPLE CHOICE

In the beginning of the 3rd week the paraxial mesoderm differentiates into segments known as:

- Somites (somitomeres)
- Neuromeres
- Metameghrines
- Metameghrines
- Blood islands

17 MULTIPLE CHOICE

The number of oogonia at birth is approximately:

- 40-200
- 400-500
- 700-1000 - 2.000.000
- 2.000-3000
- 2.000-3000

18 MULTIPLE CHOICE

The external muscle sphincter of the female genitalia is complete at:

- Birth
- 1 year of life
- Puberty
- Adulthood
- None of the answers is true

19 MULTIPLE CHOICE

At the eighth day of development the hypoblast consists of:

- Small cuboidal cells
- High cuboidal cells
- Multilayer cells
- Pseudostratifier cells
- Perikaryon cells

20 MULTIPLE CHOICE

Trophoblastic oncogenesis with rare of anticipation development may lead to:

- Asymptomatic abortion
- Blastocyst tumor
- Molar pregnancy (mydatidiform mole)
- Uterine sarcoma
- None of the answers is true

21 JUMBLED SENTENCE

Match the listed morphological manifestations to the corresponding differentiated cells from the kings dream menu.
1 High number of nuclei → **osteoclasts**
2 Processes 300 → **plasma cell**
3 Cytoplasm with vacuoles → **foamy cells**
4 Giant Red nucleoplasm → **Reed-Sternberg**
5 Cytoplasm filled with → **mucin cells**

22 MULTIPLE CHOICE

Identify the indicated structure:

- Axon with a myelin sheath
- Unmyelinated nerve fibers with a Schwann sheath
- Astrocytogliosis/sclerosis
- Acanthotic scrapes

23 MULTIPLE CHOICE

Identify the indicated cell:

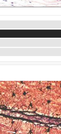

- Basal cell
- Parasphinal cell
- Intercalar cell
- Intermediate/superficial cells

24 MULTIPLE CHOICE

Identify the indicated layer:

- Stratum lucidum
- Stratum spinosum
- Stratum granulosum
- Membrana basalis (Malpighi)

25 MULTIPLE CHOICE

Identify the indicated tissue:



- Keratinized stratified cilinder-columnar epithelium
- Stratified squamous keratinized epithelium
- Transitional gastrointestinal epithelium
- Simple columnar/cuboidal epithelium

26 MULTIPLE CHOICE

Identify the indicated cells:

- Multipolar cellsby with from spinal cord
- Purkinje cellsnuron
- Multipolar pyriform neurons from cerebellar cortex
- None/angio