Final Grade
Last updated: 0 minutes ago

ATTEMPT 90 COMPLETED | QUIZ: 0:01 PM | 0 OF 0 QUESTIONS ANSWERED

1 | JOURNALIST EDITORIAL

Write the cover histopathological characteristics to the corresponding tissues from the drop-down menu:
1.Tall prismatic cells, oval nucleus, light cytoplasm in the basal layer, up to 300 microns in the apical surface 1 **Simple columnar ciliated epithelium**
2.Cuboidal cells with a round nucleus, light cytoplasm, and a brush edge on the free surface, resting on a basal membrane 2 **Simple cuboidal ciliated epithelium**
3.Cuboidal cells with central small round nuclei, loaded with dark granules large and polychromatic and acidophilic and acidophilic 3 **Simple secretory division of an exocrine glandular epithelium**
4.Cuboidal cells with central small round nuclei, loaded with dark granules large and polychromatic and acidophilic 4 **Simple secretory division of an endocrine tissue**
5.Complexes of pyramidal cells, resting on a basal membrane, covered with small cells with central round nonmotile cilia and cuboidal nonmotile cilia 5 **Endocrine glandular epithelium**

2 | MULTIPLE CHOICE

Which of the following cytoskeletal elements is important for the nucleus:

- Inactivation Alzheimer
- Actin filaments
- Microtubules
- All are important
- None are important

3 | MULTIPLE CHOICE

The structure depicted by arrows are cisterna of

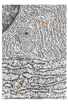

- Nucleus
- Smooth endoplasmic reticulum
- Microvesicles
- Rough endoplasmic reticulum

4 | MULTIPLE CHOICE

Which of the following answers is TRUE?
Entire cellular and cellular are characteristics enzymes for:

- Smooth endoplasmic reticulum
- Golgi complex
- Lysosomes
- Peroxisomes
- Microvesicles

5 | MULTIPLE CHOICE

The transport function in the nucleus takes place via:

- Nuclear pores complexes
- Inner nuclear membrane
- Outer nuclear membrane
- Nuclear lamina

6 | MULTIPLE CHOICE

Arrows in granules are bound by biomembranes. (LEAD)

- Microvesicles
- Endoplasmic reticulum
- Golgi complex
- Mitochondria
- Lysosomes

7 | MULTIPLE CHOICE

What type of cell junction is the adherent junction:

- Gap junc
- Gap junctions
- Actin-actin and actin-matrix
- Nuclear-actin and nuc-actin-matrix

8 | MULTIPLE CHOICE

In which of the following combinations the stages of monocytopoiesis are ordered correctly?

- monoblast → promonocyte → monocyte
- monoblast → promonocyte → monocyte
- monoblast → monocyte → promonocyte
- monoblast → monocyte → promonocyte
- monoblast → promonocyte → monocyte

9 | MULTIPLE CHOICE

The cellular tissue collapse are:

- Tapetic depts. fibrous
- Tanne, lymphoc. tapetic
- Tanne, lymphc. atactic
- Collagenous, atactic, fibrous
- Tapetic, collagenous, tanne

10 | MULTIPLE CHOICE

Which of the following substances is involved in the blood coagulation:

- None of an Hilderand
- Anaminopeptin
- Antihepatitis
- Heparina
- Lecin

11 | MULTIPLE CHOICE

Which of the following statements regarding the red muscle fibers is NOT correct ?

- they contract quickly
- they have more lipoprotein
- they have more lipid droplets
- the have less glycogen
- they have more mitochondria

12 | MULTIPLE CHOICE

Which of the following cells is NOT located in connective tissue?

- Mast cells
- Macrophages
- eosinophilic leucocytes
- plasma cells
- fibroblasts

13 | MULTIPLE CHOICE

What is the average lifespan of lymphocytes?

- Turn a few hours to a few decades
- 120 days
- 10-12 hours
- 9-12 days
- 1-6 days

14 | MULTIPLE CHOICE

The mesenchyme is an embryonic

- Connective tissue
- Blood tissue
- Nerve tissue
- Epithelial tissue
- None of these

15 | MULTIPLE CHOICE

Identify the indicated type

- Kinetom tissues
- Kinetom synovium
- Kinetom glandsystem
- Membrana elastica interna

16 | MULTIPLE CHOICE

Identify the indicated cell

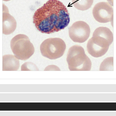

- Lymphocyte
- Monocyte
- Eosinophile granulocyte
- Neutrophile granulocyte

17 | MULTIPLE CHOICE

Identify the indicated cells

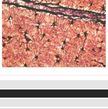

- Multipolar stellate cells from spinal cord
- Pyramidal neurons
- Multipolar pontine neurons from pontobulbar zones
- Myoneurogen

18 | MULTIPLE CHOICE

Identify the indicated cells



- Multipolar stellate cells from spinal cord
- Motor neurogen
- Multipolar pontine neurons from pontobulbar zones
- Pyramidal neurons from spinal ganglion

19 | MULTIPLE CHOICE

Identify the indicated cell

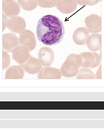

- Lymphocyte
- Monocyte
- Eosinophil
- Megakaryocyte

20 | MULTIPLE CHOICE

From the 3rd month, the hemopoiesis is

- Hepatic
- Hepatic
- There is no hemopoiesis yet
- Extramedullary
- Pulmonary

21 | MULTIPLE CHOICE

- Lymphocyte
- Monocyte
- Eosinophil
- Megakaryocyte

22 | MULTIPLE CHOICE

From the 3rd month, the hemopoiesis is

- Hepatic
- Hepatic
- There is no hemopoiesis yet
- Extramedullary
- Pulmonary

23 | MULTIPLE CHOICE

Which of the statements regarding the types of spermatogonia is NOT true?

- Type A - stem cell
- Type A dark (Ad) - longest renewal
- Type A pale (Ap) - irreversibly active
- Type B - progenitor generating spermatocytes
- Ad1 - stem cell generating Ad2 cells

24 | MULTIPLE CHOICE

The second meiotic division of the female gametes is complete at:

- Birth
- 1 year of life
- Puberty
- Ovulation
- None of the answers is true

25 | MULTIPLE CHOICE

The primordial germ cells during their migration divide by:

- Meiosis
- Apoptosis
- Mitosis and amitosis
- None of the answers is true

26 | MULTIPLE CHOICE

How long does normally capacitation of the semen take?

- 1-2 hours
- 6-7 hours
- 3-7 hours
- 1-2 hours
- 5-7 hours