1 MULTIPLE CHOICE — Correct

Which one of the following statements is NOT true regarding the adipose tissue?

- **It is responsible for the immunological defence of the organism**
- It has an infiltration endothelial facilities
- It contains a vascular or multivascular adipocytes
- It has an important metabolic function
- It can be reacted in the calculation of around the internal organs

2 MULTIPLE CHOICE — Correct

Which component of the ovary ovary contain Wolf's generations?

- **The ovarian fimbrae**
- The initial axonal segment
- The ovarian overhead
- End of the tubal
- None of the listed

3 MULTIPLE CHOICE — Correct

Serotoninin is produces in the

- **Hypothalamus**
- Metencephalon
- Mesencephalon
- Basal ganglia
- Hypothalamus infundibulum

4 MULTIPLE CHOICE — Correct

Which of the listed proteins is involved in the contraction of cardiomyocytes but not smooth muscle cells?

- **Troponin**
- Calmodulin
- Actin
- Myosin
- Inositol-3-phosphate receptor

5 MULTIPLE CHOICE — Correct

Which of the listed neurotransmitters are inhibitory?

- **GABA and Glycine**
- Glutamate and Aspartate
- Glutamate and Glycine
- Glutamate and Adrenaline
- GABA and Adenosine

6 MULTIPLE CHOICE — Correct

Nerve gab axonal transport is associated by the protein

- **Tau(t)**
- Dynein
- Synaptophysin
- Synaptotagmin
- Dynein

7 MULTIPLE CHOICE — Correct

Which one of the following statements is NOT true regarding the bone connective tissue?

- **Its cells are arranged in longarmed groups**
- Osteoblast contains Frayed all the Fossous membranes
- It is the site of first contact between bacteria and immune system
- Most of the cell types are temporary, lingering cells.
- It can increase substantially its volume during swelling

8 MULTIPLE CHOICE — Correct

Identify the tissue shown on the picture

- Complex tubuloacinar seromucous gland: serous, mucous and mixed secretory units.
- Exocrine acinus of smooth muscle cells in small intestine.
- Simple tubular mucous glands in large intestine.
- **Acquired epithelial in its form of tubules – thyroid gland.**

9 MULTIPLE CHOICE — Correct

Identify the indicated tissue

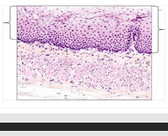

- Pseudostratified ciliated columnar epithelium
- **Stratified squamous keratinized epithelium**
- Transitional epithelium/urothelium
- Simple cuboidal (isomorphic) epithelium

10 MULTIPLE CHOICE — Correct

Identify the depicted tissue

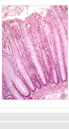

- Single layer columnar epithelium with microvilli - small intestine
- Endocrine epithelium forming follicles - thyroid gland
- Stratified non-keratinizing squamous epithelium - esophagus
- **Simple tubular (mucous glands) - large intestine**

11 MULTIPLE CHOICE — Correct

Identify the depicted structures



- Myelinated nerve fibers
- Secretory nerve endings
- **Neuromuscular junctions**
- Islets of endocrine epithelium

12 MULTIPLE CHOICE — Correct

Identify the indicated structures

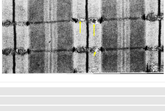

- Actins of a sarcomere
- Postsynaptic membrane
- Transversal disk
- **Trail of sarcoplasmic reticulum**

13 JUMBLED SENTENCE — Correct

Match the listed descriptions to the corresponding tissues from the drop-down menu:
1) A dense connective tissue with parallel bundles of collagen fibers is **epithelial tissue**
2) A cellular rapid response to external stimuli is **nerve tissue**
3) It is composed of with called chondrocytes and highly specialized ECM. It is **cartilaginous tissue**
4) Contains a large amount of fat cells and is a thermal insulator **adipose tissue**
5) It is characterized by a mineralized ECM. It is **bone tissue**

14 MULTIPLE CHOICE — Correct

What type of cell junction is the adhered junction

- Gap jun
- Gap junc
- Both cell-cell and cell-matrix
- Neither cell-cell nor cell-matrix

15 MULTIPLE CHOICE — 0 / 1

Which answer is TRUE?
Which of the main functions of the plasma membrane is attributed to the lipid spindel cell as a carrier?

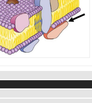

- **ATP-ATPase activation**
- **Maintenance of a barrier for water soluble molecules**
- Specific binding of ligand molecules
- Ion transport

16 MULTIPLE CHOICE — Correct

All metalloprotein are found by lysosomes were. [illegible]

- **Peroxisomes**
- Endoplasmic reticulum
- Golgi complex
- Mitochondria
- Lysosome

17 MULTIPLE CHOICE — Correct

Where are a ribs cell are localized the inter-mediate filaments, except in the cytosol?

- **Nucleus**
- Rough endoplasmic reticulum
- Lysosome
- Peroxisomes
- Golgi complex

18 MULTIPLE CHOICE — Correct

Which of the following statements is TRUE?
The diameter of an RBC filaments is approximate

- 100-150 nm
- 10-11 nm
- 5-7 nm
- **7-9 nm**
- 20-25 nm

19 MULTIPLE CHOICE — Correct

The transport frame in the nucleus takes place via:

- **Nuclear pores complexes**
- Outer nuclear membranes
- Inner nuclear membranes
- Nuclear lamina

20 MULTIPLE CHOICE — Correct

Down syndrome is an example of:

- **Autosomal trisomy**
- Autosomal monosomy
- Gonosomal trisomy
- Gonosomal monosomy
- Congenital disease with an infectious origin

21 MULTIPLE CHOICE — Correct

The following structures are NOT derived from the urobdeum:

- Bones of pelvis
- Muscles of pelvis
- Heart and vessels
- Nervous system
- **All answers are true**

22 MULTIPLE CHOICE — Correct

The animals (only appear within the

- **Sclerion**
- Cytomyrmekion
- Entocytomyrmekion
- Hypodermis
- Neuromuscl

23 MULTIPLE CHOICE — Correct

From which germ layer develop the smooth muscle cells of internal organs

- **Splanchnopleuric lateral plate mesoderm**
- Intraembryonic lateral plate coelomic
- Intermediate mesoderm
- Paraxial mesoderm
- Endoderm

24 MULTIPLE CHOICE — Correct

Which of the statements regarding the types of spermatogonia is NOT true?

- Type A – stem cell
- Type A dark (AD) - long-term reserve
- Type A pale (Ap) – irreversibly active
- Type B – irreversibly generating spermatocytes
- **Type C – stem cell generating Sertoli cells**

25 MULTIPLE CHOICE — 0 / 1

Correct Wrong Answers: Appendicitis in the Appendicitis Fecalis Acuta, Ulcerosa, Gangrenosa

- 5 Years
- **6 Years**
- 7 Years
- 40 Years
- 10 Years

26 MULTIPLE CHOICE — Correct

Trophoblastic overgrowth with lack of embryo/fetus development may lead to:

- Hydatiform abortion
- Malignant tumor
- **Molar pregnancy/hydatiform mole**
- Ectopic pregnancy
- None of the answers is true