Clinical Case B: the farmer

Fig. 9:

DUPLEX DIAGNOSIS:

Type I+N3 with incompetent Terminal Valve

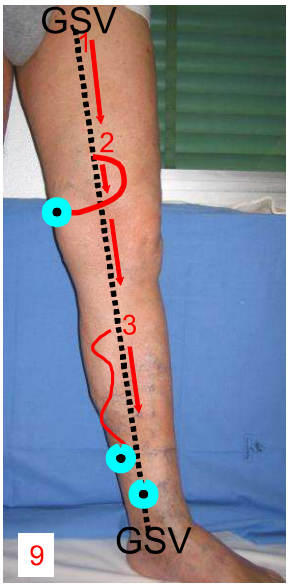

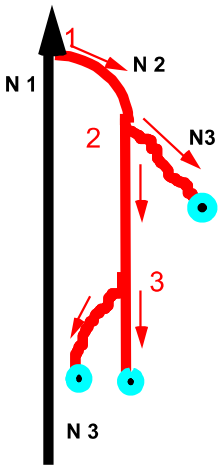

SAPHENO-FEMORAL HIGH LIGATION:

Fig.10a: Groin incision at the level of the SF junction outlined over the skin by the means of B-mode imaging. Progressive compartments dissection, in order to identify AC2 and the Saphenous trunk lying into it.

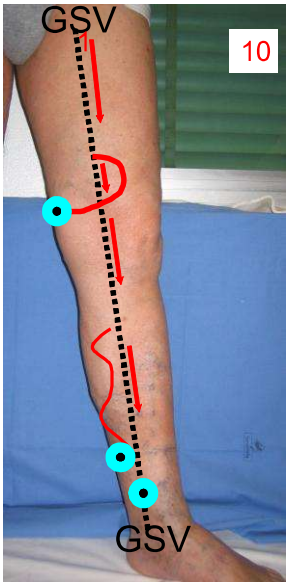

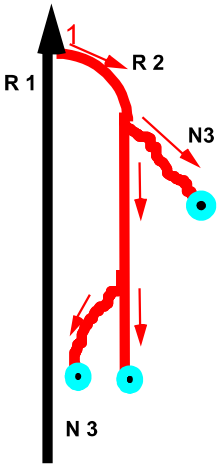

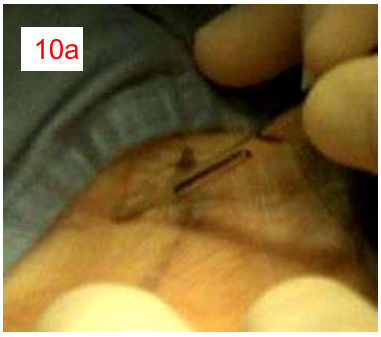

Fig. 11: Opening of the superficial fascia and exposure of the GSV trunk, SFJ and of the tributaries. The latter are encircled by a rubber loop in order to spare them (when possible).

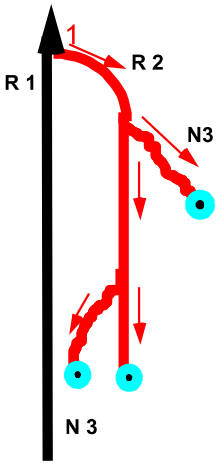

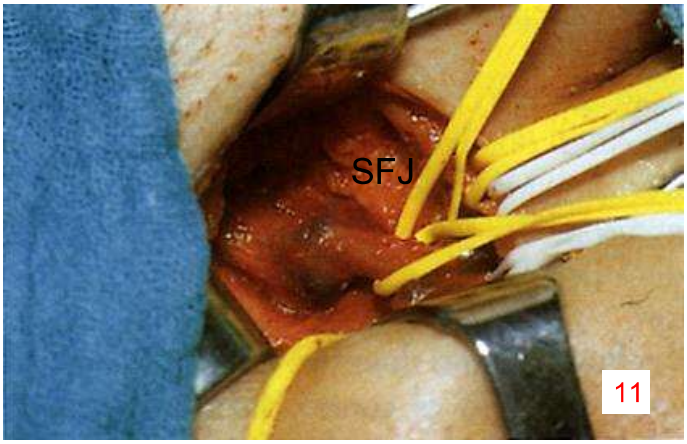

Fig.12: Right angle under the SFJ before high tie.

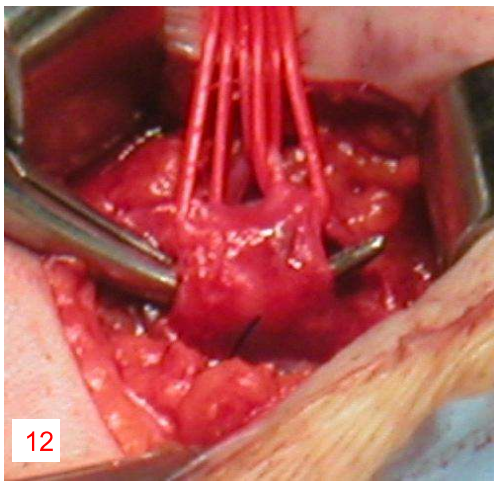

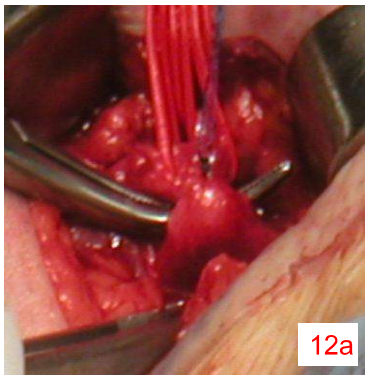

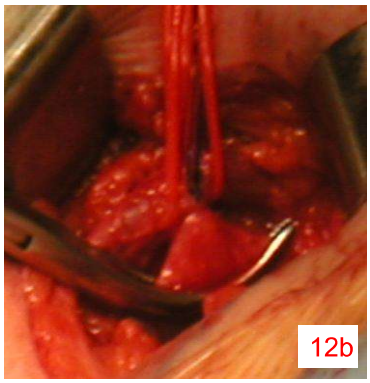

Fig.12a: Ligation of the distal part of the junction stump of the saphenous trunk.
Fig.12b: Clamping of the SFJ.

Fig.13: After ligation also of the proximal side, further clipping and disconnection of the SFJ.

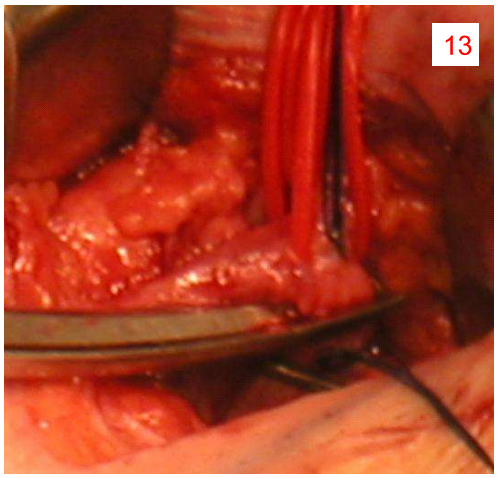

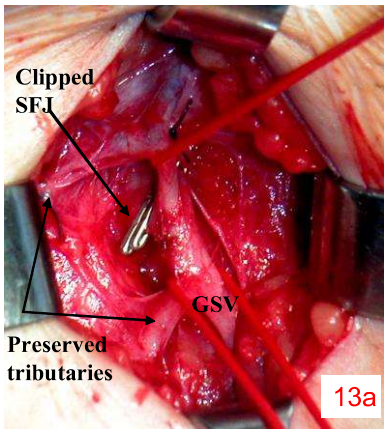

Fig.13a: In alternative, the picture shows double clipping of the SFJ without interruption. Tributaries preservation allows to mantain pelvic drainage into the GSV. The concept is to avoid interruption because could favourite the development of vicariant circulation and recurrence from neo-vascularization.

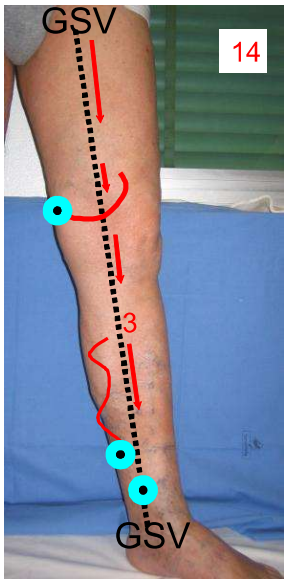

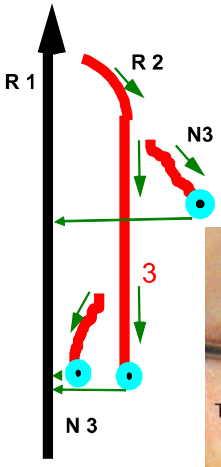

Fig. 14: Disconnection of the proximal and distal refluxing tributaries (N3) from the Saphenous trunk by the same technical procedure described in case A.

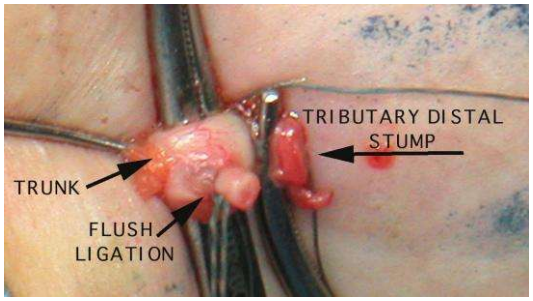

Appendix To Clinical Case B: absence of re-entry perforator on the saphenous trunk and incompetent terminal valve. The so-called type III shunt

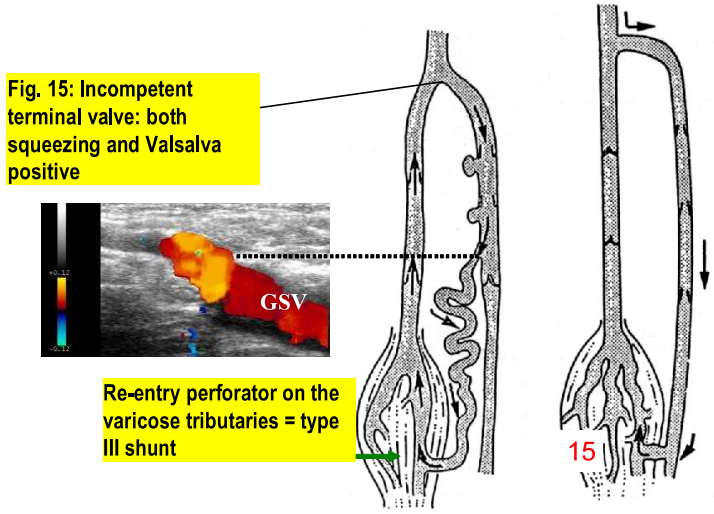

SHUNT III

Fig. 16: One shot solution with high tie determines a high rate of GSV thrombosis for creation of a non draining system. It was abandoned. [9, 47, 255]

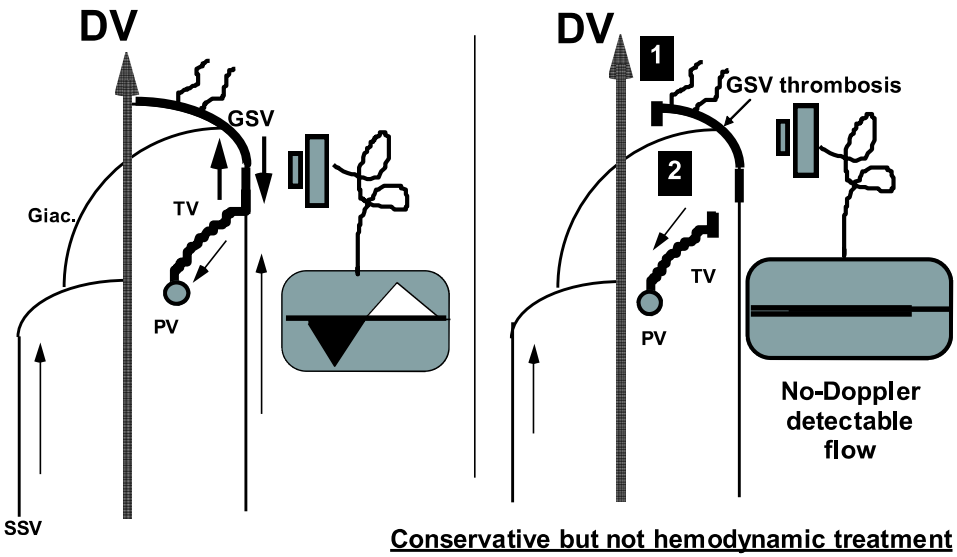

Conservative but not hemodynamic treatment

16

Fig. 17: One shot solution with high tie in a draining system was even abandoned. In fact the maintenance of the N2-N3 reflux determines an unsatisfactory cosmetic result . [9, 47, 255]

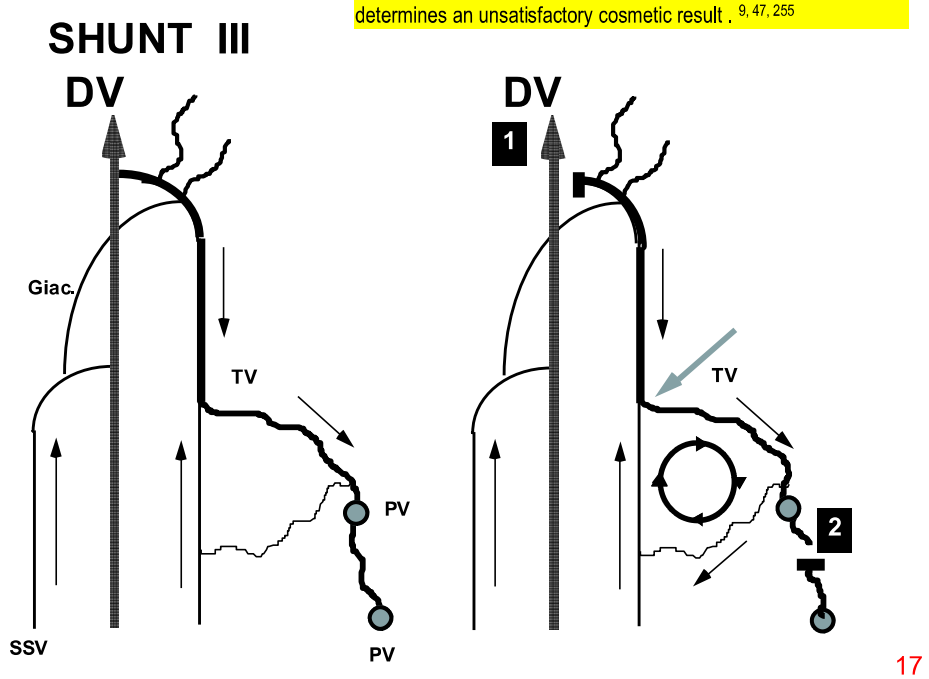

The case of absence of re-entry perforator on the saphenous trunk and incompetent terminal valve.

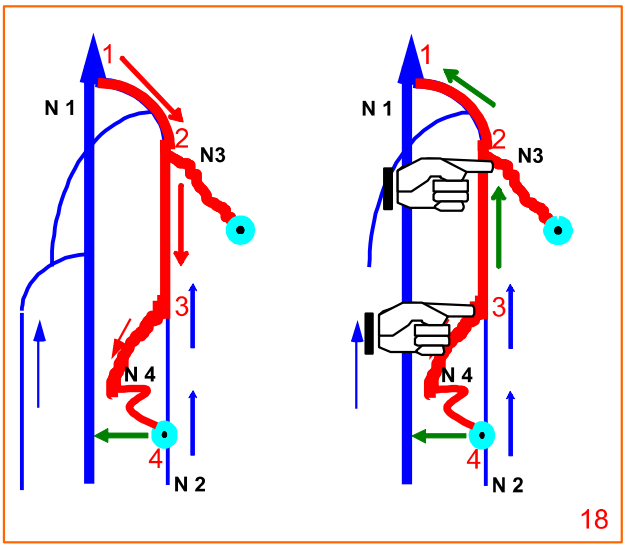

Fig. 18: In the illustrated case, the reflux elimination test (finger compression of the origin of the tributaries) [254] eliminates reflux in the GSV by eliminating the gravitational gradient. The logical consequence is to perform flush ligation of the origin of the tributaries (the so called 1st step of the CHIVA 2 procedure). [9, 47,90, 252, 255] This operation restores the physiological saphenous outflow in all cases.

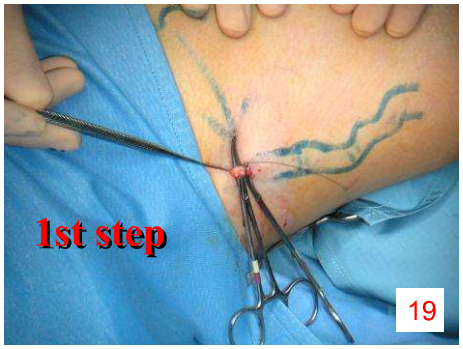

Fig. 19: However, after the 1st step a re-entry perforator along the GSV trunk could develop in a variable number of cases. [9, 47,90, 252, 255] This leads to re-appearance of reflux (type III shunt transformed in type I).

Such eventuality often occurs in case of incompetent terminal valve, and is managed by sapheno-femoral disconnection in a second session (the so called 2nd step of the CHIVA 2 procedure). [92]

One shot solution for type III shunt with associated incompetence of the terminal valve

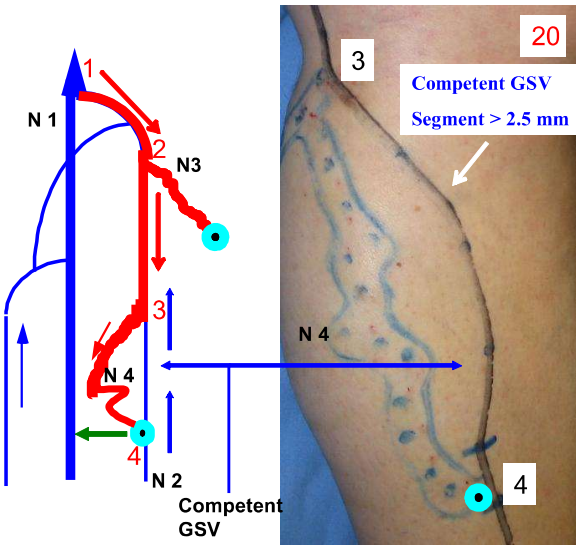

Fig. 20: Type III shunt with incompetent terminal valve, but with a re-entry perforator located in a competent segment of the GSV (from point 3 to point 4). Unfortunately the retrograde flow after high ligation cannot reach the re-entry at point 4 permitting a one shot solution.

If the competent segment of the GSV should be greater than 2.5 mm diameter, it should be possible to perform a "single shot" operation by using a valvulotomy in the competent GVS segment. The aim is to allow a retrograde flow along the trunk toward the selected re-entry perforator.

Valvulotomy for type III shunt with associated incompetence of the terminal valve

Fig.21a: After careful exposure at point 4 of the saphenous trunk at its confluence with the perforator and the N4, GSV transversal venotomy and introduction of the valvulotomy is performed.
Fig.21b: Progressive introduction of the valvulotomy from point 4 to point 3 part of GSV.

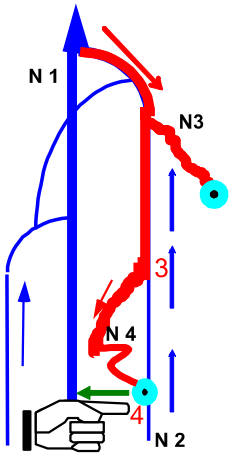

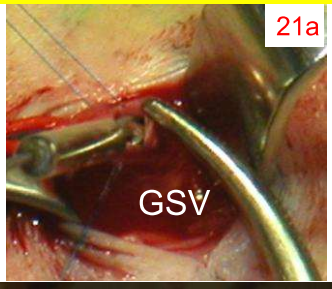

Fig. 22a: In alternative recanalization of the GSV segment can be achieved by gently and progressive veno-dilation, using rigid cylinder-tipped dilators of increased size.

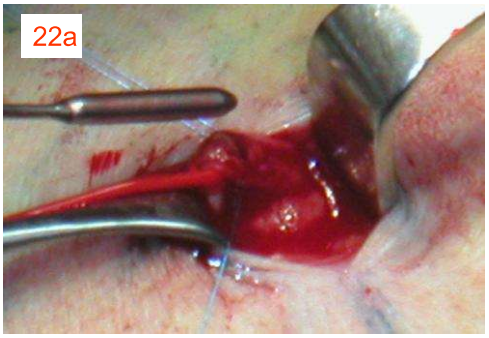

Fig. 22b: Removal of the valvulotomy

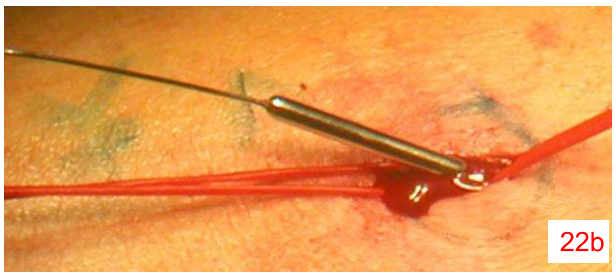

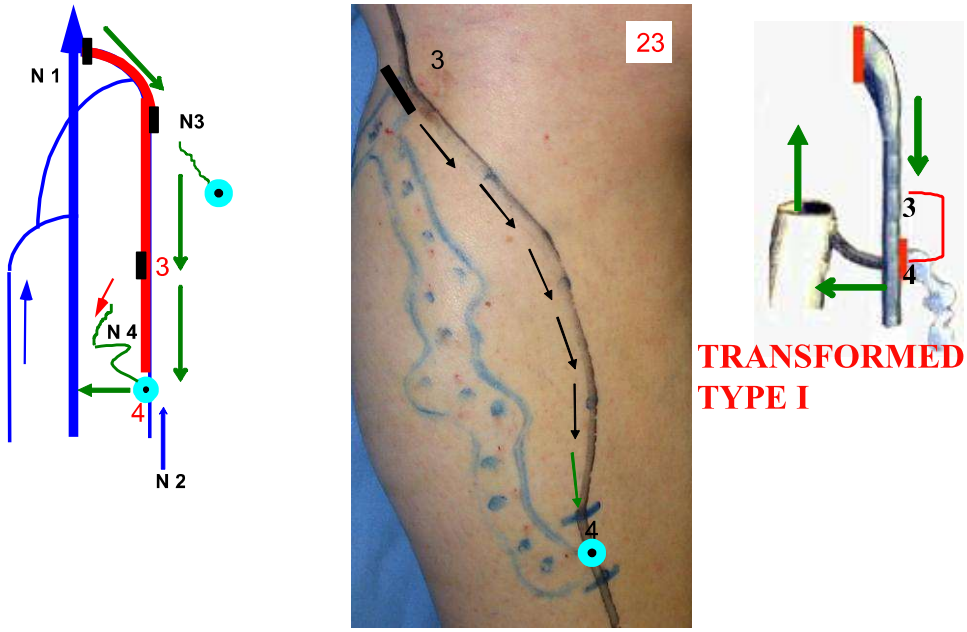

Fig. 23: This leads to the transformation of a type III shunt into a type I shunt on the operatory table. The operation can be completed as a CHIVA I procedure (high tie plus disconnection and Muller avulsion of the proximal varicose tributaries), as showed in the map.

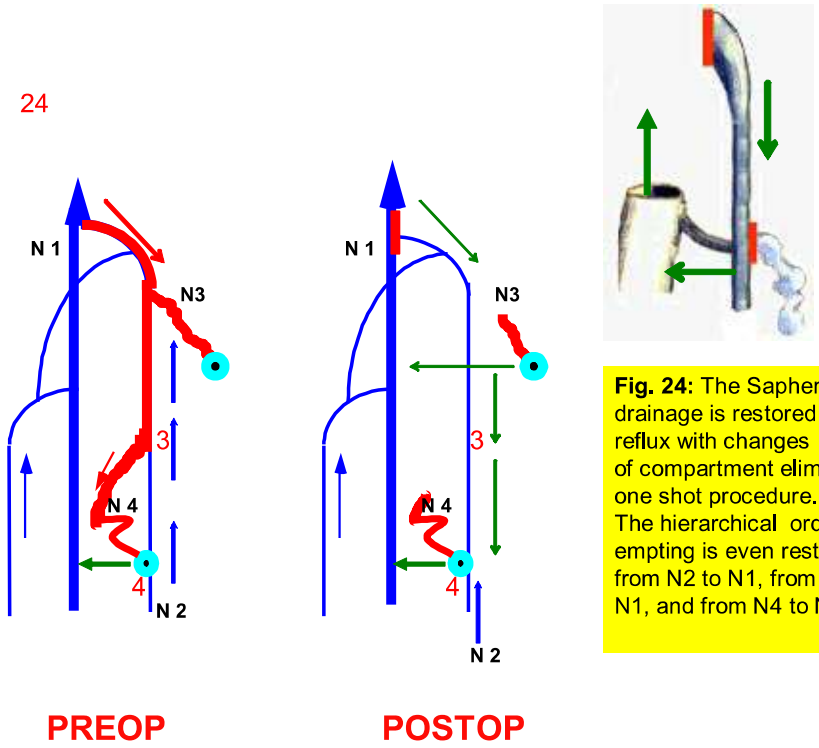

Fig. 24: The Saphenous drainage is restored and the reflux with changes of compartment eliminated in one shot procedure.
The hierarchical order of empting is even restored, from N2 to N1, from N3 to N1, and from N4 to N1.

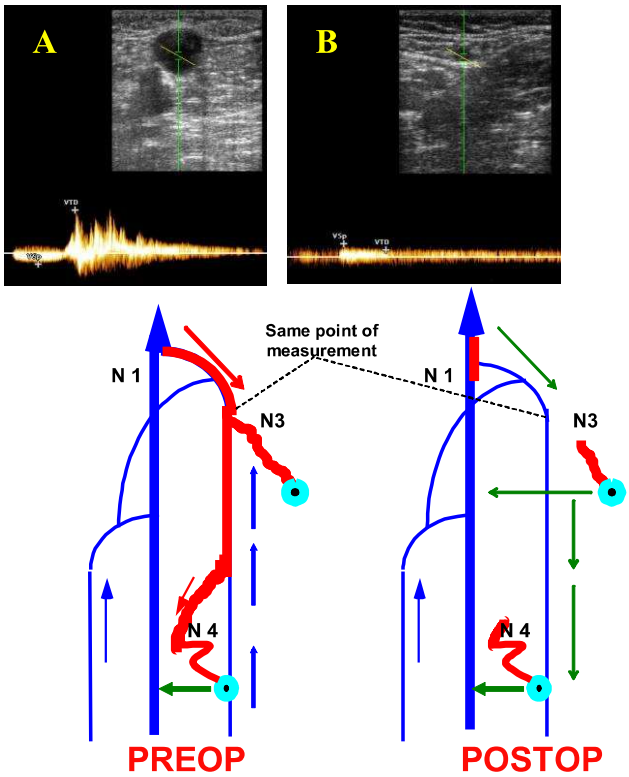

Fig. 25: A draining reverse flow is induced in the GSV either after one shot CHIVA 1 procedure, or after the second session of the CHIVA in 2 step procedure. Such reverse flow is a monodirectional low velocity flow (B), significantly different in the haemodynamic parameters from reflux with change of compartment assessed preoperatively (A) (see chapter 11). In addition, by comparing the preoperative cross sectional area of the GSV visible in the B-mode of the panel A with that depicted in panel B, a dramatic reduction of the saphenous vein dilatation is absolutely apparent postoperatively. This testifies the significant reduction of the GSV volume overload.

25

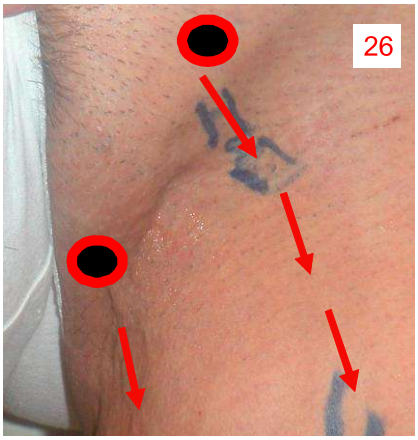

Clinical Case C:woman in child birth

Fig. 26:

DUPLEX DIAGNOSIS:

Shunt type IV (Pelvic shunts).

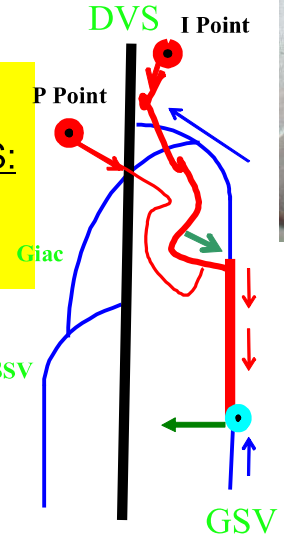

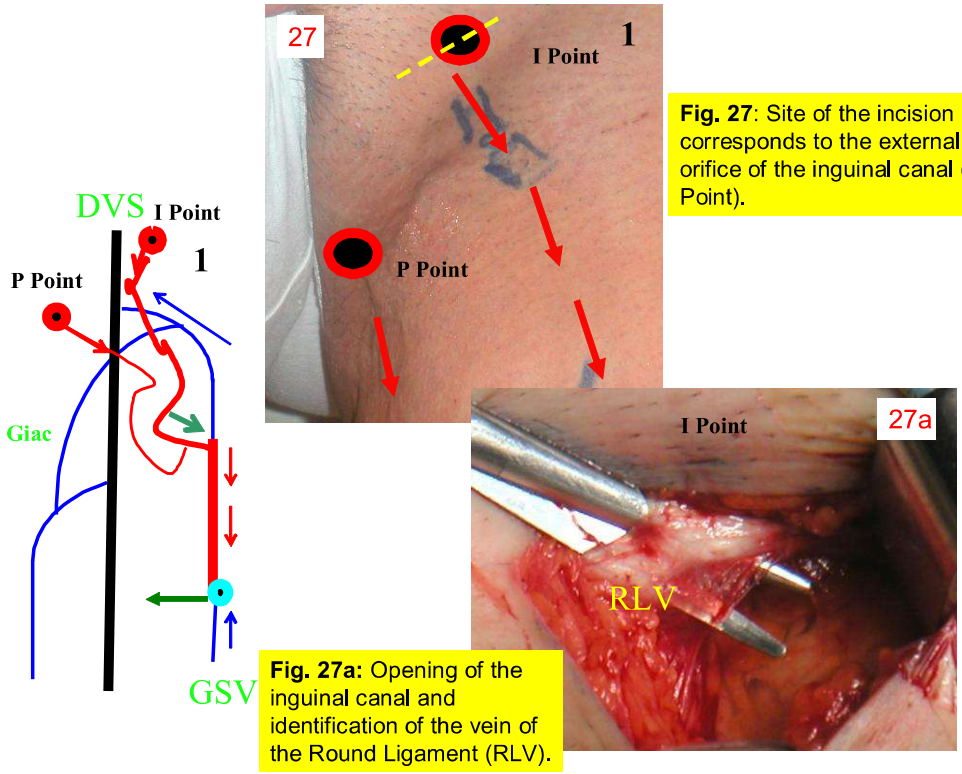

Fig. 27: Site of the incision corresponds to the external orifice of the inguinal canal (I Point).

Fig. 27a: Opening of the inguinal canal and identification of the vein of the Round Ligament (RLV).

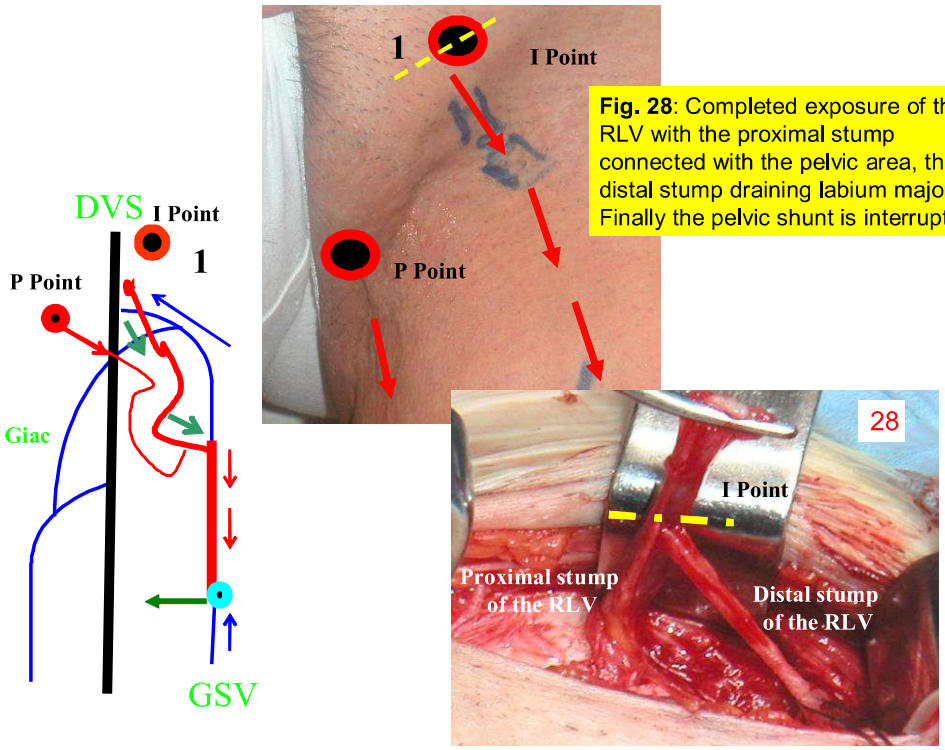

Fig. 28: Completed exposure of the RLV with the proximal stump connected with the pelvic area, the distal stump draining labium major. Finally the pelvic shunt is interrupted.

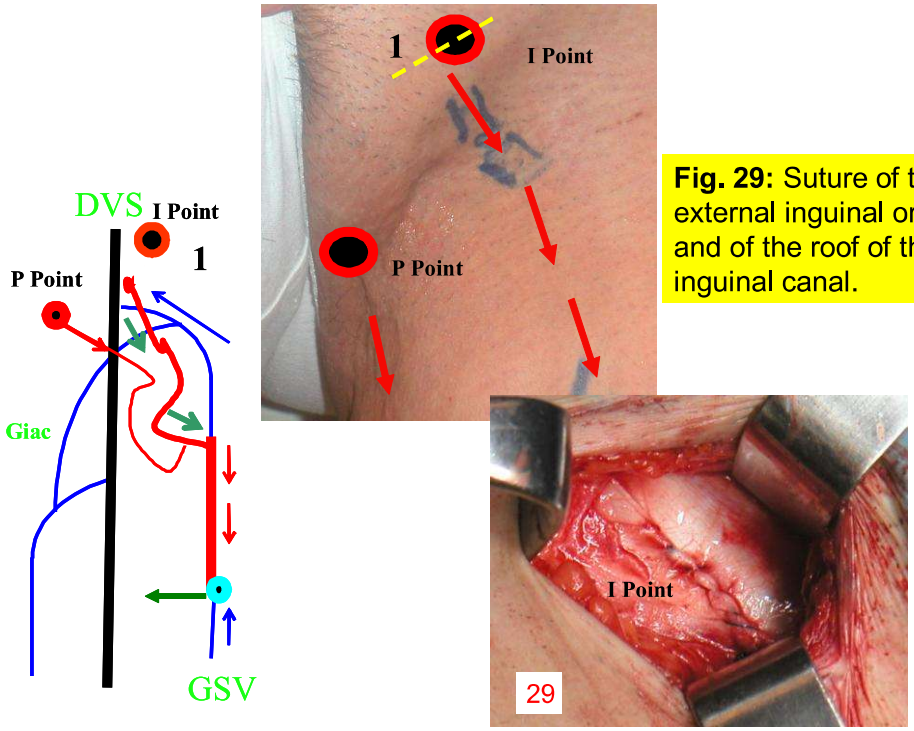

Fig. 29: Suture of the external inguinal orifice and of the roof of the inguinal canal.

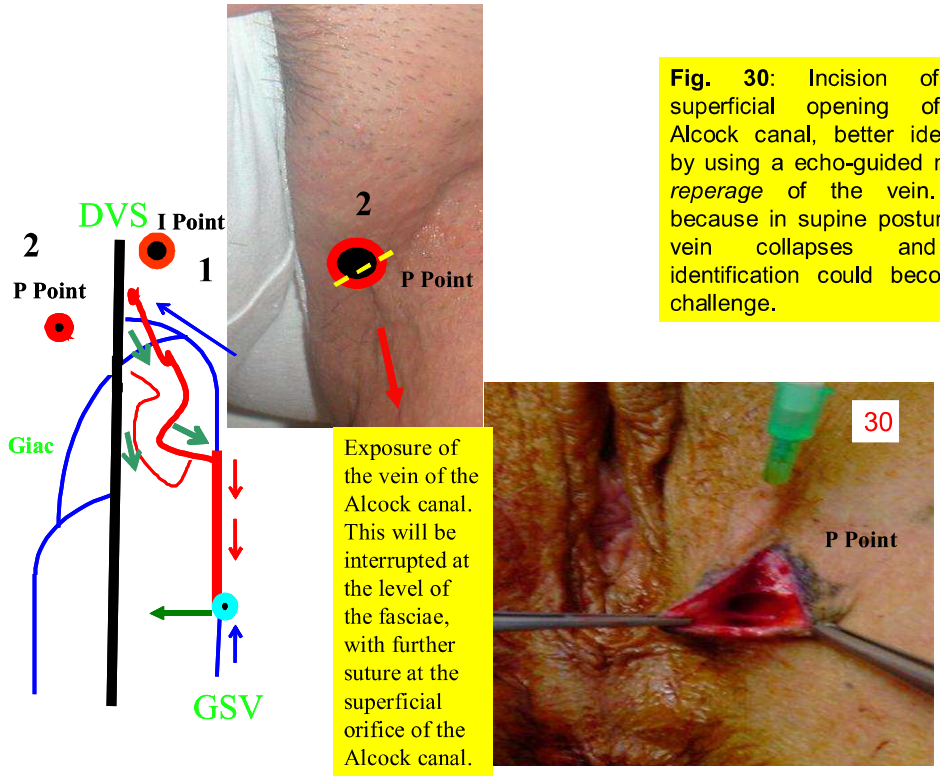

Fig. 30: Incision of the superficial opening of the Alcock canal, better identified by using a echo-guided needle *reperage* of the vein. This because in supine posture this vein collapses and its identification could become a challenge.

Exposure of the vein of the Alcock canal. This will be interrupted at the level of the fasciae, with further suture at the superficial orifice of the Alcock canal.

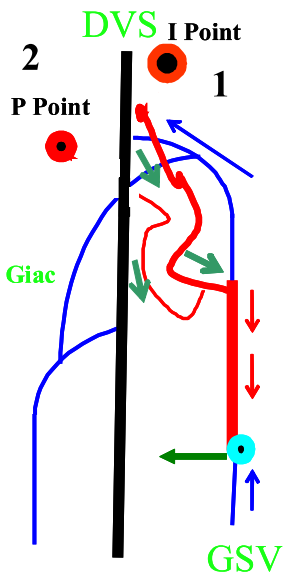

Fig. 31: The procedure is completed by multiple stab avulsion of the proximal varicose veins.

Clinical Case D:the hairdresser

Fig. 32:

DUPLEX DIAGNOSIS:

Shunt type III with perforator of the popliteal fossa (PPF, the so defined Thiery or Dodd perforator) as primary reflux point and competent SPJ. [65-67]

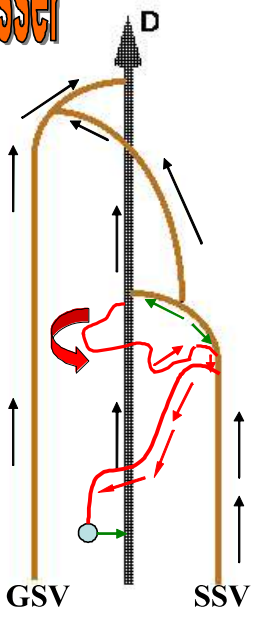

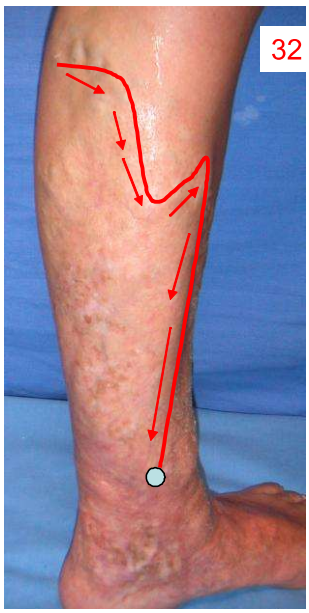

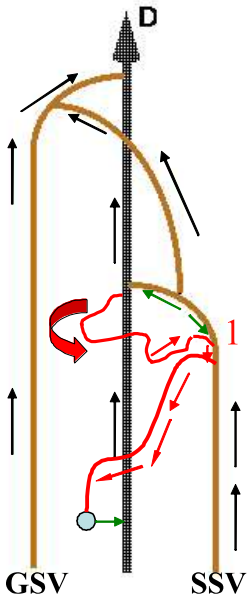

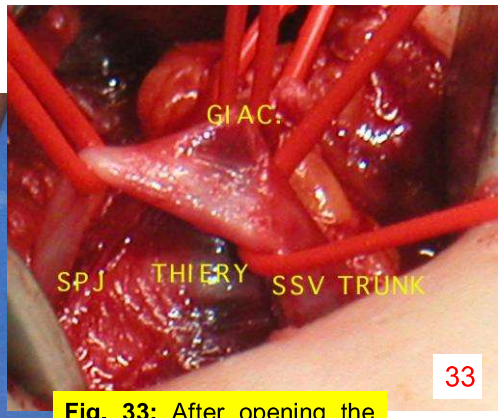

Fig. 33: After opening the popliteal fossa, below the superficial fasciae the SSV trunk is carefully exposed. Subsequently, the competent SPJ, the Giacomini's vein are both encircled by a rubber loop. Gently traction allows to identify under the SSV trunk the PPF.

Fig. 34: Disconnection of the PPF from the SSV trunk. The stump is clamped for making easier the dissection toward the popliteal vein. The procedure is then completed by flush ligation of the PPF on the popliteal wall.

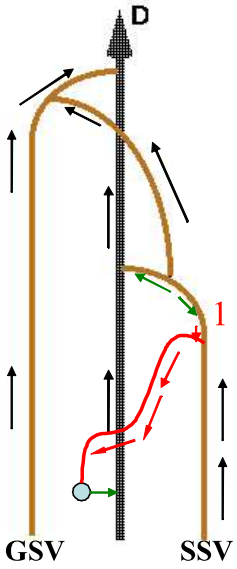

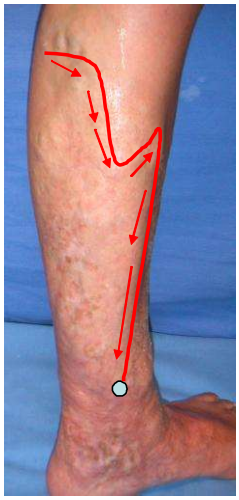

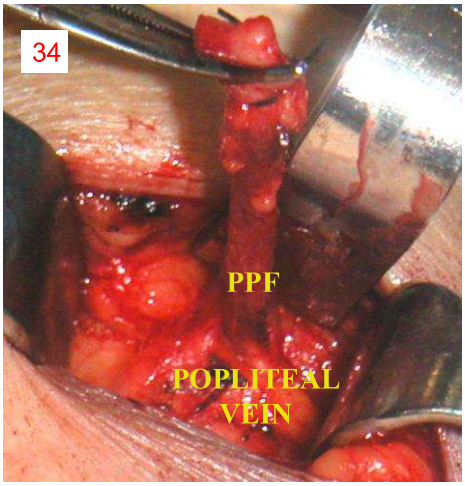

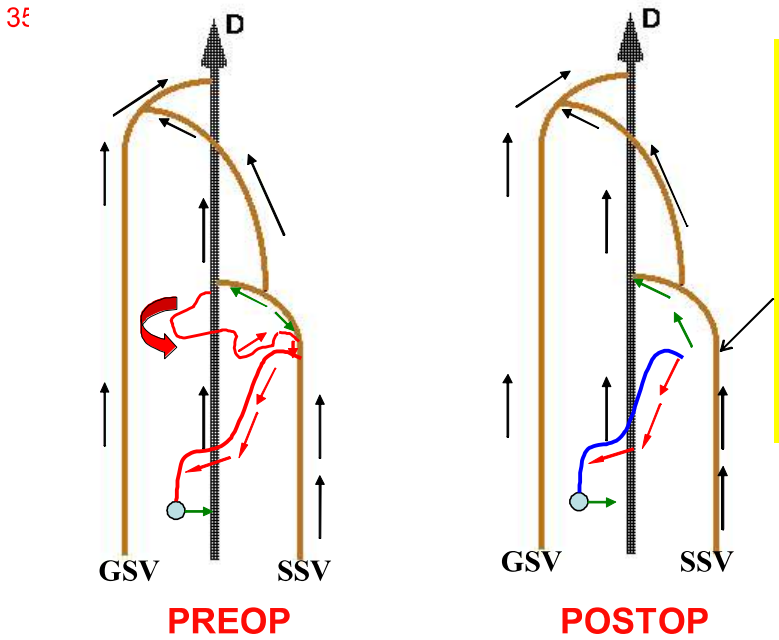

Fig. 35: Finally, N2-N3 flush ligation of the further N2-N3 completes the haemodynamic correction. We obtain a physiologic outflow in the SSV.

Clinical Case E: saleswoman

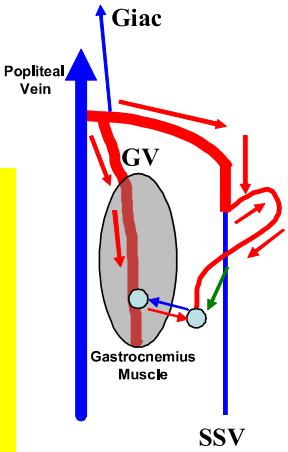

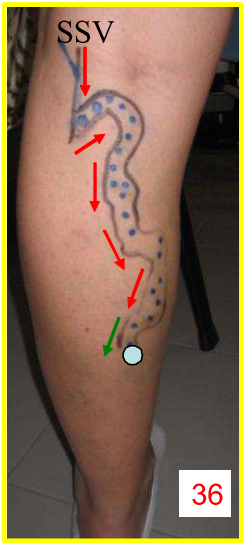

Fig. 36:

DUPLEX DIAGNOSIS:

Type III shunt of the SSV with concomitant GV reflux. GV and SSV outlet is a common trunk. Competent terminal valve of the SPJ.

Tested outflow route through the Giacomini'.

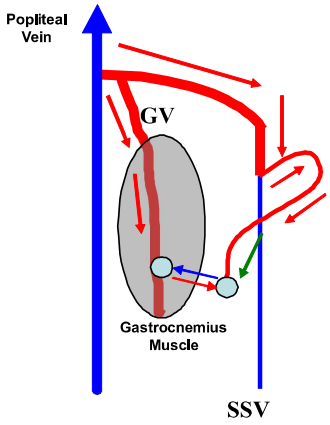

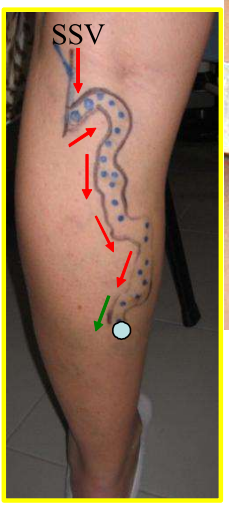

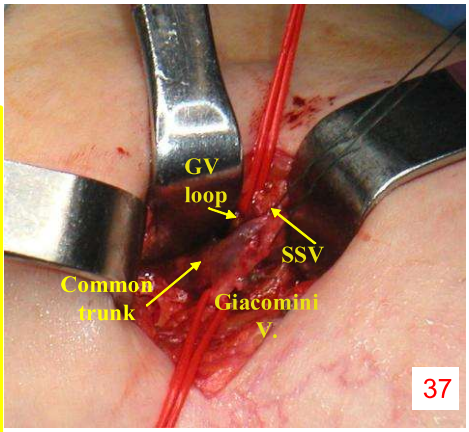

Fig. 37: Exposure of the veins of the popliteal fossa. The common trunk into the popliteal vein is well apparent.

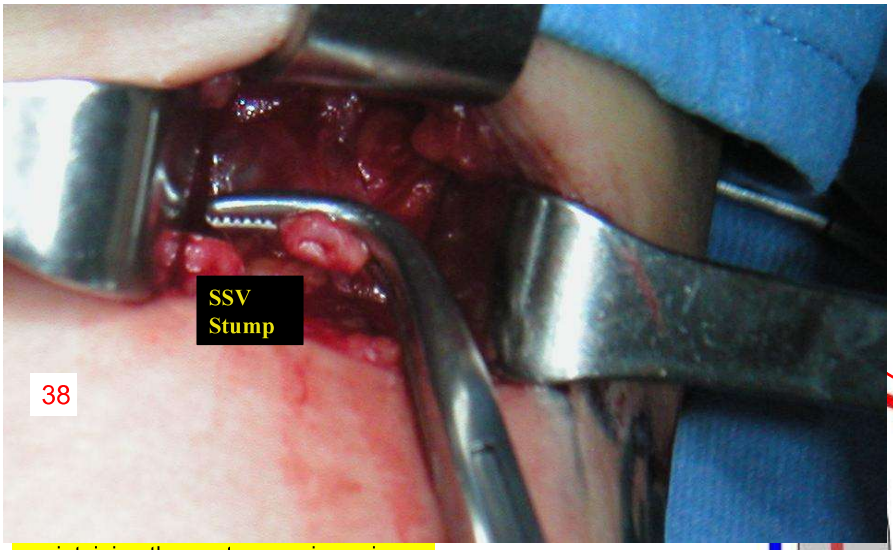

maintaining the gastrocnemius vein opening into the popliteal vein, as well as the continuity of the SSV into the Giacomini's vein.

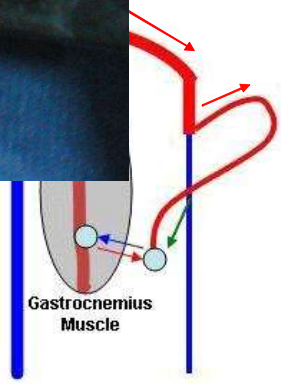

39

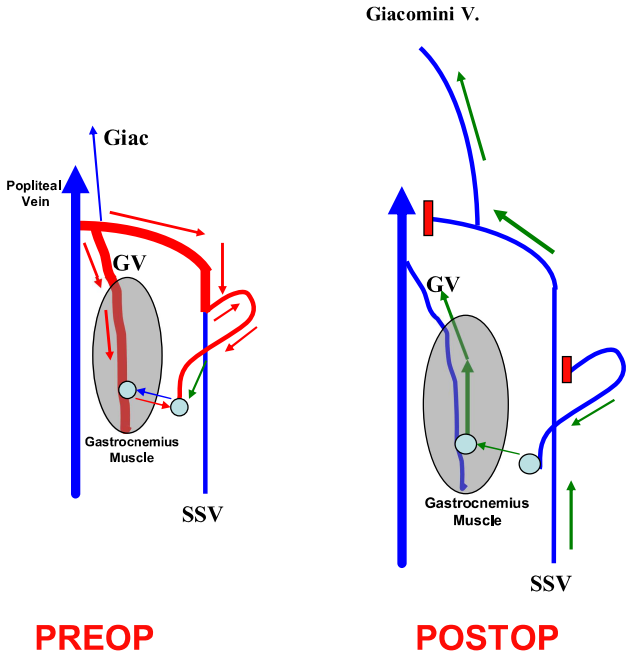

Fig. 39:
Disconnection of the refluxing N3 from the Saphenous trunk. Finally, we obtain the elimination of reflux both in the SSV and in the GV, with restoration of a physiological upward flow. In the former through the Giacomini's vein; in the latter toward the popliteal vein thanks to the elimination of the hydrostatic gradient. This is an example of indirect correction of deep reflux in the GV, acting on a superficial reflux.

Haemodynamic achievements:
- Reflux with change of compartment elimination in the SSV, GV, and N3.
- Physiologic forward flow in both SSV and GV
- Flow direction hierarchically correct N3-N1 in the tributary.

Clinical Case F: the molecular biologist

Fig. 40:

DUPLEX DIAGNOSIS:

Combined Type I Shunt of GSV and Type III Shunt of AASV

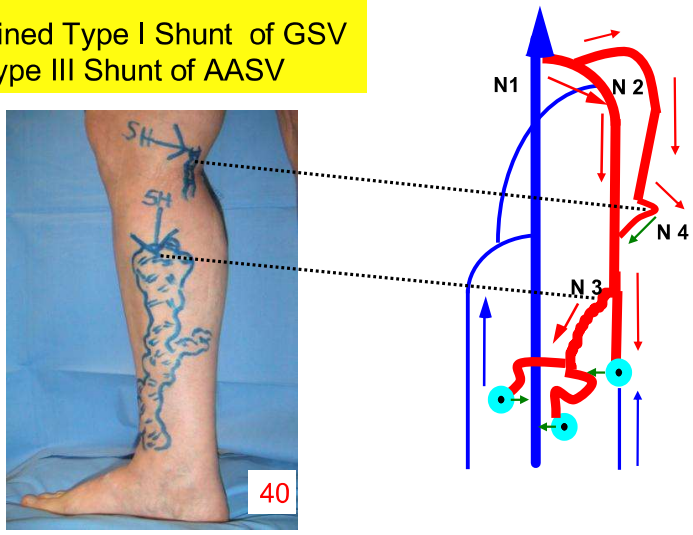

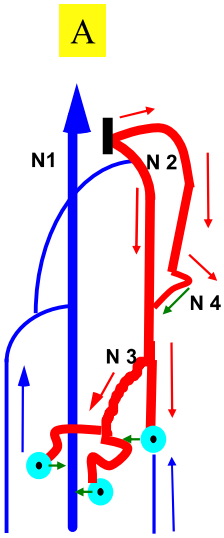

Fig. 41:
•The case depicted in fig. B is defined lambda SFJ, for the particular shape of the AASV and GSV outlet. A typical high ligation is performed, preserving the outlet of the AASV into the GSV, as clearly seen in Fig. C.
•This allows the drainage of the AASV into the GSV and the re-entry of both down-ward to the re-entry perforator, as depicted in Fig. A.

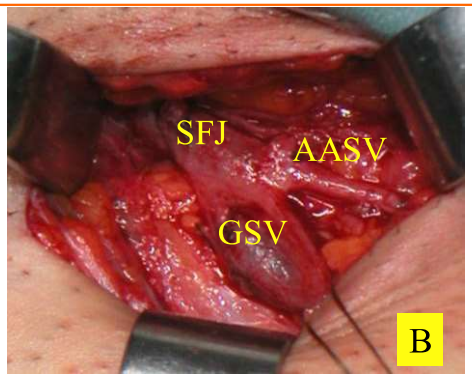

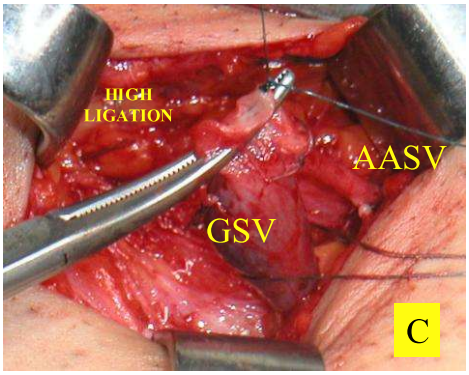

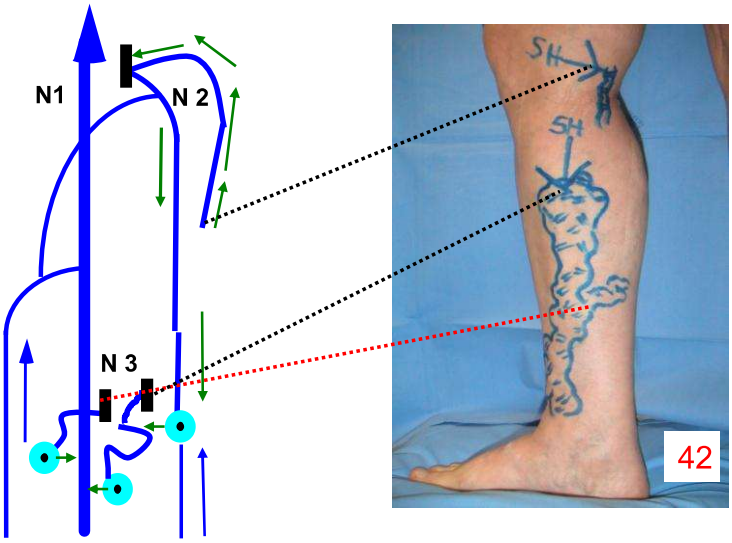

Fig. 42:
•The procedure is completed by double N2-N3 disconnection, multiple stab avulsion of the proximal varices, and disconnection of the secondary private circulations.

Anatomical variation of the so called LAMBDA SFJ

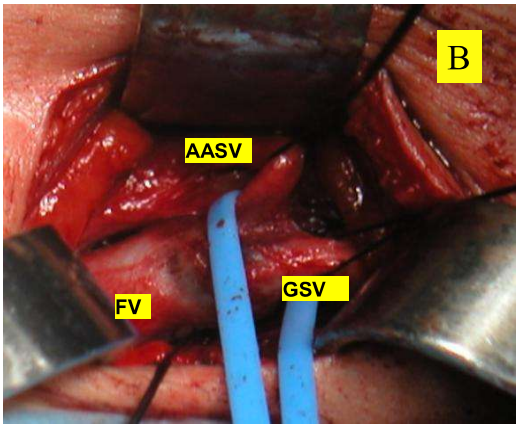

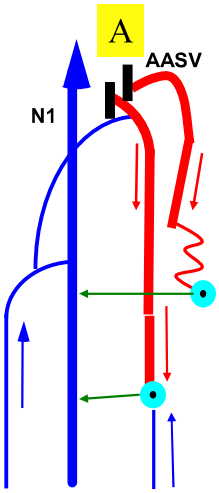

Fig. 43: If unfortunately the AASV outlet is too close to the SFJ (Fig B), usually surgeons perform disconnection of both the saphenous veins, as depicted in Fig. A.
However, such a surgical solution isn't a haemodynamic one, because provokes a flow reversal from its physiological direction in the AASV. The lack of anatomic pathways located along the AASV for re-entering flow in-ward, it is more likely to feed by reflux a tributary. Along time the latter will become varicose, leading to recurrences (red line depicted in Fig. A). [249]

43

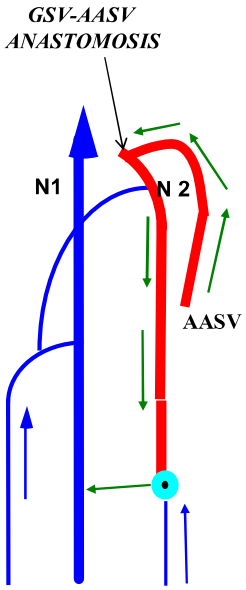

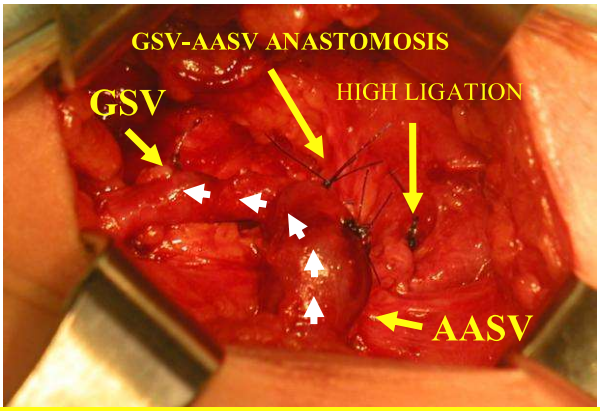

Fig. 44: In the case showed in the previous slide the haemodynamic alternative is aimed to preserve the outlet between the AASV and the GSV, despite the too close AASV to the SFJ. So far we performed end to end venous anastomosis in order to allow the drainage of the AASV into the GSV. This certainly is the most skilled but also effective surgical strategy, allowing AASV to drain into the GSV in muscular systole, and in turn the GSV to drain down-ward to the re-entry perforator in muscular diastole.

44

CLINICAL CASE G:the tobacconist

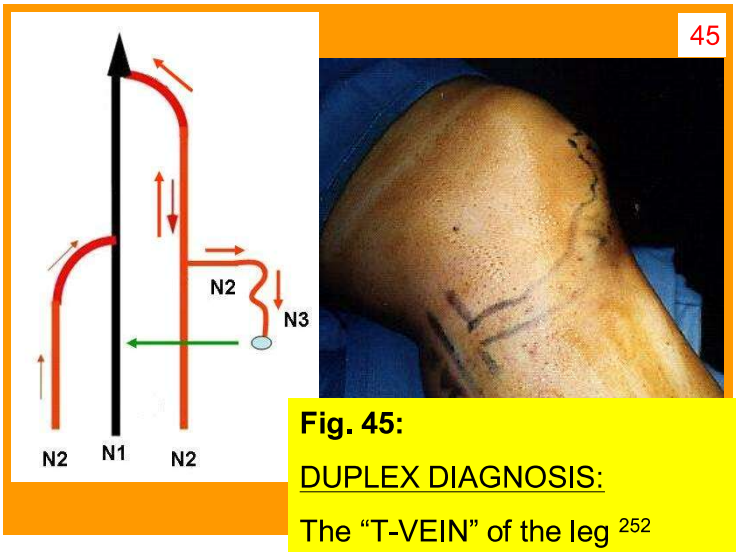

Fig. 45:

DUPLEX DIAGNOSIS:

The "T-VEIN" of the leg [252]

Type II shunt

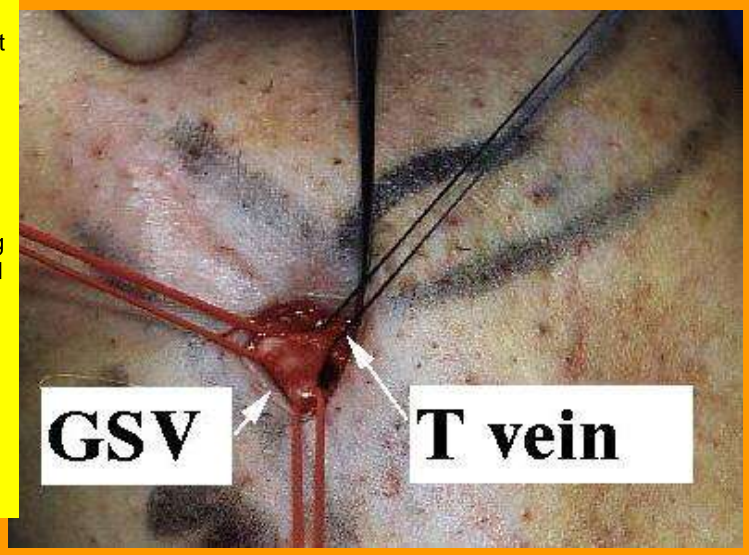

Fig. 46: As far as surgery is concerned it is impossible to treat properly such clinical case through a traditional phlebectomy micro-incision.
Due to the overlapping of the fascial layer and the T termination a flush ligation is possible only through a larger incision (1,5-2 cm), that allows a careful exposure of both saphenous vein and AC2.

46

CONCLUSIONS

At the conclusion of chapters 9 and 10, we would like to emphasize how pathological venous networks are extremely variable, and how standardized surgery cannot be adequate to all variants. We herein presented several paradigmatic cases, choose among the more frequent situations in clinical practice, and demonstrated how venous surgery could be tailored and coherent with preoperative duplex haemodynamics. The concept of Doppler guided surgery is set against that of standardized classic or endovascular ablative surgery.

CHIVA aim is to restore venous drainage by restoring the hierarchical order of emptying of the venous networks and suppressing points of reflux.

However, despite the variability of shunts presentation, CHIVA procedures can be standardized taking into account the haemodynamic findings and their relative incidence as follows:

CHIVA-TAILORED SURGERY

DUPLEX INDICATION	PROCEDURE
• ANY SHUNT TYPE, COMPETENT TERMINAL VALVE	CHIVA1 shot without high tie: T flush ligation-avulsion (case A, E, G). 45% in clinical practice
• TYPE I SHUNT, INCOMPETENT TERMINAL VALVE	CHIVA1 shot: high tie and T flush ligation-avulsion (case B, F). 25% in clinical practice
• TYPE III SHUNT INCOMPETENT TERMINAL VALVE	CHIVA2 steps: T flush ligation-avulsion, followed by high tie 6-18 months later; or, if technically feasible CHIVA 1 shot with valvulotomy (case B appendix) . 25% of cases
• OTHER HAEMODYNAMIC PRESENTATIONS	SINGLE SHOT CORRECTION *a la carte* Case C, D