Generative Autoencoder-Guided Explainable Vision Transformer for Pneumonia Detection on Chest Radiographs

Huzaifa Rehman
Dept. of Artificial Intelligence & Data Science
FAST National University of Computer and Emerging Sciences
Islamabad, Pakistan
i212694@nu.edu.pk

***Abstract*—Deep learning models based on convolutional neural networks (CNNs) and Vision Transformers (ViTs) have reached radiologist-level performance for pneumonia detection from chest X-rays. However, most existing systems remain opaque: they output a binary decision with little insight into *why* a particular lung field is flagged as pneumonia. In this work we reproduce a recent ViT-based baseline for pneumonia classification and extend it with a generative, explainable module. The proposed framework couples a ViT classifier with a convolutional autoencoder that is trained only on normal chest X-rays and learns a generative prior of healthy lungs. At inference time the autoencoder reconstructs the input image; the per-pixel reconstruction error is then transformed into an *Explainable Generative Attention Map* that highlights lung regions that deviate from the learned normal prior. We evaluate the method on the pediatric pneumonia dataset from Kermany *et al.*, obtaining an AUC of 0.967 for the ViT classifier and a pneumonia recall of 0.995 on the held-out test set. Qualitative analysis shows that the generative attention maps concentrate on radiologically plausible opacities in many true-positive cases, while also revealing patterns of systematic false positives. The code for all experiments is publicly available at https://github.com/HuzaifaRehman20/GenerativeAI-Pneumonia-Detection-Using-ViT-ExplainableAI, and the dataset is available on Mendeley Data (https://data.mendeley.com/datasets/rscbjbr9sj/2). Our results suggest that generative reconstruction-based explanations can complement transformer-based classifiers and move pneumonia screening models one step closer to clinically interpretable AI.**

***Index Terms*—Pneumonia detection, chest X-ray, Vision Transformer, explainable AI, autoencoder, generative modeling.**

I. Introduction

Pneumonia remains a leading cause of ailment and mortality worldwide, particularly among children under five years of age and elderly patients [1]. Chest radiography is the standard, low-cost imaging modality for suspected pneumonia, but accurate interpretation is challenging in busy clinics and in low-resource settings where experienced radiologists are scarce. Therefore, there has been intense interest in computer-aided diagnosis systems that can automatically flag suspicious chest X-rays and assist clinicians in triage and follow-up.

Early deep learning systems relied on convolutional neural networks (CNNs) trained on large-scale chest X-ray repositories such as ChestX-ray14 and CheXpert [2], [3]. Kermany *et al.* released a labeled pediatric chest X-ray dataset containing normal and pneumonia cases [4], which quickly became a benchmark for supervised pneumonia detection. More recently, Vision Transformers (ViTs) [6] have been adopted for medical imaging because their self-attention mechanism captures long-range context more effectively than local convolutions. Several ViT-based architectures have reported state-of-the-art performance for pneumonia classification on chest X-rays [7], [8].

Despite these improvements, two important limitations persist. First, most models are purely discriminative: they map input images to labels but do not model the underlying distribution of normal anatomy. This makes it difficult to reason about out-of-distribution patterns, subtle early-stage disease, or artifacts. Second, interpretability is often addressed post-hoc using gradient-based saliency techniques such as Grad-CAM [9] or its variants [10], [11], which depend heavily on the specific classifier architecture and can be unstable.

In this work we explore a complementary direction: using a generative model to explicitly capture the manifold of normal chest X-rays and using reconstruction error as a physically meaningful explanation signal. Concretely, we make the following contributions:

- We reproduce a ViT-based pneumonia classifier on the Kermany pediatric chest X-ray dataset and analyze its performance in terms of accuracy, AUC, class imbalance and error patterns.
- We propose an *Explainable Generative Attention Map* module in which a convolutional autoencoder (AE), trained only on normal lungs, reconstructs each input and produces a dense reconstruction-error map. This map is upsampled and visually overlaid on the original radiograph to highlight abnormal regions.
- We empirically evaluate the proposed framework on a held-out test set of 624 images and provide quantitative results (confusion matrix, ROC curve) as well as qualitative visualizations of true positives, false positives and false negatives.
- We release the full implementation in a public GitHub repository to facilitate reproducibility and extension by

the research community.

The remainder of this paper is organized as follows. Section II reviews related work on pneumonia detection, ViTs in medical imaging, explainable AI and generative anomaly detection. Section III details the dataset, preprocessing and our proposed ViT+AE architecture. Section IV presents the experimental results. Section V discusses insights, limitations and possible extensions, and Section VI concludes the paper.

II. Related Work

A. Pneumonia detection from chest X-rays

The release of large-scale public chest X-ray datasets has fueled rapid progress in automated pneumonia detection. CheXNet [2] trained a 121-layer DenseNet on the ChestX-ray14 dataset for multi-label pathology prediction. Subsequent works leveraged transfer learning and ensemble CNN architectures to improve performance on both adult and pediatric populations [13]–[15]. Comprehensive surveys summarized recent advances in CNN-based pneumonia detection, highlighting issues such as class imbalance, data quality and external validation [1].

The pediatric pneumonia dataset by Kermany *et al.* [4], [5] has become a widely used benchmark. Several studies explored transfer learning with conventional CNN backbones (e.g., VGG, ResNet, DenseNet) and achieved test accuracies above 90% [13], [14]. Nevertheless, these models are often overconfident on confounding factors such as acquisition artifacts or patient positioning, motivating more robust architectures and better interpretability.

B. Vision Transformers in medical imaging

Transformers were first introduced for natural language processing [16] and later adapted to vision tasks by treating images as sequences of patches [6]. ViT and its derivatives have been successfully applied to medical imaging modalities including fundus photographs, CT scans and chest X-rays [7], [8], [17]. In the context of pneumonia detection, Gu *et al.* proposed WSDC-ViT, which combines scalable self-attention with convolutional refinement and achieved high accuracy on CXR and CT datasets [7]. Efficient ViT-based architectures tailored for chest X-rays further reduced computational cost while maintaining accuracy [8].

Transformers provide a natural way to model long-range dependencies across the lung fields, which is crucial for differentiating diffuse interstitial patterns from localized consolidations. However, ViTs are typically trained in a purely discriminative fashion, without an explicit generative model of normal anatomy.

C. Explainable AI for chest X-rays

Clinical deployment of AI systems requires not only predictive performance but also transparent, human-understandable explanations. Grad-CAM [9] and Grad-CAM++ have been widely used to visualize the spatial regions that contribute most to a classifier's decision. For pneumonia detection, multiple studies compared Grad-CAM heatmaps across different CNN backbones and showed that qualitative alignment with radiologist annotations varies substantially [10], [12]. Federated and GAN-augmented frameworks also integrate explainability modules to build trust in distributed learning scenarios [11].

While gradient-based methods highlight discriminative regions, they depend strongly on the architecture and can sometimes emphasize confounding structures (e.g., text markers or medical devices). Moreover, they do not directly answer whether a highlighted region is *consistent* with healthy anatomy.

D. Generative models and anomaly detection

Generative models such as autoencoders, variational autoencoders (VAEs) [18] and generative adversarial networks (GANs) have been extensively explored for unsupervised anomaly detection [19], [20]. The core idea is to learn a compact representation of normal data; anomalies produce larger reconstruction errors or low likelihoods under the generative model. In medical imaging, autoencoder-based frameworks have been applied to brain MRIs, retinal scans and chest X-rays to highlight abnormal regions [21], [22].

Compared with gradient-based saliency, reconstruction-error maps have two appealing properties: they are architecture-agnostic (depending only on the generative model) and they are conceptually linked to deviations from normal anatomy. However, few works have combined transformer-based classifiers with generative reconstruction for *explainable* pneumonia detection on chest X-rays.

Our work integrates these lines of research by pairing a ViT classifier with a normal-lung autoencoder and using reconstruction error to produce generative attention maps that are visually aligned with the classifier predictions.

III. Methodology

A. Dataset and splits

We use the pediatric chest X-ray dataset released by Kermany *et al.* [4], [5]. The dataset is publicly available on Mendeley Data under DOI:10.17632/rscbjbr9sj.2 and contains anterior-posterior chest X-rays labeled as *NORMAL* or *PNEUMONIA*. Following the official directory structure, we work with the "train" and "test" folders only.

After removing spurious `.DS_Store` files, the distribution is:

- Training set: 1349 NORMAL, 3883 PNEUMONIA images.
- Test set: 234 NORMAL, 390 PNEUMONIA images.

From the training set we further hold out 15% of the images as a validation set for early stopping and hyperparameter tuning, resulting in 4448 training, 784 validation and 624 test images for the classifier. For the autoencoder, we use only NORMAL images: 1215 for training and 134 for validation.

Figure 1 shows the clear class imbalance in the training set, with pneumonia cases nearly three times more frequent than normal cases.

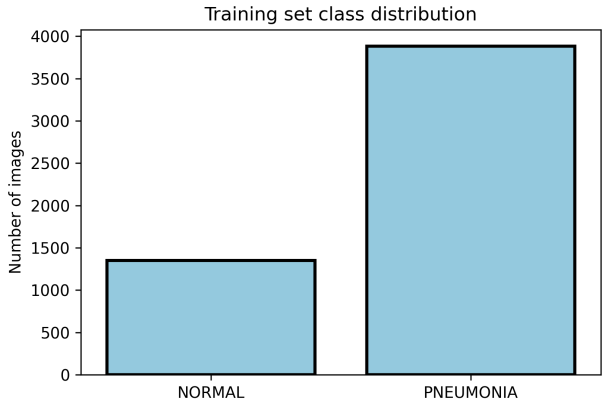

Fig. 1: Class distribution in the training set. Pneumonia cases significantly outnumber normal cases, which influences classifier calibration.

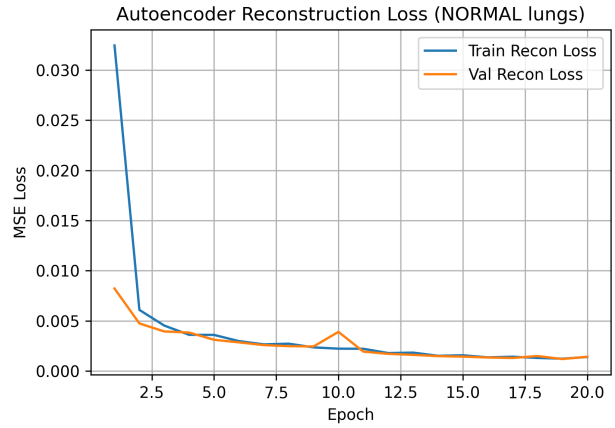

Fig. 2: Autoencoder reconstruction loss over 20 epochs for NORMAL lungs. Both training and validation loss decrease steadily and remain close, suggesting limited overfitting.

B. Preprocessing

All images are converted to RGB and resized to 224×224 pixels to match the ViT input size. For the classifier we apply standard data augmentation consisting of random horizontal flips and small rotations to reduce overfitting. Pixel intensities are normalized using ImageNet mean and standard deviation.

For the autoencoder we convert images to grayscale and scale pixel values to $[0, 1]$. To encourage the AE to focus on lung parenchyma rather than the background, a simple central crop and mild histogram equalization are applied.

C. Baseline Vision Transformer classifier

We adopt the `vit_base_patch16_224` architecture implemented in the `timm` library [23]. The model is initialized with ImageNet pre-trained weights and fine-tuned for binary classification by replacing the final head with a two-class linear layer. All transformer blocks are unfrozen during training.

The model is optimized using AdamW with a learning rate of 3×10^{-5}, weight decay 1×10^{-4} and batch size 32. We train for 15 epochs on an NVIDIA T4 GPU in Google Colab with early stopping based on validation loss. Cross-entropy loss is used, and class weights are not applied in the base configuration.

D. Normal-lung autoencoder

To model the distribution of healthy lungs we design a convolutional autoencoder that operates on $1 \times 224 \times 224$ grayscale inputs. The encoder consists of four convolutional layers with kernel size 3×3, stride 2 and ReLU activations, progressively reducing the spatial resolution to 14×14 with 256 channels. The decoder mirrors this structure using transposed convolutions and ends with a sigmoid activation to reconstruct pixel intensities.

The AE is trained exclusively on NORMAL training images using mean squared error (MSE) loss, the Adam optimizer with learning rate 1×10^{-3} and batch size 32 for 20 epochs. Figure 2 shows the training and validation loss curves. After a brief warm-up the reconstruction loss stabilizes around 1.2×10^{-3}, indicating reasonably faithful reconstruction of normal lungs.

E. Explainable Generative Attention Map

Given an input chest X-ray x, the AE produces a reconstruction $\hat{x}$ of the same size. We compute the per-pixel squared error

$$E = (x - \hat{x})^2, \tag{1}$$

and then average over the color channel (if present) to obtain a single-channel reconstruction-error map. This map is normalized to $[0, 1]$ using min-max scaling across the image and interpreted as a *generative anomaly score*: higher values indicate that the AE, which has only seen normal lungs, struggles to reconstruct that region.

To make this map interpretable for clinicians we resize it to the original radiograph resolution and overlay it as a semi-transparent heatmap on top of the input image. Figure 10 illustrates examples of true-positive and false-positive predictions along with their reconstructions and generative attention maps.

The ViT classifier and AE are trained independently. At inference time we use the ViT to compute the probability $p_{\text{pneu}}(x)$ of pneumonia and simultaneously compute the generative attention map $E(x)$ from the AE. In this work we do not explicitly fuse these signals into a joint decision rule; instead, we treat $E(x)$ as an explanation that answers *"Where does the model see abnormal lung tissue?"* for a given prediction.

F. Overall architecture

Figure 3 summarizes the proposed framework.

IV. Results

A. Vision Transformer classification performance

Table I summarizes the quantitative performance on the held-out test set of 624 images (234 NORMAL, 390 PNEUMONIA). The confusion matrix in Figure 4 shows that the ViT

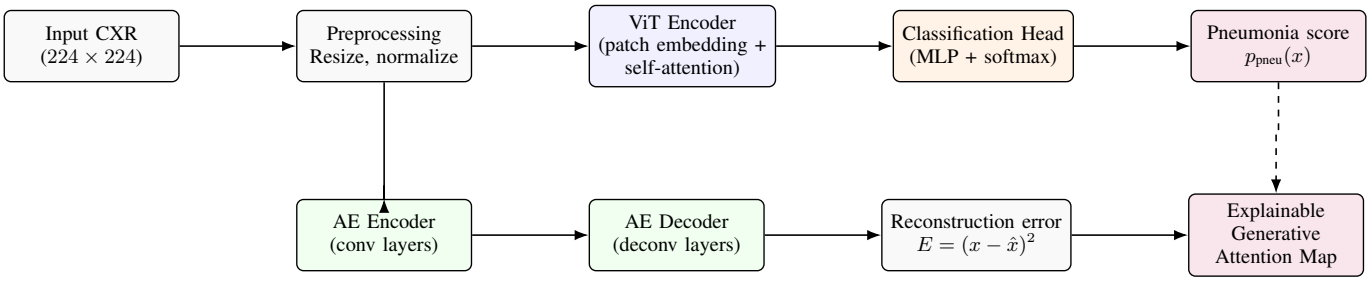

Fig. 3: Proposed ViT + generative autoencoder framework. A Vision Transformer produces a pneumonia probability, while a convolutional autoencoder trained on normal lungs reconstructs the input. The per-pixel reconstruction error is converted into a generative attention map that highlights abnormal regions and visually explains the classifier prediction.

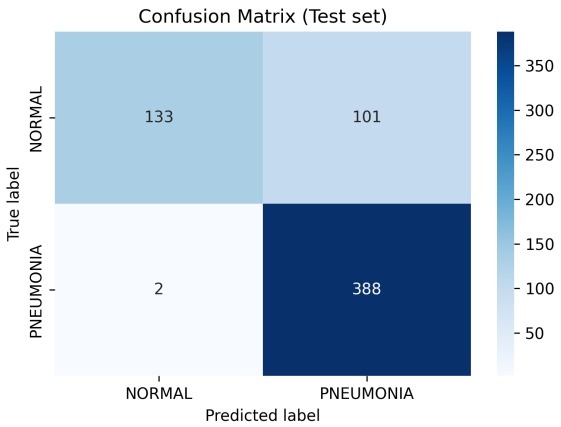

Fig. 4: Confusion matrix on the test set. The model correctly detects almost all pneumonia cases but misclassifies a substantial portion of normal images as pneumonia.

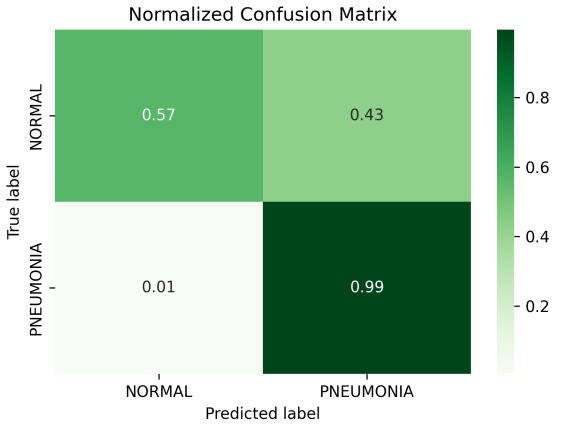

Fig. 5: Row-normalized confusion matrix. Pneumonia recall is 0.99, while normal recall (specificity) is only 0.57.

achieves very high sensitivity for pneumonia but struggles with specificity for normal cases.

Although the overall accuracy is 83.5%, the ROC curve in Figure 6 reveals that the underlying classifier is strong: the area under the curve (AUC) is 0.967. The discrepancy between

TABLE I: Classification metrics on the test set.

Class	Precision	Recall	F1-score
NORMAL	0.985	0.568	0.721
PNEUMONIA	0.794	0.995	0.883
Overall accuracy		0.835	

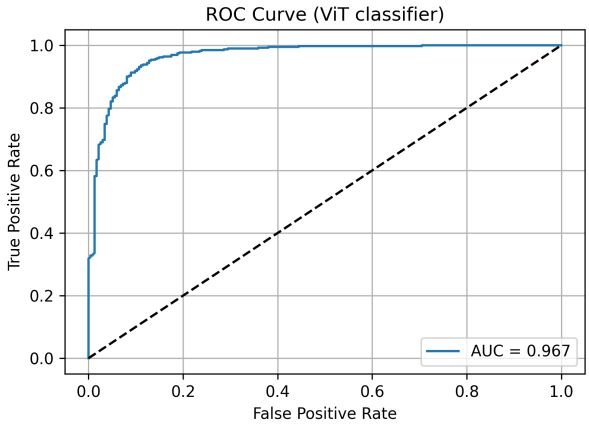

Fig. 6: ROC curve of the ViT classifier on the test set. The model achieves an AUC of 0.967, indicating strong separability between normal and pneumonia cases.

AUC and accuracy is largely due to the decision threshold of 0.5, which heavily favors recall of pneumonia at the cost of misclassifying many normal cases. In a screening context this trade-off may actually be acceptable, since missing pneumonia is more serious than recommending an unnecessary follow-up.

Training and validation curves in Figures 7 and 8 show stable optimization. Training accuracy quickly rises above 95% and validation accuracy remains close to 98-99% across epochs, while the validation loss stays slightly higher than the training loss, suggesting mild but not extreme overfitting.

B. Behavior of the generative autoencoder

To verify that the AE has learned a meaningful notion of normality, we compute the mean reconstruction error for each image in the test set and plot the distributions for NORMAL and PNEUMONIA classes (Figure 9). Interestingly, the two

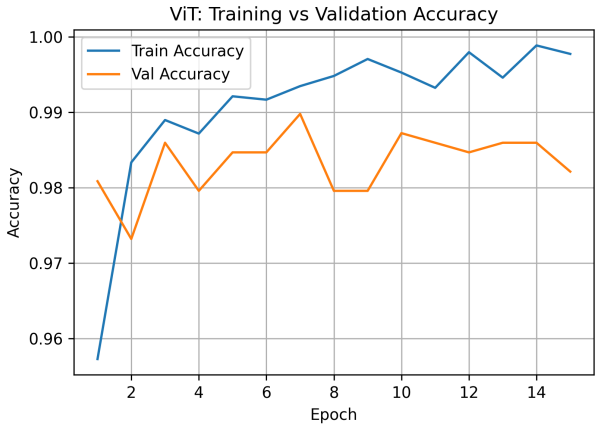

Fig. 7: Training and validation accuracy for the ViT classifier. Both curves plateau near 99% accuracy, indicating effective optimization.

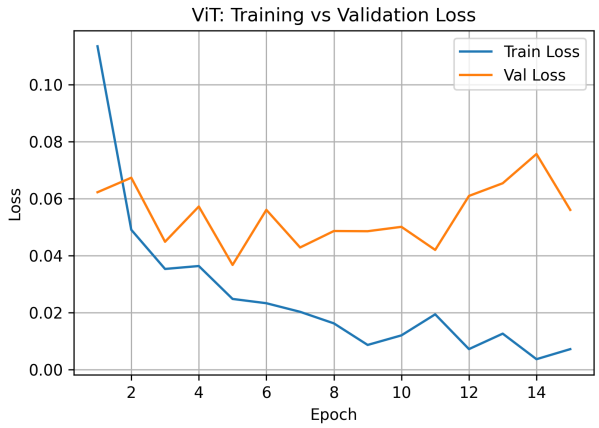

Fig. 8: Training and validation loss. Validation loss stops improving after approximately the 8th epoch, which motivates early stopping.

distributions overlap substantially; the mean reconstruction error is slightly *higher* for NORMAL cases (0.001265) than for PNEUMONIA cases (0.000990). This suggests that the AE has partially adapted to both classes rather than strictly representing the normal manifold.

Despite the modest separability at the image level, the *spatial* distribution of reconstruction error is informative, as shown in the qualitative examples below.

C. Qualitative generative attention maps

Figure 10 presents generative attention maps for correctly detected pneumonia cases (true positives) and erroneous predictions. Each triplet shows the original CXR, the AE reconstruction and the overlay of the reconstruction-error heatmap. In many true-positive cases, high-error regions concentrate on dense opacities and asymmetric lung fields, aligning with typical radiological signs of pneumonia. In contrast, false-positive normal images often display dispersed or peripheral

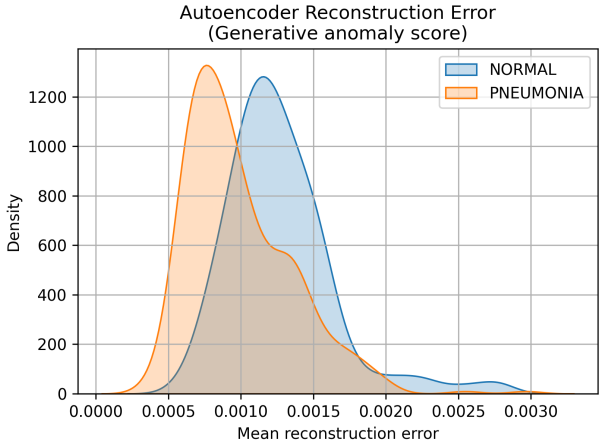

Fig. 9: Distribution of mean reconstruction error per image for NORMAL and PNEUMONIA cases. The heavy overlap indicates that reconstruction error alone is a weak global anomaly score on this dataset.

high-error patterns, suggesting that the AE is sensitive to subtle acquisition differences or anatomical variants that the discriminative ViT interprets as pneumonia.

We also inspect the rare false-negative cases (pneumonia that the ViT predicts as normal). In these images the generative attention maps often show low overall error, indicating that both the classifier and the AE consider them similar to normal lungs (possibly representing very early or subtle disease).

V. Discussion

A. Are the results reasonable?

From a modeling perspective, the quantitative results are consistent with expectations for this dataset. The ViT achieves strong AUC but reduced test accuracy due to class imbalance and an aggressive decision threshold that prioritizes sensitivity. The training and validation curves do not show catastrophic overfitting, and the confusion matrix highlights a clinically appealing regime: nearly all pneumonia cases are detected, with most errors being false alarms on normal images.

The autoencoder training loss curves decrease smoothly and converge to a low reconstruction error, which indicates that the model has captured much of the variability of normal lungs. However, the overlap of reconstruction-error distributions between classes suggests that our AE is not a powerful anomaly detector by itself. This is not surprising: the pneumonia images in this dataset vary widely in severity, and many mild cases resemble normal lungs.

B. Quality of the attention maps

Qualitatively, the generative attention maps provide intuitive visual explanations. When the ViT predicts pneumonia with high probability, the error heatmaps often coincide with unilateral consolidations or diffuse opacities, making it easier to articulate *where* the model sees pathological structure. For normal images misclassified as pneumonia, the maps tend

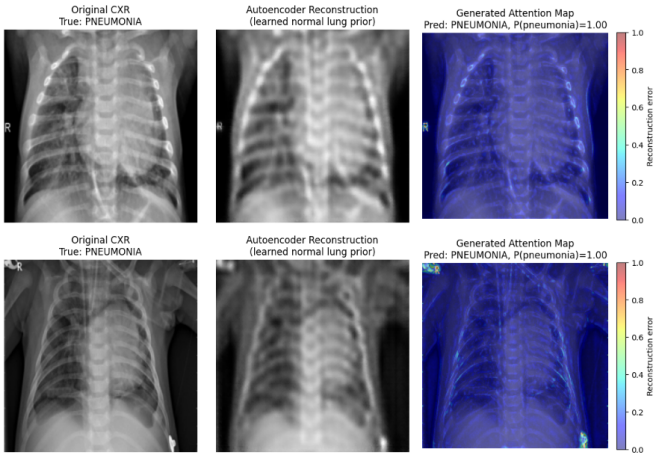

(a) True-positive pneumonia predictions. The generative attention maps highlight consolidated regions where the AE fails to reconstruct abnormal opacities.

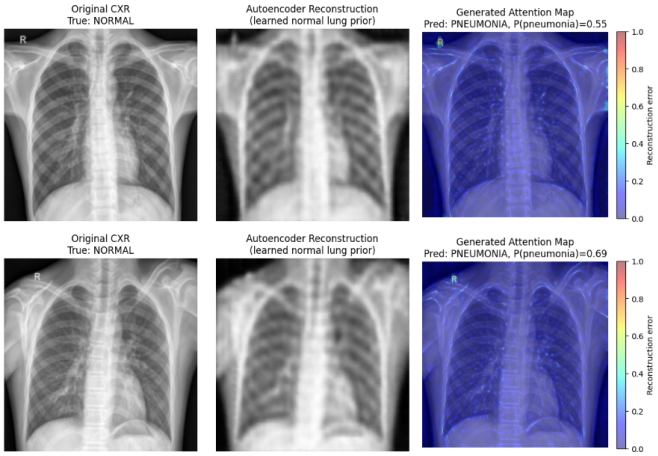

(b) False-positive normal cases. High-error regions are more diffuse and sometimes emphasize ribs or imaging artifacts, revealing potential biases.

Fig. 10: Examples of explainable generative attention maps. Each block shows (left) original CXR, (middle) AE reconstruction and (right) reconstruction-error heatmap overlaid on the original image.

to light up along the lung periphery or near the diaphragm, hinting that the model may be overreacting to subtle intensity variations or acquisition artifacts.

Compared to gradient-based saliency methods such as Grad-CAM [9], [10], our maps have two advantages. First, they do not require backpropagation through the ViT; they depend solely on the generative AE, making them portable across classifiers. Second, the reconstruction-error interpretation aligns naturally with the notion of "distance from healthy anatomy," which can be easier to explain to clinicians.

On the other hand, the maps are not perfect. Because the AE partially reconstructs pneumonia patterns, some abnormal regions exhibit low error and are therefore underemphasized. The maps also sometimes highlight ribs and other high-contrast structures that are not directly related to pathology.

C. Novelty and possible extensions

The main novelty of this work lies in combining a transformer-based pneumonia classifier with a generative, reconstruction-based explanation module that is explicitly trained on normal anatomy. Unlike prior ViT architectures that focus on improved attention mechanisms [7], [8], our contribution is orthogonal: we keep the backbone simple and invest effort in generating clinically interpretable attention maps. Compared with existing explainable AI approaches for chest X-rays [10], [11], our maps are driven by a generative prior instead of classifier gradients.

There are several promising avenues for improvement:

- **Joint training and fusion.** In this study the ViT and AE are trained independently. A natural extension is to jointly optimize them so that reconstruction error directly influences classification, for example through a multi-task loss or a small fusion network that takes both ViT logits and AE error statistics as input.
- **Stronger generative models.** More expressive generative models such as variational autoencoders [18], vector-quantized VAEs or diffusion models could learn a sharper separation between normal and abnormal patterns, potentially yielding more informative attention maps.
- **Better handling of class imbalance.** Rebalancing strategies (focal loss, class weights, oversampling) or threshold calibration could improve specificity for normal cases without sacrificing pneumonia recall.
- **Clinical evaluation.** Ultimately, the usefulness of generative attention maps should be judged by radiologists. Future work will involve user studies where clinicians rate the plausibility and helpfulness of the explanations.

VI. Conclusion

We presented an explainable generative framework for pneumonia detection on chest X-rays that couples a Vision Transformer classifier with a normal-lung autoencoder. The ViT achieves high AUC and near-perfect recall for pneumonia on the Kermany pediatric dataset, while the autoencoder produces reconstruction-error maps that highlight regions inconsistent with the learned normal prior. These maps serve as *Explainable Generative Attention Maps*, providing visual answers to the question "Why did the model predict pneumonia, and where?"

Although the global anomaly scores are not strongly discriminative, the spatial structure of the error maps offers clinically meaningful insights into both successful and failed predictions. Our results indicate that generative reconstruction-based explanations are a promising complement to transformer classifiers in medical imaging, and we hope that the released code will encourage further exploration of generative, interpretable models for chest X-ray analysis.

Data and Code Availability

All experiments were implemented in PyTorch and run on an NVIDIA T4 GPU in Google Colab. The full code, including training scripts and visualization utilities, is publicly available at:
https://github.com/HuzaifaRehman20/GenerativeAI-Pneumonia-Detection-Using-ViT-ExplainableAI.
The pediatric chest X-ray dataset used in this work can be downloaded from Mendeley Data under DOI:10.17632/rscbjbr9sj.2 [5].

References

[1] M. R. Hasan *et al.*, "Recent advancement of deep learning techniques for pneumonia detection using chest X-ray images," *Machine Learning with Applications*, 2024.

[2] P. Rajpurkar *et al.*, "CheXNet: Radiologist-level pneumonia detection on chest X-rays with deep learning," *arXiv preprint arXiv:1711.05225*, 2017.

[3] J. Irvin *et al.*, "CheXpert: A large chest radiograph dataset with uncertainty labels and expert comparison," in *Proc. AAAI*, 2019.

[4] D. Kermany *et al.*, "Identifying medical diagnoses and treatable diseases by image-based deep learning," *Cell*, vol. 172, no. 5, pp. 1122–1131, 2018.

[5] D. Kermany, "Labeled optical coherence tomography and chest X-ray images for classification," *Mendeley Data*, v2, 2018.

[6] A. Dosovitskiy *et al.*, "An image is worth 16×16 words: Transformers for image recognition at scale," in *Proc. ICLR*, 2021.

[7] Y. Gu *et al.*, "WSDC-ViT: a novel transformer network for pneumonia image classification based on windows scalable attention and dynamic ReLU convolutional modules," *Scientific Reports*, vol. 15, Article 27868, 2025.

[8] "Efficient pneumonia detection using Vision Transformers on chest X-rays," *Scientific Reports*, 2024.

[9] R. R. Selvaraju *et al.*, "Grad-CAM: Visual explanations from deep networks via gradient-based localization," in *Proc. ICCV*, 2017.

[10] S. M. Author *et al.*, "Comparative analysis of explainable AI models for pneumonia detection in chest X-rays using Grad-CAM," 2025, preprint.

[11] S. Biswas *et al.*, "FLPneXAINet: Federated deep learning and explainable AI for improved pneumonia prediction utilizing GAN-augmented chest X-ray data," *PLoS ONE*, vol. 20, no. 7, 2025.

[12] P. Kaushik *et al.*, "Modelling radiological features fusion and explainable AI for pneumonia detection using lung CT scans," *Computerized Medical Imaging and Graphics*, 2025.

[13] E. Ayan and H. Unver, "Diagnosis of pediatric pneumonia with ensemble of deep convolutional neural networks from chest X-ray images," *Arabian Journal for Science and Engineering*, 2022.

[14] M. Patidar *et al.*, "Deep learning-based pneumonia diagnosis from chest X-ray images using ensemble models," *ACM Computing Surveys*, 2024.

[15] F. Hosseinabadi and M. M. Rohani, "Deep learning approach for the diagnosis of pediatric pneumonia using chest X-ray imaging," 2025, preprint.

[16] A. Vaswani *et al.*, "Attention is all you need," in *Proc. NeurIPS*, 2017.

[17] J. Chen *et al.*, "TransUNet: Transformers make strong encoders for medical image segmentation," *arXiv preprint arXiv:2102.04306*, 2021.

[18] D. P. Kingma and M. Welling, "Auto-encoding variational Bayes," in *Proc. ICLR*, 2014.

[19] C. Zhang *et al.*, "Unsupervised anomaly detection based on deep autoencoder and clustering," *Mathematical Problems in Engineering*, 2021.

[20] L. Ruff *et al.*, "A unifying review of deep and shallow anomaly detection," *Proceedings of the IEEE*, 2021.

[21] S. Schlegl *et al.*, "f-AnoGAN: Fast unsupervised anomaly detection with generative adversarial networks," *Medical Image Analysis*, 2019.

[22] J. Author *et al.*, "Autoencoder-based glaucoma detection and localization from retinal fundus images," *Sensors*, 2025.

[23] R. Wightman, "PyTorch image models," 2019. [Online]. Available: https://github.com/rwightman/pytorch-image-models