2012 BYU Egypt Expedition - Fag el Gamous Cemetery

5-8-2012

Body Analysis Chart

Square ? Area _____ Burial # _____ Date No context

Observer(s) Basket case few bones available

I. Overall Impression

A. Preservation Index: I II III IV V

B. Hair Color _____

C. Observations (e.g., Artifacts, Burial Situation, Textiles) *continued on back*

II. Skull Analysis

A. Skull Features (gender estimation)

B. Skull Sutures (age estimation)

Sphenooccipital synchondrosis [basilar suture]
Closed (>age 18-25) *Not Closed*

Lambdoid suture [parietal-occipital]
Closed (>age 45-50) *Not Closed*

Squamos suture [parietal-temporal]
Closed (>age 60-65) *Not Closed*

B. Dentition (age estimation)

Tooth Attrition
I II III IV V

Tooth Eruption Age Estimate
_____

Skull Features		
	Male	Female
Robust	*YES*	*NO*
Supraorbital ridges	*HEAVY*	*LIGHT*
Orbit edge	*BLUNT*	*SHARP*
Parietal bossing	*NO*	*YES*
Gonion	*FLAT*	*POINTED*
Nuchal crest	*LARGER*	*SMALLER*
Zygomatic crest	*LONGER*	*SHORTER*

III. Pelvis Analysis

A. Pelvis Features (gender estimation) one side only

B. Pubic Symphisis (age estimation)
I II III IV V VI

Pelvis Features		
	Male	Female
Ventral arc	*YES*	*NO*
Subpubic angle	*NARROW*	*WIDE*
Sciatic notch	*NARROW*	*WIDE*
Medial IP ramus	*FLAT*	*RIDGED*

IV. Limb Analysis

A. Epiphyseal Union

Femur	Closed (>age 17)	Not Closed
Humerus	Closed (>age 14)	Not Closed

B. Head Diameter

Femur Head Diameter (<41.5mm=F; >45.5mm=M) 42

Humerus Head Diameter (<43mm=F; >48mm=M) _____

Observers Estimation of Age at Death

Observers Estimation of Gender *Female* *Male* *Indeterminate* possibly Male

V. Stature Estimation

[M=2.32(femur length) + 65.53; F=2.47(femur length) + 54.1]

A. Femur length (mm) 42 cm

B. Humerus length (mm) Not available Estimate of Stature _____

VI. Pathology

A. Osteophytosis None Slight Moderate Heavy

B. Caries and Periodontal Disease (noted on Figure 1)

C. Notes:

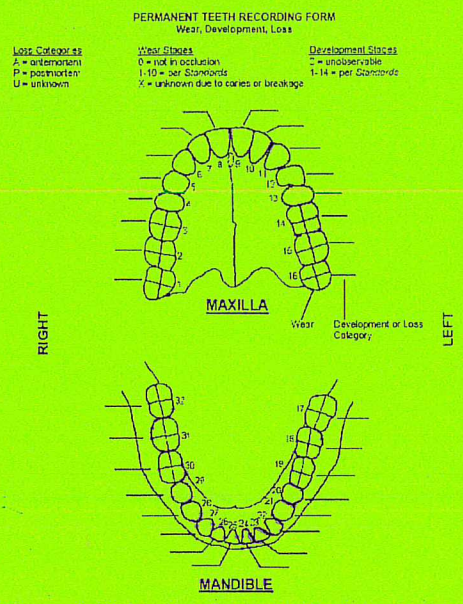

Figure 1: Caries (marked with filled circle) and Periodontal Disease (marked with X). Antemortem tooth loss is marked as darkened tooth.

VII. Samples

Observations (Artifacts, Burial situation, Textiles) *continued from front*

2012 BYU Egypt Expedition - Fag el Gamous Cemetery

Body Analysis Chart

5-6-2012

Square 160 N 30 / 200 40 E Area NE Burial # 17 NE Date Feb 2009

Observer(s) Child

I. Overall Impression

A. Preservation Index: I II III IV V

B. Hair Color Brown

C. Observations (e.g., Artifacts, Burial Situation, Textiles) *continued on back*

II. Skull Analysis

A. Skull Features (gender estimation)

B. Skull Sutures (age estimation)

Sphenooccipital synchondrosis [basilar suture]
Closed (>age 18-25) *Not Closed*

Lambdoid suture [parietal-occipital]
Closed (>age 45-50) *Not Closed*

Squamos suture [parietal-temporal]
Closed (>age 60-65) *Not Closed*

B. Dentition (age estimation)

Tooth Attrition

I II III IV V

Tooth Eruption Age Estimate

5 yrs

Skull Features		
	Male	Female
Robust	*YES*	*NO*
Supraorbital ridges	*HEAVY*	*LIGHT*
Orbit edge	*BLUNT*	*SHARP*
Parietal bossing	*NO*	*YES*
Gonion	*FLAT*	*POINTED*
Nuchal crest	*LARGER*	*SMALLER*
Zygomatic crest	*LONGER*	*SHORTER*

III. Pelvis Analysis

A. Pelvis Features (gender estimation)

B. Pubic Symphisis (age estimation)

I II III IV V VI

Pelvis Features		
	Male	Female
Ventral arc	*YES*	*NO*
Subpubic angle	*NARROW*	*WIDE*
Sciatic notch	*NARROW*	*WIDE*
Medial IP ramus	*FLAT*	*RIDGED*

IV. Limb Analysis

A. Epiphyseal Union

9 cm	Femur	Closed (>age 17)	Not Closed
15 cm	Humerus	Closed (>age 14)	Not Closed

B. Head Diameter

Femur Head Diameter (<41.5mm=F; >45.5mm=M) _____

Humerus Head Diameter (<43mm=F; >48mm=M) _____

Observers Estimation of Age at Death

Observers Estimation of Gender *Female* *Male* *Indeterminate*

V. Stature Estimation

[M=2.32(femur length) + 65.53; F=2.47(femur length) + 54.1]

A. Femur length (mm) _____

B. Humerus length (mm) _____ Estimate of Stature _____

VI. Pathology

A. Osteophytosis None Slight Moderate Heavy

B. Caries and Periodontal Disease (noted on Figure 1)

C. Notes:

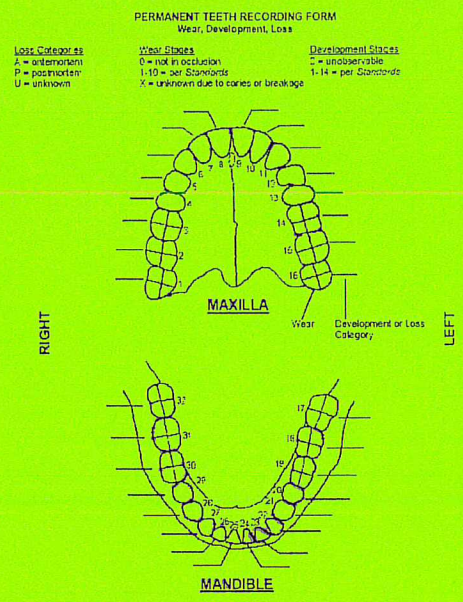

Figure 1: Caries (marked with filled circle) and Periodontal Disease (marked with X). Antemortem tooth loss is marked as darkened tooth.

VII. Samples

Observations (Artifacts, Burial situation, Textiles) *continued from front*

2012 BYU Egypt Expedition - Fag el Gamous Cemetery

Body Analysis Chart

Square 190/200 N 30/40 E Area NE Burial # 58 Date Feb 14, 2009 5-8-2012

Observer(s) Baby

I. Overall Impression

A. Preservation Index: 0 I II III IV V

B. Hair Color blonde fuzzy

C. Observations (e.g., Artifacts, Burial Situation, Textiles) *continued on back*

Tiny baby - nice textiles

II. Skull Analysis

A. Skull Features (gender estimation)

B. Skull Sutures (age estimation)

Sphenooccipital synchondrosis [basilar suture]
Closed (>age 18-25) *Not Closed*

Lambdoid suture [parietal-occipital]
Closed (>age 45-50) *Not Closed*

Squamos suture [parietal-temporal]
Closed (>age 60-65) *Not Closed*

B. Dentition (age estimation)

Tooth Attrition
I II III IV V

Tooth Eruption Age Estimate
_____

Skull Features		
	Male	Female
Robust	*YES*	*NO*
Supraorbital ridges	*HEAVY*	*LIGHT*
Orbit edge	*BLUNT*	*SHARP*
Parietal bossing	*NO*	*YES*
Gonion	*FLAT*	*POINTED*
Nuchal crest	*LARGER*	*SMALLER*
Zygomatic crest	*LONGER*	*SHORTER*

III. Pelvis Analysis

A. Pelvis Features (gender estimation)

B. Pubic Symphisis (age estimation)

I II III IV V VI

Pelvis Features		
	Male	Female
Ventral arc	*YES*	*NO*
Subpubic angle	*NARROW*	*WIDE*
Sciatic notch	*NARROW*	*WIDE*
Medial IP ramus	*FLAT*	*RIDGED*

IV. Limb Analysis

A. Epiphyseal Union

Femur	Closed (>age 17)	Not Closed
Humerus	Closed (>age 14)	Not Closed

B. Head Diameter

Femur Head Diameter (<41.5mm=F; >45.5mm=M) _____

Humerus Head Diameter (<43mm=F; >48mm=M) _____

Observers Estimation of Age at Death

Observers Estimation of Gender *Female* *Male* *Indeterminate*

V. Stature Estimation

[M=2.32(femur length) + 65.53; F=2.47(femur length) + 54.1]

A. Femur length (mm) _____

B. Humerus length (mm) _____ Estimate of Stature _____

VI. [illegible]ology

A. Osteophytosis None Slight Moderate Heavy

B. Caries and Periodontal Disease (noted on Figure 1)

C. Notes:

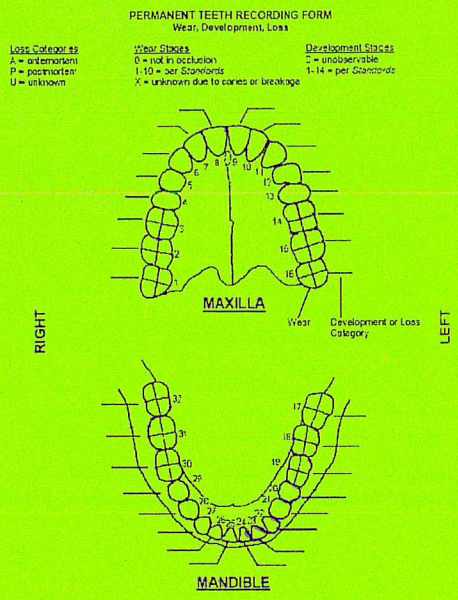

Figure 1: Caries (marked with filled circle) and Periodontal Disease (marked with X). Antemortem tooth loss is marked as darkened tooth.

VII. Samples

Observations (Artifacts, Burial situation, Textiles) *continued from front*

2012 BYU Egypt Expedition - Fag el Gamous Cemetery

Body Analysis Chart

Square 190/200N 30/40E Area NE Burial # 30 Date 2009 5-8-2012

Observer(s) Basket Case -

I. Overall Impression

A. Preservation Index: (I) II III IV V

B. Hair Color Blonde - Light Brown

C. Observations (e.g., Artifacts, Burial Situation, Textiles) *continued on back*

II. Skull Analysis

A. Skull Features (gender estimation)

B. Skull Sutures (age estimation)

Sphenooccipital synchondrosis [basilar suture]
Closed (>age 18-25) *Not Closed*

Lambdoid suture [parietal-occipital]
Closed (>age 45-50) *Not Closed*

Squamos suture [parietal-temporal]
Closed (>age 60-65) *Not Closed*

B. Dentition (age estimation)

Tooth Attrition

I (II) III IV V

Tooth Eruption Age Estimate

OLD

Skull Features		
	Male	Female
Robust	(YES)	*NO*
Supraorbital ridges	(HEAVY)	*LIGHT*
Orbit edge	(BLUNT)	*SHARP*
Parietal bossing	*NO*	*YES*
Gonion	(FLAT)	*POINTED*
Nuchal crest	(LARGER)	*SMALLER*
Zygomatic crest	(LONGER)	*SHORTER*

III. Pelvis Analysis

Pelvic walls - very thin
wear on humerus head

A. Pelvis Features (gender estimation)

B. Pubic Symphisis (age estimation)

I II III IV V VI

Pelvis Features		
	Male	Female
Ventral arc	*YES*	*NO*
Subpubic angle	*NARROW*	*WIDE*
Sciatic notch	(NARROW)	*WIDE*
Medial IP ramus	*FLAT*	*RIDGED*

IV. Limb Analysis

A. Epiphyseal Union

Femur	Closed (>age 17)	Not Closed
Humerus	(Closed (>age 14))	Not Closed

B. Head Diameter

Femur Head Diameter (<41.5mm=F; >45.5mm=M) 47.5

Humerus Head Diameter (<43mm=F; >48mm=M) 44.2

Observers Estimation of Age at Death

Observers Estimation of Gender *Female* (*Male*) *Indeterminate*

V. Stature Estimation

[M=2.32(femur length) + 65.53; F=2.47(femur length) + 54.1]

A. Femur length (mm) 44 cm

B. Humerus length (mm) 31.5

Estimate of Stature _____

VI. Pathology

A. Osteophytosis None Slight Moderate Heavy

B. Caries and Periodontal Disease (noted on Figure 1)

C. Notes:

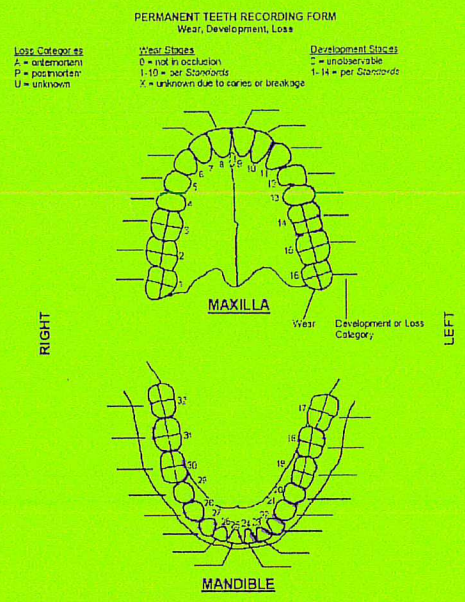

Figure 1: Caries (marked with filled circle) and Periodontal Disease (marked with X). Antemortem tooth loss is marked as darkened tooth.

VII. Samples

Observations (Artifacts, Burial situation, Textiles) *continued from front*

2012 BYU Egypt Expedition - Fag el Gamous Cemetery

Body Analysis Chart

Square 190/200 N 30/40 E Area NE Burial # 45 Date 2009 Today 5-8-2012

Observer(s) Small black beetles in hair Very deteriorated textiles

I. Overall Impression

A. Preservation Index: (I) II III IV V Basket case

B. Hair Color Pk. Brown

C. Observations (e.g., Artifacts, Burial Situation, Textiles) *continued on back*

II. Skull Analysis

A. Skull Features (gender estimation)

B. Skull Sutures (age estimation)

Sphenooccipital synchondrosis [basilar suture]
Closed (>age 18-25) *Not Closed*

Lambdoid suture [parietal-occipital]
Closed (>age 45-50) *Not Closed*

Squamos suture [parietal-temporal]
Closed (>age 60-65) *Not Closed*

B. Dentition (age estimation)

Tooth Attrition
I II (III) IV (V)

Tooth Eruption Age Estimate
35

Skull Features	Male	Female
Robust	(YES)	NO
Supraorbital ridges	(HEAVY)	LIGHT
Orbit edge	BLUNT	(SHARP)
Parietal bossing	NO	YES
Gonion	(FLAT)	POINTED
Nuchal crest	(LARGER)	SMALLER
Zygomatic crest	(LONGER)	SHORTER

III. Pelvis Analysis

only one pelvis

A. Pelvis Features (gender estimation) probably male

B. Pubic Symphisis (age estimation)

I II III IV V VI

Pelvis Features	Male	Female
Ventral arc	(YES)	NO
Subpubic angle	NARROW	WIDE
Sciatic notch	(NARROW)	WIDE
Medial IP ramus	FLAT	RIDGED

IV. Limb Analysis

A. Epiphyseal Union

Femur (Closed (>age 17)) Not Closed

Humerus (Closed (>age 14)) Not Closed

B. Head Diameter

Femur Head Diameter (<41.5mm=F; >45.5mm=M) 43.1

Humerus Head Diameter (<43mm=F; >48mm=M) 40

Observers Estimation of Age at Death

Observers Estimation of Gender *Female* (*Male*) *Indeterminate*

V. Stature Estimation

[M=2.32(femur length) + 65.53; F=2.47(femur length) + 54.1]

A. Femur length (mm) 42½ cm

B. Humerus length (mm) 29 cm

Estimate of Stature _____

VI. Pathology

A. Osteophytosis None Slight Moderate Heavy

B. Caries and Periodontal Disease (noted on Figure 1)

C. Notes:

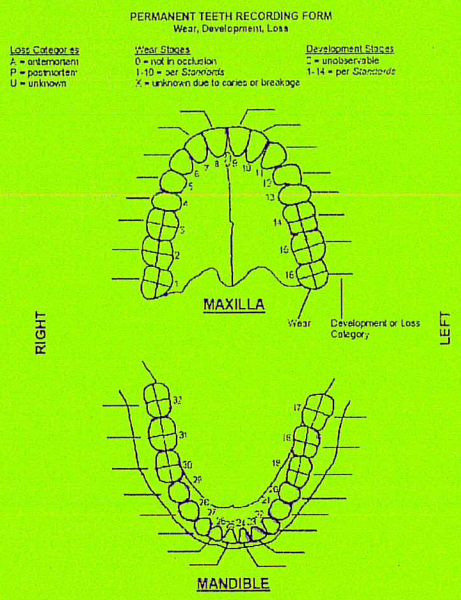

Figure 1: Caries (marked with filled circle) and Periodontal Disease (marked with X). Antemortem tooth loss is marked as darkened tooth.

VII. Samples

Observations (Artifacts, Burial situation, Textiles) *continued from front*

Windy day - we are staying inside magazine. Clear sky. Going to be Hot

2012 BYU Egypt Expedition - Fag el Gamous Cemetery

Body Analysis Chart

Square 190/200 N 30/40 E Area NE Burial # 23 Date 2009 Today - 5-8-2012

Observer(s) _____

I. Overall Impression

A. Preservation Index: (I) II III IV V

B. Hair Color Black, curly

C. Observations (e.g., Artifacts, Burial Situation, Textiles) *continued on back*

Burial is basket case - many bones that "don't fit" - 2 different Humerus bones - 2 different Pelvic bones - 2 child bones - 1 adult pelvis
1 child 1 adult.

Bits & pieces of small child

II. Skull Analysis

A. Skull Features (gender estimation)

B. Skull Sutures (age estimation)

Sphenooccipital synchondrosis [basilar suture]
(Closed (>age 18-25)) *Not Closed*

Lambdoid suture [parietal-occipital]
almost *Closed (>age 45-50)* *Not Closed*

Squamos suture [parietal-temporal]
Closed (>age 60-65) *Not Closed*

B. Dentition (age estimation)

Tooth Attrition

I II III (IV) V

Tooth Eruption Age Estimate

35 yrs

Skull Features	Male	Female
Robust	*YES* ?	*NO*
Supraorbital ridges	*HEAVY*	*LIGHT*
Orbit edge	*BLUNT*	*SHARP*
Parietal bossing	*NO*	*YES*
Gonion	*FLAT*	*POINTED*
Nuchal crest	*LARGER*	*SMALLER*
Zygomatic crest	*LONGER*	*SHORTER*

III. Pelvis Analysis

A. Pelvis Features (gender estimation) Only one broken side -

B. Pubic Symphisis (age estimation)

I II III IV V VI

Pelvis Features	Male	Female
Ventral arc	*YES*	*NO*
Subpubic angle	*NARROW*	*WIDE*
Sciatic notch	*NARROW*	*WIDE*
Medial IP ramus	*FLAT*	*RIDGED*

IV. Limb Analysis

A. Epiphyseal Union

Femur (Closed (>age 17)) Not Closed

Humerus Closed (>age 14) Not Closed

B. Head Diameter

Femur Head Diameter (<41.5mm=F; >45.5mm=M) 35.2 mm

Humerus Head Diameter (<43mm=F; >48mm=M) _____

Observers Estimation of Age at Death

Observers Estimation of Gender *Female* *Male* (*Indeterminate*)

V. Stature Estimation

[M=2.32(femur length) + 65.53; F=2.47(femur length) + 54.1]

A. Femur length (mm) 29cm

B. Humerus length (mm) none

Estimate of Stature _____

VI. Pathology

A. Osteophytosis None Slight Moderate Heavy

B. Caries and Periodontal Disease (noted on Figure 1)

C. Notes:

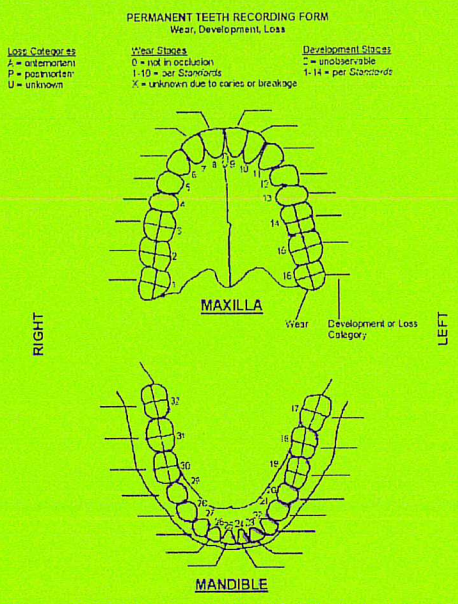

Figure 1: Caries (marked with filled circle) and Periodontal Disease (marked with X). Antemortem tooth loss is marked as darkened tooth.

VII. Samples

Observations (Artifacts, Burial situation, Textiles) *continued from front*

2012 BYU Egypt Expedition - Fag el Gamous Cemetery

Body Analysis Chart

Square 190/200 N 30/40 E Area NE Burial # 8 Date 2009 5-7-2012

Observer(s) _____

I. Overall Impression

A. Preservation Index: (I) II III IV V Basket Case

B. Hair Color _____

C. Observations (e.g., Artifacts, Burial Situation, Textiles) *continued on back*

II. Skull Analysis

A. Skull Features (gender estimation)

Skull Features	Male	Female
Robust	*YES*	*NO*
Supraorbital ridges	*HEAVY*	*LIGHT*
Orbit edge	*BLUNT*	*SHARP*
Parietal bossing	*NO*	*YES*
Gonion	*FLAT*	*POINTED*
Nuchal crest	*LARGER*	*SMALLER*
Zygomatic crest	*LONGER*	*SHORTER*

B. Skull Sutures (age estimation)

Sphenooccipital synchondrosis [basilar suture]
Closed (>age 18-25) *Not Closed*

Lambdoid suture [parietal-occipital]
Closed (>age 45-50) *Not Closed*

Squamos suture [parietal-temporal]
Closed (>age 60-65) *Not Closed*

B. Dentition (age estimation)

Tooth Attrition

I II III (IV) V

Tooth Eruption Age Estimate

_____

Very painful Decay - Many teeth missing & Jaw healed

III. Pelvis Analysis

A. Pelvis Features (gender estimation)

Pelvis Features	Male	Female
Ventral arc	*YES*	*NO*
Subpubic angle	*NARROW*	*WIDE*
Sciatic notch	*NARROW*	*WIDE*
Medial IP ramus	*FLAT*	*RIDGED*

B. Pubic Symphisis (age estimation)

I II III IV V VI

Broken Pelvis

IV. Limb Analysis

A. Epiphyseal Union

Femur (Closed (>age 17)) Not Closed

Humerus (Closed (>age 14)) Not Closed

B. Head Diameter

Femur Head Diameter (<41.5mm=F; >45.5mm=M) 40.0 mm

Humerus Head Diameter (<43mm=F; >48mm=M) 34.4

Observers Estimation of Age at Death possibly 60

Observers Estimation of Gender (*Female*) *Male* *Indeterminate*

V. Stature Estimation

[M=2.32(femur length) + 65.53; F=2.47(femur length) + 54.1]

A. Femur length (mm) 42 cm

B. Humerus length (mm) 29.5 cm

Estimate of Stature _____

VI. Pathology

A. Osteophytosis None Slight Moderate Heavy

B. Caries and Periodontal Disease (noted on Figure 1)

C. Notes:

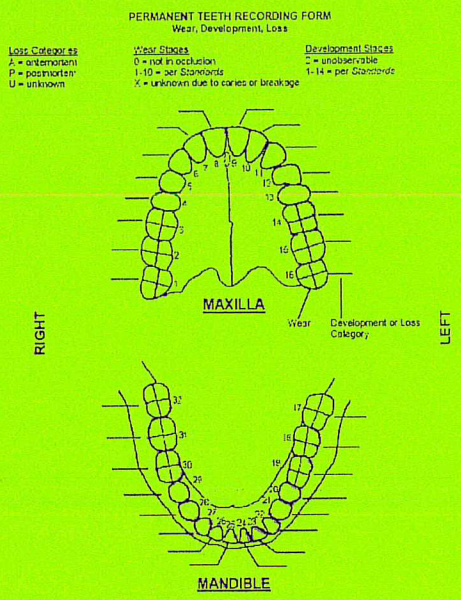

Figure 1: Caries (marked with filled circle) and Periodontal Disease (marked with X). Antemortem tooth loss is marked as darkened tooth.

VII. Samples

Observations (Artifacts, Burial situation, Textiles) *continued from front*

2012 BYU Egypt Expedition - Fag el Gamous Cemetery

Body Analysis Chart

Square 190/200 N 30/40 E Area NE Burial # 66 part 2 Date 2009 - Bottom half of 66 Today 5-6-2012

Observer(s) Nice Textiles - new fabric

I. Overall Impression

A. Preservation Index: I II III (IV) V - for half that we have

B. Hair Color No Hair

C. Observations (e.g., Artifacts, Burial Situation, Textiles) *continued on back*

II. Skull Analysis NO SKULL

A. Skull Features (gender estimation)

B. Skull Sutures (age estimation)

Sphenooccipital synchondrosis [basilar suture]
Closed (>age 18-25) *Not Closed*

Lambdoid suture [parietal-occipital]
Closed (>age 45-50) *Not Closed*

Squamos suture [parietal-temporal]
Closed (>age 60-65) *Not Closed*

B. Dentition (age estimation)

Tooth Attrition
I II III IV V

Tooth Eruption Age Estimate
_____

Skull Features		
	Male	Female
Robust	*YES*	*NO*
Supraorbital ridges	*HEAVY*	*LIGHT*
Orbit edge	*BLUNT*	*SHARP*
Parietal bossing	*NO*	*YES*
Gonion	*FLAT*	*POINTED*
Nuchal crest	*LARGER*	*SMALLER*
Zygomatic crest	*LONGER*	*SHORTER*

III. Pelvis Analysis

A. Pelvis Features (gender estimation)

B. Pubic Symphisis (age estimation)
I II III IV V VI

Pelvis Features		
	Male	Female
Ventral arc	*YES*	*NO*
Subpubic angle	*NARROW*	*WIDE*
Sciatic notch	*NARROW*	*WIDE*
Medial IP ramus	*FLAT*	*RIDGED*

IV. Limb Analysis

A. Epiphyseal Union

Femur (Closed (>age 17)) Not Closed
Humerus Closed (>age 14) Not Closed

B. Head Diameter

Femur Head Diameter (<41.5mm=F; >45.5mm=M) 36.5
Humerus Head Diameter (<43mm=F; >48mm=M) _____

Observers Estimation of Age at Death

Observers Estimation of Gender *Female* *Male* *Indeterminate*

V. Stature Estimation [M=2.32(femur length) + 65.53; F=2.47(femur length) + 54.1]

A. Femur length (mm) 40 cm

B. Humerus length (mm) _____ Estimate of Stature _____

VI. Pathology

A. Osteophytosis None Slight Moderate Heavy

B. Caries and Periodontal Disease (noted on Figure 1)

C. Notes:

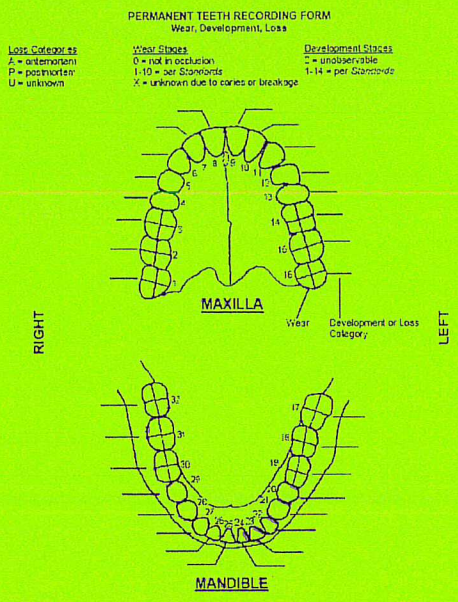

Figure 1: Caries (marked with filled circle) and Periodontal Disease (marked with X). Antemortem tooth loss is marked as darkened tooth.

VII. Samples

Observations (Artifacts, Burial situation, Textiles) *continued from front*

2012 BYU Egypt Expedition - Fag el Gamous Cemetery

Body Analysis Chart

Square 190/200 N 30/40 E Area NE Burial # 24 Date 2009 Today 5-7-2012

Observer(s) Very deteriorated - sticky - & difficult to liberate bones

I. Overall Impression

A. Preservation Index: I (II) III IV V

B. Hair Color Blonde

C. Observations (e.g., Artifacts, Burial Situation, Textiles) *continued on back*

no teeth -

II. Skull Analysis

A. Skull Features (gender estimation)

B. Skull Sutures (age estimation)

Sphenooccipital synchondrosis [basilar suture]
Closed (>age 18-25) *Not Closed*

Lambdoid suture [parietal-occipital]
Closed (>age 45-50) *Not Closed*

Squamos suture [parietal-temporal]
Closed (>age 60-65) *Not Closed*

B. Dentition (age estimation)

Tooth Attrition
I II III IV V

Tooth Eruption Age Estimate

_____

Skull Features		
	Male	Female
Robust can't tell	*YES*	*NO*
Supraorbital ridges ?	*HEAVY*	*LIGHT*
Orbit edge ?	*BLUNT*	*SHARP*
Parietal bossing	*NO*	*YES*
Gonion	*FLAT*	*POINTED*
Nuchal crest	(*LARGER*)	*SMALLER*
Zygomatic crest	*LONGER*	*SHORTER*

III. Pelvis Analysis

A. Pelvis Features (gender estimation)

B. Pubic Symphisis (age estimation)

I II III IV V VI

Pelvis Features		
	Male	Female
Ventral arc	*YES*	*NO*
Subpubic angle	*NARROW*	*WIDE*
Sciatic notch	*NARROW*	(*WIDE*)
Medial IP ramus	*FLAT*	*RIDGED*

IV. Limb Analysis

A. Epiphyseal Union

Femur	Closed (>age 17)	Not Closed
Humerus	Closed (>age 14)	Not Closed

B. Head Diameter

Femur Head Diameter (<41.5mm=F; >45.5mm=M) 40.2

Humerus Head Diameter (<43mm=F; >48mm=M) 39.9

Observers Estimation of Age at Death

Observers Estimation of Gender *Female* *Male* (*Indeterminate*)

V. Stature Estimation

[M=2.32(femur length) + 65.53; F=2.47(femur length) + 54.1]

A. Femur length (mm) 40.2 cm

B. Humerus length (mm) 28.8 cm.

Estimate of Stature _____

VI. Pathology

A. Osteophytosis None Slight Moderate Heavy

B. Caries and Periodontal Disease (noted on Figure 1)

C. Notes:

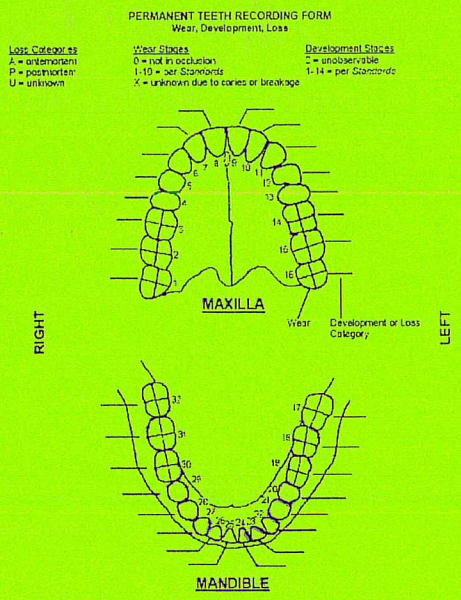

Figure 1: Caries (marked with filled circle) and Periodontal Disease (marked with X). Antemortem tooth loss is marked as darkened tooth.

VII. Samples

Observations (Artifacts, Burial situation, Textiles) *continued from front*

2012 BYU Egypt Expedition - Fag el Gamous Cemetery

5-7-2012

Body Analysis Chart

Square 190/200 N 30/40 E NE Area NE Burial # 21 Date 2009

Observer(s) Baby - Sub adult buried with Adult Adult in Lt Loosely wrapped

I. Overall Impression

A. Preservation Index: (I) II III IV V

B. Hair Color Brown

C. Observations (e.g., Artifacts, Burial Situation, Textiles) *continued on back*

Some color Textile - weft Ribs - inserted Red - Green - purple

II. Skull Analysis

A. Skull Features (gender estimation)

Skull Features	Male	Female
Robust	*YES*	*NO*
Supraorbital ridges	*HEAVY*	*LIGHT*
Orbit edge	*BLUNT*	*SHARP*
Parietal bossing	*NO*	*YES*
Gonion	*FLAT*	*POINTED*
Nuchal crest	*LARGER*	*SMALLER*
Zygomatic crest	*LONGER*	*SHORTER*

B. Skull Sutures (age estimation)

Sphenooccipital synchondrosis [basilar suture]
Closed (>age 18-25) *Not Closed*

Lambdoid suture [parietal-occipital]
Closed (>age 45-50) *Not Closed*

Squamos suture [parietal-temporal]
Closed (>age 60-65) *Not Closed*

B. Dentition (age estimation)

Tooth Attrition

(I) II III IV V

Tooth Eruption Age Estimate

5-6

But front tooth shows signs of adult teeth erupting

III. Pelvis Analysis

A. Pelvis Features (gender estimation)

Pelvis Features	Male	Female
Ventral arc	*YES*	*NO*
Subpubic angle	*NARROW*	*WIDE*
Sciatic notch	*NARROW*	*WIDE*
Medial IP ramus	*FLAT*	*RIDGED*

B. Pubic Symphisis (age estimation)

I II III IV V VI

IV. Limb Analysis

A. Epiphyseal Union

Femur	Closed (>age 17)	Not Closed
Humerus	Closed (>age 14)	Not Closed

B. Head Diameter

Femur Head Diameter (<41.5mm=F; >45.5mm=M) _____

Humerus Head Diameter (<43mm=F; >48mm=M) _____

Observers Estimation of Age at Death 5-6

Observers Estimation of Gender *Female* *Male* (*Indeterminate*)

V. Stature Estimation

[M=2.32(femur length) + 65.53; F=2.47(femur length) + 54.1]

A. Femur length (mm) 16.2 cm

B. Humerus length (mm) 12.2 cm

Estimate of Stature _____

VI. Pathology

A. Osteophytosis None Slight Moderate Heavy

B. Caries and Periodontal Disease (noted on Figure 1)

C. Notes:

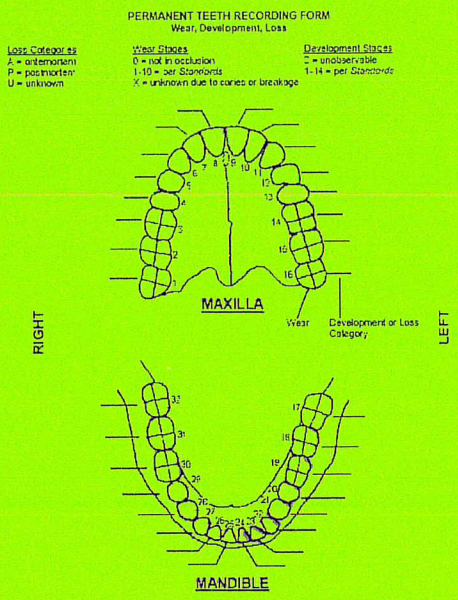

Figure 1: Caries (marked with filled circle) and Periodontal Disease (marked with X). Antemortem tooth loss is marked as darkened tooth.

VII. Samples

Observations (Artifacts, Burial situation, Textiles) *continued from front*

2012 BYU Egypt Expedition - Fag el Gamous Cemetery

Body Analysis Chart

Square 190/200 N 30/40 E Area NE Burial # 26 Date Jan 2019 Today 5-6-2012

Observer(s) Top knot wrapping on head Sub adult many support sticks

I. Overall Impression

A. Preservation Index: I (II) III IV V

B. Hair Color Redish brown

C. Observations (e.g., Artifacts, Burial Situation, Textiles) *continued on back*

no artifacts

Gender undetermined

II. Skull Analysis

A. Skull Features (gender estimation)

B. Skull Sutures (age estimation)

Sphenooccipital synchondrosis [basilar suture]
Closed (>age 18-25) *Not Closed*

Lambdoid suture [parietal-occipital]
Closed (>age 45-50) *Not Closed*

Squamos suture [parietal-temporal]
Closed (>age 60-65) *Not Closed*

B. Dentition (age estimation)

Tooth Attrition

I II III IV V

Tooth Eruption Age Estimate

5½ - 6 yrs

Skull Features		
	Male	Female
Robust	*YES*	*NO*
Supraorbital ridges	*HEAVY*	*LIGHT*
Orbit edge	*BLUNT*	*SHARP*
Parietal bossing	*NO*	*YES*
Gonion	*FLAT*	*POINTED*
Nuchal crest	*LARGER*	*SMALLER*
Zygomatic crest	*LONGER*	*SHORTER*

acute angle —

III. Pelvis Analysis

A. Pelvis Features (gender estimation)

B. Pubic Symphisis (age estimation)

I II III IV V VI

Pelvis Features		
	Male	Female
Ventral arc	*YES*	*NO*
Subpubic angle	*NARROW*	*WIDE*
Sciatic notch	*NARROW*	*WIDE*
Medial IP ramus	*FLAT*	*RIDGED*

IV. Limb Analysis

A. Epiphyseal Union

Femur	Closed (>age 17)	Not Closed
Humerus	Closed (>age 14)	Not Closed

B. Head Diameter

Femur Head Diameter (<41.5mm=F; >45.5mm=M) _____

Humerus Head Diameter (<43mm=F; >48mm=M) _____

Observers Estimation of Age at Death 5½ - 6 yrs (Tooth Attrition

Observers Estimation of Gender *Female* *Male* *Indeterminate*

V. Stature Estimation

[M=2.32(femur length) + 65.53; F=2.47(femur length) + 54.1]

A. Femur length (mm) 21.5

B. Humerus length (mm) 15.5

Estimate of Stature _____

VI. Pathology

A. Osteophytosis None Slight Moderate Heavy

B. Caries and Periodontal Disease (noted on Figure 1)

C. Notes:

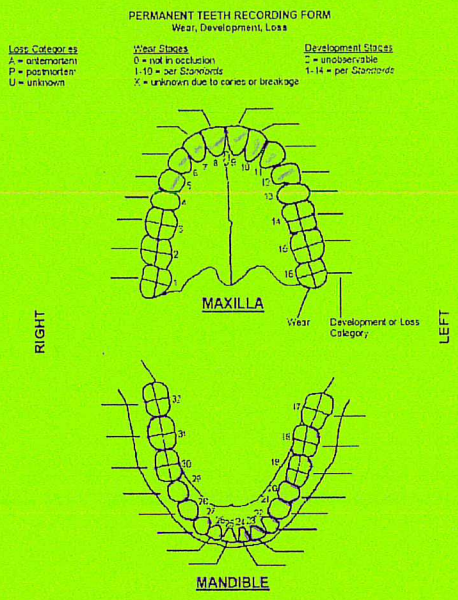

Figure 1: Caries (marked with filled circle) and Periodontal Disease (marked with X). Antemortem tooth loss is marked as darkened tooth.

VII. Samples

Observations (Artifacts, Burial situation, Textiles) *continued from front*

2012 BYU Egypt Expedition - Fag el Gamous Cemetery

Today 5-6-12

Body Analysis Chart

Square 190/200 N 30/40 E Area NE Burial # 6 Date Jan 2009

Observer(s) _____

I. Overall Impression

A. Preservation Index: I (II) III IV V

B. Hair Color Light Brown

C. Observations (e.g., Artifacts, Burial Situation, Textiles) *continued on back*

1 Large palm stick for strengthening - very visible
2nd one inside body.
3rd found

II. Skull Analysis

A. Skull Features (gender estimation)

B. Skull Sutures (age estimation)

Sphenooccipital synchondrosis [basilar suture]
Closed (>age 18-25) *(Not Closed)*
Lambdoid suture [parietal-occipital]
Closed (>age 45-50) *Not Closed*
Squamos suture [parietal-temporal]
Closed (>age 60-65) *Not Closed*

B. Dentition (age estimation)

Tooth Attrition
(I) II III IV V

Tooth Eruption Age Estimate
5+

Skull Features		
	Male	Female
Robust	*YES*	*NO*
Supraorbital ridges	*HEAVY*	*LIGHT*
Orbit edge	*BLUNT*	*SHARP*
Parietal bossing	*NO*	*YES*
Gonion	*FLAT*	*POINTED*
Nuchal crest	*LARGER*	*SMALLER*
Zygomatic crest	*LONGER*	*SHORTER*

III. Pelvis Analysis

A. Pelvis Features (gender estimation) Not able to determine

B. Pubic Symphisis (age estimation)

I II III IV V VI

Pelvis Features		
	Male	Female
Ventral arc	*YES*	*NO*
Subpubic angle	*NARROW*	*WIDE*
Sciatic notch	*NARROW*	*WIDE*
Medial IP ramus	*FLAT*	*RIDGED*

IV. Limb Analysis

A. Epiphyseal Union

Femur	Closed (>age 17)	Not Closed
Humerus	Closed (>age 14)	Not Closed

B. Head Diameter

Femur Head Diameter (<41.5mm=F; >45.5mm=M) _____
Humerus Head Diameter (<43mm=F; >48mm=M) _____

Observers Estimation of Age at Death 5+

Observers Estimation of Gender *Female* *Male* *Indeterminate*

V. Stature Estimation

[M=2.32(femur length) + 65.53; F=2.47(femur length) + 54.1]

A. Femur length (mm) 22.5 cm

B. Humerus length (mm) 13 Estimate of Stature _____

VI. Pathology

A. Osteophytosis None Slight Moderate Heavy

B. Caries and Periodontal Disease (noted on Figure 1)

C. Notes:

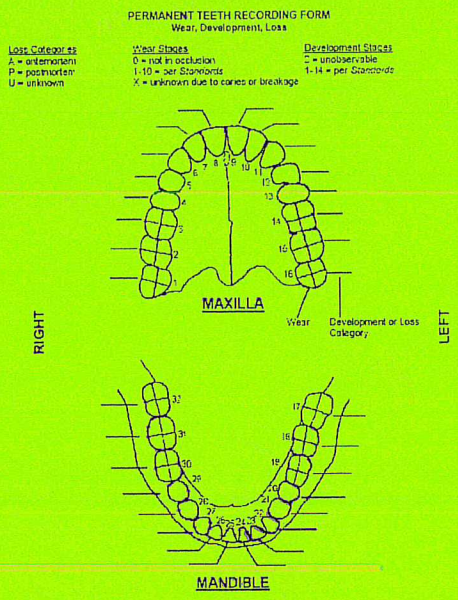

Figure 1: Caries (marked with filled circle) and Periodontal Disease (marked with X). Antemortem tooth loss is marked as darkened tooth.

VII. Samples

Observations (Artifacts, Burial situation, Textiles) *continued from front*

2012 BYU Egypt Expedition - Fag el Gamous Cemetery

Body Analysis Chart

Square 190/200 N 30/40 E Area NE Burial # 5 Date Jan 2009 5-6-2012

Observer(s) _____

I. Overall Impression

A. Preservation Index: I (II) III IV V

B. Hair Color red

C. Observations (e.g., Artifacts, Burial Situation, Textiles) *continued on back*

Two earrings - metal & a bead - one very deteriorated

Shape of head (and earrings) female

II. Skull Analysis

A. Skull Features (gender estimation)

B. Skull Sutures (age estimation)

Sphenooccipital synchondrosis [basilar suture]

Closed (>age 18-25) *Not Closed*

Lambdoid suture [parietal-occipital]

Closed (>age 45-50) *Not Closed*

Squamos suture [parietal-temporal]

Closed (>age 60-65) *Not Closed*

B. Dentition (age estimation)

Tooth Attrition

(I) II III IV V

Tooth Eruption Age Estimate

4-5

Skull Features		
	Male	Female
Robust	*YES*	*NO*
Supraorbital ridges	*HEAVY*	*LIGHT*
Orbit edge	*BLUNT*	(*SHARP*)
Parietal bossing	*NO*	*YES*
Gonion	(*FLAT*)	*POINTED*
Nuchal crest	*LARGER*	*SMALLER*
Zygomatic crest	*LONGER*	*SHORTER*

III. Pelvis Analysis

A. Pelvis Features (gender estimation)

B. Pubic Symphisis (age estimation)

I II III IV V VI

Pelvis Features		
	Male	Female
Ventral arc	*YES*	*NO*
Subpubic angle	*NARROW*	*WIDE*
Sciatic notch	*NARROW*	*WIDE*
Medial IP ramus	*FLAT*	*RIDGED*

IV. Limb Analysis

A. Epiphyseal Union

Femur	Closed (>age 17)	Not Closed
Humerus	Closed (>age 14)	Not Closed

B. Head Diameter

Femur Head Diameter (<41.5mm=F; >45.5mm=M) _____

Humerus Head Diameter (<43mm=F; >48mm=M) _____

Observers Estimation of Age at Death

Observers Estimation of Gender *Female* *Male* *Indeterminate*

V. Stature Estimation

[M=2.32(femur length) + 65.53; F=2.47(femur length) + 54.1]

A. Femur length (mm) _____

B. Humerus length (mm) _____ Estimate of Stature _____

VI. Pathology

A. Osteophytosis None Slight Moderate Heavy

B. Caries and Periodontal Disease (noted on Figure 1)

C. Notes:

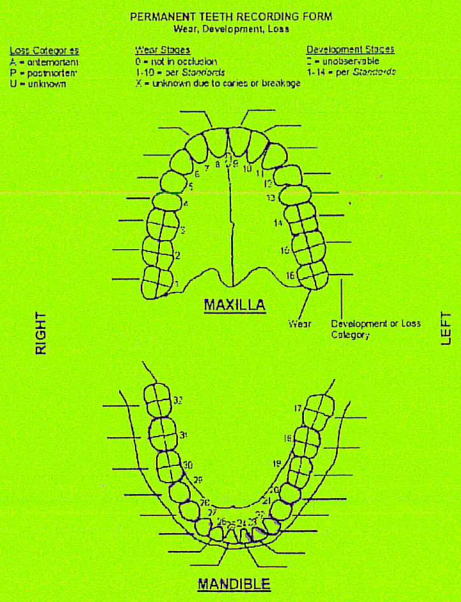

Figure 1: Caries (marked with filled circle) and Periodontal Disease (marked with X). Antemortem tooth loss is marked as darkened tooth.

VII. Samples

Observations (Artifacts, Burial situation, Textiles) *continued from front*

2012 BYU Egypt Expedition - Fag el Gamous Cemetery

Body Analysis Chart

Square 190/200 N 30/40 E Area NE Burial # 4 Date Jan 2009 Today 5-6-12

Observer(s) Sub adult.

I. Overall Impression

A. Preservation Index: I (II) III IV V Palm sticks keeping it together

B. Hair Color Brown & Braided

C. Observations (e.g., Artifacts, Burial Situation, Textiles) *continued on back*

Length of burial before unwrapping
Braided

II. Skull Analysis

A. Skull Features (gender estimation)

B. Skull Sutures (age estimation)

Sphenooccipital synchondrosis [basilar suture]
Closed (>age 18-25) *Not Closed*
Lambdoid suture [parietal-occipital]
Closed (>age 45-50) *Not Closed*
Squamos suture [parietal-temporal]
Closed (>age 60-65) *Not Closed*

B. Dentition (age estimation)

Tooth Attrition
I II III IV (V)
Tooth Eruption Age Estimate
8-10 2 front permenent teeth visibly starting to erupt

Skull Features		
	Male	Female
Robust	*YES*	(*NO*)
Supraorbital ridges	*HEAVY*	(*LIGHT*)
Orbit edge	*BLUNT*	*SHARP* ?
Parietal bossing	*NO*	*YES*
Gonion	*FLAT*	(*POINTED*)
Nuchal crest	*LARGER*	(*SMALLER*)
Zygomatic crest	*LONGER*	(*SHORTER*)

III. Pelvis Analysis

A. Pelvis Features (gender estimation)

B. Pubic Symphisis (age estimation)

I II III IV V VI

Pelvis Features		
	Male	Female
Ventral arc	*YES*	*NO*
Subpubic angle	*NARROW*	*WIDE*
Sciatic notch	*NARROW*	*WIDE*
Medial IP ramus	*FLAT*	*RIDGED*

IV. Limb Analysis

A. Epiphyseal Union Not yet

Femur	Closed (>age 17)	Not Closed
Humerus	Closed (>age 14)	Not Closed

B. Head Diameter

Femur Head Diameter (<41.5mm=F; >45.5mm=M) _____
Humerus Head Diameter (<43mm=F; >48mm=M) _____

Observers Estimation of Age at Death

Observers Estimation of Gender (*Female*) *Male* *Indeterminate*

V. Stature Estimation

[M=2.32(femur length) + 65.53; F=2.47(femur length) + 54.1]

A. Femur length (mm) 24.5 cm

B. Humerus length (mm) 18.5 Estimate of Stature _____

VI. Pathology

A. Osteophytosis None Slight Moderate Heavy

B. Caries and Periodontal Disease (noted on Figure 1)

C. Notes:

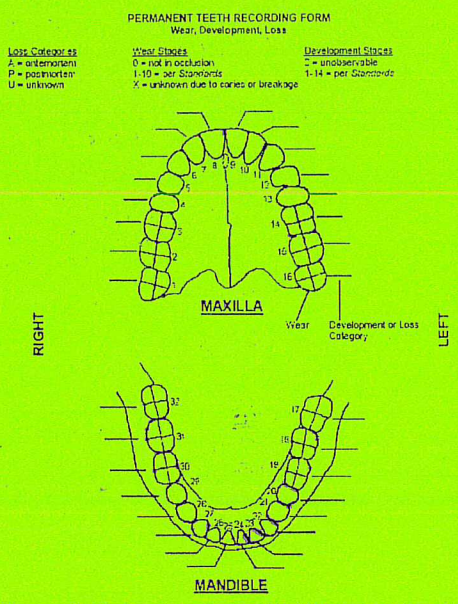

Figure 1: Caries (marked with filled circle) and Periodontal Disease (marked with X). Antemortem tooth loss is marked as darkened tooth.

VII. Samples

Observations (Artifacts, Burial situation, Textiles) *continued from front*