■ Cardiac Arrhythmia Report

■ **Patient Name:** Suresh

■ **Status:** **Old Anterior Myocardial Infarction**

■ **QRS Deviation:** 73.86%

■■ Risk Assessment & Recommendations

→ **HIGH**

→ ■ **Urgent Attention Needed: Seek immediate medical care for worsening symptoms.**

→ ■ **Continuous Monitoring: ECG or Holter monitoring may be required.**

→ ■ **Avoid Physical Stress: Restrict strenuous activities and emotional stress.**

→ ■ **Quit Smoking & Alcohol: Eliminate habits that increase cardiac risk.**

■ Cardiac Parameters

Parameter	Value
AGE	51.0
GENDER	Male
HEIGHT	160.0
WEIGHT	83.0
QRS	96
QT	400
T	301
PR	147
P	82
HEART RATE	71

■ ECG Signals

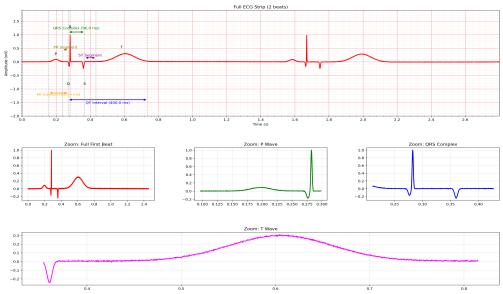
Full ECG Strip (2 beats)
Zoom: Full First Beat
Zoom: P Wave
Zoom: QRS Complex
Zoom: T Wave

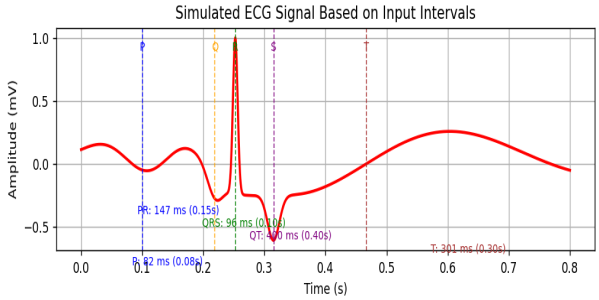
Simulated ECG Signal Based on Input Intervals
P
Q
R
S
T
PR: 147 ms (0.15s)
QRS: 96 ms (0.10s)
QT: 400 ms (0.40s)
P: 82 ms (0.08s)
T: 301 ms (0.30s)
Amplitude (mV)
Time (s)