■ Cardiac Arrhythmia Report

■ **Patient Name:** Suresh

■ **Status:** **Old Anterior Myocardial Infarction**

■ **QRS Deviation:** 73.86%

■ Diagnostic Summary

Diagnosis Status:	**Old Anterior Myocardial Infarction**
Risk Classification:	**HIGH**

■ ECG Interval Analysis

Parameter	Value (ms)	Status
QRS Duration	96	✓ Analyzed
QT Interval	400	✓ Analyzed
PR Interval	147	✓ Analyzed
P Wave Duration	82	✓ Analyzed
T Wave Duration	301	✓ Analyzed

■■ Medical Recommendations

Precautionary Measures:
- ■ Urgent Attention Needed: Seek immediate medical care for worsening symptoms.
- ■ Continuous Monitoring: ECG monitoring may be required.

Lifestyle Modifications:
- ■ Avoid Physical Stress: Restrict strenuous activities and emotional stress.
- ■ Quit Smoking & Alcohol: Eliminate habits that increase cardiac risk.

■■ **Important:** Please consult with a cardiologist immediately for further evaluation and treatment planning.

■ Generated ECG Waveform

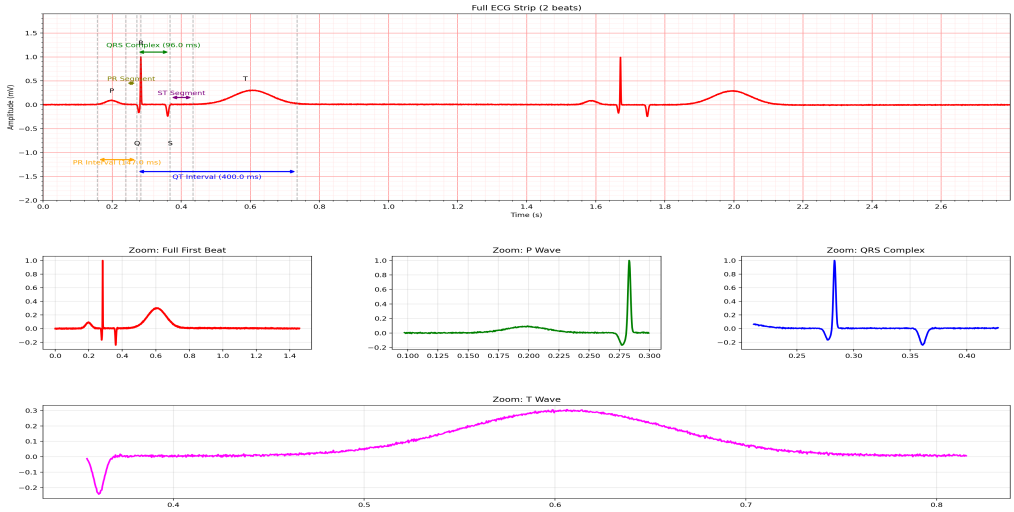

The above waveform was computationally generated based on the measured ECG intervals.

Medical Disclaimer: This report is generated by an AI-assisted diagnostic system and should be used in conjunction with professional medical advice. Always consult a qualified healthcare provider for diagnosis and treatment.

© 2025 Cardiac Arrhythmia Detection System | Confidential Medical Record