Chronic Central Serous Chorioretinopathy Imaged by Optical Coherence Tomographic Angiography

MADDALENA QUARANTA-EL MAFTOUHI, ADIL EL MAFTOUHI, AND CHIARA M. EANDI

• PURPOSE: To describe optical coherence tomographic (OCT) angiography findings in chronic central serous chorioretinopathy (CSC), and to characterize their OCT B-scans by means of the split-spectrum amplitude-decorrelation angiography algorithm.

• DESIGN: Evaluation of an imaging technique in a cohort of patients.

• METHODS: Fluorescein (FA) and indocyanine green (ICGA) angiography (Heidelberg Spectralis, Heidelberg, Germany), OCT angiography, and OCT angiography with the split-spectrum amplitude-decorrelation angiography algorithm (XR Optovue, Fremont, California, USA) were performed. A qualitative analysis of the entire imaging data was done.

• RESULTS: Twelve eyes of 10 patients were included. Mean visual acuity was 20/30. All eyes presented findings consistent with chronic CSC (lasting more than 6 months) on biomicroscopic examination, autofluorescence, FA, ICGA, and OCT. ICGA showed the characteristic choroidal hyperpermeability, while there was no evidence of choroidal neovascularization (CNV). OCT B-scans showed 2 distinct profiles of the retinal pigment epithelium (RPE): a slight RPE detachment with small undulations was evident in 7 of 12 eyes, while 5 eyes presented a flat RPE profile. OCT angiography in 7 eyes (58%) revealed the presence of a distinct CNV corresponding to the ICGA hyperpermeability. The qualitative analysis of the OCT B-scans compared to the OCT angiographic images demonstrated that the CNV corresponded to the small undulations within the slight RPE detachment, confirming its vascularized nature. On the contrary, OCT angiography showed a normal choroidal circulation in the remaining 5 eyes (42%) with a flat RPE profile.

• CONCLUSIONS: OCT angiography allows detection of CNV in chronic CSC not visible with other imaging techniques. CNV corresponds to the small undulating RPE detachment on B-scan. This might allow an appropriate treatment resulting in a better visual outcome. (Am J Ophthalmol 2015;160(3):581–587. © 2015 by Elsevier Inc. All rights reserved.)

Accepted for publication Jun 18, 2015.

From the Centre Ophtalmologique Rabelais, Lyon, France (M.Q.E.M., A.E.M.); and Department of Surgical Sciences, Eye Clinic, University of Torino, Torino, Italy (C.M.E.).

Inquiries to Chiara M. Eandi, Department of Surgical Science, Eye Clinic, University of Torino, Via Juvarra 19, 10122 Torino, Italy; e-mail: ceandi@gmail.com

CHRONIC CENTRAL SEROUS CHORIORETINOPATHY (CSC) is characterized by widespread alterations in the retinal pigment epithelium (RPE) that are associated with serous detachment of the neurosensory retina.[1]

Fluorescein angiography (FA) shows 1 or multiple leaking points and diffuse alterations at the level of the RPE. Indocyanine green (ICG) angiography reveals hyperfluorescent areas that correspond to leaking points, and the choroid appears partly hypofluorescent owing to RPE atrophy and partly hyperfluorescent owing to the choriocapillary hyperpermeability.[2–4]

Optical coherence tomographic (OCT) examinations reveal subretinal fluid and an irregular profile of the internal margin of the neurosensory retinal detachment secondary to a thickening and elongation of photoreceptor outer segments. A double-layer sign may appear with an undulating RPE profile, a hyporeflective middle layer, and an intact or slightly thickened Bruch membrane.[5,6]

Recently, new imaging technologies have developed that allow for new insights in the visualization of normal and pathologic vascularization. Specifically, software called "split-spectrum amplitude-decorrelation angiography" allows for the visualization of both the inner and outer retinal vascular plexi and the choriocapillary layer without the need for dye injection.[7,8] It is usually difficult to visualize these vascular complexes with FA and ICG angiography. This algorithm enables the noninvasive visualization of vessels in the posterior part of the eye with a segmentation of the different layers using the "en face" OCT modality.

The purposes of this study were to describe OCT angiographic findings in chronic CSC and to characterize the B-scan OCT via split-spectrum amplitude-decorrelation angiography and en face modality findings in the same cohort.

PATIENTS AND METHODS

THIS STUDY WAS APPROVED BY THE INSTITUTIONAL REVIEW Board of the Fédération France Macula, informed consent was obtained from all of the patients, and all research and data collection complied with the Declaration of Helsinki.

0002-9394/$36.00
http://dx.doi.org/10.1016/j.ajo.2015.06.016
© 2015 BY ELSEVIER INC. ALL RIGHTS RESERVED.

TABLE. Demographic, Functional, and Tomographic Findings of the Cohort of Eyes With Chronic Central Serous Chorioretinopathy

Eye #	Sex	Age (Years)	Visual Acuity (Snellen)	Choroidal Thickness (μm)	Subretinal Fluid	RPE Profile	OCT Angiography
1	Female	53	20/40	530	Yes	Undulated	Choroidal neovascularization
2	Male	62	20/40	325	Yes	Undulated	Choroidal neovascularization
3	Female	52	20/30	570	Yes	Undulated	Choroidal neovascularization
4	Female	52	20/20	470	No	Undulated	Choroidal neovascularization
5	Male	54	20/20	440	Yes	Flat	No choroidal neovascularization
6	Female	64	20/40	315	Yes	Flat	No choroidal neovascularization
7	Male	50	20/40	490	Yes	Flat	No choroidal neovascularization
8	Female	61	20/30	228	No	Undulated	Choroidal neovascularization
9	Male	50	20/30	490	Yes	Flat	No choroidal neovascularization
10	Male	49	20/30	380	Yes	Flat	No choroidal neovascularization
11	Female	54	20/30	280	Yes	Undulated	Choroidal neovascularization
12	Female	54	20/20	290	No	Undulated	Choroidal neovascularization

OCT = optical coherence tomography; RPE = retinal pigment epithelium.

We enrolled consecutive cases of chronic CSC seen at our clinic, which is the third-largest referral center for retinal pathologies, between June 2014 and December 2014.

Every patient underwent a complete ophthalmic examination that included the following: a best-corrected visual acuity measurement with the Early Treatment Diabetic Retinopathy Study (ETDRS) charts, anterior segment examination, intraocular pressure measurement by applanation tonometry, and dilated fundus biomicroscopy. Fluorescein and ICG angiography (Heidelberg Spectralis, Heidelberg, Germany), spectral-domain OCT (SD OCT), and OCT angiography using the split-spectrum amplitude-decorrelation angiography algorithm were also performed (RTVue XR Avanti with AngioVue; Optovue Inc, Fremont, California, USA). The instrument used in the OCT angiography was based on the Optovue RTVue XR Avanti (Optovue, Inc) and was used to obtain amplitude-decorrelated angiography images. This instrument has an A-scan rate of 70 000 scans per second and uses a light source centered at 840 nm and a bandwidth of 50 nm. Each OCT angiography volume contained 304 × 304 A-scans with 2 consecutive B-scans that were captured at each fixed position before proceeding to the next sampling location. Split-spectrum amplitude-decorrelation angiography was used to extract the OCT angiography information. Each OCT angiography volume was acquired over 3 seconds, and 2 orthogonal OCT angiography volumes were acquired to perform motion correction to minimize the motion artifacts arising from microsaccades and fixation changes. The angiography information is displayed as the average of the decorrelation values when viewed perpendicularly through the thickness being evaluated. The modifications in reflectivity are directly linked to blood flow. The horizontal and vertical scans were combined with an algorithm that compensates for the motion of the patient's eyes (ie, motion correction technology [MCT]) to create a 3-dimensional volume of the retinal vascularization. The en face imaging enabling us to focus on the superficial vessels by choosing the inner limiting membrane as a reference or to go deeper to focus on new vessels by choosing the RPE layer as a reference. A flat reference plan that makes the C-scan independent of the patient's retina is also available.

A qualitative analysis and comparisons of the entire imaging data set were conducted. Regarding the OCT angiography, in all cases, we set the reference at the level of the RPE. Two retinal specialists (M.Q.E.M. and C.M.E.) independently read the B-scans and OCT angiographic images to determine the presence of choroidal neovascularization (CNV) and its location in relation to the pigment epithelium detachment (PED).

RESULTS

TWELVE EYES FROM 10 PATIENTS (5 WOMEN AND 5 MEN) were included. The patients ranged in age from 49 to 64 years with a mean age of 54.6 years. All of the patients were white (Table). The diagnoses of CSC were already established in 5 patients and newly formulated in the other 5 patients based on clinical history and fundus and angiographic features. Six patients had histories of steroid use. All patients presented with a history of long-lasting (>6 months) visual impairment. The ETDRS best-corrected visual acuities ranged from 20/40 to 20/20 (mean 20/30).

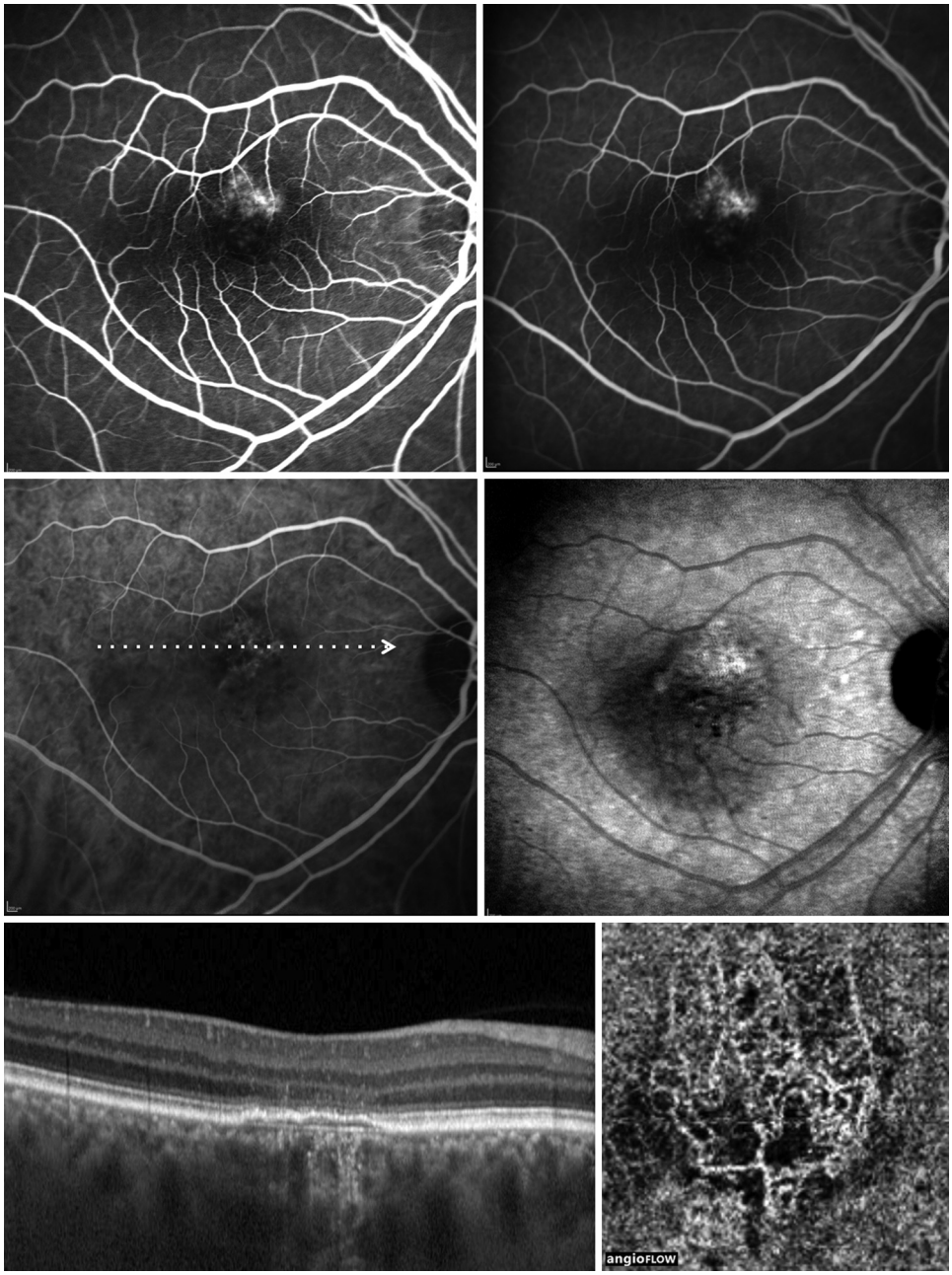

FIGURE 1. Chronic central serous chorioretinopathy and choroidal neovascular network visible on optical coherence tomographic angiography. (Top left) Early-phase fluorescein angiography of the right eye of a 57-year-old patient who had been followed for chronic central serous chorioretinopathy for 5 years. A hyperfluorescent superofoveal area is visible, showing no leakage on late phase angiograms (Top right). (Middle left) Early-phase indocyanine green (ICG) angiography shows a hyperfluorescent area without a clear branching vascular network. (Middle right) Late-phase ICG angiography depicting an area of choroidal hyperpermeability with focal hypofluorescent spots corresponding to retinal pigment epithelium (RPE) defects. (Bottom left) Horizontal B-scan optical coherence tomography (OCT) of the hyperfluorescent area reveals the presence of an irregular RPE with a slight pigment epithelium detachment and opaque content. (Bottom right) OCT angiography with the split-spectrum amplitude-decorrelation angiography algorithm at the level of the choroid demonstrates the presence of a distinct neovascular network in the same area as the ICG hyperfluorescence.

The anterior segment examinations did not reveal any relevant features.

The biomicroscopic fundus examinations revealed serous retinal detachment at the posterior pole, particularly in the macular region, and multiple zones of RPE alterations (hypo- and hyperpigmentations and atrophic changes). Neither drusen nor subretinal hemorrhages were detected.

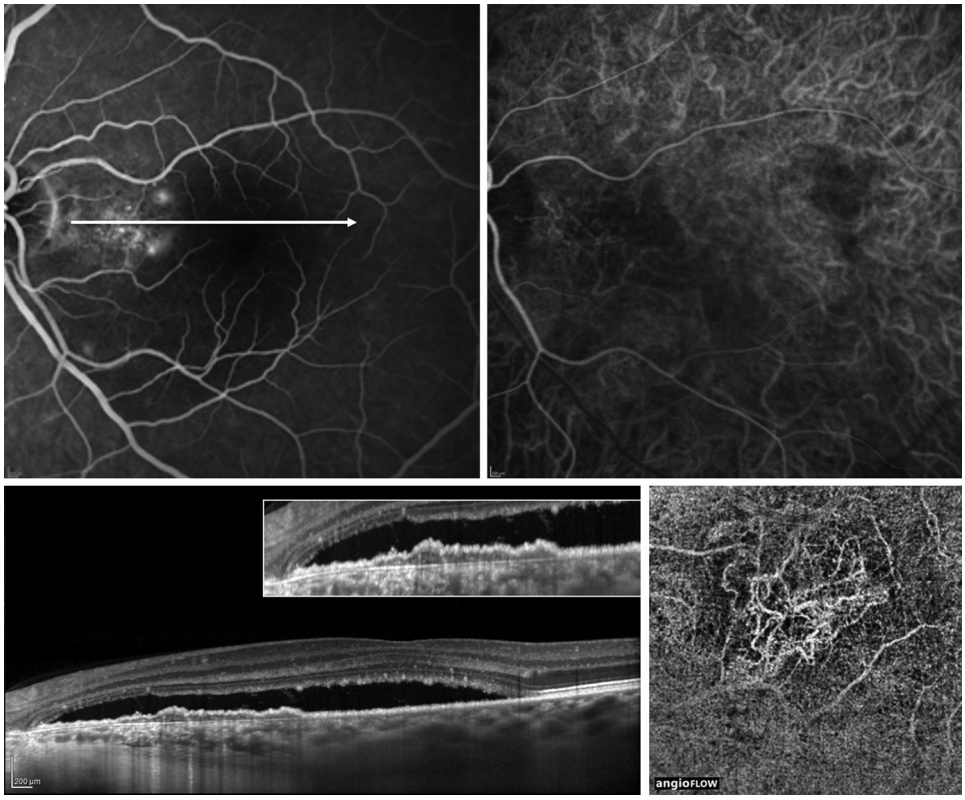

FIGURE 2. Chronic central serous chorioretinopathy and irregular pigment epithelium detachment. (Top left) Fluorescein angiography of the left eye of a 59-year-old patient with a history of chronic central serous chorioretinopathy for 4 years. A peripapillary hyperfluorescent zone with multiple leaking points is visible. (Top right) On the early-phase indocyanine green angiography, no distinct choroidal neovascularization is evident; only large choroidal vessels are visible. (Bottom left) Horizontal B-scan optical coherence tomography (OCT) showing subretinal fluid involving the fovea and an irregular pigment epithelium profile with a small pigment epithelium detachment (PED) in the same peripapillary hyperfluorescent area. Insert: higher magnification of the PED. (Bottom right) The corresponding OCT angiography image with the split-spectrum amplitude-decorrelation angiography algorithm set at the level of the choroid, demonstrating the presence of a distinct neovascular network.

All eyes presented features consistent with chronic CSC on the fundus autofluorescence, FA, ICG angiography, and SD OCT examinations. Five eyes demonstrated granular hyperautofluorescence in the macular region, and 7 exhibited a central confluent hypoautofluorescent pattern. In 8 eyes, descendent tracts were also evident.

On fluorescein angiography, the affected zones exhibited alternating hyperfluorescent and hypofluorescent spots in the early phase; in the late phase, hyperfluorescent leaking points (in 7 eyes, 58%) or small leaking areas (5 eyes, 42%) were visible and stained the serous detachment of the retina. At the posterior pole, multiple zones of RPE alterations were also visualized in 8 of the 12 eyes.

ICG angiography revealed choroidal hyperfluorescence in all eyes that was consistent with both choroidal hyperpermeability and a subretinal neovascular network. No signs of leakage or choroidal polyps were evident on the mid- or late-stage angiograms.

The B-scan SD OCT examinations demonstrated the presence of neurosensory retinal detachments and subretinal fluid in 9 of the 12 eyes (75%) and small pigment epithelium detachments in 2 of the 12 eyes (17%). Five eyes (42%) exhibited elongation of the photoreceptor outer segment on the internal margin of the retinal detachment, and none of the 12 eyes presented with intraretinal cystic degeneration. The RPE layers exhibited distinct profiles. Specifically, a slight retinal PED with small undulations and increased reflectivity between the RPE and Bruch membrane was evident in 7 of the 12 eyes (58%), and the remaining 5 eyes (42%) presented a flat RPE profile. The mean subfoveal choroidal thickness was 400 μm (range 570–228 μm) (Table).

OCT angiography with the split-spectrum amplitude-decorrelation angiography algorithm revealed normal retinal circulation in all of the eyes. In 7 of the 12 eyes (58%), outer retinal OCT angiogram revealed the presence of a distinct CNV network in a pattern that was strikingly similar to that of the ICG hyperfluorescence (Figure 1).

A qualitative comparison of the B-scan SD OCT and en face OCT scans with the OCT angiographic images revealed that the neovascular networks corresponded to

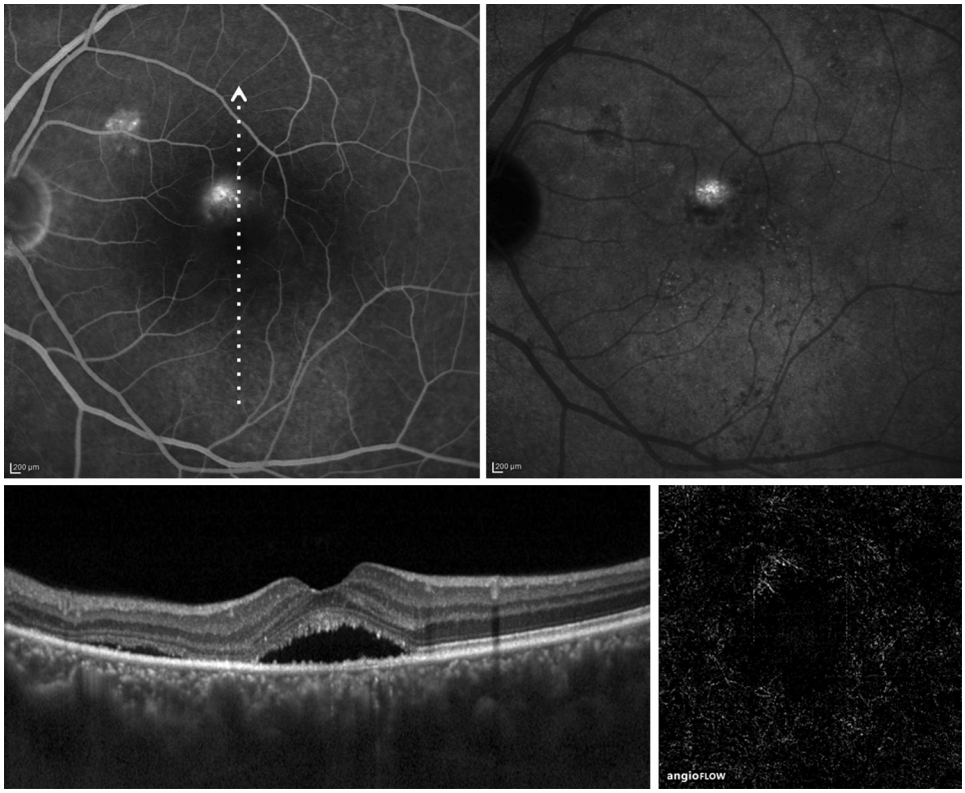

FIGURE 3. Chronic central serous chorioretinopathy and a flat retinal pigment epithelium profile. (Top left) Fluorescein angiography of the left eye of a 58-year-old patient who had been followed for chronic central serous chorioretinopathy for 7 years. A hyperfluorescent superofoveal point is visible with subfoveal neurosensory detachment and diffuse hyperfluorescence inferior to the macula, corresponding to a gravitational tract. (Top right) Mid-phase indocyanine green angiography evidencing a corresponding area of choroidal hyperpermeability without a branching vascular network. (Bottom left) Vertical B-scan optical coherence tomography (OCT) showing a subfoveal neurosensory retinal detachment with an irregular internal profile. A small detachment is also visible on the inferior part and corresponds to a gravitational tract. The retinal pigment epithelium profile is flat and regular. The choroidal thickness is increased. (Bottom right) OCT angiography image of the central retina with the split-spectrum amplitude-decorrelation angiography algorithm set at the level of the choroid, demonstrating the absence of a distinct neovascular network.

the small undulations within the slight PEDs and confirmed their vascularized nature (Figure 2). In contrast, the OCT angiography revealed normal choroidal circulation in the remaining 5 of the 12 eyes (42%) with flat RPE profiles on the B-scan SD OCT images (Table, Figure 3).

DISCUSSION

THIS STUDY SHOWED THAT CNV COMPLICATING CHRONIC CSC is only detectable with OCT angiography. Although choroidal neovascularization is a well-known complication in eyes with chronic CSC, it is considered to be a rare occurrence. The higher incidence of choroidal neovascularization in this case series might be related to the nature of the tertiary referring center of our clinic and possibly to the imaging capability of the OCT angiography. In 2000, Yannuzzi and associates reported 13 patients with polypoidal choroidal vasculopathy (PCV) masquerading as CSC.[9] At that time, SD OCT was not available, and the diagnoses of PCV were based on the presence of choroidal hyperpermeability on ICG angiography. This contrasts our study, in which all of the eyes exhibited choroidal hyperfluorescence on ICG angiography without clear evidence of neovascular networks. Recently, Yang and associates[10] reported a conversion of CSC to PCV. Similarly, there was also no evidence of CNV on either ICG angiography or OCT examination in this case series.[10] OCT is particularly useful for detecting PCV because polypoidal structures beneath the RPE are visible as small highly reflective PEDs.[11] In our study, only 2 eyes presented with these characteristic tomographic signs, and the remaining eyes exhibited either small undulations or flat PED profiles with increased or normal sub-RPE reflectivity. Moreover, with the en face OCT imaging modality, no CNV or so-called "hematocrit signs" were evident in our cases. In contrast, when we analyzed the split-spectrum amplitude-decorrelation angiography images, the presence of choroidal neovessels was evident under the RPE. This finding is consistent with

the report of Fung and associates[12] based on a case series of CSC patients with type I or subretinal pigment epithelium neovascularization. It is currently a common belief that PCV is a variant of type 1 neovascularization rather than a distinct vascular abnormality of the choroidal vessels, as has been proposed by some authors.[11] Other studies have described the presence of PCV and CSC,[10,13,14] which suggests the possibility that the development of polypoidal lesions might be secondary to long-standing exudation or the nonspecific RPE dysfunction typical of chronic CSC.

Clinically, it is occasionally difficult to differentiate these 2 entities. Demographic characteristics and histories are useful in most of the cases, as are angiographic and tomographic examinations. However, in asymptomatic patients, a type 1 CNV- or PCV-like lesion might already be present without any sign of choroidal neovessels, such as lipid exudation, subretinal fluid, RPE detachment, or ICG angiographic hyperfluorescence. Recently, Hage and associates[15] reported the presence of CNV correlated with flat irregular PEDs in 10 of 53 eyes with chronic CSC. The remaining 43 eyes were classified as presumed avascular flat irregular PEDs based on clinical and angiographic characteristics and the absence of evolution over a long period of time. In contrast, although we observed similar tomographic findings (such as opaque and hyperreflective contents of the PEDs) in the present study, we were able to demonstrate the presence of CNV in all cases with irregular RPE profiles only with OCT angiography. Specifically, the qualitative analysis of the split-spectrum amplitude-decorrelation angiography images and B-scans of our case series revealed that the locations of the CNVs corresponded to the areas of slightly irregular and hyperreflective RPE, while no CNV was detected on the split-spectrum amplitude-decorrelation angiography images when the RPE profile was flat and linear. Therefore, a CNV should always be suspected when a small and undulating PED is present on a B-scan.

These findings confirm the pathogenetic mechanism that has been proposed by some authors.[13,14] Ahuja and associates described polypoidal lesions as secondary manifestations of chronic exudation and RPE alterations typical of chronic CSC.[13] Moreover, Chung and associates examined patients with PCV and chronic CSC and suggested that PCV is more likely a secondary manifestation than a primary pathology of the choroid.[14] Therefore, it might be postulated that CSC and PCV share a common and convergent pathogenesis.

The early detection of CNV is crucial for a good visual outcome. The earlier the CNV is diagnosed and treated, the better is the final visual acuity that can be achieved. The relationship is also valid for CNV complicating chronic CSC. Therefore, the possibility of detecting choroidal neovascularization via OCT angiography in the absence of any other sign of CNV presented in this report is particularly relevant to chronic CSC patients. Split-spectrum amplitude-decorrelation angiography analysis is helpful in the visualization of CNV and allows for prompt and correct treatment of this complication that will, we hope, result in better visual outcomes.

OCT angiography presents several limitations. In particular, it requires that the patient fixate precisely for several seconds, and images are restricted to a small area. However, despite these limitations, OCT angiography is a useful noninvasive method to image details of the retinal and choroidal vasculature without injection of dye. Moreover, it is an evolving technique and the interpretation of the images needs to be refined further.

In conclusion, this study reports OCT angiography findings in patients with chronic CSC. With this imaging technique, we were able to demonstrate the presence of choroidal neovessels that were not visible with other imaging techniques. Despite the relatively small number of eyes included in this study, the findings from OCT angiography were consistent and repeatable. Further investigations in larger groups of subjects with chronic CSC are needed to assess the definitive role of this new imaging modality.

ALL AUTHORS HAVE COMPLETED AND SUBMITTED THE ICMJE FORM FOR DISCLOSURE OF POTENTIAL CONFLICTS OF INTEREST and none were reported. The authors indicate no funding support. All authors attest that they meet the current ICMJE requirements to qualify as authors.

REFERENCES

1. Gass JDM. Stereoscopic Atlas of Macular Diseases. St Louis: Mosby; 1970.
2. Zweng HC, Little HL. Diffuse Retinal Pigment Photo-coagulation. St Louis: Mosby; 1977:117–126.
3. von Winning CH, Oosterhuis JA, Renger-van Dijk AH, Homstra-Limburg H, Polak BCP. Diffuse retinal pigment epitheliopathy. *Ophthalmologica* 1982;185(1):7–14.
4. Piccolino FC, Borgia L. Central serous chorioretinopathy and indocyanine green angiography. *Retina* 1994;14(3):231–242.
5. Tsujikawa A. Pigment epithelial detachment in polypoidal choroidal vasculopathy. *Am J Ophthalmol* 2007;143(1):102–111.
6. Yang L, Jonas JB, Wei J. Choroidal vessels diameter in central serous chorioretinopathy. *Acta Ophthalmol* 2013;91(5):358–362.
7. Jia Y, Morrison JC, Tokayer J, et al. Quantitative OCT angiography of optic nerve head blood flow. *Biomed Opt Express* 2012;3(12):3127–3137.
8. Spaide RF, Klancnik JM Jr, Cooney MJ. Retinal vascular layers imaged by fluorescein angiography and optical

coherence tomography angiography. *JAMA Ophthalmol* 2015; 133(1):45–50.
9. Yannuzzi LA, Freund KB, Goldbaum M, et al. Polypoidal choroidal vasculopathy masquerading as central serous chorioretinopathy. *Ophthalmology* 2000;107(4): 767–777.
10. Yang LH, Jonas JB, Wei WB. Conversion of central serous chorioretinopathy to polypoidal vasculopathy. *Acta Ophthalmologica* 2015; http://dx.doi.org/10.1111/aos.12606.
11. Imamura Y, Engelbert M, Iida T, Freund KB, Yannuzzi LA. Polypoidal choroidal vasculopathy: a review. *Surv Ophthalmol* 2010;55(6):501–515.
12. Fung AT, Yannuzzi LA, Freund KB. Type 1 (sub-retinal pigment epithelial) neovascularization in central serous chorioretinopathy masquerading as neovascular age-related macular degeneration. *Retina* 2012;32(9):1829–1837.
13. Ahuja RM, Downes SM, Stanga PE, Koh AH, Vingerling JR, Bird AC. Polypoidal choroidal vasculopathy and central serous chorioretinopathy. *Ophthalmology* 2001;108(6): 1009–1010.
14. Chung SE, Kang SW, Lee JH, Kim YT. Choroidal thickness in polypoidal choroidal vasculopathy and exudative age-related macular degeneration. *Ophthalmology* 2011;118(5):840–845.
15. Hage R, Mrejen S, Krivosic V, Quentel G, Tadayoni R, Gaudric A. Flat irregular retinal pigment epithelium detachments in chronic central serous chorioretinopathy and choroidal neovascularization. *Am J Ophthalmol* 2015;159(5): 890–903.

Biosketch

Maddalena Quaranta-El Maftouhi, MD, is a retina specialist and Medical Director of the Centre Ophtalmologique Rabelais in France. She received her medical degree from the University of Brescia, Italy in 1989. She completed her ophthalmology residency at the University of Milan, Italy in 1991. She has been Praticien hospitalier full-time, then Assistante Specialisée des Hopîtaux in the Clinique Universitaire de Créteil from 1994 to 1999. Dr Quaranta's clinical and research interests include retina and vitreous diseases and imaging techniques. She has authored several publications in peer-reviewed journals.