Automated Multi-Label Classification of Temporomandibular Joint Osteoarthritis Signs from Cone-Beam Computed Tomography Using Deep Learning

First Author[a,], Second Author[b], Third Author[b], Fourth Author[b]

[a]*Department of Mathematics, Faculty of Science, Mahidol University, Bangkok, Thailand*
[b]*Department of Oral and Maxillofacial Radiology, Faculty of Dentistry, Mahidol University, Bangkok, Thailand*

Abstract

Objectives: Temporomandibular joint osteoarthritis (TMJOA) is diagnosed radiographically by the presence of one or more morphological signs in cone-beam computed tomography (CBCT) volumes, yet manual interpretation is time-consuming and subject to inter-observer variability. This study aimed to develop and evaluate an automated, end-to-end deep-learning pipeline for multi-label binary classification of TMJOA and four constituent signs—condylar erosion, generalised sclerosis, osteophyte, and subchondral cyst—directly from 3-D CBCT volumes requiring only joint-level diagnostic labels.

Methods: A dataset of 394 joints (209 patients) was labelled by three experienced oral and maxillofacial radiologists using DC/TMD criteria, with majority vote used to establish the gold standard. A three-stage preprocessing pipeline (automatic mandibular segmentation, condyle-centred cropping, and HU-based intensity normalisation) was applied to all volumes. Twenty deep learning architectures were trained using an informativeness-weighted 2-D sagittal slice sampling strategy and tested with aggregated inference. A two-stage, transfer-learning strategy initialising each sign-specific task from an OA-trained model was employed throughout.

Results: The best-performing architecture, ConvNeXt, achieved a mean AUC-ROC of 0.926 across all five tasks, with near-perfect discrimination for OA (AUC-ROC 0.991) and strong performance on erosion (0.952), generalised sclerosis (0.944) and osteophyte (0.921) with lower performance on subchondral cyst (0.823). The overall pipeline mean AUC-ROC

Email address: `first.author@mahidol.ac.th` (First Author)

across all 20 architectures was 0.909. GradCAM explainability maps confirmed that ConvNeXt attended to anatomically relevant condylar regions.

Conclusions: The proposed pipeline enables fully automated, multi-label TMJOA classification from CBCT volumes with no manual landmark selection. Among the architectures evaluated, ConvNeXt achieved the highest observed performance and represents a strong baseline for clinical translation.

Clinical Significance: This system provides fully automated, multi-label TMJOA screening from CBCT volumes, offering a potential second-reader tool that could reduce diagnostic variability and support CBCT interpretation in settings without specialist oral and maxillofacial radiologists. Because the proposed pipeline requires only joint-level diagnostic labels, the same determinations routinely recorded in clinical radiology reports, it can be trained and updated from existing clinical records without additional annotation effort, lowering the barrier to adoption and large-scale deployment.

Keywords: temporomandibular joint, osteoarthritis, cone-beam computed tomography, deep learning, multi-label classification, convolutional neural network, transfer learning

---

1. Introduction

Temporomandibular joint osteoarthritis (TMJOA) is a progressive degenerative condition characterised by the breakdown of articular cartilage and subchondral bone, with prevalence estimates ranging from approximately 2% to 16% [1]. Cone-beam computed tomography (CBCT) is the established modality for assessing TMJOA morphology owing to its three-dimensional visualisation of osseous structures at submillimetre resolution and a radiation dose considerably lower than conventional CT [2, 3, 4, 5]. The Diagnostic Criteria for Temporomandibular Disorders (DC/TMD) imaging protocol identifies four principal radiographic signs of osteoarthritis: surface erosion, generalised sclerosis, osteophyte formation, and subchondral cyst, with a diagnosis rendered when at least one is present [5]. Because multiple signs may coexist within a single joint, the task is inherently a multi-label classification problem. Manual interpretation is labour-intensive, requiring systematic review of hundreds of slices across three planes, underscoring the clinical need for automated decision-support systems. Deep learning has demonstrated radiologist-level accuracy in dental and craniofa-

cial imaging tasks [6, 7, 8], and systematic reviews of CBCT-based TMJOA detection report pooled AUC values of approximately 0.92 [9].

Within deep learning approaches for TMJ disorders, object detection models—particularly the YOLO family—have emerged as the dominant paradigm, localising and classifying radiographic signs from selected two-dimensional slices [8, 10, 11, 12]. However, these models require per-sign bounding-box annotations on each selected slice, imposing a substantial labelling burden. Moreover, because slice selection relies on human judgement, it may introduce operator-dependent variability and limit reproducibility. By utilising pre-trained segmentation models to localise the region and slice of interest, the need for bounding-box annotations can be eliminated. In dental imaging, DentalSegmentator [13] provides fully automatic segmentation of CBCT structures including the mandible without task-specific retraining, enabling a pipeline that requires only joint-level diagnostic labels—the same determinations routinely recorded in clinical radiology reports.

Selecting a backbone architecture remains a consequential design choice. Transfer learning from ImageNet-pretrained models is the dominant strategy given the scarcity of large annotated medical datasets [14], yet the domain gap between natural and medical images means that pretraining performance does not straightforwardly predict downstream accuracy [15]. This motivates a research question: which backbone architecture yields the best performance for TMJOA classification from CBCT volumes under our transfer-learning strategy?

To address these gaps, we present an end-to-end pipeline that (i) automatically segments the mandible and crops a condyle-centred volume, (ii) classifies all five DC/TMD targets simultaneously from CBCT volumes without manual slice selection, and (iii) recovers spatial explainability through GradCAM [16] activation maps. We systematically benchmark 20 deep learning architectures using an informativeness-weighted slice sampling strategy and compare this approach against a native three-dimensional convolutional network using ResNet as a common backbone architecture. Together, these experiments establish a practical framework for clinical deployment, requiring only the diagnostic labels already produced during routine CBCT reporting and no additional annotation effort for dataset curation.

2. Materials and Methods

2.1. Ethical Approval and Dataset

This retrospective study was conducted under institutional review board approval (MU-MOU CoA 2024/018.1804, Mahidol University Faculty of Dentistry, Bangkok, Thailand). Written informed consent was waived owing to the retrospective design.

CBCT volumes were acquired on a 3D Accuitomo XYZ scanner (J. Morita, Kyoto, Japan) at 90 kVp, 5 mA, with a voxel size of 0.125 mm and a field of view of 60 × 60 mm centred on the ipsilateral temporomandibular joint. A total of 394 joints from 209 patients (age range 18–80 years; mean 45 years; male:female ≈ 1:6) were included. Each joint was treated as an independent observation. Exclusion criteria were: history of mandibular fracture or orthognathic surgery, developmental anomalies of the condyle, diagnosis of a systemic inflammatory joint disease (e.g. rheumatoid arthritis), and poor image quality precluding reliable assessment.

The dataset was partitioned at the patient level into training (271 joints), validation (80 joints), and test (43 joints) sets to prevent data leakage between joints from the same patient. The class distributions across all splits are reported in Table 1, and the co-occurrence patterns among the four condylar signs are illustrated in Figure 1. Generalised sclerosis and subchondral cyst exhibited substantial class imbalance.

Table 1: Class distribution across the training, validation, and test sets for each of the five classification tasks. Note the pronounced imbalance for generalised sclerosis and subchondral cyst.

	Training ($n = 271$)			Validation ($n = 80$)			Test ($n = 43$)		
Task	Pos	Neg	% Pos	Pos	Neg	% Pos	Pos	Neg	% Pos
Osteoarthritis	168	103	61.99	45	35	56.25	25	17	58.14
Erosion	158	113	58.30	36	44	45.00	24	18	55.81
Generalised sclerosis	57	217	19.93	8	72	10.00	7	35	16.28
Osteophyte	132	139	48.71	31	49	38.75	19	23	44.19
Subchondral cyst	91	180	33.58	13	67	16.25	13	29	30.23

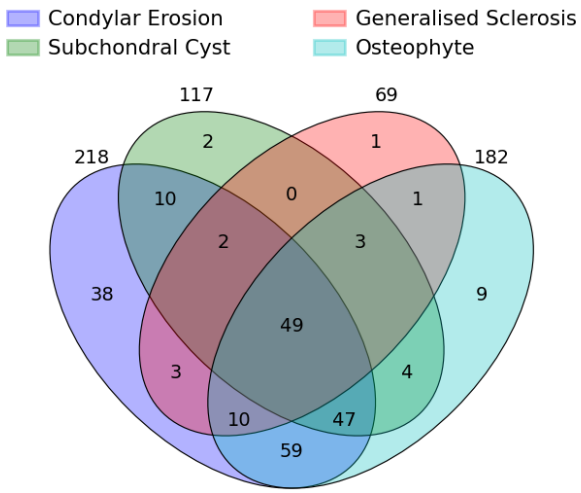

Figure 1: Four-set Venn diagram illustrating the co-occurrence of condylar erosion, generalised sclerosis, osteophyte, and subchondral cyst among the OA-positive joints in the full dataset.

2.1.1. Reference Standard and Inter-Rater Reliability

Three oral and maxillofacial radiologists with 20–29 years of experience independently labelled each joint for the five DC/TMD signs (condylar erosion, generalised sclerosis, osteophyte, subchondral cyst, and overall OA) using a standardised scoring sheet. The gold-standard label for each sign was determined by majority vote. Inter-rater reliability was quantified using Cohen's κ for all pairwise combinations and Fleiss' multi-rater κ (Table 2).

Table 2: Inter-rater reliability statistics for four TMJOA radiographic signs. Cohen's κ is reported for each pairwise rater combination and Fleiss' κ reflects multi-rater agreement.

Sign	κ **R1–R2**	κ **R1–R3**	κ **R2–R3**	**Fleiss'** κ
Osteoarthritis	0.847	0.869	0.892	0.869
Erosion	0.810	0.852	0.871	0.844
Generalised sclerosis	0.557	0.630	0.864	0.664
Osteophyte	0.780	0.803	0.932	0.837
Subchondral cyst	0.670	0.629	0.645	0.648

2.2. Preprocessing Pipeline

All volumes were preprocessed through a three-stage pipeline (Figure 2).

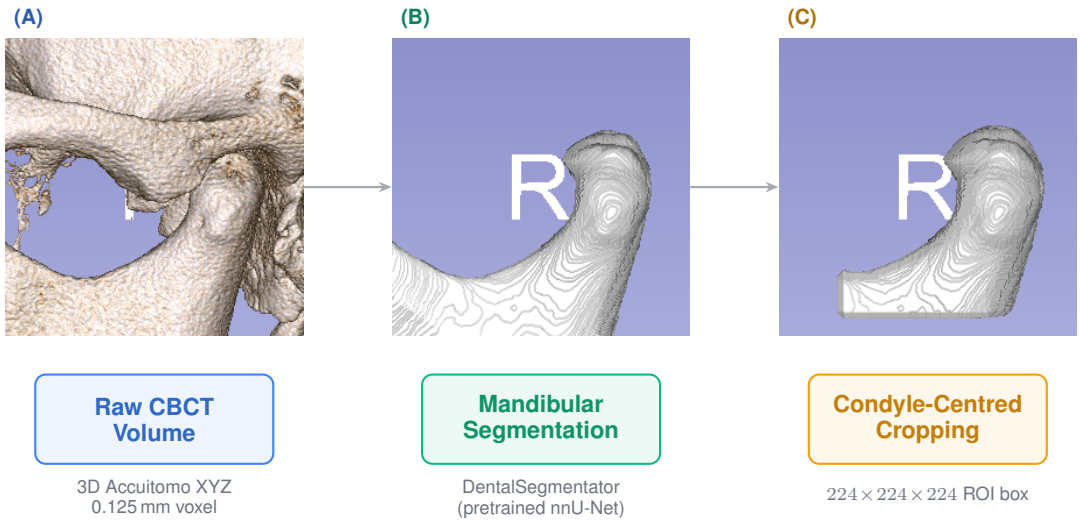

Figure 2: Preprocessing pipeline for condylar volume extraction. (A) Raw CBCT volume acquired on a 3D Accuitomo XYZ scanner. (B) Automatic mandibular segmentation using DentalSegmentator. (C) Condyle-centred cropping via 3-D skeletonisation of the mandibular mask.

2.2.1. Stage 1: Mandibular Segmentation

Automatic segmentation of the mandible was performed using DentalSegmentator [13], a publicly available nnU-Net [17] model fine-tuned on a multi-centre dental CBCT dataset. No further fine-tuning or manual correction was applied, deliberately simulating real-world deployment conditions where post-hoc mask editing is impractical. The segmentation mask was used exclusively to define the bounding geometry of the mandible in subsequent steps.

2.2.2. Stage 2: Condyle-Centred Cropping

The condylar centre was identified via 3-D skeletonisation of the mandibular mask using the `morphology.skeletonize` function from scikit-image [18]. The skeleton was traversed to identify the most superior branch tip, taken as a proxy for the condylar process apex. A $224 \times 224 \times 224$ voxel region of interest was then extracted, centred on this point.

2.2.3. Stage 3: Intensity Normalisation

Hounsfield unit values were windowed to the 2.5th–97.5th percentile range computed on the training dataset, encompassing soft-tissue and cortical bone intensities relevant to condylar morphology, then linearly rescaled to [0,1]. Processed volumes were saved in NIfTI format with all patient metadata stripped.

2.3. Classification Framework

2.3.1. Task Definition

For each condylar volume, the model predicted five independent binary labels corresponding to the DC/TMD signs: condylar erosion, generalised sclerosis, osteophyte, subchondral cyst, and overall OA.

2.3.2. Classification Models

Twenty backbone architectures spanning CNNs, lightweight mobile networks, vision transformers, and hybrid designs were evaluated. All backbones were initialised from ImageNet pre-trained weights; when multiple weight sets existed for a given variant, the one with the highest ImageNet top-1 accuracy was selected, and the largest publicly available variant of each architecture was used to maximise representational capacity. The specific variant and weight configuration for each architecture are listed in Supplementary Table S1. Weights were sourced from the TorchVision library [19] for all architectures except YOLOv11x-cls, which used Ultralytics [20]. All backbone parameters were frozen during training; only the classification heads were updated, reducing the risk of overfitting on the limited training set. For each backbone, the original classification layer was replaced with five task-specific multi-layer perceptron heads ($512 \rightarrow 256 \rightarrow 1$ with ReLU activations and dropout $p = 0.3$), attached to the pooled feature representation (Figure 3).

2.3.3. Loss Function and Optimisation

Binary cross-entropy with logits (`BCEWithLogitsLoss`) was used for all tasks. Minority-class oversampling was applied for generalised sclerosis and subchondral cyst to address class imbalance. All models were optimised with stochastic gradient descent (SGD) with cosine annealing of the learning rate.

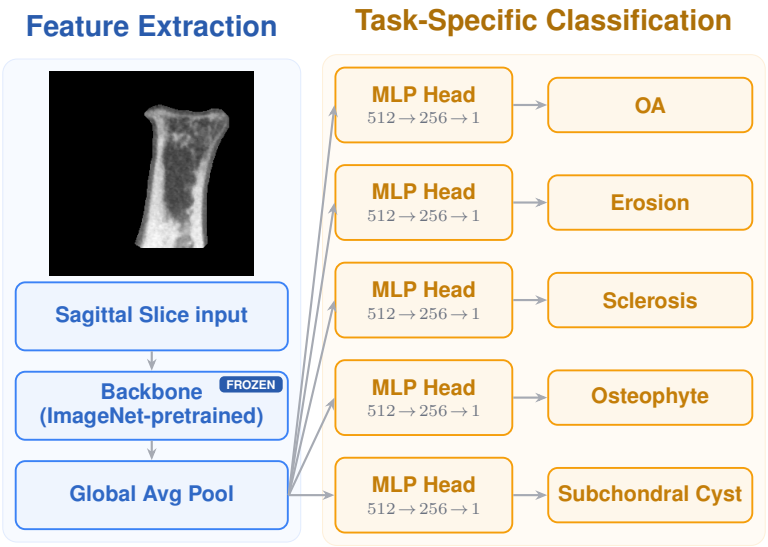

Figure 3: Classification framework architecture. Left: the feature extraction pipeline consisting of a sagittal slice input, a frozen ImageNet-pretrained backbone, and global average pooling. Right: five task-specific MLP heads ($512 \rightarrow 256 \rightarrow 1$ with ReLU and dropout $p = 0.3$), one per DC/TMD sign.

2.3.4. Two-Stage Training Strategy

To leverage the coarse-to-fine relationship among labels (OA is positive whenever any other sign is present), a two-stage training strategy was adopted. In Stage 1, the classification head was trained for OA classification. In Stage 2, the OA-trained head weights initialised the four sign-specific heads (condylar erosion, generalised sclerosis, osteophyte, subchondral cyst), which were then fine-tuned independently.

2.3.5. Data Augmentation

Online data augmentation was applied to each sampled training slice using a RandAugment-style policy [21]. A pool of 17 candidate transformations (10 intensity, 6 spatial and an identity transformation) was assembled from the MONAI library [22]. For each training sample, two transformations were drawn uniformly at random from this pool, transformation magnitude was then randomised within the admissible range. No augmentation was applied during validation or testing. The full transformation list and admissible parameter ranges are provided in Supplementary Table S3.

2.3.6. Threshold Selection

For each task, the classification threshold was set at the value maximising Youden's J statistic ($J = \text{sensitivity} + \text{specificity} - 1$) on the validation set.

2.4. Informativeness-Weighted 2-D Slice Sampling

Each 3-D volume was treated as a pool of 2-D sagittal slices. An *informativeness score* was defined for each slice as the ratio of the number of pixels belonging to the segmented condylar region to the total number of pixels in the slice:

$$s_i = \frac{\text{Segmented condylar pixels in slice } i}{\text{Total pixels in slice } i}. \tag{1}$$

2.4.1. Slice sampling during training

During training, a single slice was sampled from each volume in the training batch with probability proportional to s_i, encouraging the model to learn from slices rich in condylar anatomy (Figure 4). Grayscale slices were replicated to three channels to match ImageNet-pretrained backbone input requirements.

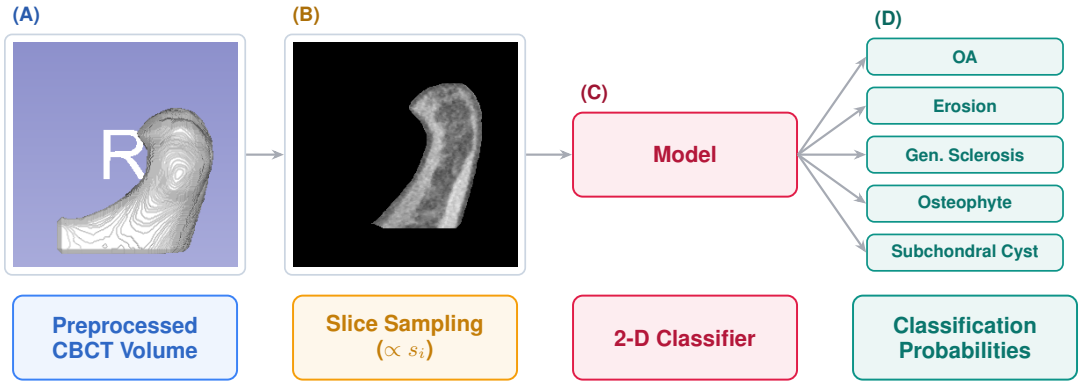

Figure 4: Inference process during training. (A) Preprocessed CBCT volume input. (B) A single sagittal slice is sampled with probability proportional to its informativeness score s_i. (C) The sampled slice is passed through the model. (D) Five independent binary classification outputs.

2.4.2. Slice aggregation during deployment.

In deployment, all sagittal slices with an informativeness score $s_i > 0.05$ were filtered to exclude peripheral slices containing negligible condylar anatomy. To reduce redundancy

among visually similar consecutive slices, every third slice from this filtered subset was retained. Slice-level predictions from the resulting set were combined into a volume-level probability using an informativeness-weighted average (Figure 5):

$$\hat{p} = \frac{\sum_{j \in \mathcal{J}} s_j \cdot \sigma(\hat{y}_j)}{\sum_{j \in \mathcal{J}} s_j}, \tag{2}$$

where $\mathcal{J}$ denotes the index set of retained slices, $\sigma(\cdot)$ is the sigmoid function, and $\hat{y}_j$ is the logit for slice j. The volume-level probability $\hat{p}$ was then compared against the task-specific threshold selected on the validation set (Section 2.3.6) to produce the final binary prediction. The test results reported in Section 3 were obtained using this inference procedure.

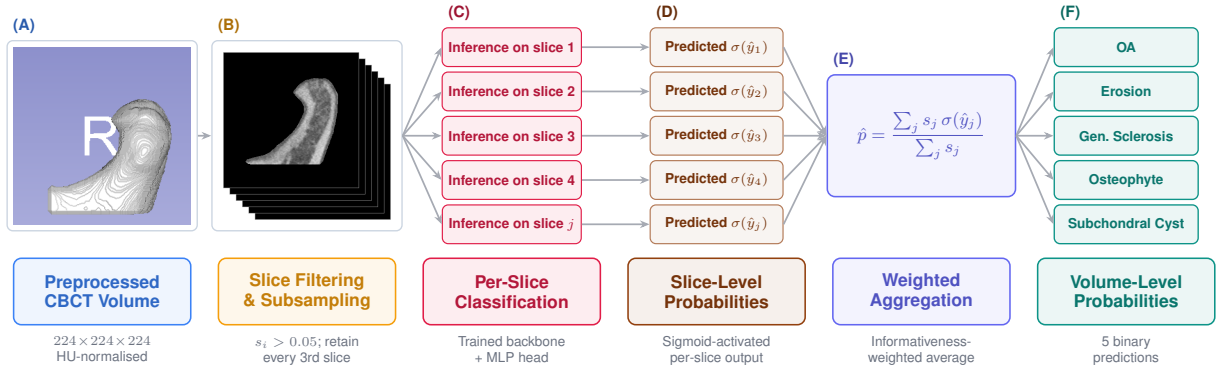

Figure 5: Inference process in deployment. (A) Preprocessed CBCT volume input. (B) Sagittal slices are filtered and subsampled. (C) Each retained slice is independently classified by the trained model. (D) Slice-level sigmoid probabilities output $\sigma(\hat{y}_j)$. (E) Informativeness-weighted aggregation produces volume-level probability $\hat{p}$ (Equation 2). (F) Final binary predictions.

2.5. Explainability

GradCAM [16] was applied to all models at inference. The resulting activation maps were overlaid on the corresponding sagittal slices for visual inspection. Qualitative results are reported for the highest-ranked model (ConvNeXt) (Figure 7).

2.6. Evaluation Metrics

Performance was evaluated on the held-out test set (43 joints) using accuracy, precision, recall, F1 score, area under the receiver-operating characteristic curve (AUC-ROC) and area under the precision-recall curve (AUC-PR). Emphasis is placed on AUC-ROC and AUC-PR as threshold-independent metrics.

2.7. Implementation Details

All models were implemented in Python using PyTorch 2.9.0 [23], the Ultralytics library 8.4.14 [20] (for YOLOv11), and MONAI 1.5.2 [22] for volumetric data handling. Visual inspection of raw CBCT volumes and preprocessed outputs at each pipeline stage was performed using 3D Slicer 5.8.1 [24]. Training was performed on an NVIDIA L4 GPU; each model–task combination required approximately 2–3 hours. All models were trained with an initial learning rate of 10^{-2}, cosine annealing, and a batch size of 8 for 1000 epochs per task, with early stopping triggered after 50 consecutive epochs without validation loss improvement. Because slice sampling is stochastic, validation was performed three times per epoch and the scores averaged.

2.8. Native 3-D Baseline: MONAI ResNet50

To contextualise the 2-D slice sampling approach, a native 3-D ResNet50 baseline was trained directly on the preprocessed CBCT volumes using the MONAI framework [22]. This model processes the entire volumetric input in a single forward pass without any dimensionality reduction or slice sampling, representing the most straightforward application of a deep learning classifier to 3D CBCT image. The architecture followed the standard ResNet50 design with 3D convolutional kernels throughout, initialised with random weights. The same two-stage training strategy, loss function, classifier head, and SGD optimiser with cosine annealing were applied for consistency; batch size was set to 2 owing to GPU memory constraints imposed by the full volumetric input.

3. Results

3.1. Inter-Rater Reliability and Rater Performance

Inter-rater reliability statistics are presented in Table 2. Agreement was excellent for erosion (Fleiss' $\kappa = 0.844$) and osteophyte ($\kappa = 0.837$), and moderate for generalised sclerosis ($\kappa = 0.664$) and subchondral cyst ($\kappa = 0.648$).

3.2. Model Performance

Per-task AUC-ROC and AUC-PR for each architecture is reported in Table 3. Full results including accuracy, precision, recall, and F1 are provided in Supplementary Table S2.

Table 3: Test-set AUC-ROC and AUC-PR for all 20 architectures across five tasks, sorted by mean AUC-ROC. Best value per sub-column in **bold**.

	OA		**Erosion**		**Sclerosis**		**Osteophyte**		**Cyst**		**Mean**	
Model	*ROC*	*PR*	*ROC*	*PR*	*ROC*	*PR*	*ROC*	*PR*	*ROC*	*PR*	*ROC*	*PR*
ConvNeXt	**.991**	**.994**	**.952**	**.941**	.944	.595	.921	.803	.823	.528	**.926**	.772
DenseNet	.987	.992	.945	.926	.913	.593	.923	.908	.836	.588	.921	.801
ViT	.980	.986	.939	.927	.893	.543	**.950**	**.942**	.841	.627	.920	.805
Inception V3	.978	.986	.936	.931	.909	.589	.925	.892	**.849**	**.678**	.919	.815
ResNeXt	.984	.989	.943	.929	.909	.460	.921	.839	.839	.584	.919	.760
Swin Transformer	.964	.976	.925	.925	**.956**	.719	.917	.869	.828	.554	.918	.809
YOLOv11	.980	.987	.939	.932	.917	**.768**	.906	.877	.844	.643	.917	.841
VGG	.971	.981	.923	.916	.937	.569	.917	.904	.828	.626	.915	.799
Swin Transformer V2	.969	.979	.923	.902	.925	.504	.921	.891	.836	.598	.915	.775
RegNetX	.978	.985	.939	.931	.921	.741	.925	.897	.808	.672	.914	**.845**
MobileNet V2	.976	.985	.925	.879	.929	.548	.904	.847	.833	.560	.913	.764
GoogLeNet	.976	.983	.930	.925	.929	.534	.906	.869	.823	.533	.913	.769
MobileNet V3	.984	.989	.945	.917	.893	.582	.919	.802	.808	.513	.910	.760
EfficientNet V2	.969	.979	.925	.918	.901	.452	.923	.905	.826	.562	.909	.763
MaxViT	.971	.981	.921	.874	.877	.423	.941	.933	.821	.517	.906	.746
ShuffleNet V2	.960	.974	.912	.910	.921	.677	.921	.915	.780	.504	.899	.796
EfficientNet	.969	.979	.910	.837	.885	.436	.936	.921	.782	.542	.896	.743
ResNet	.980	.986	.932	.881	.821	.470	.932	.916	.805	.649	.894	.780
MNASNet	.951	.966	.930	.916	.893	.647	.886	.767	.800	.624	.892	.784
RegNetY	.951	.970	.908	.867	.837	.364	.893	.862	.767	.542	.871	.721
Mean	.973	.982	.930	.909	.905	.561	.919	.878	.819	.582	.909	.782

Best model by observed mean AUC-ROC, ConvNeXt achieved near-perfect discrimination for OA (AUC-ROC 0.991) and strong performance on erosion (0.952), generalised sclerosis (0.944), and osteophyte (0.921), with lower performance on the imbalanced subchondral cyst class (0.823).

Bootstrap resampling (10,000 iterations, Holm–Bonferroni correction over 190 pairwise tests, $\alpha = 0.05$) revealed no statistically significant pairwise differences in mean AUC-ROC, likely owing to the limited test-set size ($n = 43$). ConvNeXt achieved the highest observed mean AUC-ROC (0.926) and ranked first most frequently (28.5% of resamples; mean rank 3.4), followed by DenseNet201 (0.921; mean rank 5.5) and ViT-L/16 (0.920; mean rank 5.8), although substantial rank overlap among the top 10 architectures indicates that these differences are not robust to sampling variability (Figure 6). Notably, vision transformers performed comparably to lightweight CNNs such as MobileNet V2 (0.914), indicating that ImageNet-pretrained CNN features transfer effectively to this domain even without architectural complexity.

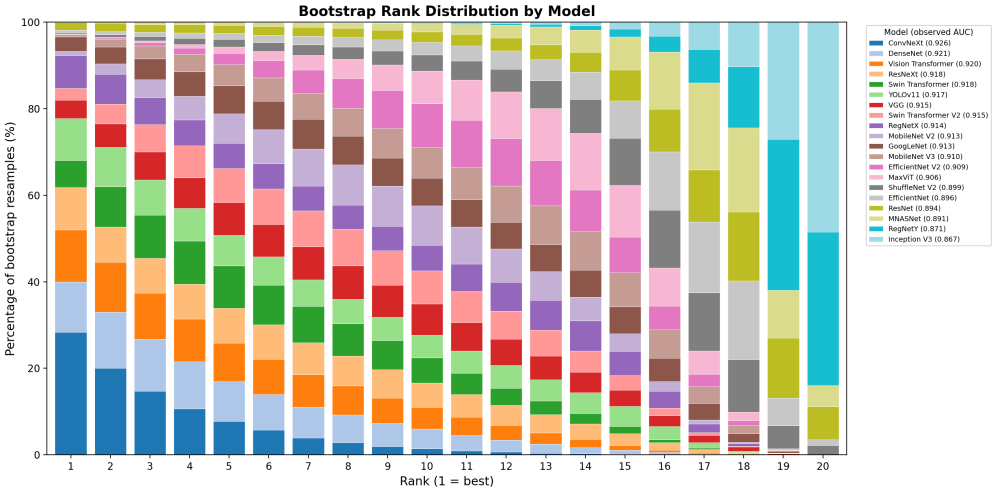

Figure 6: Bootstrap rank distribution across 10,000 resamples for all 20 architectures, sorted by observed mean AUC-ROC. Stacked bars indicate the proportion of resamples in which each architecture achieved a given rank. Substantial rank overlap among the top 10 models indicates that observed performance differences are not robust to sampling variability.

3.3. Task-Level Summary

As shown in the mean row of Table 3, OA achieved the highest mean AUC-ROC (0.973), followed by erosion (0.930), osteophyte (0.919), generalised sclerosis (0.905), and subchondral cyst (0.819). Although generalised sclerosis and subchondral cyst achieved comparable AUC-ROC values, their mean AUC-PR scores (0.561 and 0.582, respectively) were substantially lower than those of the other tasks, reflecting the combined effect of class imbalance and moderate inter-rater reliability.

3.4. Explainability

GradCAM visualisations for ConvNeXt (Figure 7) showed activation concentrated on anatomically relevant condylar regions across all five tasks, confirming that predictions were driven by meaningful morphological features rather than background artefacts. The activation pattern for subchondral cyst closely resembled that of the overall OA task, suggesting that this sign-specific head may not have learned features beyond those acquired during OA initialisation, a likely consequence of the two-stage training strategy.

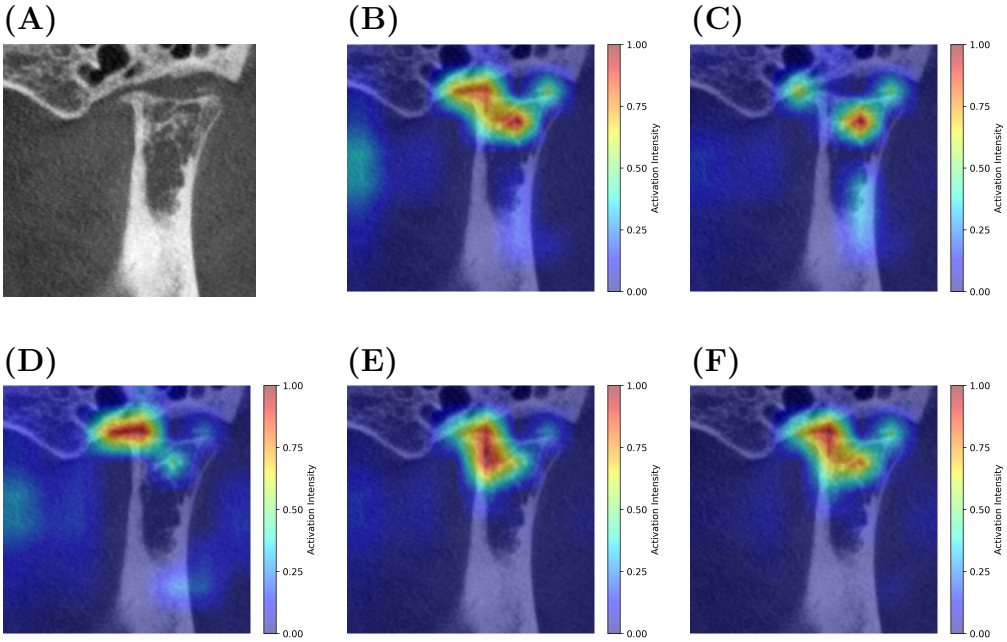

Figure 7: GradCAM visualisation for ConvNeXt. (A) Sagittal slice (original), and GradCAM overlays for true-positive predictions of (B) Osteoarthritis, (C) Condylar erosion, (D) Generalised sclerosis, (E) Osteophyte, and (F) Subchondral cyst.

3.5. Native 3-D Baseline Comparison

Table 4 compares ResNet under the 2-D slice sampling and native 3-D MONAI paradigms. The 3-D model achieved a higher mean AUC-ROC (0.938 vs. 0.894), with the largest gains on generalised sclerosis (0.968 vs. 0.821).

Table 4: Direct comparison of ResNet across dimensionality paradigms on the held-out test set. AUC = AUC-ROC. Per-volume GFLOPs for the 2-D model are estimated as per-slice GFLOPs × mean retained slices (48.36). Best value per column in **bold**.

Paradigm	**OA**	**Erosion**	**Sclerosis**	**Osteo.**	**Cyst**	**Mean**	**Compute**
	AUC	AUC	AUC	AUC	AUC	AUC	GLOPS
2-D slice sampling	**0.980**	0.932	0.821	0.932	0.805	0.894	∼261
MONAI native 3-D	0.958	**0.945**	**0.968**	**0.971**	**0.846**	**0.938**	5,234

The performance advantage of the 3-D model came at a substantial computational cost. In terms of FLOPs, the native 3-D model required 5,234 GFLOPs per volume compared with ∼261 GFLOPs for the 2-D approach, a 20-fold difference.

Per-volume FLOPs for the 2-D model were estimated as the per-slice cost (5.40 GFLOPs) multiplied by the mean number of retained slices after filtering and subsampling (48.36 across the test set). During training, the computational gap is even wider as the 2-D approach processes only a single sampled slice per volume at each iteration, whereas the 3-D model must process the entire volume.

4. Discussion

This study demonstrates that fully automated, multi-label classification of TMJOA radiographic signs from CBCT is achievable with clinically useful accuracy using standard deep learning backbones and image-level annotations. The principal findings are discussed below.

4.1. End-to-End Automation and Reduced Annotation Burden

A key contribution of the proposed pipeline is the elimination of the localisation labelling step between raw CBCT acquisition and classification output. Prior work has commonly required bounding-box annotation for object detection networks [8, 10, 11, 25, 26]. By combin-

ing DentalSegmentator [13] for automated mandibular segmentation with a skeletonisation-based condyle localiser, our approach requires only image-level binary labels—the standard output of a clinical radiological report—substantially reducing the cost of dataset curation.

This design exploits the fact that osseous structure segmentation is a considerably easier task for deep learning than pathology classification. Osseous structures exhibit high contrast and well-defined boundaries that generalise across patients, whereas classifying degenerative changes requires distinguishing subtle morphological alterations on which even experienced radiologists disagree (Table 2). Empirical evidence from Eşer et al. [25] illustrates this gap: a single YOLOv5 model trained jointly for TMJ segmentation and four-class OA classification on CBCT sagittal slices achieved an AUC-ROC of 0.972 for segmentation but only 0.497 for classification, essentially chance-level performance. Similarly, Fu et al. [12] reported a two-stage pipeline for CBCT-based TMJ disc displacement screening in which the localisation stage (YOLOv11) achieved near-perfect detection (precision 0.986, recall 0.982, mAP50 0.988), whereas the downstream classification stage attained an AUC of only 0.733 and an accuracy of 0.669, further underscoring the disparity between localisation and pathology classification difficulty in TMJ imaging.

By treating localisation and classification as separate stages, our pipeline exploits the reliability of the easier task (segmentation via DentalSegmentator) to provide a stable anatomical reference, and then allows the model to concentrate solely on the harder task (pathology classification) within a well-defined region of interest. This separation also permits each stage to be independently improved or replaced as more capable models become available.

4.2. Informativeness-Weighted Slice Sampling as a Radiologist-Mimicking Strategy

The strong performance of the informativeness-weighted 2-D slice sampling approach supports the hypothesis that this is an effective strategy for extracting disease-relevant features from 3-D CBCT volumes using 2-D networks. The slices weighting scheme (Equation 1) mimics the radiologist's natural tendency to select slices that pass through the bulk of the condyle, thereby maximising the likelihood that diagnostically relevant signs are captured within the sampled slice. The aggregated inference (Equation 2) then combines evidence across the entire volume without requiring a single "best" slice to be pre-selected, a task

that is itself non-trivial to automate.

This approach parallels multiple-instance learning frameworks applied to other volumetric imaging tasks [27, 28], but differs in that our aggregation weights are computed from a simple geometric prior (condylar cross-sectional area) rather than learned attention, rendering them interpretable and computationally inexpensive.

4.3. Architecture Insights

ConvNeXt's frequent top ranking in bootstrap resampling is consistent with recent benchmarks showing that modernised pure-CNN architectures match or exceed vision transformers on medical imaging tasks with limited training data [29]. Nevertheless, the substantial rank overlap among the top 10 architectures (Figure 6) indicates that this advantage is not statistically robust at the present sample size. Large transformers (ViT, Swin Transformer) performed competitively but did not demonstrate clear superiority, likely reflecting their well-documented data-hungry nature [30, 31]. The competitive performance of compact architectures such as MobileNet V2 (AUC-ROC 0.914) and MobileNet V3 (0.910) has practical implications for deployment on commodity hardware in community dental clinics or low-resource settings.

4.4. 2-D Slice Sampling versus Native 3-D Processing

As reported in Section 3.5, the native 3-D ResNet50 outperformed its 2-D counterpart on mean AUC-ROC (0.938 vs. 0.894), with the largest gains on generalised sclerosis. This might suggest that the morphological expression of this sign is better captured with 3-D spatial context, though the improvement could also reflect the substantially higher computational budget of the volumetric model. Disentangling the contributions of spatial context and model capacity warrants further investigation. Notably, the 3-D model achieved this advantage despite being trained from random initialisation, without the large-scale ImageNet pre-training that underpins the 2-D approach. This suggests that the results reported here may underestimate the full potential of volumetric models; domain-specific 3-D pre-training could further widen the performance gap.

However, the 3-D advantage must be weighed against a 20-fold increase in computational cost (per-volume FLOPs 5,234 vs. $\sim$261 GFLOPs) and substantially higher GPU memory

requirements. Moreover, the 2-D paradigm permits access to stronger backbone architectures. The highest-ranked 2-D model, ConvNeXt, achieved a mean AUC-ROC of 0.926 at an estimated ∼2,172 GFLOPs per volume, less than half the 3-D cost. At the sign level, ConvNeXt surpassed the 3-D ResNet50 on OA (0.991 vs. 0.958) and erosion (0.952 vs. 0.945), and performed comparably on generalised sclerosis (0.944 vs. 0.968) and subchondral cyst (0.823 vs. 0.846). The 3-D model retained a clearer advantage only on osteophyte (0.921 vs. 0.971). Taken together, these results indicate that a more expressive 2-D backbone can narrow or close the gap with native volumetric processing on most signs, at a fraction of the computational cost. This comparison illustrates a practical advantage of the 2-D paradigm: it enables a much broader architecture search than is currently feasible in 3-D.

A further practical consideration is that extending modern architectures (e.g. ConvNeXt, Swin Transformer) to native 3-D is non-trivial: it substantially increases parameter count and memory consumption, and may render existing 2-D pretrained weights incompatible. Systematic conversion methods such as ACS convolutions [32] have been validated only for classical CNN families and their applicability to modern architectures remains unexplored. The 2-D slice sampling paradigm therefore remains a practical route to leveraging the full diversity of state-of-the-art ImageNet-pretrained backbones for 3-D medical imaging tasks, as demonstrated by the 20-architecture comparison in this study.

4.5. Generalised Sclerosis and Subchondral Cyst: The Difficult Signs

Generalised sclerosis and subchondral cyst were consistently the most difficult signs, with mean F1 scores of 0.540 and 0.616, respectively. These signs also exhibited the lowest inter-rater agreement (Fleiss' $\kappa = 0.664$ and 0.648), suggesting that model difficulty mirrors inherent diagnostic ambiguity and that label noise places an intrinsic ceiling on attainable performance. Both signs additionally suffer from severe class imbalance and strong co-occurrence with other signs: only 1 joint in the dataset was exclusively positive for generalised sclerosis and only 2 for subchondral cyst (Figure 1), potentially limiting the models' ability to learn sign-specific discriminative features.

4.6. Comparison with Prior Work

Direct numerical comparison with prior studies is complicated by differences in dataset composition, scanner characteristics, and evaluation protocols. Among detection-based approaches, Lee et al. [10] reported accuracy of 0.86 and F1 of 0.84 using SSD on 3,514 manually selected slices; Talaat et al. [8] achieved accuracy exceeding 95% with YOLOv5 on 2,737 images; and Mao et al. [11] detected four signs with AUC values of 0.872–0.911 using YOLOv10 on 7,357 slices. All three required manually selected slices and per-sign bounding-box annotations, a substantially heavier annotation burden than the joint-level classification labels used in our pipeline. Among classification-based approaches, Eşer et al. [25] achieved 0.768 classification accuracy and an F1 of 0.869 with YOLOv5 on 2,000 sagittal sections.

Our highest-ranked model (ConvNeXt, mean AUC-ROC 0.926; OA AUC-ROC 0.991) substantially exceeds the classification performance reported by Eşer et al. and is comparable to the sign-level AUC values of Mao et al., while requiring neither manual slice selection nor bounding-box annotation. This demonstrates that publicly available pretrained segmentation models can effectively substitute for the labour-intensive spatial annotations demanded by detection-based approaches, without sacrificing discriminative performance.

4.7. Limitations and Future Directions

This is a single-centre study using one CBCT scanner, and the test set is relatively small (n=43). The informativeness weighting relies on automated segmentation quality, and clinical validation in a prospective workflow has not been performed. Because the entire pipeline depends on DentalSegmentator for both condyle localisation and informativeness scoring, segmentation errors propagate directly into downstream classification; however, the extent of this dependency has not been formally quantified. Future work should prioritise external validation on multi-centre, multi-scanner data; formal ablation of the two-stage training strategy and informativeness weighting; systematic analysis of how segmentation accuracy affects classification performance, for example by evaluating the pipeline under deliberately degraded or alternative segmentation models; exploration of 3-D architectures with domain-specific pretraining; and prospective clinical evaluation with radiologist feedback.

5. Conclusions

We have presented a fully automated end-to-end pipeline for multi-label binary classification of five DC/TMD radiographic signs of temporomandibular joint osteoarthritis from CBCT volumes. The pipeline integrates automated mandibular segmentation, skeletonisation-based condyle localisation, and deep learning classification without any manual slice selection or bounding-box annotation. Among 20 architectures evaluated, ConvNeXt achieved the highest observed mean AUC-ROC of 0.926, with near-perfect discrimination for the overall OA label (AUC-ROC 0.991), although bootstrap resampling indicated substantial rank overlap among the top-performing architectures. GradCAM explainability maps confirmed that the highest-ranked models attended to anatomically plausible condylar regions. These findings support the feasibility of deploying this system as a computer-aided diagnosis adjunct to conventional CBCT reporting, with the potential to reduce diagnostic variability and accelerate large-scale TMJOA screening.

Conflict of Interest

The authors declare no conflict of interest.

Funding

This research did not receive any specific grant from funding agencies in the public, commercial, or not-for-profit sectors.

Data Availability

The dataset used in this study is not publicly available owing to patient confidentiality requirements. De-identified summary statistics and model weights may be made available upon reasonable request.

Acknowledgements

The authors thank the clinical staff at the Department of Oral and Maxillofacial Radiology, Mahidol University Faculty of Dentistry, for facilitating data collection.

References

[1] C. Xu, C. Yu, T. Wang, X. Gao, Bibliometric and visualization analysis of temporomandibular joint osteoarthritis from 2004 to 2024, Frontiers in Oral Health 6 (2025) 1596551. doi:10.3389/froh.2025.1596551.

[2] T. Larheim, A. Abrahamsson, M. Kristensen, L. Arvidsson, Temporomandibular joint diagnostics using cbct, Dentomaxillofacial Radiology 44 (1) (2015) 20140235. doi:10.1259/dmfr.20140235.

[3] O. B. Honey, W. C. Scarfe, M. J. Hilgers, K. Klueber, A. M. Silveira, B. S. Haskell, A. G. Farman, Accuracy of cone-beam computed tomography imaging of the temporomandibular joint: comparisons with panoramic radiology and linear tomography, American journal of orthodontics and dentofacial orthopedics 132 (4) (2007) 429–438. doi:10.1016/j.ajodo.2005.10.032.

[4] M. Ahmad, L. Hollender, Q. Anderson, K. Kartha, R. Ohrbach, E. L. Truelove, M. T. John, E. L. Schiffman, Research diagnostic criteria for temporomandibular disorders (rdc/tmd): development of image analysis criteria and examiner reliability for image analysis, Oral Surgery, Oral Medicine, Oral Pathology, Oral Radiology, and Endodontology 107 (6) (2009) 844–860. doi:10.1016/j.tripleo.2009.02.023.

[5] E. Schiffman, R. Ohrbach, E. Truelove, J. Look, G. Anderson, J.-P. Goulet, T. List, P. Svensson, Y. Gonzalez, F. Lobbezoo, et al., Diagnostic criteria for temporomandibular disorders (dc/tmd) for clinical and research applications: recommendations of the international rdc/tmd consortium network and orofacial pain special interest group, Journal of oral & facial pain and headache 28 (1) (2014) 6. doi:10.11607/jop.1151.

[6] H. Chen, K. Zhang, P. Lyu, H. Li, L. Zhang, J. Wu, C.-H. Lee, A deep learning approach to automatic teeth detection and numbering based on object detection in dental periapical films, Scientific reports 9 (1) (2019) 3840. doi:10.1038/s41598-019-40414-y.

[7] E. Choi, D. Kim, J.-Y. Lee, H.-K. Park, Artificial intelligence in detecting temporo-

mandibular joint osteoarthritis on orthopantomogram, Scientific reports 11 (1) (2021) 10246. doi:10.1038/s41598-021-89742-y.

[8] W. M. Talaat, S. Shetty, S. Al Bayatti, S. Talaat, L. Mourad, S. Shetty, A. Kaboudan, An artificial intelligence model for the radiographic diagnosis of osteoarthritis of the temporomandibular joint, Scientific Reports 13 (1) (2023) 15972. doi:10.1038/s41598-023-43277-6.

[9] L. Xu, J. Chen, K. Qiu, F. Yang, W. Wu, Artificial intelligence for detecting temporomandibular joint osteoarthritis using radiographic image data: A systematic review and meta-analysis of diagnostic test accuracy, PLoS One 18 (7) (2023) e0288631. doi:10.1371/journal.pone.0288631.

[10] K. Lee, H. Kwak, J. Oh, N. Jha, Y. Kim, W. Kim, U. Baik, J. Ryu, Automated detection of tmj osteoarthritis based on artificial intelligence, Journal of dental research 99 (12) (2020) 1363–1367. doi:10.1177/0022034520936950.

[11] W.-Y. Mao, Y.-Y. Fang, Z.-Z. Wang, M.-Q. Liu, Y. Sun, H.-X. Wu, J. Lei, K.-Y. Fu, Automated diagnosis and classification of temporomandibular joint degenerative disease via artificial intelligence using CBCT imaging, Journal of Dentistry 154 (2025) 105592. doi:10.1016/j.jdent.2025.105592.

[12] Y. Fu, J. Li, Q. Zhai, M. Cui, X. Huang, Z. Wang, Q. Wu, C. Liu, Cbct assisted diagnosis system for temporomandibular joint disc displacement based on deep learning, Progress in Orthodontics 27 (1) (2026) 4. doi:10.1186/s40510-026-00606-5.

[13] G. Dot, A. Chaurasia, G. Dubois, C. Savoldelli, S. Haghighat, S. Azimian, A. R. Taramsari, G. Sivaramakrishnan, J. Issa, A. Dubey, et al., Dentalsegmentator: Robust open source deep learning-based ct and cbct image segmentation, Journal of dentistry 147 (2024) 105130. doi:10.1016/j.jdent.2024.105130.

[14] H. E. Kim, A. Cosa-Linan, N. Santhanam, M. Jannesari, M. E. Maros, T. Ganslandt, Transfer learning for medical image classification: a literature review, BMC medical imaging 22 (1) (2022) 69. doi:10.1186/s12880-022-00793-7.

[15] M. R. Hosseinzadeh Taher, F. Haghighi, R. Feng, M. B. Gotway, J. Liang, A systematic benchmarking analysis of transfer learning for medical image analysis, in: MICCAI Workshop on Domain Adaptation and Representation Transfer, Springer, 2021, pp. 3–13. doi:10.1007/978-3-030-87722-4_1.

[16] R. R. Selvaraju, M. Cogswell, A. Das, R. Vedantam, D. Parikh, D. Batra, Grad-cam: Visual explanations from deep networks via gradient-based localization, International Journal of Computer Vision 128 (2) (2019) 336–359. doi:10.1007/s11263-019-01228-7.

[17] F. Isensee, P. F. Jaeger, S. A. Kohl, J. Petersen, K. H. Maier-Hein, nnu-net: a self-configuring method for deep learning-based biomedical image segmentation, Nature methods 18 (2) (2021) 203–211. doi:10.1038/s41592-020-01008-z.

[18] S. Van der Walt, J. L. Schönberger, J. Nunez-Iglesias, F. Boulogne, J. D. Warner, N. Yager, E. Gouillart, T. Yu, scikit-image: image processing in python, PeerJ 2 (2014) e453. doi:10.7717/peerj.453.

[19] PyTorch Contributors, Torchvision: Models and pre-trained weights, accessed: 2026-03-17 (2024).
URL https://docs.pytorch.org/vision/master/models.html

[20] G. Jocher, J. Qiu, Ultralytics yolo11 (2024).
URL https://github.com/ultralytics/ultralytics

[21] E. D. Cubuk, B. Zoph, J. Shlens, Q. V. Le, Randaugment: Practical automated data augmentation with a reduced search space, in: Proceedings of the IEEE/CVF conference on computer vision and pattern recognition workshops, 2020, pp. 702–703. doi:10.1109/CVPRW50498.2020.00359.

[22] MONAI Consortium, MONAI: Medical open network for AI (2026). doi:10.5281/zenodo.18408724.

[23] A. Paszke, S. Gross, F. Massa, A. Lerer, J. Bradbury, G. Chanan, T. Killeen, Z. Lin,

N. Gimelshein, L. Antiga, et al., Pytorch: An imperative style, high-performance deep learning library, Advances in neural information processing systems 32 (2019).

[24] A. Fedorov, R. Beichel, J. Kalpathy-Cramer, J. Finet, J.-C. Fillion-Robin, S. Pujol, C. Bauer, D. Jennings, F. Fennessy, M. Sonka, et al., 3d slicer as an image computing platform for the quantitative imaging network, Magnetic resonance imaging 30 (9) (2012) 1323–1341. doi:10.1016/j.mri.2012.05.001.

[25] G. Eşer, Ş. B. Duman, İ. Ş. Bayrakdar, Ö. Çelik, Classification of temporomandibular joint osteoarthritis on cone beam computed tomography images using artificial intelligence system, Journal of oral rehabilitation 50 (9) (2023) 758–766. doi:10.1111/joor.13481.

[26] E. Choi, S. Shin, K. Lee, T. An, R. K. Lee, S. Kim, Y. Son, S. T. Kim, Artificial intelligence-enhanced diagnosis of degenerative joint disease using temporomandibular joint panoramic radiography and joint noise data, Scientific reports 15 (1) (2025) 1823. doi:10.1038/s41598-024-83750-4.

[27] M. Ilse, J. Tomczak, M. Welling, Attention-based deep multiple instance learning, in: International conference on machine learning, PMLR, 2018, pp. 2127–2136. doi:10.48550/arXiv.1802.04712.

[28] G. Campanella, M. G. Hanna, L. Geneslaw, A. Miraflor, V. Werneck Krauss Silva, K. J. Busam, E. Brogi, V. E. Reuter, D. S. Klimstra, T. J. Fuchs, Clinical-grade computational pathology using weakly supervised deep learning on whole slide images, Nature medicine 25 (8) (2019) 1301–1309. doi:10.1038/s41591-019-0508-1.

[29] Z. Liu, H. Mao, C.-Y. Wu, C. Feichtenhofer, T. Darrell, S. Xie, A convnet for the 2020s, in: Proceedings of the IEEE/CVF conference on computer vision and pattern recognition, 2022, pp. 11976–11986. doi:10.48550/arXiv.2201.03545.

[30] A. Dosovitskiy, L. Beyer, A. Kolesnikov, D. Weissenborn, X. Zhai, T. Unterthiner, M. Dehghani, M. Minderer, G. Heigold, S. Gelly, et al., An image is worth 16x16 words:

Transformers for image recognition at scale, arXiv preprint arXiv:2010.11929 (2020). doi:10.48550/arXiv.2010.11929.

[31] M. Raghu, T. Unterthiner, S. Kornblith, C. Zhang, A. Dosovitskiy, Do vision transformers see like convolutional neural networks?, Advances in neural information processing systems 34 (2021) 12116–12128. doi:10.48550/arXiv.2108.08810.

[32] J. Yang, X. Huang, Y. He, J. Xu, C. Yang, G. Xu, B. Ni, Reinventing 2d convolutions for 3d images, IEEE Journal of Biomedical and Health Informatics 25 (8) (2021) 3009–3018. doi:10.1109/JBHI.2021.3049452.