Documents - VensoPro

172.18.0.17:8080/VENSOPRO/Document/ViewDoc?id=7FCC0863-C97E-4CC0-B8DC-8B83E3FD3885&q=55022

DMS

Father Muller Charitable Institutions

IP MRD

View Document

7 of 99 Automatic Zoom

SEX	: MALE	DISCHARGED ON	: 28-05-2015 / 12:14
BED NO	: R1 M SPVT3	UNIT HEAD	: Dr.VENKATESHA B.M. MBBS,MD
ADDRESS	: D.NO 12-191,RAJEEV NAGAR SHAKTHINAGAR		
	MANGALORE		

DIAGNOSIS
DENGUE FEVER

COMPLAINTS
fever, vomiting, pain abdomen since 2 days

PAST HISTORY
no h/o dm,htn,tb

FAMILY HISTORY
nothing significant

PERSONAL HISTORY
sleep - normal appetite - decreased diet - mixed bowel and bladder - regular,

GENERAL EXAMINATION
patient was conscious, cooperative, well oriented with time, place and person.
moderately built and n
pallor,icterus, cyanosis, clubbing, lymphadenopathy, edema absent
PR-80 bpm BP- 120/80mmHg TEMP - 98.6F RR-16 CYCLES / MIN

SYSTEMIC EXAMINATION
RS: trachea central, accessory muscles not in use, chest movement b/l symmetrical. vf&vr appear b/l equal. vbs+, .
CVS: no precordial bulge, jvp not elevated, apex beat palpable in (I) 5th ics 1/2 " medial to mcl. cardiac borders percussed wnl. s1 &s2 + ; no added sounds/ murmurs.
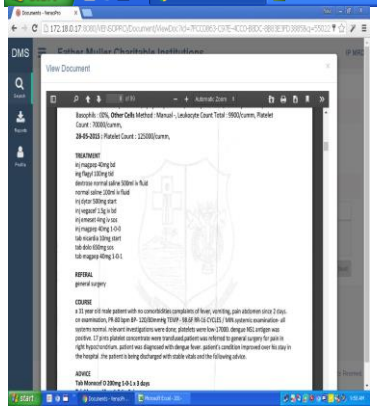
start | Documents - VensoPr... | Microsoft Excel - 201- | 9:56 AM