# DentalAI

## Dental Caries Detection Report

| | | | |
|---|---|---|---|
| **Patient Name** | Kashif Bhutto | **Patient ID** | PT-2026-4MZU0 |
| **Report ID** | RPT-TC059VLW | **Date of Analysis** | April 21, 2026 |
| **Time of Analysis** | 04:32 AM | **Analyzed File** | dentaltest.jpg |
| **Generated By** | DentalAI AI-Assisted Dental Analysis System | **Average Confidence** | 53.9% (Moderate) |

*This report is AI-generated and is intended for informational purposes only. It does not constitute a medical diagnosis. Please consult a licensed dental professional for clinical evaluation.*

## Radiographic Analysis - Annotated Image

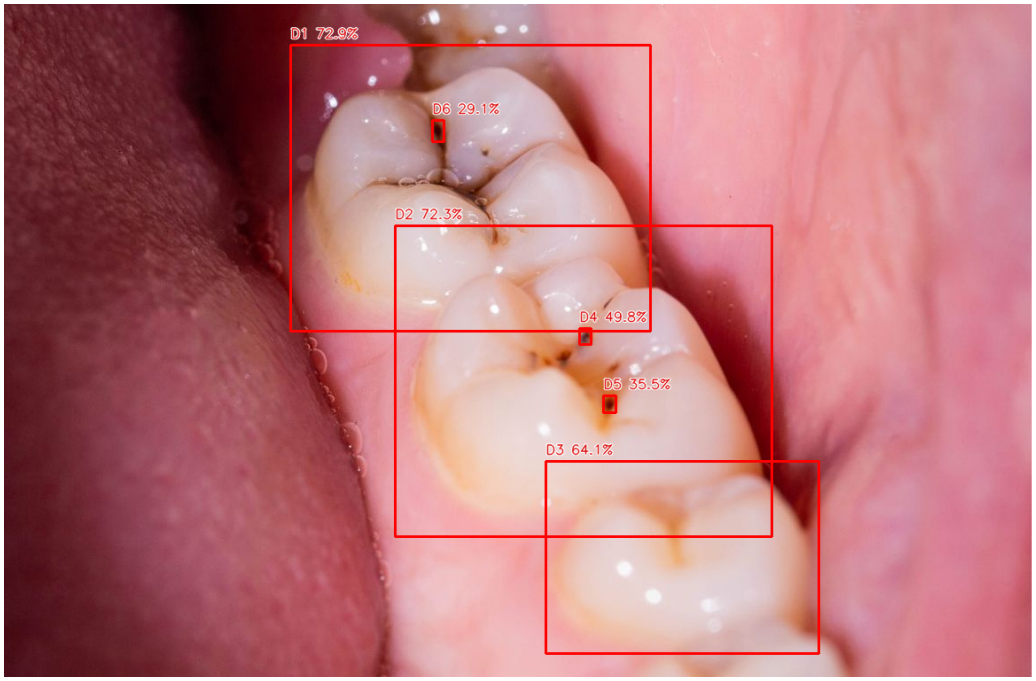


Figure 1: AI-detected regions of interest are highlighted. Each box corresponds to a suspected area of concern.

| Detection # | Region Coordinates | Confidence Score | Severity Level |
|---|---|---|---|
| 1 | (323, 46) - (729, 369) | 72.9% | Moderate Concern |
| 2 | (441, 250) - (866, 601) | 72.3% | Moderate Concern |
| 3 | (611, 516) - (919, 733) | 64.1% | Moderate Concern |
| 4 | (649, 366) - (662, 384) | 49.8% | Low Concern / Monitor |
| 5 | (676, 442) - (690, 461) | 35.5% | Low Concern / Monitor |
| 6 | (483, 131) - (496, 155) | 29.1% | Low Concern / Monitor |

## Clinical Terminology & Findings Explained

| Term | Status | Brief Explanation |
|---|---|---|
| Dental Caries (Tooth Decay) | Detected / Possibly Affected | Bacterial destruction of tooth enamel caused by acid produced from sugars |
| Enamel | Not Indicated | The hard outer layer of the tooth. Early caries often begins here. |
| Dentin | Not Indicated | The layer beneath enamel. If caries penetrates here, sensitivity and pain m |
| Dental Pulp | Not Indicated | The innermost soft tissue of the tooth containing nerves and blood vessels. |
| Periapical Region | Not Indicated | The area at the root tip. Infection here may appear as a dark shadow on X- |
| Interproximal Caries | Detected / Possibly Affected | Decay occurring between teeth, often harder to detect visually. |
| Occlusal Surface | Detected / Possibly Affected | The biting surface of the tooth where caries frequently begins in pits and fis |
| Calculus / Tartar | Detected / Possibly Affected | Hardened plaque deposits that can accelerate decay if present. |

## Final Verdict

### Verdict Level: Significant

Multiple regions of concern detected. Prompt consultation with a licensed dentist is strongly recommended for clinical examination and appropriate treatment planning.

## General Dental Health Recommendations

- Brush twice daily with fluoride toothpaste.
- Floss daily to remove interproximal plaque.
- Limit sugary and acidic food and drink intake.
- Schedule professional cleanings every 6 months.
- Drink fluoridated water where available.
- Do not ignore tooth sensitivity - seek early evaluation.