DentalAI

Dental Caries Detection Report

Patient Name	Kashif Bhutto	**Patient ID**	PT-2026-4MZU0
Report ID	RPT-ITR7C6EX	**Date of Analysis**	April 30, 2026
Time of Analysis	07:01 AM	**Analyzed File**	1_jpg.rf.d457f5e405ec791f72b2afe864e2a19b.j
Generated By	DentalAI AI-Assisted Dental Analysis System	**Average Confidence**	62.0% (Moderate)

This report is AI-generated and is intended for informational purposes only. It does not constitute a medical diagnosis. Please consult a licensed dental professional for clinical evaluation.

Radiographic Analysis - Annotated Image

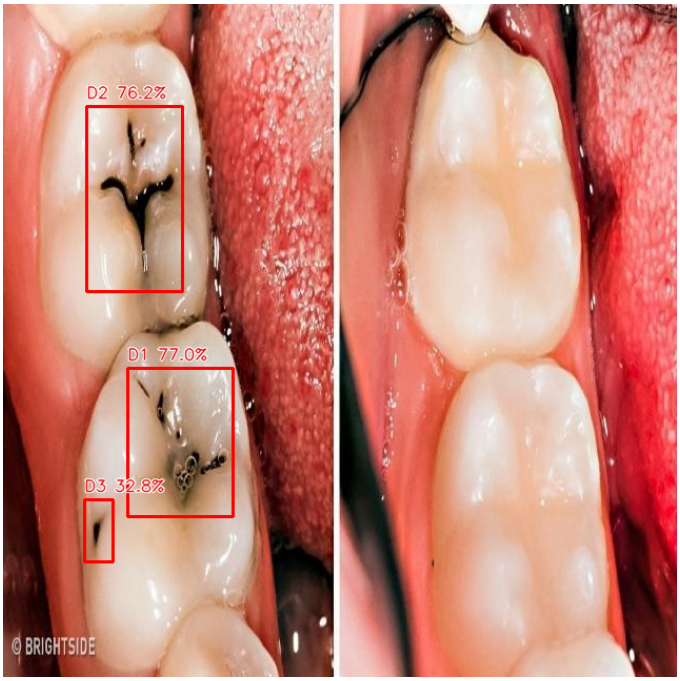

Figure 1: AI-detected regions of interest are highlighted. Each box corresponds to a suspected area of concern.

Detection #	Region Coordinates	Confidence Score	Severity Level
1	(118, 346) - (218, 487)	77.0%	High Concern
2	(79, 97) - (170, 273)	76.2%	High Concern
3	(77, 471) - (104, 530)	32.8%	Low Concern / Monitor

Clinical Terminology & Findings Explained

Term	Status	Brief Explanation
Dental Caries (Tooth Decay)	Detected / Possibly Affected	Bacterial destruction of tooth enamel caused by acid produced from sugars
Enamel	Detected / Possibly Affected	The hard outer layer of the tooth. Early caries often begins here.
Dentin	Detected / Possibly Affected	The layer beneath enamel. If caries penetrates here, sensitivity and pain m
Dental Pulp	Not Indicated	The innermost soft tissue of the tooth containing nerves and blood vessels.
Periapical Region	Detected / Possibly Affected	The area at the root tip. Infection here may appear as a dark shadow on X-
Interproximal Caries	Detected / Possibly Affected	Decay occurring between teeth, often harder to detect visually.
Occlusal Surface	Detected / Possibly Affected	The biting surface of the tooth where caries frequently begins in pits and fis
Calculus / Tartar	Detected / Possibly Affected	Hardened plaque deposits that can accelerate decay if present.

Final Verdict

Verdict Level: Significant

Multiple regions of concern detected. Prompt consultation with a licensed dentist is strongly recommended for clinical examination and appropriate treatment planning.

General Dental Health Recommendations

- Brush twice daily with fluoride toothpaste.
- Floss daily to remove interproximal plaque.
- Limit sugary and acidic food and drink intake.
- Schedule professional cleanings every 6 months.
- Drink fluoridated water where available.
- Do not ignore tooth sensitivity - seek early evaluation.