DentalAI

Dental Caries Detection Report

Patient Name	Kashif Bhutto	**Patient ID**	PT-2026-4MZU0
Report ID	RPT-P2NU1RLS	**Date of Analysis**	April 30, 2026
Time of Analysis	07:34 AM	**Analyzed File**	1_jpg.rf.03dbafc1a2ffeeaeda2754481b7e7551.j
Generated By	DentalAI AI-Assisted Dental Analysis System	**Average Confidence**	79.9% (High)

This report is AI-generated and is intended for informational purposes only. It does not constitute a medical diagnosis. Please consult a licensed dental professional for clinical evaluation.

Radiographic Analysis - Annotated Image

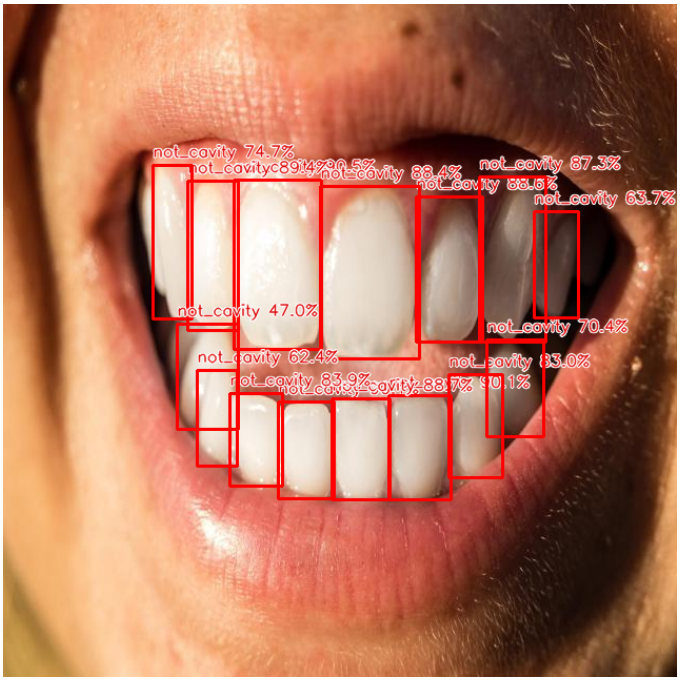

Figure 1: AI-detected regions of interest are highlighted. Each box corresponds to a suspected area of concern.

Class	Region Coordinates	Confidence Score	Severity Level
not_cavity	(219, 167) - (302, 328)	90.5%	High Concern
not_cavity	(261, 378) - (314, 470)	90.1%	High Concern
not_cavity	(366, 372) - (425, 471)	90.1%	High Concern
not_cavity	(175, 168) - (223, 310)	89.4%	High Concern
not_cavity	(312, 375) - (367, 471)	88.7%	High Concern
not_cavity	(392, 183) - (455, 321)	88.6%	High Concern
not_cavity	(301, 173) - (395, 337)	88.4%	High Concern
not_cavity	(452, 164) - (515, 321)	87.3%	High Concern
not_cavity	(215, 370) - (265, 458)	83.9%	High Concern
not_cavity	(423, 352) - (474, 450)	83.0%	High Concern
not_cavity	(142, 153) - (179, 299)	74.7%	Moderate Concern

not_cavity	(459, 319) - (513, 411)	70.4%	Moderate Concern
not_cavity	(504, 197) - (546, 298)	63.7%	Moderate Concern
not_cavity	(184, 348) - (222, 439)	62.4%	Moderate Concern
not_cavity	(165, 304) - (223, 404)	47.0%	Low Concern / Monitor

Clinical Terminology & Findings Explained

Term	Status	Brief Explanation
Dental Caries (Tooth Decay)	Detected / Possibly Affected	Bacterial destruction of tooth enamel caused by acid produced from sugars
Enamel	Detected / Possibly Affected	The hard outer layer of the tooth. Early caries often begins here.
Dentin	Detected / Possibly Affected	The layer beneath enamel. If caries penetrates here, sensitivity and pain m
Dental Pulp	Detected / Possibly Affected	The innermost soft tissue of the tooth containing nerves and blood vessels.
Periapical Region	Detected / Possibly Affected	The area at the root tip. Infection here may appear as a dark shadow on X-
Interproximal Caries	Detected / Possibly Affected	Decay occurring between teeth, often harder to detect visually.
Occlusal Surface	Detected / Possibly Affected	The biting surface of the tooth where caries frequently begins in pits and fis
Calculus / Tartar	Detected / Possibly Affected	Hardened plaque deposits that can accelerate decay if present.

Final Verdict

Verdict Level: Significant

Multiple regions of concern detected. Prompt consultation with a licensed dentist is strongly recommended for clinical examination and appropriate treatment planning.

General Dental Health Recommendations

- Brush twice daily with fluoride toothpaste.
- Floss daily to remove interproximal plaque.
- Limit sugary and acidic food and drink intake.
- Schedule professional cleanings every 6 months.
- Drink fluoridated water where available.
- Do not ignore tooth sensitivity - seek early evaluation.