DentalAI

Dental Caries Detection Report

Patient Name	shah Jahan	**Patient ID**	PT-2026-0958A
Report ID	RPT-3XSWMSTP	**Date of Analysis**	April 21, 2026
Time of Analysis	06:39 AM	**Analyzed File**	1_jpg.rf.03dbafc1a2ffeeaeda2754481b7e7551.j
Generated By	DentalAI AI-Assisted Dental Analysis System	**Average Confidence**	79.4% (High)

This report is AI-generated and is intended for informational purposes only. It does not constitute a medical diagnosis. Please consult a licensed dental professional for clinical evaluation.

Radiographic Analysis - Annotated Image

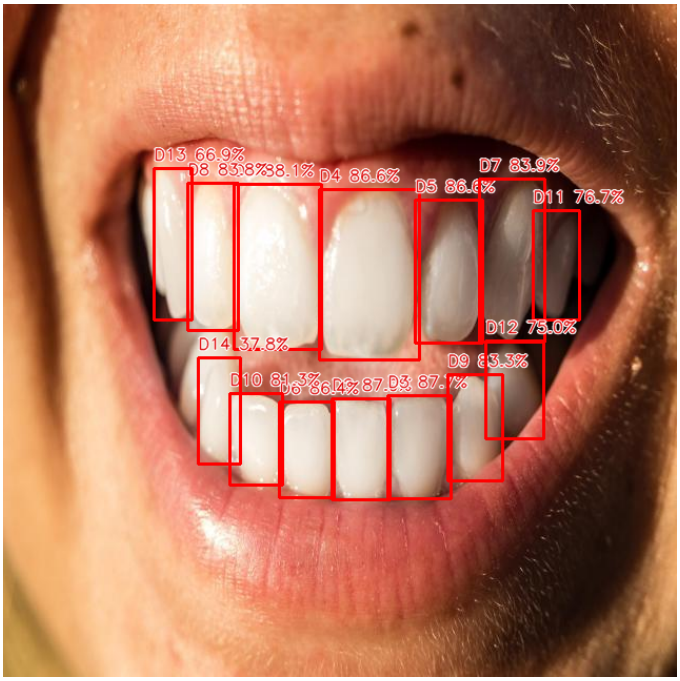

Figure 1: AI-detected regions of interest are highlighted. Each box corresponds to a suspected area of concern.

Detection #	Region Coordinates	Confidence Score	Severity Level
1	(219, 171) - (302, 328)	88.1%	High Concern
2	(312, 375) - (367, 471)	87.9%	High Concern
3	(365, 372) - (425, 470)	87.7%	High Concern
4	(300, 176) - (395, 338)	86.6%	High Concern
5	(391, 186) - (455, 322)	86.6%	High Concern
6	(262, 378) - (314, 469)	86.4%	High Concern
7	(452, 166) - (514, 321)	83.9%	High Concern
8	(175, 170) - (223, 310)	83.8%	High Concern
9	(422, 352) - (474, 453)	83.3%	High Concern
10	(215, 370) - (265, 457)	81.3%	High Concern
11	(503, 196) - (547, 300)	76.7%	High Concern

12	(458, 320) - (513, 413)	75.0%	High Concern
13	(143, 156) - (179, 300)	66.9%	Moderate Concern
14	(185, 336) - (225, 437)	37.8%	Low Concern / Monitor

Clinical Terminology & Findings Explained

Term	Status	Brief Explanation
Dental Caries (Tooth Decay)	Detected / Possibly Affected	Bacterial destruction of tooth enamel caused by acid produced from sugars
Enamel	Detected / Possibly Affected	The hard outer layer of the tooth. Early caries often begins here.
Dentin	Detected / Possibly Affected	The layer beneath enamel. If caries penetrates here, sensitivity and pain m
Dental Pulp	Detected / Possibly Affected	The innermost soft tissue of the tooth containing nerves and blood vessels.
Periapical Region	Detected / Possibly Affected	The area at the root tip. Infection here may appear as a dark shadow on X-
Interproximal Caries	Detected / Possibly Affected	Decay occurring between teeth, often harder to detect visually.
Occlusal Surface	Detected / Possibly Affected	The biting surface of the tooth where caries frequently begins in pits and fis
Calculus / Tartar	Detected / Possibly Affected	Hardened plaque deposits that can accelerate decay if present.

Final Verdict

Verdict Level: Significant

Multiple regions of concern detected. Prompt consultation with a licensed dentist is strongly recommended for clinical examination and appropriate treatment planning.

General Dental Health Recommendations

- Brush twice daily with fluoride toothpaste.
- Floss daily to remove interproximal plaque.
- Limit sugary and acidic food and drink intake.
- Schedule professional cleanings every 6 months.
- Drink fluoridated water where available.
- Do not ignore tooth sensitivity - seek early evaluation.