DentalAI

Dental Caries Detection Report

Patient Name	shah Jahan	**Patient ID**	PT-2026-0958A
Report ID	RPT-ADBDU9T2	**Date of Analysis**	April 21, 2026
Time of Analysis	06:28 AM	**Analyzed File**	1_jpg.rf.03dbafc1a2ffeeaeda2754481b7e7551.j
Generated By	DentalAI AI-Assisted Dental Analysis System	**Average Confidence**	71.3% (Moderate)

This report is AI-generated and is intended for informational purposes only. It does not constitute a medical diagnosis. Please consult a licensed dental professional for clinical evaluation.

Radiographic Analysis - Annotated Image

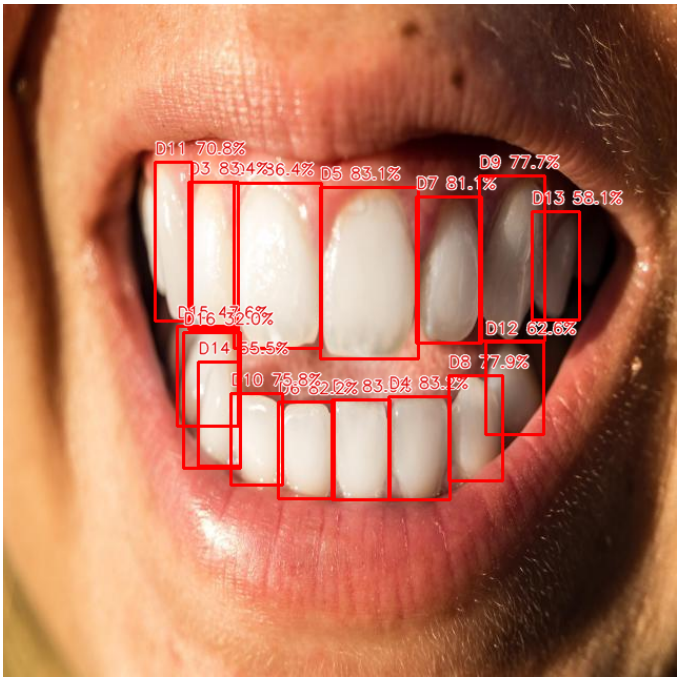

Figure 1: AI-detected regions of interest are highlighted. Each box corresponds to a suspected area of concern.

Detection #	Region Coordinates	Confidence Score	Severity Level
1	(219, 170) - (302, 327)	86.4%	High Concern
2	(312, 376) - (367, 471)	83.9%	High Concern
3	(176, 169) - (223, 309)	83.4%	High Concern
4	(366, 373) - (424, 471)	83.2%	High Concern
5	(301, 174) - (394, 337)	83.1%	High Concern
6	(261, 378) - (314, 470)	82.2%	High Concern
7	(392, 183) - (454, 322)	81.1%	High Concern
8	(423, 353) - (474, 453)	77.9%	High Concern
9	(452, 163) - (514, 320)	77.7%	High Concern
10	(216, 370) - (265, 457)	75.8%	High Concern
11	(144, 150) - (179, 301)	70.8%	Moderate Concern

12	(458, 321) - (513, 409)	62.6%	Moderate Concern
13	(502, 197) - (547, 300)	58.1%	Moderate Concern
14	(185, 340) - (225, 439)	55.5%	Moderate Concern
15	(165, 306) - (223, 401)	47.6%	Low Concern / Monitor
16	(171, 312) - (225, 441)	32.0%	Low Concern / Monitor

Clinical Terminology & Findings Explained

Term	Status	Brief Explanation
Dental Caries (Tooth Decay)	Detected / Possibly Affected	Bacterial destruction of tooth enamel caused by acid produced from sugars
Enamel	Detected / Possibly Affected	The hard outer layer of the tooth. Early caries often begins here.
Dentin	Detected / Possibly Affected	The layer beneath enamel. If caries penetrates here, sensitivity and pain m
Dental Pulp	Not Indicated	The innermost soft tissue of the tooth containing nerves and blood vessels.
Periapical Region	Detected / Possibly Affected	The area at the root tip. Infection here may appear as a dark shadow on X-
Interproximal Caries	Detected / Possibly Affected	Decay occurring between teeth, often harder to detect visually.
Occlusal Surface	Detected / Possibly Affected	The biting surface of the tooth where caries frequently begins in pits and fis
Calculus / Tartar	Detected / Possibly Affected	Hardened plaque deposits that can accelerate decay if present.

Final Verdict

Verdict Level: Significant

Multiple regions of concern detected. Prompt consultation with a licensed dentist is strongly recommended for clinical examination and appropriate treatment planning.

General Dental Health Recommendations

- Brush twice daily with fluoride toothpaste.
- Floss daily to remove interproximal plaque.
- Limit sugary and acidic food and drink intake.
- Schedule professional cleanings every 6 months.
- Drink fluoridated water where available.
- Do not ignore tooth sensitivity - seek early evaluation.