DentalAI

Dental Caries Detection Report

Patient Name	shah Jahan	**Patient ID**	PT-2026-0958A
Report ID	RPT-ASEU49T3	**Date of Analysis**	April 21, 2026
Time of Analysis	11:29 AM	**Analyzed File**	-17-_jpg.rf.0dd7183e2c6e7e1af379199cf01055
Generated By	DentalAI AI-Assisted Dental Analysis System	**Average Confidence**	43.8% (Low)

This report is AI-generated and is intended for informational purposes only. It does not constitute a medical diagnosis. Please consult a licensed dental professional for clinical evaluation.

Radiographic Analysis - Annotated Image

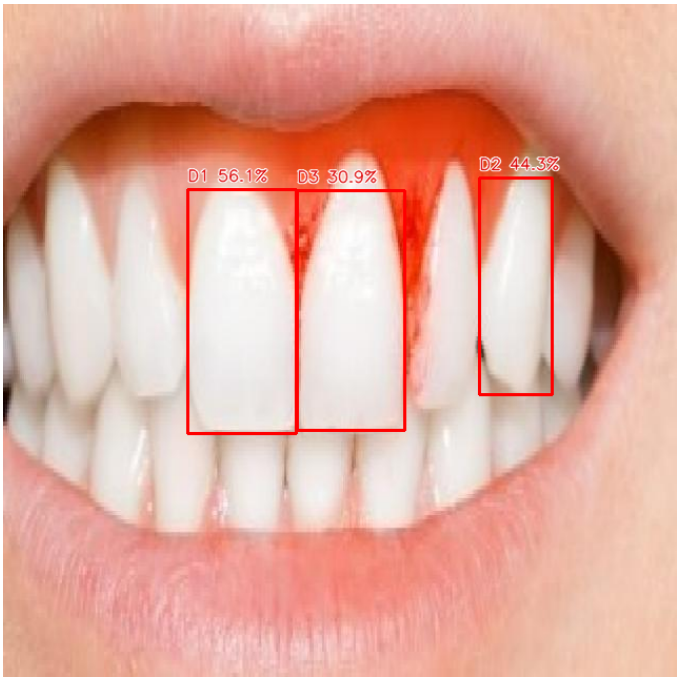

Figure 1: AI-detected regions of interest are highlighted. Each box corresponds to a suspected area of concern.

Detection #	Region Coordinates	Confidence Score	Severity Level
1	(175, 176) - (278, 408)	56.1%	Moderate Concern
2	(452, 165) - (521, 371)	44.3%	Low Concern / Monitor
3	(279, 177) - (381, 405)	30.9%	Low Concern / Monitor

Clinical Terminology & Findings Explained

Term	Status	Brief Explanation
Dental Caries (Tooth Decay)	Detected / Possibly Affected	Bacterial destruction of tooth enamel caused by acid produced from sugars
Enamel	Not Indicated	The hard outer layer of the tooth. Early caries often begins here.
Dentin	Not Indicated	The layer beneath enamel. If caries penetrates here, sensitivity and pain m
Dental Pulp	Not Indicated	The innermost soft tissue of the tooth containing nerves and blood vessels.
Periapical Region	Not Indicated	The area at the root tip. Infection here may appear as a dark shadow on X-
Interproximal Caries	Detected / Possibly Affected	Decay occurring between teeth, often harder to detect visually.
Occlusal Surface	Detected / Possibly Affected	The biting surface of the tooth where caries frequently begins in pits and fis
Calculus / Tartar	Not Indicated	Hardened plaque deposits that can accelerate decay if present.

Final Verdict

Verdict Level: Mild

Early or mild signs of dental caries may be present in 3 region(s). Professional evaluation is advised to confirm findings and discuss preventive care.

General Dental Health Recommendations

- Brush twice daily with fluoride toothpaste.
- Floss daily to remove interproximal plaque.
- Limit sugary and acidic food and drink intake.
- Schedule professional cleanings every 6 months.
- Drink fluoridated water where available.
- Do not ignore tooth sensitivity - seek early evaluation.