# DentalAI

## Dental Caries Detection Report

| | | | |
|---|---|---|---|
| **Patient Name** | shah Jahan | **Patient ID** | PT-2026-0958A |
| **Report ID** | RPT-P45B9UUB | **Date of Analysis** | April 21, 2026 |
| **Time of Analysis** | 06:39 AM | **Analyzed File** | 1_jpg.rf.03dbafc1a2ffeeaeda2754481b7e7551.j |
| **Generated By** | DentalAI AI-Assisted Dental Analysis System | **Average Confidence** | 79.4% (High) |

*This report is AI-generated and is intended for informational purposes only. It does not constitute a medical diagnosis. Please consult a licensed dental professional for clinical evaluation.*

## Radiographic Analysis - Annotated Image

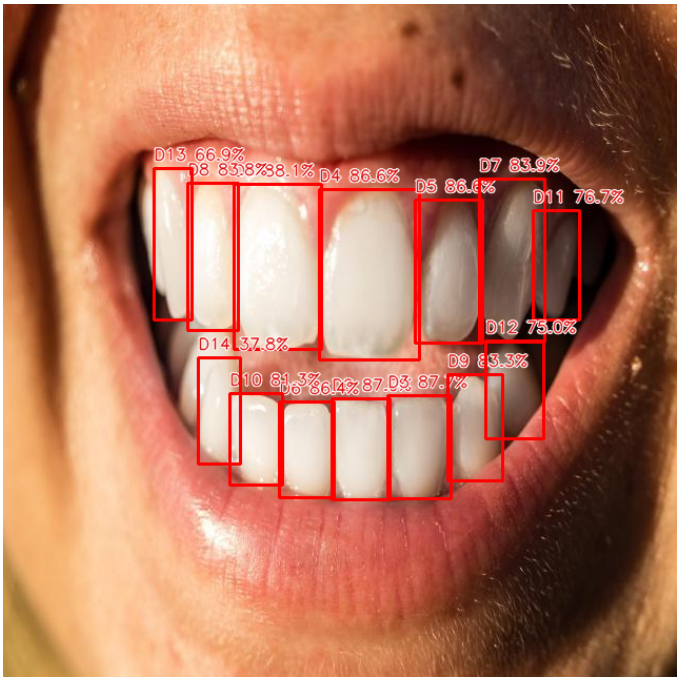


Figure 1: AI-detected regions of interest are highlighted. Each box corresponds to a suspected area of concern.

| Detection # | Region Coordinates | Confidence Score | Severity Level |
|---|---|---|---|
| 1 | (219, 171) - (302, 328) | 88.1% | High Concern |
| 2 | (312, 375) - (367, 471) | 87.9% | High Concern |
| 3 | (365, 372) - (425, 470) | 87.7% | High Concern |
| 4 | (300, 176) - (395, 338) | 86.6% | High Concern |
| 5 | (391, 186) - (455, 322) | 86.6% | High Concern |
| 6 | (262, 378) - (314, 469) | 86.4% | High Concern |
| 7 | (452, 166) - (514, 321) | 83.9% | High Concern |
| 8 | (175, 170) - (223, 310) | 83.8% | High Concern |
| 9 | (422, 352) - (474, 453) | 83.3% | High Concern |
| 10 | (215, 370) - (265, 457) | 81.3% | High Concern |
| 11 | (503, 196) - (547, 300) | 76.7% | High Concern |

| | | | |
|---|---|---|---|
| 12 | (458, 320) - (513, 413) | 75.0% | High Concern |
| 13 | (143, 156) - (179, 300) | 66.9% | Moderate Concern |
| 14 | (185, 336) - (225, 437) | 37.8% | Low Concern / Monitor |

## Clinical Terminology & Findings Explained

| Term | Status | Brief Explanation |
|---|---|---|
| Dental Caries (Tooth Decay) | Detected / Possibly Affected | Bacterial destruction of tooth enamel caused by acid produced from sugars |
| Enamel | Detected / Possibly Affected | The hard outer layer of the tooth. Early caries often begins here. |
| Dentin | Detected / Possibly Affected | The layer beneath enamel. If caries penetrates here, sensitivity and pain m |
| Dental Pulp | Detected / Possibly Affected | The innermost soft tissue of the tooth containing nerves and blood vessels. |
| Periapical Region | Detected / Possibly Affected | The area at the root tip. Infection here may appear as a dark shadow on X- |
| Interproximal Caries | Detected / Possibly Affected | Decay occurring between teeth, often harder to detect visually. |
| Occlusal Surface | Detected / Possibly Affected | The biting surface of the tooth where caries frequently begins in pits and fis |
| Calculus / Tartar | Detected / Possibly Affected | Hardened plaque deposits that can accelerate decay if present. |

## Final Verdict

### Verdict Level: Significant

Multiple regions of concern detected. Prompt consultation with a licensed dentist is strongly recommended for clinical examination and appropriate treatment planning.

## General Dental Health Recommendations

- Brush twice daily with fluoride toothpaste.
- Floss daily to remove interproximal plaque.
- Limit sugary and acidic food and drink intake.
- Schedule professional cleanings every 6 months.
- Drink fluoridated water where available.
- Do not ignore tooth sensitivity - seek early evaluation.