VINBIGDATA

VinDr-CXR: An open dataset of chest X-rays with radiologist's annotations

•Gồm **18.000 ảnh X-quang ngực tư thế PA**.
•Chia thành:
•**15.000 ảnh train**
•**3.000 ảnh test**
•Ảnh được thu thập từ các bệnh viện lớn tại Việt Nam.
•Ảnh được chú thích bởi **17 bác sĩ chẩn đoán hình ảnh**, mỗi người có ít nhất 8 năm kinh nghiệm.
•Mỗi ảnh train được gán nhãn độc lập bởi **3 bác sĩ**.

•**!! Không có thông tin trẻ em và demographic**

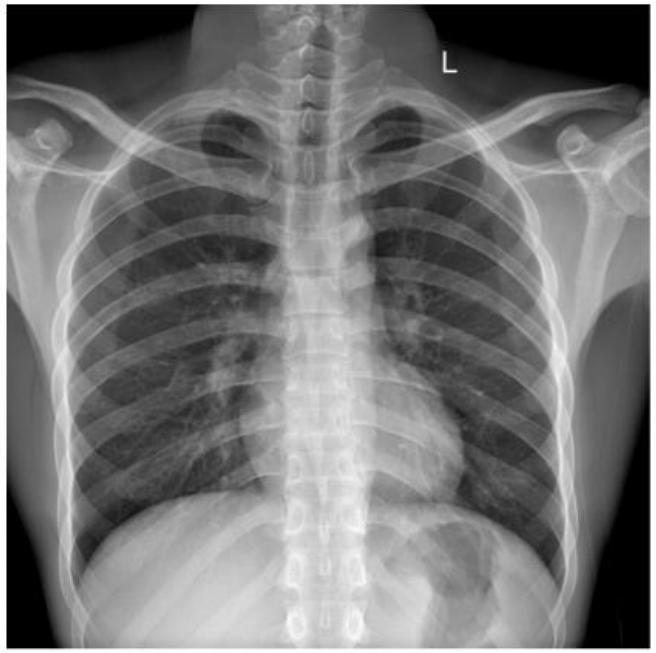

No finding

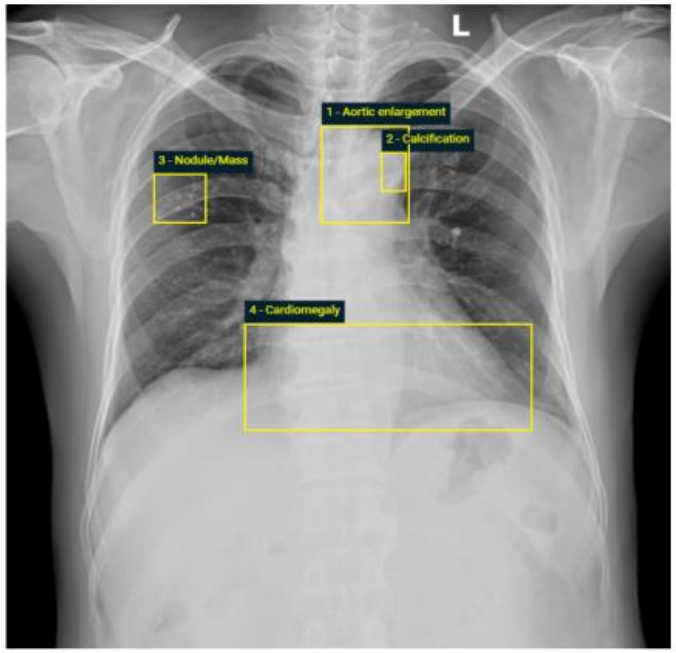

Tuberculosis

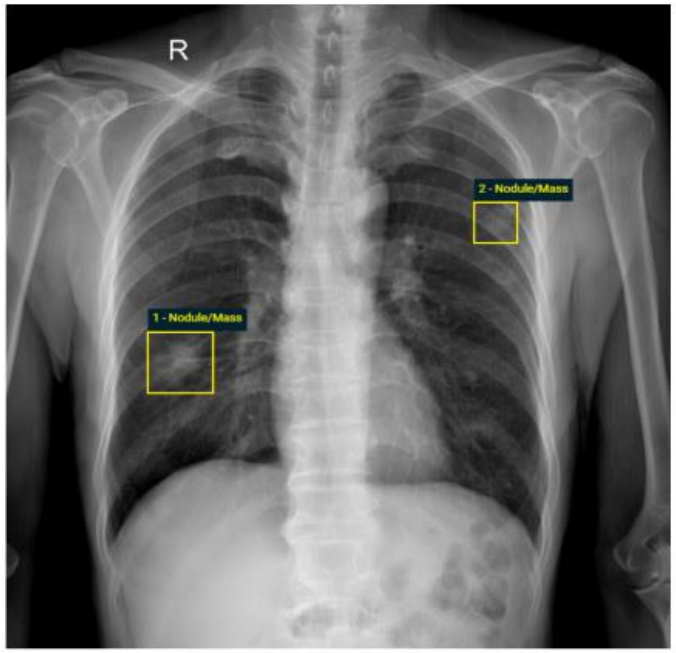

Lung tumor

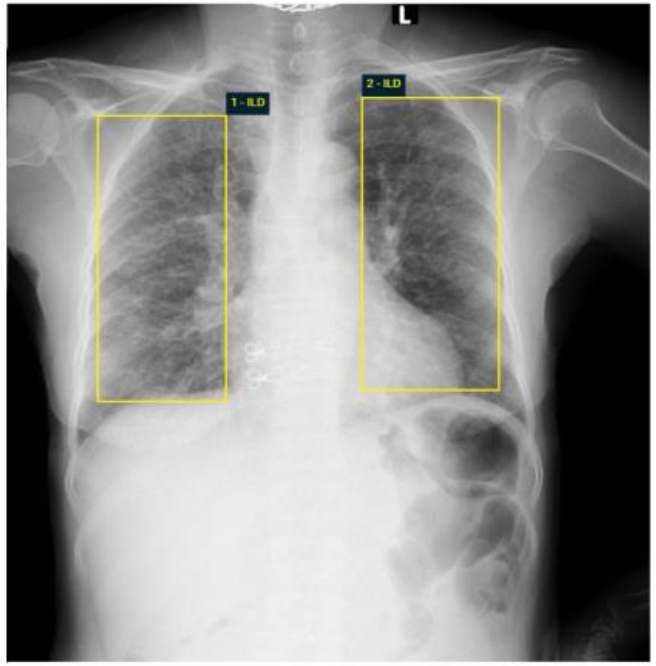

Pneumonia

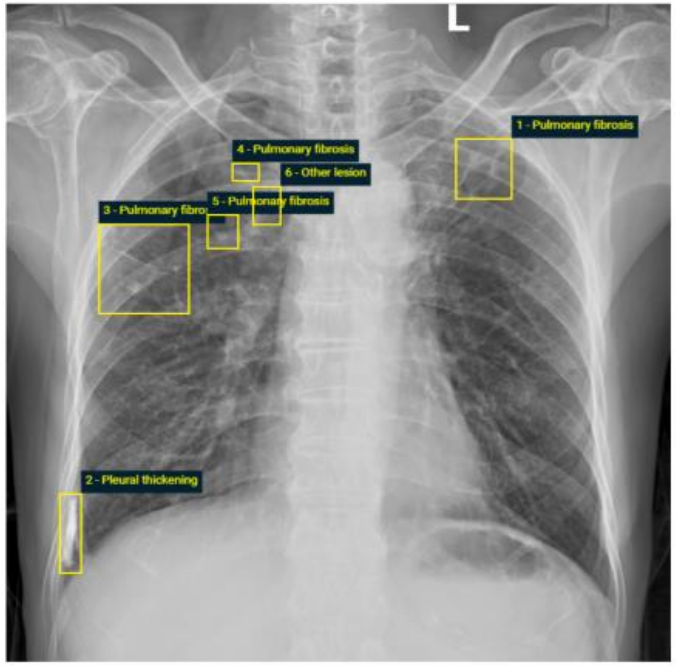

Tuberculosis

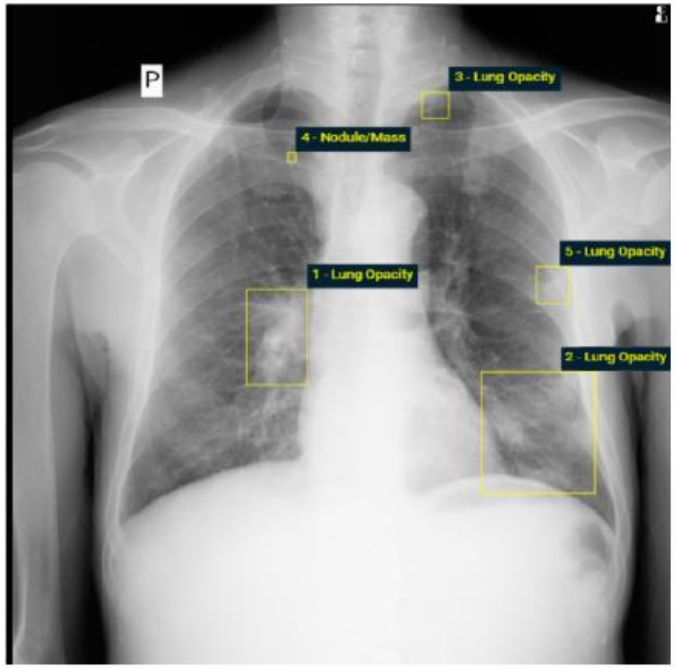

Pneumonia , Lung tumor

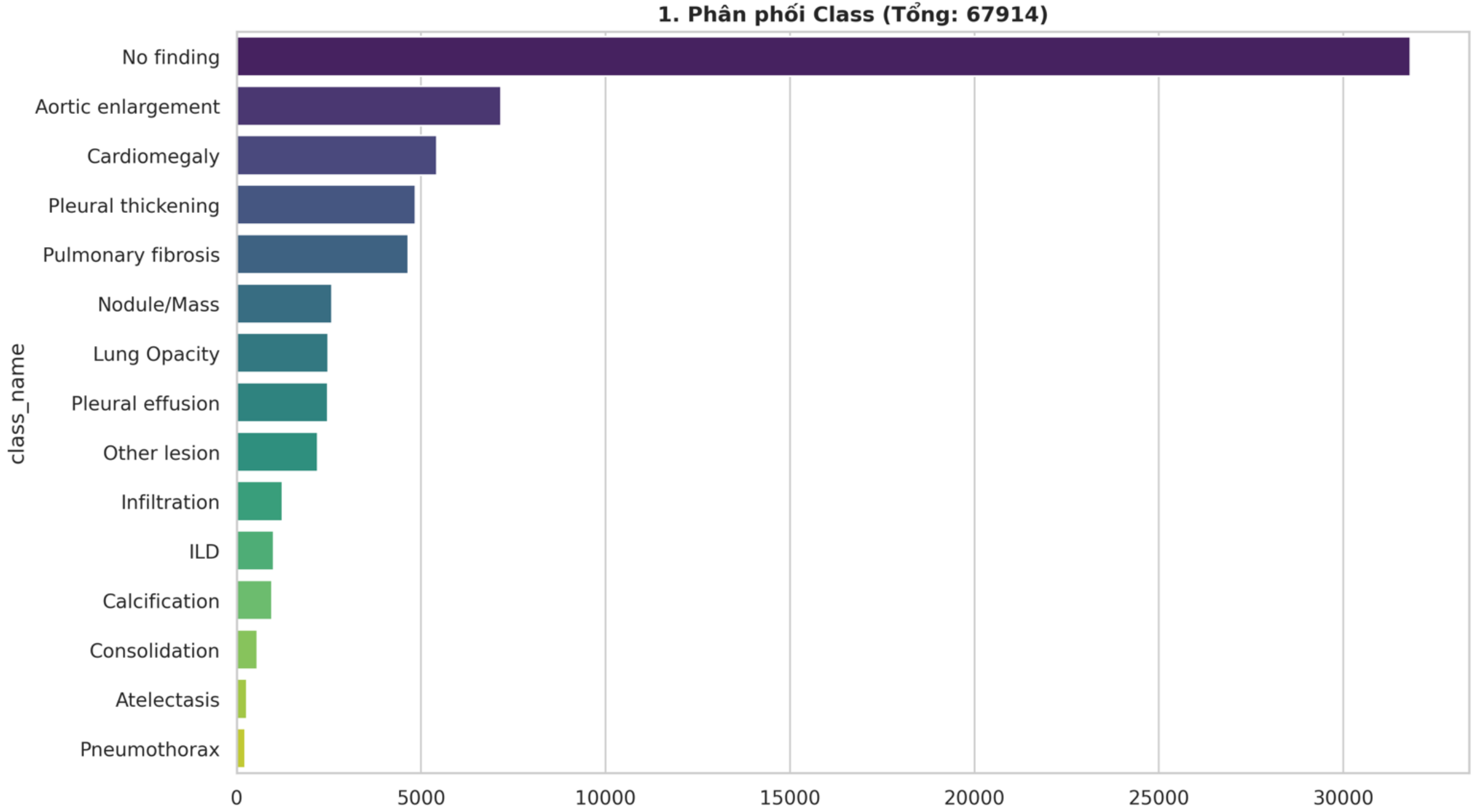
1. Phân phối Class (Tổng: 67914)
class_name
No finding
Aortic enlargement
Cardiomegaly
Pleural thickening
Pulmonary fibrosis
Nodule/Mass
Lung Opacity
Pleural effusion
Other lesion
Infiltration
ILD
Calcification
Consolidation
Atelectasis
Pneumothorax
0
5000
10000
15000
20000
25000
30000

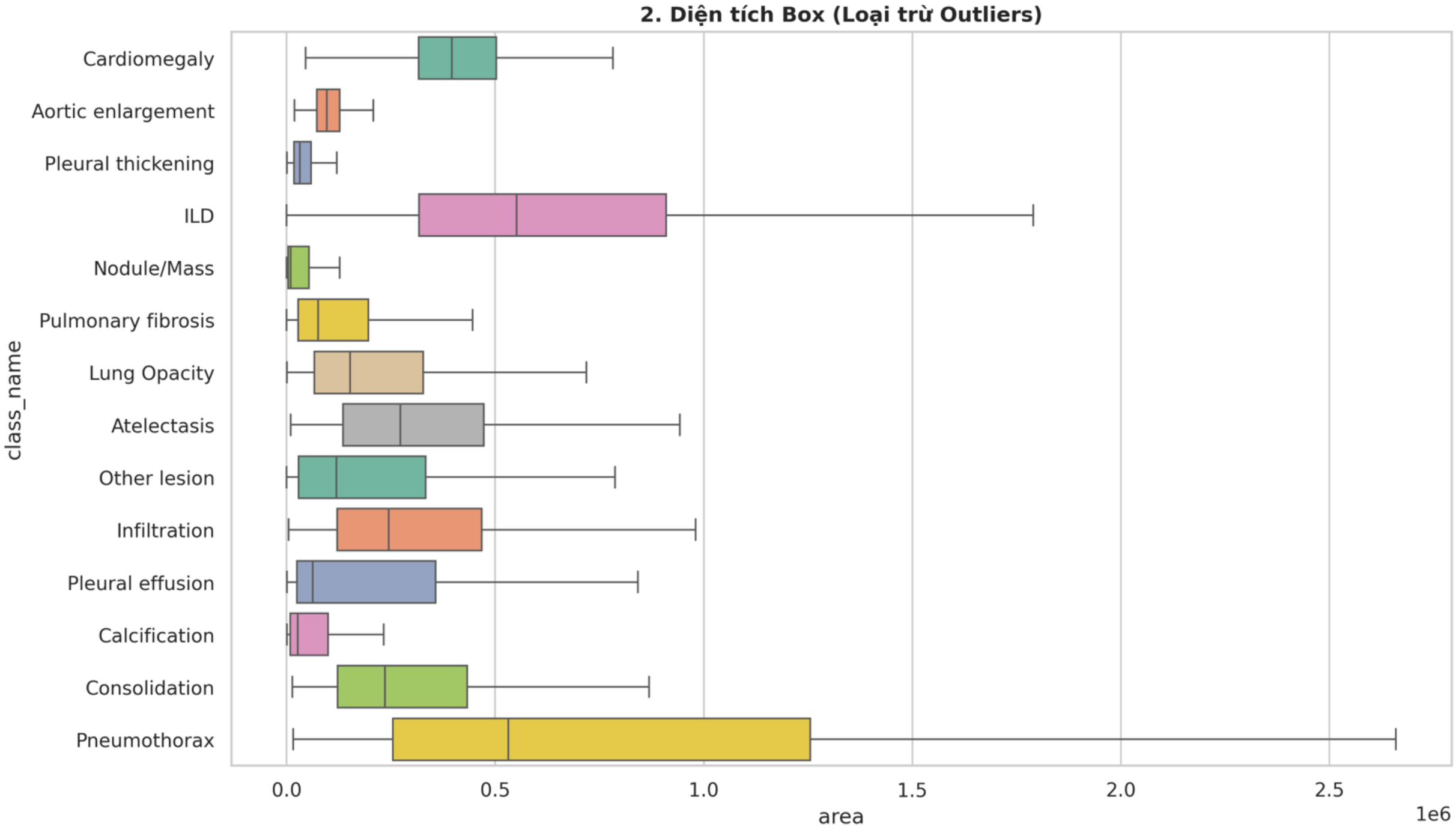
2. Diện tích Box (Loại trừ Outliers)
Cardiomegaly
Aortic enlargement
Pleural thickening
ILD
Nodule/Mass
Pulmonary fibrosis
Lung Opacity
Atelectasis
Other lesion
Infiltration
Pleural effusion
Calcification
Consolidation
Pneumothorax
class_name
0.0
0.5
1.0
1.5
2.0
2.5
1e6
area

3. Ma trận Bệnh lý Đồng xuất hiện

class_name	Aortic enlargement	Atelectasis	Calcification	Cardiomegaly	Consolidation	ILD	Infiltration	Lung Opacity	Nodule/Mass	Other lesion	Pleural effusion	Pleural thickening	Pneumothorax	Pulmonary fibrosis
Aortic enlargement	0	74	301	1973	156	238	302	771	498	724	571	1339	35	940
Atelectasis	74	0	35	38	57	22	49	103	43	83	90	123	16	130
Calcification	301	35	0	174	25	51	35	113	187	175	87	253	3	229
Cardiomegaly	1973	38	174	0	103	122	181	507	279	512	348	858	17	535
Consolidation	156	57	25	103	0	32	139	297	124	109	194	194	25	187
ILD	238	22	51	122	32	0	137	128	78	124	103	209	5	211
Infiltration	302	49	35	181	139	137	0	378	109	174	222	322	10	414
Lung Opacity	771	103	113	507	297	128	378	0	395	482	543	710	52	666
Nodule/Mass	498	43	187	279	124	78	109	395	0	328	205	410	16	380
Other lesion	724	83	175	512	109	124	174	482	328	0	367	619	47	510
Pleural effusion	571	90	87	348	194	103	222	543	205	367	0	839	60	499
Pleural thickening	1339	123	253	858	194	209	322	710	410	619	839	0	60	971
Pneumothorax	35	16	3	17	25	5	10	52	16	47	60	60	0	34
Pulmonary fibrosis	940	130	229	535	187	211	414	666	380	510	499	971	34	0

class_name

1750
1500
1250
1000
750
500
250
0

Mỗi ảnh train được gán nhãn bởi 3 bác sĩ

Nhiễu Label

Chồng lấp Box

WBF - Weighted Boxes Fusion

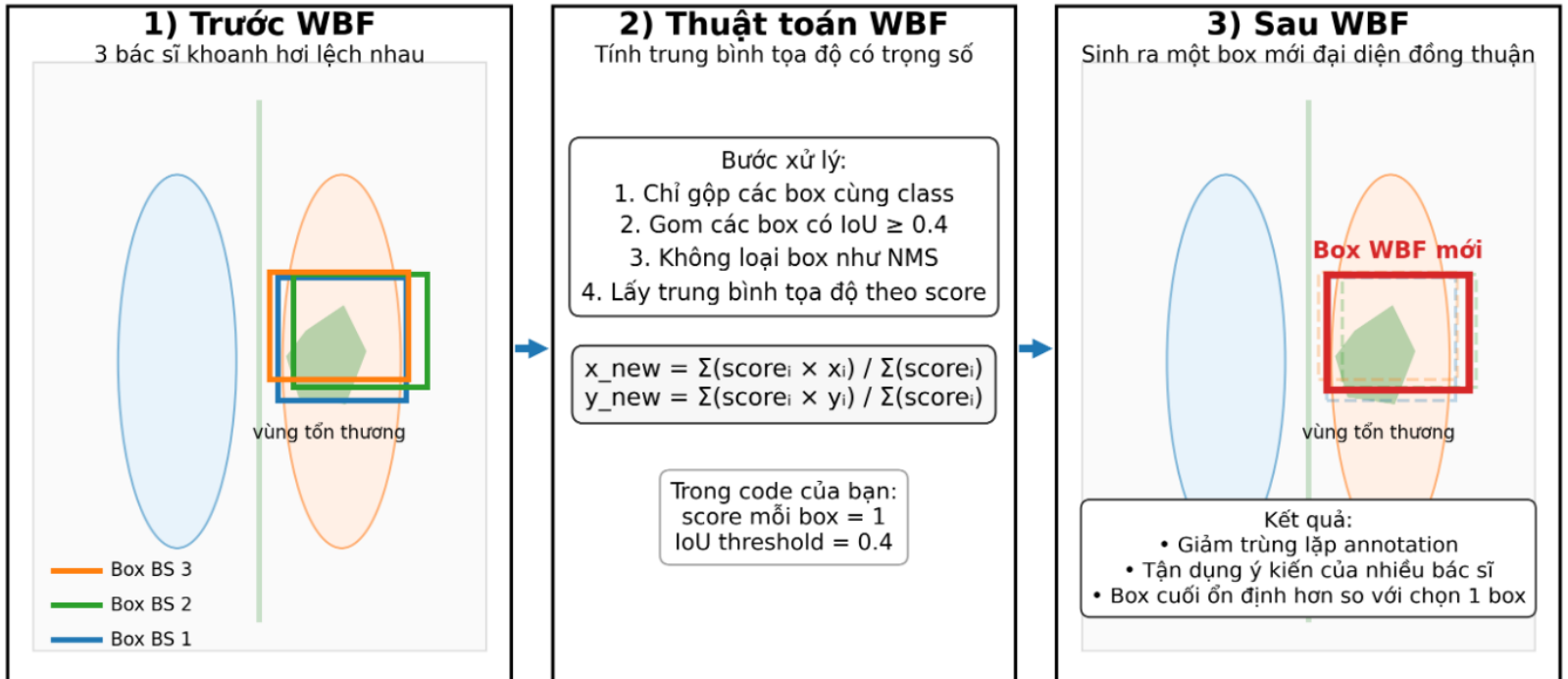

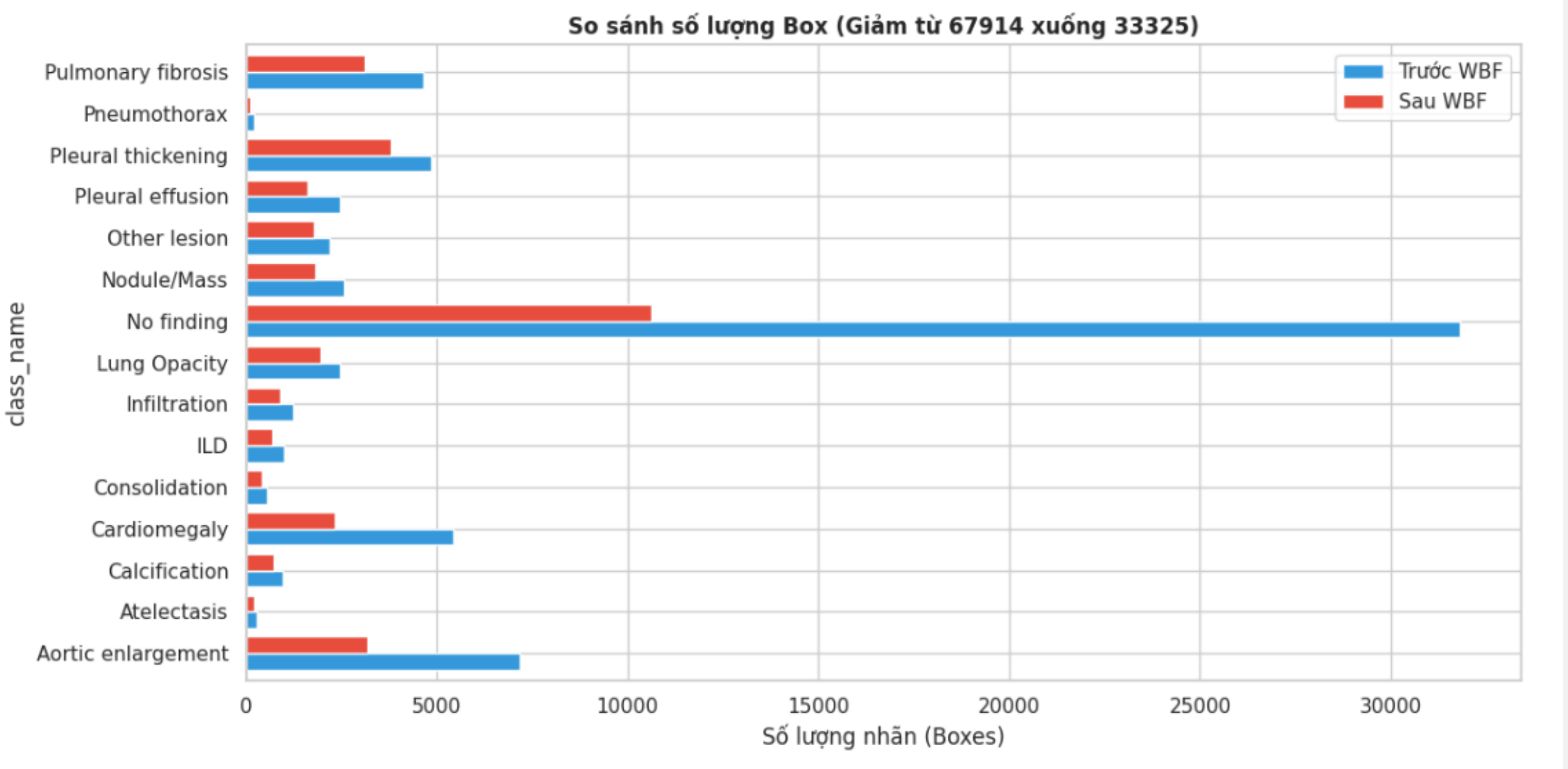
So sánh số lượng Box (Giảm từ 67914 xuống 33325)
Trước WBF
Sau WBF
class_name
Pulmonary fibrosis
Pneumothorax
Pleural thickening
Pleural effusion
Other lesion
Nodule/Mass
No finding
Lung Opacity
Infiltration
ILD
Consolidation
Cardiomegaly
Calcification
Atelectasis
Aortic enlargement
0
5000
10000
15000
20000
25000
30000
Số lượng nhãn (Boxes)

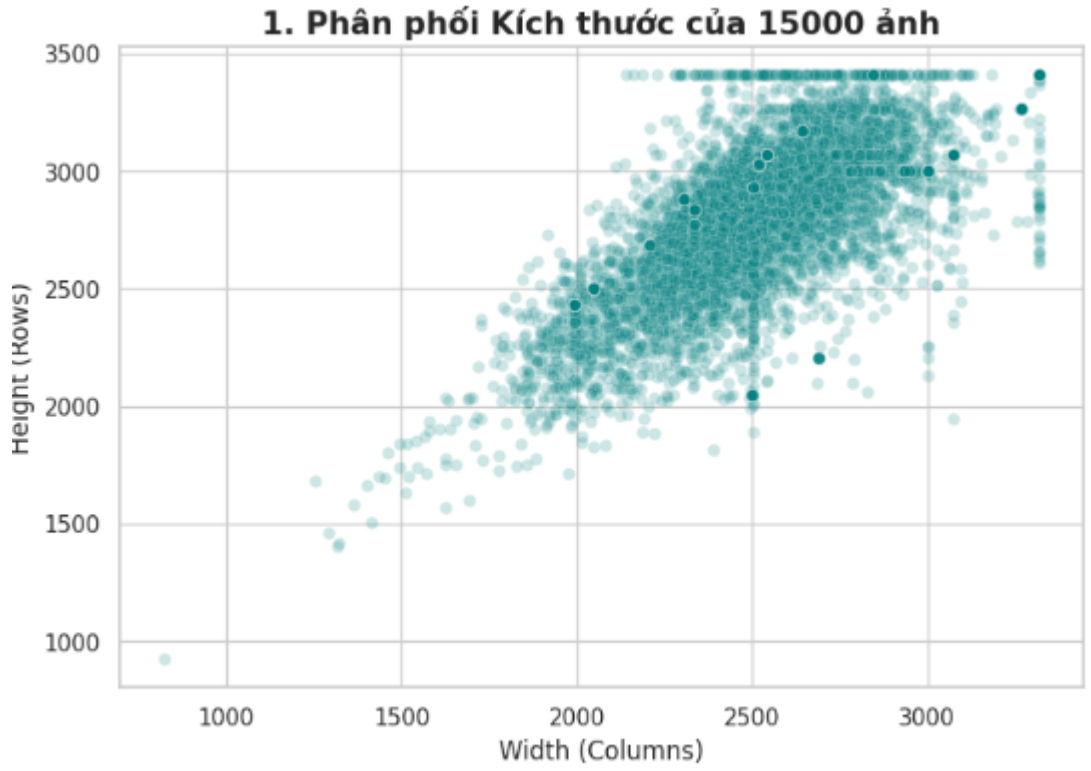

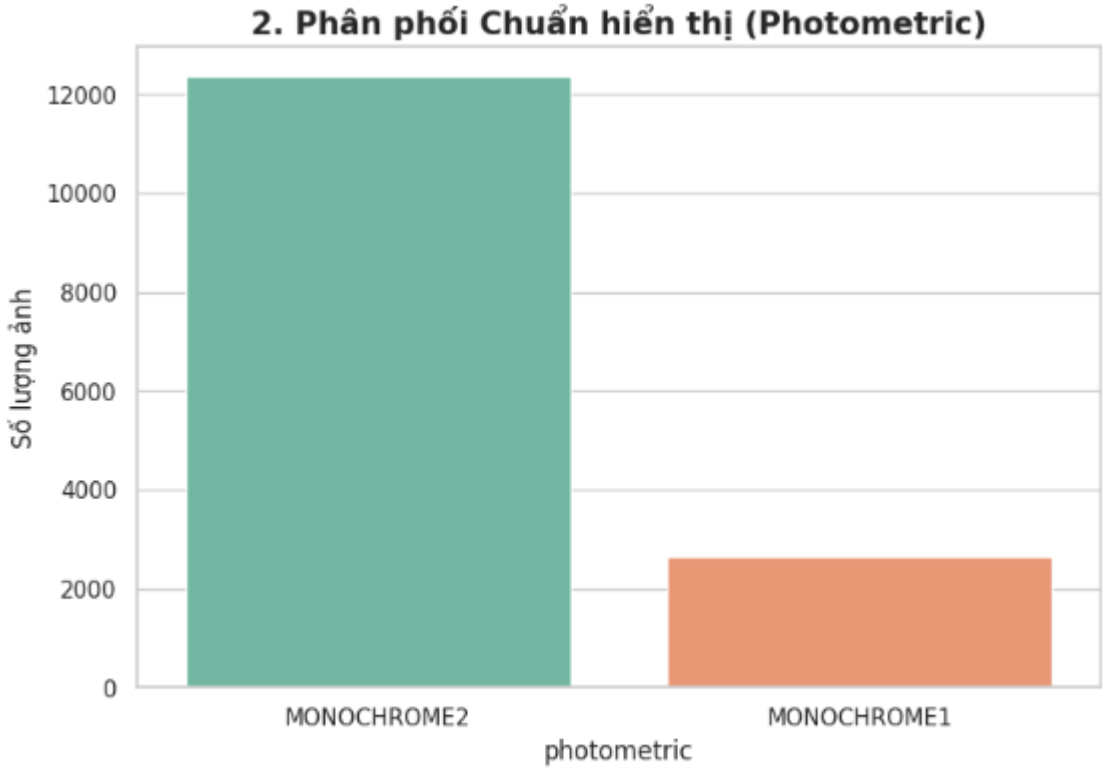

Kích thước ảnh không đồng nhất:

- Width: **823** → **3320**, trung bình **2446**
- Height: **927** → **3408**, trung bình **2787**
- Aspect ratio: **0.63** → **1.58**

Dữ liệu gồm 2 chuẩn hiển thị:

- **MONOCHROME2: 12.357 ảnh ~ 82.4%**
- **MONOCHROME1: 2.643 ảnh ~ 17.6%**

```
Tensor: torch.Size([3, 512, 512]) | torch.float32
Label ID: 3
Pixel: 0.00 - 1.00
```

Test Dataloader - Label: 3
(Letterbox & Normalized)

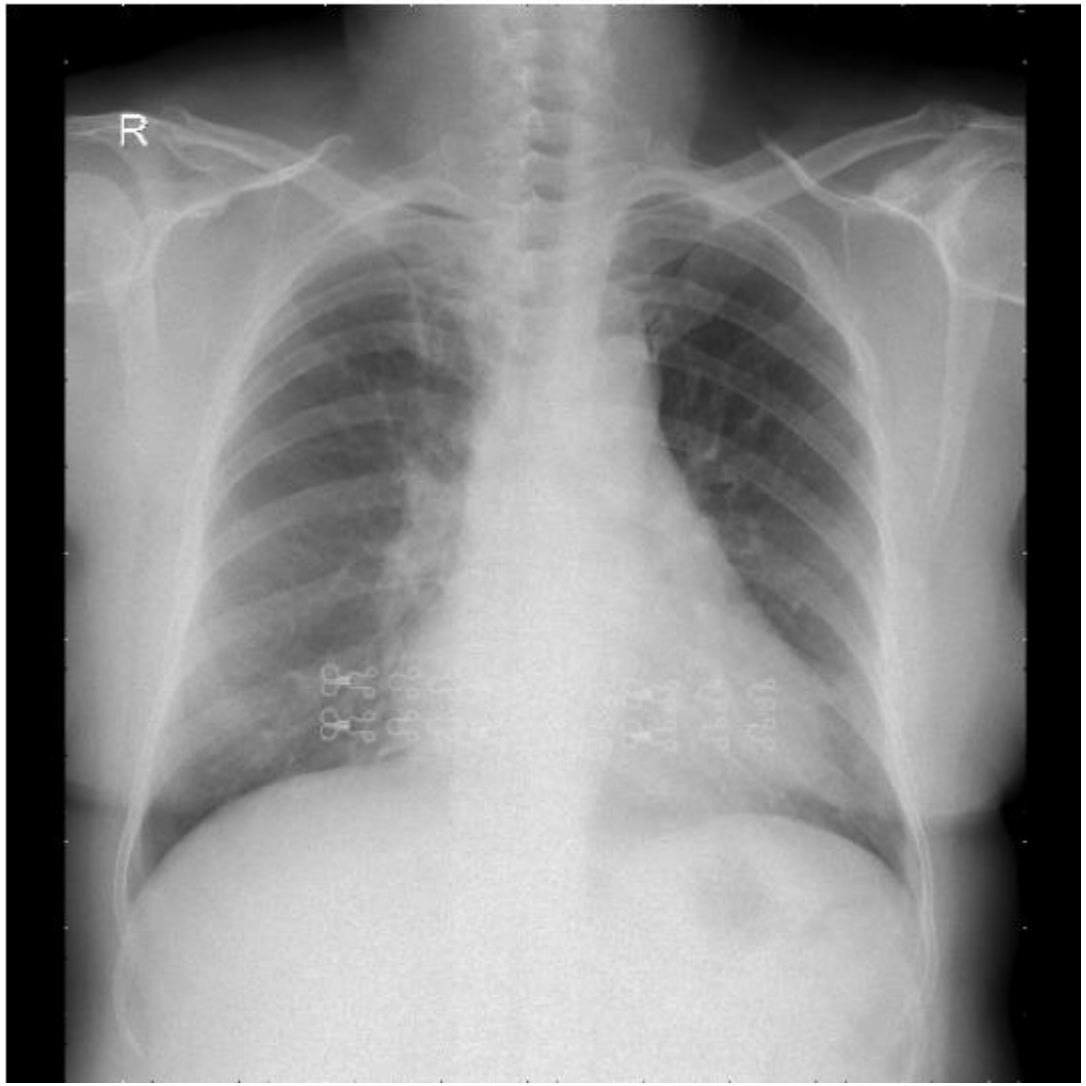

Preprocessing Pipeline:

```
DICOM image
   ↓
Đọc pixel bằng pydicom
   ↓
Apply VOI LUT
   ↓
Xử lý MONOCHROME1 / MONOCHROME2
   ↓
Normalize pixel về [0, 255]
   ↓
Convert grayscale → RGB
   ↓
Letterbox resize về 512×512
   ↓
Convert thành PyTorch Tensor [3, 512, 512]
   ↓
Return image tensor + class_id
```

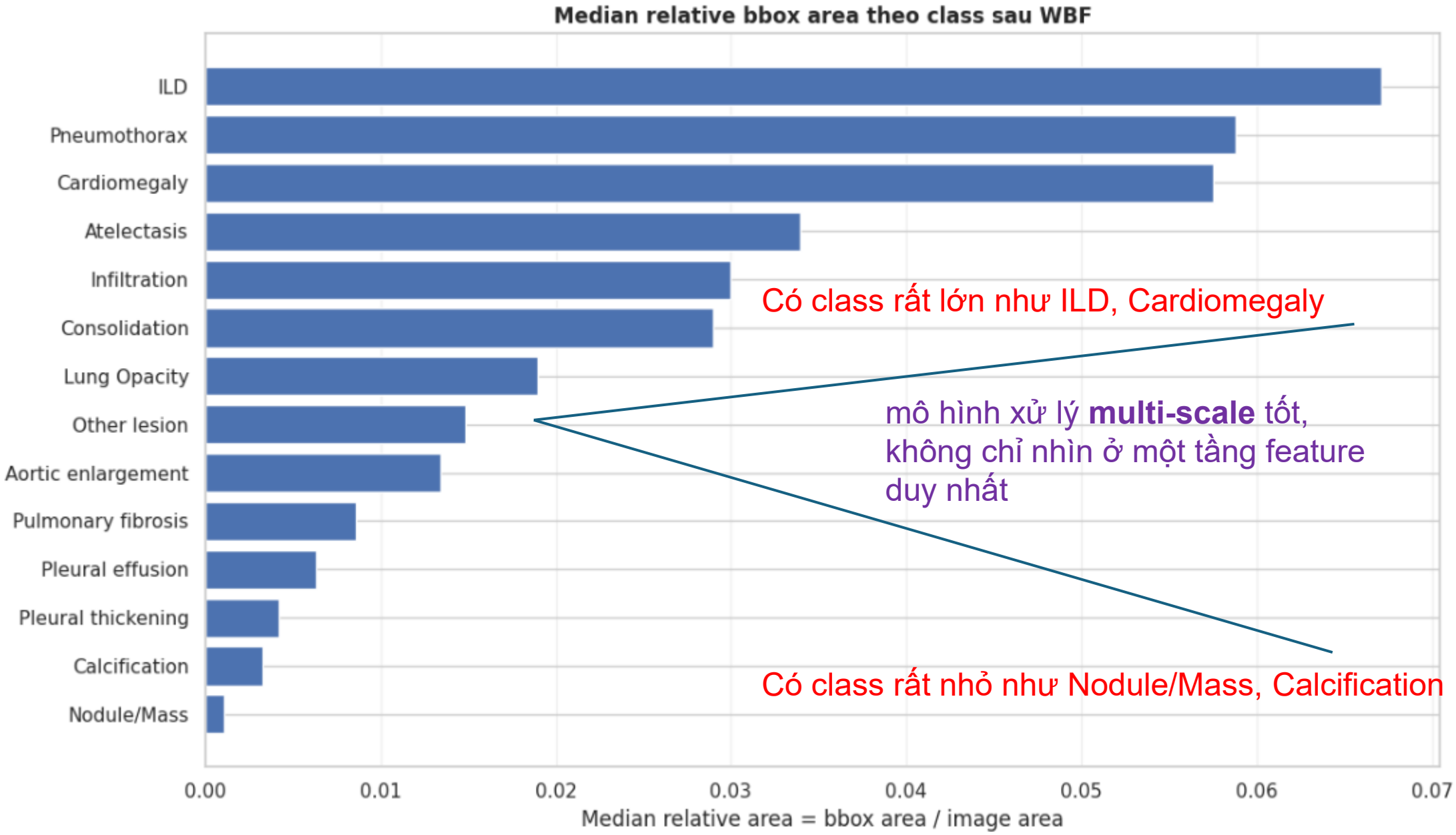
Median relative bbox area theo class sau WBF
ILD
Pneumothorax
Cardiomegaly
Atelectasis
Infiltration
Consolidation
Lung Opacity
Other lesion
Aortic enlargement
Pulmonary fibrosis
Pleural effusion
Pleural thickening
Calcification
Nodule/Mass
0.00
0.01
0.02
0.03
0.04
0.05
0.06
0.07
Median relative area = bbox area / image area
Có class rất lớn như ILD, Cardiomegaly
mô hình xử lý multi-scale tốt, không chỉ nhìn ở một tầng feature duy nhất
Có class rất nhỏ như Nodule/Mass, Calcification

[1] Rajpurkar et al., “CheXNet: Radiologist-Level Pneumonia Detection on Chest X-Rays with Deep Learning,” arXiv, 2017.
[2] Nguyen et al., “VinDr-CXR: An open dataset of chest X-rays with radiologist’s annotations,” Scientific Data, 2022.

v:1711.05225v3 [cs.CV] 25 Dec 2017

Matthew P. Lungren[3] Andrew Y. Ng[1]

Abstract

We develop an algorithm that can detect pneumonia from chest X-rays at a level exceeding practicing radiologists. Our algorithm, CheXNet, is a 121-layer convolutional neural network trained on ChestX-ray14, currently the largest publicly available chest X-ray dataset, containing over 100,000 frontal-view X-ray images with 14 diseases. Four practicing academic radiologists annotate a test set, on which we compare the performance of CheXNet to that of radiologists. We find that CheXNet exceeds average radiologist performance on the F1 metric. We extend CheXNet to detect all 14 diseases in ChestX-ray14 and achieve state of the art results on all 14 diseases.

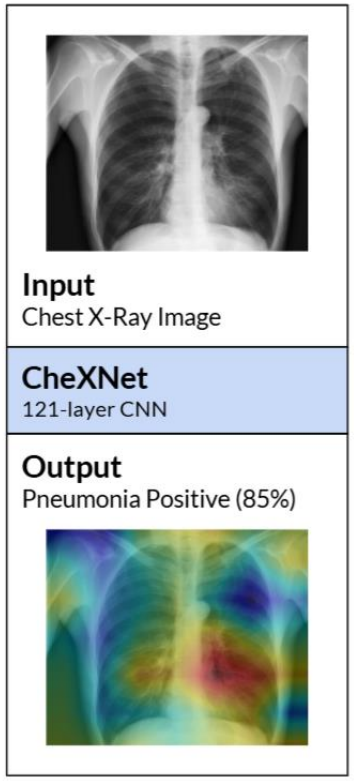

1. Introduction

More than 1 million adults are hospitalized with pneumonia and around 50,000 die from the disease every year in the US alone (CDC, 2017). Chest X-rays

dự đoán bệnh ở mức toàn ảnh nhưng chưa localize chính xác vùng tổn thương

re.com/scientificdata/

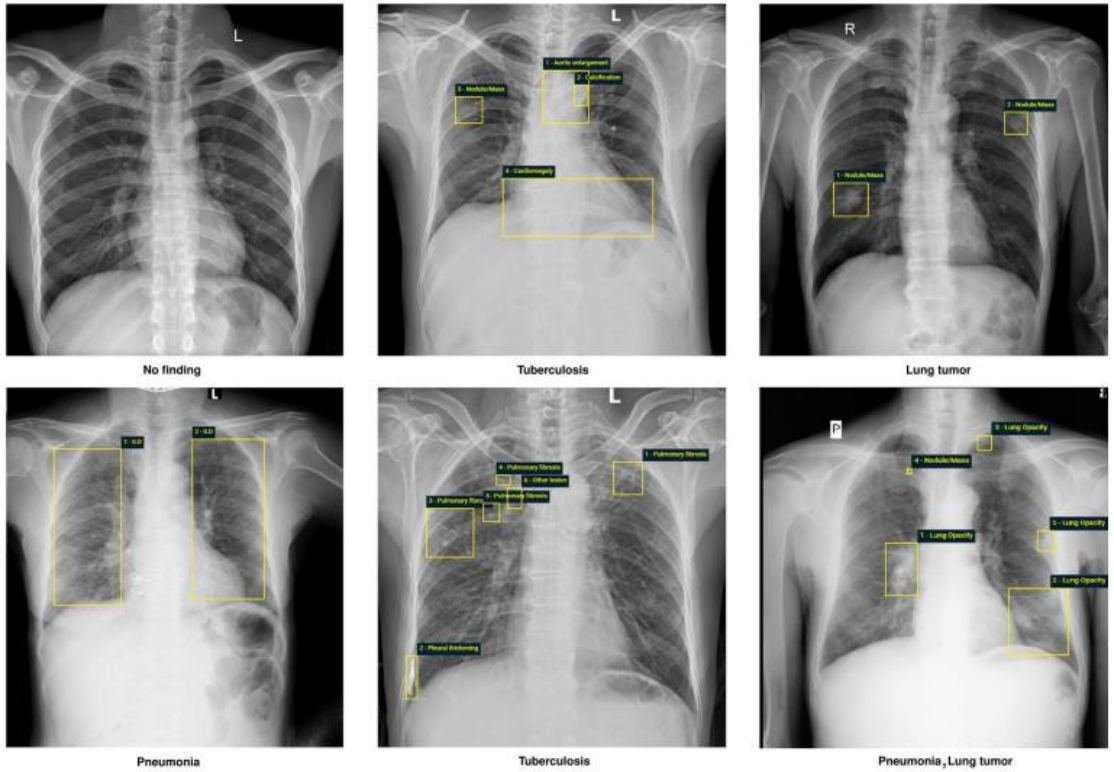

Fig. 3 Examples of CXRs with radiologist’s annotations. Abnormal findings (local labels) marked by radiologists are plotted on the original images for visualization purpose. The global labels are in bold and listed at the bottom of each example. Better viewed on a computer and zoomed in for details.

phù hợp hơn với object detection

bbox có kích thước rất khác nhau, từ Nodule/Mass rất nhỏ đến Cardiomegaly rất lớn

Lựa chọn detector

DINO với multi-scale feature thay vì chỉ dùng classifier.

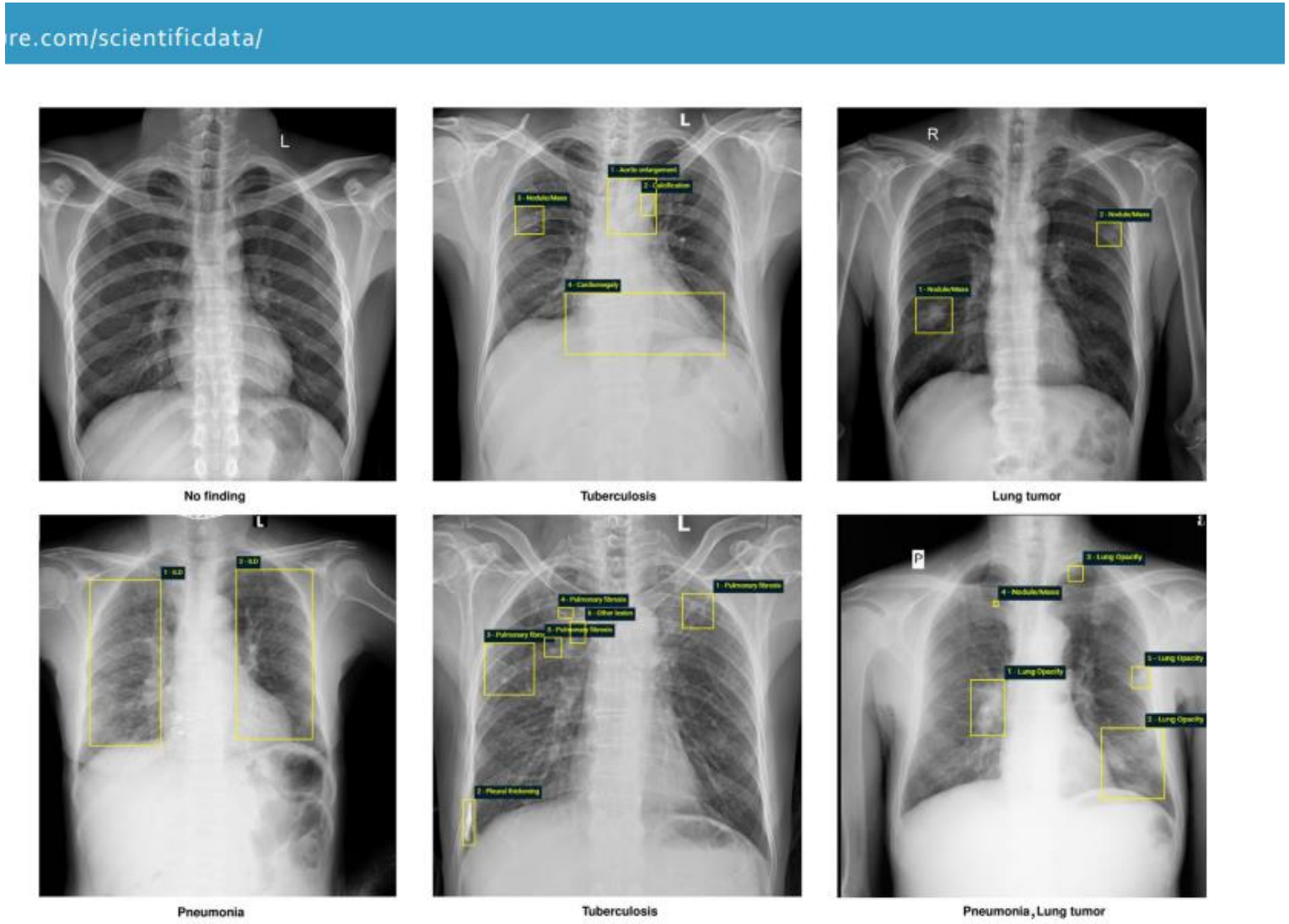

Fig. 3 Examples of CXRs with radiologist's annotations. Abnormal findings (local labels) marked by radiologists are plotted on the original images for visualization purpose. The global labels are in bold and listed at the bottom of each example. Better viewed on a computer and zoomed in for details.

KIẾN TRÚC MÔ HÌNH: DINO DETECTOR VỚI RESNET-50 BACKBONE

Mục tiêu: *Phát hiện và định vị 14 bất thường trên ảnh X-quang ngực (bounding box + nhân bệnh + độ tin cậy)*

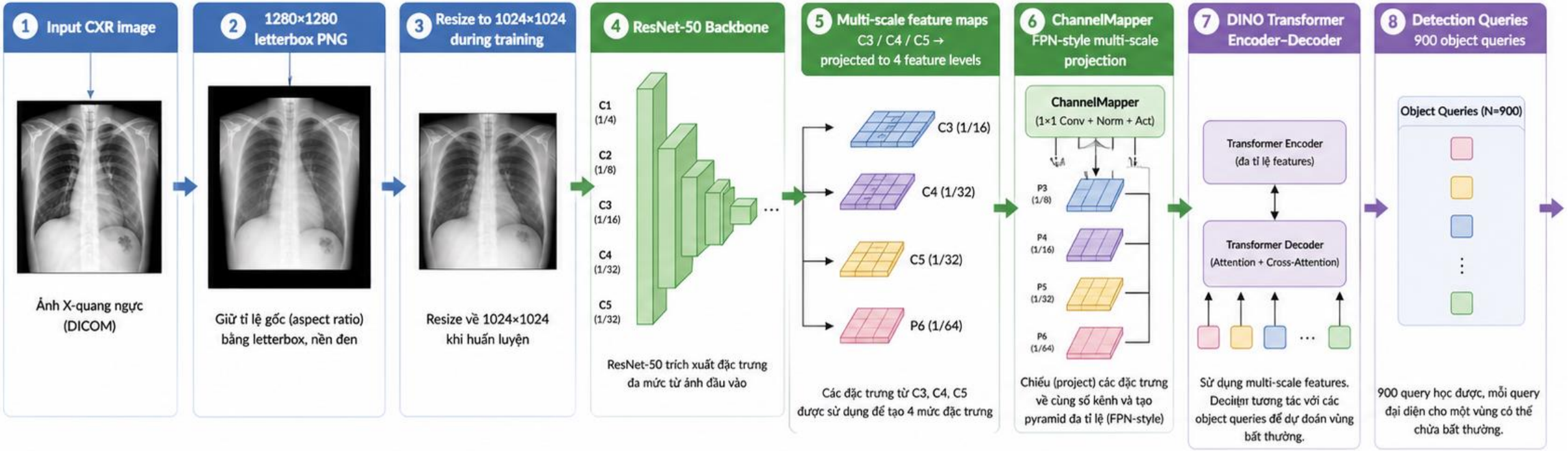

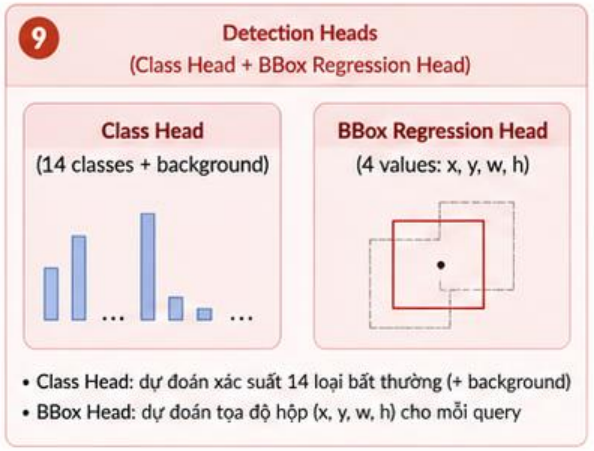

10 Output

[disease class, bounding box, confidence score]

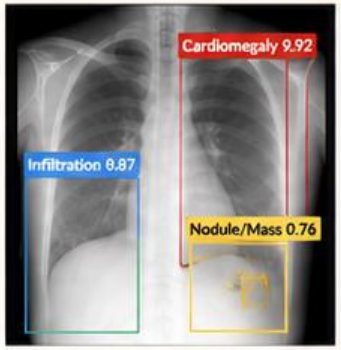

Class (14)	Bounding Box (x_1, y_1, x_2, y_2)	Score
Cardiomegaly	(120, 80, 900, 920)	0.92
Infiltration	(50, 200, 350, 600)	0.87
Nodule/Mass	(700, 620, 950, 900)	0.76
...	...	...

- Predict đồng thời: lớp bệnh + tọa độ bbox + độ tin cậy
- Hỗ trợ phát hiện cả bất thường nhỏ (vd: Nodule) và lớn (vd: Cardiomegaly, ILD) nhờ đặc trưng đa tỉ lệ
- Huấn luyện end-to-end với hàm mất mát: Classification + L1 bbox + GIoU + Hungarian matching

Thông tin mô hình chính

- Backbone: ResNet-50
- Số mức feature: 4 (P3, P4, P5, P6)
- Số object queries: 900
- Số lớp bệnh: 14

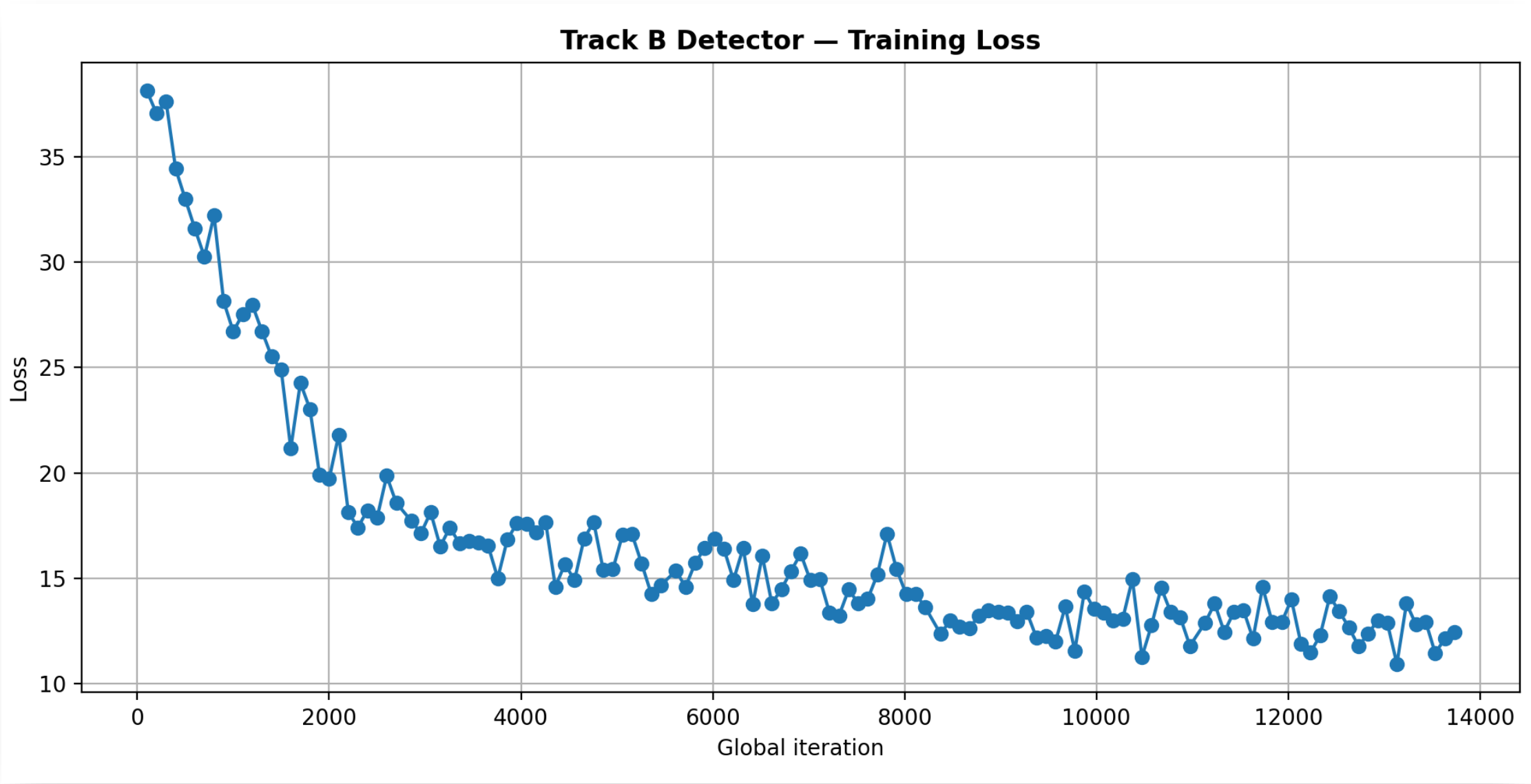
Track B Detector — Training Loss
Loss
Global iteration
35
30
25
20
15
10
0
2000
4000
6000
8000
10000
12000
14000

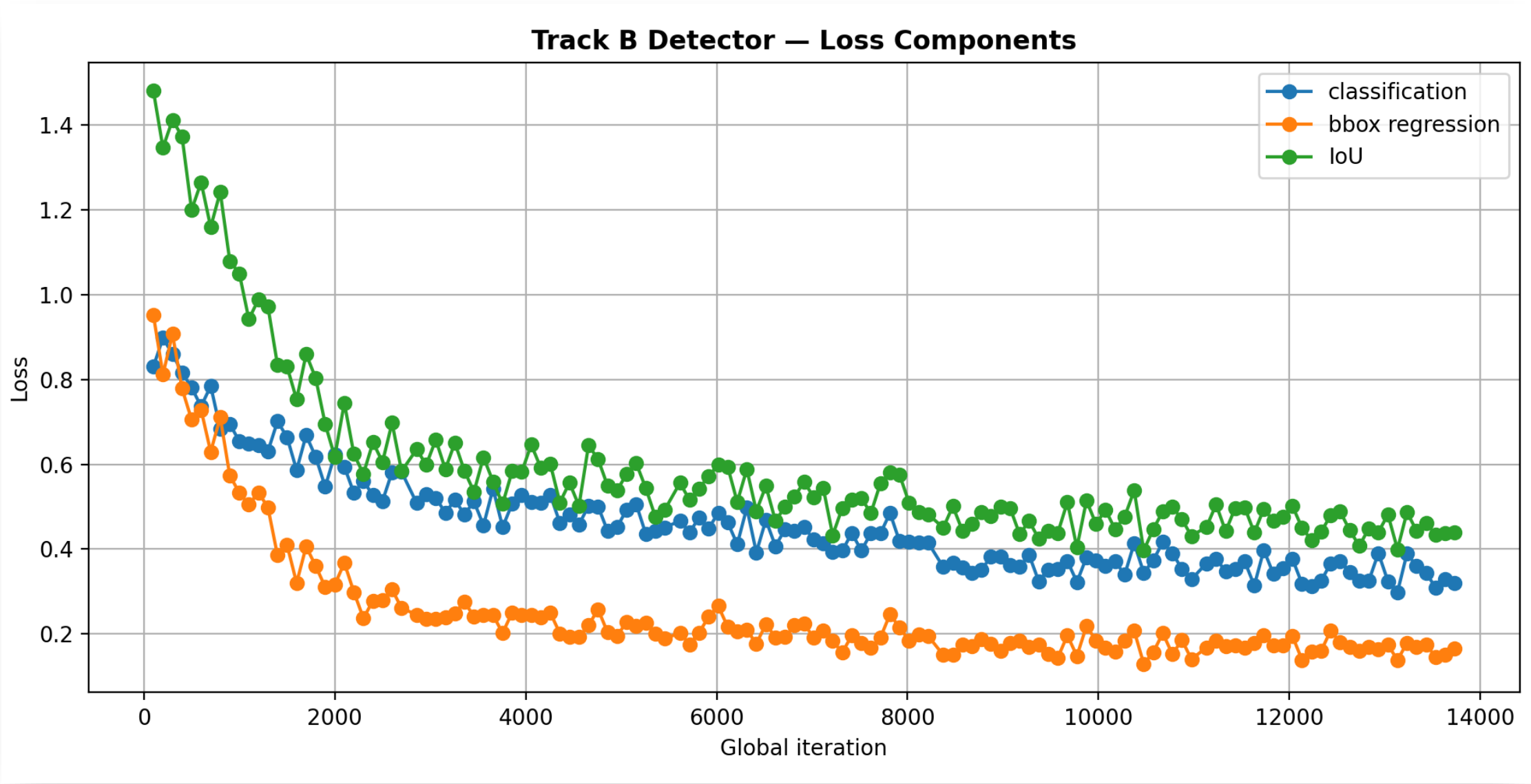
Track B Detector — Loss Components
classification
bbox regression
IoU
Loss
Global iteration
0.2
0.4
0.6
0.8
1.0
1.2
1.4
0
2000
4000
6000
8000
10000
12000
14000

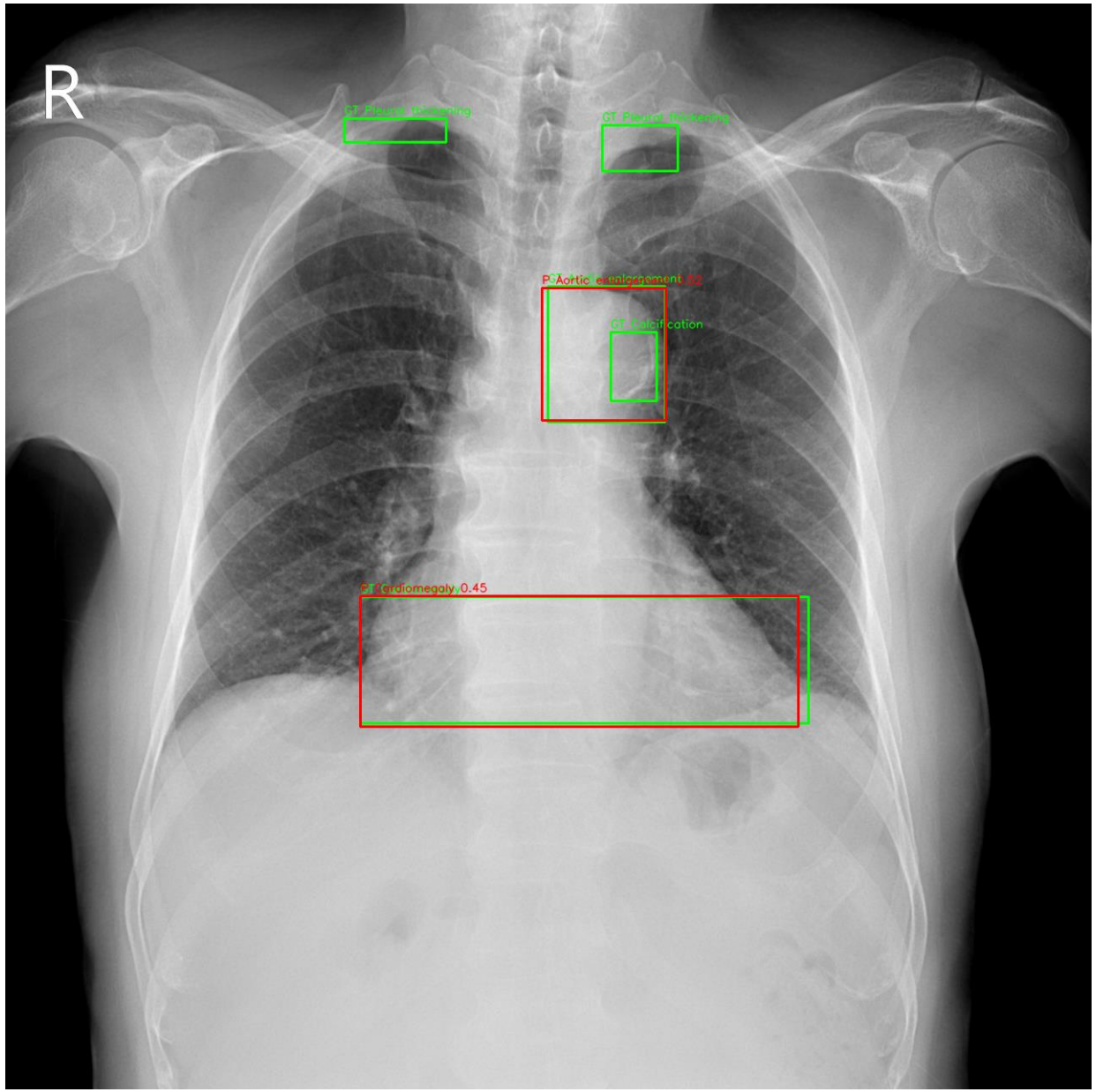
R
GT Pleural thickening
GT Pleural thickening
P Aortic enlargement 0.52
GT Calcification
P Cardiomegaly 0.45

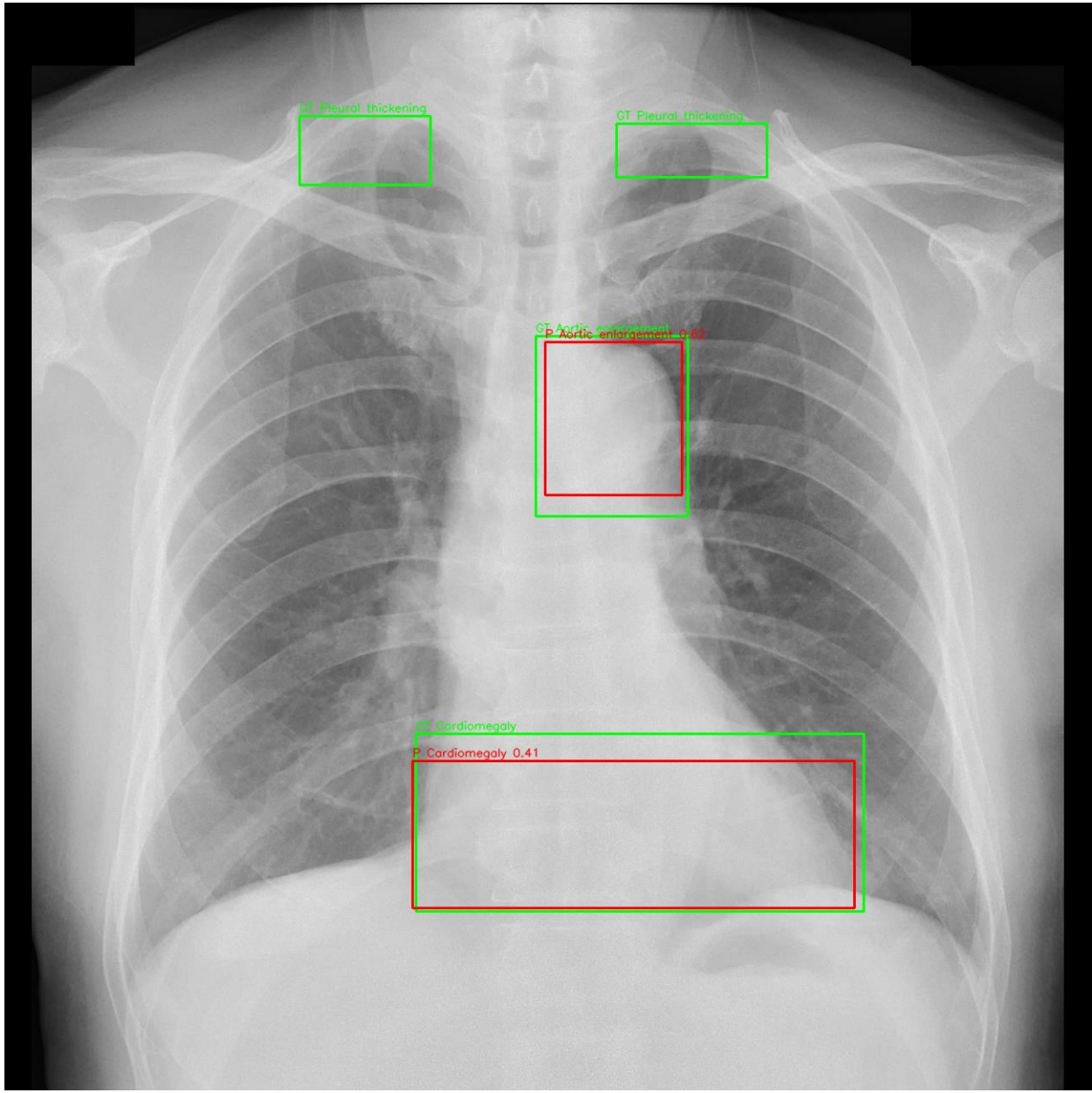
GT Pleural thickening
GT Pleural thickening
GT Aortic enlargement
P Aortic enlargement 0.62
GT Cardiomegaly
P Cardiomegaly 0.41

```
Raw annotations
      ↓
WBF per image
      ↓
Split by image_id
      ↓
Train set ──────────────► update model weights
Val set   ──────────────► evaluate mAP + select best checkpoint
Test set  ──────────────► untouched until final inference
```

```
Stage 1: Fast training
balanced subset → DINO detector → best checkpoint mAP@0.4 = 0.247

Stage 2: Full fine-tuning In comming!!
full train split + best checkpoint → lower LR → better generalization
```