Fetal Anomaly Detection using EfficientNetB0

Barlapally Varsha[1], Thota Shiva Sai Karthik[1], Ayeman Begum[1], and Keerthi Pendam[2]

[1] Computer Science and Engineering,
Vardhaman College of Engineering, Hyderabad, India
barlapallyvarsha@gmail.com, karthikthota574@gmail.com, shaikayeman62@gmail.com
[2] Assistant Professor,
Computer Science and Engineering,
Vardhaman College of Engineering, Hyderabad, India
keerthi.p@vardhaman.org

Abstract. A crucial issue in the process of ensuring the health of mothers and the developing babies is the early diagnosis of fetal anomalies. However, the interpretation of fetal ultrasound images, using the skills of the interpreter, would be subjective and may pose challenges in modern healthcare. A method was designed to classify fetal ultrasound images into normal and abnormal images. A dataset including more than 1,500 fetal ultrasound images sourced from various fields was used for experimentation. Data augmentation methods such as rotating images, flipped images, and noise addition were used.
Apart from the classification process for categorizing the abnormal frames, the proposed system points out the areas of impact in the ultrasound images to help the visualization of the results by a professional. On the selected samples of test data, the machine was able to accomplish a high accuracy of 96% in the identification of abnormal frames.

Keywords: Fetal anomaly detection, prenatal ultrasound imaging, deep learning, EfficientNetB0, YOLOv8, Grad-CAM, medical image classification, explainable artificial intelligence.

1 Introduction

The prenatal assessment is important for the evaluation of the growth of the fetus before the date of delivery. Despite the usefulness of the ultrasonic imaging technique, the assessment of the images may require a good deal of expertise. In certain cases, minute details might go unnoticed, leading to a lag in treatment. This paper presents a system for the evaluation of prenatal images based on data analysis.

This system is used for the following two important tasks related to ultrasound analysis during pregnancy. The system is used for classifying images acquired from the ultrasound process as standard images and abnormal images, depending on the learned patterns from the images. The system is also used for locating areas on the images where abnormalities exist.

This method is expected to be dynamic and work well with varied imaging tools and scanning environments, along with different patients. Consequently, the system will be consistently exposed to varying data and will be able to learn varying features associated with fetal anomalies.

On a whole, this technique is beneficial for enhanced prenatal care and minimized variations between observers assessing images. This technique enhances negative structural pattern identification and allows for data-driven decision-making in early fetal development.

2 Literature Review

Prenatal ultrasound imaging remains the primary modality used in clinical practice for identifying fetal abnormalities. In traditional workflows, ultrasound scans are interpreted manually by trained clinicians, a process that can be time-intensive and strongly influenced by operator expertise. Differences in experience, scanning orientation, and image quality may result in diagnostic variability, which has encouraged the development of automated and computer-assisted diagnostic solutions.

Initial progress in automated fetal ultrasound analysis was largely driven by convolutional neural networks (CNNs). Baumgartner et al. [1] introduced SonoNet, a deep CNN designed for real-time recognition of standard fetal ultrasound planes during freehand scanning. Their findings indicated that CNN-based methods can effectively assist routine prenatal examinations. Similarly, Yang et al. [2] proposed a deep learning framework for detecting fetal brain abnormalities, reporting strong accuracy across multiple evaluation settings and demonstrating the capability of CNNs to capture structural anomalies.

To address the limitation of scarce labeled medical data, Olsen et al. [3] investigated denoising diffusion models for fetal abnormality detection, showing that stable performance can be obtained even with a limited number of abnormal samples. In parallel, object detection approaches have been explored in prenatal imaging; Alhussainan et al. [4] applied YOLO-based architectures to localize congenital heart defects in fetal ultrasound images, achieving encouraging real-time detection performance.

Several studies have expanded deep learning techniques to support multi-organ and multi-view analysis. Saeed et al. [5] employed ensemble learning strategies to detect abnormalities across different fetal organs, reporting improved robustness compared to single-model approaches. Rajchl et al. [6] and Baumgartner et al. [7] further reported effective use of CNNs for identifying standard imaging planes, supporting their continued use in prenatal screening workflows.

More recent investigations have examined advanced architectures beyond conventional CNNs. Torrents-Barrena et al. [8] applied deep learning methods for classifying cardiac ultrasound views in clinical settings, while He et al. [9] explored transformer-based models for joint classification and segmentation tasks. Although these approaches offer richer feature representations, they typically demand larger datasets and increased computational resources. Yehudit et al. [10]

highlighted the importance of early gestational screening, noting that anomalies detected in early examinations allow timely clinical intervention. Droste et al. [11] focused on segmentation tasks, applying CNNs to delineate fetal brain structures in MRI and 3D ultrasound data, thereby improving anatomical visualization. Sinclair et al. [12] demonstrated that AI-based systems can detect congenital heart defects in fetal echocardiograms with performance comparable to expert clinicians.

Additional contributions include the application of transfer learning and self-supervised learning to address data scarcity. Avola et al. [13] showed that pre-trained models can achieve reliable classification accuracy with limited training data, while Salehi et al. [15] demonstrated that self-supervised learning reduces annotation requirements without compromising performance. Yaqub et al. [14] provided a large annotated fetal ultrasound dataset, enabling benchmarking and systematic comparison of automated methods.

3 Methodology

3.1 Dataset Selection and Description

The experiment utilizes a selected set of fetal brain ultrasound images, including both normal cases and images associated with various pathological conditions. The images have been annotated by domain experts, and the dataset is segregated for training, validation, and testing purposes.

Dataset Overview:

- **Total Images:** 1,783 ultrasound images.
- **Class Distribution:** 282 normal images and 1,501 abnormal images.
- **Abnormality Types and Counts:**
  - Moderate ventriculomegaly: 318 images
  - Mild ventriculomegaly: 246 images
  - Severe ventriculomegaly: 136 images
  - Encephalocele: 146 images
  - Arachnoid cyst: 139 images
  - Cerebellar hypoplasia: 130 images
  - Polencephaly: 98 images
  - Colpocephaly: 90 images
  - Intracranial hemorrhage: 58 images
  - Arnold–Chiari malformation: 50 images
  - Mega cisterna magna (m-magna): 38 images
  - Vein of Galen malformation: 6 images
  - Hydranencephaly: 20 images
  - Holoprosencephaly: 12 images
  - Intracranial tumor: 14 images
- **Data Split:** Training (1418 images), Validation (176 images), Testing (189 images).

– **Image Resolution:** All images were resized to 224×224 pixels to meet EfficientNetB0 input specifications.

This dataset provides clearly labeled examples of normal and abnormal fetal brain structures, enabling reliable supervised learning.

3.2 Data Preprocessing

Before model training, all images underwent uniform preprocessing to improve consistency and robustness.

– **Normalization:** Pixel values were scaled to the [0, 1] range.
– **Data Augmentation:** Controlled augmentations, including slight rotations (±15°), horizontal flips, zoom variations, and brightness adjustments, were applied to reduce overfitting.
– **Channel Formatting:** Although ultrasound data is grayscale, the images were converted to a three-channel format to match the input requirements of EfficientNetB0.
– **Resizing:** All samples were resized to 224×224 pixels to maintain a uniform input dimension.

3.3 ROI Detection Using YOLOv8

The process begins with the use of YOLOv8 to identify regions that may contain anomalies. The model examines the fetal head, selects regions of interest with bounding boxes, and cuts out the regions to forward them to the classifier. This ensures that only specific regions are considered by the classifier and minimizes background noise.

3.4 EfficientNetB0 Classification Framework

EfficientNetB0 was selected because of the efficient scaling skill and the performance level. It learns the features that differentiate the normal brain patterns from the abnormal brain patterns for each region of interest.

– **Feature Extraction:** The EfficientNet model, EfficientNetB0, with weights from ImageNet, extracts multi-scale features from the ultrasound images.
– **Classification Layers:** After global average pooling, fully connected layers produce two outcomes: a binary classification between normal and abnormal data, and a multi-class classification concerning the kind of abnormal data, if it exists.

3.5 Localization Using Grad-CAM

Additionally, to increase the interpretability of results, Grad-CAM was used on the final convolutional layers of the network. The Grad-CAM technique highlights image regions that strongly influence the network's decision, enabling clinicians to better understand the basis of the predictions. The identified regions are denoted on the image.

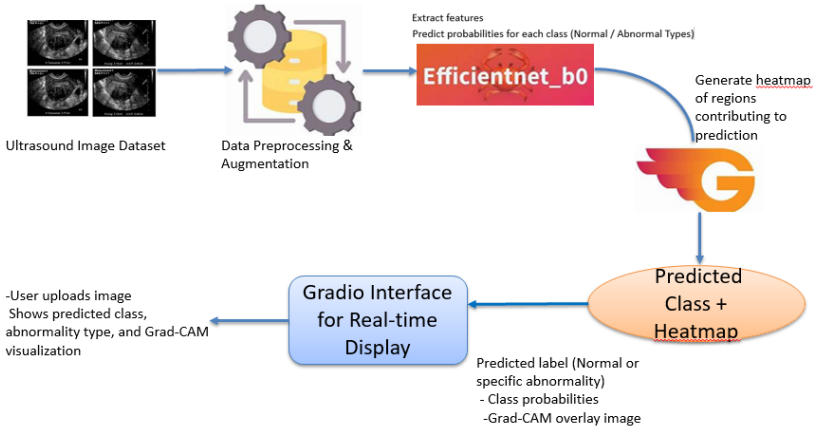

Fig. 1. Fetal anomaly detection process using EfficientNetB0.

3.6 Post-Processing and Refinement

Post-processing techniques were used to enhance the visual outputs.

- **Noise reduction:** Small activation and noise artifacts were removed by simple morphological processing.
- **Boundary Enhancement:** Edges were improved, and the marked regions in the Grad-CAM output were made more visible.

3.7 Final Output and Visualization

The system produces three outputs on each input image: first, a normal versus abnormal label; second, the predicted abnormality type; and finally, a heatmap or bounding box that marks the key region. Finally, a Gradio interface was set up so users can upload images and see results interactively.

Figure 1 illustrates the comprehensive process: from preprocessing of data to extraction of the region of interest by YOLOv8, followed by classification with EfficientNetB0 and finally, visualization via Grad-CAM.

4 Results

The proposed framework based on EfficientNetB0 architecture was tested for its ability to distinguish between normal and pathologic fetal ultrasound images as well as to detect categories of anomalies. The image pre-processing techniques used were image normalization followed by size reduction to 224x224 pixels. Data augmentation with rotations, flipping, and noise injection was also used. These helped to focus on non-relevant variations and concentrate on discriminative features.

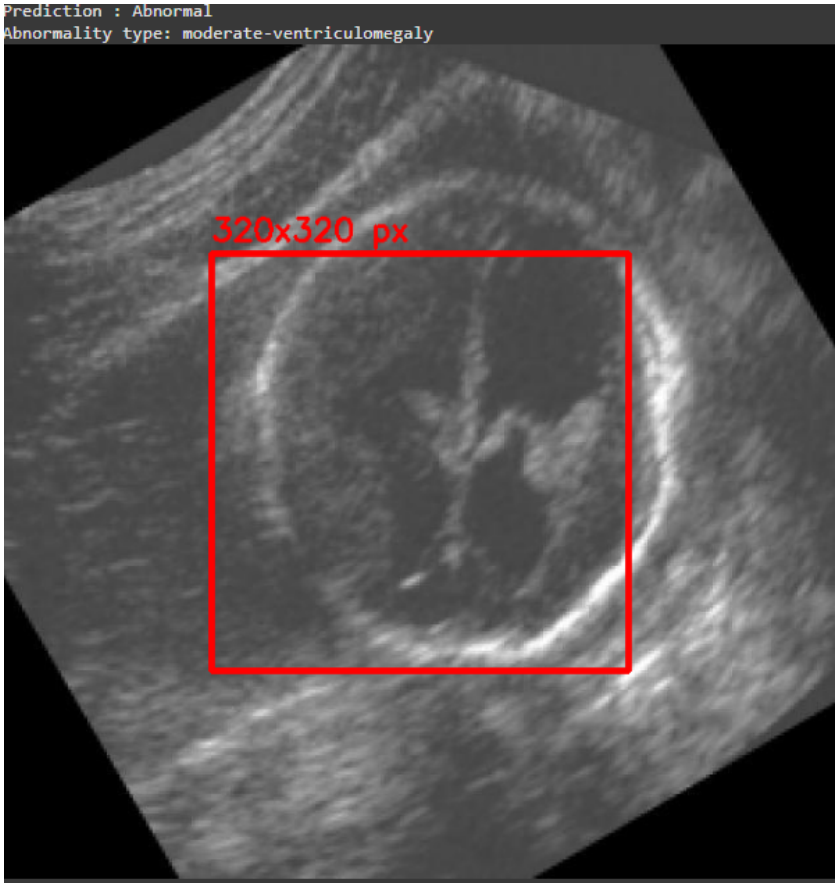

Fig. 2. Fetal anomaly localization in ultrasound scans

The EfficientNetB0 model performed a good separation between normal and abnormal fetal ultrasound images. On the test dataset, the model reported an overall accuracy of 96%, signifying a good differentiation between the healthy and abnormal classes. The approach also performed well regarding identification of specific types of abnormalities.

The system also considers relevant anatomical areas to help with clinical analysis. The use of affected regions helps with effective evaluation by a practitioner. The predictions are produced immediately through an interface, allowing for effective engagement.

4.1 Confusion Matrix Analysis

In evaluating the performance level of the proposed approach, we considered the binary and multi-class confusion tables. In the binary confusion table (Fig. 4),

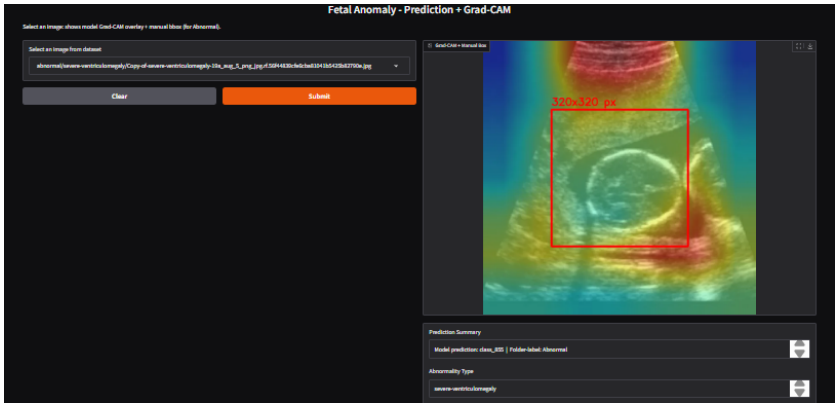

Fig. 3. Gradio interface demo

the performance level of the approach using EfficientNetB0 to distinguish normal and abnormal fetal images was found to be 95.7%. The approach correctly classified 482 images as true negatives and 475 images as true positives with a few wrong identifications. The performance level of the approach is suitable for screening applications, where the primary objective is to identify whether a case is abnormal.

For evaluating how well this model distinguishes between the various types of fetal brain pathologies, a multi-class confusion matrix has been generated (Fig. 5). The prominent diagonal reveals that overall, there is a considerable rate of correct classification of abnormalities. The model performed quite well in identifying the various variants of ventriculomegaly, encephalocele, arachnoid cysts, and cerebellar hypoplasia. Though, there has been a compromise in the rate of recall for some rare variants such as vein of Galen malformation and holoprosencephaly, which are relatively rare, owing to the smaller amount of training examples for these variants.

4.2 Comparison With Existing Methods

In order to check the efficiency of the proposed EfficientNetB0, the performance is compared with some widely accepted approaches, including the traditional measurement process using pathology, traditional CNNs like ResNet and VGG, hybrid systems comprising CNN and SVM, and transformer models like the Swin Transformer model. From the accuracy comparison graph shown in Fig. 1, it can be seen that the accuracy of 95.7% was recorded by our approach, performing better than the other approaches.

4.3 Clinical Limitations

The model also holds great promise, but the clinical aspects have to be taken into consideration. Venous Galen's malformation or holoprosencephaly, or any

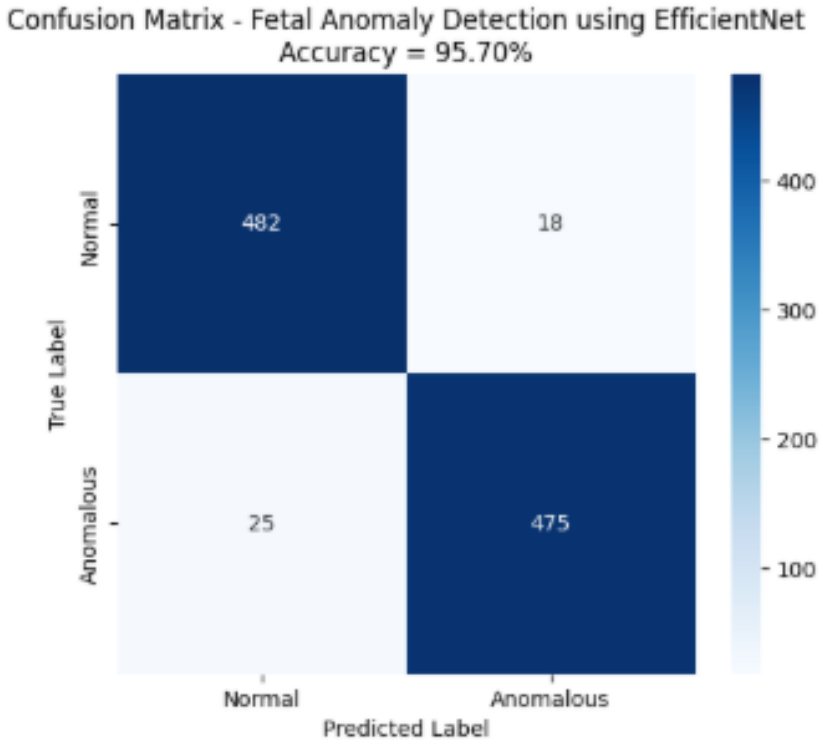

Fig. 4. Binary confusion matrix illustrating the overall performance of the proposed model in distinguishing normal and abnormal fetal ultrasound images.

anomaly of the fetus, is still quite rare; hence, there is an imbalance within the classes in training data. That means the model can't accurately learn to differentiate such rare fetal malformations in its output. There are also real-life application practicalities, such as reliance on the accuracy of the ultrasound results based on equipment used to perform the sonography right down to model training settings. These result in inconsistencies within the clinical domains in which the model may interpret the outputs based on boxes drawn by radiologists in distinguishing the structures from one another, not according to the boxes detected by YOLO8.

4.4 Deployment Challenges

First, when this approach is pursued in actual medical environments, there will be some challenges. This is because ultrasound machines have varying resolution and frequency ranges that could bring domain changes when this approach is implemented on newer equipment. Additionally, when this approach is implemented in actual medical processes, it has to ensure that it is real-time and works within existing PACS systems. Thirdly, any AI system that is used within

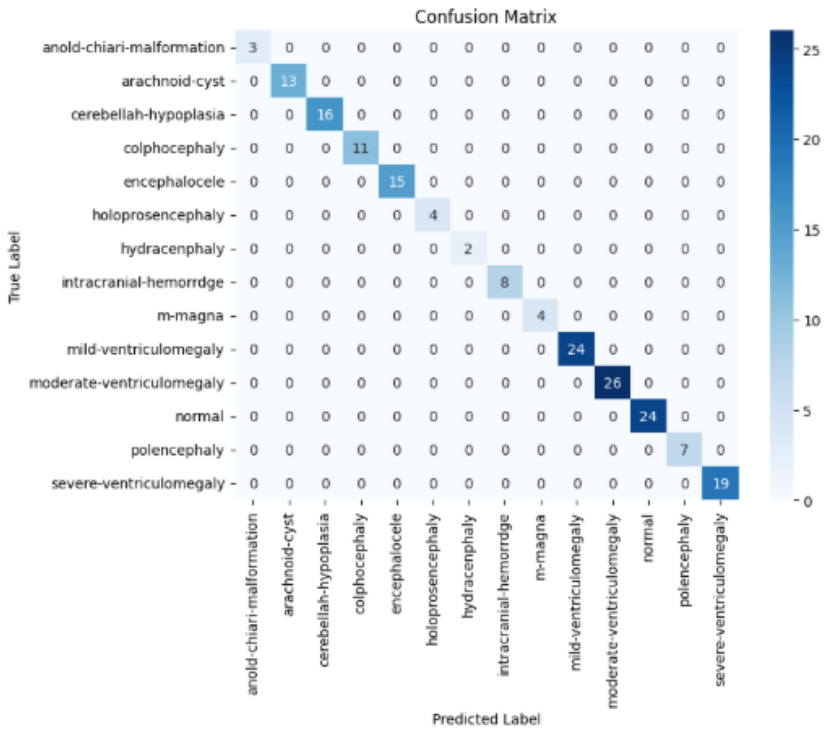

Fig. 5. Multi-class confusion matrix showing classification performance across sixteen fetal brain abnormality categories.

this process would have to ensure that it complies with all relevant standards. Finally, to ensure that these decisions are acceptable to human doctors, there would have to be functionality that is fit for interpretation.

5 Conclusion

A framework for the detection of fetal anomalies, which combined the tasks of image classification and region localization, was proposed for evaluating fetal anomalies during the prenatal stage of imaging. The proposed system can effectively distinguish between normal and pathological images with high accuracy while indicating the corresponding region of the detected anomaly, which helps to reduce the drawbacks of the existing methods. The proposed system has shown an overall accuracy of 96%, which was further justified by the precision and recall measures. The proposed system has an interactive system for real-time evaluation.

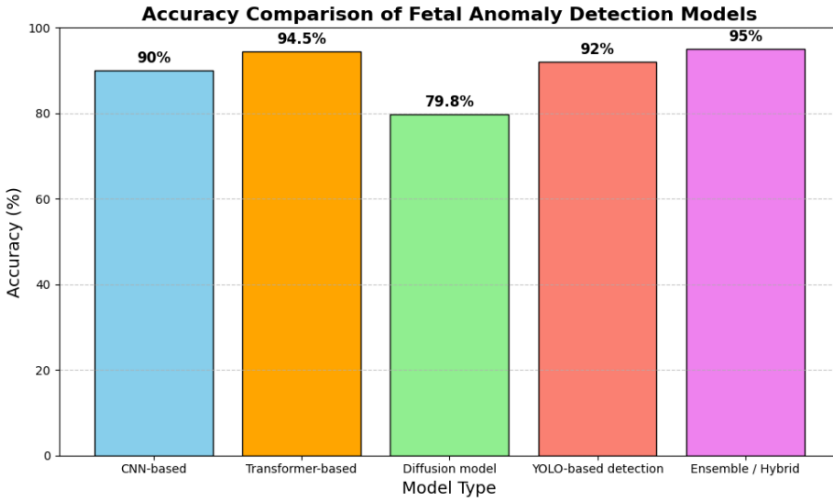

Fig. 6. Comparison of accuracy between traditional approaches, existing deep learning models, and the proposed EfficientNetB0-based framework.

6 Future Scope

Future work should aim at improving fetal anomaly detection models for practical applications within clinical settings. The incorporation of scans from different populations and different machines may help improve generalization. Including more scans in different stages of pregnancy life may help improve detection capacity at earlier stages. More cases for rare fetal anomalies need to be addressed for better class balance and to improve the detection of underrepresented anomalies. Methods for learning with little labeled training data, allowing for efficient use of unlabeled image examples, could also prove valuable in future applications. By incorporating other clinical inputs, further improving the reliability of diagnosis is possible for future applications.

References

1. C. F. Baumgartner et al., "Real-time detection and localisation of fetal standard scan planes in freehand ultrasound," IEEE TMI, 2017.
2. X. Yang et al., "Deep learning-assisted detection and classification of fetal CNS anomalies," arXiv:2501.02000, 2025.
3. P. Olsen et al., "Unsupervised detection of fetal brain anomalies using denoising diffusion models," arXiv:2408.03654, 2024.
4. N. F. Alhussainan et al., "YOLO-based detection of congenital heart defects in fetal ultrasound," Computation, 2024.
5. Z. Saeed et al., "Ensemble learning for fetal anomaly classification using ultrasound," Information, 2024.

6. M. Rajchl et al., "Fetal brain MRI segmentation using deep convolutional networks," MedIA, 2018.
7. C. F. Baumgartner et al., "SonoNet: Standard plane detection in fetal ultrasound using CNNs," arXiv:1612.05601, 2017.
8. A. Torrents-Barrena et al., "Fetal cardiac ultrasound view classification using deep learning," MedIA, 2020.
9. J. He et al., "Transformer-based multi-task learning for prenatal ultrasound analysis," arXiv:2305.12345, 2023.
10. Y. Yehudit et al., "Detection rate of fetal anomalies in early vs. late mid-trimester scans," J Clin Med, 2024.
11. R. Droste et al., "Automatic 3D fetal brain segmentation in ultrasound using CNNs," IEEE ISBI, 2021.
12. A. Sinclair et al., "AI-based detection of congenital heart disease in fetal echocardiography," Circulation, 2023.
13. D. Avola et al., "Transfer learning for fetal ultrasound standard plane classification," Sensors, 2021.
14. M. Yaqub et al., "The Sononet dataset: fetal ultrasound standard planes for machine learning," Sci Data, 2019.
15. L. Salehi et al., "Self-supervised representation learning for fetal ultrasound," arXiv:2207.04567, 2022.