Deep learning-based segmentation of edentulous space on cone-beam computed tomography images

Manha Fathima P

A report submitted as part of the requirements for the Internship
Computer Science and Engineering
NIT Calicut

July 2025

Supervisor Dr. Jayaraj P B

Abstract

Edentulous areas of the jaw, which indicate missing teeth, present significant challenges during implant planning. Identifying these regions manually on cone-beam computed tomography (CBCT) scans can be labor-intensive and subject to variations between clinicians. This internship project focused on creating an automated deep learning solution to segment edentulous spaces in CBCT images. Employing a 3D U-Net model implemented with the MONAI framework, the approach combined existing anatomical segmentations with manually labeled edentulous regions. The model was trained using multi-class label maps to recognize various anatomical structures while specifically identifying implant-relevant sites. The overall objective was to enhance clinical workflows by delivering reliable, precise, and streamlined segmentation results.

Acknowledgements

I would like to express my deepest gratitude to everyone who supported me throughout this internship.

Firstly, I am profoundly thankful to my supervisor, Dr. Jayaraj P B, for their invaluable mentorship, guidance, and constant encouragement. Their expertise and constructive feedback were instrumental in shaping my learning experience and ensuring the success of my project. I sincerely thank Dr. Abu Nazar N and Ms. Seenia Jinson for providing knowledge on medical imaging analysis and deep learning models.

I also extend sincere thanks to the entire team at Department of Computer Science and Engineering for fostering a collaborative and supportive environment.

I am grateful to NIT Calicut for granting me this opportunity to apply my academic knowledge in a real-world setting, and for the foundational skills I acquired prior to this internship.

Chapter 1

Introduction

Dental implants are a widely used solution to replace missing teeth. Successful implant planning relies on understanding the available bone, proximity to nerves, and the precise location of the edentulous spaces in the jaw. CBCT imaging has become an essential diagnostic tool, offering 3D visualization of dental structures with high spatial resolution.

Despite its advantages, manual segmentation of the edentulous regions in CBCT scans is labor intensive and subjective, often requiring considerable time from trained professionals. Automating this process can help clinicians save time, improve consistency, and support digital planning workflows for custom implant placement.

The growing adoption of artificial intelligence (AI), particularly deep learning-based convolutional neural networks (CNNs), offers the promise of consistent, automated segmentation of dental anatomy. While prior work has successfully applied 3D U-Net architectures to segment teeth, bone, and nerves on CBCT scans, specific segmentation of edentulous spaces for single-tooth implants remains underexplored. This internship focused on designing and implementing a deep learning-based pipeline that automatically segments edentulous spaces in CBCT scans, integrating these

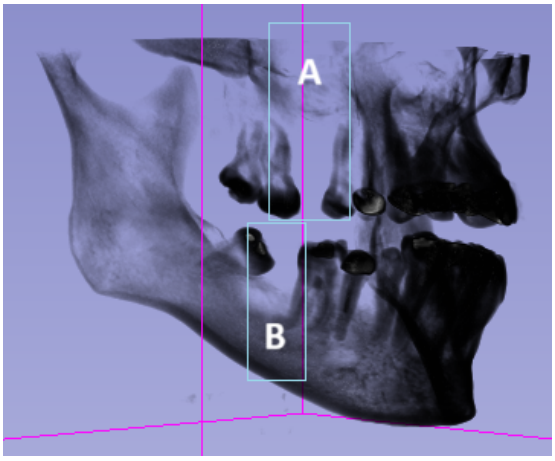

Figure 1.1: Edentulous spaces A and B for single missing tooth

results into a streamlined process for dental implant planning.

1.1 Objectives and Motivation

Planning dental implants requires precise identification of the space available for placement, especially in cases of single-tooth loss. Manual segmentation of the edentulous area is prone to human error and variability, which can lead to inconsistencies in planning and treatment outcomes.

In addition, the presence of metallic restorations and image artifacts in CBCT scans further complicates the accuracy of anatomical boundaries. These challenges call for the need for robust and automated solutions that can consistently detect and segment edentulous spaces regardless of imaging variability.

The specific objectives of this internship project are:

- To design a preprocessing pipeline for converting and preparing CBCT and segmentation data.
- To develop a multi-class label map integrating existing anatomical structures with manually annotated edentulous regions.
- To train and validate a 3D U-Net model for accurate, automated segmentation of edentulous spaces.
- To ensure compatibility with clinical tools such as 3D Slicer for visualization and planning.

The motivation behind this project is to reduce clinician workload, enhance planning accuracy and promote standardized workflows by developing a deep learning-based system capable of automatically identifying edentulous regions in CBCT data.

Chapter 2

Background

This chapter provides some background research on the project and examines some previous work.

2.1 CBCT Imaging in Dental Implants

Successful dental implant placement depends on thorough preoperative planning, which requires detailed visualization of the patient's jawbone, adjacent teeth, nerves, and other anatomical structures.

Cone-beam computed tomography (CBCT) has revolutionized dental imaging by providing high-resolution, three-dimensional views of maxillofacial anatomy at relatively low radiation doses compared to conventional CT (or FBCT). CBCT scans enable clinicians to evaluate bone quantity and quality, proximity to mandibular nerve, sinus,etc, which are factors to be looked into for the successful placement of dental implant.

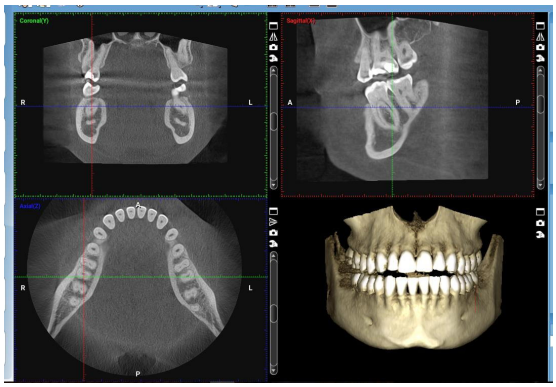

Figure 2.1: Dental CBCT scanned images

Due to this, CBCT is now routinely used in treatment planning for dental implants, allowing for more predictable outcomes and fewer surgical complications.

2.2 The Challenge of Manual Segmentation

While CBCT imaging offers great anatomical detail, interpreting and utilizing this data effectively remains challenging. For implant planning, clinicians need to segment anatomical structures from the scan such as teeth, mandible, maxilla, nerves, and importantly, the edentulous spaces where implants are intended to go.

Current planning software typically relies on thresholding, region-growing, or semi-automated contouring tools. However, these methods can be imprecise, especially in the presence of imaging artifacts like beam hardening from metallic restorations. Such artifacts can obscure boundaries, necessitating extensive manual correction.

Segmenting edentulous spaces poses a unique difficulty because they represent absence rather than presence of tissue. Experts must carefully mark where the tooth is missing in 3D space, taking into account the proximity of mandibular nerve, sinus cavities and the teeth located close to the edentulous space. This process is time-consuming (often taking 15–30 minutes per case), and introduces variability that can affect treatment outcomes.

2.3 Advances in Automated Segmentation Using Deep Learning

Recent years have seen significant progress in applying deep learning to medical image segmentation. Convolutional neural networks (CNNs), especially U-Net architectures, have demonstrated high accuracy in segmenting complex anatomical structures in volumetric data. By learning hierarchical features from annotated datasets, these models can consistently mark out boundaries even in noisy imaging conditions.

In dental imaging, research has applied these methods to segment teeth, roots, crowns, and surrounding bone structures from CBCT scans. Such work has reduced the need for manual correction and improved planning workflows.

2.4 Deep learning-based segmentation of dental implants on CBCT images

Elgarba et al. (2023)

It is a comprehensive study applying deep learning techniques to segment dental implants and crowns from CBCT images. Their work stands out as an early and robust validation of convolutional neural networks (CNNs) in handling the complex and

artifact-prone domain of dental CBCT data.

Their methodology involved collecting CBCT scans with existing dental implants and annotating the implants and surrounding crowns in three dimensions. A 3D U-Net architecture was trained on these annotated volumes to perform voxel-wise segmentation of implants and crowns. The training process considered data augmentation and cross-validation to improve generalization for diverse patients and imaging conditions.

Once trained, their model was able to take raw CBCT volumes as input and automatically produce segmented masks of implants and crowns, with high accuracy. The final segmentations were evaluated using quantitative metrics such as the Dice similarity coefficient, showing strong overlap with expert manual annotations.

The model achieved Dice scores above 90 percent, showing excellent agreement with ground truth.

Automated segmentation dramatically reduced the time required compared to manual annotation.

The approach was shown to work across varying patient anatomies and even in the presence of metallic artifacts common in dental imaging.

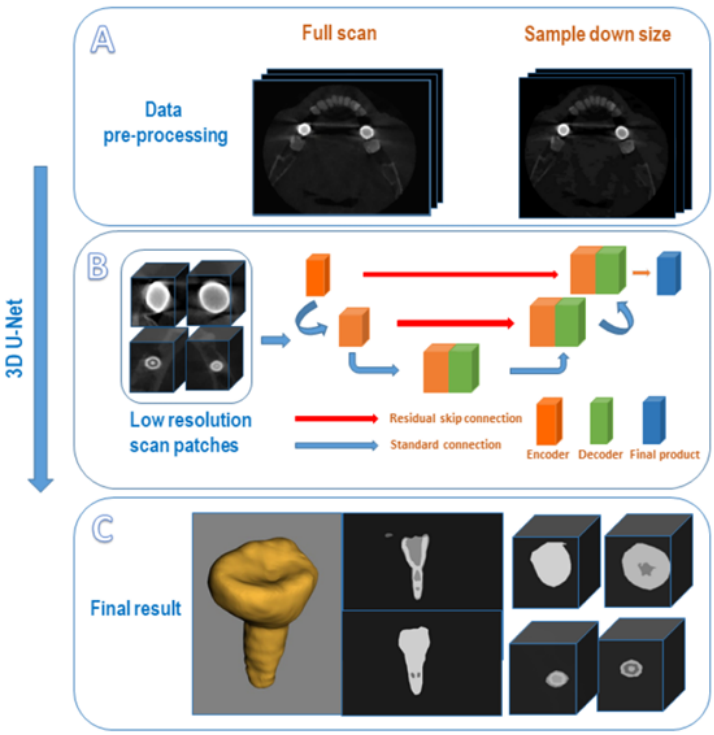

Figure 2.2: Workflow of 3-D Unet Model for segmentation of dental implants

Despite its success, the approach was focused specifically on segmenting existing implants and crowns— structures with clear, high-density contrast in CBCT scans. It didn't help in identifying edentulous spaces which represent a different challenge entirely.

It did not address merging multi-class anatomical structures (teeth, bone, nerves) with manually annotated planned implant sites into a unified training dataset.

Their success, however, clearly demonstrated that 3D CNNs can handle CBCT data despite artifacts and variability. This validation directly inspired the current project's motivation: to extend deep learning segmentation from existing implants to the automated identification of edentulous spaces.

2.5 Deep Learning Approaches for Identifying Missing Tooth Regions in Panoramic Radiographs

Park et al. (2022)

It introduced a deep learning framework aimed at identifying regions of missing teeth in panoramic radiographic images, supporting automated implant planning workflows. Their approach focused on panoramic X-rays, which are more widely accessible and affordable in clinical settings compared to CBCT for assessing edentulous areas.

The system was designed as a sequential two-step pipeline:

1)Tooth Instance Segmentation: A Mask R-CNN model with a ResNet-101 backbone was used to segment individual teeth within panoramic radiographs. This model was trained to exclude third molars, isolating the 28 permanent teeth typically of interest.

2)Detection of Missing Teeth: It used Faster R-CNN to analyze the segmented tooth masks and identify regions corresponding to missing teeth. The outputs were bounding boxes labeled with tooth numbers to indicate edentulous locations.

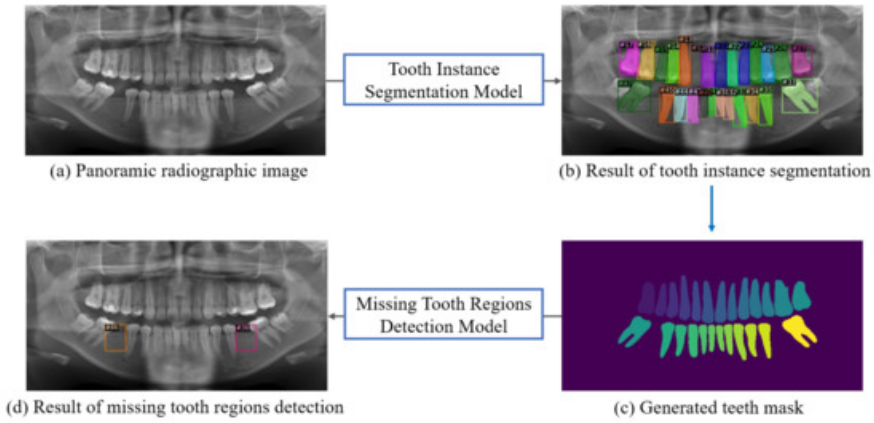

Figure 2.3: Process of detection of missing tooth regions

To address the challenge of limited training data, the authors created synthetic images, which helped their model perform better on new, unseen clinical cases.

By using panoramic radiographs, which are common and low-cost in dental clinics, their method was more accessible for everyday use.

They used a two-step approach where each model had a clear role:

- The segmentation model focused on outlining individual teeth accurately.
- The detection model identified where teeth were missing.

Their segmentation model worked well, achieving a mean Average Precision (mAP) of 92.14 percent at an IoU over 0.5. This showed it could reliably identify teeth.

The limitations of the study include:

- The detection part was less accurate, with mAP dropping to 59.09 percent at IoU greater than 0.5 and even lower at stricter levels. This shows it was harder to spot missing teeth using only 2D images.
- Panoramic X-rays flatten the view of the mouth, making it hard to see depth or bone structure which is important for implant planning.
- The method marked missing teeth as simple boxes instead of detailed shapes, which is less useful for surgery planning.
- The synthetic images were based on only 170 masks, which might not cover all real-world variations.

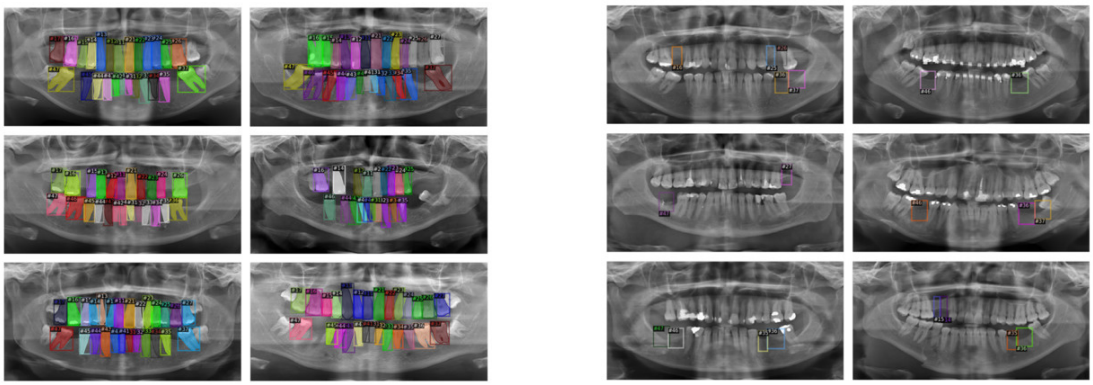

(a) Tooth instance segmentation model

(b) Missing tooth region detection model

Figure 2.4: Results of missing tooth region detection by two models

Park et al.'s work shows deep learning can help detect missing teeth from 2D X-rays. But their approach is limited because it doesn't capture 3D details.

Our current project overcomes this by using 3D CBCT scans. We also use a segmentation-first approach, but in 3D with multiple classes (like bone, nerves, edentulous space). This enables more detailed and clinically useful planning for implants.

Chapter 3

Design

This chapter outlines the design of a deep learning-based system for segmenting edentulous (toothless) regions in dental CBCT scans. The aim is to generate detailed 3D segmentations that assist in implant planning.

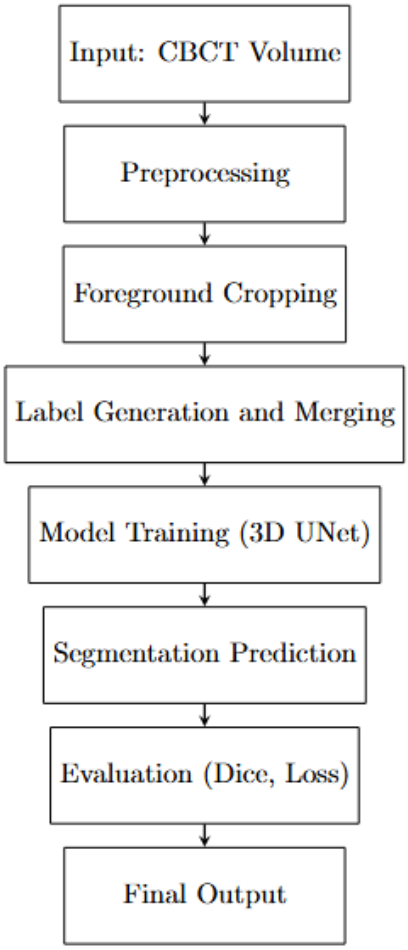

3.1 Input Data: Dental CBCT Volumes

The process begins with a high-resolution CBCT scan of the patient's jaw. These volumetric images provide a 3D view of dental anatomy, including bone, teeth, and edentulous areas. Each scan is converted into a standard format such as NIfTI.

3.2 Preprocessing

To ensure consistent input across patients, the following preprocessing steps are applied:

- Resampling: Make voxel sizes consistent.
- Common Orientation: Align all scans in the same way.

- Intensity Normalization: Standardize brightness values.
- Cropping: Focus on the important region.

3.3 Data Quality Filtering

Scans affected by motion artifacts, missing slices, or poor contrast are excluded from training and evaluation to improve overall model performance.

3.4 Label Generation and Merging

For training, we generate multi-class labels by merging two types of data: automated segmentations of teeth and manually annotated edentulous regions. The dental segmentation provides detailed tooth structures, while the edentulous masks highlight missing tooth spaces. These combined labels create a single volume with multiple classes, enabling the model to learn to identify both teeth and edentulous areas simultaneously.

3.5 Data Augmentation

To improve generalization, random transformations are applied during training:

- Spatial augmentations: crops, rotations, flips
- Intensity augmentations: scaling, shifting, noise

These help simulate real-world variability and reduce overfitting.

3.6 3D Segmentation Model

The core segmentation model is a 3D U-Net architecture with encoder-decoder structure and skip connections. It takes the CBCT volume as input and outputs a multi-class segmentation map covering teeth, bone, and edentulous regions.

3.7 Loss Function and Optimization

The model is trained with a combined loss function to improve segmentation performance:

- Dice Loss: Addresses class imbalance by directly optimizing overlap between predictions and ground truth.
- Cross-Entropy Loss: Enhances class separation by penalizing misclassifications.

Optimization is performed using the Adam optimizer with a learning rate of 1×10^{-4}, providing stable and efficient convergence.

3.8 Evaluation Metrics

Model performance is evaluated using:

- Training and Validation Loss: Tracks overall learning progress and overfitting.
- Dice Coefficient per Class: Measures segmentation accuracy for each anatomical label.
- Mean Dice Score: Summarizes overall segmentation quality across all classes.

These metrics support effective model selection, tuning, and monitoring during training.

3.9 Output

The final output includes:

- Segmented Volume: 3D scans with each voxel labeled by anatomical class (e.g., maxilla, mandible, teeth, edentulous regions, nerve).
- Quantitative Metrics: Dice scores per class and overall mean Dice to assess segmentation quality.
- Training Logs: Records of loss, metrics, and model checkpoints for reproducibility.
- Visualization Outputs: 3D images with segmentation overlays to aid clinical review.

3.10 Clinical Relevance

CBCT provides 3D spatial context essential for accurate implant planning. This system delivers anatomically detailed, voxel-level segmentation that supports precise, patient-specific treatment design.

Chapter 4

Implementation

This chapter describes how the proposed deep learning–based model for segmenting edentulous regions was implemented.

4.1 Computing Environment

The project was developed in Python using a Jupyter Notebook interface connected through MobaXterm. This setup allowed remote GPU acceleration for training large 3D models. The MONAI framework was used for preprocessing, model design, training, and evaluation. It provides ready-to-use 3D medical imaging transforms, data loaders, loss functions, and metrics tailored for segmentation problems. Key libraries included MONAI, PyTorch, nibabel, SimpleITK, pynrrd, and tqdm.

4.2 Data Preparation

A total of 167 CBCT scans were collected from clinical sources, each representing a complete jaw (full arch) scan. These scans were acquired from patients undergoing dental imaging procedures, ensuring a diverse and clinically relevant dataset. Each volume was provided in DICOM format and subsequently processed for segmentation. All scans were manually annotated in 3D Slicer, an open-source medical imaging platform, to label edentulous regions. The DentalSegmentator module

4.2.1 DICOM to NIfTI Conversion

CBCT volumes were originally provided as DICOM series. A preprocessing script automatically located DICOM folders (including nested subfolders) and converted them

into standardized 3D NIfTI volumes using SimpleITK. This ensured consistent data formatting for the deep learning pipeline.

4.2.2 NRRD to NIfTI Conversion

Manually annotated segmentation masks, originally in NRRD format, were batch-converted to NIfTI to maintain a consistent volumetric format across all inputs and labels.

4.2.3 Label Merging

For supervised learning, single multi-class label volumes were created by merging existing dental segmentation masks with manually annotated edentulous regions. Each merged label assigned a unique class ID to edentulous areas, ensuring the model learned to distinguish them.

4.3 Dataset Creation

A data list was programmatically generated, pairing each patient's CBCT volume with its corresponding merged multi-class label map. This allowed automated loading of image–label pairs during training.

4.4 Preprocessing and Data Augmentation

Preprocessing and augmentation were implemented using MONAI transforms. The steps included:

- Resampling: Standardized voxel spacing to 0.5 mm for consistent resolution.
- Orientation Alignment: Ensured all scans used the same anatomical orientation.
- Intensity Normalization: Scaled voxel intensities between 0 and 1 for stable model learning.
- Foreground Cropping: Removed empty spaces, focusing on jaw regions.
- Random Augmentations: Included flips, rotations, intensity scaling, and shifting.
- Random Cropping: Generated smaller, class-balanced sub-volumes to improve learning efficiency and reduce GPU memory usage.

4.5 Data Loading

The MONAI CacheDataset class was used to accelerate repeated data loading with caching. Training data was loaded in shuffled batches to ensure varied input during learning, while validation data was loaded deterministically.

4.6 Model Architecture

A 3D U-Net architecture was implemented using MONAI's UNet class. The network featured:

- Encoder–decoder structure with skip connections.
- Multiple resolution levels with increasing channels (32 to 512).
- Output layer producing voxel-wise multi-class segmentation with seven anatomical labels, including edentulous regions.

This design was chosen for its effectiveness in volumetric medical image segmentation tasks.

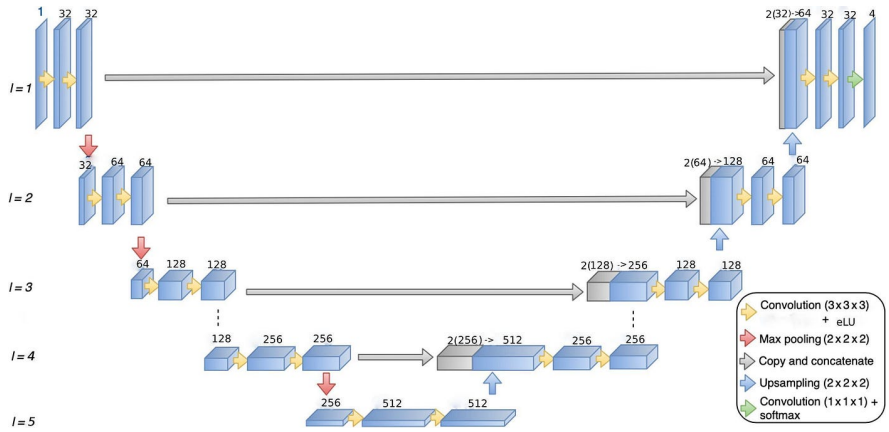

Figure 4.1: 3-D UNet Model used for segmentation

4.7 Loss Function and Optimization

A combined Dice and Cross-Entropy loss was used to handle class imbalance and encourage precise separation between anatomical labels. Class weights were adjusted to give higher importance to edentulous regions. The Adam optimizer was used with a learning rate of 1×10^{-4}.

4.7.1 Training Procedure

The model was trained for 500 epochs using the prepared 3D CBCT dataset. The training loop included:

- Forward and backward passes with a hybrid loss function.
- Optimizer updates to adjust weights.
- Periodic validation to calculate Dice scores for each class.
- Saving checkpoints to preserve the model state and training progress.

Validation was conducted at regular intervals, with logs of training and validation losses and Dice scores maintained to monitor learning over time.

4.7.2 Evaluation and Output

After training, the model generated:

- 3D segmentation maps labeling anatomical structures, including edentulous regions.
- Dice scores to assess per-class and overall segmentation quality.
- Optional visualizations to review segmentation results in context, supporting clinical planning.

Chapter 5

Results

This chapter evaluates the overall project and provides results of tests carried out. The evaluation focuses on training progress, quantitative metrics, and example outputs generated by the trained network.

5.1 Training Overview

The 3D UNet model was trained for 500 epochs using the MONAI framework on GPU. The hybrid loss function (Dice + Cross-Entropy) with class weighting was used to handle class imbalance, especially emphasizing edentulous regions.

Training and validation losses were recorded at each epoch to monitor learning progress. Validation was performed at regular intervals, calculating per-class and overall mean Dice coefficients.

Fig 5.1 shows the reduction in loss over 500 training epochs. Both training and validation loss curves decrease steadily, indicating effective learning and convergence. The small gap between the curves suggests good generalization without significant overfitting.

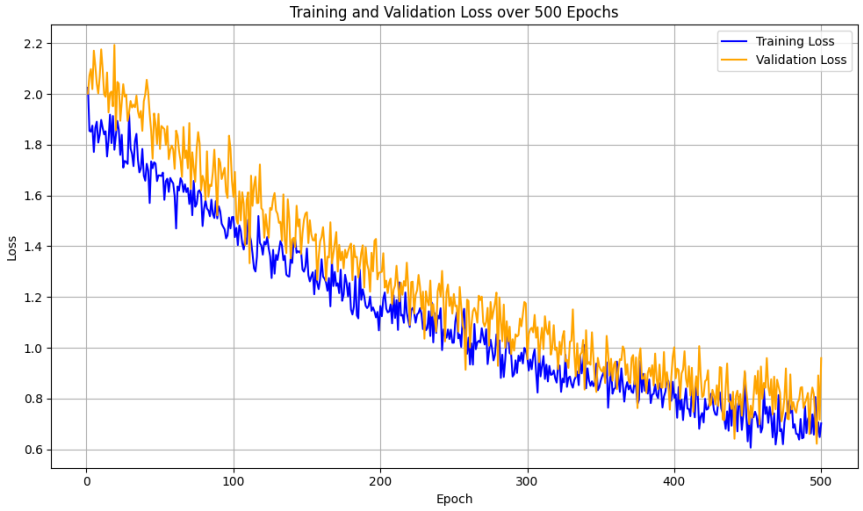

Figure 5.1: Plot of training and validation loss over 500 epochs.

The loss curves showed gradual convergence, with no major overfitting observed.

5.2 Quantitative Metrics

Dice coefficients were computed for each anatomical class on the validation set. The overall mean Dice score across all classes was approximately 0.60, reflecting robust segmentation performance despite variability in patient anatomy and scan quality.

Table 5.1: Validation Dice Scores by Anatomical Class

Class	**Mean Dice Score**
Maxilla and Upper Skull	0.62
Mandible	0.65
Mandibular Nerve	0.55
Upper Teeth	0.61
Lower Teeth	0.63
Edentulous Region	0.58
Other Structures	0.59
Overall Mean Dice	**0.60**

These scores indicate consistent detection of key anatomical structures, including the challenging edentulous regions critical for implant planning.

5.3 Example Segmentation Outputs

The trained model generated 3D NIfTI volumes with voxel-wise labels for seven anatomical classes. Figure 5.2 shows a sample slice with predicted segmentation.

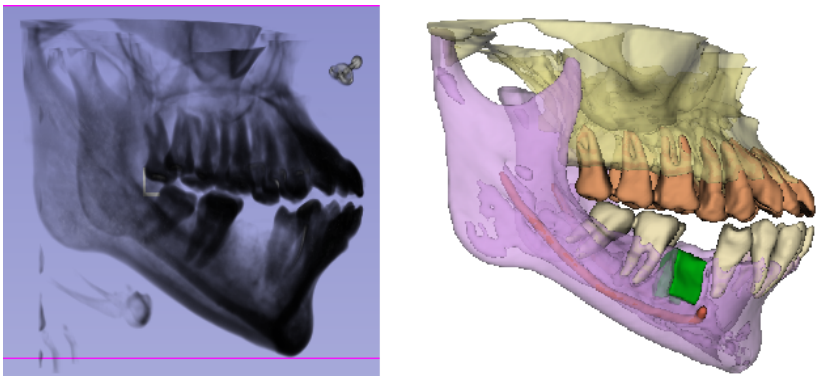

Figure 5.2: Predicted sample of CBCT dental scan

Segmented volumes allow visualization of missing tooth spaces, by labeling them separately, helping clinicians in the design of implants.

5.4 Discussion

The model demonstrated strong performance in distinguishing dental and skeletal structures in CBCT scans, with a particular focus on edentulous regions. While the overall mean Dice of 0.60 reflects solid accuracy, further refinements (e.g., more annotated data, advanced loss weighting) could improve segmentation of smaller structures.

These results confirm the feasibility of a deep learning pipeline for automated detection of voxel-level edentulous space in CBCT scans, supporting personalized and precise dental implant planning.

Chapter 6

Conclusion

This chapter summarises the main outcomes and conclusions resulting from this body of work.

6.1 Conclusions

This project presented the development and implementation of a deep learning-based system for automatic segmentation of edentulous (missing tooth) regions and related anatomical structures in dental CBCT scans. Using a 3D U-Net architecture built with the MONAI framework, the approach focused on voxel-wise multi-class segmentation to label structures such as the maxilla, mandible, upper and lower teeth, mandibular nerve, and edentulous areas.

A dataset of 167 CBCT scans was prepared for training, with segmentation masks created by merging existing dental segmentations and manually annotated edentulous regions. Preprocessing steps ensured consistent voxel spacing, orientation, and intensity normalization. The model was trained over 500 epochs using a hybrid loss function (Dice + Cross-Entropy) with class weighting to address class imbalance, leading to stable convergence and a mean Dice score around 0.6 across validation samples.

The results demonstrate that deep learning can effectively segment dental anatomy and identify edentulous spaces directly from CBCT volumes. Such segmentation provides clinicians with clear, labeled 3D volumes that can assist in pre-surgical planning for dental implants.

6.2 Future Work

While the system achieved promising results, there is scope for further improvement and extension in future research:

- Including more diverse and varied CBCT scans from multiple devices and patient populations to improve generalization.
- Applying more complex augmentation techniques (e.g. elastic deformations, noise, intensity shifts) to make the model robust to real-world variability.
- Integrating attention modules or transformer-based architectures to better focus on complex anatomical boundaries.
- Calculation of bone quality and bone density, which are factors that are helpful for implant placement.
- Incorporating morphological operations or Conditional Random Fields (CRF) to refine segmentation boundaries and reduce artifacts.
- Conducting clinical studies with expert evaluation of segmentation results for practical use in implant planning workflows.
- Development of tools to import segmentation results directly into surgical planning platforms for implant placement simulations.

In general, this work lays the foundation for auto-segmentation of edentulous regions in dental CBCT imaging. This project supports a shift towards precision-guided, data-driven dentistry.

Chapter 7

References

Ronneberger, O., Fischer, P., and Brox, T. (2015). U-Net: Convolutional Networks for Biomedical Image Segmentation. In *Medical Image Computing and Computer-Assisted Intervention (MICCAI)*, pp. 234–241. Springer.

Park, J., Kim, D., and Lee, J. (2022). Deep Learning-Based Detection of Missing Tooth Regions in Panoramic Radiographs. *International Journal of Computer Assisted Radiology and Surgery*, 17(3), 419–429.

Elgarba, A., Cardoso, M. J., Li, W., et al. (2021). MONAI: An Open-Source Framework for Deep Learning in Healthcare Imaging. Available at: https://monai.io/

MONAI Consortium. (2020–2024). MONAI: Medical Open Network for AI. Available at: https://monai.io/

SimpleITK Image Analysis Notebooks. Available at: https://simpleitk.readthedocs.io/

Kikinis, R., Pieper, S. D., and Vosburgh, K. G. (2014). 3D Slicer: A Platform for Subject-Specific Image Analysis, Visualization, and Clinical Support. In *Intraoperative Imaging and Image-Guided Therapy* (pp. 277–289). Springer.

Ibáñez, L., Schroeder, W., Ng, L., and Cates, J. (2005). The ITK Software Guide. Kitware, Inc.

Goodfellow, I., Bengio, Y., and Courville, A. (2016). *Deep Learning*. MIT Press.

C. Mangano, F. Iaculli, A. Piattelli, F. Mangano, Fixed restorations supported by Morse-taper connection implants: a retrospective clinical study with

10–20 years of follow-up, Clin. Oral Implants Res. 26 (2015) 1229-1236,https://doi.org/10.1111/clr.12439.

F. Mangano, R. Bakaj, I. Frezzato, A. Frezzato, S. Montini, C. Mangano, Morse taper connection implants placed in grafted sinuses in 65 patients: a retrospective clinical study with 10 years of follow-up, Int. J. Dent. 2017 (2017), 4573037, https://doi.org/10.1155/2017/4573037.

F.G. Mangano, J.A. Shibli, R.L. Sammons, F. Iaculli, A. Piattelli, C. Mangano, Short (8-mm) locking-taper implants supporting single crowns in posterior region: a prospective clinical study with 1-to 10-years of follow-up, Clin. Oral Implants Res. 25 (2014) 933-940,https://doi.org/10.1111/clr.12181.

F. Mangano, A. Macchi, A. Caprioglio, R.L. Sammons, A. Piattelli, C. Mangano, Survival and complication rates of fixed restorations supported by locking-taper implants: a prospective study with 1 to 10 years of follow-up, J. Prosthodont. 23 (2014) 434–444, https://doi.org/10.1111/jopr.12152.

T.M. Nasr Mostafa, B.M. Elgarba, A.M. Alam-Eldein, Evaluation of retention and attachment wear of CAD/CAM versus conventional implant-assisted overdenture frameworks, Int. J. Periodontics Restorative Dent. 43 (2023) 43–51, https://doi.org/10.11607/prd.5785.