Research Square

Preprints are preliminary reports that have not undergone peer review. They should not be considered conclusive, used to inform clinical practice, or referenced by the media as validated information.

Developmental atlas of phase-amplitude coupling between physiologic high-frequency oscillations and slow waves

Eishi Asano (easano@med.wayne.edu)
Wayne State University https://orcid.org/0000-0001-8391-4067
Kazuki Sakakura
Wayne State University
Naoto Kuroda
Wayne State University
Masaki Sonoda
Wayne State University
Takumi Mitsuhashi
Wayne State University
Ethan Firestone
Wayne State University https://orcid.org/0000-0003-3677-9581
Aimee Luat
Wayne State University
Neena Marupudi
Wayne State University
Sood Sandeep
Wayne State University

Article

Keywords:

Posted Date: April 14th, 2023

DOI: https://doi.org/10.21203/rs.3.rs-2799931/v1

License: This work is licensed under a Creative Commons Attribution 4.0 International License.
Read Full License

Additional Declarations: There is **NO** Competing Interest.

Version of Record: A version of this preprint was published at Nature Communications on October 13th, 2023. See the published version at https://doi.org/10.1038/s41467-023-42091-y.

Abstract

The cortex generates high-frequency oscillations (HFO) nested in slow waves during sleep, and these signals are especially elevated in the seizure onset zone. Thus, HFO occurrence rate and Modulation Index (MI), which quantifies the strength of coupling between HFO amplitude and slow-wave phase, represent promising epilepsy biomarkers. However, their diagnostic utility may be suboptimal because the endogenous developmental distributions are unknown. To improve age-appropriate localization of the epileptogenic zone, we hence constructed normative brain atlases demonstrating the developmental changes in MI and HFO rate.

Our study investigated extraoperative, intracranial EEG data from 114 patients with focal epilepsy (ages 1.0 to 41.5 years) who achieved International League Against Epilepsy class I outcomes following resective surgery. We analyzed 20-minute slow-wave sleep epochs at 8,251 nonepileptic electrode sites (those outside the seizure onset zone, interictal spike zone, or MRI-visible lesions). Each electrode was transposed onto a standard brain template, and we then calculated its MI and HFO occurrence rate using four different detector toolboxes. Linear and nonlinear regression models determined the developmental slope of MI and HFO rate at each cortical mesh point. Mixed model analysis established the significance of MI and HFO rate developmental changes in each region of interest, while accounting for the independent effects of patient and epilepsy profiles. Finally, we created a dynamic tractography movie visualizing white matter pathways connecting cortical regions showing developmental co-growth in MI.

We found that the occipital lobe exhibited enhanced MI compared to other lobes in both children and adults. Increased age, square root of age, and log base 10 of age were independently associated with elevated MI exclusively in the occipital lobe. The cortical regions showing developmental co-growth in MI were connected via the vertical occipital fasciculi and posterior callosal fibers. In contrast, we did not observe any significant association between age measures and HFO rate in the occipital lobe, but rather noted an inverse relationship between age and HFO rate in the temporal, frontal, and parietal lobes.

Our study suggests that phase-amplitude coupling between physiologic HFO and delta waves, as rated by MI, is strengthened during development, in the occipital lobe particularly during toddlerhood and preschool. Given that occipital delta-nested HFO are believed to support visual memory consolidation, our observations imply that process may be significantly strengthened during early childhood. The data is publicly available to provide investigators with a crucial reference for MI and HFO-based presurgical evaluation of the epileptogenic zone.

Introduction

Intracranial EEG biomarkers in epilepsy presurgical evaluation

In patients with drug-resistant focal epilepsy, surgical resection of the epileptogenic zone results in long-term seizure control, and clinicians employ intracranial EEG (iEEG) recording via subdural and/or depth electrodes to localize such areas. The occurrence rate of spontaneous interictal high-frequency oscillations (HFO) - defined as transient bursts of ≥ 80 Hz activity (Zweiphenning et al., 2022a) - has garnered significant attention as an iEEG-based epilepsy biomarker, since it is generally increased in the seizure onset zone (SOZ) (Gloss et al., 2014; Höller et al., 2015; Frauscher et al., 2017; Remakanthakurup Sindhu et al., 2020). Furthermore, a randomized clinical trial involving 78 patients with extratemporal lobe epilepsy recently reported that the efficacy of HFO-guided resection in controlling seizures was non-inferior to that of conventional resection guided by interictal spike discharges (Zweiphenning et al., 2022a).

In addition, HFO are generally nested within slow waves during sleep, and modulation index (MI) is a quantitative measure of the coupling strength between HFO amplitude and slow-wave phase (Canolty et al., 2006; Miyakoshi et al., 2013). MI represents a potentially valuable iEEG-based epilepsy biomarker; in particular, it is an effective proxy measure for epileptiform spike-and-wave discharges, since each spike component is associated with a transient increase in HFO that is stereotypically coupled with a delta wave (Motoi et al., 2018; Kural et al., 2020). Retrospective analysis of iEEG recordings from human epilepsy patients demonstrated that MI is elevated in the SOZ, and complete resection of high-value MI sites was associated with better postoperative seizure outcomes (Nonoda et al., 2016; Iimura et al., 2018; Motoi et al., 2018; Kural et al., 2020; Kuroda et al., 2021; Ma et al., 2021). Notably, MI has advantages over HFO rate as a biomarker that include being a continuous measure and requiring significantly less computational time (Kuroda et al., 2021).

Clinical needs for the normative, developmental atlas of iEEG biomarkers

In clinical practice, caution is required when using MI and HFO rate as iEEG biomarkers because these signals are endogenously present and exhibit topographical variation across the cortex (Guragain et al., 2018; Bernabei et al., 2022; Taylor et al., 2022). The occipital lobe is an area that naturally exhibits elevated MI and HFO rate, regardless of epileptogenicity (Nagasawa et al., 2012; Alkawadri et al., 2014; Frauscher et al., 2018; Kuroda et al., 2021). However, the developmental implications of these physiologic distributions remain unknown, and gleaning this knowledge is expected to significantly improve interpretation of iEEG biomarker clinical significance, in the pediatric brain.

The aim of the present study was to create a novel normative atlas that visualizes developmental changes in MI and HFO rate across artifact-free nonepileptic iEEG electrode sites (defined as those outside the SOZ, interictal spike zone, and MRI-visible lesions; Frauscher et al., 2018; Kuroda et al., 2021; Bernabei et al., 2022; Taylor et al., 2022). To optimize the generalizability of our observations, we employed four different detector toolboxes to calculate HFO rate (Staba et al., 2002; Gardner et al., 2007; Crépon et al., 2010; Zelmann et al., 2010) and used mixed model analysis to determine whether the

observed developmental slope of iEEG biomarkers remained significant after accounting for the independent effects of patient and epilepsy profiles (Sakakura et al., 2022).

Physiological HFO nested in delta waves in the developing brain

Invasive studies of healthy cortices in animal models and nonepileptic cortices of patients with focal epilepsy have reported that spontaneous HFO are nested in delta waves and involve large-scale cortical networks during slow-wave sleep (Steriade et al., 1993; Contreras et al., 1996; Sanchez-Vives and McCormick, 2000; Csercsa et al., 2010; Hangya et al., 2011; Nagasawa et al., 2012; Arnulfo et al., 2020). This nested HFO during slow-wave sleep is believed to replay sensory-related neural communications across two regions occurring during wakefulness and facilitate the consolidation of long-term memory related to given sensory representations. For example, spontaneous $HFO_{\geq 80\ Hz}$ nested in delta $waves_{0.5–1\ Hz}$ in the primary visual cortex during slow-wave sleep are thought to be involved in the consolidation of visual memory (Ji and Wilson, 2007; Mehta, 2007; Sasaki et al., 2010; Buzsáki and da Silva, 2012; Nagasawa et al., 2012).

Given that preverbal infants are known to encode and retain visual information (Werner and Perlmutter, 1979) and this process likely involves HFO-delta phase-amplitude coupling, we hypothesized that young children would have already developed the spatial profile of $MI_{\geq 80\ Hz\ \&\ 0.5–1\ Hz}$: namely physiological enhancement in the nonepileptic occipital lobe, as seen in older children and adults. In addition, since pattern recognition memory is known to improve most rapidly before six years of age (Toornstra et al., 2019), we further hypothesized that the developmental slope of $MI_{\geq 80\ Hz\ \&\ 0.5–1\ Hz}$ would be steepest during young childhood. Here, $MI_{\geq 80\ Hz\ \&\ 0.5–1\ Hz}$ denotes the strength of coupling between the amplitude of $HFO_{\geq 80\ Hz}$ and the phase of $slow\text{-}wave_{0.5–1\ Hz}$.

White matter pathways supporting network communications by spontaneous delta-nested HFO

In addition to modeling cortical ontogenic changes, the present study also visualized white matter pathways supporting the development of neural communications via delta-nested HFO (as rated by $MI_{\geq 80\ Hz\ \&\ 0.5–1\ Hz}$), during slow-wave sleep. To accomplish this, we utilized our novel imaging technique, dynamic tractography, which combines iEEG signals with MRI tractography (Sonoda et al., 2021; Kitazawa et al., 2023; Ono et al., 2023). Previous studies in animal models and patients with focal epilepsy have demonstrated that neural circuits engaging in high-frequency communication are susceptible to use-dependent modifications of synaptic transmission that enhance effective connectivity via monosynaptic white matter tracts in the developing brain (Buonomano and Merzenich, 1998; Singer, 2018; Sonoda et al., 2021). Additionally, white matter development, as rated by MRI tractography, is generally drastic during early childhood and modest during late adolescence (Asato et al., 2010; Lebel et al., 2018; Baum et al., 2022). Using the dynamic tractography method, we visualized intra- and inter-

hemispheric, monosynaptic white matter tracts that connect cortical regions exhibiting significant developmental co-growth of $MI_{\geq 80\ Hz\ \&\ 0.5–1\ Hz}$.

Materials And Methods

Patients

We studied a consecutive series of 114 patients with focal epilepsy (ages 1.0 to 41.5 years) who met the following eligibility criteria (Table 1; **Figure S1**). Inclusion criteria consisted of: [a] simultaneous video-iEEG recording between January 2007 and November 2020, as part of presurgical assessment at Children's Hospital of Michigan or Harper University Hospital, Detroit Medical Center, [b] iEEG sampling rate of 1,000 Hz (Davis et al., 2018), [c] iEEG contained an artifact-free 20-minute slow-wave sleep epoch at least two hours apart from clinical seizure events (Bagshaw et al., 2009; Nagasawa et al., 2012), and [d] International League Against Epilepsy (ILAE) class 1 outcome in the last follow-up after focal resection (Kuroda et al., 2021). Exclusion criteria included [a] a history of previous resective epilepsy surgery, [b] undergoing hemispherotomy or hemispherectomy, and [c] lacking artifact-free, nonepileptic electrode sites (defined as those outside the SOZ [Asano et al., 2009], interictal spike zone [Kural et al., 2020], and MRI-visible lesions [van Klink et al., 2021]). The Institutional Review Board of Wayne State University approved the current study, and we obtained written informed consent from the patients' legal guardians and written assent from pediatric patients aged 13 years or older.

Table 1
Patient Profile. In **Figure S1**, we have provided the distribution of patient ages.

Number of patients	**114**
Mean age in years (range)	11.4 (1.0–41.5)
Proportion of female (%)	47.4
Sampled hemisphere (%)	
Left	45.6
Right	43.0
Both	11.4
Seizure onset zone (%)	
Frontal	24.6
Temporal	47.4
Parietal	27.2
Occipital	19.3
MRI-visible structural lesion (%)	66.7
Mean number of antiseizure medications (range)	2.0 (1–5)

Extraoperative video-iEEG

We acquired extraoperative video-iEEG data using the same protocols as reported in our previous studies (Nagasawa et al., 2012; Kuroda et al., 2021; Sakakura et al., 2022). A licensed neurosurgeon surgically implanted platinum subdural disk electrodes (3 mm diameter and 10 mm center-to-center distance) on the hemisphere suspected to contain the epileptogenic zone, followed by the placement of surface electromyographic electrodes on the deltoid muscles and electrooculographic electrodes (2.5 cm below and 2.5 cm lateral to the outer canthi) to assess body movements during iEEG recording (Nariai et al., 2011; Nagasawa et al., 2012). Intracranial EEG recording aimed to determine the boundaries of the presumed epileptogenic zone, as well as functionally important cortices, and the spatial extent and duration of iEEG sampling were solely determined by clinical needs specific to each patient. Following implantation, iEEG data was continuously recorded at the bedside with a sampling rate of 1,000 Hz, for 2–7 days. To ensure the accuracy of the developmental iEEG atlases, we only included artifact-free iEEG segments from 8,251 nonepileptic electrode sites (mean: 72.4 per patient; range: 12 to 121; Fig. 1A). This approach minimized the unwanted effects of pathological HFO events (Guth et al., 2021; Dimakopoulos et al., 2022).

MRI

We obtained preoperative 3-tesla MRI data, including T1-weighted spoiled gradient-echo volumetric and fluid-attenuated inversion recovery images (Nakai et al., 2017; Sakakura et al., 2022). The FreeSurfer software package was used to reconstruct the MRI surface image of patients aged two and above (http://surfer.nmr.mgh.harvard.edu; Desikan et al., 2006; Ghosh et al., 2010). In cases where the software failed to detect the pial surface accurately due to insufficient cerebral myelination, a board-certified neurosurgeon (K.S.) manually delineated the pial surface using the Control Point function (https://surfer.nmr.mgh.harvard.edu/fswiki/FsTutorial/ControlPoints_freeview/; Deoni et al., 2015; Croteau-Chonka et al., 2016; Remer et al., 2017; Sakakura et al., 2022). For patients younger than two, we used the Infant FreeSurfer software package to reconstruct the surface image (https://surfer.nmr.mgh.harvard.edu/fswiki/infantFS; Zöllei et al., 2020; Sakakura et al., 2022).

We displayed electrode sites on the pial surface of the brain using preoperative MRI and a post-implant CT image (Stolk et al., 2018; Sakakura et al., 2022). Two board-certified neurosurgeons (K.S. and N.K.) visually assessed intraoperative photographs to confirm the spatial accuracy of electrode locations co-registered to the MRI surface image (Pieters et al., 2013). In order to pool sites from all patients, it was necessary to normalize the electrode locations to the standardized FSaverage brain surface (http://surfer.nmr.mgh.harvard.edu). In a previous iEEG study of 32 patients, we found that the mean coregistration error ranged below 0.4 mm, and there was no significant correlation between patient age and the severity of coregistration error (Sakakura et al., 2022).

Focal resection and postoperative seizure outcome

In our previous studies (Asano et al., 2009; Sonoda et al., 2022), we described the guiding principle for determining the boundary of cortical resection. Our aim was to remove the SOZ and any adjacent MRI lesions, while preserving functionally-important cortex; this procedure is intended to maximize seizure control and minimize development of cognitive and/or sensorimotor deficits. Importantly, none of the data from this study was available to inform clinical decision making. Consistent with the study design, all 114 patients achieved ILAE Class-1 outcome at the last follow-up, which occurred at least one year after surgery.

Modulation index (MI)

We identified artifact-free, 20-minute slow-wave sleep iEEG recordings that were at least 2 hours apart from ictal events using visual assessment (Bagshaw et al., 2009; Motoi et al., 2018; Kuroda et al., 2021). At each artifact-free nonepileptic site, we used the EEGLAB winPACT toolbox (https://sccn.ucsd.edu/wiki/WinPACT; Miyakoshi et al., 2013) to automatically compute MI; this program transforms all iEEG data points into Hilbert spectra and quantifies the strength of coupling between HFO amplitude and the instantaneous phase of slow waves. In the notation $\mathrm{MI}_{\geq f\,\mathrm{Hz}\ \mathrm{and}\ s\,\mathrm{Hz}}$ denotes the strength of coupling between the amplitude of $\mathrm{HFO}_{\geq f\,\mathrm{Hz}}$ and the phase of slow-wave$_{s\,\mathrm{Hz}}$.

Below, we report the normative developmental changes primarily in $\mathrm{MI}_{\geq 80\ \mathrm{Hz}\ \&\ 0.5\text{–}1\ \mathrm{Hz}}$ (Fig. 2), which is considered a surrogate marker of the delta-nested HFO that are believed to underly consolidation of long-

term memory related to given sensory representations (Ji and Wilson, 2007; Mehta, 2007; Sasaki et al., 2010; Buzsáki and da Silva, 2012; Nagasawa et al., 2012; Nonoda et al., 2016). We also report the normative developmental changes in $MI_{\geq 80\ Hz\ \&\ 3–4\ Hz}$, which are suggested to be increased in iEEG traces showing frequent interictal spike-and-wave discharges (Motoi et al., 2018; Kural et al., 2020). The normative spatial variability of this biomarker value could be a valuable reference in epilepsy presurgical evaluation.

High-frequency oscillation (HFO)

During the same 20-minute slow-wave sleep iEEG epochs described above, we used the RIPPLELAB software (https://github.com/BSP-Uniandes/RIPPLELAB/; Navarrete et al., 2016) to compute the HFO rate at each artifact-free nonepileptic site, using four different detection algorithms: [1] Short Time Energy (STE) method (Staba et al., 2002), [2] Short Line Length (SLL) method (Gardner et al., 2007), [3] Hilbert (HIL) method (Crépon et al., 2010), and [4] Montreal Neurological Institute (MNI) method (Zelmann et al., 2010). The STE method defines a $HFO_{STE\ \geq f\ Hz}$ event as an iEEG segment presenting successive root mean square values greater than five standard deviations above the overall mean of root mean squares and containing more than six peaks greater than three standard deviations on the *f*-Hz high-pass filtered iEEG trace. The SLL method defines a $HFO_{SLL\ \geq f\ Hz}$ as an iEEG segment presenting SLL amplitude augmentation greater than the 97.5th percentile of the empirical cumulative distribution function computed on the *f*-Hz high-pass filtered iEEG trace. The HIL method defines a $HFO_{HIL\ \geq f\ Hz}$ as an iEEG segment presenting Hilbert transform-based envelope augmentation greater than five standard deviations on the *f*-Hz high-pass filtered iEEG trace. The MNI method defines a $HFO_{MNI\ \geq f\ Hz}$ as an iEEG segment presenting root mean square energy above the 99.9999th percentile compared to the baseline. If the baseline was absent due to persistent high-frequency activity, the MNI method treated an iEEG segment presenting the ≥ 95th percentile of the cumulative distribution function as computed on the 1-minute *f*-Hz high-pass filtered iEEG trace. We used the default parameter settings in the RIPPLELAB software, as reported previously (Kuroda et al., 2021). In the present study, we focused on reporting the developmental changes in the occurrence rate of $HFO_{HIL\ \geq 80\ Hz}$ (/min) as HFO event was defined commonly on Hilbert transformed iEEG traces when quantifying the HFO_{HIL} occurrence rate and computing MI.

An ancillary analysis was performed on the rates of $HFO_{\geq 150\ Hz}$ and $HFO_{\geq 250\ Hz}$ for interested readers.

Statistical analysis to confirm physiological enhancement of MI and HFO in the occipital lobe during young childhood

In a previous study, we created normative atlases of MI and HFO based on data from 47 patients aged between 4 and 19 years, which revealed a general enhancement of these measures in the occipital lobe (Kuroda et al., 2021). In the current study, we aimed to replicate this finding in a cohort of 14 children aged between 1.0 and 3.9 years and 100 individuals aged 4 years or older. We used mixed model analysis with electrode location in the occipital lobe (yes = 1) as the fixed effect predictor variable and either $MI_{\geq 80\ Hz\ \&\ 0.5–1\ Hz}$, $MI_{\geq 80\ Hz\ \&\ 3–4\ Hz}$, $HFO_{STE\ \geq 80\ Hz}$, $HFO_{SLL\ \geq 80\ Hz}$, $HFO_{HIL\ \geq 80\ Hz}$, or $HFO_{MNI\ \geq 80\ Hz}$ as the

dependent variable. The random effect factors included intercept and patient. We considered an FDR-corrected p-value of less than 0.05 as significant, for comparisons of six iEEG measures. We reported the mixed model effect and 95% confidence interval (95% CI) to highlight the impact of topography on normative iEEG biomarker measures. All statistical analyses were performed using Matlab R2020a (MathWorks Inc., Natick, MA).

Statistical analysis to visualize the developmental slope of cortical MI and HFO at given mesh points

We presented iEEG biomarker measures at each nonepileptic electrode site on a standardized brain surface image using FreeSurfer and interpolation within 10 mm from the electrode center at the individual patient level (Sakakura et al., 2022, Ono et al., 2023). Using linear and nonlinear univariate regression models at cortical surface mesh points consisting of 20 neighboring FreeSurfer vertex finite elements (Desikan et al., 2006; Sakakura et al., 2022), we then determined the developmental slope of the iEEG biomarker, at the whole brain level. We used age, square root of age (√age), and $\log_{10}$ age as an independent variable, and $MI_{\geq 80\ Hz\ \&\ 0.5-1\ Hz}$, $MI_{\geq 80\ Hz\ \&\ 3-4\ Hz}$, $HFO_{STE\ \geq 80\ Hz}$, $HFO_{SLL\ \geq 80\ Hz}$, $HFO_{HIL\ \geq 80\ Hz}$, or $HFO_{MNI\ \geq 80\ Hz}$ as dependent variables. We evaluated the goodness of fit of each regression model using Akaike Information Criterion (AIC). A biomarker value was considered to increase with age if the regression slope was significantly greater than zero. We identified the mesh points where the developmental change (enhancement or diminution) of a given iEEG biomarker measure survived an FDR correction (for 18 comparisons: six iEEG measures × three types of age measures) in the resulting normative atlas. We also created video atlases, each displaying $MI_{\geq 80\ Hz\ \&\ 0.5-1\ Hz}$, $MI_{\geq 80\ Hz\ \&\ 3-4\ Hz}$, or $HFO_{HIL\ \geq 80\ Hz}$ values predicted by a given regression model at cortical mesh points (Fig. 3; **Videos S1-S3**).

Statistical analysis to determine the independent effects of development on cortical MI and HFO in each lobe

We used mixed model analysis (Sonoda et al., 2021; Sakakura et al., 2022) to determine the lobe where a developmental change of a given iEEG biomarker remained significant, after controlling for the independent effects of clinical profile and epilepsy-related variables. The aim was to account for potential confounders that could affect MI and HFO measures.

To assess the developmental change of MI at each lobe, we utilized the MATLAB fitlme command (https://www.mathworks.com/help/stats/fitlme.html) to fit a mixed model specified by the following formula: 'MI ~ 1 + age + sex + SOZ + MRI + hemisphere + number of antiseizure medications + (1|patient)'. Here, the dependent variable was MI at a given analysis mesh point, and the fixed effect predictors included [1] age at surgery (e.g., √year), [2] sex (female = 1), [3] presence of SOZ in a given lobe (yes = 1), [4] presence of MRI-visible structural lesion (yes = 1), [5] sampled hemisphere (left = 1), and [6] number of oral antiseizure medications taken immediately before the initiation of iEEG recording. We considered a larger number of antiseizure medications as a surrogate of a more severe seizure-related cognitive burden since polytherapy is associated with more disabling seizures and seizure-related cognitive impairment (Kwan and Brodie, 2001; Kuroda et al., 2021). We employed this approach since no single

neuropsychological assessment can quantify the severity of cognitive impairment across all age ranges. Our random effect factors included the intercept and patient. We deemed an FDR-corrected p-value of 0.05 (for 18 comparisons: six iEEG measures × three types of age measures) as the significance threshold.

Statistical analysis to determine if the spectral frequency band of slow waves nesting HFO would change with development

Some might hypothesize that slow waves with a higher spectral frequency band would facilitate a higher rate of spontaneous neural communication through nested HFO. As an ancillary analysis, we, therefore, sought to determine whether the spectral frequency band of slow waves nesting HFO would change with development. To accomplish this, we measured $MI_{\geq 80\ Hz\ \&\ s\ Hz}$, where *s* was 0.5-1, 1–2, 2–3, 3–4, 4–5, 5–6, 6–7, or 7–8 (Fig. 4) and calculated the regression slope of $MI_{\geq 80\ Hz\ \&\ s\ Hz}$ with respect to *s* Hz, in each lobe. We then assessed whether this regression slope was dependent on patient age in each lobe using the Spearman correlation. A higher regression slope in older individuals, compared to younger individuals, would suggest that $HFO_{\geq 80\ Hz}$ in older individuals were preferentially coupled with slow waves of higher spectral frequency bands. We set an FDR-corrected p-value of 0.05 (for testing at four lobes) as the significance threshold.

Statistical analysis: white matter tracts between cortices showing developmental MI co-growth

We visualized white matter tracts directly connecting cortical mesh points that showed significant developmental co-growth (or co-reduction) of $MI_{\geq 80\ Hz\ \&\ 0.5–1\ Hz}$. To this end, we used the regression slope of $MI_{\geq 80\ Hz\ \&\ 0.5–1\ Hz}$ as a function of $\sqrt{age}$ at each cortical mesh point, as computed in a regression analysis mentioned above. We declared that the developmental enhancement (or reduction) of nested HFO-based neural communications took place between two cortical mesh points only if [1] two distinct mesh points showed significantly positive (or negative) regression slopes, and [2] these mesh points were accompanied by direct tractography streamlines on diffusion-weighted imaging (DWI) analysis (Kitazawa et al., 2023; Ono et al., 2023).

We delineated white matter DWI streamlines using open-source data from 1,065 healthy participants (http://brain.labsolver.org/diffusion-mri-templates/hcp-842-hcp-1021; Yeh et al., 2018), as previously reported (Mitsuhashi et al., 2021, 2022; Sonoda et al., 2021; Kitazawa et al., 2023; Ono et al., 2023). Our group validated the use of open-source DWI data by demonstrating that the inferred velocity of neural propagations induced by single-pulse electrical stimulation was similar whether using open-source or individual patient DWI data (Sonoda et al., 2021). We placed seeds (4-mm radius) at cortical mesh points demonstrating significant developmental enhancement (or reduction) of nested HFO-based neural communications (as rated by $MI_{\geq 80\ Hz\ \&\ 0.5–1\ Hz}$). Using DSI Studio (http://dsi-studio.labsolver.org/), we visualized DWI streamlines directly connecting the mesh points within Montreal Neurological Institute standard space. For fiber tracking, we utilized the following parameters: a quantitative anisotropy

threshold of 0.05, a maximum turning angle of 70°, and a streamline length of 20 to 250 mm. In this investigation, we exclusively visualized DWI streamlines with at least 50% of their coordinates in one of the following white matter tracts: arcuate fasciculus, cingulum, corpus callosum, extreme capsule, frontal aslant tract, inferior fronto-occipital fasciculus, inferior longitudinal fasciculus, middle longitudinal fasciculus, superior longitudinal fasciculus, uncinate fasciculus, or vertical occipital fasciculus, as defined in DSI Studio (as previously performed in Sonoda et al. 2021). We excluded streamlines involving the brainstem, basal ganglia, thalamus, or cerebrospinal fluid space.

The resulting dynamic tractography video atlases highlighted the intensity of $MI_{\geq 80\ Hz\ \&\ 0.5–1\ Hz}$ developmental co-growth (or co-reduction) via given tractography streamlines for every 0.1 years; thereby, the intensity was defined as ($\sqrt{|\text{regression slope at a mesh point}|} \times \sqrt{|\text{regression slope at another mesh point}|}$), at a given streamline connecting a pair of mesh points (Fig. 5).

Data and code availability statement

The iEEG data are available at https://openneuro.org/ (doi:10.18112/openneuro.ds004551.v1.0.2) and https://nemar.org/. The analysis codes are available at https://github.com/kaz1126/flatten_map_and_tractography.

Results

Developmental atlas of cortical MI

Figure 2A illustrates the developmental changes in cortical $MI_{\geq 80\ Hz\ \&\ 0.5\text{-}1\ Hz}$ at specific lobes using dot plots. The regression slope, uncorrected p-value, regression t-value, and degrees of freedom (DF) are also shown. **Video S1** provides a comprehensive summary of normative development of $MI_{\geq 80\ Hz\ \&\ 0.5\text{-}1\ Hz}$, estimated by univariate regression models with age, √age, or $\log_{10}$ age as independent variables. Linear and nonlinear regression models consistently indicate significant developmental growth in $MI_{\geq 80\ Hz\ \&\ 0.5\text{-}1\ Hz}$ prominently in the occipital lobe during young childhood and beyond. The assessment of AIC suggests that the developmental growth in occipital $MI_{\geq 80\ Hz\ \&\ 0.5\text{-}1\ Hz}$ was drastic during young childhood and modest during older childhood. The mean regression slope was +0.0072 /year (95%CI: +0.0050 to +0.0093; AIC: -368.0) in the linear regression model, +0.047 /√year (95%CI: +0.034 to +0.060; AIC: -374.3) and +0.14 /$\log_{10}$ year (95%CI: +0.10 to +0.18; AIC: -376.6) in the nonlinear models. The regression slopes of $MI_{\geq 80\ Hz\ \&\ 0.5\text{-}1\ Hz}$ in the parietal, temporal, and frontal lobes were much flatter, compared to the occipital lobe (**Figure 2** and **Video S1**).

As detailed in **Figure S2** and **Video S2**, the developmental changes of $MI_{\geq 80\ Hz\ \&\ 0.5\text{-}1\ Hz}$ and $MI_{\geq 80\ Hz\ \&\ 3\text{-}4\ Hz}$ were qualitatively similar. The developmental growth of $MI_{\geq 80\ Hz\ \&\ 3\text{-}4\ Hz}$ was highest in the occipital lobe. The mean regression slope was +0.019 /√year (95%CI: +0.014 to +0.023) in the occipital lobe but not significantly different from zero in the remaining lobes.

Figure 3A displays snapshots of normative developmental atlases for $MI_{\geq 80\ Hz\ \&\ 0.5\text{-}1\ Hz}$ at the whole brain level, emphasizing the increased values in cortical regions near the calcarine sulcus.

Developmental atlas of cortical HFO rate

The regression models, applied to all 114 patients, did not demonstrate any significant developmental growth or diminution of occipital $HFO_{\geq 80\ Hz}$ as defined by any detector (uncorrected p-value > 0.05; **Figure 2B; Figure S2**). In contrast, the rate of extra-occipital $HFO_{\geq 80\ Hz}$ generally showed significant developmental diminution (uncorrected p-value < 0.001). Such developmental diminution of extra-occipital HFO resulted in a relatively maintained HFO occurrence rate in the occipital lobes, particularly those adjacent to the calcarine cortex, during adolescence and beyond (**Figure 3B**). Below, we describe the findings of $HFO_{HIL\ \geq 80\ Hz}$ in detail.

Video S3 provides a comprehensive summary of normative development of $HFO_{HIL \geq 80\ Hz}$ rate. Occipital $HFO_{HIL\ \geq 80\ Hz}$ rate failed to show significant developmental change (uncorrected p-value > 0.05; **Figure 2B**). In contrast, extra-occipital $HFO_{HIL\ \geq 80\ Hz}$ rate showed significant developmental diminution (uncorrected p-value < 0.001; **Figure 2B**). The assessment of AIC suggested that the developmental diminution in extra-occipital $HFO_{HIL\ \geq 80\ Hz}$ was comparable during young and older childhood (AIC in extra-occipital lobes: 2.60 x 10^4 in age-incorporated model; 2.59 x 10^4 in $\sqrt{age}$ model; 2.59 x 10^4 in $\log_{10}$ age model). The regression slope was -0.41/$\sqrt{year}$ (95%CI: -0.46 to -0.36) in the frontal lobe, -0.30/$\sqrt{year}$ (95%CI: -0.36 to -0.25) in the temporal lobe, -0.33/$\sqrt{year}$ (95%CI: -0.40 to -0.26) in the parietal lobe, and +0.081/$\sqrt{year}$ (95%CI: -0.075 to +0.24) in the occipital lobe.

Due to the infrequent occurrence of events, regression models failed to fit the data of $HFO_{\geq 150\ Hz}$ and $HFO_{\geq 250\ Hz}$ rates in a meaningful manner.

MI enhancement in the occipital lobe during young childhood and after

The mixed model analysis of iEEG data of 14 children aged from 1.0 and 3.9 suggested that, as compared to the other lobes, the occipital lobe showed higher $MI_{\geq 80\ Hz\ \&\ 0.5\text{-}1\ Hz}$ (mixed model effect: +0.087 [95%CI: +0.078 to +0.097]; uncorrected p-value: < 0.001) and $MI_{\geq 80\ Hz\ \&\ 3\text{-}4\ Hz}$ (mixed model effect: +0.033 [95%CI: +0.028 to +0.038]; uncorrected p-value: < 0.001).

An ancillary mixed model analysis of iEEG data of 100 individuals aged from 4.0 and 41.5 suggested that, as compared to the other lobes, the occipital lobe likewise showed higher $MI_{\geq 80\ Hz\ \&\ 0.5\text{-}1\ Hz}$ (mixed model effect: +0.17 [95%CI: +0.17 to +0.18]; uncorrected p-value: < 0.001) and $MI_{\geq 80\ Hz\ \&\ 3\text{-}4\ Hz}$ (mixed model effect: +0.063 [95%CI: +0.061 to +0.066]; uncorrected p-value: < 0.001). These findings indicate that the nonepileptic occipital lobe exhibits higher MI in comparison to the other regions, across all age groups (**Figure 3A**). Moreover, the difference in MI between the occipital and extra-occipital lobe regions was found to be approximately two times greater in older individuals.

Topographical variations of HFO rate during young childhood and after

The mixed-model analysis of iEEG data from 14 children between the ages of 1.0 and 3.9 did not show a higher HFO rate in the occipital lobe compared to extra-occipital lobes, except when considering the HFO rate defined by the Hilbert method ($HFO_{STE \geq 80\ Hz}$ mixed model effect: +0.022 [95%CI: -0.039 to +0.082]; uncorrected p-value: 0.48; $HFO_{SLL \geq 80\ Hz}$ mixed model effect: +0.036 [95%CI: -0.46 to +0.53]; uncorrected p-value: 0.89; $HFO_{HIL \geq 80\ Hz}$ mixed model effect: +0.84 [95%CI: +0.57 to +1.1]; uncorrected p-value: < 0.001; $HFO_{MNI \geq 80\ Hz}$ mixed model effect: -0.044 [95%CI: -0.90 to +3.0 x 10^{-3}]; uncorrected p-value: 0.067). The model suggests that the nonepileptic occipital lobe of children under four years old generates Hilbert method-defined $HFO_{\geq 80\ Hz}$ occurrences at a rate of 0.84/min more frequently than extra-occipital lobe regions.

Another mixed-model analysis of iEEG data from 100 individuals between the ages of 4.0 and 41.5 demonstrated that the occipital lobe had a higher HFO rate compared to the extra-occipital lobes, except when considering the HFO rate defined by the MNI method ($HFO_{STE \geq 80\ Hz}$ mixed model effect: +0.14 [95%CI: +0.12 to +0.16]; uncorrected p-value: < 0.001; $HFO_{SLL \geq 80\ Hz}$ mixed model effect: +0.59 [95%CI: +0.43 to +0.75]; uncorrected p-value: < 0.001; $HFO_{HIL \geq 80\ Hz}$ mixed model effect: +1.8 [95%CI: +1.7 to +1.9]; uncorrected p-value: < 0.001; $HFO_{MNI \geq 80\ Hz}$ mixed model effect: +0.043 [95%CI: -0.014 to +0.099]; uncorrected p-value: 0.14). The model suggests that the non-epileptic occipital lobe of individuals of four years old or above generates Hilbert method-defined $HFO_{\geq 80\ Hz}$ occurrences at a rate of 1.8/min more frequently than extra-occipital lobe regions (**Figure 3B**).

Independent effects of development on cortical MI in each lobe

The mixed model analysis, employed to all 114 patients, confirmed that an increase in √age was associated with an increase in occipital $MI_{\geq 80\ Hz\ \&\ 0.5\text{-}1\ Hz}$ (mixed model effect: +0.046 [95%CI: +0.019 to +0.072]; uncorrected p-value: 7.43 x 10^{-4}; t-value: +3.39; DF: 868) and $MI_{\geq 80\ Hz\ \&\ 3\text{-}4\ Hz}$ (mixed model effect: +0.019 [95%CI: +0.0090 to +0.029]; uncorrected p-value: 1.22 x 10^{-4}; t-value: +3.86; DF: 868), independent of patient and epilepsy profiles. In contrast, mixed model analysis failed to confirm that an increase in √age was associated with an increase in extra-occipital $MI_{\geq 80\ Hz\ \&\ 0.5\text{-}1\ Hz}$ or $MI_{\geq 80\ Hz\ \&\ 3\text{-}4\ Hz}$ (uncorrected p-value: >0.05).

Independent effects of development on cortical HFO rate in each lobe

The mixed model analysis confirmed that an increase in √age was independently associated with a diminution of $HFO_{HIL \geq 80\ Hz}$ rate in the frontal (mixed model effect: -0.53; uncorrected p-value: 5.68 x 10^{-7}; t-value: -4.97; DF: 2973), temporal (mixed model effect: -0.34; uncorrected p-value: 2.0 x 10^{-3}; t-value: -3.09; DF: 2388), and parietal lobes (mixed model effect: -0.38; uncorrected p-value: 5.43 x 10^{-4}; t-value: -3.46; DF: 1994). However, this phenomenon was not observed in the occipital lobe (mixed model effect: +0.069; uncorrected p-value: 0.69; t-value: +0.40; DF: 868).

Developmental changes of the spectral frequency band of slow waves nesting HFO

Looking at $MI_{\geq 80\ Hz\ \&\ varying\ slow\ waves}$, we failed to find a significant developmental change of the frequency band of slow waves nesting HFO (**Figure 4**). On average, the regression slope of $MI_{\geq 80\ Hz\ \&\ s\ Hz}$ as a function of slow waves (*s* Hz) was -0.014 /Hz in the frontal lobe, -0.013 /Hz in the parietal lobe, -0.010 /Hz in the temporal lobe, and -0.027 /Hz in the occipital lobe. In other words, $MI_{\geq 80\ Hz}$ values were generally higher when using lower frequency slow waves. The Spearman correlation failed to demonstrate a significant correlation between this regression slope and patient age in any lobe (uncorrected p-value: >0.05). Thus, the present study failed to demonstrate that the spectral frequency band of slow waves nesting HFO would change with development.

White matter tracts connecting cortices with developmental MI co-growth

Univariate regression models, incorporating √age as an independent variable, found that 159 out of the 9464 cortical mesh points (1.7%) showed significantly positive regression slopes, whereas no cortical mesh points showed significantly negative regression slopes. DWI analysis revealed that the vertical occipital fasciculi and posterior callosal fibers directly connected mesh point pairs showing significant developmental co-growth of $MI_{\geq 80\ Hz\ \&\ 0.5\text{-}1\ Hz}$ (**Figure 5A** and **Video S4**).

White matter tracts connecting cortices with developmental HFO co-diminution

Univariate regression models incorporating √age as an independent variable found that 902 out of the 9464 cortical mesh points (9.5%) showed significantly negative regression slopes, whereas no cortical mesh points showed significantly positive regression slopes. DWI analysis revealed that the arcuate fasciculus, corpus callosum, extreme capsule, frontal aslant tract, inferior fronto-occipital fasciculus, inferior longitudinal fasciculus, middle longitudinal fasciculus, and superior longitudinal fasciculus directly connected mesh point pairs showing significant developmental co-diminution of $HFO_{HIL\geq 80\ Hz}$ rate (**Figure 5B** and **Video S5**).

Discussion

Clinical significance of enhanced MI in the occipital lobe in epilepsy presurgical evaluation

For the first time, the current study created a developmental atlas of MI at the whole brain level, including the medial and inferior surfaces of the cerebral cortex. It demonstrated physiologically enhanced MI in the nonepileptic occipital lobe of children younger than 4 years and in the older patient group. The occipital lobe showed higher $MI_{\geq 80\ Hz\ \&\ 3\text{–}4\ Hz}$ than the other lobes by 0.033 on average in children younger than 4 years and by 0.063 on average in older patients. Although $MI_{\geq 80\ Hz\ \&\ 3\text{–}4\ Hz}$ is an excellent surrogate marker of interictal spike-and-wave discharges (Motoi et al., 2018; Kural et al., 2020), the occurrence of physiological HFO nested in slow-wave background activity (Steriade et al., 1993; Contreras

et al., 1996; Sanchez-Vives and McCormick, 2000, Nagasawa et al., 2012; Nonoda et al., 2016) inflates $MI_{\geq 80\ Hz\ \&\ 3–4\ Hz}$ in the nonepileptic occipital lobe. Therefore, iEEG investigators should cautiously interpret the significance of high-value, occipital MI in presurgical evaluation for young and older patients with drug-resistant focal epilepsy. Nonepileptic occipital lobe sites, especially those proximal to the calcarine sulcus, are expected to show MI values higher than nonepileptic extra-occipital lobe sites (**Video S1 and** Fig. 3A). With awareness of such topographic variations of MI, iEEG investigators can reduce the risk of incorrect localization of the epileptogenic zone.

Investigators previously reported the utility of normative atlases of MI, HFO, and other spectral frequency bands, in the presurgical evaluation of patients with the mean age ranging between adolescence and adulthood (Frauscher et al., 2018; Guragain et al., 2018; Kuroda et al., 2021; Bernabei et al., 2022; Taylor et al., 2022; Zweiphenning et al., 2022b). A prospective study is warranted to investigate whether a more inclusive resection of cortical sites, whose MI values deviate from the age-specific normal range, would predict better postoperative seizure control in young children.

Clinical significance of HFO atlases in epilepsy presurgical evaluation

For the first time, the current study investigated the developmental changes of HFO occurrence rate defined by four open-source detectors (Fig. 2; **Figure S2**). Commonly across detectors, the HFO rate diminished in the frontal, parietal, and temporal lobes with development. Thus, clinicians need to be aware that young children may show nonepileptic HFO in the extra-occipital lobe regions more frequently than adults. As best demonstrated in **Video S3**, $HFO_{HIL\ \geq 80\ Hz}$ rate was physiologically enhanced in the occipital regions proximal to the calcarine cortex, but such occipital HFO enhancement was only evident during adolescence and adulthood and not during infancy or toddlerhood.

$HFO_{MNI\ \geq 80\ Hz}$ rate was very low in the occipital lobes throughout all ages; this MNI method-specific observation can be attributed to its detector being designed to be agnostic to persistent forms of high-frequency activity (Zelmann et al., 2010), as often seen in the nonepileptic occipital lobe (Nagasawa et al., 2012).

Mechanistic significance of developmental changes of MI and HFO

What is responsible for the developmental enhancement of MI in the occipital lobe? The current study found that $MI_{\geq 80\ Hz\ \&\ 0.5–1\ Hz}$ increases rapidly during early childhood and modestly thereafter. However, the occipital HFO rate did not increase significantly with development, suggesting that rate changes may not sufficiently account for the developmental enhancement of MI (Fig. 2B). Furthermore, an assessment of the spectral frequency bands of slow-waves nesting HFO (Fig. 4) did not provide evidence that such nesting slow rhythms become faster with development. In contrast, our white matter connectivity assessment revealed that occipital regions exhibiting a developmental enhancement of MI were accompanied by monosynaptic white matter streamlines, including the vertical occipital fasciculi and

posterior callosal fibers (Fig. 5A). These white matter structures are essential for object recognition (Baynes et al., 1998; Schulte et al., 2010; Yeatman et al. 2014; Herbet et al., 2018); thus, one possible explanation for the developmental enhancement of occipital MI is that the cerebral cortex learns to generate HFO at a preferred phase of background rhythms in an experience-dependent manner, optimizing visual memory consolidation during slow-wave sleep (Ji and Wilson, 2007; Mehta, 2007; Sasaki et al., 2010; Buzsáki and da Silva, 2012; Nagasawa et al., 2012). This notion is supported by the observation that monocular sight deprivation during a critical period altered delta-gamma phase-amplitude coupling in the mouse visual cortex (Malik et al., 2022).

Innovation

The methodological innovations in the current study include the generation of developmental atlases based on iEEG signals from 114 patients, including infants and toddlers. We previously validated our group-level analysis of iEEG across generations from infancy to adulthood (Sakakura et al., 2022). A pivotal procedure to ensure the spatial accuracy of electrode-brain surface coregistration was a manual delineation of the pial surface in the temporal lobe regions that are frequently unmyelinated in young children (Sakakura et al., 2022).

Visualization of the direct white matter streamlines connecting cortical regions with a developmental enhancement of MI is an innovative application of dynamic tractography technology (Sonoda et al., 2021; Kitazawa et al., 2023; Ono et al., 2023). We interpret the visualized streamlines, including vertical occipital fasciculi and posterior callosal fibers, to reflect the ongoing development of large-scale neural communications based on slow wave-nested HFO before reaching the adult level.

Methodological considerations

Inevitable limitations in the present study include limited spatial sampling, though 8,251 nonepileptic electrode sites were available for analysis. We are only able to place electrodes that are clinically indicated. Neither Heschl nor insular gyri were analyzed in the present study using subdural electrodes. Thus, our study was not designed to assess the developmental enhancement of MI or HFO in much of the primary auditory cortex. We did not sample iEEG signals from the thalamus either because there was no clinical indication. Since stereotactic-EEG depth electrodes are used to assess the thalamic nuclei to determine the optimal target for deep brain stimulation and responsive neurostimulation therapy, further studies are expected to determine the developmental changes of MI and HFO in such deep brain structures in the future.

Another limitation included cross-sectional measurement due to the invasive nature of iEEG recording. Chronic iEEG recording is available through eight intracranial electrode contacts in patients undergoing responsive neurostimulation. Yet, longitudinal assessment of nonepileptic iEEG signals using these contacts may not be feasible because these electrodes are implanted in the area proximal to the epileptogenic zone.

Our ancillary analysis on the rates of $HFO_{\geq 150\ Hz}$ and $HFO_{\geq 250\ Hz}$ revealed that the infrequent occurrence of these events made it impossible for regression models to meaningfully fit the data. To detect sufficient numbers of $HFO_{\geq 150\ Hz}$ and $HFO_{\geq 250\ Hz}$ events for analysis of developmental changes, interictal slow-wave sleep epochs much longer than 20 minutes would be necessary. However, the duration of iEEG recording is determined solely by clinical needs, making it unrealistic to expect that all study participants would have prolonged iEEG epochs that meet the eligibility criteria employed in this study. Although the spatial distribution of the rates of $HFO_{\geq 80\ Hz}$, $HFO_{\geq 150\ Hz}$, and $HFO_{\geq 250\ Hz}$ are generally similar to each other, some studies suggest that $HFO_{\geq 250\ Hz}$ may be more specific than $HFO_{\geq 80\ Hz}$ in localizing the epileptogenic zone; however, others imply that $HFO_{\geq 250\ Hz}$ may not be as practical as $HFO_{\geq 80\ Hz}$ due to its rarity and its presence in the nonepileptic eloquent cortex (Gloss et al., 2014; Höller et al., 2015; Frauscher et al., 2017; Roehri et al., 2018; Kuroda et al., 2021; Zweiphenning et al., 2022a).

One drawback of using iEEG is that we are unable to include healthy controls, because it is unethical to implant subdural electrodes without clinical indication. Thus, we excluded electrode sites affected by either SOZ, interictal spike zone, and MRI-visible lesions from the analysis. Furthermore, we employed mixed model analysis to control the effects of potential confounding factors on MI/HFO measures, including antiseizure medications, presence of MRI-visible lesions, and locations of SOZ. Despite those issues, iEEG involves benefits over scalp recording such as, > 100 times better signal fidelity and sampling from the medial or inferior cerebral cortex surface (Ball et al., 2009).

References

1. Zweiphenning W, Klooster MAV', van Klink NEC, et al. Intraoperative electrocorticography using high-frequency oscillations or spikes to tailor epilepsy surgery in the Netherlands (the HFO trial): a randomised, single-blind, adaptive non-inferiority trial. Lancet Neurol. 2022;21(11):982–993.
2. Gloss D, Nolan SJ, Staba R. The role of high-frequency oscillations in epilepsy surgery planning. Cochrane Database Syst Rev. 2014;1(1):CD010235.
3. Höller Y, Kutil R, Klaffenböck L, et al. High-frequency oscillations in epilepsy and surgical outcome. A meta-analysis. Front Hum Neurosci. 2015;9:574.
4. Frauscher B, Bartolomei F, Kobayashi K, et al. High-frequency oscillations: The state of clinical research. Epilepsia. 2017;58(8):1316–1329.
5. Remakanthakurup Sindhu K, Staba R, Lopour BA. Trends in the use of automated algorithms for the detection of high-frequency oscillations associated with human epilepsy. Epilepsia. 2020;61(8):1553–1569.
6. Canolty RT, Edwards E, Dalal SS, et al. High gamma power is phase-locked to theta oscillations in human neocortex. Science. 2006;313(5793):1626–1628.
7. Miyakoshi M, Delorme A, Mullen T, Kojima K, Makeig S, Asano E. Automated detection of cross-frequency coupling in the electrocorticogram for clinical inspection. Annu Int Conf IEEE Eng Med Biol Soc. 2013;2013:3282–3285.

8. Kuroda N, Sonoda M, Miyakoshi M, et al. Objective interictal electrophysiology biomarkers optimize prediction of epilepsy surgery outcome. Brain Commun. 2021;3(2):fcab042.
9. Nonoda Y, Miyakoshi M, Ojeda A, et al. Interictal high-frequency oscillations generated by seizure onset and eloquent areas may be differentially coupled with different slow waves. Clin Neurophysiol. 2016;127(6):2489–2499.
10. Iimura Y, Jones K, Takada L, et al. Strong coupling between slow oscillations and wide fast ripples in children with epileptic spasms: Investigation of modulation index and occurrence rate. Epilepsia. 2018;59(3):544–554.
11. Ma H, Wang Z, Li C, Chen J, Wang Y. Phase-Amplitude Coupling and Epileptogenic Zone Localization of Frontal Epilepsy Based on Intracranial EEG. Front Neurol. 2021;12:718683.
12. Motoi H, Miyakoshi M, Abel TJ, et al. Phase-amplitude coupling between interictal high-frequency activity and slow waves in epilepsy surgery. Epilepsia. 2018;59(10):1954–1965.
13. Kural MA, Duez L, Sejer Hansen V, et al. Criteria for defining interictal epileptiform discharges in EEG: A clinical validation study. Neurology. 2020;94(20):e2139-e2147.
14. Guragain H, Cimbalnik J, Stead M, et al. Spatial variation in high-frequency oscillation rates and amplitudes in intracranial EEG. Neurology. 2018;90(8):e639-e646.
15. Bernabei JM, Sinha N, Arnold TC, et al. Normative intracranial EEG maps epileptogenic tissues in focal epilepsy [published correction appears in Brain. 2023 Jan 5;146(1):e5]. *Brain*. 2022;145(6):1949–1961.
16. Taylor PN, Papasavvas CA, Owen TW, et al. Normative brain mapping of interictal intracranial EEG to localize epileptogenic tissue. Brain. 2022;145(3):939–949.
17. Nagasawa T, Juhász C, Rothermel R, Hoechstetter K, Sood S, Asano E. Spontaneous and visually driven high-frequency oscillations in the occipital cortex: intracranial recording in epileptic patients. Hum Brain Mapp. 2012;33(3):569–583.
18. Alkawadri R, Gaspard N, Goncharova II, et al. The spatial and signal characteristics of physiologic high frequency oscillations. Epilepsia. 2014;55(12):1986–1995.
19. Frauscher B, von Ellenrieder N, Zelmann R, et al. High-Frequency Oscillations in the Normal Human Brain. Ann Neurol. 2018;84(3):374–385.
20. Staba RJ, Wilson CL, Bragin A, Fried I, Engel J Jr. Quantitative analysis of high-frequency oscillations (80–500 Hz) recorded in human epileptic hippocampus and entorhinal cortex. J Neurophysiol. 2002;88(4):1743–1752.
21. Gardner AB, Worrell GA, Marsh E, Dlugos D, Litt B. Human and automated detection of high-frequency oscillations in clinical intracranial EEG recordings. Clin Neurophysiol. 2007;118(5):1134–1143.
22. Crépon B, Navarro V, Hasboun D, et al. Mapping interictal oscillations greater than 200 Hz recorded with intracranial macroelectrodes in human epilepsy. Brain. 2010;133(Pt 1):33–45.
23. Zelmann R, Mari F, Jacobs J, Zijlmans M, Chander R, Gotman J. Automatic detector of high frequency oscillations for human recordings with macroelectrodes. Annu Int Conf IEEE Eng Med Biol

Soc. 2010;2010:2329–2333.

24. Sakakura K, Sonoda M, Mitsuhashi T, et al. Developmental organization of neural dynamics supporting auditory perception. Neuroimage. 2022;258:119342.
25. Steriade M, Nuñez A, Amzica F. A novel slow (< 1 Hz) oscillation of neocortical neurons in vivo: depolarizing and hyperpolarizing components. J Neurosci. 1993;13(8):3252–3265.
26. Contreras D, Timofeev I, Steriade M. Mechanisms of long-lasting hyperpolarizations underlying slow sleep oscillations in cat corticothalamic networks. J Physiol. 1996;494 (Pt 1)(Pt 1):251–264.
27. Sanchez-Vives MV, McCormick DA. Cellular and network mechanisms of rhythmic recurrent activity in neocortex. Nat Neurosci. 2000;3(10):1027–1034.
28. Csercsa R, Dombovári B, Fabó D, et al. Laminar analysis of slow wave activity in humans. Brain. 2010;133(9):2814–2829.
29. Hangya B, Tihanyi BT, Entz L, et al. Complex propagation patterns characterize human cortical activity during slow-wave sleep. J Neurosci. 2011;31(24):8770–8779.
30. Arnulfo G, Wang SH, Myrov V, et al. Long-range phase synchronization of high-frequency oscillations in human cortex. Nat Commun. 2020;11(1):5363. Published 2020 Oct 23.
31. Ji D, Wilson MA. Coordinated memory replay in the visual cortex and hippocampus during sleep. Nat Neurosci. 2007;10(1):100–107.
32. Mehta MR. Cortico-hippocampal interaction during up-down states and memory consolidation. Nat Neurosci. 2007;10(1):13–15.
33. Sasaki Y, Nanez JE, Watanabe T. Advances in visual perceptual learning and plasticity. Nat Rev Neurosci. 2010;11(1):53–60.
34. Buzsáki G, Silva FL. High frequency oscillations in the intact brain. Prog Neurobiol. 2012;98(3):241–249.
35. Werner JS, Perlmutter M. Development of visual memory in infants. Adv Child Dev Behav. 1979;14:1–56.
36. Toornstra A, Hurks PPM, Van der Elst W, Kok G, Curfs LMG. Measuring visual, spatial, and visual spatial short-term memory in schoolchildren: studying the influence of demographic factors and regression-based normative data. Journal of Pediatric Neuropsychology. 2019;5:119–131.
37. Kitazawa Y, Sonoda M, Sakakura K, et al. Intra- and inter-hemispheric network dynamics supporting object recognition and speech production. Neuroimage. 2023;270:119954.
38. Ono H, Sonoda M, Sakakura K, et al. Dynamic cortical and tractography atlases of proactive and reactive alpha and high-gamma activities. Brain Commun. 2023 https://doi.org/10.1093/braincomms/fcad111
39. Buonomano DV, Merzenich MM. Cortical plasticity: from synapses to maps. Annu Rev Neurosci. 1998;21:149–186.
40. Singer W. The role of oscillations and synchrony in the development of the nervous system. In: Benasich AA, Ribary U, Lupp J, eds. *Emergent Brain Dynamics. Prebirth to Adolescence. Strungmann*

Forum Reports. MIT Press; 2018:15–32.

41. Sonoda M, Silverstein BH, Jeong JW, et al. Six-dimensional dynamic tractography atlas of language connectivity in the developing brain. Brain. 2021;144(11):3340–3354.
42. Asato MR, Terwilliger R, Woo J, Luna B. White matter development in adolescence: a DTI study. Cereb Cortex. 2010;20(9):2122–2131.
43. Lebel C, Deoni S. The development of brain white matter microstructure. Neuroimage. 2018;182:207–218.
44. Baum GL, Flournoy JC, Glasser MF, et al. Graded Variation in T1w/T2w Ratio during Adolescence: Measurement, Caveats, and Implications for Development of Cortical Myelin. J Neurosci. 2022;42(29):5681–5694.
45. Davis KA, Devries SP, Krieger A, et al. The effect of increased intracranial EEG sampling rates in clinical practice. Clin Neurophysiol. 2018;129(2):360–367.
46. Bagshaw AP, Jacobs J, LeVan P, Dubeau F, Gotman J. Effect of sleep stage on interictal high-frequency oscillations recorded from depth macroelectrodes in patients with focal epilepsy. Epilepsia. 2009;50(4):617–628.
47. Asano E, Juhász C, Shah A, Sood S, Chugani HT. Role of subdural electrocorticography in prediction of long-term seizure outcome in epilepsy surgery. Brain. 2009;132(Pt 4):1038–1047.
48. van Klink NEC, Zweiphenning WJEM, Ferrier CH, et al. Can we use intraoperative high-frequency oscillations to guide tumor-related epilepsy surgery?. Epilepsia. 2021;62(4):997–1004.
49. Nariai H, Nagasawa T, Juhász C, Sood S, Chugani HT, Asano E. Statistical mapping of ictal high-frequency oscillations in epileptic spasms. Epilepsia. 2011;52(1):63–74.
50. Guth TA, Kunz L, Brandt A, et al. Interictal spikes with and without high-frequency oscillation have different single-neuron correlates. Brain. 2021;144(10):3078–3088.
51. Dimakopoulos V, Gotman J, Stacey W, et al. Protocol for multicentre comparison of interictal high-frequency oscillations as a predictor of seizure freedom. Brain Commun. 2022;4(3):fcac151.
52. Nakai Y, Jeong JW, Brown EC, et al. Three- and four-dimensional mapping of speech and language in patients with epilepsy. Brain. 2017;140(5):1351–1370.
53. Desikan RS, Ségonne F, Fischl B, et al. An automated labeling system for subdividing the human cerebral cortex on MRI scans into gyral based regions of interest. Neuroimage. 2006;31(3):968–980.
54. Ghosh SS, Kakunoori S, Augustinack J, et al. Evaluating the validity of volume-based and surface-based brain image registration for developmental cognitive neuroscience studies in children 4 to 11 years of age. Neuroimage. 2010;53(1):85–93.
55. Deoni SC, Dean DC 3rd, Remer J, Dirks H, O'Muircheartaigh J. Cortical maturation and myelination in healthy toddlers and young children. Neuroimage. 2015;115:147–161.
56. Croteau-Chonka EC, Dean DC 3rd, Remer J, Dirks H, O'Muircheartaigh J, Deoni SCL. Examining the relationships between cortical maturation and white matter myelination throughout early childhood. Neuroimage. 2016;125:413–421.

57. Remer J, Croteau-Chonka E, Dean DC 3rd, et al. Quantifying cortical development in typically developing toddlers and young children, 1–6 years of age. Neuroimage. 2017;153:246–261.
58. Zöllei L, Iglesias JE, Ou Y, Grant PE, Fischl B. Infant FreeSurfer: An automated segmentation and surface extraction pipeline for T1-weighted neuroimaging data of infants 0–2 years. Neuroimage. 2020;218:116946.
59. Stolk A, Griffin S, van der Meij R, et al. Integrated analysis of anatomical and electrophysiological human intracranial data. Nat Protoc. 2018;13(7):1699–1723.
60. Pieters TA, Conner CR, Tandon N. Recursive grid partitioning on a cortical surface model: an optimized technique for the localization of implanted subdural electrodes. J Neurosurg. 2013;118(5):1086–1097.
61. Sonoda M, Rothermel R, Carlson A, et al. Naming-related spectral responses predict neuropsychological outcome after epilepsy surgery. Brain. 2022;145(2):517–530.
62. Navarrete M, Alvarado-Rojas C, Le Van Quyen M, Valderrama M. RIPPLELAB: A Comprehensive Application for the Detection, Analysis and Classification of High Frequency Oscillations in Electroencephalographic Signals. PLoS One. 2016;11(6):e0158276.
63. Kwan P, Brodie MJ. Neuropsychological effects of epilepsy and antiepileptic drugs. Lancet. 2001;357(9251):216–222.
64. Yeh FC, Panesar S, Fernandes D, et al. Population-averaged atlas of the macroscale human structural connectome and its network topology. Neuroimage. 2018;178:57–68.
65. Mitsuhashi T, Sonoda M, Sakakura K, et al. Dynamic tractography-based localization of spike sources and animation of spike propagations. Epilepsia. 2021;62(10):2372–2384.
66. Mitsuhashi T, Sonoda M, Firestone E, et al. Temporally and functionally distinct large-scale brain network dynamics supporting task switching. Neuroimage. 2022;254:119126.
67. Zweiphenning WJEM, von Ellenrieder N, Dubeau F, et al. Correcting for physiological ripples improves epileptic focus identification and outcome prediction. Epilepsia. 2022;63(2):483–496.
68. Baynes K, Eliassen JC, Lutsep HL, Gazzaniga MS. Modular organization of cognitive systems masked by interhemispheric integration. Science. 1998;280(5365):902–905.
69. Schulte T, Müller-Oehring EM. Contribution of callosal connections to the interhemispheric integration of visuomotor and cognitive processes. Neuropsychol Rev. 2010;20(2):174–190. doi:10.1007/s11065-010-9130-1
70. Yeatman JD, Weiner KS, Pestilli F, Rokem A, Mezer A, Wandell BA. The vertical occipital fasciculus: a century of controversy resolved by in vivo measurements. Proc Natl Acad Sci U S A. 2014;111(48):E5214-E5223.
71. Herbet G, Zemmoura I, Duffau H. Functional Anatomy of the Inferior Longitudinal Fasciculus: From Historical Reports to Current Hypotheses. Front Neuroanat. 2018;12:77.
72. Malik A, Eldaly ABM, Agadagba SK, et al. Neuromodulation in the developing visual cortex after long-term monocular deprivation [published online ahead of print, 2022 Nov 17]. Cereb Cortex.

2022;bhac448.
73. Roehri N, Pizzo F, Lagarde S, et al. High-frequency oscillations are not better biomarkers of epileptogenic tissues than spikes. Ann Neurol. 2018;83(1):84–97.
74. Ball T, Kern M, Mutschler I, Aertsen A, Schulze-Bonhage A. Signal quality of simultaneously recorded invasive and non-invasive EEG. Neuroimage. 2009;46(3):708–716.

Figures

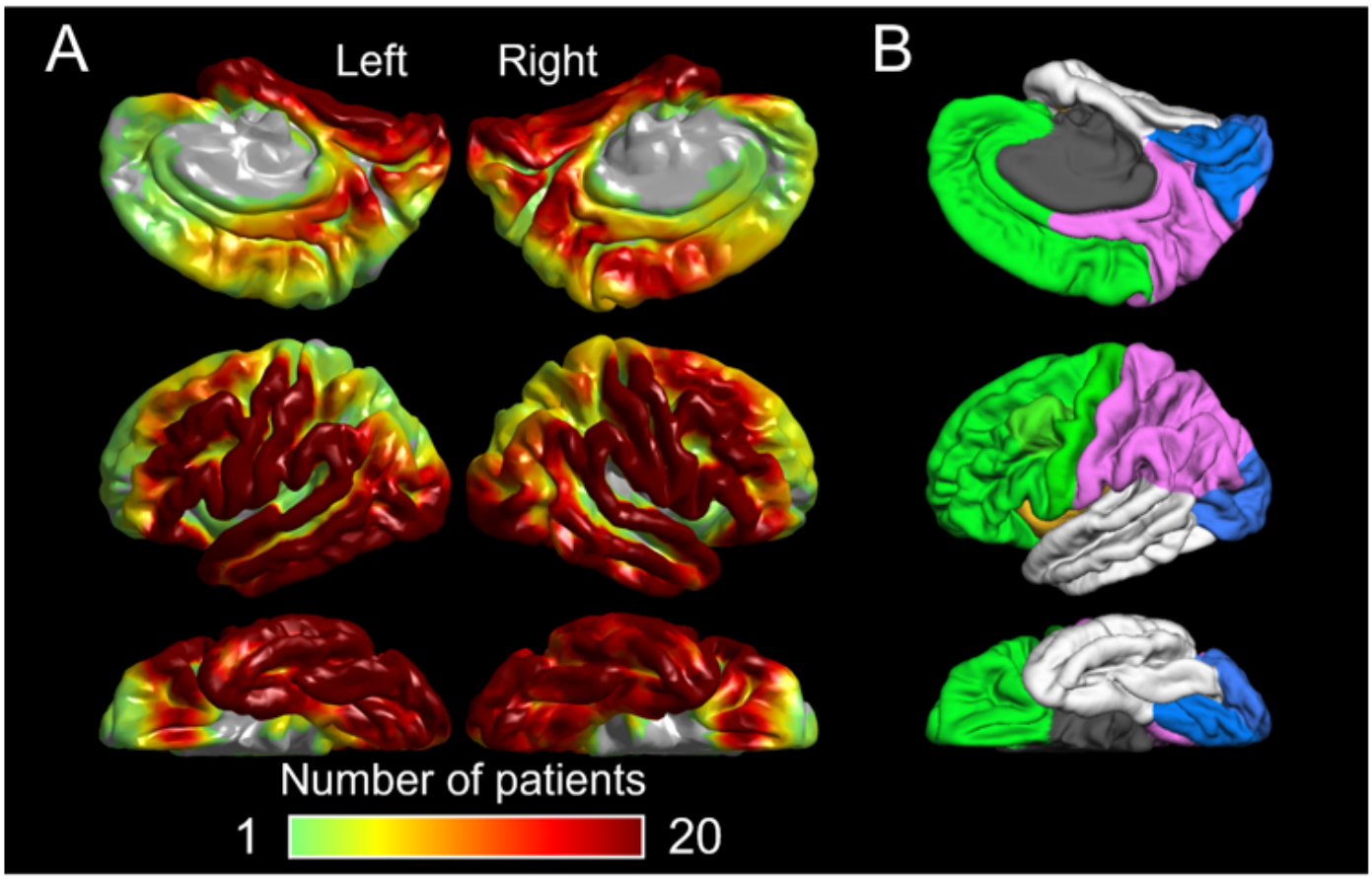

Figure 1

Spatial distribution of intracranial electrode sampling. (A) The figure shows the number of patients whose artifact-free, nonepileptic intracranial EEG data were available at each cortical site. (B) The cerebral cortex was divided into four lobes using FreeSurfer (https://surfer.nmr.mgh.harvard.edu/fswiki/CorticalParcellation; Desikan et al., 2006). Green represents the frontal lobe, white represents the temporal lobe, pink represents the parietal lobe, and blue represents the occipital lobe.

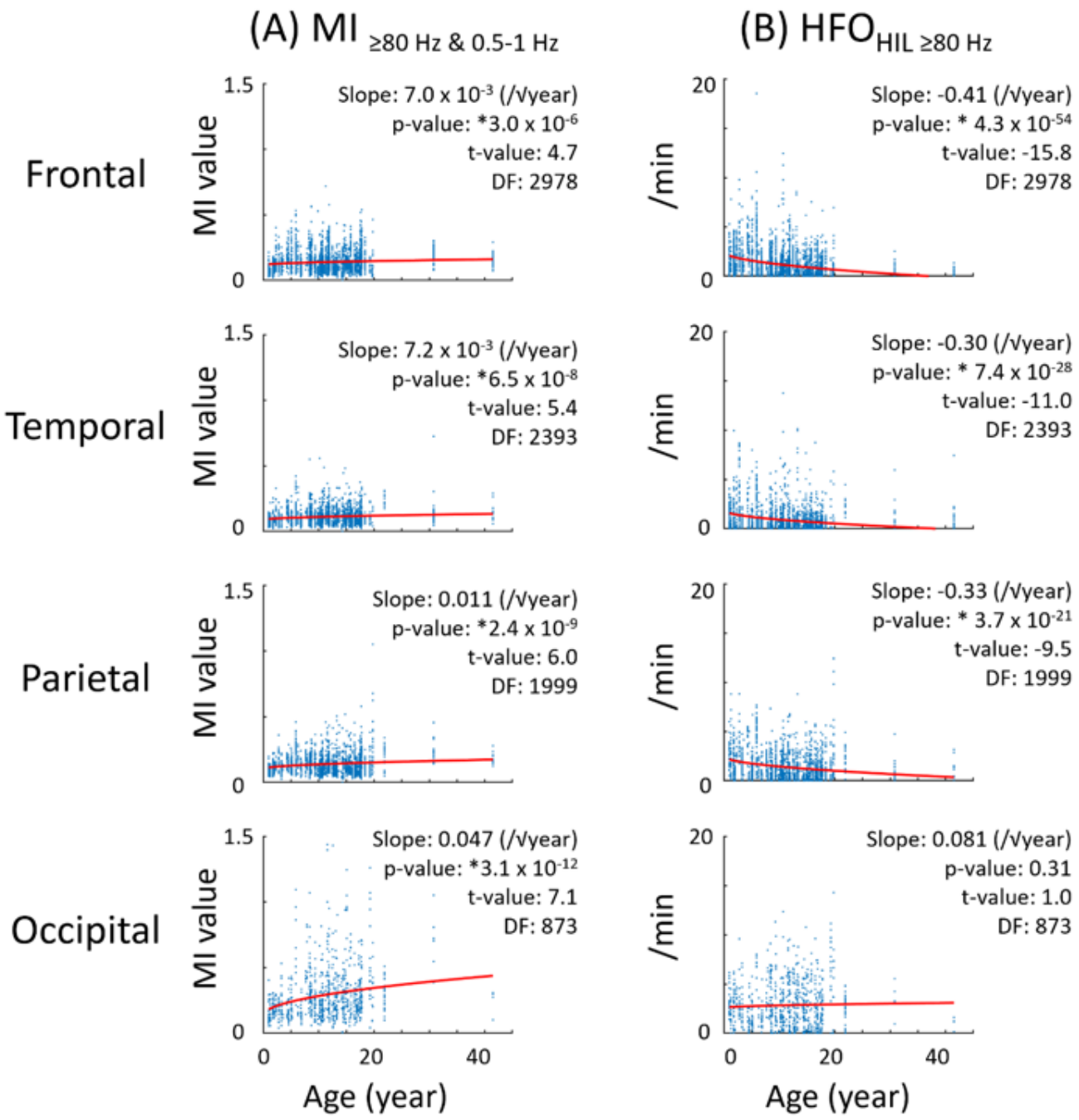

Figure 2

The developmental changes of cortical MI and HFO at given lobes. (A) $MI_{\geq 80\ Hz\ \&\ 0.5\text{-}1\ Hz}$ and (B) $HFO_{HIL\ \geq 80\ Hz}$ occurrence rate (/min). In each dot plot, a regression line is depicted based on a statistical model that incorporates the square root of age (√age) as an independent variable. MI: modulation index. $MI_{\geq 80\ Hz\ and\ 0.5\text{-}1\ Hz}$ denotes the strength of coupling between the amplitude of $HFO_{\geq 80\ Hz}$ and the phase of slow-$wave_{0.5\text{-}1\ Hz}$. HFO_{HIL}: high-frequency oscillation defined by Crépon et al., 2010.

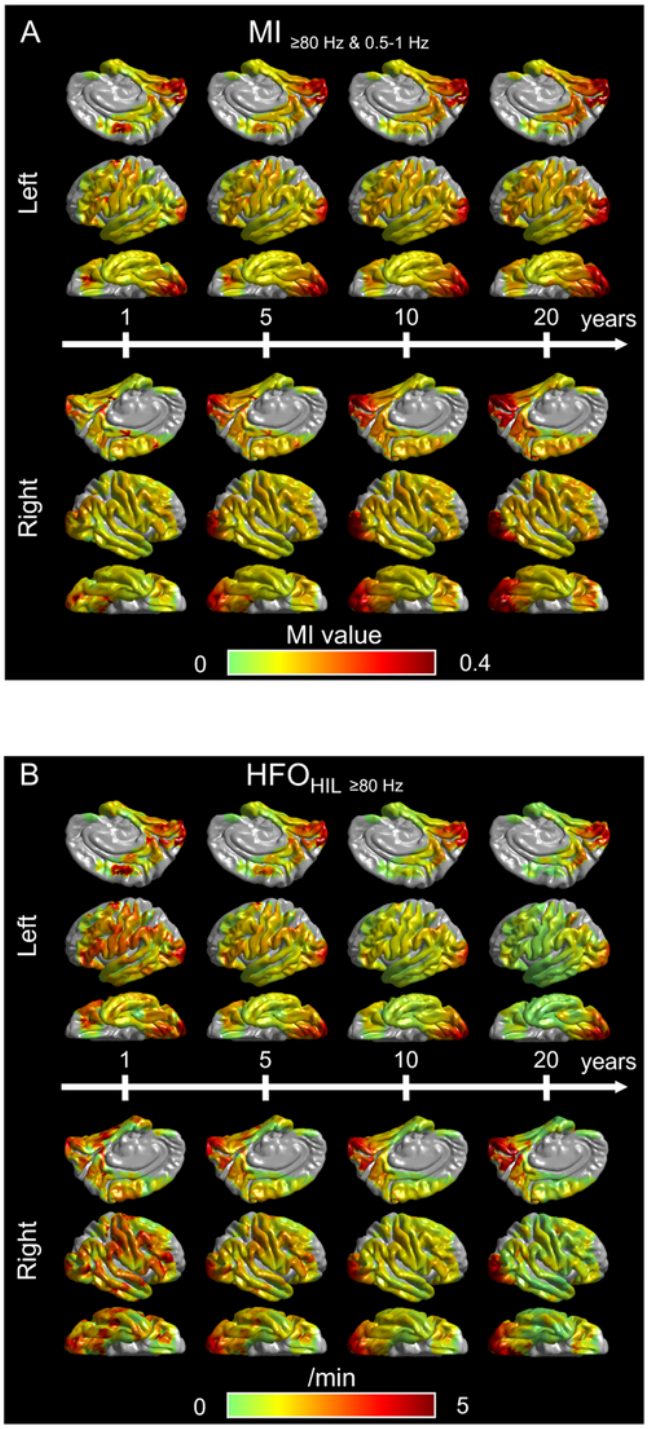

Figure 3

Snapshots of the developmental atlases of cortical MI and HFO. (A) Model-predicted $MI_{\geq 80\ Hz\ \&\ 0.5\text{-}1\ Hz}$ and (B) $HFO_{HIL\ \geq 80\ Hz}$ occurrence rate. Each snapshot presents model-predicted values at ages 1, 5, 10, and 20 years. MI: modulation index. $MI_{\geq 80\ Hz\ and\ 0.5\text{-}1\ Hz}$ denotes the strength of coupling between the amplitude of $HFO_{\geq 80\ Hz}$ and the phase of slow-wave$_{0.5\text{-}1\ Hz}$. HFO_{HIL}: high-frequency oscillation defined by

Crépon et al., 2010. Videos S1-S3 present the longitudinal values spanning from 1 to 21 years of age across multiple generations.

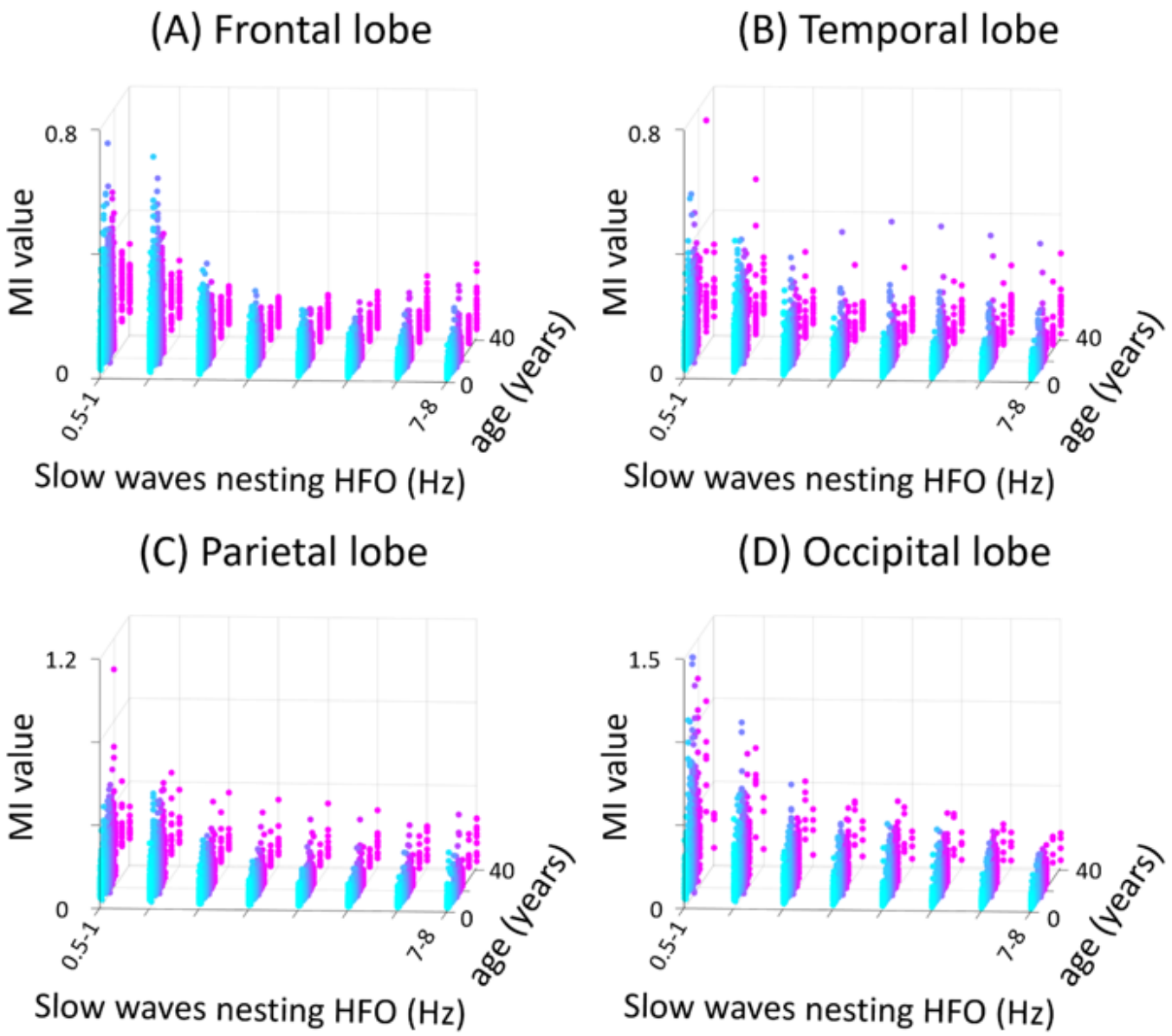

Figure 4

Effect of slow-wave spectral frequency bands on modulation index (MI). (A) frontal lobe. (B) Temporal lobe. (C) Parietal lobe. (D) Occipital lobe. $MI_{\geq 80\ Hz\ and\ s\ Hz}$ denotes the strength of coupling between the amplitude of $HFO_{\geq 80\ Hz}$ and the phase of slow-$wave_{s\ Hz}$. $MI_{\geq 80\ Hz\ \&\ s\ Hz}$ at a given electrode site is plotted as a function of *s* being 0.5-1, 1-2, 2-3, 3-4, 4-5, 5-6, 6-7, or 7-8 Hz. Light blue dots: younger individuals. Magenta dots: older individuals.

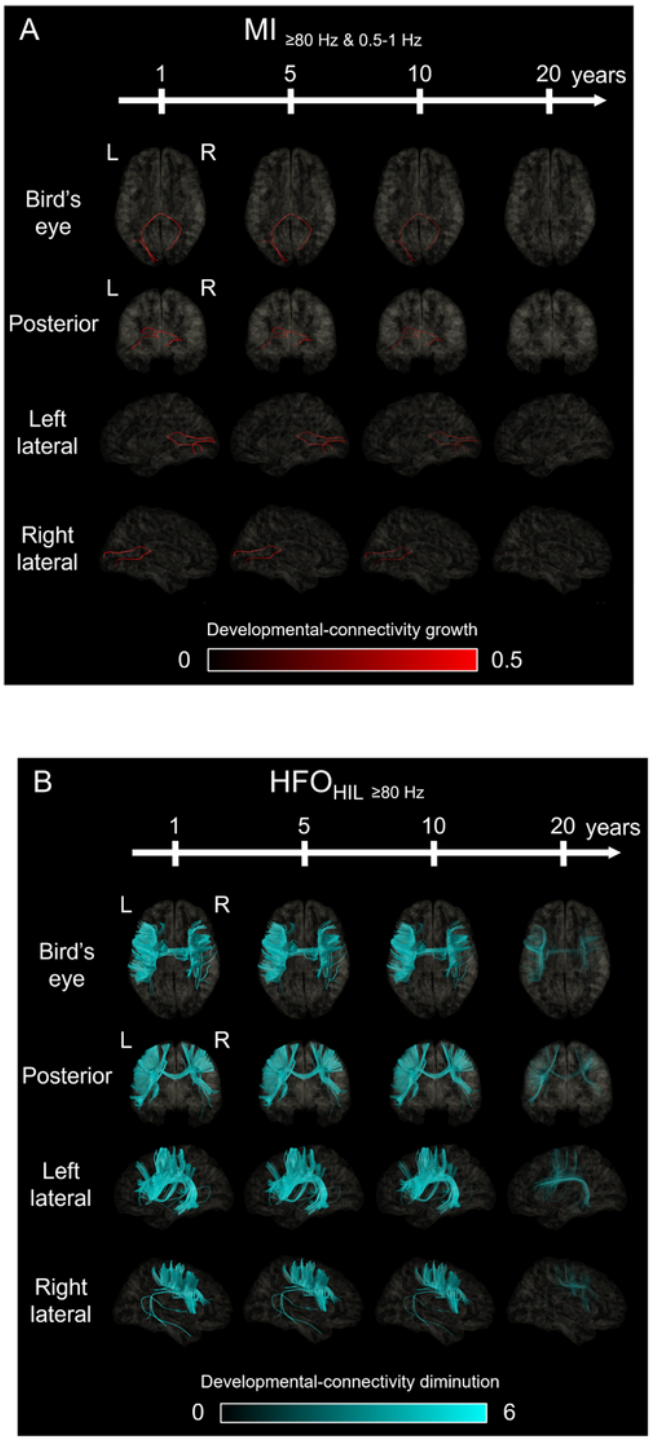

Figure 5

Dynamic tractography. The video snapshots present the varying intensity of (A) co-growth of $MI_{\geq 80\ Hz\ \&\ 0.5\text{-}1\ Hz}$ and (B) co-diminution of $HFO_{HIL\geq 80\ Hz}$ at ages 1, 5, 10, and 20 years, as estimated by univariate regression analysis incorporating √age as an independent variable. Videos S4-S5 show the data across generations from 1 to 21 years.

Supplementary Files

This is a list of supplementary files associated with this preprint. Click to download.

- HFOsakakuradevelopmentsupplementarydocumentea7ks5.docx
- nreditorialpolicychecklistks1.pdf
- nrreportingsummaryks2ea1.pdf
- NCOMMS2315354rs.pdf
- VideoS1MI800.5ks2.mp4
- VideoS2MI803ks1.mp4
- VideoS3HIL80ks2.mp4
- VideoS4MI800.5tractks1.mp4
- VideoS5HIL80tractks3.mp4
- nrreportingsummaryea2.pdf