USMLE STEP 1 SAMPLE TEST QUESTIONS

BLOCK 1, ITEMS 1-40

1. A 14-year-old boy is brought to the emergency department by his parents because of a 1-month history of intermittent right knee pain that has worsened during the past day. He rates his current pain as a 6 on a 10-point scale and says that it worsens when he walks and lessens when he sits. During the past 2 weeks, he has been walking 1 mile daily in preparation for participation in the school marching band. He has not taken any medications for his pain. He sustained a right tibia and fibula fracture at the age of 8 years after a skateboarding accident, which was treated with internal fixation and casting. He has asthma treated with inhaled budesonide daily and inhaled albuterol as needed. His mother has type 2 diabetes mellitus, and his maternal grandmother has osteoporosis. The patient is 170 cm (5 ft 7 in; 77th percentile) tall and weighs 88 kg (195 lb; >95th percentile); BMI is 31 kg/m^2 (98th percentile). Temperature is 37.0°C (98.6°F), pulse is 95/min, and blood pressure is 130/80 mm Hg. Physical examination shows hyperpigmented, thickened skin at the nape of the neck. There is tenderness to palpation of the anterior aspect of the right hip and limited range of motion on abduction, internal rotation, and flexion of the right hip. The left hip and knees are nontender; range of motion is full in all directions. The remainder of the examination discloses no abnormalities. Which of the following factors in this patient's history most increased his risk for developing this condition?

(A) BMI
(B) Family history
(C) Medication use
(D) Previous fractures
(E) Recent physical activity

2. A 14-year-old girl is brought to the office by her mother because of a 3-month history of red bumps on her skin. The patient says the bumps are not itchy or painful but that she finds them embarrassing. She has no history of major medical illness and takes no medications. Her vital signs are within normal limits. Physical examination shows the findings in the photograph. Which of the following is the most likely diagnosis?

(A) Eczema
(B) Folliculitis
(C) Hidradenitis
(D) Keratosis pilaris
(E) Urticaria

---

3. A 50-year-old man comes to the office because of a 2-month history of increasing daytime somnolence. He has obstructive sleep apnea for which he has only intermittently used a continuous positive airway pressure device. He is 170 cm (5 ft 7 in) tall and weighs 181 kg (400 lb); BMI is 63 kg/m^2. His temperature is 37°C (98.6°F), pulse is 100/min, respirations are 12/min, and blood pressure is 135/80 mm Hg. Physical examination shows a gray-blue tinge to the lips, earlobes, and nail beds. Cardiac examination shows no other abnormalities. Arterial blood gas analysis on room air shows a pH of 7.31, P_{CO_2} of 70 mm Hg, and P_{O_2} of 50 mm Hg. Which of the following additional findings would be most likely in this patient?

(A) Decreased serum bicarbonate concentration
(B) Increased hemoglobin concentration
(C) Increased total lung capacity
(D) Left ventricular hypertrophy

4. A 32-year-old man comes to the office because of a 1-day history of cough productive of small amounts of blood and a 2-day history of shortness of breath and swelling of his ankles. He also has a 2-week history of progressive fatigue and episodes of dark urine. He has no history of major medical illness and takes no medications. His temperature is 37°C (98.6°F), pulse is 90/min, respirations are 18/min, and blood pressure is 175/110 mm Hg. Pulse oximetry on room air shows an oxygen saturation of 91%. Diffuse inspiratory crackles are heard over all lung bases. There is 2+ pitting edema of both ankles. Results of laboratory studies are shown:

Hemoglobin	8.9 g/dL
Hematocrit	27%
Serum	
Urea nitrogen	55 mg/dL
Creatinine	2.9 mg/dL
Urine RBC	20–40/hpf

Urinalysis also shows some dysmorphic RBCs and rare RBC casts. Examination of a kidney biopsy specimen shows crescentic glomerulonephritis and linear deposition of IgG along the glomerular capillaries. This patient most likely has antibodies directed against which of the following antigens?

(A) Collagen
(B) Double-stranded DNA
(C) Nucleolar protein
(D) Phospholipid
(E) Proteins in neutrophil cytoplasm

---

5. A 5-year-old girl is brought to the emergency department because of a 2-day history of fever, urinary urgency, and burning pain with urination. She has had four similar episodes during the past year. A diagnosis of urinary tract infection is made. Subsequent renal ultrasonography shows one large U-shaped kidney. Which of the following is the most likely embryologic origin of this patient's condition?

(A) Failure of the kidneys to rotate 90 degrees medially
(B) Failure of normal kidney ascent
(C) Failure of one ureteric bud to develop normally
(D) Fusion of the inferior poles of the metanephros during ascent

6. A 78-year-old man comes to the office for a follow-up examination. He was discharged from the hospital 1 week ago after being treated for a nontuberculous mycobacterial infection. He started treatment with ciprofloxacin and rifampin at that time. He also has hypertension and underwent placement of a mechanical aortic valve 6 years ago for aortic stenosis. Other current medications are hydrochlorothiazide, lisinopril, and warfarin. His warfarin dose was doubled 4 days ago. He says that he is trying to follow a healthier diet. He drinks two 12-oz beers daily. Results of laboratory studies done 4 days ago and today are shown

	4 Days Ago	**Today**
Prothrombin time	11 sec (INR=1)	11.2 sec (INR=1.1)
Partial thromboplastin time	29 sec	27 sec

Which of the following is the most likely cause of this patient's laboratory findings?

(A) Decreased protein binding
(B) Eradication of gut flora
(C) Increased alcohol intake
(D) Increased vegetable consumption
(E) Induction of cytochrome enzymes

---

7. A 32-year-old man comes to the office because of a 2-week history of fever and throat pain. He is 173 cm (5 ft 8 in) tall and weighs 63 kg (140 lb); BMI is 21 kg/m^2. His pulse is 110/min, respirations are 16/min, and blood pressure is 98/68 mm Hg. Physical examination shows scattered 2- to 4-cm lymph nodes in the neck, axillae, and inguinal regions. There is a bilateral tonsillar exudate but no ulcerations. Results of laboratory studies are shown:

Hemoglobin	9.6 g/dL
Hematocrit	29%
Leukocyte count	1500/mm^3
Platelet count	60,000/mm^3

A heterophile antibody test result is negative. Which of the following is the most likely diagnosis?

(A) Epstein-Barr virus infection
(B) Gonococcal pharyngitis
(C) HIV infection
(D) Lymphogranuloma venereum infection
(E) Streptococcal pharyngitis

---

8. A 50-year-old man comes to the office for a follow-up examination. He has a 2-month history of headache and shortness of breath with exertion. He also has hypertension treated with hydrochlorothiazide for the past 2 years. His blood pressure is 180/105 mm Hg. Ophthalmoscopic examination is most likely to show which of the following in this patient?

(A) Arteriovenous nicking
(B) Melanocytes in the uvea
(C) Optic neuritis
(D) Posterior subcapsular cataracts
(E) Tractional retinal detachment

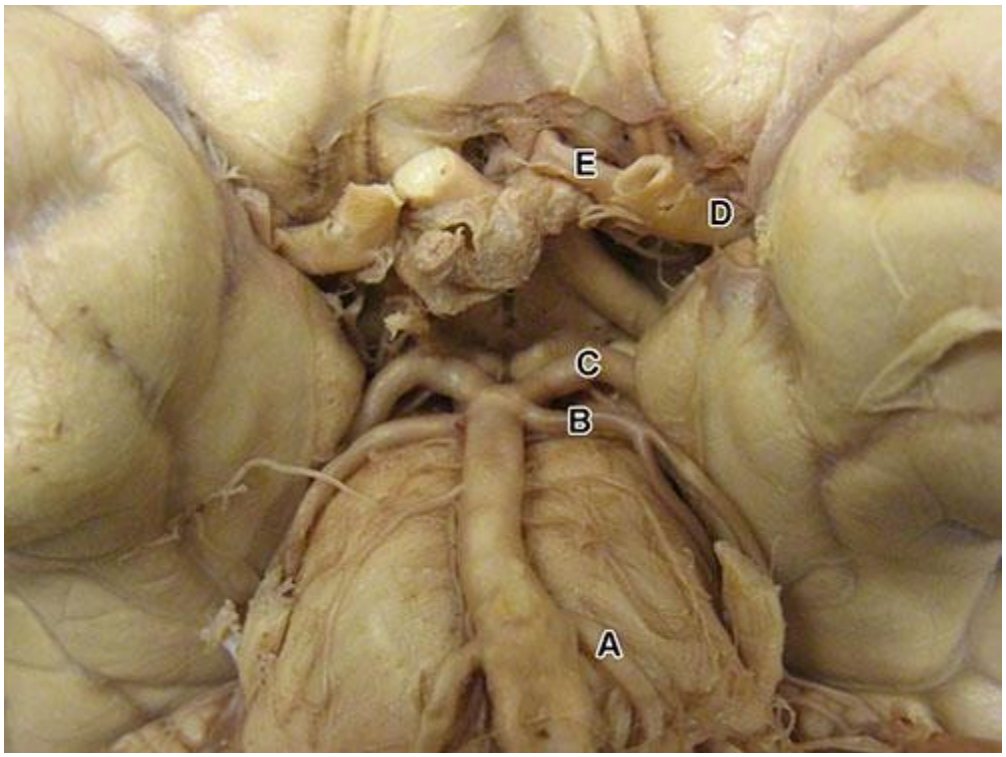

9. A 65-year-old woman with a history of rheumatic mitral valve disease is brought to the emergency department 30 minutes after the sudden onset of right-sided weakness and inability to speak. Neurologic examination shows weakness of the right lower side of the face and difficulty swallowing. Muscle strength is 3/5 on the right side. She can understand what is said to her, but she cannot repeat words or answer questions. An ECG shows atrial fibrillation. The most likely cause of the neurologic findings in this patient is occlusion of which of the following labeled arteries in the photograph of a normal brain?

(A) A
(B) B
(C) C
(D) D
(E) E

---

10. A 51-year-old man with a 10-year history of gastroesophageal reflux and suspected Barrett esophagus comes to the office because his omeprazole dose "doesn't work around the Christmas holidays." He states that he prides himself on having a large appetite and "holding his liquor" during the holidays. He currently takes the maximum dose of omeprazole. Which of the following is the most appropriate initial action by the physician?

(A) Ask the patient how much he is eating and drinking during the holidays
(B) Explain the hazards of untreated reflux in the presence of Barrett esophagus
(C) Order an upper endoscopy
(D) Refer the patient to a gastroenterologist
(E) Switch the omeprazole to pantoprazole