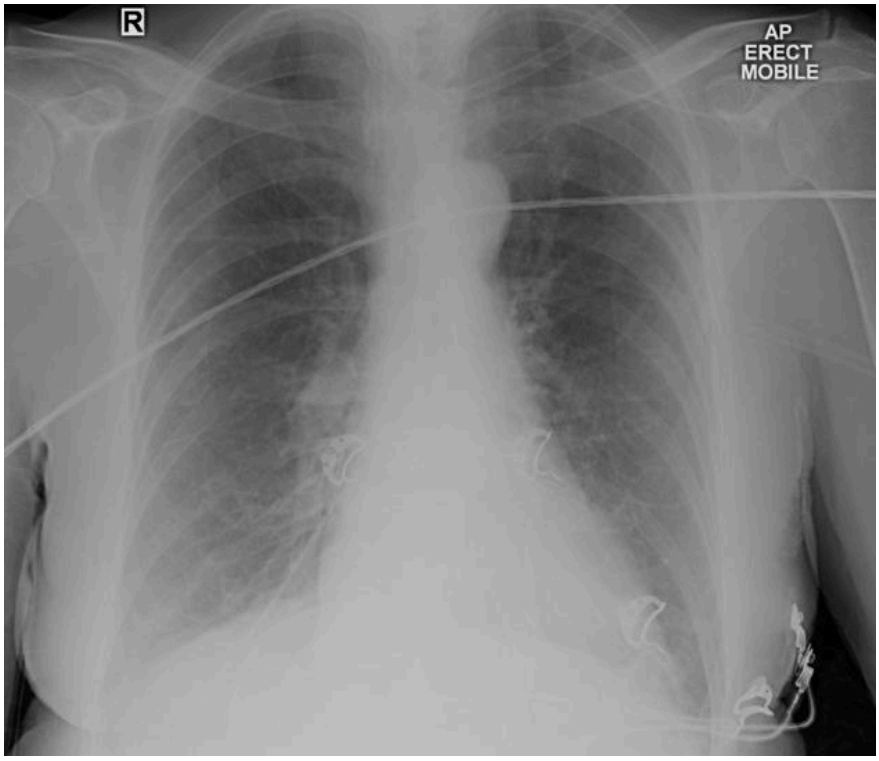

EXAM: PORTABLE XR CHEST 1 VIEW

CLINICAL INDICATION: Acute hypoxic respiratory failure

TECHNIQUE: A single view of the chest was obtained

COMPARISON: None prior

IMPRESSION:

- **Postsurgical Changes/Catheters and Support Devices:** None appreciated.
- **Lungs/Pleural Spaces:** Diffuse vascular congestion. Bilateral pleural effusions. No focal consolidation or pneumothorax.
- **Heart/Mediastinum:** Within normal limits.
- **Other:** No other significant findings.
- **Summary:** Congested X-ray as above.

Electronic access to images is available to referring providers online.

FINAL RESULT BY: SUPER MAN, MD
DICTATED: 11/8/2025 8:32 AM