148 Grafts

Désirée Ratner and Priya Mahindra Nayyar

Chapter Contents

Wound Healing Considerations 2556
Full-Thickness Skin Grafts 2557
Split-Thickness Skin Grafts 2561
Composite Grafts 2565
Free Cartilage Grafts 2566

Key features

- Free skin grafts are pieces of skin that have been severed from their local blood supply and transferred to another location
- Grafts for soft tissue reconstruction can be divided into four types: full-thickness skin grafts, split-thickness skin grafts, composite grafts, and free cartilage grafts
- In dermatologic surgery, grafts are most commonly used to repair defects created after removal of skin cancers; grafts also provide coverage and more rapid healing of leg ulcers
- The clinical situation determines the type of graft to be placed
- A working knowledge of the indications, techniques, donor site considerations, postoperative care, and postoperative complications of all types of skin grafting is essential for optimal soft tissue reconstruction

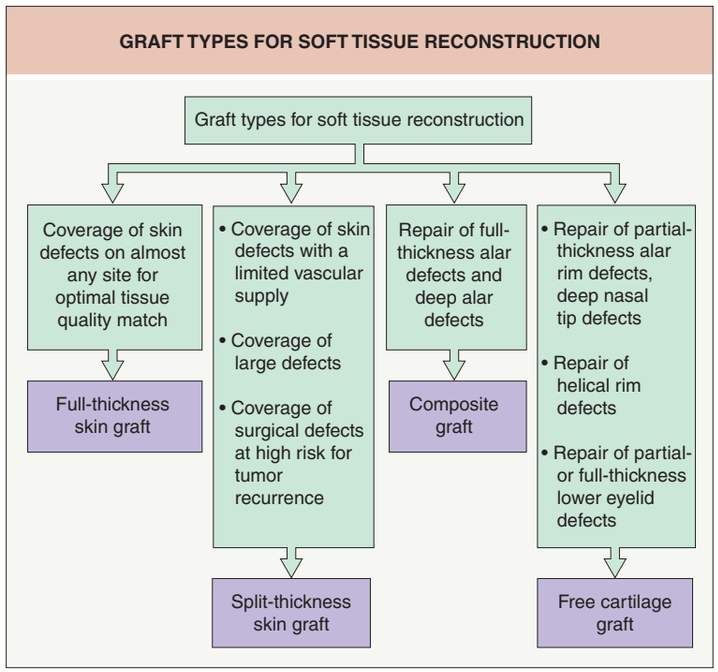

Fig. 148.1 Graft types for soft tissue reconstruction.

INTRODUCTION AND BACKGROUND

Skin grafting procedures originated approximately 2500 to 3000 years ago, when surgeons of the Hindu Tilemaker caste replaced noses amputated as punishment for theft and adultery with skin grafts harvested from the gluteal region[1]. It was not until the nineteenth century that skin grafting was reintroduced. In 1869, Reverdin's account of pinch grafting for leg ulcers was published; in subsequent decades, Ollier and Thiersch's accounts of thin split-thickness skin grafting, and Wolfe and Krause's accounts of full-thickness skin grafting, appeared in the literature. While these and other nineteenth-century surgeons used skin grafts to address only the most difficult problems of surgical management, skin grafting has since evolved into a reconstructive option that is routinely, and sometimes preferentially, used for the surgical repair of skin defects.

Free skin grafts are pieces of skin which have been severed from their blood supply and transferred to another location. They can be divided into four types: full-thickness skin grafts (FTSGs), split-thickness skin grafts (STSGs), composite grafts, and free cartilage grafts (Fig. 148.1; Tables 148.1 and 148.2)[2,3]. FTSGs are composed of the entire epidermis and the full thickness of dermis, including adnexal structures such as hair follicles and sweat glands. STSGs are composed of the full thickness of the epidermis and partial thickness of dermis. These can be subdivided into thin, medium, and thick grafts, depending on the amount of dermis included in the graft. Composite grafts are composed of at least two different tissue types, usually skin and cartilage. Free cartilage grafts consist of cartilage with its overlying perichondrium.

WOUND HEALING CONSIDERATIONS

Wound healing after skin grafting proceeds through a unique series of events[2,4]. The first 24-hour period following graft placement is termed the stage of plasmatic imbibition, during which fibrin glue attaches the graft to its recipient bed, allowing it to take up the underlying wound exudate and to become edematous, gaining up to 40% in weight. The graft thereby remains hydrated and obtains a supply of nutrients, which maintains graft vessel patency until revascularization begins. The fibrin beneath the graft is subsequently replaced by granulation tissue, which attaches the graft permanently to its bed.

With proper apposition of the graft to its bed, revascularization may proceed. Anastomoses begin to form within 48–72 hours of grafting between the recipient bed and pre-existing vessels in the dermis of the graft, a process known as inosculation. Vascular proliferation occurs next, with sprouting and budding of vessels in the graft and its bed. Even relatively avascular tissue may be grafted, as long as the avascular area is small and surrounded by a rich vascular supply. Through a process known as the bridging phenomenon, vascular connections arising from the vascularized part of the recipient bed allow blood flow to occur through pre-existing graft vasculature, so that nutrients reach the part of the graft overlying the avascular area. Full circulation is restored to the graft within 4–7 days.

Restoration of the lymphatic circulation parallels restoration of the blood supply over the first week. Epidermal proliferation occurs between the 4th and 8th day post-transplant and persists for several weeks. Degeneration of sebaceous and eccrine glands may occur initially, but subsequent glandular regeneration may allow partial function to be maintained. Graft reinnervation and return of sensory nerve function may begin as early as 2–4 weeks after grafting, although patients do not usually regain full sensation for many months.

If extension of the ischemic period occurs, decreased graft survival may result (Table 148.3). Hematoma or seroma formation, infection, or mechanical shear forces may disrupt the fragile vascular connections between the graft and its bed. These complications tend to affect FTSGs (which have a greater volume to nourish and revitalize) more than STSGs.

Downloaded for Anonymous User (n/a) at Egyptian Knowledge Bank from ClinicalKey.com by Elsevier on March 10, 2024. For personal use only. No other uses without permission. Copyright ©2024. Elsevier Inc. All rights reserved.

COMPARISON OF GRAFT TYPES USED IN SOFT TISSUE RECONSTRUCTION								
Graft type	**Tissue match**	**Nutritional requirements**	**Requirement for recipient bed vascularity**	**Infection risk**	**Graft contraction risk**	**Durability**	**Sensation**	**Adnexal functions**
FTSG	Good to excellent	High	High	Low	Low	Good to excellent	Good	Excellent
STSG	Poor to fair	Low	Low	Low	High	Fair to good	Fair	Poor
Composite	Good	High	Very high	Moderate	Low	Fair	Fair	Good
Free cartilage	NA	Moderate	High	Moderate	Migration or deformation possible, with subsequent resorption	Good	NA	NA

Table 148.1 Comparison of graft types used in soft tissue reconstruction. FTSG, full-thickness skin graft; NA, not available; STSG, split-thickness skin graft.

INDICATIONS, CONTRAINDICATIONS, ADVANTAGES, AND DISADVANTAGES OF GRAFT TYPES USED IN SOFT TISSUE RECONSTRUCTION				
Graft type	**Indications**	**Contraindications**	**Advantages**	**Disadvantages**
Full-thickness skin graft (FTSG)	Coverage of skin defects, usually located on the face or scalp, requiring an optimal tissue quality match	Avascular graft bed	Excellent color and texture match Minimal graft contraction	Time consuming Donor site requires closure Requires meticulous technique
Split-thickness skin graft (STSG)	Coverage of large defects and defects with a limited vascular supply or at sites at high risk for tumor recurrence	Defects near free margins Facial defects in cosmetically sensitive areas	Increased chance of survival Ease of application Ability to cover large defects Able to act as a "window" to detect recurrence of high-risk tumors	Suboptimal cosmetic appearance Decreased durability Presence of granulating donor site wound Greater graft contraction Special equipment required to harvest larger grafts
Perichondrial cutaneous graft	Repair of deep nasal tip and alar defects, especially those with exposed cartilage	Avascular graft bed	Thicker than FTSG Contract less than FTSG Increased chance of survival under conditions of vascular compromise (compared to FTSG)	
Composite graft	Repair of full-thickness alar defects or nasal tip defects (<2 cm in diameter) with cartilage loss	Defects >2 cm in diameter	Single-stage procedure May yield good functional and aesthetic results when used to repair appropriately sized defects	Greater risk of graft failure under conditions of vascular compromise Graft size limitations (<2 cm) Limited donor tissue available Donor site may require flap or complex closure Increased risk of infection and graft displacement
Free cartilage graft	Repair of defects of nasal ala, tip or sidewall, ear or eyelid requiring restoration of structural support or preservation of contour of free margins	None	Provide structural support for selected facial and ear defects	Donor site may be painful Increased risk of postoperative infection Increased risk of graft displacement

Table 148.2 Indications, contraindications, advantages, and disadvantages of graft types used in soft tissue reconstruction.

Even after the ischemic period is past, other factors may decrease the vascular supply nourishing the undersurface of the graft[2,3,5]. The most important of these is cigarette smoking or use of other nicotine-containing products,[5] but diabetes mellitus, protein deprivation, and severe trace element or vitamin deficiencies may also increase the risk of graft failure. Certain systemic medications, such as corticosteroids, chemotherapeutic agents, other immunosuppressive drugs and anticoagulants, may interfere with wound healing as well.

Other causes of graft failure include: insufficient vascularity due to necrotic debris within the recipient bed, hematoma, seroma, an avascular wound bed, previous radiotherapy, infection, excessive graft tension, mechanical shearing forces, and improper postoperative care (see Table 148.3)[2,3]. The most common infectious agents associated with graft failure include coagulase-positive staphylococci, β-hemolytic streptococci, and *Pseudomonas* spp. Pseudomonal infections are particularly common in auricular grafts. For all of these reasons, a thorough preoperative evaluation, meticulous intraoperative technique, and good postoperative care are essential to maximize graft survival.

FULL-THICKNESS SKIN GRAFTS

Indications/Contraindications

FTSGs are most commonly used to repair facial defects resulting from skin cancer removal. They may be used to repair defects at virtually any site, as long as the recipient bed has a sufficiently rich vascular supply to promote capillary regrowth and fibroblasts to supply collagen for graft adherence. Small avascular areas may be grafted due to the bridging phenomenon. Larger avascular areas, including patches of exposed bone, cartilage, tendon or nerve devoid of periosteum, perichondrium, peritenon or perineurium, respectively, are unable to support FTSGs. For this reason, FTSGs should not be placed over larger areas of avascular tissue.

Under the proper circumstances, FTSGs can provide excellent color, texture, and thickness match for facial defects because they include the full thickness of epidermis and dermis. Wound contraction is minimized since the full thickness of dermis is present, and adnexal structures remain intact[6]. FTSGs may be especially useful for the cosmetically and functionally acceptable repair of defects of the nasal tip, dorsum, ala and lateral sidewall, as well as the lower eyelid and ear (Fig. 148.2)[7].

Preoperative History and Donor Site Considerations

A thorough preoperative evaluation that includes questions regarding bleeding tendencies, alcohol use, use of anticoagulant medications (including aspirin and nonsteroidal anti-inflammatory drugs), and a history of hypertension can help assess the risk of excessive bleeding and clot formation beneath the graft[2,3]. Diabetes mellitus, nutritional deficiencies, cigarette smoking, or the use of other nicotine-containing

Downloaded for Anonymous User (n/a) at Egyptian Knowledge Bank from ClinicalKey.com by Elsevier on March 10, 2024. For personal use only. No other uses without permission. Copyright ©2024. Elsevier Inc. All rights reserved.

CAUSES OF GRAFT FAILURE	
Poor graft–bed contact	Hematoma
	Seroma
	Shearing forces due to excessive postoperative activity
	Shearing forces due to inadequate immobilization of graft
Poor recipient bed vascularity	Inadequate vascular bed (e.g. previous radiotherapy)
	Exposed cartilage, bone, tendon
	Nicotine-induced vasoconstriction
Infection	Coagulase-positive *Staphylococcus* spp.
	Beta-hemolytic *Streptococcus* spp.
	Pseudomonas spp.
Host factors	Diabetes mellitus
	Immunosuppression
	Poor general health
	Nutritional deficiencies, including hypoalbuminemia
	Systemic conditions with vascular compromise
Technique	Rough handling of tissue
	Excessive devitalized tissue in recipient bed due to cautery
	Increased tension on graft due to inadequate size
	Inadequate hemostasis
	Inadequate trimming of adipose layer
	Placement of upside-down graft (more common with STSG)
	Inadequate anchoring (composite and free cartilage grafts)

Table 148.3 Causes of graft failure. STSG, split-thickness skin graft.

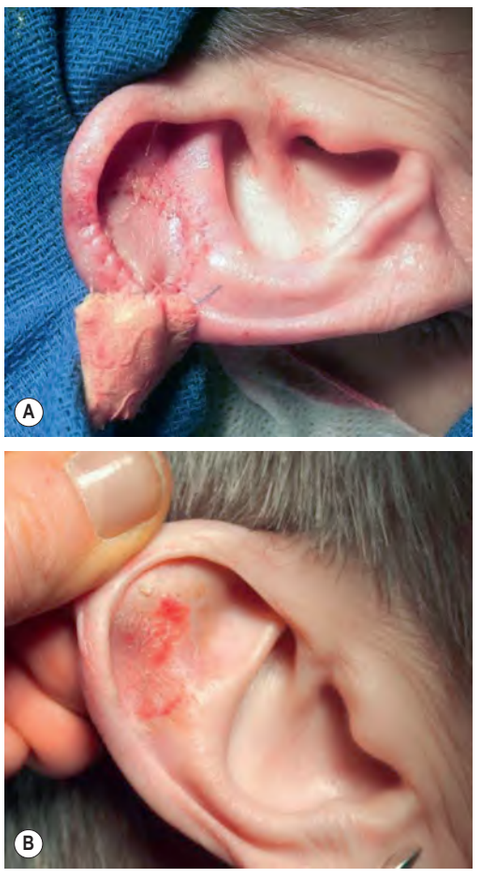

Fig. 148.2 Full-thickness skin graft. A Full-thickness skin graft taken from the preauricular region was used to repair this defect of the right upper anterior ear. **B** Eight-week postoperative result.

products may increase the risk of graft failure, and any history of these should be identified preoperatively.

Selection of a donor site for full-thickness skin grafting depends upon the color, texture, thickness, and sebaceous qualities of the skin surrounding the defect (Tables 148.4 and 148.5). Most FTSGs are taken from sun-exposed areas above the shoulders whose color, vascular pattern, texture, and distribution of adnexal structures best match the skin surrounding facial defects. The thinnest grafts are usually harvested from the upper eyelid or the postauricular sulcus. Medium-thickness grafts are often harvested from the preauricular and cervical regions, while thicker grafts may be taken from the supraclavicular or clavicular region, conchal bowl, or nasolabial fold. Donor skin thickness, irrespective of site, will vary from one patient to another. It is therefore important to examine all sites carefully to find the best possible tissue match. This approach will ensure optimal donor site selection for each individual patient and surgical defect.

DONOR SITE CONSIDERATIONS FOR FULL-THICKNESS SKIN GRAFTS	
• Pattern of sun exposure • Color • Vascular pattern • Texture • Sebaceous quality	• Skin thickness • Skin consistency • Sufficient tissue available for harvesting • Ability to camouflage donor site scar

Table 148.4 Donor site considerations for full-thickness skin grafts.

SUMMARY OF POSSIBLE FULL-THICKNESS SKIN GRAFT DONOR SITES FOR DEFECTS IN DIFFERENT LOCATIONS	
Defect sites	**Donor sites**
Nasal dorsum, sidewalls, tip	Preauricular region, supraclavicular region or lateral neck (if large)
Nasal tip, ala	Preauricular region, conchal bowl, nasolabial fold
Junction of nasal dorsum/tip	Burow's graft
Ear	Postauricular sulcus, preauricular cheek
Lower eyelid/ medial canthus	Upper eyelid, postauricular sulcus
Scalp	Supraclavicular region, lateral neck, inner upper arm
Forehead	Burow's graft, supraclavicular region, lateral neck, inner upper arm (if large)

Table 148.5 Summary of possible full-thickness skin graft donor sites for defects in different locations.

A regional approach may, at times, be used to obtain the best possible match for a given defect. Grafts taken from redundant upper eyelid skin may be used to repair lower eyelid defects, providing a good color and texture match in addition to a well-camouflaged donor site scar. Grafts used for lower eyelid defects should be oversized by 100%–200% to allow for contraction and to avoid ectropion. Due to its relatively large size and inconspicuous location, postauricular skin may also be useful as a donor site for eyelid and auricular defects. Because postauricular skin is relatively non-sun-exposed, grafts harvested from this region may not provide a good color or texture match for other facial defects.

Preauricular skin is more versatile and can be used to repair most nasal defects, since the thickness and degree of sun exposure of these areas tend to be comparable. Donor site scars in this region can be easily camouflaged, as in facelift surgery, to provide a cosmetically desirable result. Even bearded individuals have a 1–2 cm hairless zone in the preauricular region. Care must be taken not to harvest hair-bearing skin in grafts taken from this area. Accidentally including mature follicular units may produce undesirable hair growth within the graft. Hair-bearing skin from the temporoparietal region may be used to repair eyebrow defects, where survival of the follicular units after transplantation may produce a superior cosmetic result. Skin from the nasolabial fold or the conchal bowl can sometimes be used to graft small nasal tip or ala defects with good tissue match[8]. At times, sufficient skin laxity may be present, particularly on the nose or forehead, to allow for partial defect closure, utilizing the adjacent Burow's triangle as a FTSG to repair the remainder of the defect, providing an excellent tissue match[9–11].

For larger defects requiring FTSGs of sun-damaged skin, such as the forehead and scalp vertex, the supraclavicular region or lateral neck can be used as donor sites. Again, care must be taken not to harvest

Downloaded for Anonymous User (n/a) at Egyptian Knowledge Bank from ClinicalKey.com by Elsevier on March 10, 2024. For personal use only. No other uses without permission. Copyright ©2024. Elsevier Inc. All rights reserved.

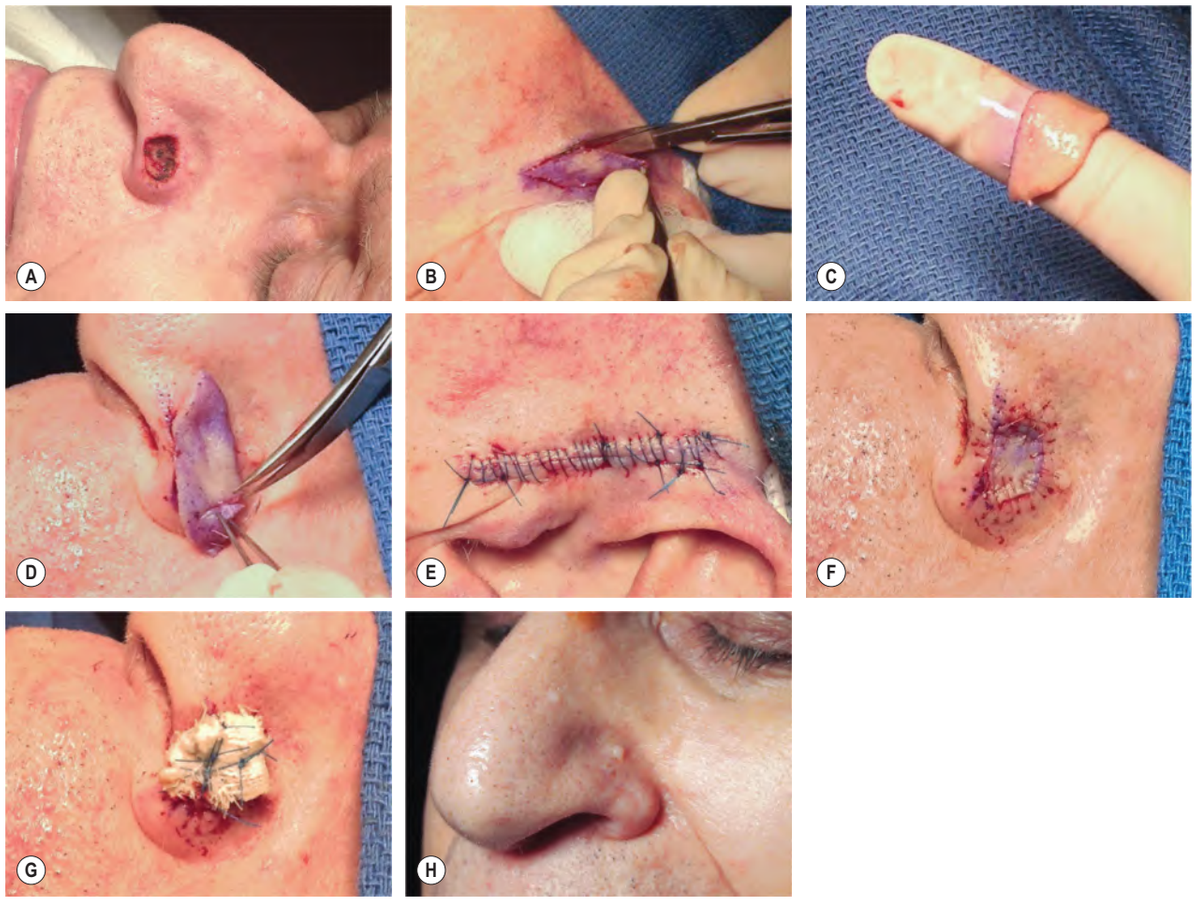

Fig. 148.3 Placement of a full-thickness skin graft. A Defect of the left nasal ala, measuring 1.8 × 1.2 cm, is present after removal of basal cell carcinoma via Mohs micrographic surgery. A preauricular donor site will provide the best match based upon color, sebaceous quality, degree of photodamage, and thickness. **B** With a sterile marker, a template has been made from the periphery of the recipient site and the template is then used to produce an inked margin at the donor site (center of wedge). Next, Burow's triangles are outlined on either side of the template. Marking the donor site prior to injecting local anesthesia prevents incorrect sizing due to tissue stretch from lidocaine infiltration. The donor site is excised with a scalpel to the level of the subcutaneous fat. **C** The graft is carefully defatted with curved iris scissors so that only the white, glistening surface of the dermis remains. **D** The full-thickness skin graft is trimmed with curved iris scissors to ensure a perfect fit. **E** The preauricular donor site is closed primarily. **F** Full-thickness skin graft sewn into place with 6–0 fast-absorbing gut sutures. **G** Xeroform™ bolster sewn into place over the full-thickness skin graft with 5–0 polypropylene tie-over sutures. **H** Sixteen-week postoperative result. The graft shows good color and texture match with the surrounding skin.

unwanted hair along with the graft. These donor sites are often more difficult to camouflage, especially in areas that might not always be covered by clothing, and must be carefully oriented. Although their color and texture match may be suboptimal, areas below the neck with thin, redundant skin, such as the upper inner arms, forearms and inguinal area, can also be considered as donor sites.

Description of Technique

Varying techniques for harvesting and placing FTSGs have been described[2,3,9–11]. To perform a FTSG, a template of the defect is first made, using any flexible material, such as gauze, Telfa™ or aluminum foil, which can be bent to conform to the defect (Fig. 148.3A). After marking the periphery of the recipient site with a sterile marker, the template material is pressed against the defect, and the resulting outline of the inked margin serves as a guide to cut a perfect template. The template is applied to the donor site, and inking material is applied around it (Fig. 148.3B). The graft should be 3%–5% larger than the true template to allow for the natural contraction and shrinkage of the graft after it has been harvested. Often, just cutting around the outside of the inked margin accounts for this extra "safety" skin. For eyelid defects, grafts should be oversized significantly to minimize the risk of ectropion. Marking the donor site prior to local anesthesia prevents incorrect sizing due to tissue stretch from lidocaine infiltration. It is important to note that a donor site ellipse with a 3 : 1 ratio may not always be required, allowing for smaller donor defects[12].

After the donor site is marked, local anesthesia is injected into the donor and recipient sites. Epinephrine (adrenaline) may be used without compromising graft survival. If waterproof ink is not available for template marking, the outline of the template may be scored on the donor site with a needle. The donor site and recipient beds are then scrubbed with an antibacterial preparation such as povidone–iodine (especially around the eyes and ears) or chlorhexidine, excess scrub is removed, and sites are draped with sterile towels.

The donor site is excised with a scalpel to the level of the subcutaneous fat (Video 148.1). The graft is placed in a sterile bowl or Petri dish containing sterile normal saline, where it may remain for up to 1–2 hours. Grafts may be utilized up to 24 hours after harvesting if refrigerated or kept on ice. Before suturing the graft into place, defatting should occur. This is an essential step, since direct contact between the graft and its bed promotes connections between existing vessels as well as new vessel growth and nutritional support from the base of the defect. Adipose tissue adherent to the graft is poorly vascularized and is therefore not an effective medium for vessel growth between the graft and its bed.

When defatting is performed, the graft is placed dermal-side-up on the fingers or in the palm. All fat is trimmed from the underside using sharp scissors (Video 148.2). Fat is adequately removed when all of the yellow globular material is gone, leaving a white glistening dermal surface (Fig. 148.3C, Video 148.3). If indicated, part of the dermis can also be trimmed to allow for differences in recipient site depth, although adnexal structures may be removed in the process, potentially altering the cosmetic result. The graft is then placed dermis-down in its bed, and rotated and trimmed if necessary, to achieve a perfect fit (Fig. 148.3D, Videos 148.4 and 148.5). While one surgeon is trimming the graft, another may close the donor site, usually in a linear layered

Downloaded for Anonymous User (n/a) at Egyptian Knowledge Bank from ClinicalKey.com by Elsevier on March 10, 2024. For personal use only. No other uses without permission. Copyright ©2024. Elsevier Inc. All rights reserved.

fashion with bilateral removal of standing cones (Fig. 148.3E). For conchal bowl donor sites, a 2- or 3-mm punch biopsy instrument may be used to remove full-thickness discs of cartilage, thereby facilitating second intention healing from the underlying dermis.

Contouring of donor skin in FTSGs may be challenging, particularly when repairing defects on the nasal tip, ala, lateral nasal sidewall, helical rim, and eyelid[13]. Graft contouring often requires multiple trial placements within the recipient bed, as well as multiple trimmings, to obtain an optimal result. Removal of cartilage not needed for structural support from the recipient site may increase the chance of graft survival, particularly for auricular defects, without compromising the aesthetic appearance of the repair[14].

Securing the Graft

Perimeter sutures, basting sutures, support dressings, or a combination of any or all of these can be used to anchor the FTSG. Depending upon the graft's size, four to eight interrupted 4–0 or 5–0 absorbable or non-absorbable sutures may be placed at opposite edges of the graft periphery (e.g. at 3, 6, 9 and 12 o'clock) to tack down its four quadrants. A simple running suture, such as 6–0 fast-absorbing chromic gut suture, may then be placed around the graft's perimeter (Fig. 148.3F, Video 148.6). Great care is taken to achieve perfect epidermal wound approximation. The running suture is placed in almost epicuticular fashion, passing the needle first through the graft and then through the surrounding skin. Placing the suture slightly higher in the dermis on the graft side and slightly deeper in the dermis of the surrounding skin makes suture placement easier, prevents tenting of the graft edges, and maximizes graft–recipient bed contact.

Using tissue adhesives in full-thickness skin grafting has been investigated. In a pilot study, it was found that applying cyanoacrylate tissue adhesive to secure FTSGs to their recipient bed wound edges produced cosmetic results essentially identical to those achieved with suturing[15]. Because these adhesives set virtually instantaneously, the graft must be perfectly trimmed and aligned before adhesive application, since fine adjustments in positioning the graft's edges are not easily made. Tissue adhesives may represent a time-saving alternative for securing the periphery of certain grafts, particularly those in relatively immobile areas such as the temple, forehead, and distal nose.

Basting or quilting sutures, usually simple interrupted 6–0 fast-absorbing gut sutures, can occasionally be placed to secure the central portion of the graft. They can be useful in securing large grafts to provide extra support against movement, as well as grafts placed on a concave surface where tenting could possibly occur. All sutures should be snug, but not strangulating, so as not to compromise graft survival.

Immobilization of the graft over its bed can be maximized with pressure dressings. Classically, tie-over bolster dressings have been employed to immobilize grafts, using anchoring stents to ensure direct contact between the graft and its bed[2,3]. These stents may consist of various materials including Xeroform™ gauze (bismuth tribromophenate-petrolatum-impregnated gauze), cotton balls, foam rubber, sponges, plastic beads, or disks. Although sutures or skin staples are usually employed to anchor the stent, adhesive wound closure tapes or Steri-Strips™ can also be applied to exert even pressure on the bolster[16]. Adherence of the dressing to the graft, which tends to pull the graft from its bed at the time of dressing removal, is minimized by first applying petrolatum ointment, a non-adherent contact dressing, or Xeroform™ gauze to the graft site. Pressure or tie-over dressings help immobilize the newly placed graft during the critical period of revascularization, thereby preventing hematoma or seroma formation. While such dressings may not be necessary to secure very small FTSGs[17], a recent literature review found that graft take, cosmetic outcomes, and postoperative complications after use of either tie-over bolsters or quilting sutures were comparable[18].

The simplest bolster consists of Xeroform™ gauze alone, which is molded and placed to apply pressure to the graft. One end of each peripheral non-absorbable suture is cut long, to a length of approximately 3–6 cm, and its opposing suture is left uncut (Video 148.7). The suture ends can then be tied over the dressing two at a time (i.e. 12 o'clock to 6 o'clock and 3 o'clock to 9 o'clock) to secure the bolster (Fig. 148.3G, Video 148.8). Alternatives to tie-over sutures include the running bolster suture, staples, and the "Lilliputian" technique[19,20]. A light dressing consisting of Telfa™ and Hypafix® may be placed over the graft. A pressure dressing should be placed over the donor site for 24 hours.

Postoperative Care

After the pressure dressings are removed, careful wound care should be performed once to twice daily. One method is to gently clean both the donor site and the area immediately surrounding the bolster with hydrogen peroxide to remove all crusts, followed by application of petrolatum ointment (Vaseline®). The bolster is not disturbed until dressing removal at 1 week, at which point the bolster and all tie-over sutures are removed. Steri-Strips™ may be applied to the donor site as needed after suture removal.

The ideal graft is light pink when the bolster is removed. Its color may range, however, from pink or red to darker blue or purple, depending on the extent of graft revascularization. Patients should be cautioned about these color changes beforehand. A bluish tinge may be a sign of ecchymosis rather than graft failure. At the 1-week time point, a white graft is a sign that the graft has not revascularized and will fail, requiring the underlying wound to heal secondarily. A black graft signals necrosis and is also undesirable. It is possible that the entire epidermal surface may become black and necrotic and then slough without adversely affecting the graft's dermal portion, as re-epithelialization can occur from adnexal structures and the epithelial edges, with an acceptable cosmetic result. Therefore, eschars should not be debrided, since they can serve as natural dressings under which healing will progress. Patients should be counseled that the graft's vascular supply remains fragile for weeks. For this reason, trauma, including direct shower water to the area, and excessive activity should be avoided for an additional 1 to 2 weeks.

When there is a good color and texture match between the FTSG and the surrounding skin, the cosmetic result is excellent (Fig. 148.3H).

Variations/Unusual Situations

Purse-string suture

The purse-string suture is a subcuticular stitch placed around the periphery of a circular or oval surgical defect[21]. This type of suture allows partial defect closure by advancing skin from the entire periphery of the wound and may help to cover areas of exposed cartilage or bone at the wound edges that could inhibit graft take. In addition, the graft required to cover the remainder of the defect is greatly reduced in size due to an ~50% decrease in the defect area. Because of this reduced defect size, the graft needed to complete the repair may be harvested from traditional preauricular, postauricular or supraclavicular donor sites, which provide the best color, texture, and thickness match for most sun-exposed areas. Furthermore, FTSG placement decreases the risk of significant wound contraction, resulting in better cosmetic and functional results than would be produced by split-thickness skin grafting or second intention healing.

Large scalp defects extending to bone can present a significant management challenge, which can be handled by placing a purse-string suture followed by a galeal hinge flap[22]. After purse-string placement, the galea aponeurotica adjacent to the scalp defect is scored with a scalpel, and a partial-thickness galeal flap of sufficient size to cover all or a portion of the exposed periosteum or bone may be dissected free and transposed into place, using the same motion as turning a page of a book. This hinged galeal tissue serves to recreate the vascular bed required for successful graft placement and thus permits repair of deep and often difficult scalp defects in a single operative session.

Burow's grafts

Defects of the nasal sidewall and dorsum, and sometimes of the forehead, lateral neck or other areas, may be repaired with Burow's grafts[9–11]. Because Burow's grafts utilize skin adjacent to the defect, they tend to provide a cosmetically superior match compared to grafts harvested from distant locations. In general, these grafts are harvested from the skin superior to the defect if on the nose, and medial or lateral to the defect if on the forehead. The Burow's triangle is excised (see Ch. 146) and the resulting donor defect is closed primarily, thereby partially decreasing the original defect size. The triangle is defatted, trimmed, and sutured into the defect. Operating time is decreased because a separate donor site is not required. Burow's grafts tend to be limited in size. When insufficient laxity is present for partial donor site closure, or if the Burow's triangle is not sufficiently large to cover the remaining defect, alternative donor sites should be sought.

Downloaded for Anonymous User (n/a) at Egyptian Knowledge Bank from ClinicalKey.com by Elsevier on March 10, 2024. For personal use only. No other uses without permission. Copyright ©2024. Elsevier Inc. All rights reserved.

Deep nasal defects

Deep postsurgical defects on the nose may, at times, pose a challenge for repair. Delaying FTSG placement for 12 to 14 days may increase the likelihood of graft survival over defects of the nasal tip and ala with denuded cartilage[23]. Also, when tissue loss is deep in these areas, delaying skin grafting for 7 to 14 days may allow granulation tissue to fill in the defect such that a better contour may ultimately be achieved[23]. Because the early granulating wound produces an excellent vascular bed, delayed grafting may be considered in patients with reduced wound bed vascularity, e.g. those who smoke or have had previous radiotherapy. At the time of delayed graft placement, the wound bed is debrided by rubbing with dry gauze and the wound edges refreshed by scraping them with a scalpel oriented perpendicular to the wound edges. Prophylactic antibiotics are often prescribed when placing delayed grafts.

If a depressed defect is anticipated, but immediate reconstruction is preferred, dermal grafts can be used as tissue filler prior to FTSG placement[24]. Dermal grafts can effectively fill the defect, with little risk of resorption, and eliminate the need for a more complicated repair choice. The "drumhead" graft repair of deep nasal alar defects involves application of an overlying rigid plastic suspension coupled with an undersized graft, thereby preventing graft depression and nasal valve collapse; a cut portion of the periphery of the sterile plastic packaging from a suture packet can serve as the plastic suspension[25]. It enables the graft to remain apposed to the recipient bed, suspended as it would be in its natural form if it were supported both by soft tissue and by nasal cartilage. A bolster can be placed overlying the graft.

Perichondrial cutaneous grafts (PCCGs) are actually composite grafts composed of full-thickness skin and subjacent perichondrium; PCCGs may be used as substitutes for FTSGs when reconstructing deep nasal tip and alar defects, particularly those with exposed cartilage[26,27]. PCCGs are harvested from the conchal bowl, utilizing the subperichondrial plane as the plane of dissection. The cartilage is not removed, making this graft more analogous to a FTSG than a cartilage-containing composite graft. The advantages of PCCGs over FTSGs include the following: PCCGs are thicker, have a greater chance of survival under conditions of vascular compromise, contract less than FTSGs, and may achieve better skin texture match on the distal nose due to the sebaceous nature of conchal bowl skin.

Postoperative Complications

Complications of full-thickness skin grafting can be divided into short-term problems of graft failure and long-term functional and cosmetic problems[2,3]. Short-term problems include infection, hematoma, seroma, and shearing of the graft over its bed. These problems are significant when they occur, but can usually be avoided. Infection after grafting of facial defects, in particular, is not often encountered, and oral antibiotics are not routinely given postoperatively. Nevertheless, it is important to be gentle while handling tissue intraoperatively and to minimize devitalized tissue created by electrocoagulation to minimize the risk of infection. Prophylactic oral antibiotics covering *Staphylococcus* and *Streptococcus* spp. may be helpful in selected patients, especially those with diabetes mellitus, immunosuppression, or a prolonged intraoperative time. Grafts on the ears, fingers, and legs may benefit from prophylactic antibiotics, as these sites can be prone to postoperative wound infections.

Hematoma and seroma formation can be avoided by meticulous intraoperative hemostasis, pressure dressings, and postoperative caution. After consultation with the patient's internist, cardiologist, or primary care physician, patients may be instructed to avoid aspirin for 10 days before surgery, nonsteroidal anti-inflammatory drugs for 5 days before surgery, and alcohol for 2 days before and 2 days after surgery. In the past, patients taking antithrombotic medications were advised to discontinue them before surgery if their internist or cardiologist was in agreement. The current recommendations for management have, however, changed. While the risk of bleeding complications increases slightly if oral anticoagulants are not discontinued, most dermatologic surgeons do not routinely request that these medications be discontinued preoperatively, since the risk of morbidity from hemorrhagic complications is minimal compared to that of the thrombotic events potentially associated with their discontinuation[28]. Patients are also advised not to engage in vigorous activity, heavy lifting, or bending for at least 2 weeks postoperatively. The latter measures help to inhibit graft movement and supplement the bolster's effectiveness in minimizing shearing of the graft over its bed.

Long-term complications of FTSGs consist of cosmetic and functional problems. It is imperative to stress to the patient prior to graft placement that FTSGs usually take months to look natural. Preoperative counseling may help to alleviate fears concerning the graft's appearance during the first weeks after bolster removal. Make-up can usually be applied 3–4 weeks after grafting. It is important to note that FTSGs are often depressed during their first 2–4 weeks. This depression will usually correct itself within 4–6 weeks.

Although careful donor site selection will minimize the color, texture, and contour deformities that can occur, patient and physician satisfaction with the cosmetic result may not be complete after healing has finished. Spot dermabrasion or laser resurfacing has traditionally been performed at 6 weeks to 6 months after grafting to correct differences in elevation between the graft and its surrounding skin, as well as to improve color and texture mismatch[29]. While studies have focused on pulsed dye laser (PDL) treatment of postsurgical scars rather than FTSGs or STSGs, a meta-analysis found an average 72% rate of improvement or no recurrence of hypertrophic scars and keloids with PDL therapy[30]. Graft hyperpigmentation can be addressed with a brief course of topical hydroquinone and/or tretinoin.

Functional complications of FTSGs occur primarily as a result of wound contraction. Grafts contract secondary to the centripetal movement of unopposed elastic fibers. A variable amount of shrinkage can therefore be expected, depending upon donor site thickness and elasticity[6,31]. In one study, it was found that the area of FTSGs contracted by a mean of 38% by 16 weeks after placement, with grafts applied to the periorbital area and nose contracting more than those on the scalp and temples[32]. Contraction usually increases as graft thickness decreases, and it is thought to occur in the fibrous layer under the graft, either in the bed itself or in the layer of scar tissue wedged between the graft and its bed[6]. Complications due to graft contraction are usually minimal in FTSGs. If wound contraction does produce functional or cosmetic abnormalities, revisional surgery may be needed.

Future Directions

For defects with an inadequate vascular bed, full-thickness skin grafting may not be possible, necessitating repair with a less cosmetically elegant STSG. High-density, porous, polyethylene implants have therefore been designed which permit ingrowth of fibroneovascular tissue without changing the size or shape of the implant[33]. When these prefabricated implants were placed in rabbits, it was found that they developed sufficient vascularity to sustain FTSGs. This technology holds promise for patients with deep nasal and ear defects, in whom an anatomically correct structure could be implanted, after which time would be allowed for fibrovascular tissue ingrowth, with full-thickness skin grafting performed later for a superior cosmetic result.

Progress is also being made on incorporating complex blood vessels into bioengineered skin equivalents, while 3D printing techniques have been investigated as a means of generating skin equivalents. Recently, a vascularized, perfusable skin graft was fabricated via 3D printing utilizing a bioink that contained human foreskin dermal fibroblasts, endothelial cells, and placental pericytes suspended in rat tail type I collagen to form a dermis. This was followed by 3D printing with a second bioink containing human foreskin keratinocytes to form an epidermis. *In vitro*, the keratinocytes replicated and matured to form a multilayered barrier while the endothelial cells and pericytes self-assembled into interconnected microvascular networks[34]. With these advances in technology, it seems possible that, at some point, 3D printing of complex tissue-like constructs to use as skin grafts could become routine.

SPLIT-THICKNESS SKIN GRAFTS

Split-thickness skin grafts (STSGs) consist of epidermis and a portion of the dermis. These grafts vary in thickness from ~0.005 to 0.030 inches (0.13–0.78 mm), and are classified as thin, medium, or thick, depending upon the amount of dermis included within the graft (Table 148.6).

Downloaded for Anonymous User (n/a) at Egyptian Knowledge Bank from ClinicalKey.com by Elsevier on March 10, 2024. For personal use only. No other uses without permission. Copyright ©2024. Elsevier Inc. All rights reserved.

CLASSIFICATION OF SPLIT-THICKNESS SKIN GRAFTS	
Thin	0.005–0.012 in/0.13–0.30 mm
Medium	0.012–0.018 in/0.30–0.46 mm
Thick	0.018–0.030 in/0.46–0.76 mm

Table 148.6 Classification of split-thickness skin grafts.

Indications/Contraindications

STSGs contain less tissue requiring revascularization than FTSGs and are therefore more likely to survive when placed on almost any recipient bed, including those with a limited vascular supply. As a result, these grafts may be placed over periosteum, perichondrium, peritenon, and perineurium. STSGs are also used to cover large defects (Fig. 148.4A), particularly those that cannot be covered by a flap or would heal too slowly by second intention, as well as refractory venous leg ulcers[2,3]. STSGs may be useful for covering surgical defects in sites at high risk for tumor recurrence, since recurrent tumor is usually visible when growing through split-thickness skin. If the tumor has not recurred after 1–2 years, the graft can be removed and definitive reconstruction performed.

Advantages of STSGs over FTSGs include their improved chance of survival under conditions of vascular compromise, their ease of application, their ability to cover large defects, and their ability to act as a "window" for recurrence of high-risk lesions. The principal disadvantages of STSGs include their suboptimal cosmetic appearance, the presence of a granulating donor site wound requiring postoperative care, greater contraction, and the special equipment required to harvest larger grafts. Furthermore, because of their relative thinness, STSGs may be less durable than FTSGs, necessitating regrafting or partial healing by second intention.

While thicker STSGs tend to be cosmetically superior to thinner ones, poor color and texture match with the surrounding skin often occurs after STSG placement. STSGs tend to be pale or white in color, hairless, and smooth, with impaired sweating due to the fact that adnexal structures are not removed in their entirety with the graft and do not survive. The contrast between the STSG and its surrounding skin can therefore produce a "tire-patch" appearance (Fig. 148.4B), which is more pronounced than that seen with FTSGs.

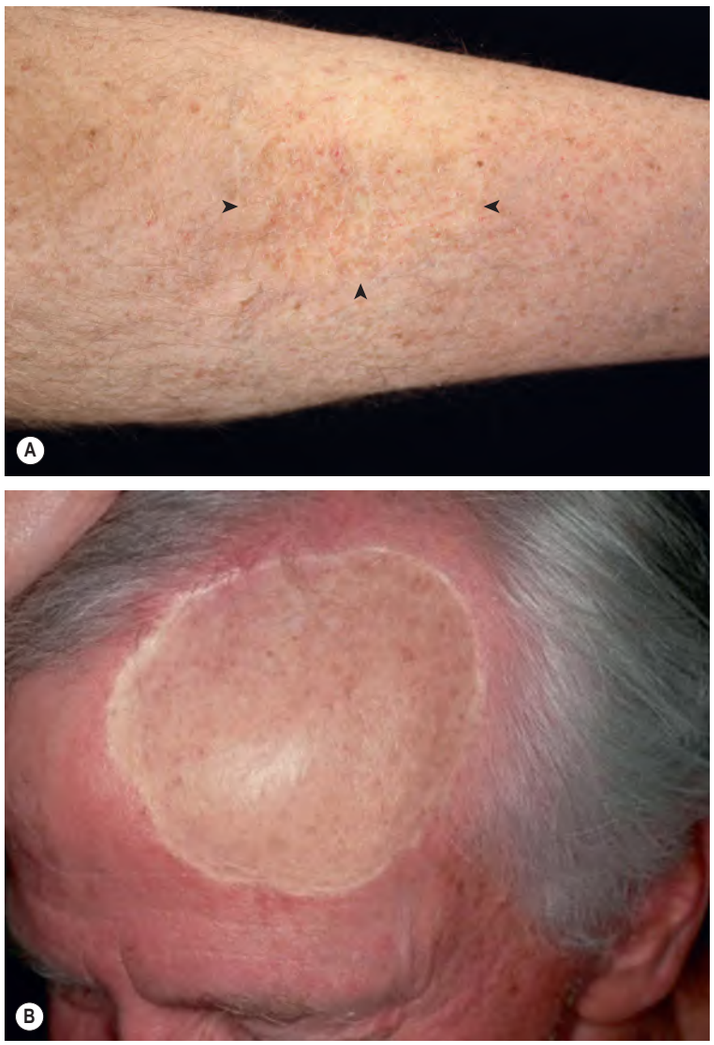

Fig. 148.4 Split-thickness skin grafts (STSGs). A A relatively thick STSG placed on the medial aspect of the lower extremity with excellent cosmetic results; arrowheads denote the edges of the graft. **B** STSG placed on the forehead and scalp several years prior, following excision of a cutaneous melanoma. Note the relative hypopigmentation, altered texture, and depression of the STSG compared to the normal surrounding skin. *Courtesy Jean L. Bolognia, MD.*

Preoperative History and Donor Site Considerations

Donor scar cosmesis should be taken into consideration when selecting a split-thickness donor site. The ease of postoperative care and the type of instrument used to harvest the graft may also help dictate donor site choice. Ideally, STSGs should be harvested from a site where a broad area of skin can be removed while still being concealed beneath clothing. The most common donor sites include the anterior, medial, and lateral portions of the upper thigh, the inner and outer aspects of the upper arm, and the inner aspect of the forearm. Lower back and abdominal skin can also be harvested. The anteromedial thigh is most frequently used as the donor site for STSGs, as harvesting and wound care are convenient, and wounds in this location do not interfere with ambulation. Donor site wounds on the buttocks tend to require assisted postoperative care, although their scars are ideally placed from a cosmetic standpoint. Power-driven dermatomes and large freehand knives require large flat donor surfaces, which may limit donor sites to the thighs, abdomen, and buttocks, while smaller grafts can be harvested freehand or with a power-driven dermatome.

Description of Grafting Techniques

A wide variety of techniques for harvesting and placing STSGs have been described[2,3]. The instruments used to harvest STSGs can be classified into freehand and electric dermatomes. Freehand dermatomes include scalpel blades, double-edged razor blades, and knives such as the Weck blade. Although acceptable grafts can be obtained using these freehand devices, considerable technical expertise is required to harvest them.

A standard #15, #15c, or #10 blade can be an effective tool for harvesting small STSGs of medium thickness. After a template of the defect is made, the donor site is marked, anesthetized with 1% or 2% lidocaine, or with a dilute lidocaine solution if the tumescent technique is to be employed, and scored lightly with the blade. The graft is then harvested by orienting the blade parallel to the skin and gently sweeping it just below the level of the epidermis, so that the blade is visible beneath the skin (Fig. 148.5). It is helpful to have an assistant apply traction to the donor site while the graft is harvested. Several blades may be required for harvesting, as blade sharpness diminishes quickly with multiple passes. This technique may be especially useful in harvesting small medium-thickness STSGs to repair auricular and postauricular defects.

Power-driven dermatomes became the standard method of harvesting larger STSGs after Brown developed the first such instrument in the 1940s. Electric dermatomes designed to harvest STSGs of varying thicknesses and widths, from several centimeters up to nearly 15 cm, are now commonly employed, and lithium ion battery-powered units are also available. Although STSGs can be obtained easily and reliably with any of these devices when properly used, graft quality is technique-dependent, and substantial irregularity in graft thickness and width may occur. The Zimmer dermatome, which was originally powered by compressed water-pumped nitrogen and subsequently modified into an electrically powered version, tends to harvest uniform grafts of predetermined width and thickness such that consistent graft quality tends to be less dependent on the operator's technique. Multipurpose motor systems now exist which include a control box, foot switch, and autoclavable motor that can be used not only with dermatomes,

Downloaded for Anonymous User (n/a) at Egyptian Knowledge Bank from ClinicalKey.com by Elsevier on March 10, 2024. For personal use only. No other uses without permission. Copyright ©2024. Elsevier Inc. All rights reserved.

but also with diamond fraises for dermabrasion, adjustable skin graft meshers, and other types of surgical handpieces, allowing a wide array of procedures to be performed using a single unit.

After the dermatome is prepared, the donor and recipient sites are anesthetized, prepped and draped in the usual sterile fashion. If chlorhexidine surgical scrub is used, a saline wash is employed to remove any excess scrub. The donor site is lubricated in advance with sterile mineral oil or another lubricant to ease travel of the dermatome over the skin. The handpiece is held on the donor site at an angle of 30–45°. A throttle control is pressed to start the cut, and the unit is guided forward using light downward pressure to ensure that the cutting edge remains in continuous contact with the donor site. An assistant applies tension by pulling the skin away from the donor area to create a flat, even surface. As the dermatome glides over the donor skin, the graft emerges from the pocket of the dermatome, and is lifted away from the machine with tissue forceps or hemostats (Fig. 148.6A). Once a sufficiently large graft has been harvested, the dermatome is pulled away from the skin and the graft is placed in sterile saline or on sterile saline-soaked gauze (Fig. 148.6B). A modified harvesting technique using tumescent anesthesia and placement of a polyurethane membrane over the donor site has been reported to prevent graft shrinkage and dehydration and to facilitate graft fixation at the recipient site[35].

Fig. 148.5 Freehand harvesting of a small split-thickness skin graft from the upper outer arm. The blade is oriented parallel to the skin, and gently swept just below the level of the epidermis, so that it is just visible through the graft. An assistant applies traction to the donor site to facilitate harvesting.

Securing the Graft

As in the case of FTSGs, STSGs should be secured so that infection, hematoma or seroma formation, and mechanical shearing forces can be prevented. Both the perimeter and the central portion of the graft must be secured for adequate nutritional support and to ensure graft survival. The edges of STSGs need not be as closely approximated to the surrounding wound edges as those of FTSGs, since overlapping skin will slough without affecting the ultimate cosmetic result. After the graft has been placed with the dermal side adherent to the recipient bed, its perimeter may be secured with sutures or staples. Centrally placed basting sutures may also be helpful in ensuring apposition of the graft to its bed. Once the graft has been secured and its bolster sewn into place, a non-adhesive dressing or pressure dressing may be applied as an additional precaution. Sutures or staples are removed after 7–10 days.

Donor Site Care

Harvesting STSGs creates a second wound, the donor defect, which often causes more postoperative discomfort than the grafted area itself.

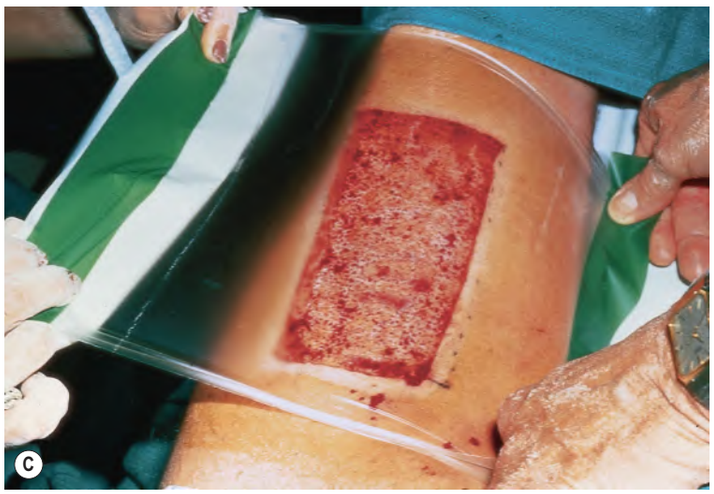

Fig. 148.6 Harvesting of a large split-thickness skin graft with an electric dermatome. A As the Zimmer dermatome glides over the donor skin, the graft emerges from the pocket area of the dermatome and is then lifted away from the machine with sterile hemostats. **B** Split-thickness skin graft placed on sterile saline-soaked gauze. Note that the edges curl inward toward the dermal surface of the graft. **C** An Opsite® dressing is placed over the donor site on the anterior thigh immediately after harvesting.

Downloaded for Anonymous User (n/a) at Egyptian Knowledge Bank from ClinicalKey.com by Elsevier on March 10, 2024. For personal use only. No other uses without permission. Copyright ©2024. Elsevier Inc. All rights reserved.

This partial-thickness wound heals by second intention. While STSG donor sites were once treated with bulky occlusive dressings left in place for 10–14 days, the advent of transparent, vapor-permeable dressings such as Opsite® has improved both patient comfort and ease of care in the postoperative period (Fig. 148.6C)[36]. These dressings are advantageous because they allow the serosanguineous drainage that inevitably accumulates at the donor site to collect, keeping the wound moist and thereby shortening healing time. Because these dressings are transparent, the wound can easily be observed for complications during healing. In one review, these dressings were associated with the fastest healing rates, low infection rates, the least amount of pain, and lower cost when compared with other dressings[37].

After the skin around the donor site area is cleaned and dried, a thin coat of an adhesive such as Mastisol® is applied around the wound and allowed to dry. An Opsite® dressing is then placed over the wound. Paper tape is placed around the perimeter of the Opsite®, followed by a gauze dressing and an elastic bandage (e.g. Ace™ wrap).

Variations/Unusual Situations

Meshing the graft with scalpel slits may be performed to allow drainage of accumulated blood or serosanguineous material that could otherwise inhibit graft–bed contact. This technique may also be used to expand the surface area of STSGs. A meshing machine may be utilized to expand the graft's surface area further by ratios ranging from 3:1 to 9:1. Meshing can facilitate coverage of a large recipient area with smaller donor grafts. Expanded meshed grafts placed experimentally on contaminated recipient beds have been found to exhibit increased take as compared to non-meshed donor skin[38].

Postoperative Care

During the first 24 hours after grafting, a large amount of serosanguineous fluid may accumulate beneath the donor site dressing. Patients need to be forewarned about this possibility so that they do not become alarmed. If necessary, the fluid can be drained with a needle and syringe, and an Opsite® patch applied. Alternatively, a new Opsite® dressing can be placed. The dressing can then be left in place until healing is complete. Depending on the STSG's thickness, the donor site should fully re-epithelialize in 7–21 days. The scar usually evolves in color from pink to white over a period of months.

Complications

The complications of split-thickness skin grafting can be divided into early complications, which stem from failure of engraftment, and late complications[2,3]. Failure of engraftment may result from hematoma or seroma formation, infection, or shearing forces. Late complications can be divided into cosmetic and functional problems (Fig. 148.7).

Color and texture mismatch of STSGs with the surrounding skin is predictable and expected. Grafts often remain erythematous for months to years after placement. More importantly, they may exhibit significant postoperative hyperpigmentation or hypopigmentation. Darker-skinned patients are especially prone to graft hyperpigmentation, despite observance of preventive measures. Patients should therefore minimize graft exposure to the sun without sunscreens for 6 months, and wear sunscreens consistently thereafter. The absence of adnexal structures predisposes to xerosis and a build-up of keratinous debris. The resultant scaling, pruritus, and dryness can be minimized with liberal emollient use.

Functional considerations are of paramount concern, since STSGs contract more than FTSGs and can create forces powerful enough to produce joint contracture if placed over or near joints. Contraction of facial grafts, especially near the nasal ala, the eyelid, the helical rim and the free margins of the vermilion border, may produce significant cosmetic deformities, including alar retraction, ectropion, helical rim distortion, and vermilion border distortion, respectively. Hypertrophic scarring of the graft and donor sites may also occur, which can be treated with corticosteroid-impregnated tape, intralesional corticosteroids, or pulsed dye laser. Graft fragility and breakdown can occur in areas of trauma, particularly in sites such as the lower leg, or in areas with little underlying soft tissue support, such as those directly overlying perichondrium or periosteum. These complications are not always avoidable, but forewarning patients may reduce unnecessary trauma to the area. Lastly, bullae can occur within graft sites, presumably related to decreased anchoring properties of the basement membrane zone (see Ch. 33).

Future Directions

In recent years, biosynthetic and tissue-engineered living skin replacements have been the focus of research in skin transplantation[39–41]. Cultured human keratinocytes have been seeded onto type I collagen membranes petrolatum gauze to reconstitute the epidermis, enabling

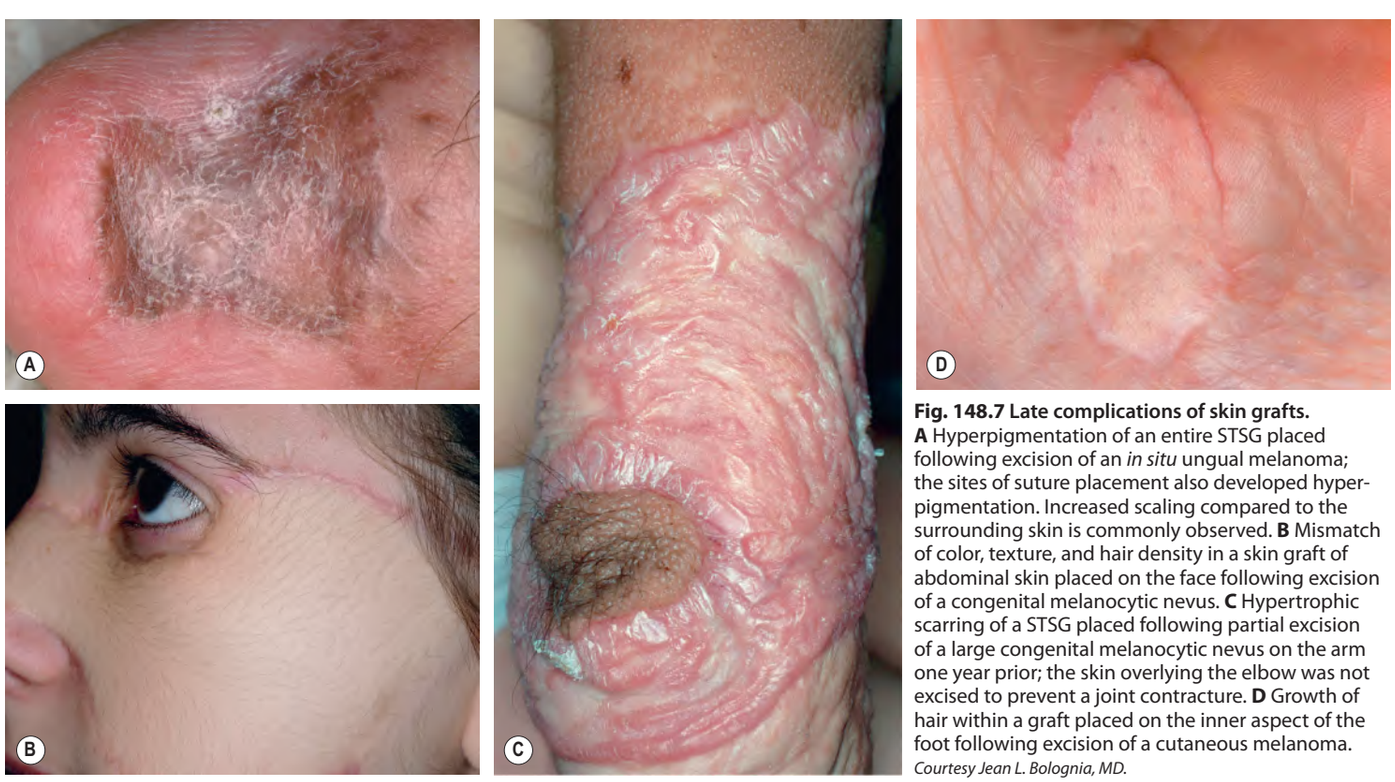

Fig. 148.7 Late complications of skin grafts. **A** Hyperpigmentation of an entire STSG placed following excision of an *in situ* ungual melanoma; the sites of suture placement also developed hyperpigmentation. Increased scaling compared to the surrounding skin is commonly observed. **B** Mismatch of color, texture, and hair density in a skin graft of abdominal skin placed on the face following excision of a congenital melanocytic nevus. **C** Hypertrophic scarring of a STSG placed following partial excision of a large congenital melanocytic nevus on the arm one year prior; the skin overlying the elbow was not excised to prevent a joint contracture. **D** Growth of hair within a graft placed on the inner aspect of the foot following excision of a cutaneous melanoma. *Courtesy Jean L. Bolognia, MD.*

Downloaded for Anonymous User (n/a) at Egyptian Knowledge Bank from ClinicalKey.com by Elsevier on March 10, 2024. For personal use only. No other uses without permission. Copyright ©2024. Elsevier Inc. All rights reserved.

transfer of actively proliferating keratinocytes onto partial-thickness wounds. Human epidermal tissues mimicking the biochemical and morphologic properties of human skin have been established *in vitro* by growing human keratinocytes on a dermal fibroblast-containing collagen gel. Such skin-equivalent cultures are being used to reconstitute the epidermis in patients with full-thickness burn wounds and chronic ulcers (see Ch. 145).

Artificial dermis is now routinely used prior to full-thickness grafting, and an acellular allograft dermal matrix has been shown to provide a good bed for STSGs in patients with full- and partial-thickness burns. A tissue-engineered human skin equivalent, i.e. a bilayered product containing living human fibroblasts, keratinocytes and bovine collagen, is commercially available for the repair of surgical defects and coverage of lower leg ulcers that would previously have been repaired with STSGs. Dermal–epidermal composites using autologous keratinocytes and human allodermis may in the future be used for grafting full-thickness wounds in patients with burns, leg ulcers, or surgical wounds.

COMPOSITE GRAFTS

Indications/Contraindications

Composite grafts are modified FTSGs, consisting of two or more tissue layers. In dermatologic surgery, these grafts are usually composed of skin and cartilage, although they may be composed of skin and fat or skin and perichondrium[3,26,42–48]. Composite grafts are especially useful for repairing full-thickness alar rim defects, as well as nasal tip defects with cartilage loss[46,47]. Full-thickness nasal mucosal defects can be repaired using composite grafts to provide mucosal lining and structural support with a nasolabial or forehead flap placed thereafter to reconstruct the overlying soft tissue defect (see Fig. 147.29). As discussed earlier, conchal bowl composite grafts or PCCGs, consisting of skin and perichondrium, may be used (with or without an underlying cartilage graft) for deeper nasal defects requiring skin coverage, especially defects with exposed cartilage[48].

Preoperative History and Considerations

Composite grafts require rapid revascularization to survive. Early re-establishment of circulation occurs via direct vessel anastomoses between the subdermal plexus of the graft and the subdermal plexus of the wound edge. Since composite grafts are dependent upon this bridging phenomenon for their survival, they are of necessity limited in size, with no point being more than 1 cm from a vascular source, as the risk of central necrosis increases significantly at graft diameters >2 cm[3,47]. Composite grafts for nasal ala and ear reconstruction are possible because of the rich vascular supply of the nose and ear, and because of the small surface areas generally involved. Composite grafts, like FTSGs, are threatened by excessive shearing forces of the graft over its bed, which prevent revascularization.

Composite grafts pass through four stages as they heal[3,47]. After graft placement, the tissue blanches completely. By 6 hours, the graft becomes pale pink, signifying anastomosis of the graft vessels with those of the recipient site. At 12–24 hours, the graft appears dusky blue, reflecting venous congestion, and by 3–7 days, it should be pink, indicating graft survival.

Donor Site Considerations for Composite Grafts

The complexity of nasal ala anatomy makes reconstruction of full-thickness defects in this area difficult. There may be insufficient nasal skin to develop adequate local flaps, and nasolabial flaps, which provide reasonable defect coverage, generate other cosmetic deformities. Loss of alar tissue support also creates a functional deficit, as the alar skin is liable literally to "blow in the breeze" on inspiration and expiration. Composite grafts provide an excellent cosmetic and functional alternative for repair of full-thickness alar rim defects <2 cm in diameter[46]. Grafts taken from the earlobe have been used successfully for this type of repair, although grafts taken from the cartilaginous portion of the ear are more frequently used[43,46].

Donor sites for harvesting auricular composite grafts include the helical crus, helical rim, and conchal bowl (see Ch. 142)[46–48]. Small alar defects with cartilage loss can be elegantly repaired using the helical crus as donor site, while more substantial defects may require repair using the helical rim or conchal bowl, since the crus may not provide sufficient inner lining for the graft. Donor defects involving the helical crus can be repaired with minimal scar formation, while wedge excisions are usually necessary to repair helical rim donor sites. Conchal bowl donor sites heal by second intention.

The advantages of auricular composite grafts in repairing full-thickness alar rim defects relate mainly to the presence of cartilage, which provides structural support and stability, with prevention of alar distortion during inspiration and at rest[46,48]. Disadvantages include a higher risk of graft failure with an increased number of tissue layers, substantial graft size limitations, and limited donor tissue availability. Nevertheless, these grafts, when properly applied, can yield outstanding results. In one animal study, maintaining an intact skin-to-cartilage interface and an equivalent skin-to-cartilage ratio improved composite graft survival; however, when cartilage size exceeded skin size, or when skin and cartilage were separated before transfer, survival decreased, highlighting the importance of an intact skin-to-cartilage interface in optimizing graft survival[49].

Composite grafts used for full-thickness nasal mucosal repair are usually obtained from the triangular fossa, scapha, conchal cavum, cymba, or helical crus (see Fig. 142.13). The appropriate donor site is that which best matches the contour of the surgical defect. These donor sites are usually allowed to heal by second intention, with good aesthetic outcomes.

Description of Technique

Composite grafts used for alar repair are performed as follows (Fig. 148.8)[42,46,48]: the donor and recipient sites are anesthetized using local anesthesia, and prepped with an antiseptic solution. If the alar tissue is scarred and retracted, the area must be vigorously debrided to assure the best possible blood supply for the graft. The defect is then

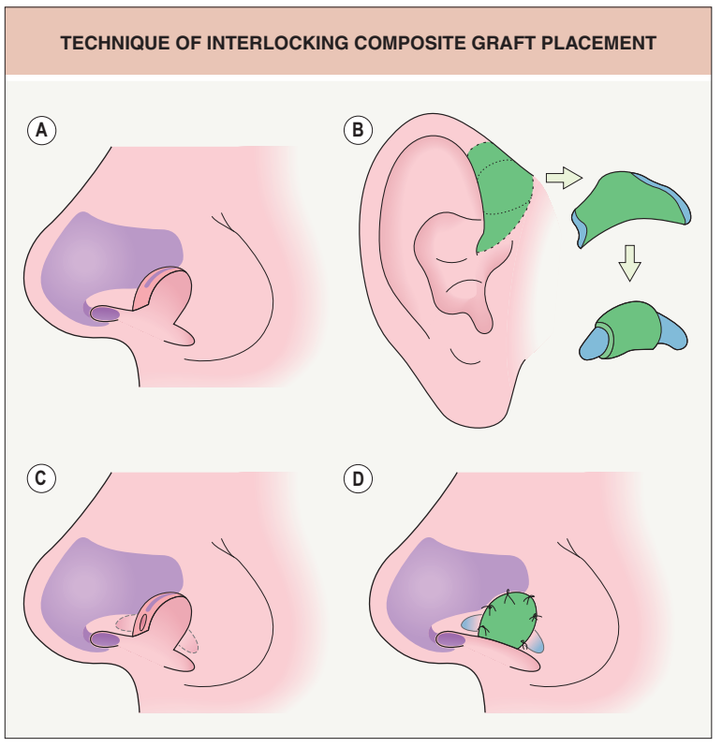

Fig. 148.8 Technique of interlocking composite graft placement. A A full-thickness nasal ala defect extending through both skin and cartilage requires repair. **B** Donor site at the crus of the helix. An area of skin ~5%–10% greater in area than the actual defect is marked out, with cartilaginous wings marked out on either side. After the graft is harvested, the skin is removed on both sides to expose the cartilaginous portion of the graft, such that two cartilaginous pegs with their overlying perichondrium (blue color) frame the lateral aspects of the graft. **C** A pocket is undermined on either side of the recipient site into which the cartilaginous pegs will be placed. **D** The cartilaginous pegs are inserted into the holes prepared within the alar tissue on either side of the defect. The graft is then sutured into place.

Downloaded for Anonymous User (n/a) at Egyptian Knowledge Bank from ClinicalKey.com by Elsevier on March 10, 2024. For personal use only. No other uses without permission. Copyright ©2024. Elsevier Inc. All rights reserved.

measured and a template made as described previously. The donor site is marked and anesthetized, and the graft is harvested. The tissue is handled very gently and placed in sterile saline until ready for placement.

Due to the fragility of composite grafts, a tongue-in-groove technique is recommended to maximize graft stability and increase graft survival[46]. Two cartilaginous wings are marked out and anesthetized on either side of the donor site prior to graft harvesting. After the graft is harvested, the skin overlying these two cartilaginous wings is removed, leaving the cartilage with its overlying perichondrium (Fig. 148.8B). These wings are then inserted into pockets prepared within the alar tissue of both sides of the defect (Fig. 148.8C) such that the graft interlocks with its recipient bed (Fig. 148.8D). Interlocking the graft with its bed may help to minimize shearing forces and provide a larger surface area for revascularization.

The graft is sutured into place in two layers. The undersurface of the graft, which replaces the inner lining of the nose, can be secured first using a 6–0 absorbable suture. The skin is then closed with a 6–0 non-absorbable suture, taking very small tissue bites to minimize vessel strangulation and to maximize the number of potential vessels available for reanastomosis. The needle should pass through the mucosal portion of the graft first, then through the outer epithelial edge of the graft, so that the knots are tied externally, and are not buried between the graft and its recipient bed. The cartilage does not need to be sutured, as it will heal on its own. A Vaseline® gauze or Xeroform™ dressing can then be placed in the nasal vestibule for support, and petrolatum ointment applied to the external suture line. A non-stick dressing is then applied to protect the graft from external injury.

Conchal bowl composite grafts used for reconstruction of deep alar defects are harvested in essentially the same way as composite grafts taken from the helical crus[47]. Potential advantages of the conchal bowl technique include increased bulk, which may be superior in filling deep partial-thickness alar defects, and an excellent cosmetic match for the sebaceous skin of the nose.

Donor Site Closure[48]

Helical crus defects can often be closed in a side-to-side fashion. A simple advancement, rotation, or transposition flap may also be utilized to take advantage of loose preauricular skin. Helical rim defects are usually closed with an ear wedge resection. Auricular grafts obtained from the triangular fossa, scapha, conchal bowl, or cymba heal well by second intention. Conchal bowl defects may heal more rapidly if a 2 or 3 mm punch biopsy instrument is used to remove small plugs of conchal cartilage, which allows healing by second intention from the dermis on the opposite side.

Variations/Unusual Situations

When securing composite grafts onto the nasal ala, delayed intranasal knot tying has been recommended by some authors to facilitate wound closure by improving visualization, allowing gentler manipulation of tissue, and enabling precise suture placement in a confined space[50]. When placing intranasal sutures, the needle of the 6–0 fast-absorbing chromic gut suture is first passed through the nasal mucosa, and then through the corresponding location on the "mucosal" side of the graft. Sutures are placed at 1–2 mm intervals along the defect and graft, and their free ends are held separately by hemostats to prevent tangling. After all intranasal sutures have been placed, the composite graft is placed into the alar defect and the cartilaginous wings inserted. The most internal intranasal sutures are then tied first, followed by the more accessible external sutures.

Postoperative Care

To minimize edema, ice packs should be applied to the grafted area as often as possible for up to several days postoperatively. Oral antibiotics are generally advisable because of the high bacterial colonization around the nares and the higher risk of failure with composite grafts. Sutures are removed after 1 week.

Complications

As with other types of grafts, there is a risk of necrosis in the early stages of healing, and contraction, textural changes, atrophy, and contour irregularities thereafter. If the graft survives but the cosmetic result is suboptimal, dermabrasion or laser resurfacing may be performed 6 weeks to 6 months postoperatively to correct textural differences between the graft and the surrounding skin, and to improve the color match between them. Resurfacing of the entire cosmetic unit may provide superior cosmetic results. In the event of composite graft failure, a two-stage revision with placement of a cheek interpolation flap may be performed or, alternatively, a second composite grafting procedure may be undertaken.

Conchal bowl donor sites are at somewhat greater risk of postoperative bleeding than other areas if left to heal by second intention. Application of pressure dressings over the front and back of the ear to "sandwich" the conchal cartilage with placement of hemostatic foam over the donor site may decrease this risk. Other types of complications at auricular donor sites are rare[51].

The ear is also prone to infection with *Pseudomonas* spp., which reside in the external auditory meatus. Cleaning the ear with a dilute vinegar solution, applying topical gentamicin ointment, and oral quinolone antibiotics are all helpful prophylactic measures which should be considered after harvesting auricular cartilage. If infection is suspected, oral quinolone antibiotics should be started immediately, and therapy guided thereafter by the results of cultures and sensitivities. If the infection does not resolve with appropriate antibiotics, the presence of a fungal infection, most often secondary to *Candida*, should be excluded.

FREE CARTILAGE GRAFTS

Indications/Contraindications

Free cartilage grafts are used most commonly in dermatologic surgery to reconstruct the nasal ala, tip and sidewall, the ear, and the eyelid[42,44,51–53]. These grafts may be used to restore the architecture of an anatomic site that has undergone significant cartilage loss. Free cartilage grafts are also useful in stabilizing the position and contour of free margins against the forces of contraction during wound healing.

Nasal Ala

Partial-thickness alar defects extending into deep soft tissue or approaching the alar rim often lead to rim collapse, producing a functional as well as a cosmetic deficit. Placement of cartilage grafts, consisting of cartilage with its overlying perichondrium, can be used to avert this potential problem[51–53]. The grafted cartilage provides a rigid but flexible framework that braces the alar rim against collapse during inspiration and expiration. Cartilage grafts may be used in conjunction with flaps and FTSGs to maintain airway patency and to minimize the risk of alar retraction during healing (Fig. 148.9)[44,51–53].

The usefulness of the free cartilage graft lies in its ability to prevent alar retraction. It is possible that long-term survival of the cartilage itself may not ultimately be important, as the mere presence of the rigid framework of the graft in the initial stages of wound healing seems to be sufficient to inhibit alar retraction.

Fig. 148.9 Distortion of the nasal alar rim due to scar retraction from second intention healing following removal of a basal cell carcinoma. Use of free cartilage grafts or composite grafts composed of skin and cartilage can help to prevent this complication. *Courtesy Jean L. Bolognia, MD.*

Downloaded for Anonymous User (n/a) at Egyptian Knowledge Bank from ClinicalKey.com by Elsevier on March 10, 2024. For personal use only. No other uses without permission. Copyright ©2024. Elsevier Inc. All rights reserved.

Nasal Sidewall and Tip

Deep nasal sidewall defects may, at times, involve loss of the upper lateral nasal cartilage. Nasal valve obstruction may result, which becomes noticeable with inspiration and resolves on expiration. Delayed nasal valve obstruction can also occur if unresisted scar contracture collapses the remaining cartilaginous structure of the nasal sidewall. Replacing lost cartilage at the time of reconstruction can avert these potential problems. Similarly, loss of cartilage at the distal nasal tip necessitates structural support replacement for optimal function and cosmesis.

Ear

Auricular defects involving cartilage loss are generally repaired for cosmetic, rather than functional, reasons. Cartilage grafts may be used as braces along the helical rim to minimize the risk of contracture, and may also be used in the conchal bowl to assist in hearing-aid placement[42].

Preoperative History and Donor Site Considerations

Potential donor sites for free cartilage grafts include the conchal bowl, the auricular helix, the antihelix, nasal septum, and ribs[42]. The conchal bowl and antihelix are the donor sites most frequently used by dermatologic surgeons[44,48,53]. Conchal cartilage is elastic, has a high degree of memory, and has varied contours that can be matched to the desired alar contour. Although an anterior approach to the conchal bowl may be used, the posterior approach results in better camouflage of the donor site scar and preservation of the shape of the ear. If the antihelix is used as a donor site, it is recommended that subtotal resection of the antihelical cartilage be performed, leaving a complete rim of intact helical cartilage to prevent distortion.

Description of Technique

Nasal ala

The techniques for alar batten cartilage grafting have been well described[42,44,48,51]. The alar batten provides a rigid but flexible cartilaginous framework to brace against alar rim collapse. The length of the cartilage graft is determined by measuring the distance between the lateral and medial borders of the defect at the alar rim, and adding to that measurement an extra 4–5 mm. The conchal bowl donor site is incised anteriorly or posteriorly, whereas the antihelical donor site is incised anteriorly. The skin overlying the cartilage is then undermined with blunt-scissor dissection to expose the perichondrial surface. The desired length of cartilage is incised with a scalpel (Fig. 148.10A), and a second incision is made exactly parallel to the first, creating a cartilaginous strip that may be 3–6 mm in width, depending upon the desired width of the graft (Video 148.9). Alternatively, a larger disk or oblong-shaped piece may be harvested to match the base of the defect. The cartilage is easily separated from the overlying skin with sharp-scissor dissection. The graft is placed in sterile saline while the donor site is reapproximated with non-absorbable sutures.

The cartilage graft is secured by undermining the soft tissue of the recipient bed medially and laterally with a hemostat or blunt-scissor dissection, and the ends of the graft are inserted into the undermined pockets such that the graft interlocks with its bed (Fig. 148.10B, Videos 148.10 and 148.11). The graft is anchored to its bed with one or two 5–0 absorbable sutures for additional security (Video 148.12). A disk- or oblong-shaped cartilage graft also requires suturing for secure placement.

After the graft has been anchored, a nasolabial transposition flap or FTSG is sutured into place to complete the closure (Fig. 148.10C,D, and see Videos 148.1, 148.2, 148.3, 148.4, 148.5, 148.6). A standard tie-over bolster is placed over the FTSG and secured with 5–0 non-absorbable sutures (see Videos 148.7, 148.8). Sutures are removed at 1 week.

Fig. 148.10 Harvesting and placement of a free cartilage graft. A The posterior conchal bowl donor site has been incised to the level of the perichondrium. The desired length of cartilage was incised with the scalpel, and a second incision made parallel to the first to isolate a cartilaginous strip with its overlying perichondrium. **B** The ends of the cartilaginous strip with its overlying perichondrium have been inserted into pockets undermined on either side of the recipient bed, such that the graft interlocks with its recipient bed on the left nasal ala. The graft is sutured to the underlying dermis with one 5–0 absorbable suture for additional security. **C** A full-thickness skin graft has been sutured into place over the free cartilage graft. **D** Eight-week postoperative view of the full-thickness skin graft and underlying free cartilage graft on the left nasal ala. The alar rim remains in perfect alignment.

Downloaded for Anonymous User (n/a) at Egyptian Knowledge Bank from ClinicalKey.com by Elsevier on March 10, 2024. For personal use only. No other uses without permission. Copyright ©2024. Elsevier Inc. All rights reserved.

Nasal sidewall and tip

Free cartilage grafts used for nasal sidewall and tip reconstruction are harvested in much the same way as free cartilage grafts for alar reconstruction[42]. Nasal sidewall grafts tend to be wider and broader than alar grafts, since they must brace a broader area against the forces of inspiration. Alternatively, multiple cartilaginous strips can be placed perpendicular to the lateral nasal sidewall, and then secured with absorbable or non-absorbable sutures to brace the side of the nose against collapse. After the cartilaginous structure is in place, a flap or FTSG may be performed to cover the remaining cutaneous defect.

Nasal tip grafts for distal nasal reconstruction are organized to provide both proximal and distal structural support, thus optimizing the aesthetic and functional result[42,51,52]. The proximal grafts consist of bilateral batten grafts secured to the lateral cartilages with 5–0 or 6–0 non-absorbable sutures. On top of these may be sewn a dorsal nasal cartilage graft. A columellar strut of cartilage often provides distal support, on top of which may be sewn an additional tip graft. Alar batten grafts secured to the columellar strut and lateral alar soft tissue provide alar rim support. A paramedian forehead flap or melolabial interpolation flap may be placed thereafter to provide coverage of the cutaneous defect.

Ear

If conchal cartilage is used to repair a large helical defect, the cartilage graft should match the defect as closely as possible in size and shape[42]. Harvesting and placing a narrow strip of cartilage matching the helical defect alone will result in helical rim collapse under the forces of wound contraction. If necessary, a partial wedge closure of the defect may be performed to decrease the size of the defect requiring replacement of structural support. The cartilage graft is secured by sewing it to the intact cartilaginous framework with 5–0 absorbable or non-absorbable sutures. The graft is then generally covered with a pedicled retroauricular advancement flap.

Eyelid

Partial-thickness lower eyelid defects with loss of the tarsal plate, as well as full-thickness lower eyelid defects, may be repaired with cartilage grafts. Stabilization of the eyelid margin with free cartilage grafts provides structural support, minimizing the risk of ectropion and preventing corneal desiccation. The technique for performing free cartilage grafts to repair full-thickness and partial-thickness lower eyelid defects is beyond the scope of this chapter, but is well described by Otley and Sherris[42].

Postoperative Care

Regardless of the site of cartilage grafting, care must be taken postoperatively to minimize movement of the graft. Routine wound care is performed to the flap or skin graft overlying the free cartilage graft. Trauma to the area should be minimized.

Complications

Postoperative complications following cartilage grafting are rare. There is a risk of postoperative infection at conchal bowl donor sites, particularly with Gram-negative bacilli, which reside within the external auditory meatus. Appropriate bacterial and fungal cultures of any exudate should be obtained if infection is suspected. Empiric therapy with quinolone antibiotics should be initiated, and modified as sensitivities dictate. When prophylactic antibiotics and appropriate operative technique are used, the risk of suppurative chondritis is extremely low[54].

Postoperative tenderness, swelling, and erythema may herald inflammatory chondritis or perichondritis, which should be treated with cool compresses and nonsteroidal anti-inflammatory drugs for several weeks or even months postoperatively.

Later complications may include graft resorption, displacement or deformation after placement, and extrusion. Surgical revision may be required if these complications occur. Auricular and nasal recipient sites are subject to trauma and are therefore at increased risk of graft displacement and resorption. Every effort should therefore be made intraoperatively to utilize grafts of sufficient thickness and stiffness to resist the forces of trauma and wound contracture, and to anchor these grafts to maximize their stability.

Future Trends

While autologous cartilage is considered the optimal grafting material due to its pliability, accessibility, and ease of harvesting under local anesthesia, its supply may be limited, and harvesting may entail additional morbidity. Other implantable materials for nasal reconstruction have been investigated, including porous, high-density polyethylene implants, which have been well tolerated as replacements for native cartilage in patients requiring rhinoplasty or nasal reconstruction[55,56].

Tissue engineering has been used to generate autologous cartilage implants to fill defects of the nose or outer ear[57]. Chondrocytes can be stimulated with growth factors to increase their proliferative rate and extracellular matrix production. Such chondrocytes, when implanted in a resorbable synthetic scaffold, can thereby be induced to produce three-dimensional aggregates of cartilage. In one study, collagen lattices containing cultured chondrocytes implanted into rabbit auricular cartilage generated new cartilage within 5 weeks[57]. *In vitro* engineering of human cartilage could be the ideal replacement method, without the risk of infection and with the possibility of reconstructing large defects with different configurations. In a first-in-human trial, autologous chondrocytes harvested from the nasal septum were cultured in media with autologous serum and seeded onto collagen type I and type III membranes[58]. After 4 weeks, the resulting engineered cartilage grafts, 25 × 25 × 2 mm, were successfully implanted beneath forehead or nasolabial flaps, just as native auricular cartilage would have been, with comparable aesthetic and functional results. These and newer implantable materials should become increasingly available over time, and will undoubtedly be useful for surgeons who perform nasal reconstruction.

CONCLUSIONS

A working knowledge of the indications, techniques, donor site considerations, and postoperative complications of all types of skin grafts is necessary for soft tissue reconstruction. As the incidence of skin cancer continues to rise, increasing numbers of patients are likely to undergo reconstructive procedures requiring full-thickness skin and/or cartilage grafting. Lower extremity ulcers are another common problem, and split-thickness skin grafting remains an effective, reasonable treatment for such patients. With proper defect assessment, reconstructive planning, and attention to detail preoperatively, intraoperatively and postoperatively, optimal cosmetic and functional results can be achieved using the full range of grafting techniques, a thorough understanding of which is therefore invaluable for all physicians performing reconstructive surgery.

Additional figures available in our eBook (see inside front cover for access code).

REFERENCES

1. Hauben DJ, Baruchin A, Mahler A. On the history of the free skin graft. *Ann Plast Surg*. 1982;9:242–245.
2. Ratner D. Skin grafting. *Semin Cutan Med Surg*. 2003;22:295–305.
3. Adams DC, Ramsey ML. Grafts in dermatologic surgery: review and update on full- and split-thickness grafts, free cartilage grafts and composite grafts. *Dermatol Surg*. 2005;31:1055–1067.
4. Smahel J. The healing of skin grafts. *Clin Plast Surg*. 1977;4:409–424.
5. Goldminz D, Bennett RG. Cigarette smoking and flap and full-thickness graft necrosis. *Arch Dermatol*. 1991;127:1012–1015.
6. Walden JL, Garcia H, Hawkins H, et al. Both dermal matrix and epidermis contribute to an inhibition of wound contraction. *Ann Plast Surg*. 2000;45:162–166.
7. Gloster Jr. HM. The use of full-thickness skin grafts to repair nonperforating nasal defects. *J Am Acad Dermatol*. 2000;42:1041–1050.
8. Rohrer TE, Dzubow LM. Conchal bowl skin grafting in nasal tip reconstruction: clinical and histologic evaluation. *J Am Acad Dermatol*. 1995;33:476–481.
9. Zitelli JA. Burow's grafts. *J Am Acad Dermatol*. 1987;17:271–279.
10. Krishnan R, Hwang L, Orengo I. Dog-ear graft technique. *Dermatol Surg*. 2001;27:312–314.
11. Kaufman AJ. Adjacent-tissue skin grafts for reconstruction. *Dermatol Surg*. 2004;30:1349–1353.
12. Wang Q, Cai M, Wu YL, Zhang GC. Mathematical guide to minimize donor site in full-thickness skin grafting. *Dermatol Surg*. 2009;35:1364–1367.
13. Hill TG. Contouring of donor skin in full-thickness skin grafting. *J Dermatol Surg Oncol*. 1987;13:883–888.
14. Larson PO, Ragi G, Mohs FE, Snow SN. Excision of exposed cartilage for management of Mohs surgery defects of the ear. *J Dermatol Surg Oncol*. 1991;17:749–752.
15. Craven NM, Telfer NR. An open study of tissue adhesive in full-thickness skin grafting. *J Am Acad Dermatol*. 1999;40:607–611.

Downloaded for Anonymous User (n/a) at Egyptian Knowledge Bank from ClinicalKey.com by Elsevier on March 10, 2024. For personal use only. No other uses without permission. Copyright ©2024. Elsevier Inc. All rights reserved.

16. Orengo I, Lee MW. Surgical pearl: the "unsuture" technique for skin grafts. *J Am Acad Dermatol*. 1998;38:758–759.
17. Langtry JA, Kirkham P, Martin IC, Fordyce A. Tie-over bolster dressings may not be necessary to secure small full thickness skin grafts. *Dermatol Surg*. 1998;24:1350–1353.
18. Kromka W, Cameron M, Fathi R. Tie-over bolster dressings vs basting sutures for the closure of full-thickness skin grafts: a review of the literature. *J Cut Med Surg*. 2018;22:602–606.
19. Adams DC, Ramsey ML, Marks VJ. The running bolster suture for full-thickness skin grafts. *Dermatol Surg*. 2004;30:92–94.
20. Srivastava D, Kouba DJA. "Lilliputian" technique for rapid and efficient securing of bolster dressings over full-thickness skin grafts. *Dermatol Surg*. 2009;35:1280–1281.
21. Brady JG, Grande DJ, Katz AE. The purse-string suture in facial reconstruction. *J Dermatol Surg Oncol*. 1992;18:812–816.
22. Halpern ME, Adams C, Ratner D. Galeal hinge flaps: a useful technique for immediate repair of scalp defects extending to periosteum. *Dermatol Surg*. 2009;35:1127–1130.
23. Robinson JK, Dillig G. The advantages of delayed nasal full-thickness skin grafting after Mohs micrographic surgery. *Dermatol Surg*. 2002;28:845–851.
24. Meyers S, Rohrer T, Grande D. Use of dermal grafts in reconstructing deep nasal defects and shaping the ala nasi. *Dermatol Surg*. 2001;27:300–305.
25. Draper BL, Wentzell JM. The "drumhead" graft repair of deep nasal alar defects. *Dermatol Surg*. 2007;33:17–22.
26. Gloster Jr HM, Brodland DG. The use of perichondrial cutaneous grafts to repair defects of the lower third of the nose. *Br J Dermatol*. 1997;136:43–46.
27. Thibault MJ, Bennett RG. Success of delayed full-thickness skin grafts after Mohs micrographic surgery. *J Am Acad Dermatol*. 1995;32:1004–1009.
28. Callahan S, Goldsberry A, Kim G, Yoo S. The management of antithrombotic medication in skin surgery. *Dermatol Surg*. 2012;38:1417–1426.
29. Nehal KS, Levine VJ, Ross B, Ashinoff R. Comparison of high-energy pulsed carbon dioxide laser resurfacing and dermabrasion in the revision of surgical scars. *Dermatol Surg*. 1998;24:647–650.
30. Leventhal D, Furr M, Reiter D. Treatment of keloids and hypertrophic scars: a meta-analysis and review of the literature. *Arch Facial Plast Surg*. 2006;8:362–368.
31. Stephenson AJ, Griffiths RW, La Hausse-Brown TP. Patterns of contraction in human full thickness skin grafts. *Br J Plast Surg*. 2000;53:397–402.
32. Michelotti B, Mathis R, Roberts J, et al. Periorbital Mohs reconstruction: characterization of tumor histology, anatomic location, and factors influencing postoperative complications. *Dermatol Surg*. 2014;40:1084–1093.
33. Can Z, Ercocen AR, Apaydin I, et al. Tissue engineering of high density porous polyethylene implant for three-dimensional reconstruction: an experimental study. *Scand J Plast Reconstr Surg Hand Surg*. 2000;34:9–14.
34. Baltazar T, Merola J, Catarino C, et al. Three dimensional bioprinting of a vascularized and perfusable skin graft using human keratinocytes, fibroblasts, pericytes, and endothelial cells. *Tissue Eng Part A*. 2020;26:227–238.
35. Kneiling M, Breuninger H, Schippert W, et al. A modified, improved, easy and fast technique for split-thickness skin grafting. *Brit J Dermatol*. 2011;165:581–584.
36. Field LM. Harvesting split-thickness grafts in direct continuity with "op-site" membrane biologic dressings [letter]. *Dermatol Surg*. 1995;21:357–359.
37. Rakel BA, Bermel MA, Abbott LI, et al. Split-thickness skin graft donor site care: a quantitative synthesis of the research. *Appl Nurs Res*. 1998;11:174–182.
38. Nappi JF, Falcone RE, Ruberg RL. Meshed skin grafts versus sheet skin grafts on a contaminated bed. *J Dermatol Surg Oncol*. 1984;10:380–381.
39. Horch RE, Debus M, Wagner G, Stark GB. Cultured human keratinocytes on type I collagen membranes to reconstitute the epidermis. *Tissue Eng*. 2000;6:53–67.
40. Suzuki S, Shin-ya K, Kawai K, Nishimura Y. Application of artificial dermis prior to full-thickness skin grafting for resurfacing the nose. *Ann Plast Surg*. 1999;43:439–442.
41. Metcalfe AD, Ferguson MW. Bioengineering skin using mechanisms of regeneration and repair. *Biomaterials*. 2007;28:5100–5103.
42. Otley CC, Sherris DA. Spectrum of cartilage grafting in cutaneous reconstructive surgery. *J Am Acad Dermatol*. 1998;39:982–992.
43. Haas AF, Glogau RG. A variation of composite grafting for reconstruction of full-thickness nasal alar defects. *Arch Dermatol*. 1994;130:978–980.
44. Adams C, Ratner D. Composite and free cartilage grafting. *Dermatol Clin*. 2005;23:129–140. vii.
45. Geyer AS, Pasternack F, Adams C, Ratner D. Use of a skin-fat composite graft to prevent alar notching: an alternative to the delayed postoperative repair. *Dermatol Surg*. 2005;31:602–607.
46. Ratner D, Katz A, Grande DJ. An interlocking auricular composite graft. *Dermatol Surg*. 1995;21:789–792.
47. Weisberg NK, Becker DS. Repair of nasal ala defects with conchal bowl composite grafts. *Dermatol Surg*. 2000;26:1047–1051.
48. Haug MD, Rieger UM, Gubisch W. Managing the ear as a donor site for composite graft in nasal reconstruction: update on technical refinements and donor site management in 110 cases. *Ann Plast Surg*. 2009;63:171–175.
49. Lu GN, Tawfik O, Sykes K, et al. Association of skin and cartilage variables with composite graft healing in a rabbit model. *JAMA Facial Plastic Surg*. 2019;21:44–49.
50. Albertini JG, Ramsey ML. Surgical pearl: delayed intranasal knot tying for composite grafts of the ala. *J Am Acad Dermatol*. 1998;39:787–788.
51. Otley CC. Alar batten cartilage grafting. *Dermatol Surg*. 2000;26:969–972.
52. Byrd DR, Otley CC, Nguyen TH. Alar batten cartilage grafting in nasal reconstruction: functional and cosmetic results. *J Am Acad Dermatol*. 2000;43:833–836.
53. Zopf DA, Iams W, Kim JC, et al. Full-thickness skin graft overlying a separately harvested auricular cartilage graft for alar reconstruction. *JAMA Facial Plastic Surg*. 2013;15:131–134.
54. Kaplan AL, Cook JL. The incidences of chondritis and perichondritis associated with the surgical manipulation of auricular cartilage. *Dermatol Surg*. 2004;30:58–62. discussion 62.
55. Williams JD, Romo III T, Sclafani AP, Cho H. Porous high-density polyethylene implants in auricular reconstruction. *Arch Otolaryngol Head Neck Surg*. 1997;123:578–583.
56. Naumann A, Rotter N, Buija J, Aigner J. Tissue engineering of autologous cartilage transplants for rhinology. *Am J Rhinol*. 1998;12:59–63.
57. Sterodimas A, DeFaria J, Correa WE, Pitangiy I. Tissue engineering in plastic surgery: an up-to-date review of the current literature. *Ann Plast Surg*. 2009;62:97–103.
58. Fulco I, Miot S, Haug MD, et al. Engineered autologous cartilage tissue for nasal reconstruction after tumour resection: an observational first-in-human trial. *Lancet*. 2014;384:337–346.

Downloaded for Anonymous User (n/a) at Egyptian Knowledge Bank from ClinicalKey.com by Elsevier on March 10, 2024. For personal use only. No other uses without permission. Copyright ©2024. Elsevier Inc. All rights reserved.

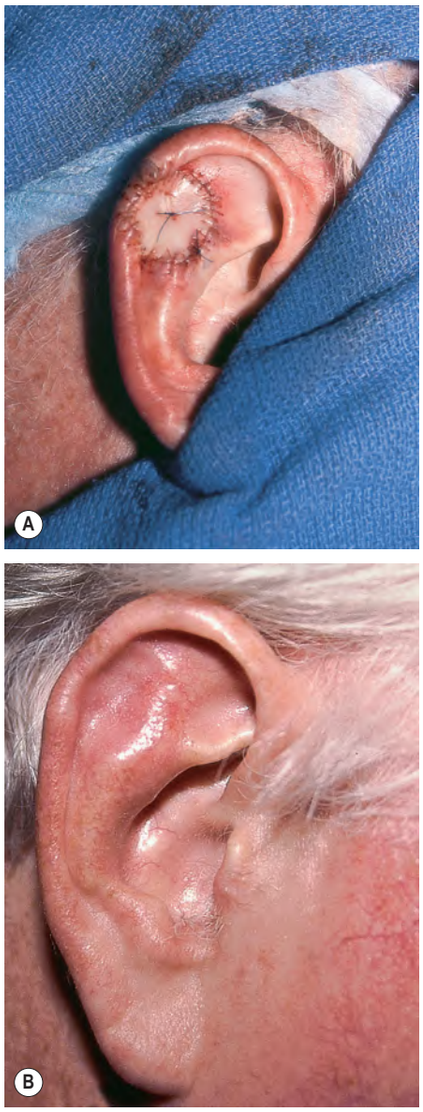

eFig. 148.1 Full-thickness skin graft. A Full-thickness skin graft taken from the preauricular region was used to repair this defect of the right upper anterior ear. **B** Eight-week postoperative result.

Downloaded for Anonymous User (n/a) at Egyptian Knowledge Bank from ClinicalKey.com by Elsevier on March 10, 2024. For personal use only. No other uses without permission. Copyright ©2024. Elsevier Inc. All rights reserved.