Graft-versus-Host Disease 52

Jennifer T. Huang and Edward W. Cowen

Key features

- Currently, over 35 000 allogeneic hematopoietic stem cell transplants (HSCTs) are performed worldwide each year
- An HLA-matched sibling donor is the ideal donor source
- Nowadays nearly all eligible patients can receive an allogeneic HSCT due to the increased use of alternative stem cell sources including matched unrelated donors, haploidentical donors, and umbilical cord blood
- Reduced intensity conditioning regimens allow older patients and those with comorbidities to receive allogeneic HSCTs
- Donor lymphocyte infusions as well as withdrawal of immunosuppression may impact the incidence, timing, and presentation of graft-versus-host disease (GVHD)
- Acute GVHD is a major complication of allogeneic HSCT; severe skin involvement, although uncommon, is associated with a high mortality rate
- Chronic cutaneous GVHD is a polymorphous condition with features that can resemble lichen planus, lichen sclerosus, morphea, and eosinophilic fasciitis
- Chronic cutaneous GVHD is difficult to treat and the aggressiveness of treatment must be balanced against the complications of chronic immunosuppression

INTRODUCTION

Graft-versus-host disease (GVHD) is a multi-organ disorder most commonly due to the transfer of foreign donor hematopoietic stem cells into a host recipient via an allogeneic hematopoietic stem cell transplant (HSCT). GVHD may also occur following transfusion of non-irradiated blood products (to immunocompromised hosts) or rarely in the setting of solid organ transplantation. Despite decades of experience with HSCT for a broadening array of disorders (Table 52.1), GVHD remains a significant cause of non-relapse-related morbidity and mortality.

HISTORY

The first successful allogeneic bone marrow transplant was performed in 1968. Subsequent advances in histocompatibility antigen testing increased safety, while establishment of bone marrow donor registries made HSCT accessible to thousands of patients each year who lacked a matched related donor. The introduction of alternative stem cell sources, including matched unrelated donors and especially haploidentical family donors, has led to a further increase in the number of transplants. In addition, when neither of these donor sources is available, umbilical cord stem cells represent a more universal option because a greater degree of mismatch is better tolerated. The evolution of reduced intensity conditioning regimens has permitted older patients and those with comorbidities to receive HSCTs. Post-transplant cyclophosphamide, initially introduced for haploidentical HSCTs, is increasingly being used for matched sibling and matched unrelated donor (MUD) HSCTs where it has significantly reduced the incidence and severity of acute and chronic GVHD.

EPIDEMIOLOGY

Currently, over 35 000 allogeneic HSCTs are performed worldwide each year. Although a variety of donor and recipient factors ultimately impact GVHD incidence (e.g. older age, T cell-replete graft), the most important predictor of GVHD remains HLA compatibility between donor and recipient. With traditional immunosuppression consisting of a calcineurin inhibitor plus either methotrexate or mycophenolate mofetil, ~40% of HLA-identical HSCT recipients and 60%–70% of HLA-mismatched HSCT recipients will develop GVHD. Of note, post-transplant cyclophosphamide (given on days +3 and +4) significantly reduces the incidence and severity of acute and chronic GVHD via enrichment of regulatory T cells. In addition, abatacept has recently been approved for prophylaxis against acute GVHD.

Because of ease of acquisition and more rapid engraftment, peripheral blood has surpassed bone marrow as the predominant source of stem cells. The one disadvantage is that peripheral blood has been associated with an increased risk of chronic GVHD (cGVHD)[1]. Cord blood stem cells are used primarily in children because of higher rates of non-engraftment in adults. The two major advantages of cord blood transplantation are: (1) decreased incidence of GVHD; and (2) nearly universal availability of donors for patients who lack matched related or unrelated donors.

Several other trends in HSCT are affecting the natural history of GVHD. Removal of donor T cells ("T cell depletion") prior to transplantation through *ex vivo* graft manipulation (e.g. cell separation), or *in vivo* treatment of the recipient (e.g. antithymocyte globulin, alemtuzumab), significantly decreases the risk of GVHD, but at the expense of increased infection rates. The advent of reduced intensity conditioning regimens has decreased conditioning-related toxicities (e.g. mucositis) and allowed for HSCT in older patients and those with comorbidities. While these regimens appear to decrease the risk of acute GVHD (aGVHD), they may also delay the appearance of "classic" aGVHD manifestations. The use of total body irradiation for conditioning (in place of or in conjunction with chemotherapy) may confer an increased risk for the later development of cGVHD[2]. Finally, donor lymphocyte infusions (DLI), administered to the recipient post-HSCT to augment the graft-versus-tumor effect or to attempt to reverse falling donor chimerism, can alter the traditional timing of both "acute" and "chronic" disease. For instance, DLI may induce classic aGVHD manifestations even when administered after the 100-day time period.

PRIMARY DISORDERS TREATED WITH ALLOGENEIC HEMATOPOIETIC STEM CELL TRANSPLANTATION
• Leukemias (e.g. acute myelogenous, acute lymphoblastic > chronic myelogenous, chronic lymphocytic)
• Lymphomas (e.g. non-Hodgkin)
• Bone marrow failure (e.g. aplastic anemia, dyskeratosis congenita, Fanconi anemia)
• High-risk myelodysplasia
• Immunodeficiencies (e.g. severe combined immunodeficiency, Griscelli syndrome [type 2], Chédiak–Higashi syndrome, Wiskott–Aldrich syndrome, ataxia–telangiectasia syndrome, chronic granulomatous disease, DiGeorge syndrome, familial hemophagocytic lymphohistiocytosis, GATA2 deficiency, DOCK8 immunodeficiency syndrome)
• Other myeloproliferative disorders (e.g. myelofibrosis)
• Other hematologic disorders (e.g. plasma cell dyscrasias including myeloma, hypereosinophilic syndrome, paroxysmal nocturnal hemoglobinuria, sickle cell disease, thalassemia)
• Metabolic disorders (e.g. fucosidosis, Gaucher disease, mucopolysaccharidoses)
• Autoimmune diseases (e.g. ALPS, IPEX syndrome)
• Miscellaneous (e.g. congenital erythropoietic porphyria [Günther disease], histiocytoses, epidermolysis bullosa)

Table 52.1 Primary disorders treated with allogeneic hematopoietic stem cell transplantation. ALPS, autoimmune lymphoproliferative syndrome; IPEX, immune dysregulation, polyendocrinopathy, X-linked.

Downloaded for Anonymous User (n/a) at Egyptian Knowledge Bank from ClinicalKey.com by Elsevier on March 10, 2024. For personal use only. No other uses without permission. Copyright ©2024. Elsevier Inc. All rights reserved.

The skin is the most frequently affected organ in both aGVHD and cGVHD. Approximately 80% of patients who develop aGVHD have skin involvement at the time of diagnosis[3]. The incidence of skin involvement in patients with cGVHD ranges from 30%–40%[4]. In one institutional review of 270 consecutive patients following HLA-identical HSCT, only 7 (13%) of 53 patients with cGVHD manifested sclerotic features[5]. In contrast, in a cross-sectional cohort of 206 NIH cGVHD patients enriched for refractory disease, sclerotic features were detected in 109 (53%)[2].

PATHOGENESIS

The current model for aGVHD pathogenesis can be summarized in a three-step process. First, HSCT conditioning and consequent damage to host tissues leads to activation of *host* antigen-presenting cells (APCs). Second, *donor* T cells proliferate in response to contact with activated APCs. Finally, destruction of target tissues (skin, liver, gastrointestinal tract) occurs via cytotoxic T lymphocytes, natural killer cells, and soluble factors (TNF, IFN-γ, IL-1, nitric oxide)[6]. Recently, humanized mouse models have demonstrated that *donor* APC activation of *host* resident T cells can also elicit a graft-versus-host response. These two proposed mechanisms may not contradict, but rather complement, one another and suggests multiple pathways of disease pathogenesis.

A clear understanding of cGVHD is still lacking and available murine models recapitulate only select features of human disease (e.g. sclerotic skin involvement, autoantibodies). Alloreactive T cells are again thought to play a central role, but a number of other immune mediators have been increasingly implicated. Many cGVHD manifestations resemble autoimmune disease, suggesting a role for B cells in the disease process. Indeed, rituximab (anti-CD20 antibody) is a beneficial salvage therapy in some patients. B cells appear to prime T cells to minor histocompatibility antigens, and serum levels of *B* cell *a*ctivating *f*actor of the TNF *f*amily (BAFF), a marker of B cell activation, correlate with cGVHD. Multiple autoantibodies are often present in patients with cGVHD, including anti-nuclear, anti-dsDNA, and anti-smooth muscle antibodies, although, to date, they have not been shown to correlate with specific disease manifestations. Activating antibodies against the platelet-derived growth factor receptor (PDGFR) were observed in patients with cGVHD, suggesting that targeting this receptor and its profibrotic pathway with agents such as imatinib mesylate could improve cGVHD[7]. However, the functional significance of these antibodies remains uncertain[8].

HSCT recipients have also been shown to have a deficiency of regulatory T cells (Tregs) due to decreased thymic differentiation. Tregs are integral to the development and maintenance of self-tolerance, and impairment of Treg function is associated with autoimmunity. In mouse models of allogeneic HSCT, adoptive transfer of Tregs has been shown to ameliorate signs and symptoms of cGVHD[9]. A possible role for Th17 cells was suggested by elevated levels of IL-17 and -22 in tissue and plasma in patients and mouse models of cutaneous cGVHD[10,11] and IL-17 inhibitors have been investigated as treatment for cGVHD[12]. Of note, different mechanisms may underlie cGVHD based on duration and phenotype of disease[13].

CLINICAL FEATURES

Acute GVHD

Acute GVHD presents in the skin as a morbilliform exanthem (Fig. 52.1), with an initial predilection for acral areas (e.g. dorsal hands and feet, palms, soles, forearms, ears), as well as the upper trunk. Lesions most commonly appear 4–6 weeks following HSCT despite prophylactic immunosuppressive therapy. Pruritus is variable and a folliculocentric pattern may be observed. Patients may be thrombocytopenic, which can give the eruption a hemorrhagic appearance. The gastrointestinal tract (nausea, voluminous diarrhea, abdominal pain) and the liver (cholestasis > transaminitis) are the two other primary organ systems affected by aGVHD. Together with body surface area of skin involvement, these manifestations are used for staging and grading of disease severity (Table 52.2). Stage IV acute skin disease consists of generalized involvement with bullae formation which may lead to skin sloughing resembling toxic epidermal necrolysis and portends a very low likelihood of survival. Fortunately, this degree of severity is nowadays rarely seen.

Chronic GVHD

In contrast to aGVHD, cGVHD may manifest in nearly any organ system (Fig. 52.2). Skin and mucosal involvement are exceedingly common, but there is remarkable variability in both presentation and severity. Other common sites of involvement include the eyes (keratoconjunctivitis sicca, blepharitis, corneal erosions), salivary glands (sicca syndrome), and lungs (bronchiolitis obliterans); less commonly, the esophagus (strictures, webs), liver, and pancreas (exocrine insufficiency) are affected.

Fig. 52.1 Clinical spectrum of acute cutaneous graft-versus-host disease. A *Stage I* – discrete and coalescing small pink papules on the upper chest and neck of a woman 6 weeks following allogeneic bone marrow transplant. **B, C** *Stage II* – pink macules and papules on the dorsal aspect of the hands that are becoming confluent 4 weeks post allogeneic bone marrow transplant, and widespread pink–violet macules and papules on the abdomen in a liver transplant recipient. **D** *Stage III* – diffuse erythema with desquamation, but without bullae formation. **E** *Stage IV* – widespread bullae and epidermal necrosis in a patient who had received a donor lymphocyte infusion (DLI) following allogeneic bone marrow transplant; note the resemblance to toxic epidermal necrolysis. *C, Courtesy Julie V. Schaffer, MD.*

Downloaded for Anonymous User (n/a) at Egyptian Knowledge Bank from ClinicalKey.com by Elsevier on March 10, 2024. For personal use only. No other uses without permission. Copyright ©2024. Elsevier Inc. All rights reserved.

CLINICAL STAGING OF ACUTE GRAFT-VERSUS-HOST DISEASE (aGVHD)			
Stage	**Skin**	**Liver**	**Gut**
1	Erythematous macules and papules, <25% BSA	Bilirubin 2 to <3 mg/dl	Diarrhea, 500–1000 ml/day, or persistent nausea
2	Erythematous macules and papules, 25%–50% BSA	Bilirubin 3–6 mg/dl	Diarrhea, 1000–1500 ml/day
3	Erythematous macules and papules (>50% BSA) to generalized erythroderma	Bilirubin 6–15 mg/dl	Diarrhea, >1500 ml/day
4	Generalized erythroderma with bulla formation	Bilirubin >15 mg/dl	Severe abdominal pain with or without ileus

Table 52.2 Clinical staging of acute graft-versus-host disease (aGVHD). Grade I aGVHD represents stage 1 or 2 cutaneous aGVHD while grade II aGVHD represents stage 3 cutaneous aGVHD; neither grade I nor II have significant liver or gut involvement. Grades III and IV aGVHD require internal involvement. BSA, body surface area.

DIAGNOSTIC MUCOCUTANEOUS MANIFESTATIONS OF CHRONIC GRAFT-VERSUS-HOST DISEASE
Skin
Lichen planus-like (Fig. 52.3A) Lichen sclerosus-like (Fig. 52.3B) Morphea-like (Fig. 52.3C,D) Scleroderma-like (Fig. 52.3F) Fasciitis (Fig. 52.4) Poikiloderma
Oral mucosa
Keratotic plaques Lichen planus-like (Fig. 52.6B) Restriction of oral opening from sclerosis
Genital mucosa
Lichen planus-like (Fig. 52.6A) Vaginal scarring and/or stenosis

Table 52.3 Diagnostic mucocutaneous manifestations of chronic graft-versus-host disease (based on NIH Consensus Criteria[14]). For involvement of other organs, see Fig. 52.2.

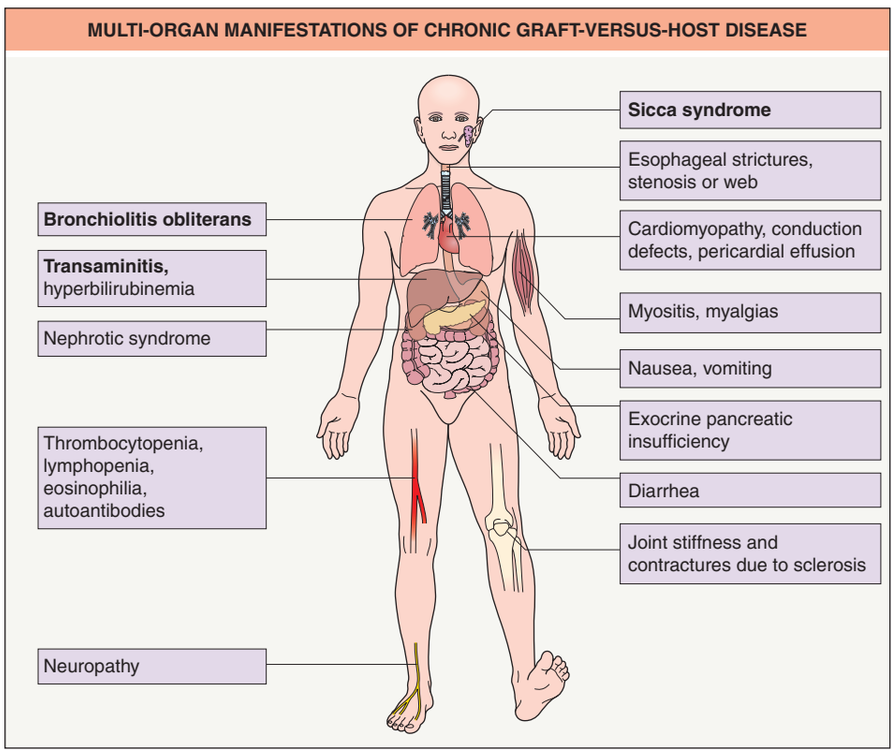

Fig. 52.2 Protean multi-organ manifestations of chronic graft-versus-host disease. The most common manifestations are in **bold**.

In the past, differentiation of aGVHD and cGVHD was linked to time of onset following HSCT (≤ or >100 days); however, this is a somewhat arbitrary distinction and newer HSCT regimens have altered the onset of classic aGVHD and cGVHD manifestations. As a result, acute features may first present after day 100 (delayed acute GVHD). In addition, features of aGVHD can be seen in patients who also meet the diagnostic criteria for cGVHD and is referred to as overlap cGVHD. The NIH Consensus Project proposed a classification of cGVHD using organ-specific criteria[14]. "Diagnostic" criteria, i.e. those skin manifestations sufficient to make a clinical diagnosis of cGVHD, are provided in Table 52.3. "Distinctive" cGVHD criteria (e.g. papulosquamous lesions, vitiligo, alopecia) require exclusion of other possible etiologies.

The most characteristic manifestation of epidermal cGVHD involvement is reticulate pink to violaceous papules and plaques with overlying scale, which in some patients resembles lichen planus (LP; Fig. 52.3A). Lesions often initially involve the dorsal aspects of the hands and feet, the forearms and trunk, but they can become widespread. In the past, the term "lichenoid" was used as a broad term which encompassed this presentation as well as all other non-sclerotic cGVHD skin eruptions. In light of the greater appreciation for the breadth of clinical presentations of cutaneous cGVHD and to utilize more precise diagnostic terminology, the term "lichenoid" should be reserved for histologic description rather than as designation of a GVHD phenotype. In addition to LP-like lesions, psoriasiform plaques, keratosis pilaris-like follicular erythema, a subacute cutaneous LE-like eruption, or poikiloderma may develop (Table 52.4). Epidermal cGVHD involvement often leaves a remarkable patterned hyperpigmentation which is often reticulated and resolves very slowly over several months.

Similar to the use of "lichenoid", the single designation "sclerodermoid" cGVHD is inadequate to describe the spectrum of sclerotic skin and subcutaneous tissue presentations. Sclerotic involvement includes superficial lichen sclerosus-like plaques, localized or widespread morphea-like involvement, and subcutaneous rippling of the skin with joint contractures resembling eosinophilic fasciitis[15]. Lichen sclerosus-like involvement commonly presents as shiny, wrinkled, gray–white plaques on the upper back (Fig. 52.3B); there may be associated follicular plugging. Morphea-like (morpheaform) areas of sclerosis may occur anywhere on the body, but frequently localize to sites of previous

Downloaded for Anonymous User (n/a) at Egyptian Knowledge Bank from ClinicalKey.com by Elsevier on March 10, 2024. For personal use only. No other uses without permission. Copyright ©2024. Elsevier Inc. All rights reserved.

Fig. 52.3 Clinical spectrum of chronic cutaneous graft-versus-host disease. A Lichen planus-like: thin pink–violet papules and plaques with scale, admixed with postinflammatory hyperpigmentation. **B** Lichen sclerosus-like: multiple gray–white thin plaques with obvious wrinkling are present on the mid back. **C, D** Morphea-like: shiny, hyperpigmented, sclerotic plaques extending from the breasts to the lateral torso and in the girdle area; the latter is a common site of involvement for this form of cGVHD. **E** Morphea-like: sclerotic hyperpigmented plaque on the upper arm, with shiny bound-down skin of the forearm and dorsal hand; note the joint contractures. **F** Scleroderma-like: the skin is shiny and bound-down with dyspigmentation, hair loss, multiple erosions and ulceration; angiomatous nodules and marked reduction in range of motion of the ankles are also present.

ADDITIONAL CUTANEOUS MANIFESTATIONS OF CHRONIC GRAFT-VERSUS-HOST DISEASE (cGVHD)
Skin lesions
• Psoriasiform, eczematous/dyshidrotic, SCLE-like, pityriasis rosea-like • Eczema craquelé, ichthyosis-like, keratosis pilaris-like follicular erythema • Hypo- or hyperpigmentation, vitiligo (Fig. 52.5A) • Angiomatous nodules (Fig. 52.3F) • Calcinosis cutis
Hair
• New-onset alopecia (patchy > diffuse; scarring or non-scarring; Fig. 52.5B), alopecia areata • Premature graying
Nails
• Ridging, thinning, splitting, brittleness, onycholysis, dorsal pterygium, anonychia (Fig. 52.5C)
Oral mucosa
• Gingivitis, mucositis, pseudomembranes, ulcers (Fig. 52.6B) • Xerostomia*, mucosal atrophy, mucocele
Genital mucosa
• Fissures, erosions, ulcers, balanitis, phimosis (Fig. 52.6C)
*For xerostomia treatment regimen, see Table 45.5.

Table 52.4 Additional cutaneous manifestations of chronic graft-versus-host disease (cGVHD). These clinical findings are considered non-diagnostic, i.e. insufficient to establish a diagnosis of chronic GVHD without further testing or evidence of other organ system involvement. SCLE, subacute cutaneous lupus erythematosus.

Fig. 52.4 Eosinophilic fasciitis-like presentation of chronic cutaneous graft-versus-host disease. A rippled appearance and irregular nodular texture to the skin is indicative of involvement of subcutaneous tissues. Especially in the earlier, edematous phase, the presence of hypereosinophilia may be a clue to the diagnosis.

skin injury (e.g. port placement sites) as well as areas of friction (e.g. the waistband) (Fig. 52.3C–E). In young children, the diaper area can be the initial area of involvement. In contrast to systemic sclerosis, cGVHD is rarely associated with sclerodactyly, pinched facies, or Raynaud phenomenon[15]. Deep-seated fibrosis of the subcutaneous tissue and fascia may present with insidious loss of joint range-of-motion or as nonspecific myalgias and cramping. Subtle rippling of the overlying skin may be present with a firm, nodular texture noted with deep palpation (Fig. 52.4). Linear depressions within sites of fascial involvement (groove sign) demarcate the path of vascular structures or fascial bundles. Longstanding fibrosis may result in skin ulceration, particularly of the legs and frictional surfaces, and the proliferation of benign angiomatous nodules[16] (Fig. 52.3F).

Vitiligo can develop within skin affected by cGVHD as well as uninvolved skin. It occurs in 1%–2% of patients who have had an HSCT and ~5% of patients with cGVHD[17,18]. The presence of vitiligo should alert the clinician to examine for additional evidence of cGVHD (Fig. 52.5A,B).

Mucosal surfaces are frequently affected by cGVHD (Fig. 52.6). Oral involvement resembles LP with lacy white plaques on the non-attached mucosa, ulceration, and gingivitis. Cheilitis is also a common manifestation (see Figs. 72.15 & 72.16F) and the development of mucoceles is an additional clinical finding. Genital involvement, ranging from

Downloaded for Anonymous User (n/a) at Egyptian Knowledge Bank from ClinicalKey.com by Elsevier on March 10, 2024. For personal use only. No other uses without permission. Copyright ©2024. Elsevier Inc. All rights reserved.

Fig. 52.5 Additional cutaneous findings in chronic graft-versus-host disease. **A** Vitiligo with patches of amelanosis; note the nail dystrophy. **B** Scarring alopecia and vitiligo in the setting of extensive sclerotic cGVHD. **C** Nail thinning, splitting, and dorsal pterygium formation.

erythema and fissuring to labial resorption and fusion, can occur in as many as 50% of female patients[19]. Symptoms of burning, pruritus, and dyspareunia are common. Scarring of the vagina may lead to shortening and narrowing of the vaginal canal and risk of hematocolpos in menstruating women. Male genital involvement is less common, but includes balanoposthitis and lichen planus-like lesions, and phimosis may develop in some patients.

Nail changes in cGVHD range from thin, brittle nails with distal splitting to dorsal pterygium and anonychia (Fig. 52.5C). In children, nail dystrophy, particularly dorsal pyterygium, has been associated with pulmonary cGVHD[20]. Additional cutaneous findings include facial milia, alopecia areata, angiomatous nodules, scarring alopecia, and calcinosis cutis. The latter three entities are seen in patients with sclerotic disease and calcinosis cutis may contribute to decreased range of motion[21].

PATHOLOGY

Histologically, aGVHD is characterized by widespread keratinocyte necrosis, basal layer hydropic degeneration, and a band-like lymphohistiocytic infiltrate in the upper dermis (Fig. 52.7). However, skin biopsies obtained shortly after disease onset may display more subtle findings, e.g. only focal vacuolar change of basal keratinocytes, and histologic features of aGVHD may be limited to the hair follicle. In addition, these histologic features overlap with those of viral exanthems and drug eruptions, making a definitive diagnosis difficult to render in some patients. With increasing severity of aGVHD, basilar vacuoles can fuse to form clefts and microvesicles and even complete separation of epidermis from dermis.

The histology of cGVHD reflects the variable skin manifestations of the condition[22]. cGVHD with epidermal involvement may resemble aGVHD, but with a more robust lichenoid infiltrate and additional features of epidermal orthohyperkeratosis, hypergranulosis, and variable (usually mild) acanthosis. The sclerotic subtypes of cGVHD may have concurrent epidermal features or may only demonstrate sclerosis of the dermis (Fig. 52.8), subcutaneous tissue, and/or fascia. Thickening of subcutaneous fat septae indicates a deep-seated sclerosis and magnetic resonance imaging may be helpful to identify fascial involvement (Fig. 52.9).

DIFFERENTIAL DIAGNOSIS

The primary differential diagnosis of aGVHD is morbilliform drug eruption, viral exanthem, and engraftment syndrome (Table 52.5). If there is prominent acral involvement, particularly involvement of the palms and soles, toxic erythema of chemotherapy should be considered, especially if there is flexural involvement and in men, scrotal burning and erythema. The possibility of a viral exanthem is more likely in children and is favored if conjunctivitis, rhinorrhea, or cough are present. Engraftment syndrome often presents with fever and fluid overload, including pulmonary edema, at the time of neutrophil engraftment (see Table 52.5).

Because of its clinical variability, the differential diagnosis of cGVHD is much broader, and includes lichenoid drug eruptions, autoimmune connective tissue diseases (lupus, dermatomyositis, morphea, systemic sclerosis), and papulosquamous disorders. Reports of transient acantholytic dermatosis[23] and voriconazole-associated photosensitivity[24] misdiagnosed as cGVHD emphasize the value of biopsy confirmation when non-diagnostic clinical features are encountered.

TREATMENT

Acute GVHD

Limited cutaneous aGVHD (without other organ involvement) may initially be managed with topical corticosteroids while patients with more extensive skin involvement or internal manifestations require systemic treatment. First-line therapy consists of adding oral prednisone or IV methylprednisolone (0.5–1 mg/kg twice daily) to ongoing prophylactic GVHD therapy (usually a systemic calcineurin inhibitor plus either methotrexate or mycophenolate mofetil). This treatment approach results in disease control in ~50% of patients. Recently, the JAK inhibitor ruxolitinib was FDA-approved for steroid-refractory aGVHD and represents the preferred second-line therapy[25]. Increasingly it is being used as a steroid-sparing agent earlier after the diagnosis of aGVHD. Third-line therapies include other immunomodulatory agents such as TNF antagonists, but they are associated with an increased risk of infections. Unfortunately, until the recent introduction of ruxolitinib, patients who did not respond well to corticosteroid therapy were at high risk of mortality.

Downloaded for Anonymous User (n/a) at Egyptian Knowledge Bank from ClinicalKey.com by Elsevier on March 10, 2024. For personal use only. No other uses without permission. Copyright ©2024. Elsevier Inc. All rights reserved.

Fig. 52.6 Orogenital involvement in chronic cutaneous graft-versus-host disease. A, B Lichen planus-like: flat-topped violet papules on the penis and several ulcers on the tongue with a lacy white pattern on the upper vermilion lip and the distal dorsal tongue. **C** Severe erosive disease of the vulva, with nearly total resorption of the labia minora and agglutination of the lips of the clitoral hood. The vulvar introitus is also markedly narrowed. *B, Courtesy Jean L. Bolognia, MD.*

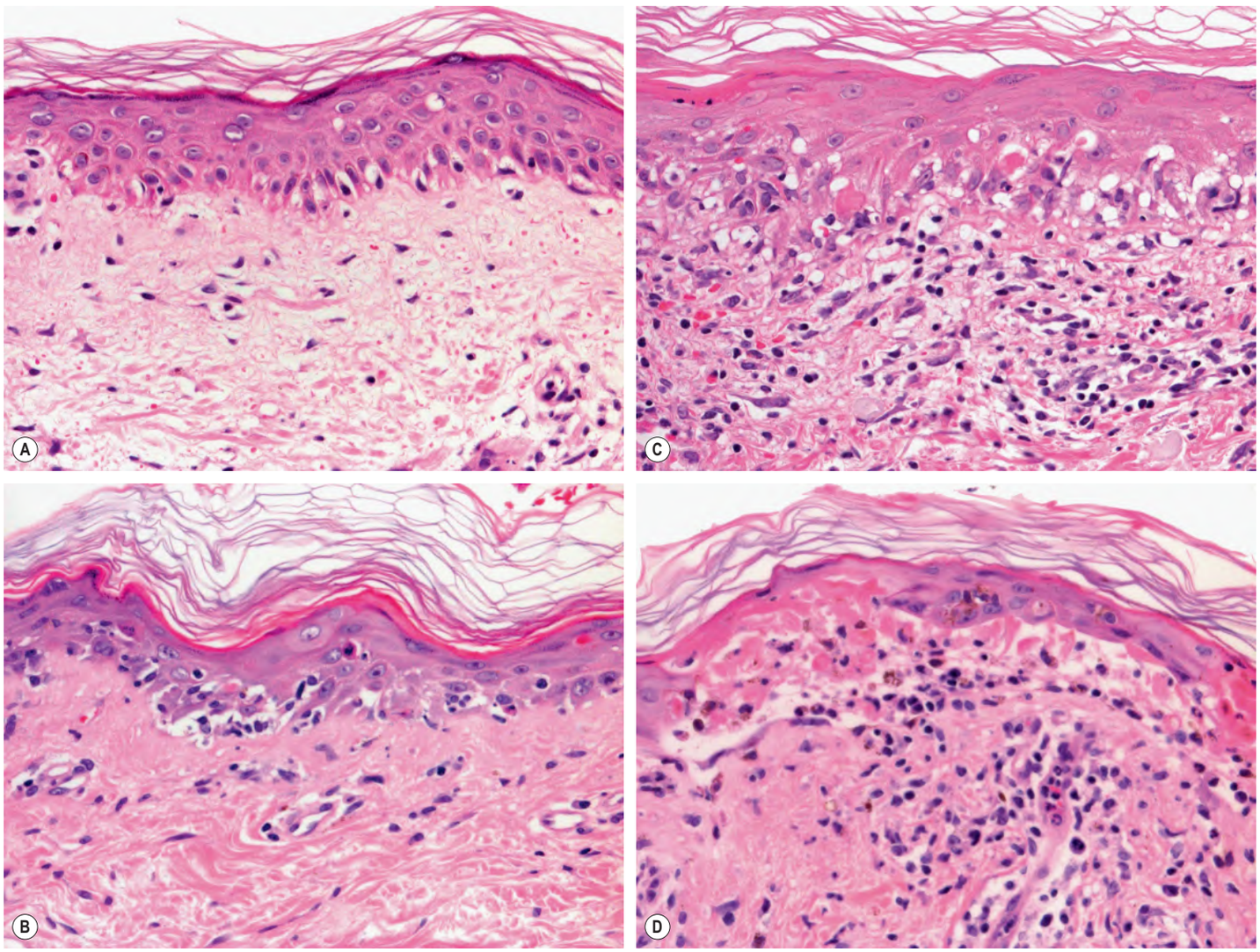

Fig. 52.7 Acute cutaneous graft-versus-host disease – histopathologic grades. A Grade I: focal vacuolar changes of the basal layer of the epidermis and sparse lymphocytic infiltrate. **B** Grade II: necrosis of keratinocytes and more obvious vacuolar degeneration of the basal layer. **C** Grade III: apoptosis of keratinocytes and blurring of the dermal–epidermal junction due to marked vacuolar degeneration and a lichenoid infiltrate of lymphocytes. **D** Grade IV: full-thickness necrosis of the epidermis with separation of the epidermis from the dermis. Of note, grade I changes are rather nonspecific and are also seen with autoimmune disorders showing the histopathologic pattern of an interface dermatitis (e.g. lupus erythematosus). *Courtesy Lorenzo Cerroni, MD.*

Downloaded for Anonymous User (n/a) at Egyptian Knowledge Bank from ClinicalKey.com by Elsevier on March 10, 2024. For personal use only. No other uses without permission. Copyright ©2024. Elsevier Inc. All rights reserved.

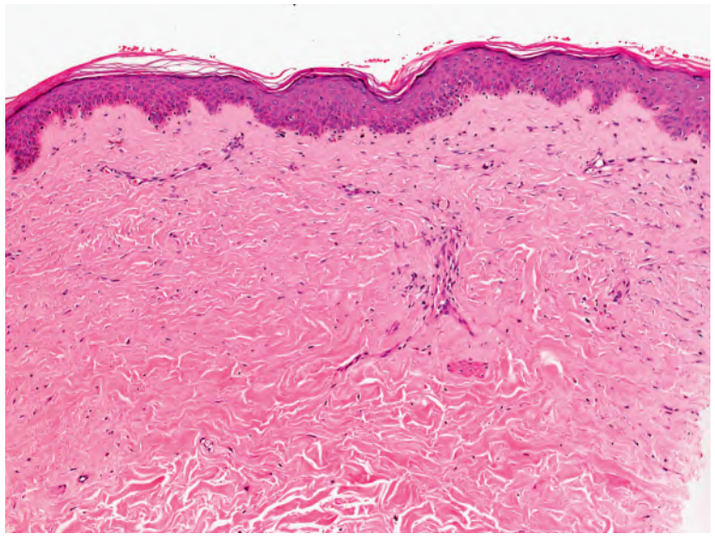

Fig. 52.8 Chronic cutaneous graft-versus-host disease (morphea-like) – histologic features. There is sclerosis of the dermis with thickening of collagen bundles. These same histologic features can be seen in morphea and systemic sclerosis (scleroderma). Pigmentary incontinence, with a few melanophages within the papillary dermis can also be seen in this form of chronic GVHD.
Courtesy Lorenzo Cerroni, MD.

CLINICAL FEATURES OF ENGRAFTMENT SYNDROME VERSUS ACUTE GRAFT-VERSUS-HOST DISEASE (GVHD)		
Clinical feature	**Engraftment syndrome**	**Acute GVHD**
Type of transplant	Autologous or allogeneic	Allogeneic
Exanthem	Yes	Yes
Pruritus	Variable	Variable
Fever	Yes	Uncommon
Peripheral eosinophilia	Variable	Variable
Diarrhea	No	Yes
Transaminitis/cholestasis	Uncommon	Yes
Pulmonary edema	Yes	No
Weight gain	Yes	No
Renal insufficiency	Variable	No
Encephalopathy	Uncommon	No
Rapid response to corticosteroids	Yes	Variable to yes
Timing post-transplant	~10–12 days (coinciding with myeloid recovery)	Peak incidence at 30–40 days

Table 52.5 Clinical features of engraftment syndrome versus acute graft-versus-host disease (GVHD).

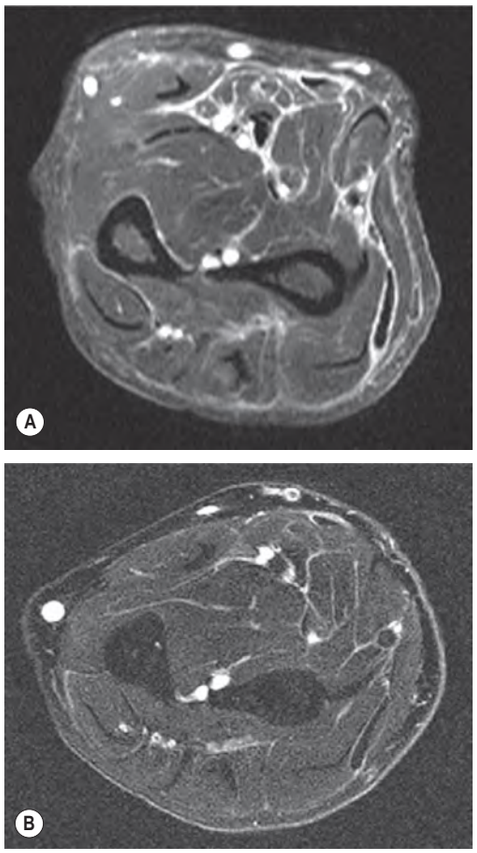

Fig. 52.9 Magnetic resonance imaging of the eosinophilic fasciitis-like presentation of chronic cutaneous graft-versus-host disease. A Prior to treatment (systemic corticosteroids), with a lace-like white pattern representing edema of the fascia. **B** After treatment, with marked diminution of edema. The round white circles represent blood vessels.
Courtesy Dennis Cooper, MD.

Chronic GVHD

Chronic GVHD continues to be a major therapeutic challenge, but the consistent observation that post-transplant cyclophosphamide has reduced its incidence without an increase in relapse or opportunistic infections is encouraging. With respect to cutaneous cGVHD, skin-directed therapies can play an important adjunctive role. For an LP-like eruption or pruritus, medium- to high-potency topical corticosteroids and topical calcineurin inhibitors (pimecrolimus, tacrolimus) are effective. Of note, use of topical tacrolimus under occlusion may lead to toxic drug levels in patients on concurrent systemic tacrolimus[26]. Various forms of phototherapy have shown some benefit in small series, however controlled trial data are needed. The potential for increased skin cutaneous malignancies in the setting of concurrent immunosuppressive therapy or prophylactic voriconazole must also be weighed against the benefit of UV therapy.

As with aGVHD, first-line systemic therapy of cGVHD is systemic corticosteroids, but while the dose is less (maximum dose of prednisone is 1 mg/kg/day), the duration of treatment is often prolonged. This extended corticosteroid therapy is a major cause of non-relapse morbidity and mortality, especially from opportunistic infections. Approximately 50% of cGVHD patients will not respond adequately to corticosteroid therapy, and better treatment for this group remains a critical unmet need. Ibrutinib[27] is FDA-approved for steroid-refractory cGVHD, but since the approval of ruxolitinib[28] for the same indication, the use of ibrutinib has declined. For patients who have failed ≥2 lines of therapy, belumosudil, a well-tolerated oral inhibitor of rho-associated coil kinase 2 (ROCK2), has recently been FDA-approved given a response rate of >70%. There are also ongoing trials of the use of axatilimab, an anti-CSF-1R antibody, for cGVHD[28a]. Other options include extracorporeal photophoresis[29], sirolimus, imatinib mesylate[30], and rituxumab[31].

Patients with mucocutaneous cGVHD should undergo ocular, oral, and genital examinations. Site-specific therapies, including scleral contact lenses, oral rinses (e.g. dexamethasone elixir), and vaginal dilators can prove very helpful. Referral to physical therapy is strongly recommended in patients with sclerotic involvement to improve any decreased joint range-of-motion.

Long term, the importance of sun protection should be emphasized, as patients are typically prescribed one or more photosensitizing agents, including trimethoprim–sulfamethoxazole, levofloxacin, and voriconazole. In addition, the latter drug can increase the risk of developing cutaneous malignancies. Patients, especially those with significant photodamage and/or a previous history of cutaneous carcinomas, should be educated regarding skin cancer risk in the setting of immunosuppression, and they should receive regular surveillance for skin cancer. Ideally, patients with chronic mucocutaneous GVHD should be managed in a coordinated multidisciplinary manner by specialists in ophthalmology, gynecology, oral medicine, physiatry, and dermatology in order to optimize care.

Additional figures and tables on Risk factors associated with the development of graft-versus-host disease, and Comparison of clinical and laboratory features of sclerotic-type chronic GVHD and systemic sclerosis, available in our eBook (see inside front cover for access code).

Downloaded for Anonymous User (n/a) at Egyptian Knowledge Bank from ClinicalKey.com by Elsevier on March 10, 2024. For personal use only. No other uses without permission. Copyright ©2024. Elsevier Inc. All rights reserved.

REFERENCES

1. Pidala J, Anasetti C, Kharfan-Dabaja MA, et al. Decision analysis of peripheral blood versus bone marrow hematopoietic stem cells for allogeneic hematopoietic cell transplantation. *Biol Blood Marrow Transplant*. 2009;15:1415–1421.
2. Martires KJ, Baird K, Steinberg SM, et al. Sclerotic-type chronic GVHD of the skin: clinical risk factors, laboratory markers, and burden of disease. *Blood*. 2011;118:4250–4257.
3. Martin PJ, Schoch G, Fisher L, et al. A retrospective analysis of therapy for acute graft-versus-host disease: initial treatment. *Blood*. 1990;76:1464–1472.
4. Flowers ME, Martin PJ. How we treat chronic graft-versus-host disease. *Blood*. 2015;125:606–615.
5. Chosidow O, Bagot M, Vernant JP, et al. Sclerodermatous chronic graft-versus-host disease. Analysis of seven cases. *J Am Acad Dermatol*. 1992;26:49–55.
6. Ferrara JLM, Levine JE, Reddy P, Holler E. Graft-versus-host disease. *Lancet*. 2009;373:1550–1561.
7. Chen GL, Arai S, Flowers ME, et al. A phase 1 study of imatinib for corticosteroid-dependent/refractory chronic graft-versus-host disease: response does not correlate with anti-PDGFRA antibodies. *Blood*. 2011;118:4070–4078.
8. Spies-Weisshart B, Schilling K, Bohmer F, et al. Lack of association of platelet-derived growth factor (PDGF) receptor autoantibodies and severity of chronic graft-versus-host disease (GvHD). *J Cancer Res Clin Oncol*. 2013;139:1397–1404.
9. Cutler CS, Koreth J, Ritz J. Mechanistic approaches for the prevention and treatment of chronic GVHD. *Blood*. 2017;129:22–29.
10. Gartlan KH, Bommiasamy H, Paz K, et al. A critical role for donor-derived IL-22 in cutaneous chronic GVHD. *Am J Transplant*. 2018;18:810–820.
11. Klimczak A, Suchnicki K, Sedzimirska M, et al. Diverse activity of IL-17^{+} cells in chronic skin and mucosa graft-versus-host disease. *Arch Immunol Ther Exp (Warsz)*. 2019;67:311–323.
12. Debureaux PE, de Masson A, Battistella M, et al. Chronic graft-versus-host disease and inhibition of interleukin-17: proof of concept in humans. *Br J Dermatol*. 2020;182:1038–1041.
13. Bruggen MC, Klein I, Greinix H, et al. Diverse T-cell responses characterize the different manifestations of cutaneous graft-versus-host disease. *Blood*. 2014;123:290–299.
14. Jagasia MH, Greinix HT, Arora M, et al. National Institutes of Health Consensus Development Project on Criteria for Clinical Trials in Chronic Graft-versus-Host Disease: I. The 2014 Diagnosis and Staging Working Group report. *Biol Blood Marrow Transplant*. 2015;21:389–401.
15. Hymes SR, Alousi AM, Cowen EW. Graft-versus-host disease: part I. Pathogenesis and clinical manifestations of graft-versus-host disease. *J Am Acad Dermatol*. 2012;66(515):e1–e18.
16. Kaffenberger BH, Zuo RC, Gru A, et al. Graft-versus-host disease-associated angiomatosis: a clinicopathologically distinct entity. *J Am Acad Dermatol*. 2014;71:745–753.
17. Totani A, Amin H, Bacchi S, et al. Vitiligo following stem-cell transplant. *Bone Marrow Transplant*. 2020;55:332–340.
18. Zuo RC, Naik HB, Steinberg SM, et al. Risk factors and characterization of vitiligo and alopecia areata in patients with chronic graft-vs-host disease. *JAMA Dermatol*. 2015;151:23–32.
19. Zantomio D, Grigg AP, MacGregor L, et al. Female genital tract graft-versus-host disease: incidence, risk factors and recommendations for management. *Bone Marrow Transplant*. 2006;38:567–572.
20. Huang JT, Duncan CN, Boyer D, et al. Nail dystrophy, edema, and eosinophilia: harbingers of severe chronic GVHD of the skin in children. *Bone Marrow Transplant*. 2014;49:1521–1527.
21. Saardi KM, Rosenstein RK, Anadkat MJ, et al. Calcinosis cutis in the setting of chronic skin graft-versus-host disease. *JAMA Dermatol*. 2020;156:814–817.
22. Shulman HM, Cardona DM, Greenson JK, et al. NIH Consensus Development Project on Criteria for Clinical Trials in Chronic Graft-versus-Host Disease: II. The 2014 Pathology Working Group Report. *Biol Blood Marrow Transplant*. 2015;21:589–603.
23. Bolaños-Meade J, Anders V, Wisell J, et al. Grover's disease after bone marrow transplantation. *Biol Blood Marrow Transplant*. 2007;13:1116–1117.
24. Patel AR, Turner ML, Baird K, et al. Voriconazole-induced phototoxicity masquerading as chronic graft-versus-host disease of the skin in allogeneic hematopoietic cell transplant recipients. *Biol Blood Marrow Transplant*. 2009;15:370–376.
25. Zeiser R, von Bubnoff N, Butler J, et al. Ruxolitinib for glucocorticoid-refractory acute graft-versus-host disease. *N Engl J Med*. 2020;382:1800–1810.
26. Olson KA, West K, McCarthy PL. Toxic tacrolimus levels after application of topical tacrolimus and use of occlusive dressings in two bone marrow transplant recipients with cutaneous graft-versus-host disease. *Pharmacotherapy*. 2014;34:e60–e64.
27. Miklos D, Cutler CS, Arora M, et al. Ibrutinib for chronic graft-versus-host disease after failure of prior therapy. *Blood*. 2017;130:2243–2250.
28. Modi B, Hernandez-Henderson M, Yang D, et al. Ruxolitinib as salvage therapy for chronic graft-versus-host disease. *Biol Blood Marrow Transplant*. 2019;25:265–269.

28a. Kitko CL, Arora M, DeFilipp Z, et al. Axatilimab for chronic graft-versus-host disease after failure of at least two prior systemic therapies: results of a Phase I/II study. *J Clin Oncol*. 2023;41:1864–1875.

29. Flowers ME, Apperley JF, van Besien K, et al. A multicenter prospective phase 2 randomized study of extracorporeal photopheresis for treatment of chronic graft-versus-host disease. *Blood*. 2008;112:2667–2674.
30. Olivieri A, Cimminiello M, Corradini P, et al. Long-term outcome and prospective validation of NIH response criteria in 39 patients receiving imatinib for steroid-refractory chronic GVHD. *Blood*. 2013;122:4111–4118.
31. Cutler C, Miklos D, Kim HT, et al. Rituximab for steroid-refractory chronic graft-versus-host disease. *Blood*. 2006;108:756–762.

Downloaded for Anonymous User (n/a) at Egyptian Knowledge Bank from ClinicalKey.com by Elsevier on March 10, 2024. For personal use only. No other uses without permission. Copyright ©2024. Elsevier Inc. All rights reserved.

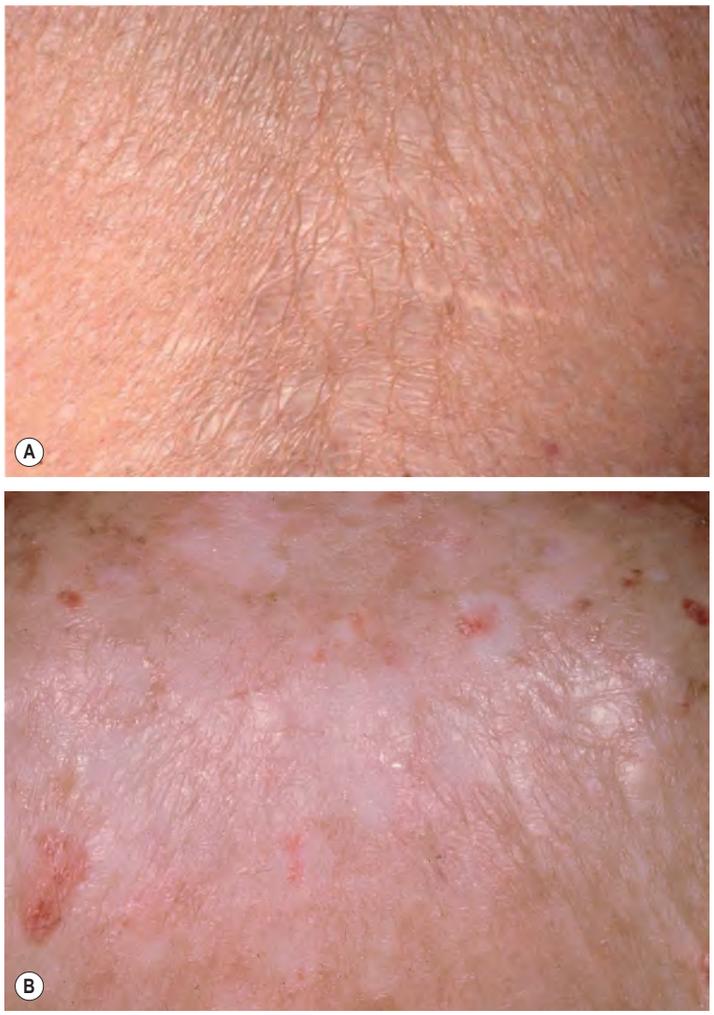

eFig. 52.1 Chronic cutaneous graft-versus-host disease – lichen sclerosus type. A Subtle gray–white ovoid plaques on the back. **B** Shiny hypopigmented plaques of the upper back, a common location for this form of cGVHD. *B, Courtesy Joyce Rico, MD*.

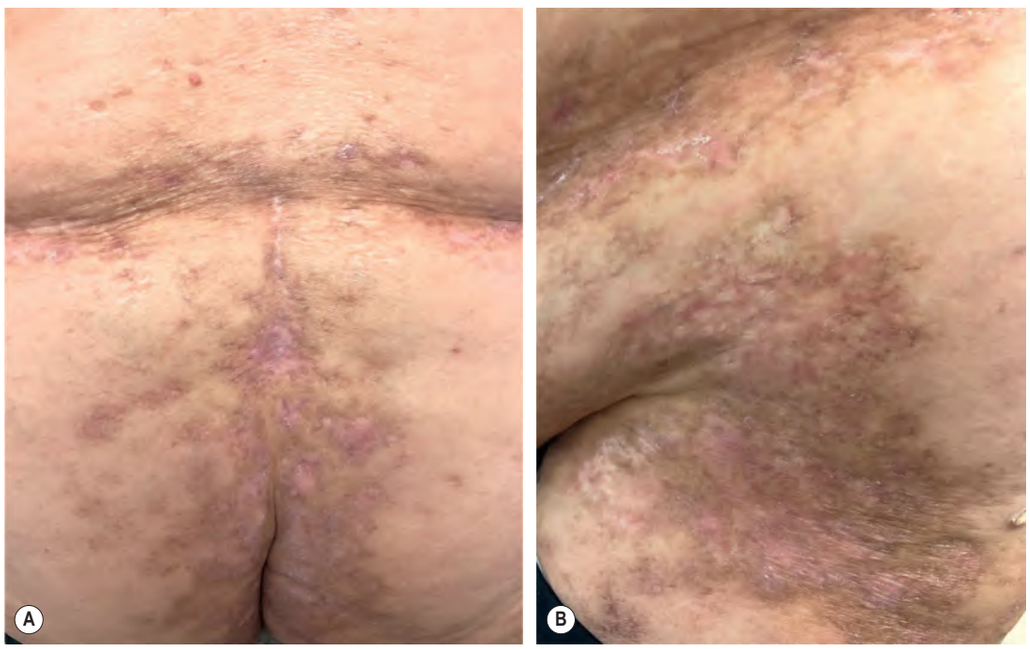

eFig. 52.2 Chronic graft-versus-host disease – morpheaform type. A, B Symmetric sclerotic plaques with central inflammation and peripheral hyperpigmentation involving the major body folds and flanks. *Courtesy Jonathan S. Leventhal, MD*.

Downloaded for Anonymous User (n/a) at Egyptian Knowledge Bank from ClinicalKey.com by Elsevier on March 10, 2024. For personal use only. No other uses without permission. Copyright ©2024. Elsevier Inc. All rights reserved.

eFig. 52.3 Chronic graft-versus-host disease – morpheaform type. Sclerotic plaques in a "waistband" distribution in child who wears diapers.

eFig. 52.4 Chronic graft-versus-host disease – sclerotic type. Inflamed and hyperpigmented bound-down skin of the wrist and hand with joint contractures and superficial ulceration.

eFig. 52.5 Chronic graft-versus-host disease – sclerodermal-like (sclerodermoid) type. The skin is shiny and bound-down. Additional findings include dyspigmentation, erosions, angiomatous papules, and a loss of the nail plates of the great toes.

eFig. 52.6 Chronic cutaneous graft-versus-host disease – eosinophilic fasciitis-like presentation. A rippled appearance and irregular nodular texture to the skin is indicative of involvement of subcutaneous tissues. Especially in the earlier, edematous phase, the presence of hypereosinophilia may be a clue to the diagnosis.

eFig. 52.7 Residual dyspigmentation from chronic cutaneous graft-versus-host disease (cGVHD). Extensive hyper- and hypopigmentation in an African-American child with a history of epidermal involvement of cGVHD.

Downloaded for Anonymous User (n/a) at Egyptian Knowledge Bank from ClinicalKey.com by Elsevier on March 10, 2024. For personal use only. No other uses without permission. Copyright ©2024. Elsevier Inc. All rights reserved.

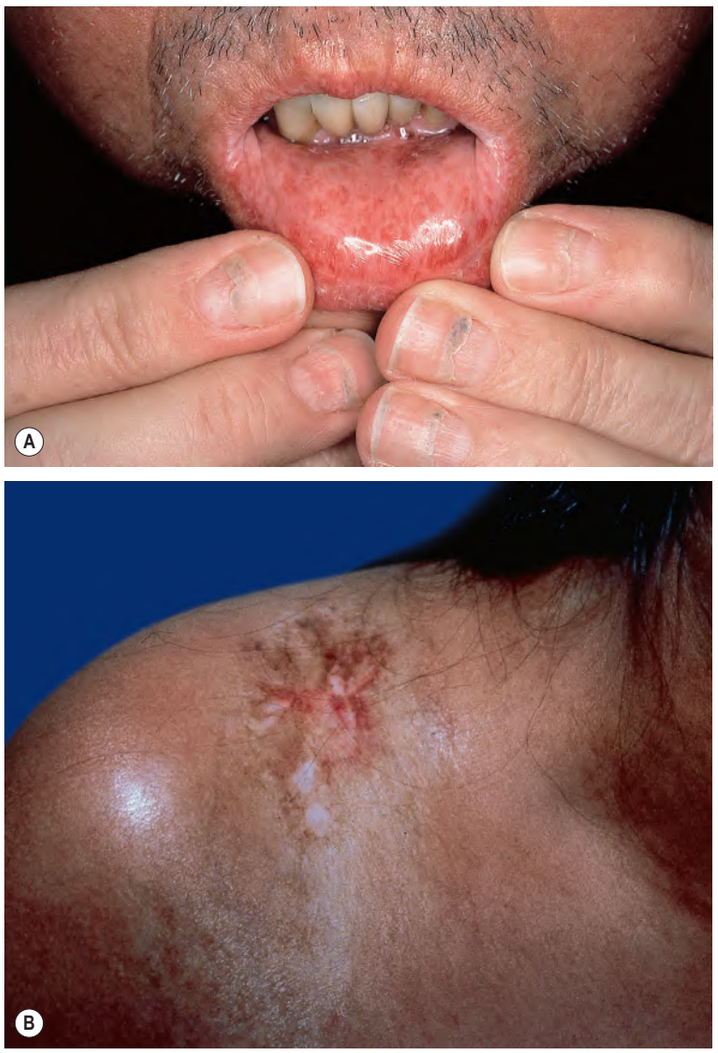

eFig. 52.8 Chronic graft-versus-host disease. A Lacy white pattern on the mucosal surface of the lower lip in the lichen planus-like form. Note the Beau's lines of the fingernails reflecting the time of the transplant. **B** Morphea-like plaque with a healing ulceration on the shoulder.

eFig. 52.9 Chronic graft-versus-host disease. Well demarcated pink–violet plaques with scale favoring areas of pressure. *Courtesy Julie V. Schaffer, MD.*

RISK FACTORS ASSOCIATED WITH THE DEVELOPMENT OF GRAFT-VERSUS-HOST DISEASE
Donor
HLA incompatibility with recipient Unrelated to recipient Female (especially multiparous) with male recipient
Recipient
Age (older-aged > middle-aged > pediatric)
Stem cell source
Peripheral blood > bone marrow > cord blood T cell-replete graft
Other
Myeloablative conditioning regimen*
*Associated with higher rate of acute GVHD compared with non-myeloablative HSCT, but does not affect incidence of chronic GVHD.

eTable 52.1 Risk factors associated with the development of graft-versus-host disease (GVHD). HSCT, hematopoietic stem cell transplant.

COMPARISON OF CLINICAL AND LABORATORY FEATURES OF SCLEROTIC-TYPE CHRONIC GVHD (cGVHD) AND SYSTEMIC SCLEROSIS		
	Sclerotic-type cGVHD	**Systemic sclerosis**
Autoantibodies	Variable, nonspecific	Yes, associated with specific clinical subtypes
Cardiac involvement	Rare	Yes, conduction system abnormalities
GI dysmotility/ strictures	Yes	Yes
Pulmonary hypertension	No	Yes
Pulmonary fibrosis	Yes*	Yes
Renal disease	Rare, nephrotic syndrome	Yes, scleroderma renal crises (in diffuse subtype)
Raynaud disease	Rare	Yes
Sclerodactyly	Rare	Yes
Skin manifestations		
Fibrosis	Dermis, subcutaneous tissue, and/or fascia	Dermis
Natural history	Patchy involvement, variable course	Symmetric, acral to proximal progression
Facial involvement	Rare, usually patchy involvement	Common, diffuse skin tightening (scleroderma facies)
*In setting of bronchiolitis obliterans.		

eTable 52.2 Comparison of clinical and laboratory features of sclerotic-type chronic GVHD (cGVHD) and systemic sclerosis.

Downloaded for Anonymous User (n/a) at Egyptian Knowledge Bank from ClinicalKey.com by Elsevier on March 10, 2024. For personal use only. No other uses without permission. Copyright ©2024. Elsevier Inc. All rights reserved.

PATIENT HANDOUT – GENERAL DERMATOLOGIC RECOMMENDATIONS FOR PATIENTS WITH CUTANEOUS GRAFT-VERSUS-HOST DISEASE (GVHD)
Dry skin and pruritus
Use soapless, fragrance-free cleansers
Apply emollients frequently, in particular ointments and thicker creams
Avoid tight-fitting or abrasive clothing; wear cool, breathable fabrics
Avoid antihistamines if there is dryness of the eyes or mouth (sicca syndrome)
Nail dystrophy
Keep nails trimmed or filed to prevent breakage and pain
A clear nail lacquer can be used as a nail hardener
Signs of skin sclerosis (hardening)
Early signs of skin sclerosis (hardening) include darkening or tightening of the skin at the waistband or bra line, rippling or dimpling of the skin, and decreased joint range-of-motion
Skin ulcers
Areas of skin breakdown serve as potential sites where bacteria can enter the body; these areas should be kept clean and covered
Recommendations regarding sun exposure and skin cancer
The risk of skin cancer is increased in patients with GVHD, especially those who are chronically immunosuppressed and/or receive phototherapy (e.g. UVB, PUVA)
Exposure to sunlight can trigger a flare of GVHD or photodrug eruption
Several frequently prescribed medications can increase sun sensitivity; they include trimethoprim–sulfamethoxazole (Septra®, Bactrim®) and voriconazole (Vfend®)
If possible, avoid outdoor activities during peak hours of UVR (10 am–4 pm)
Apply broad-spectrum sunblock on sun-exposed sites on a regular basis
Use a broad-brimmed hat and protective clothing; consider using a laundry additive that increases the UV protective factor of clothing (e.g. SunGuard™)
Perform skin self-examination on a regular basis

eTable 52.3 Patient handout – general dermatologic recommendations for patients with cutaneous graft-versus-host disease (GVHD).

Downloaded for Anonymous User (n/a) at Egyptian Knowledge Bank from ClinicalKey.com by Elsevier on March 10, 2024. For personal use only. No other uses without permission. Copyright ©2024. Elsevier Inc. All rights reserved.