43 Systemic Sclerosis (Scleroderma) and Related Disorders

Gideon P. Smith, Anna K. Haemel and M. Kari Connolly

Chapter Contents

Systemic Sclerosis 702
Eosinophilic Fasciitis 713
Stiff Skin Syndrome 713
Sclerodermoid Syndromes Induced by Exogenous Substances . .714

SYSTEMIC SCLEROSIS

Synonyms: Systemic sclerosis: ■ Scleroderma ■ Progressive systemic sclerosis
Subtypes of cutaneous involvement: ■ Diffuse ■ Limited (includes CREST syndrome)

Key features

- An uncommon autoimmune connective tissue disease of unknown etiology
- Characterized by symmetric hardening of the skin of the fingers, hands, and face that may generalize
- Raynaud phenomenon is common, and digital ulcers may develop
- Internal organ involvement is frequent and affects the lungs, gastrointestinal tract, heart, and kidneys
- Important to monitor for lung involvement because pulmonary disease is the leading cause of death
- Treatment focuses on internal organ manifestations; effective therapy for cutaneous sclerosis remains inadequate

Introduction

Systemic sclerosis (SSc, scleroderma) is an autoimmune connective tissue disease (AI-CTD) of unknown etiology that affects the skin, blood vessels, and internal organs[1]. The name *systemic sclerosis* is meant to convey the systemic nature of the disease, which has two major clinical subtypes: *limited cutaneous SSc* (lcSSc) and *diffuse cutaneous SSc* (dcSSc). LcSSc is characterized by cutaneous sclerosis that is limited to the fingers, hands, and face. In dcSSc, generalized cutaneous sclerosis is seen that usually begins in the fingers and hands but eventually extends to the forearms, arms, face, trunk, and lower extremities. Other entities that can lead to symmetric and widespread cutaneous induration include generalized morphea, eosinophilic fasciitis, scleromyxedema, nephrogenic systemic fibrosis, scleredema, and chronic GVHD (Table 43.1).

History

The first reported case of SSc in 1754 was a young Italian woman who developed progressive skin induration[1]. From the clinical description, it is impossible to determine whether she had true SSc or another sclerodermoid disorder such as scleredema.

Epidemiology

SSc has a worldwide distribution and affects all races. The annual incidence and prevalence rates in the US are approximately 20 and 275 cases per million, respectively[2]. Women are affected three to four times as often as men. Although SSc can occur in children and the elderly, onset is typically between the ages of 35 and 50 years. Black individuals have an earlier mean age of onset and a higher likelihood of diffuse disease[2]. Approximately 1.5% of SSc patients have one or more affected first-degree relatives, representing a 10- to 15-fold higher risk of SSc in family members than in the general population[1]. SSc is associated with significant mortality, with an overall 10-year survival of ~70%[1]. Clinical features predicting a worse prognosis include male sex, older age at diagnosis, being African-American, internal organ involvement (especially pulmonary) at the time of diagnosis, cutaneous sclerosis affecting the trunk, and elevated ESR[1].

Pathogenesis

The pathogenesis of SSc is unknown. Key pathogenic abnormalities in the skin and internal organs are vascular dysfunction, immune activation with autoantibody production, and tissue sclerosis characterized by deposition of collagen and other extracellular matrix proteins (Fig. 43.1)[2a–5].

Vascular dysregulation

Impaired angiogenesis is an early event in the pathogenesis of SSc[5]. The blood vessels affected range from the smallest capillaries within the proximal nail fold to the large pulmonary arteries. Endothelial cell injury occurs early (before sclerosis is evident), based on changes seen by electron microscopy, such as perivascular leak and edema[6]. Endothelial cell activation leads to increased expression of adhesion molecules and binding of circulating inflammatory cells. Vascular endothelial growth factor (VEGF) and its receptors (VEGFR) are elevated in the dermis in SSc[5].

Surrounding smooth muscle cells are also affected and have altered production of and responsiveness to vasoconstrictive (e.g. cold, endothelin) and vasodilatory (e.g. nitric oxide) factors. Structural abnormalities such as intimal proliferation lead to luminal occlusion and hypoxia which then induces synthesis of profibrotic cytokines, fibroblast activation, and collagen production[7]. Raynaud phenomenon and digital ulcers are caused by reversible vasospasm as well as irreversible arterial damage with intimal proliferation and luminal obstruction. Scleroderma renal crisis and pulmonary artery hypertension are manifestations of large vessel dysregulation.

Immune dysregulation

Autoantibodies unique to SSc, in particular anti-centromere, anti-topoisomerase I, and anti-RNA polymerase III, are useful for diagnostic and prognostic purposes (see Ch. 40)[1,8]. These three autoantibodies bind tissues of interest in SSc, as do anti-U3RNP (antifibrillarin), anti-Th/To, anti-U1RNP, anti-PM-Scl, and anti-Ku autoantibodies[5,8]. The latter are rather rare and play a role in overlap syndromes.

Evidence of a direct pathogenic role for these autoantibodies includes complexes containing topoisomerase I autoantibody that, when bound to the surface of fibroblasts, have been found to stimulate monocyte adhesion and activation. In addition, anti-endothelial cell antibodies from SSc patient sera can trigger endothelial cell apoptosis. One group described stimulatory autoantibodies against the platelet-derived growth factor (PDGF) receptor in SSc sera, which induced reactive oxygen species and expression of type I collagen by normal human fibroblasts[9]. However, two subsequent studies were unable to confirm these findings[10].

Lymphocytic infiltrates, composed of both T and B cells, have been observed in the skin and lungs of SSc patients before the development of fibrosis. Oligoclonal T cell expansion has been identified in lesional skin, indicating an antigen-driven response, and T cells demonstrate

Downloaded for Anonymous User (n/a) at Egyptian Knowledge Bank from ClinicalKey.com by Elsevier on March 10, 2024. For personal use only. No other uses without permission. Copyright ©2024. Elsevier Inc. All rights reserved.

MAJOR CLINICAL AND LABORATORY MANIFESTATIONS OF SYSTEMIC SCLEROSIS AND OTHER SELECTED CONDITIONS CHARACTERIZED BY CUTANEOUS INDURATION							
	Systemic sclerosis	**Morphea**	**Eosinophilic fasciitis**	**Scleredema**	**Scleromyxedema**	**NSF**	**Chronic GVHD**
Major clinical variants	• Limited • Diffuse	• Plaque-type (circumscribed) morphea • Linear morphea • Generalized morphea		• Post-infectious (type I) • Monoclonal gammopathy-associated (type II) • Diabetes mellitus-associated (type III)			• Lichen sclerosis-like • Morphea-like • Scleroderma-like • Fasciitis
Raynaud phenomenon	++	–	–	–	–	–	–
Symmetric induration	++*	– plaque-type and linear ± generalized	++*	++	++	+	+
Sclerodactyly	++	–	–	–	–	–	–
Facial involvement	+	– plaque-type and generalized + linear (en coup de sabre)	–	± types I and II – type III	+	–	±
Systemic involvement	++	– for plaque-type but ± for linear involving head (ocular, CNS)	+	–	++	+	+
Anti-nuclear antibodies	++	± generalized and linear – plaque-type	–	–	–	–	±
Anti-centromere antibodies	+ limited	–	–	–	–	–	–
Anti-topoisomerase I (Scl-70) antibodies	+ diffuse	–	–	–	–	–	–
Anti-RNA polymerase III	+ diffuse	–	–	–	–	–	–
Monoclonal gammopathy	–	–	±	+ type II	++	–	–
Spontaneous remission	–	++ plaque-type + generalized ± linear	++	++ type I ± types II and III	–	±†	–

*May be preceded by edematous phase.
†With improved renal function.

Table 43.1 Major clinical and laboratory manifestations of systemic sclerosis and other selected conditions characterized by cutaneous induration. NSF, nephrogenic systemic fibrosis; ++, almost always; +, common; ±, sometimes; –, rare or unusual. *Courtesy Vincent Falanga, MD.*

INTERACTIONS BETWEEN ENDOTHELIAL CELLS, LEUKOCYTES, AND FIBROBLASTS IN SYSTEMIC SCLEROSIS PATHOGENESIS

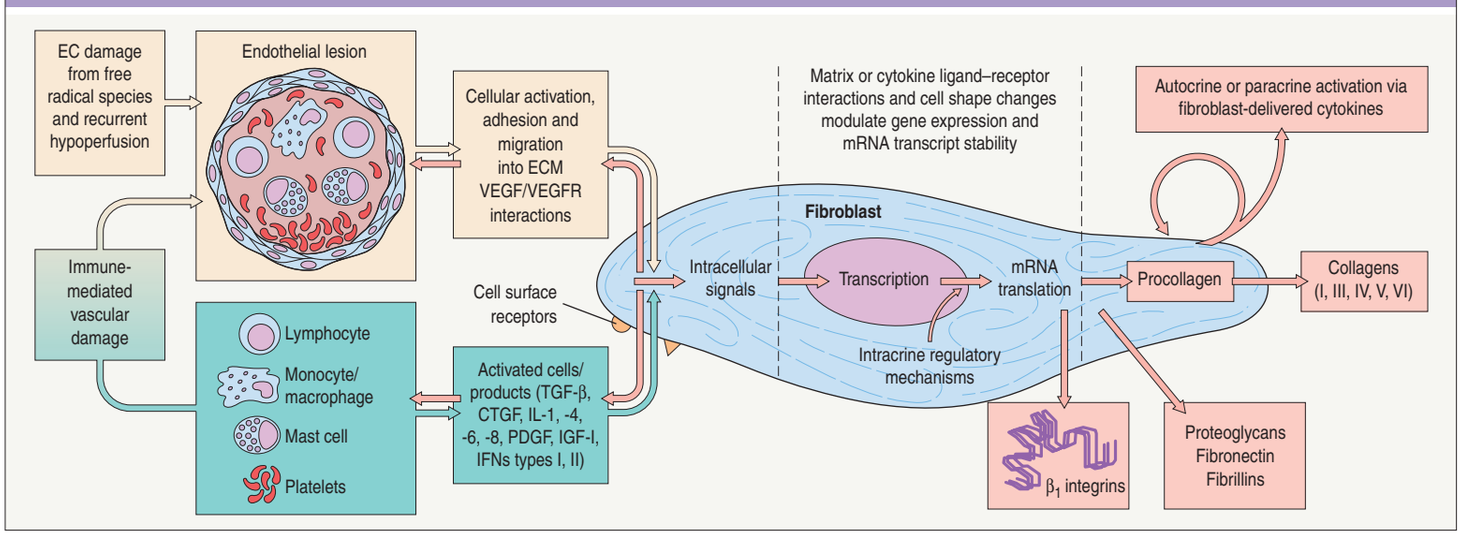

Fig. 43.1 Interactions between endothelial cells, leukocytes, and fibroblasts in systemic sclerosis pathogenesis. In patients with systemic sclerosis, variants in genes involved in innate immunity (e.g. *IRF5*), T cell activation (e.g. *STAT4*), and the TNF pathway (e.g. *TNFAIP3*) have been identified. Mutations in the gene that encodes fibrillin-1 (*FBN1*) lead to stiff skin syndrome. CTGF, connective tissue growth factor; EC, endothelial cell; ECM, extracellular matrix; IFN, interferon; IGF, insulin-like growth factor; PDGF, platelet-derived growth factor; TGF, transforming growth factor; VEGF, vascular endothelial growth factor; VEGFR, VEGF receptor. *Adapted from Hochberg MC, Silman AJ, Smolen JS, et al (eds). Rheumatology, 3rd edn. Edinburgh: Mosby, 2003.*

Downloaded for Anonymous User (n/a) at Egyptian Knowledge Bank from ClinicalKey.com by Elsevier on March 10, 2024. For personal use only. No other uses without permission. Copyright ©2024. Elsevier Inc. All rights reserved.

a Th2-predominant profile with up-regulation of profibrotic cytokines such as interleukin (IL)-4 and IL-13. SSc patients also have expansion of naive B cells and chronic activation, but a decreased number, of memory B cells.

More recently, Th17 cells and IL-17 have been implicated in SSc, as have the *innate* immune system and types I (α,β) and II (γ) interferons. For example, elevated numbers of plasmacytoid dendritic cells have been observed in the blood and skin of SSc patients[11]. In a proteome-wide analysis of five large cohorts, circulating levels of the chemokine CXCL4 were found to be significantly elevated (compared to controls), and the CXCL4 levels correlated with the presence and progression of pulmonary disease[11]. Prospective studies have shown changes in CXCL4 at 12 months predicted future progression[12].

Extracellular matrix dysregulation

Sclerosis represents the final common pathway for tissue damage in SSc. There is excessive deposition of collagens, proteoglycans, fibronectin, fibrillins, and adhesion molecules (e.g. β_1-integrins), which sequester cytokines and growth factors (see Fig. 43.1). Attention has focused on transforming growth factor β (TGF-β) and connective tissue growth factor (CTGF). The latter is induced by TGF-β and may be responsible for maintenance of collagen synthesis.

Given the complex extracellular matrix changes seen in SSc[13], both the fibroblast and the myofibroblast have been a focus of investigation. There is evidence suggesting an inherent defect, an autocrine loop, or a hypersensitivity to growth factors in SSc fibroblasts. Alternatively, SSc fibroblasts may have a normal phenotype but instead find themselves in an abnormal microenvironment with enhanced growth factors or ischemic mediators. The accumulation of collagen in SSc seems to be primarily the result of increased synthesis, rather than decreased degradation.

ACR/EULAR CRITERIA FOR THE CLASSIFICATION OF SYSTEMIC SCLEROSIS		
Item	**Sub-item**	**Weight/score**
Skin thickening of the fingers of both hands extending proximal to the MCP joints (*sufficient criterion*)	–	9
Skin thickening of the fingers	Puffy fingers - *or* - Sclerodactyly	2 4
Fingertip lesion	Digital tip ulcers - *or* - Pitting scars	2 3
Telangiectasias	–	2
Abnormal nail-fold capillaries	–	2
Pulmonary arterial hypertension - *or* - Interstitial lung disease		2 2
Raynaud phenomenon	–	3
SSc-related autoantibodies	Anti-centromere Anti-topoisomerase I Anti-RNA polymerase III	3

Table 43.2 2013 American College of Rheumatology (ACR)/European League Against Rheumatism (EULAR) criteria for the classification of systemic sclerosis (SSc). The total score is determined by adding the maximum weight (score) in each category. Patients with a total score of ≥9 are classified as having *definite* SSc. *From Van den Hoogen F, Khanna D, Fransen J, et al. 2013 classification criteria for systemic sclerosis. Arthritis Rheum. 2013;65:2737–47.*

Clinical Features

Classification and diagnostic criteria

The American College of Rheumatology (ACR) updated the classification criteria for SSc in 2013 (Table 43.2)[14]. These classification criteria ensure the patient population being studied is well-defined and homogeneous, which is particularly important in rheumatic diseases where nonspecific and overlapping symptoms may lead to misclassification. As a result, *classification* criteria are stricter than the *diagnostic* criteria used for an individual patient. Nonetheless, for our purposes, they will be used interchangeably.

In the 2013 classification scheme for SSc, the sole major criterion – skin thickening of the fingers on both hands extending proximal to the metacarpophalangeal (MCP) joints – leads to a diagnosis of *definite* SSc (9 points)[14]. If the patient does not meet this criterion, seven other minor criteria may be used to reach a diagnosis of SSc (see Table 43.2). These 2013 criteria have greater sensitivity (91%) and specificity (92%) compared to older criteria[14].

Based upon the degree of skin involvement, there are two major clinical subtypes (Fig. 43.2): lcSSc and dcSSc[1]. When the skin disease involves the distal and proximal portions of the extremities, trunk and face, it is considered dcSSc, but when the induration is limited to the distal extremities and face, it is considered lcSSc[1]. Although both can have systemic manifestations, there are variable patterns and severity of internal organ involvement (Table 43.3). Typically, dcSSc is associated with early internal organ involvement (within 5 years of disease onset) and a worse prognosis[1], whereas patients with lcSSc tend to develop internal involvement later in the disease and have a better prognosis.

The acronym CREST describes clinical features in a subset of patients with lcSSc: *c*alcinosis, *R*aynaud phenomenon, *e*sophageal involvement, *s*clerodactyly and *t*elangiectasia. However, because not every patient has all five features, the term lcSSc is favored. Rarely, patients present with characteristic internal organ involvement, Raynaud phenomenon, abnormal nail-fold capillaries, and positive serologies, but no cutaneous sclerosis. This clinical presentation is referred to as *systemic sclerosis sine scleroderma* (ssSSc), and it behaves similarly to lcSSc.

COMPARISON OF CLINICAL AND LABORATORY FEATURES OF DIFFUSE AND LIMITED SYSTEMIC SCLEROSIS		
Clinical feature	**Diffuse SSc (%)**	**Limited SSc (%)**
Raynaud phenomenon	90	99
Finger swelling	95	90
Tendon friction rubs	70	5
Arthralgia	98	80
Proximal weakness	80	60
Calcinosis	20	40
Mat telangiectasias*	60	90
Esophageal dysmotility	80	90
Small bowel involvement	40	60
Interstitial lung disease	70	35
Pulmonary arterial hypertension	10	30
Cardiomyopathy	15	10
Renal crisis	20†	1
Sicca syndrome	15	35
Anti-nuclear antibodies	90	90
Anti-centromere antibody	5-10	30-70
Anti-topoisomerase I (Scl-70) antibody	30-70	5-15
Anti-RNA polymerase III antibody	5-25	1-5
Cumulative survival (5 years)	80	90
(10 years)	70	80

*In addition, nail-fold capillary abnormalities are observed in >90% of SSc patients.
†Has decreased with the use of angiotensin-converting enzyme (ACE) inhibitors.

Table 43.3 Comparison of clinical and laboratory features of diffuse and limited systemic sclerosis (SSc). *Adapted from Pauling JD, McHugh N. The clinical aspects on autoantibodies. In: Varga J, Denton CP, Wigley FM (eds). Scleroderma: from pathogenesis to comprehensive management. New York: Springer Science+Business Media LLC 2012:209–25.*

Cutaneous features

Many patients with SSc experience an early edematous phase, which often features pitting edema of the digits (Fig. 43.3). Digital pits are also a characteristic finding (Fig. 43.4). The skin subsequently hardens and develops a taut, shiny appearance (indurated phase). Eventually,

Downloaded for Anonymous User (n/a) at Egyptian Knowledge Bank from ClinicalKey.com by Elsevier on March 10, 2024. For personal use only. No other uses without permission. Copyright ©2024. Elsevier Inc. All rights reserved.

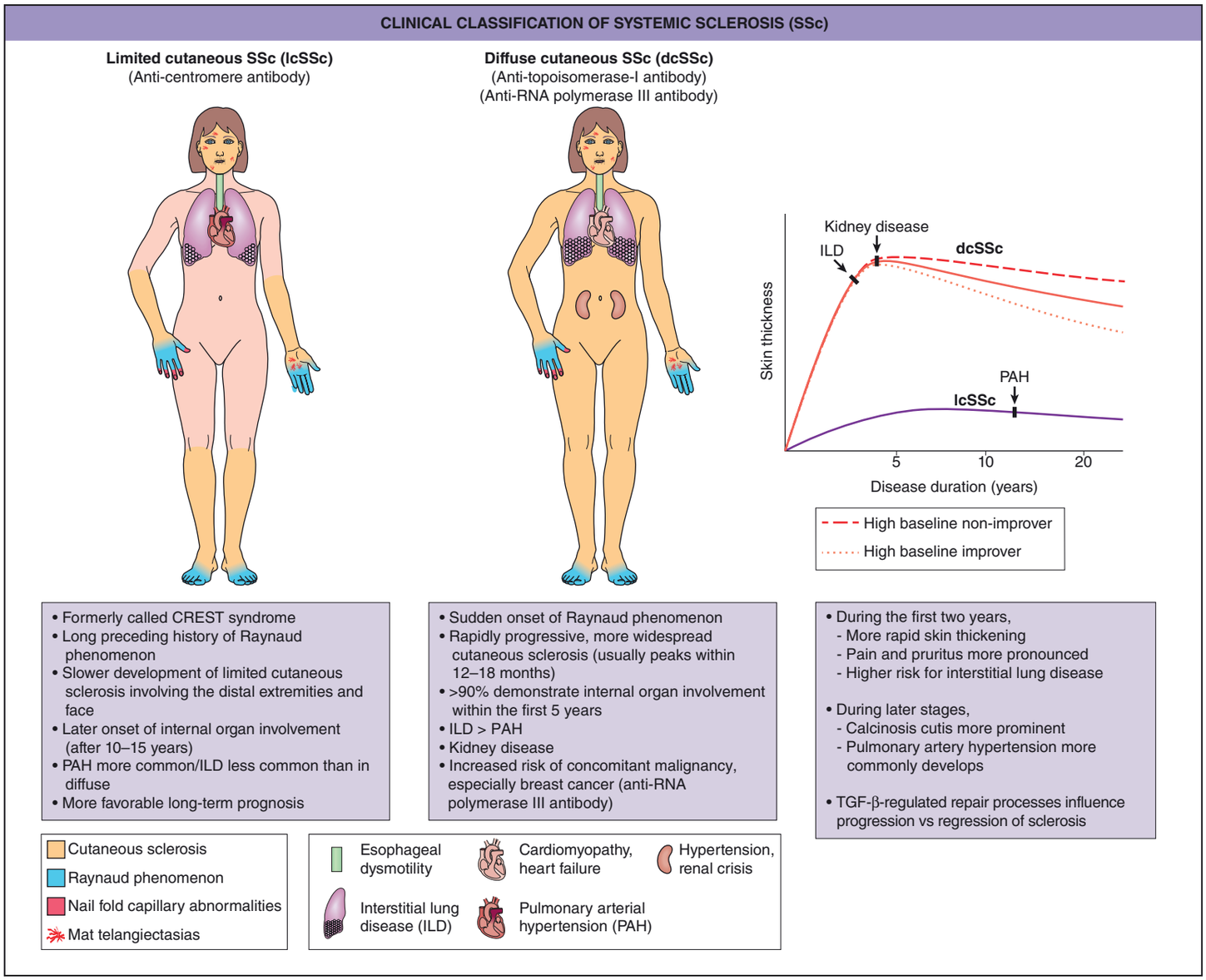

Fig. 43.2 Clinical classification of systemic sclerosis (SSc). *Courtesy Karynne O. Duncan, MD.*

there may be gradual thinning of the skin (late atrophic phase). The fingers can develop flexion contractures and ulcers (Fig. 43.5) while involvement of the face can lead to a beaked nose, microstomia, and a more youthful appearance.

There are a number of cutaneous changes other than sclerosis in patients with SSc. **Dyspigmentation** in areas of sclerosis is commonly observed. Some patients develop diffuse hyperpigmentation, with accentuation in sun-exposed areas and sites of pressure. The "leukoderma of scleroderma" is characterized by localized areas of depigmentation with sparing of the perifollicular skin; this helpful diagnostic finding is sometimes referred to as the "salt and pepper" sign (Fig. 43.6). Pigment may also be retained in the skin overlying superficial veins. This leukoderma favors the upper trunk and central face and may overlie uninvolved or sclerotic skin.

Telangiectasias are more common in patients with lcSSc but also occur in patients with dcSSc (see Table 43.3). The telangiectasias most often involve the face, lips, and palms. These telangiectatic macules are matted or squared-off (Fig. 43.7). Capillary abnormalities in the proximal nail fold are present in more than 90% of SSc patients and can be useful in supporting the diagnosis[15]. Use of magnification may enhance appreciation of these findings. In SSc, capillary loss ("drop out") alternating with dilated loops is characteristic, and density changes have been shown to have prognostic value for fingertip ulceration and lung disease progression.

Calcinosis cutis most commonly develops on the extremities, usually near joints and in distal locations (Fig. 43.8). In addition, the skin is often

Fig. 43.3 Early, edematous phase of systemic sclerosis. Note the demonstration of pitting edema on two of the digits. *Courtesy Jean L. Bolognia, MD.*

Downloaded for Anonymous User (n/a) at Egyptian Knowledge Bank from ClinicalKey.com by Elsevier on March 10, 2024. For personal use only. No other uses without permission. Copyright ©2024. Elsevier Inc. All rights reserved.

dry due to decreased sweating, and pruritus can be quite marked. Sclerotic skin may show diminished hair growth, but this is variable; hypertrichosis can also occur, particularly during the recovery phase. Overall, the cutaneous changes are extremely troublesome to patients with SSc. In a questionnaire-based study involving 300 patients with SSc, facial involvement and microstomia were the patients' greatest concerns[16].

Raynaud phenomenon is characterized by episodic vasospasm of the digital arteries resulting in white, blue, and red discoloration of the fingers secondary to cold exposure[17]. Raynaud phenomenon occurs in two settings (Table 43.4). *Primary Raynaud phenomenon* (Raynaud disease) typically develops in adolescent girls and young women and is not associated with any underlying medical problems[18]. Primary Raynaud phenomenon is common and estimated to affect 3% to 5% of the population. In contrast, *secondary Raynaud phenomenon* is uncommon and is associated with an underlying medical disorder, including SSc (Fig. 43.9; Table 43.5). An approach to differentiating primary from secondary Raynaud phenomenon is presented in Figure 43.10.

Cutaneous ulcers are common in patients with SSc (Fig. 43.11). Whereas ulcers on the tips of the digits are probably due to ischemia, those on the interphalangeal joints are more likely to persist because of continued trauma (see Fig. 43.5). They may also overlie sites of calcinosis cutis. Ulcers can lead to osteomyelitis and even amputation (autoamputation or surgical).

Extracutaneous features

The majority of SSc patients have internal organ involvement (Table 43.6), which is the major cause of morbidity and mortality in this disease[1,19]. Occasionally, a patient with SSc will present with internal organ involvement before skin involvement is evident. The most commonly affected organs are the gastrointestinal tract, lungs, heart, and kidneys. Of note, pulmonary disease has replaced renal crisis as the leading cause of death in SSc. There are two major forms of pulmonary involvement in SSc[1,19]: (1) interstitial lung disease (ILD); and (2) pulmonary arterial hypertension (PAH). Screening tests for both disorders are outlined in Table 43.6. Recently, a rare subtype of ILD referred to as pleuroparenchymal fibroelastosis (PPFE) was described. It is characterized by fibrotic thickening of the visceral pleura as well as the subadjacent parenchymal areas of the lungs' upper lobes. PPFE portends a poor prognosis and requires close monitoring with serial determinations of DLCO (*d*iffusing capacity of the *l*ungs for *c*arbon *m*onoxide) and high-resolution computed tomography scans.

Autoantibodies

Autoantibody testing is useful in confirming the diagnosis of SSc (see Ch. 40). Most SSc patients have elevated titers of anti-nuclear antibodies (ANA)[1,8], with the nucleolar or discrete speckled (centromere) patterns being relatively specific for SSc. Patients with anti-centromere antibodies are more likely to have lcSSc, digital gangrene, and PAH[1]. Patients with antibodies to topoisomerase I (Scl-70) are more likely to have dcSSc with an increased risk of ILD leading to pulmonary fibrosis[1]. Lastly, the subset of patients with anti-RNA polymerase III antibodies is more likely to have rapidly progressive, diffuse skin disease, and renal involvement[1]. This subset may also have an increased risk of an associated malignancy, most commonly breast cancer[20].

Pathology

Histologically, areas of cutaneous induration are characterized by compact or hyalinized collagen, excessive deposition of collagen, atrophic eccrine and pilosebaceous glands, "miniaturization" or loss of subcutaneous fat, and a sparse lymphocytic infiltrate in the dermis and subcutis (Fig. 43.12). Plasma cells may be present. Adnexal structures, especially eccrine glands, appear "trapped" by the excessive deposition of collagen. In some cases, there may be a

Fig. 43.4 Pitted scars of the digital pulp in a patient with systemic sclerosis. *Courtesy Kalman Watsky, MD.*

Fig. 43.5 Late-stage disease in a patient with diffuse cutaneous systemic sclerosis. Note the fixed flexion contractures, sclerodactyly, and the digital ulceration overlying the third proximal interphalangeal joint.

Fig. 43.6 The "salt and pepper" sign. Leukoderma with retention of perifollicular pigmentation in a patient with systemic sclerosis. *Courtesy Joyce Rico, MD.*

Downloaded for Anonymous User (n/a) at Egyptian Knowledge Bank from ClinicalKey.com by Elsevier on March 10, 2024. For personal use only. No other uses without permission. Copyright ©2024. Elsevier Inc. All rights reserved.

Fig. 43.7 Mat (squared-off) telangiectasias in systemic sclerosis (SSc). **A, B** Two patients with limited cutaneous SSc; the face and palms are two of the most common sites for mat telangiectasias. **C** This patient presented with diffuse hyperpigmentation and interstitial lung disease and the presence of mat telangiectasias pointed to the diagnosis. *B, Courtesy Kalman Watsky, MD; C, Courtesy Jean L. Bolognia, MD.*

Fig. 43.9 Raynaud phenomenon in a patient with early systemic sclerosis. There is obvious blanching of two fingers as well as a violaceous hue of the forefinger. *Courtesy Jeffrey P. Callen, MD.*

CLINICAL AND LABORATORY FEATURES OF PRIMARY AND SECONDARY RAYNAUD PHENOMENON		
Feature	**Primary**	**Secondary**
Sex	F:M 20:1	F:M 4:1
Age at onset	Puberty	>25 years
Frequency of attacks	Usually <5 per day	5–10+ per day
Precipitants	Cold, emotional stress	Cold
Ischemic injury	Absent	Present
Abnormal capillaroscopy	Absent	>95%
Other vasomotor phenomena	Yes	Yes
Anti-nuclear antibodies	Absent/low titer	90–95%
Anti-centromere antibody	Absent	30–40%
Anti-topoisomerase I (Scl-70) antibody	Absent	20–30%
Anti-RNA polymerase III antibody	Absent	10–20%
In vivo platelet activation	Absent	>75%

Table 43.4 Clinical and laboratory features of primary and secondary Raynaud phenomenon. *Adapted from Pauling JD, McHugh N. The clinical aspects on autoantibodies. In: Varga J, Denton CP, Wigley FM (eds). Scleroderma: from pathogenesis to comprehensive management. New York: Springer Science+Business Media LLC 2012:209–25.*

Fig. 43.8 Calcinosis cutis of the finger in a patient with systemic sclerosis.

perineural arrangement of the inflammatory infiltrate within the deep dermis. Of note, the different subsets of SSc cannot be distinguished histologically.

Direct immunofluorescence studies are usually negative in patients with SSc. While endothelial damage can occur in cutaneous blood vessels, this finding is only seen at the ultrastructural level[6]; reduplication of the basement membrane is also observed. It should be noted that, in its end stage, areas of sclerosis may be indistinguishable histologically from other diseases characterized by collagen deposition, such as morphea (which tends to have a more robust inflammatory infiltrate than SSc in its earlier stages).

Differential Diagnosis

The primary differential diagnosis of SSc is outlined in Table 43.1 while additional entities that may have a sclerodermoid presentation are

Downloaded for Anonymous User (n/a) at Egyptian Knowledge Bank from ClinicalKey.com by Elsevier on March 10, 2024. For personal use only. No other uses without permission. Copyright ©2024. Elsevier Inc. All rights reserved.

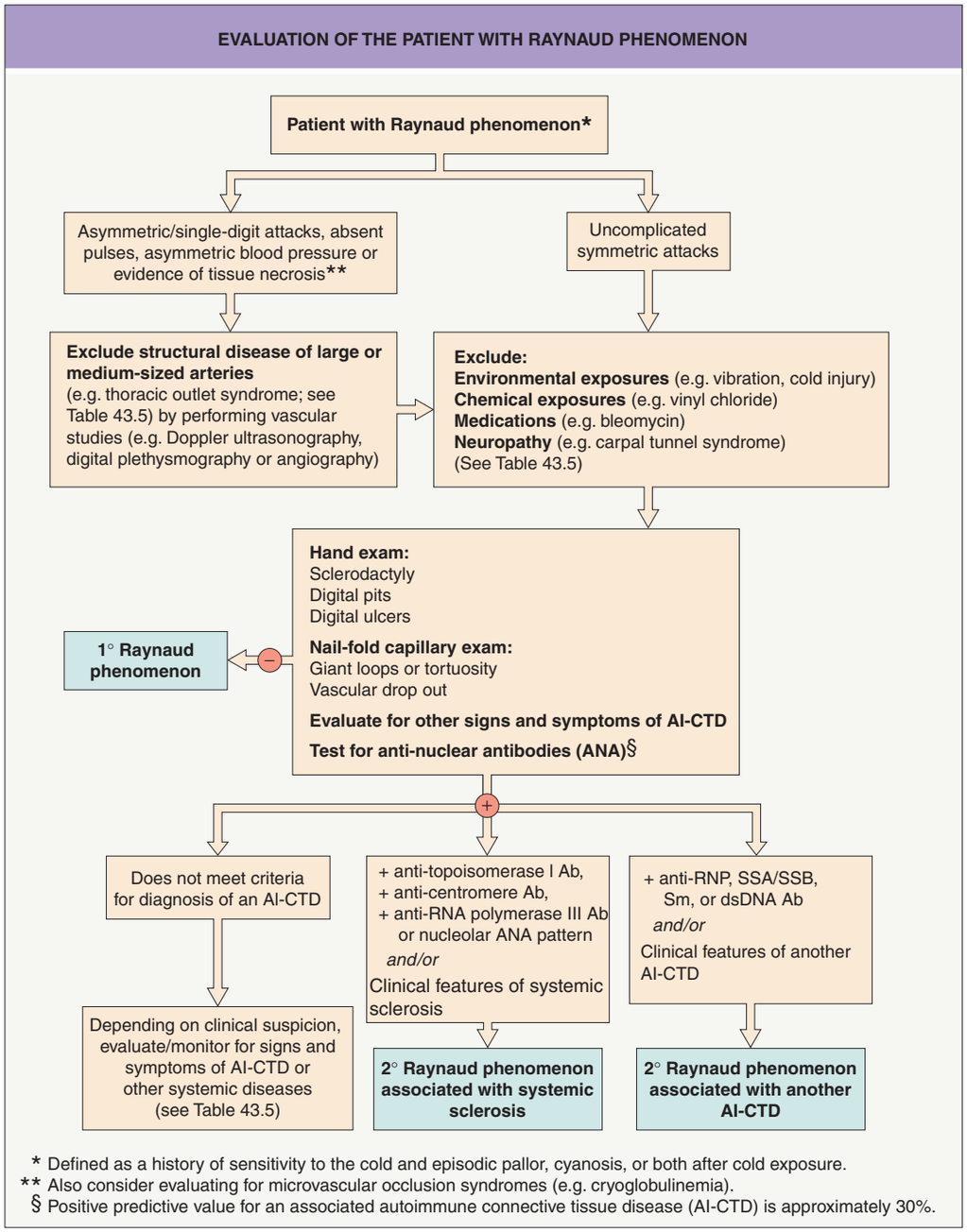

Fig. 43.10 Evaluation of the patient with Raynaud phenomenon. ds, double-stranded; RNP, ribonucleoprotein; Sm, Smith.

listed in Table 43.7[21]. Of note, chronic GVHD can have both pulmonary (e.g. bronchiolitis obliterans) and gastrointestinal manifestations. Some patients with SSc also have features of another AI-CTD, i.e. an overlap syndrome. Localized forms of scleroderma (morphea) are discussed in Chapter 44 as are morpheaform disorders.

Treatment

SSc is a challenging disease to treat[21a,21b]. Therapeutic interventions focus primarily on internal organ involvement (see Table 43.6), but unfortunately most of these treatments have minimal effect on cutaneous sclerosis and the other cutaneous manifestations (Table 43.8)[1,22].

Raynaud phenomenon

First-line therapy for Raynaud phenomenon is behavioral and involves educating patients to keep warm and avoid smoking to minimize the frequency and severity of attacks[23].

Second-line therapy is pharmacologic, starting with vasodilators[18]. Calcium channel blockers (e.g. nifedipine, amlodipine) have been the most widely used medications (see Table 43.8). Angiotensin II receptor blockers (e.g. losartan) may also be effective, and combination therapy can be tried. More recently, phosphodiesterase type 5 inhibitors (e.g. sildenafil, tadalafil) that target the nitric oxide-mediated vasodilation pathway have been employed[24]. Care must be taken so that the vasodilators do not excessively lower systemic blood pressure. In addition, calcium channel blockers may exacerbate gastroesophageal reflux disease and lead to peripheral edema. In patients who cannot tolerate these medications because of hypotension, a selective serotonin reuptake inhibitor (e.g. fluoxetine) may be an option[23]. Injections of botulinum toxin type A into the base of digits have also been reported as successful and their use has increased [24a], although outcomes in a prospective trial were disappointing[25].

Oral antiplatelet agents (e.g. low-dose aspirin, clopidogrel) and/or pentoxifylline may theoretically provide additional blood flow to compromised distal sites. Biofeedback can also be helpful. Use of HMG-CoA reductase inhibitors ("statins") as a vasoprotective treatment is under investigation and appears to be safe and well tolerated[26].

Cutaneous ulcers

Digital ulcers on the fingers are difficult to treat and a source of great morbidity. Management includes the treatments for Raynaud phenomenon outlined above. Detailed occupational and recreational histories are important to identify risk factors and sources of injury

Downloaded for Anonymous User (n/a) at Egyptian Knowledge Bank from ClinicalKey.com by Elsevier on March 10, 2024. For personal use only. No other uses without permission. Copyright ©2024. Elsevier Inc. All rights reserved.

DIFFERENTIAL DIAGNOSIS OF RAYNAUD PHENOMENON
Structural vasculopathies
Large and medium-sized arteries
Thoracic outlet syndrome Brachiocephalic trunk disease (atherosclerosis, Takayasu arteritis) Buerger disease (thromboangiitis obliterans)* Crutch pressure
Small arteries and arterioles
Systemic sclerosis Systemic lupus erythematosus Dermatomyositis Overlap syndromes Cold injury Vibration disease (hand–arm vibration syndrome, hypothenar hammer syndrome) Chemotherapy (bleomycin, vinca alkaloids, cisplatin, carboplatin) Vinyl chloride disease Arsenic poisoning
Normal blood vessels – abnormal blood elements
Cryoglobulinemia (monoclonal or mixed) Cryofibrinogenemia Cold agglutinin disease Myeloproliferative disorders (e.g. essential thrombocythemia)
Normal blood vessels – abnormal vasomotion
Primary (idiopathic) Raynaud phenomenon Drug-induced (ergot alkaloids, bromocriptine, interferon, estrogen, cyclosporine, sympathomimetic agents, clonidine, cocaine, nicotine, calcitonin gene-related peptide (CGRP)-targeting drugs) Carpal tunnel syndrome Pheochromocytoma Carcinoid syndrome Complex regional pain syndrome Other vasospastic disorders (migraine, Prinzmetal)
*Can also affect small arteries.

Table 43.5 Differential diagnosis of Raynaud phenomenon. Paraneoplastic acral vascular syndrome, which can present with Raynaud phenomenon as well as acrocyanosis and gangrene, has been observed in patients with various solid tumors (e.g. lung or ovarian carcinoma). In acute idiopathic blue finger (Achenbach syndrome), the digital blue discoloration represents ecchymosis.
Adapted from Hochberg MC, Silman AJ, Smolen JS, et al (eds). Rheumatology, 3rd edn. Edinburgh: Mosby, 2003. © Elsevier 2003.

Fig. 43.11 Cutaneous ulcerations in systemic sclerosis. Ulcers favor the digits (**A**) and sites of trauma such as the elbow (**B**). Note the calcinosis cutis at the base of the forefinger and the pterygium inversum unguis of the third finger.
A, Courtesy Kalman Watsky, MD; B, Courtesy Joyce Rico, MD.

and cold exposure. Based upon two randomized controlled trials, bosentan, an oral endothelin receptor antagonist, has been approved in Europe, but not the US, for the prevention of new digital ulcers in SSc patients[27]. While disappointing results were observed in a double-blind randomized trial of *oral* iloprost (a prostacyclin analogue)[28], when administered *intravenously*, it resulted in a reduction in digital ulcers and improved healing[29]. More limited studies of the subcutaneous prostacyclin analogue treprostinil suggest that it may also be effective. In refractory cases, nerve blocks and sympathectomies may be considered.

In patients with SSc, autolytic debridement of ulcers via occlusive dressings is thought to be safer than mechanical debridement. In general, moist hydrocolloid dressings provide a better wound healing environment than dry or wet-to-dry dressings. Skin equivalents or grafts can also be used to stimulate the wound bed and decrease wound pain. Topical vasodilators such as nitroglycerin are attractive because of ease of application and minimal systemic side effects; however, evidence-based data on their effectiveness are lacking[23].

Cutaneous sclerosis

In the early stage of SSc, cutaneous and subcutaneous edema develops rapidly, but during the indurated and atrophic stages, the cutaneous involvement progresses more slowly and tends to gradually improve, independent of treatment. Unfortunately, objective, quantitative measurements of cutaneous sclerosis that are sensitive to change over short periods of time are currently lacking for SSc. The traditional instrument for measuring skin involvement in SSc is the modified

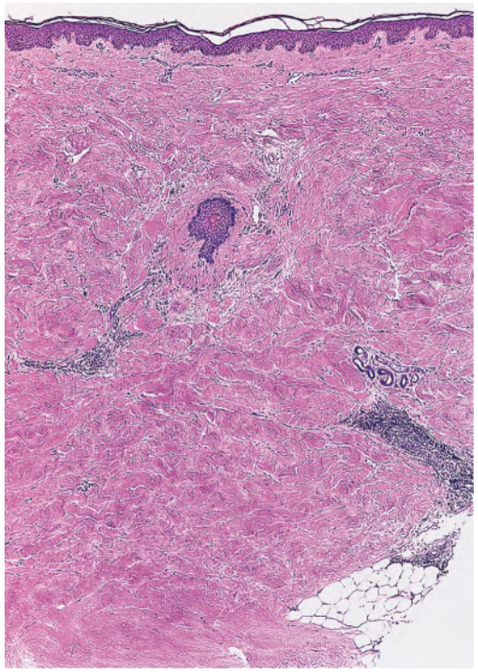

Fig. 43.12 Systemic sclerosis – histopathologic features. There is a dense sclerosis of the dermis with decreased adnexal structures and "trapping" of remaining adnexal structures that are encased by collagen. Sparse perivascular infiltrates of lymphocytes are present. *Courtesy Ronald P. Rapini, MD.*

Downloaded for Anonymous User (n/a) at Egyptian Knowledge Bank from ClinicalKey.com by Elsevier on March 10, 2024. For personal use only. No other uses without permission. Copyright ©2024. Elsevier Inc. All rights reserved.

INTERNAL ORGAN INVOLVEMENT IN SYSTEMIC SCLEROSIS – SCREENING AND TREATMENT OPTIONS		
Internal organ	**Screening tools***	**Treatment options**
Lung*		
• Interstitial lung disease (ILD)	• **PFTs (DLCO, spirometry, and lung volumes)** • **High-resolution CT (HRCT)** • Bronchoalveolar lavage and lung biopsy	• Immunosuppression (e.g. mycophenolate mofetil, cyclophosphamide, rituximab) • Nintedanib†, tocilizumab† • Lung transplantation • Autologous HSCT in selected patients with rapidly progressive ILD
• Pulmonary arterial hypertension (PAH)	• **Transthoracic echocardiography** • **Serum *N*-Tpro-BNP level** • Right heart catheterization	• Oxygen • Anticoagulation • Endothelin receptor antagonists (e.g. bosentan) • Phosphodiesterase type 5 inhibitors (e.g. tadalafil) • Prostacyclin analogues (e.g. treprostinil) • Prostacyclin receptor agonists (e.g. selexipag) • Soluble guanylate cyclase stimulant (e.g. riociguat) • Lung transplantation
Kidney		
• Renal crisis • Hypertension	• **Close monitoring of blood pressure** • **BUN/Cr** • **Urinalysis**	• ACE inhibitors instituted early for treatment but not helpful for prevention
Heart		
• Fibrosis/restrictive cardiomyopathy • Heart failure secondary to PAH	• Echocardiography	• ACE inhibitors
Gastrointestinal tract		
• Esophageal dysmotility • Small bowel involvement	• Barium swallow with small bowel follow through • Manometry • Endoscopy	• Proton pump inhibitors • Promotility agents (e.g. ondansetron)

*Patients are typically asymptomatic during the early stages of ILD and PAH, which is when the diagnosis should be made and treatment instituted; cough, dyspnea on exertion, and shortness of breath are typical later-onset symptoms.
†FDA-approved for SSc-ILD.

Table 43.6 Internal organ involvement in systemic sclerosis – screening and treatment options. Initial screening tests for all patients are in **bold**. ACE, angiotensin-converting enzyme; BUN, blood urea nitrogen; Cr, creatinine; CT, computed tomography scan; DLCO, diffusing capacity of the lung for carbon monoxide; HSCT, hematopoietic stem cell transplant; *N*-Tpro-BNP, *N*-terminal pro b-type natriuretic peptide; PFTs, pulmonary function tests.

DIFFERENTIAL DIAGNOSIS OF SCLERODERMOID CONDITIONS	
Disorder	**Clinical features**
Mucinoses	
• Scleredema	Induration of the upper back, neck and face; occasional internal involvement (see Ch. 46)
• Scleromyxedema	Waxy papules (often in a linear array); diffuse induration favoring the face, upper trunk, arms, and thighs; monoclonal gammopathy; neurologic, gastrointestinal, and pulmonary involvement (see Ch. 46)
Immunologic	
• Sclerotic chronic GVHD*	Variable sclerosis that often resembles plaque-type or deep morphea initially and then may become generalized; eosinophilic fasciitis (see Ch. 52)
• Eosinophilic fasciitis	Symmetric induration with a "pseudo-cellulite" appearance on the extremities (sparing hands and feet) (see text)
• Generalized morphea*	Expansion and coalescence of morphea plaques to involve a large portion of the trunk and extremities (see Ch. 44)
• Fibroblastic rheumatism	Sclerodactyly; fibrotic nodules on the hands
• Overlap syndromes	Sclerodactyly; myositis; arthritis
Paraneoplastic	
• POEMS syndrome	Sclerotic skin on the extremities (see Ch. 114)
• Amyloidosis (primary systemic)†	Diffuse induration favoring the face, distal extremities, and trunk (see Ch. 47)
• Carcinoid syndrome	Sclerotic skin on the legs (see Table 53.2)
• Paraneoplastic scleroderma-like syndrome	Similar to systemic sclerosis, but older age at onset; seen in association with a monoclonal gammopathy, hairy cell leukemia, and solid tumors (e.g. breast, lung)
Neoplastic	
• Carcinoma *en cuirasse**	Sclerodermoid encasement of the chest by metastatic carcinoma (usually breast cancer) (see Ch. 122)

Table 43.7 Differential diagnosis of sclerodermoid conditions.

Downloaded for Anonymous User (n/a) at Egyptian Knowledge Bank from ClinicalKey.com by Elsevier on March 10, 2024. For personal use only. No other uses without permission. Copyright ©2024. Elsevier Inc. All rights reserved.

DIFFERENTIAL DIAGNOSIS OF SCLERODERMOID CONDITIONS	
Disorder	**Clinical features**
Metabolic	
• Diabetic cheiroarthropathy	Thickened skin and limited mobility of the hands (see Fig. 53.18)
• Porphyria cutanea tarda*,‡	Morpheaform plaques in sun-exposed areas (see Ch. 49)
Neurologic	
• Complex regional pain syndrome*	Painful, cold, swollen extremity eventually develops cutaneous sclerosis (see Ch. 6)
• Spinal cord injury	Sclerotic skin in affected areas
Toxin-mediated	
• Nephrogenic systemic fibrosis*	Associated with exposure to gadolinium-based contrast agents (new cases becoming rare) (see text)
• Eosinophilia–myalgia syndrome	Associated with L-tryptophan ingestion (US, 1989) (see text)
• Toxic oil syndrome*	Associated with toxic oil ingestion (Spain, 1981) (see text)
• Silicosis	Associated with occupations such as mining (see text)
Drug- or chemical-induced (see text)	
• Bleomycin*	Acrosclerosis; Raynaud phenomenon; pulmonary fibrosis (more common, usually no concurrent skin fibrosis)
• Taxanes*	Edema followed by sclerosis of the lower extremities; acrosclerosis; rarely, pulmonary fibrosis
• Vinyl chloride, chlorinated hydrocarbons*	Acrosclerosis; acral fibrotic papulonodules; Raynaud phenomenon; acro-osteolysis; pulmonary fibrosis
Venous insufficiency	
• Lipodermatosclerosis*	Woody induration and red–brown discoloration of the lower legs in the chronic phase; may also involve the pannus (see Ch. 100)
Genetic disorders	
• Restrictive dermopathy¶	Tight, thin skin over the entire body; joint contractures; *LMNA* or *ZMPSTE24* mutations
• Hutchinson–Gilford progeria syndrome	Sclerotic skin on the lower trunk, buttocks and thighs; *LMNA* mutations (see Ch. 63)
• Werner syndrome	Tight, sclerotic skin on the distal extremities; *WRN*/*RECQL2* mutations (see Ch. 63)
• Stiff skin syndrome*	Fibrosis of the skin/fascia of the buttocks and thighs with hip contractures; *FBN1* mutations (see text)
• Phenylketonuria	Sclerotic skin on the thighs and buttocks with hip contractures; *PAH* mutations (see Ch. 63)
• MONA (multicentric osteolysis, nodulosis, and arthropathy)	Areas of skin thickening with overlying hyperpigmentation and hypertrichosis; subcutaneous nodules favoring hands/feet; digital swelling; *MMP2* mutations
• Weill–Marchesani syndrome 2	Sclerosis of the back and extensor surfaces of the extremities, with sparing of the face; also referred to as GEMSS (glaucoma, lens ectopia, microspherophakia, stiffness of the joints, and shortness) syndrome; *FBN1* mutations
• Primary hypertrophic osteoarthropathy (pachydermoperiostosis)	Thickening of the skin of the distal extremities and face, with furrowing of the forehead; seborrhea; digital clubbing; *HPGD* and *SLCO2A1* mutations (see Ch. 98)
• Ataxia–telangiectasia	Tight, sclerotic facial skin; *ATM* mutations (see Ch. 60)
• Huriez syndrome	Congenital scleroatrophy of distal extremities, palmoplantar keratoderma, hypoplastic nails & development of aggressive SCC in affected areas; haploinsufficiency of *SMARCAD1* which encodes a DNA helicase (see Ch. 58)
• Geleophysic dysplasia	Thick skin, short stature, a "happy" face, and joint contractures; mutations in *ADAMTSL2*, *FBN1*, and *LTBP3*
• H syndrome (histiocytosis–lymphadenopathy plus syndrome)	*H*ypertrichosis in association with areas of *h*yperpigmentation and induration (primarily lower trunk and lower extremities), sensorineural *h*earing loss, short *h*eight, *h*eart anomalies, *h*epatosplenomegaly, scrotal masses, hypergonadotropic *h*ypogonadism, antibody-negative insulin-dependent diabetes mellitus, facial telangiectasias (see Fig. 55.2); mutations in *SLC29A3* which encodes nucleoside transporter hENT3

*Can overlap with morpheaform disorders, which are listed in Table 44.1.
†Primary cutaneous amyloidosis can also occur in patients with systemic sclerosis and generalized morphea.
‡May also be observed in patients with congenital erythropoietic porphyria and hepatoerythropoietic porphyria.
¶Sclerodermoid changes are typically present at birth.

Table 43.7 Differential diagnosis of sclerodermoid conditions. Disorders with a clinical presentation similar to systemic sclerosis are referred to as *sclerodermoid*, while those reminiscent of morphea are referred to as *morpheaform* (see Ch. 44).

Rodnan skin score (mRSS)[1]. Although this is a validated outcome measure, it is not ideal and is relatively insensitive to small changes over short periods of time. An adapted engineering tool, the durometer, may be more suitable for assessing cutaneous induration and hardness in patients with SSc[30]. Ultrasound and lasers have also been used to measure skin sclerosis.

In general, topical therapies and phototherapeutic regimens are those utilized for morphea (see Ch. 44)[31] and may help some SSc patients. With regard to systemic medications, in a trial of D-penicillamine for dcSSc, there was no difference between the low-dose and the high-dose treatment groups, and this drug is now rarely used[32]. Although minocycline looked promising in a pilot study, a larger follow-up study failed to show a benefit[33]. Methotrexate (MTX) can be helpful in SSc patients with overlapping myositis and inflammatory arthritis. However, in a randomized, placebo-controlled trial (involving 71 patients with early SSc) in which MTX was administered for 1 year, there was a trend in favor of MTX, but it did not reach statistical significance[34]. Nonetheless, based upon its usefulness in morphea[31], a 3- to 6-month trial of MTX is reasonable in patients *without* ILD (see Table 43.8).

Mycophenolate mofetil (MMF) is routinely used for SSc-ILD (see below) and in some patients, it may be of benefit for early cutaneous sclerosis[35]. However, there is no consensus regarding a 6- to 12-month empiric

Downloaded for Anonymous User (n/a) at Egyptian Knowledge Bank from ClinicalKey.com by Elsevier on March 10, 2024. For personal use only. No other uses without permission. Copyright ©2024. Elsevier Inc. All rights reserved.

CUTANEOUS FEATURES OF SYSTEMIC SCLEROSIS – POSSIBLE TREATMENTS	
Cutaneous feature	**Possible treatment options**
Cutaneous sclerosis	• Topical therapies (see Ch. 44) • UV phototherapy (see Ch. 44) • Mycophenolate mofetil • D-penicillamine* • Methotrexate (if no ILD)‡,¶ • IVIg • Rituxumab
Raynaud phenomenon (Figs. 43.9 and 43.10)	**First-line** • Cold avoidance • Hand and feet warming packets • Discontinue all tobacco products **Second-line** • Calcium channel blockers (for normotensive patients, starting doses: nifedipine SR 30 mg daily, increasing to BID after 2 weeks if tolerated; amlodipine 2.5 mg daily, with increments of 2.5 mg every 2 weeks as tolerated, up to 10 mg daily) **Third-line** (especially when accompanied by ulceration) • Phosphodiesterase type 5 inhibitors (sildenafil: initial dose as low as 5 mg PO TID, but most patients tolerate and require 50 mg PO BID; tadalafil: initially 20 mg PO every other day, then increased every 3–5 days as tolerated up to 40 mg PO daily) • α-Adrenergic blockers (e.g. prazosin) • Angiotensin II receptor blockers (e.g. losartan) • Endothelin receptor antagonists (e.g. bosentan) **Fourth-line** • Serotonin reuptake inhibitors (e.g. fluoxetine) • Botulinum toxin type A injections into base of digits
Cutaneous ulcers (Fig. 43.11)	• Avoid excessive debridement • Moist, non-adherent dressings • Therapies listed above for Raynaud phenomenon • Low-dose aspirin or clopidogrel • IV prostanoid (e.g. epoprostenol) • Surgical excision (recalcitrant and severe cases)
Calcinosis cutis (Fig. 43.8)	• Bisphosphonates • Calcium channel blockers (e.g. diltiazem) • Sodium thiosulfate (see Ch. 50)
Mat telangiectasias (Fig. 43.7)	• Lasers appropriate for vascular lesions

*Nowadays used infrequently.
‡Methotrexate-induced pneumonitis may complicate SSc-ILD picture.
¶Concern that concomitant administration of systemic corticosteroids may increase risk of developing renal crisis; low-dose corticosteroids (e.g. prednisone <10 mg daily) may be safe.

Table 43.8 Cutaneous features of systemic sclerosis – possible treatments. Therapeutic agents under investigation include romilkimab, a humanized antibody that neutralizes IL-4/IL-13, and in preclinical models, dersimelagon, an oral agonist of the melanocortin I receptor. BID, twice a day; ILD, interstitial lung disease; IV, intravenous; PO, per os (oral administration); SR, slow release; TID, three times a day; UV, ultraviolet.

trial of MMF (2–3 g daily) for early dcSSc. As expected, the dosage may need to be adjusted based upon side effects, in particular cytopenias and gastrointestinal symptoms (see Ch. 130). MMF may be used in junction with MTX for severe, rapidly progressive cutaneous sclerosis, but close monitoring is required. Sirolimus is an mTOR inhibitor that has been used for renal transplant rejection and may also be a candidate drug for SSc. It has an anti-fibrotic effect and has been used in GVHD. Some data exist to support the use of IVIg, even in recalcitrant cutaneous disease, but larger studies are needed[36]. In a phase II trial, the autotaxin inhibitor ziritaxestat led to an improvement in cutaneous sclerosis based upon mRSS.

A number of other systemic agents have been tried in SSc, but ultimately most have been shown to be ineffective[37]. A small study that examined anti-TGF-β1 antibodies did not show a benefit[1]. Histologically, a decrease in skin thickness was observed in dcSSc following 12 months of imatinib[38].

Other cutaneous complications

Calcinosis cutis represents a serious problem for which no effective medical therapy exists. While low-dose warfarin may decrease the inflammatory reaction associated with calcium deposits, it is no longer a recommended treatment[38a]. Although there were case reports of the effectiveness of calcium channel blockers for calcinosis, this was not observed in larger patient series. Topical and intralesional sodium thiosulfate has been used to treat calcinosis cutis[37], but the injections can be painful (see Table 50.2). In certain situations, surgical removal of the calcium deposits may be necessary. Treatment with extracorporeal shock wave lithotripsy has also been reported. Telangiectasias can be treated cosmetically with lasers appropriate for vascular lesions (e.g. pulsed dye).

Internal organ involvement

Treatment of specific internal organ involvement is outlined in Table 43.6. Detailed discussions of these therapeutic approaches are available in other texts[1,19]. Of note, the use of ACE inhibitors to treat scleroderma renal crisis represents a major therapeutic advance[1].

In a number of studies, treatment with either cyclophosphamide or MMF has been shown to benefit SSc-ILD[1]. For example, one prospective, randomized, controlled trial showed a modest benefit with oral cyclophosphamide (1 to 2 mg/kg/day for 1 year) compared to placebo[39]. However, there are significant potential side effects associated with cyclophosphamide, such as cytopenias, hemorrhagic cystitis, and an increased risk of bladder carcinoma (see Ch. 130). A large, multicenter, randomized, controlled trial showed that cyclophosphamide and MMF had an equivalent benefit on SSc-ILD, but MMF had a superior tolerability and safety profile[40].

Nintedanib blocks autophosphorylation-based activation of several growth factor receptors (GFRs) – fibroblast (FGFRs), platelet-derived (PDGFRs) and vascular endothelial (VEGFRs) – via binding to their intracellular ATP binding sites. It was FDA-approved for the treatment of SSc-ILD based upon less of a decline in forced vital capacity in a randomized, double-blind, controlled trial involving 576 patients[41]. The most common side effects include diarrhea, nausea, transaminitis, hypertension, and pneumonia. Tocilizumab, an interleukin 6 receptor inhibitor, is also FDA-approved for SSc-ILD but in a phase III randomized trial its effect on skin fibrosis did not differ from placebo[42].

Advances in the treatment of PAH have also occurred, in particular the use of oral vasoactive compounds, some of which are also used for Raynaud phenomenon and digital ulcers[1]. These include endothelin receptor antagonists (bosentan[43], ambrisentan, macitentan) and phosphodiesterase type 5 inhibitors (sildenafil, tadalafil). Prostacyclin analogues (iloprost [inhaled], epoprostenol [intravenous], treprostinil [inhaled, subcutaneous, or intravenous]) and the oral prostacyclin receptor agonist selexipag are approved for PAH in SSc patients but are no longer sole or first-line therapy[1]. Lung transplantation is an option, with survival rates as well as risks for developing acute rejection and bronchiolitis obliterans syndrome similar in SSc patients when compared to those without AI-CTDs[44].

A French nationwide cohort study found that IVIg led to an improvement in muscle and joint, but not skin, disease[45]. In a recent meta-analysis examining the efficacy of imatinib, cutaneous sclerosis improved based upon mRSS following a 6- to 12-month course, but there were insufficient data regarding its effect on lung involvement[46]. Rituximab has been investigated as a rescue therapy and in one trial was superior to cyclophosphamide for SSc-ILD[47].

Three randomized controlled trials comparing cyclophosphamide versus autologous hematopoietic stem cell transplantation (HSCT) demonstrated HSCT superiority, with greater improvement in lung and skin disease as well as quality-of-life[48]. Risks include transplant-related mortality and recurrence of disease. Therefore, autologous HSCT is considered for selected patients with rapidly progressive SSc at risk of organ failure or significant morbidity.

Downloaded for Anonymous User (n/a) at Egyptian Knowledge Bank from ClinicalKey.com by Elsevier on March 10, 2024. For personal use only. No other uses without permission. Copyright ©2024. Elsevier Inc. All rights reserved.

EOSINOPHILIC FASCIITIS

Synonyms: ▪ Shulman syndrome ▪ Diffuse fasciitis with eosinophilia

History

Eosinophilic fasciitis was first reported in 1975 by Shulman, who described a fibrosing disorder characterized by the rapid onset of woody induration of the extremities in association with peripheral eosinophilia[49].

Clinical Features

A history of strenuous physical activity precedes the clinical findings in about 30% of patients with eosinophilic fasciitis. Initial manifestations include edema and pain of the involved extremities, which quickly progress to sclerosis and a dimpled or "pseudo-cellulite" appearance (Fig. 43.13). The distribution is symmetric and usually spares the hands, feet and face. The "groove sign" refers to linear depressions where veins appear to be sunken within the indurated skin.

Laboratory findings include an elevated ESR, hypergammaglobulinemia, and peripheral eosinophilia[50]; the latter may not be present if the patient is already receiving corticosteroids. The ANA titer is typically not elevated, and complement levels are normal. Pancytopenia, anemia, thrombocytopenia, myeloproliferative disorders, and monoclonal gammopathy have been reported in association with this disease. Some authors have advocated that patients with eosinophilic fasciitis and unexplained anemia undergo bone marrow biopsy to evaluate for a hematologic malignancy. Patients with chronic GVHD can develop clinical manifestations resembling eosinophilic fasciitis (see Ch. 52), as can those receiving immune checkpoint inhibitors, in particular anti-PD-1 and -PD-L1 antibodies.

Pathology

Histologically, there is a thickening of the deep fascia, which may be 10 to 50 times the normal width (Fig. 43.14). Within the fascia and subfascial muscle, a patchy infiltrate composed of lymphocytes, plasma cells, and a variable number of eosinophils is seen. Dermal sclerosis is a feature in some cases[51].

Treatment

Once the diagnosis of eosinophilic fasciitis is established via fascial biopsy and/or MRI (see Fig. 52.9), prompt treatment is essential to preserve mobility and function and prevent joint contractures. Therapy is usually initiated with oral corticosteroids (e.g. prednisone 1–2 mg/kg daily). Response is typically noted within the first few weeks, and clinical improvement may be seen over several months. The dose of prednisone is tapered over 6–24 months as tolerated. Due to the need for a relatively prolonged course of corticosteroids, a concurrent immunosuppressive drug (e.g. methotrexate, MMF) is often administered[52]. If an inadequate response is observed, other options include pulse-dose corticosteroids, IVIg, hydroxychloroquine, JAK inhibitors, UVA-based phototherapy, and cyclosporine.

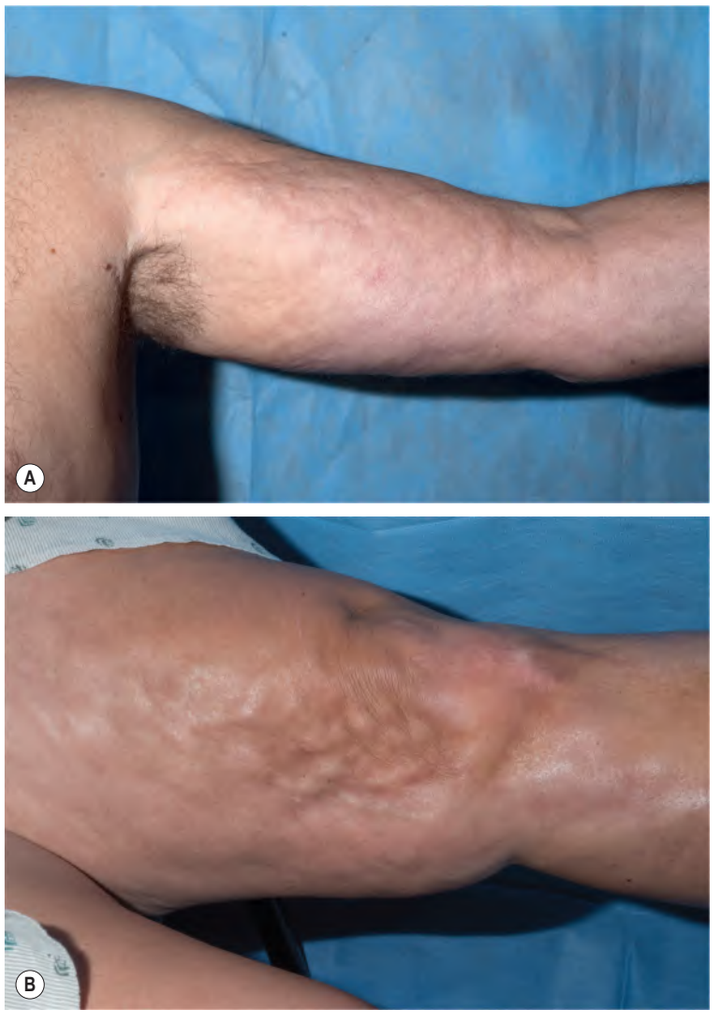

Fig. 43.13 Eosinophilic fasciitis – clinical features. A Induration of the arm with a dimpled or "pseudo-cellulite" appearance, also referred to as rippling or puckering. **B** Firm, irregular induration and nodularity of the medial thigh. The differential diagnosis includes deep morphea. *Courtesy Edward Cowen, MD.*

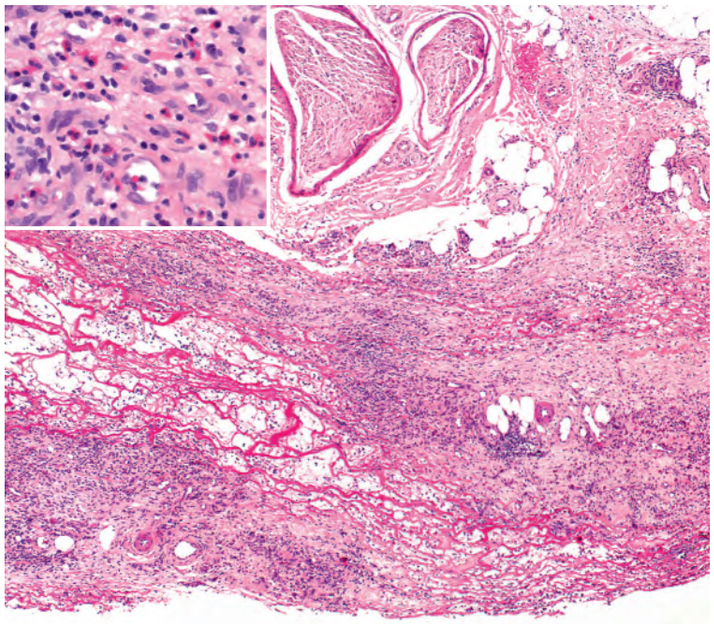

Fig. 43.14 Eosinophilic fasciitis – histopathologic features. Thickening of the deep fascia and septae of the subcutis with an inflammatory infiltrate comprised of lymphocytes, histiocytes, and eosinophils (inset). *Courtesy Luis Requena, MD.*

STIFF SKIN SYNDROME

Synonym: ▪ Congenital fascial dystrophy

History

Stiff skin syndrome was first described by Esterly and McKusick in 1971[53].

Epidemiology

This condition may be congenital or develop during early childhood. Familial occurrences have been described.

Downloaded for Anonymous User (n/a) at Egyptian Knowledge Bank from ClinicalKey.com by Elsevier on March 10, 2024. For personal use only. No other uses without permission. Copyright ©2024. Elsevier Inc. All rights reserved.

Pathogenesis

Stiff skin syndrome is due to heterozygosity for a mutation in the gene that encodes fibrillin-1 (*FBN1*). The presence of giant "amianthoid-like" collagen fibrils in affected fascia had been postulated to reflect a disturbance in the organization of collagen and glycosaminoglycans within the extracellular matrix.

Clinical Features

Stiff skin syndrome is characterized by "rock hard" induration and thickening of the skin and subcutaneous tissues, which is most pronounced on the buttocks and thighs, with characteristic sparing of the inguinal folds[54]. The hands and feet are not involved. Mild hypertrichosis is often observed in affected areas. Restricted joint mobility leads to a characteristic posture of hip and knee flexion and prominent lumbar lordosis while standing, and patients may have short stature. The condition is stable or slowly progressive, and abnormalities of internal organs are not typically observed.

Patients with unilateral involvement have been reported, some with features that overlapped with scleredema, deep morphea, and linear melorheostotic scleroderma. In a patient with the segmental form of stiff skin syndrome, an interleukin(IL)-17C mutation was detected.

Pathology

Histopathologic examination demonstrates markedly thickened, hyalinized fascia without an associated inflammatory infiltrate. Thickened collagen bundles and mucin deposition may or may not be present in the overlying dermis.

Treatment

Stiff skin syndrome has a chronic course, and no effective treatments have been reported. Physical therapy can help to prevent progressive joint contractures. The segmental form with an associated IL-17 mutation (see above) was successfully treated with secukinumab.

SCLERODERMOID SYNDROMES INDUCED BY EXOGENOUS SUBSTANCES

Exposure to drugs, chemicals, and other exogenous substances can lead to cutaneous and extracutaneous sclerosis (see Table 43.7)[21].

Nephrogenic Systemic Fibrosis

Synonym: ▪ Nephrogenic fibrosing dermopathy

Fortunately, the incidence of nephrogenic systemic fibrosis (NSF) has steadily declined since nearly all patients had a history of exposure to gadolinium-based contrast agents with the vast majority having advanced chronic kidney disease or acute kidney injury at the time of exposure (see Table 43.1)[55–57]. Initial cases were described in the early 2000s and by 2010, the FDA had declared three gadolinium-based contrast agents (gadopentetate dimeglumine [Magnevist®], gadodiamide [Omniscan™], gadoversetamide [OptiMARK™]) as contraindicated in such patients.

NSF presents with thick, indurated plaques distributed symmetrically on the trunk and extremities, often resulting in joint contractures (Fig. 43.15). The plaques are erythematous to hyperpigmented and can have an irregular advancing edge with an "ameboid" appearance. In addition to yellow scleral plaques, fibrosis can develop within the heart, lungs, and skeletal muscle. Because the disease process typically extends along fibrous septa into the subcutis, a deep biopsy specimen is required for diagnosis. Histopathologic features include a haphazard arrangement of thickened collagen bundles and increased dermal fibroblast-like cells that stain positively for CD34 and procollagen I. Mucin deposition and osseous metaplasia may be seen and by energy dispersive spectroscopy, particles of gadolinium can be detected within involved tissue.

Fig. 43.15 Nephrogenic systemic fibrosis (NSF) – clinical features. Orange–brown indurated plaques. Note the "ameboid" outline of one of the plaques on the left foot. *Courtesy Edward Cowen, MD.*

NSF is generally refractory to treatment with corticosteroids and other immunosuppressive drugs; potential therapeutic options are outlined in Table 53.14. Improvement in renal function following renal transplantation has been reported to improve NSF.

Toxic Oil Syndrome

In 1981, the toxic oil syndrome affected more than 25 000 people in Spain; 600 died and ~300 remained permanently disabled. It resulted from the ingestion of aniline-degraded and reprocessed rapeseed oil, which led to a specific immune response in genetically susceptible individuals. In humans, toxic oil syndrome started with a morbilliform eruption and flu-like symptoms such as fever and headache; peripheral eosinophilia was observed in half of affected individuals. The inflammatory process subsequently affected the CNS, lungs, and salivary glands. Skin involvement either resolved, evolved into a lichen planus-like eruption, or progressed to a morpheaform or sclerodermoid picture.

Eosinophilia–Myalgia Syndrome

In 1989, a contaminated preparation of L-tryptophan led to an outbreak of "eosinophilia–myalgia syndrome", which affected more than 1500 people in the US and led to at least 30 fatalities. The acute phase of the condition was characterized by severe myalgias, fever, dyspnea, edema, a macular exanthem, and peripheral eosinophilia. Despite the discontinuation of L-tryptophan intake, approximately half of patients went on to a chronic phase that featured diffuse, deep sclerodermoid induration of the extremities (with acral sparing), progressive peripheral neuropathy, and myopathy.

Sclerodermoid Syndromes Induced by Other Chemicals

Exposure to certain organic chemicals can lead to a clinical picture that resembles SSc (see Table 43.7). In contrast to the acute onset of the toxic oil and eosinophilia–myalgia syndromes, exposure to vinyl chloride, organic solvents (e.g. trichloroethylene, trichloroethane, perchloroethylene), pesticides, or epoxy resins induces a slowly progressive process of sclerosis. It typically begins with insidious acrosclerosis and Raynaud phenomenon (especially with vinyl chloride exposure). Acral osteolysis, hepatic toxicity, and pulmonary involvement are often observed. In addition, patients experience fatigue, weight loss, arthralgias, and myalgias. Autoantibodies are absent, and cessation or reversal of the disease process follows removal of the exposure.

Downloaded for Anonymous User (n/a) at Egyptian Knowledge Bank from ClinicalKey.com by Elsevier on March 10, 2024. For personal use only. No other uses without permission. Copyright ©2024. Elsevier Inc. All rights reserved.

Silicosis

The incidence of SSc is approximately 20-fold higher in individuals with occupational exposure to silica, such as miners and foundry workers, than in the general population. In an epidemiologic study from Germany, three-quarters of men with typical SSc had been exposed to silica dust in the workplace. The mean duration of exposure was 14 years, with a mean delay in onset of the disease of 24 years from the first exposure. Once absorbed, silica cannot be removed from the body. Although silica has nonspecific proinflammatory and profibrotic effects, HLA and TNF allele associations suggest the need for a specific pre-existing immunophenotype for disease progression to occur. SSc associated with pulmonary silicosis is clinically, serologically, and immunologically indistinguishable from the idiopathic form of the disease.

Sclerodermoid Syndromes Induced by Drugs

Several drugs, particularly bleomycin and the taxanes (see Table 43.7), can induce cutaneous sclerosis and pulmonary fibrosis mimicking SSc. Additional medications that have been associated with sclerodermoid changes include other chemotherapeutic agents such as cisplatin, pemetrexed, carboplatin, topotecan, and gemcitabine (especially of the lower extremities) as well as ergot alkaloids, L-5-hydroxytryptophan +/– carbidopa, appetite suppressants, and cocaine.

Additional figures and table on Eosinophilic fasciitis - diagnostic criteria, available in our eBook (see inside front cover for access code).

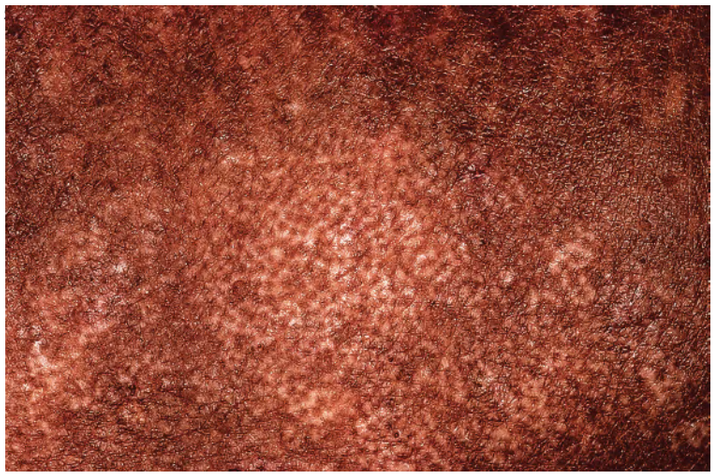

eFig. 43.1 The "salt and pepper" sign. Leukoderma with retention of perifollicular pigmentation in a patient with systemic sclerosis.

eFig. 43.2 Mat (squared-off) telangiectasias in systemic sclerosis. The palms are a common site for mat telangiectasias. *Courtesy Kalman Watsky, MD.*

eFig. 43.3 Pitted scars of the digital pulp in a patient with systemic sclerosis. *Courtesy Frank Samarin, MD.*

eFig. 43.4 Raynaud phenomenon in a patient with severe sclerotic chronic graft-versus-host disease. The fingers have a violaceous hue as well as areas of blanching (white) and digital ulceration. Oral sildenafil led to a significant improvement. *Courtesy Jean L. Bolognia, MD.*

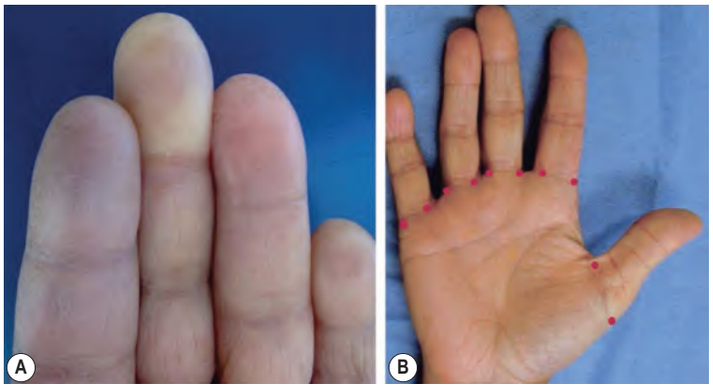

eFig. 43.5 Raynaud phenomenon. A Pallor of fingers due to vasoconstriction and interruption of regional vascular flow as well as blue-colored cyanosis corresponding to blood de-oxygenation. **B** Injection of botulinum toxin type A into the bases of the fingers restores normal circulation. Some clinicians avoid injecting the thumb unless there is significant symptomatic involvement. *Courtesy Alastair Carruthers, MD, and Jean Carruthers, MD.*

Downloaded for Anonymous User (n/a) at Egyptian Knowledge Bank from ClinicalKey.com by Elsevier on March 10, 2024. For personal use only. No other uses without permission. Copyright ©2024. Elsevier Inc. All rights reserved.

eFig. 43.6 Stiff skin syndrome. Rock-hard, irregular induration of the thighs with overlying hypertrichosis. The inguinal creases were spared. *Courtesy Julie V. Schaffer, MD.*

eFig. 43.7 Linear melorheostotic scleroderma. A Limb swelling accompanied by hyperostosis. **B** X-ray demonstrating the dripping candle wax-like changes of the cortical bone of the femur. *Courtesy Smita Jha, MD.*

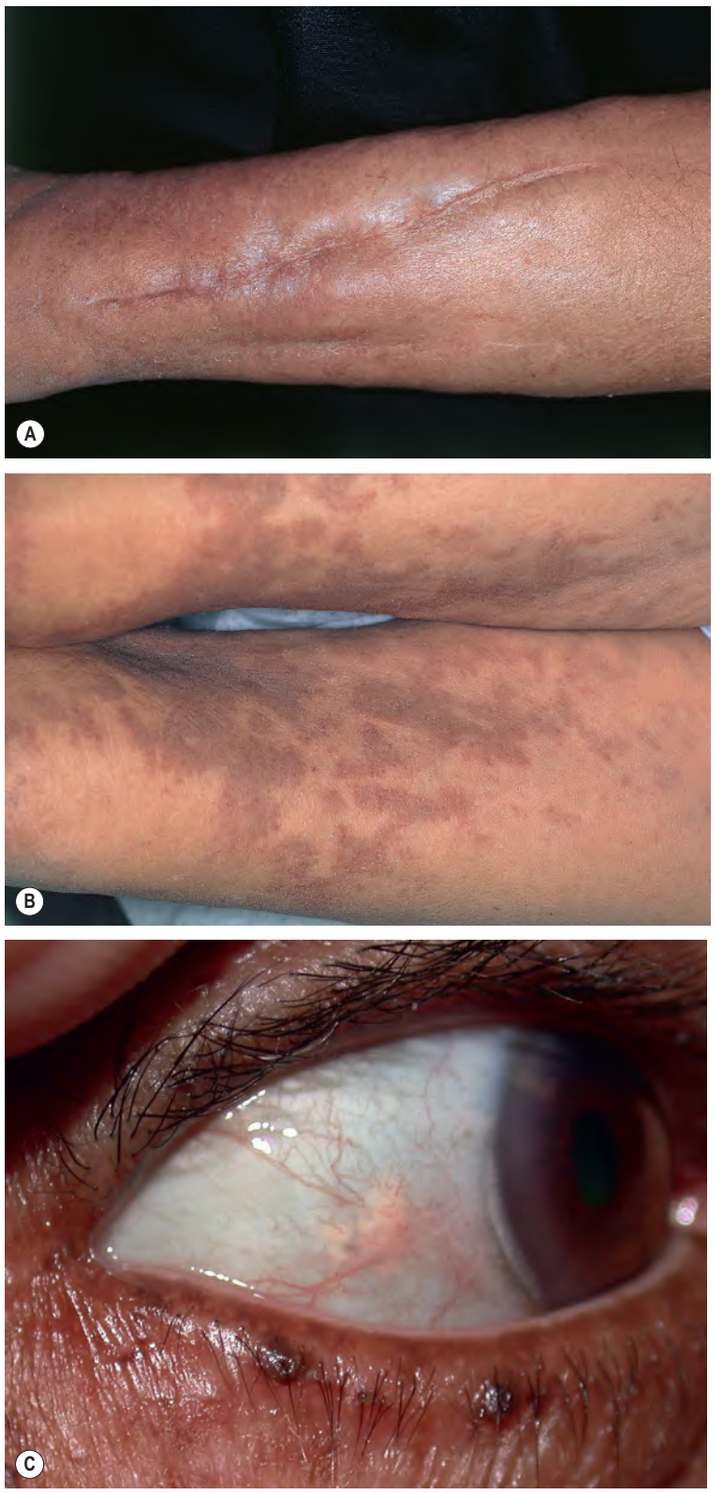

eFig. 43.8 Nephrogenic systemic fibrosis (NSF) – clinical features. Thickening and induration of the skin can be obvious (**A**), or lesions may present as purple–brown plaques (**B**). Scleral plaques (**C**) in a patient less than 45 years of age is a minor criterion for NSF. *A, Courtesy Jean L. Bolognia, MD; B, Courtesy Kalman Watsky, MD.*

Downloaded for Anonymous User (n/a) at Egyptian Knowledge Bank from ClinicalKey.com by Elsevier on March 10, 2024. For personal use only. No other uses without permission. Copyright ©2024. Elsevier Inc. All rights reserved.

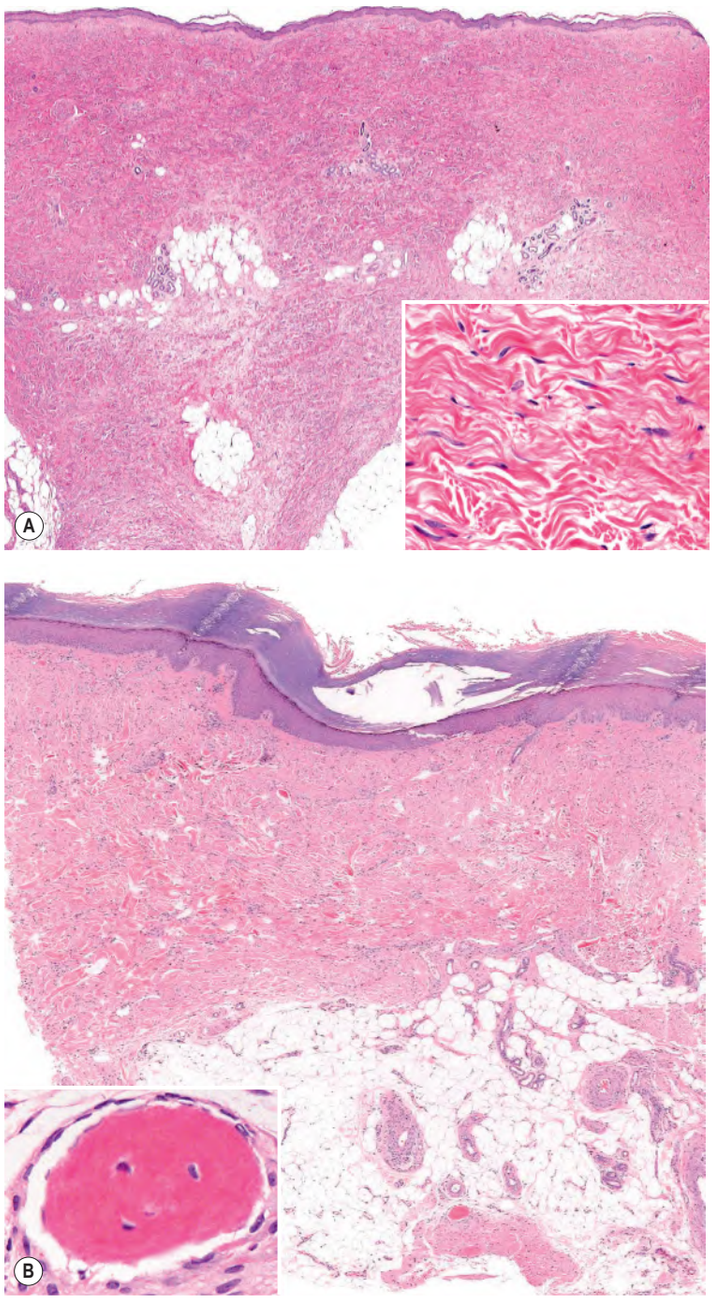

eFig. 43.9 Nephrogenic systemic fibrosis – histopathologic features. A, B There is an increase in the cellularity and amount of collagen in the dermis and within the septae of the panniculus. The spindle cells (inset, **A**) stain positively for CD34 and procollagen I. If present, osseous metaplasia ("osteoid bodies") is a useful clue to the diagnosis (inset, **B**). *Courtesy Lorenzo Cerroni, MD.*

EOSINOPHILIC FASCIITIS – DIAGNOSTIC CRITERIA
Major criterion
• Symmetric plate-like sclerotic lesions on four extremities*
Minor criteria
• Histopathology (biopsy specimen includes fascia) – fibrosis of subcutaneous connective tissue, with thickening of the fascia and inflammatory infiltrate of eosinophils and monocytes
• Diagnostic imaging, e.g. MRI – thickening of fascia
Definitive diagnosis: 1 major and 1 minor or 1 major and 2 minor criteria
*Absence of Raynaud phenomenon and systemic sclerosis excluded.

eTable 43.1 Eosinophilic fasciitis – diagnostic criteria.

Downloaded for Anonymous User (n/a) at Egyptian Knowledge Bank from ClinicalKey.com by Elsevier on March 10, 2024. For personal use only. No other uses without permission. Copyright ©2024. Elsevier Inc. All rights reserved.