Xanthomas 92

William Trent Massengale

Key features

- Cutaneous xanthomas can signal the presence of an underlying hyperlipidemia or monoclonal gammopathy
- An understanding of basic lipid metabolism provides insight into the underlying hyperlipoproteinemias as well as the formation of xanthomas
- The major forms of xanthomas associated with hyperlipidemia are: eruptive, tuberous, tendinous, and plane (including xanthelasma)
- Normolipemic plane xanthomas occur in association with monoclonal gammopathies
- Histologically, lipid-laden macrophages (foam cells) are seen in the dermis
- Prompt recognition and proper treatment can lead to xanthoma resolution as well as prevention of potentially life-threatening complications

INTRODUCTION

Cutaneous xanthomas develop as a result of deposition of lipid in the dermis, primarily within macrophages (foam cells) but also extracellularly. One of their major distinguishing clinical features is a characteristic yellow to orange hue. Xanthomas may present with a variety of morphologies, from macules and papules to plaques and nodules. As discussed below, the morphology and anatomic location of the lesions often suggest the type of underlying lipid disorder or the presence of a paraproteinemia.

Xanthomas can develop in the setting of primary or secondary disorders of lipid metabolism. Thus, early recognition of these lesions can make a significant impact on the diagnosis, management, and prognosis of patients who suffer from an underlying disease. It is therefore important for dermatologists to become familiar with the basic concepts of lipid metabolism and the associated disease states, as well as to be able to recognize the often pathognomonic cutaneous findings.

EPIDEMIOLOGY

Hyperlipidemia is quite common in the general population. In North America alone, it is estimated that over 100 million people currently have an elevated serum cholesterol level >200 mg/dl. Despite the large number of people who suffer from hyperlipidemia, only a minority will develop cutaneous xanthomas. Also, because the exact mechanism by which xanthomas form is not yet fully understood, it is not always possible to predict who will develop them. Xanthomas are thought to result from the permeation of circulating plasma lipoproteins through dermal capillary blood vessels followed by phagocytosis of the lipoproteins by macrophages, forming lipid-laden cells known as foam cells[1]. However, the precise steps and their regulation are still an area of investigation.

PATHOGENESIS

There is strong evidence to support the theory that the lipids found in the various xanthomas are the same as those in the circulation[2]. The majority of plasma lipids are transported in complex structures known as lipoproteins. The basic structure of the lipoprotein allows the delivery of triglycerides and cholesterol to peripheral cells for their metabolic needs. This structure consists of a hydrophilic outer shell and a hydrophobic core. The outer shell consists of phospholipids, free cholesterol, and non-covalently linked specialized proteins known as apolipoproteins or apoproteins (apo). The inner core contains triglycerides and cholesterol esters.

Lipoproteins differ in their core lipid content. Triglycerides are the major core lipids in chylomicrons and very-low-density lipoproteins (VLDLs), while cholesterol esters dominate the core of low-density lipoproteins (LDLs), high-density lipoproteins (HDLs), and remnants of chylomicrons and VLDLs. The apoproteins found in the outer shell can also differ amongst the various lipoproteins (Table 92.1). These apoproteins serve several important functions, such as mediating the binding of lipoproteins to their respective receptors in target organs and activating enzymes involved in their metabolism.

There are two major pathways of lipoprotein synthesis (Fig. 92.1A). The *exogenous* pathway begins with dietary fat intake. Through the action of pancreatic lipase and bile acids, dietary triglycerides are degraded to fatty acids and monoglycerides. After absorption by the intestinal epithelium, the triglycerides are reformed and packaged with a small amount of cholesterol esters into the central core of a chylomicron. The outer shell of the chylomicron consists of phospholipids, free cholesterol, and several apoproteins, including B-48, E, A-I, A-II, and C-II.

Chylomicrons then enter the lymphatics and eventually the systemic circulation via the thoracic duct. Once in the circulation, hydrolysis of the core triglycerides occurs, releasing free fatty acids to the peripheral tissues. This is mediated through the action of the enzyme lipoprotein lipase that is bound to capillary endothelium. The activation of the lipoprotein lipase system is complex and involves not only hormones such as insulin, but also apoproteins such as C-II, located on the lipoprotein outer surface, and GPIHBP1, a protein expressed on endothelial cells that binds lipoprotein lipase and shuttles it to its site of action in the capillary lumen.

After hydrolysis of ~70% of the original triglyceride content, a chylomicron "remnant" exists. The central core now contains predominantly cholesterol ester that has been acquired from circulating HDL molecules. The chylomicron remnant is taken up by the liver via specialized high-affinity apo B-100/E receptors that recognize the apoproteins E_3 or E_4 on the remnant's outer shell. Once in the liver, the remaining lipids enter hepatic storage and apoproteins such as B-48 are degraded.

IMPORTANT APOPROTEINS		
Apoprotein	**Lipoprotein association**	**Function and comments**
A-I	Chylomicrons, HDLs	Major protein of HDL; activates lecithin:cholesterol acyltransferase (LCAT)
B-48	Chylomicrons, chylomicron remnants	Unique marker for chylomicrons
B-100	VLDLs, IDLs, and LDLs	Major protein of LDL; binds to LDL receptor
C-II	Chylomicrons, VLDLs, IDLs, and HDLs	Activates lipoprotein lipase
E (at least 3 alleles [E_2, E_3, E_4])	Chylomicrons, chylomicron remnants, VLDLs, IDLs, and HDLs	Binds to LDL receptor (B-100/E receptor)

Table 92.1 Important apoproteins. See Fig. 92.1. Lipoprotein X appears in the sera of patients with severe cholestatic liver diseases. HDL, high-density lipoprotein; IDL, intermediate-density lipoprotein; LDL, low-density lipoprotein; VLDL, very-low-density lipoprotein.

Downloaded for Anonymous User (n/a) at Egyptian Knowledge Bank from ClinicalKey.com by Elsevier on March 10, 2024. For personal use only. No other uses without permission. Copyright ©2024. Elsevier Inc. All rights reserved.

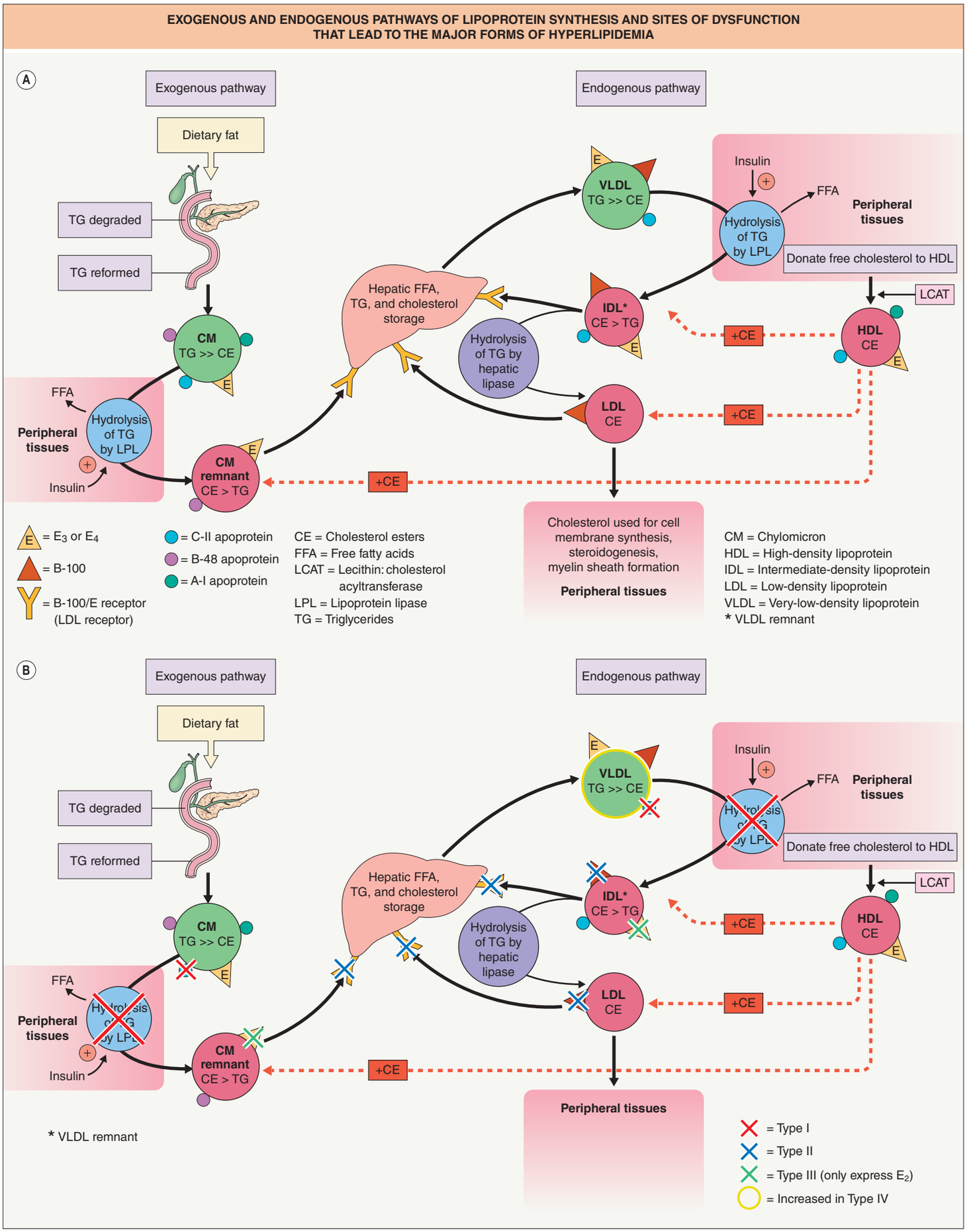

Fig. 92.1 Exogenous and endogenous pathways of lipoprotein synthesis (A) and sites of dysfunction that lead to the major forms of hyperlipidemia (B). Lipoprotein lipase (LPL) is activated by the C-II apoprotein.

Downloaded for Anonymous User (n/a) at Egyptian Knowledge Bank from ClinicalKey.com by Elsevier on March 10, 2024. For personal use only. No other uses without permission. Copyright ©2024. Elsevier Inc. All rights reserved.

The *endogenous* pathway begins with the hepatic formation of VLDL particles. The central core of the VLDL consists primarily of triglycerides, which are derived from circulating free fatty acids and hepatic triglyceride stores. Important apoproteins found on the outer shell include B-100, E, and C-II. In a fashion similar to the chylomicron, lipoprotein lipase mediates hydrolysis of the VLDL molecule, removing the majority of its triglyceride content, and its cholesterol esters are acquired from HDL molecules. Lipoprotein lipase activation requires the presence of apo C-II on the VLDL outer shell. After removal of the majority of the triglyceride content, the VLDL "remnant", also known as an intermediate-density lipoprotein (IDL), can then be taken up by the liver via apo B-100/E receptors and degraded. IDLs that escape uptake by the hepatocyte are stripped of their remaining core triglycerides by extracellular hepatic lipases and enter the circulation as LDLs.

The LDL contains predominantly cholesterol ester in its central core and expresses B-100 on its surface. LDL delivers cholesterol ester to peripheral tissues, where it can be converted to free cholesterol. Cholesterol has several important functions within the body, including being an essential component of cell membrane bilayers. It is also important in the production of the myelin sheath of nerves, adrenal and gonadal steroidogenesis, and the production of bile acids. Hepatocytes play the major role in the catabolism of LDLs. Their uptake is mediated through the high-affinity apo B-100/E receptor found on the cell surface of the hepatocytes. Of note, the LDL receptors on hepatocytes are catabolized by PCSK9 (proprotein convertase subtilisin/kexin type 9). Free cholesterol in excess of metabolic needs is re-esterified for storage.

HDLs serve several important functions in cholesterol metabolism (see Fig. 92.1A). One of the primary functions of HDLs is the removal of cholesterol from the peripheral tissues. During this process, free cholesterol and phospholipids are transferred from the cell membranes of peripheral cells to the HDL molecules. The free cholesterol is then esterified by the enzyme *l*ecithin:*c*holesterol *a*cyl*t*ransferase, or LCAT. This enzyme requires the presence of the HDL apoprotein A-I. HDL molecules then transfer the cholesterol esters to other lipoproteins such as LDLs and remnants of chylomicrons or VLDLs for transportation back to the liver.

The liver plays the central role in the overall cholesterol economy. Hepatic intracellular cholesterol levels have a direct impact on the activity of HMG-CoA reductase, the rate-limiting enzyme of cholesterol synthesis, and on the expression of the high-affinity apo B-100/E receptor. When intracellular cholesterol levels are low, HMG-CoA reductase becomes activated and high-affinity apo B-100/E receptor expression increases. The increase in high-affinity receptors leads to increased uptake of cholesterol-containing lipoproteins such as chylomicron remnants, IDLs, and LDLs. This is followed by the lowering of plasma cholesterol levels. As discussed later, this mechanism will be the basis for many of the pharmacologic interventions aimed at lowering cholesterol levels.

CLINICAL FEATURES

Due to the complexity of cholesterol homeostasis, there are several possible ways in which hyperlipidemia may occur, from inherited disorders to metabolic diseases such as diabetes mellitus. Genetic mutations can affect important enzymes, receptors, or receptor ligands, with such defects leading to the overproduction of lipoproteins or the inhibition of their clearance (Fig. 92.1B). Each possible defect would lead to a different abnormal lipid profile.

In 1965, Lees and Frederickson[3] published a system for classifying various disorders of lipid metabolism based upon the electrophoretic migration of the serum lipoproteins present. This system for phenotyping hyperlipoproteinemias is used today in a modified form (Table 92.2). In the next section, descriptions of underlying lipid disorders will reference not only the Frederickson classification system, but also the specific molecular defects when possible.

With the exception of the homozygous form of familial hypercholesterolemia (type II) and rare disorders such as sitosterolemia and biliary atresia, most cutaneous xanthomas do not appear until adulthood. Once the diagnosis is established, treatment of associated disorders (e.g. metabolic syndrome [see Table 53.5]) should reduce the incidence of potential systemic sequelae such as myocardial infarctions, cerebrovascular accidents, and hepatic steatosis[4].

Eruptive Xanthomas

Eruptive xanthomas appear as erythematous to yellow papules, approximately 1 to 5 mm in diameter (Fig. 92.2 & 92.3). They are usually distributed on the extensor surfaces of the extremities, buttocks, and hands. Early in their development, lesions may have an inflammatory halo (likely due to their triglyceride component), which may be accompanied by tenderness and pruritus. The Koebner phenomenon has been reported to occur with eruptive xanthomas[5].

Eruptive xanthomas can be seen in the setting of primary or secondary *hypertriglyceridemia*. Triglyceride levels in patients with eruptive xanthomas often exceed 3000 to 4000 mg/dl. In the Frederickson classification of hyperlipidemias, hypertriglyceridemia can be seen in type I (elevated chylomicrons), type IV (elevated VLDLs), and type V (elevated chylomicrons and VLDLs).

One reason for elevated triglyceride levels is failure to remove such lipids from the circulation (Fig. 92.4). Deficient activity of lipoprotein lipase will lead to accumulation of triglyceride-rich chylomicrons and VLDLs (see Fig. 92.1B). This can be related to either abnormalities in the enzyme itself, as in *lipoprotein lipase deficiency* (*chylomicronemia syndrome*), or in other controlling factors such as *dysfunctional apoprotein C-II* or *impaired insulin activity*[6,7]. In addition to *deficiency of GPIHBP1*, autoantibodies against GPIHBP1 can also lead to hypertriglyceridemia[8].

Another reason for increased triglyceride levels is hepatic overproduction of triglyceride-rich lipoproteins via the endogenous pathway. In *endogenous familial hypertriglyceridemia*, a genetic defect exists that causes the liver to respond abnormally to dietary carbohydrates and insulin, with overproduction of hepatic VLDLs. The result is a Frederickson type IV pattern of hypertriglyceridemia. Secondary acquired defects in lipoprotein lipase activity, such as those due to diabetes mellitus, are not uncommon in these patients. With this second insult, the lipoprotein lipase system can become saturated and, as a result, no longer handles dietary lipids, leading to chylomicron elevations as well. This pattern is classified as a Frederickson type V phenotype.

Environmental factors and underlying diseases commonly exacerbate genetic defects of triglyceride metabolism, leading to worsening of the hypertriglyceridemia with eruptive xanthoma formation (see Fig. 92.4). Such factors include obesity, high caloric intake, diabetes mellitus, alcohol abuse, oral estrogen replacement, and systemic medications that can lead to hypertriglyceridemia (e.g. retinoids, protease inhibitors, olanzapine). The resultant pattern usually leads to a Frederickson type IV phenotype. Oral retinoid therapy, especially bexarotene, can elevate triglyceride levels through an elevation in hepatic VLDL secretion. With isotretinoin, this elevation seems to be more prevalent in genetically predisposed individuals and may signal an increased risk for future metabolic syndrome[9]. Two of the five criteria for the clinical diagnosis of metabolic syndrome are lipid abnormalities – elevated triglycerides and reduced HDLs (see Table 53.5).

The treatment of eruptive xanthomas involves the identification and treatment of the underlying causes of the hypertriglyceridemia (see Fig. 92.4). Failure to recognize and treat the patient with hypertriglyceridemia could lead to complications such as acute pancreatitis. Pharmacologic and dietary lowering of the circulating triglycerides to reasonable levels will result in the prompt resolution of the eruptive lesions.

Tuberous/Tuberoeruptive Xanthomas

Tuberoeruptive and tuberous xanthomas are clinically and pathologically related and often described as being on a continuum. Tuberoeruptive xanthomas present as pink–yellow papules or nodules on extensor surfaces, especially the elbows and knees (Fig. 92.5). Tuberous lesions are noted to be larger than tuberoeruptive lesions and may exceed 3 cm in diameter (Fig. 92.6). Together, these lesions can be seen in hypercholesterolemic states such as *dysbetalipoproteinemia* (Frederickson type III) and *familial hypercholesterolemia* (Frederickson type II; see below). In contrast to eruptive xanthomas, tuberous xanthomas are usually slow to regress following institution of appropriate therapy.

Dysbetalipoproteinemia, or broad beta disease, is a genetic disorder of lipid metabolism that is usually inherited in an autosomal recessive fashion. It is caused by the presence of an isoform of apo E, primarily

Downloaded for Anonymous User (n/a) at Egyptian Knowledge Bank from ClinicalKey.com by Elsevier on March 10, 2024. For personal use only. No other uses without permission. Copyright ©2024. Elsevier Inc. All rights reserved.

IMPORTANT HYPERLIPOPROTEINEMIAS				
Type	**Pathogenesis**	**Laboratory findings**	**Clinical findings**	
			Skin (types of xanthoma)	**Systemic**
Type I (familial LPL deficiency, familial hyperchylomicronemia)	(a) Deficient or abnormal LPL (AR) (b) Apo C-II deficiency (AR) (c) Deficient glycosyl-phosphatidylinositol-anchored HDL-binding protein 1 [GPIHBP1] (AR) (d) Apo A-V* deficiency (AR)	Slow chylomicron clearance Reduced LDL and HDL levels **Hypertriglyceridemia**	Eruptive	No increased risk of coronary artery disease Recurrent pancreatitis
Type II (familial hypercholesterolemia)	(a) LDL receptor defect (AD)† (b) Reduced affinity of LDL for LDL receptor due to dysfunction of apo B-100 (ligand) (AD) (c) Accelerated degradation of LDL receptor due to missense *PCSK9* mutations (AD‡) (d) Defective LDL receptor adaptor protein 1 (required for receptor internalization) (AR)	Reduced LDL clearance **Hypercholesterolemia**	Tendinous, tuberoeruptive, tuberous, plane (xanthelasma, intertriginous areas, interdigital web spaces¶)	Atherosclerosis of peripheral and coronary arteries
Type III (familial dysbetalipoproteinemia, remnant removal disease, broad beta disease, apo E deficiency)	Hepatic remnant clearance impaired due to apo E abnormality; vast majority of patients only express the apo E_2 isoform that interacts poorly with the apo E receptor (AR >> AD)	Elevated levels of chylomicron remnants and IDLs **Hypercholesterolemia** **Hypertriglyceridemia**	Tuberoeruptive, tuberous, plane (palmar creases) – most characteristic Tendinous	Atherosclerosis of peripheral and coronary arteries
Type IV (endogenous familial hypertriglyceridemia)	Elevated production of VLDL associated with glucose intolerance and hyperinsulinemia; may be associated with heterozygous variants, e.g. in apo A-V*, LPL, or the glucokinase regulator protein	Increased VLDLs **Hypertriglyceridemia**	Eruptive	Frequently associated with type 2 non-insulin-dependent diabetes mellitus, obesity, alcoholism (see Fig. 92.4)
Type V	Elevated chylomicrons and VLDLs; may be associated with heterozygous variants, e.g. in apo A-V*, LPL, or the glucokinase regulator protein	Decreased LDLs and HDLs **Hypertriglyceridemia**	Eruptive	Diabetes mellitus

*Apolipoprotein A-V (apo A-V) interacts with the LDL receptor and activates lipoprotein lipase, inhibiting VLDL-TG production and modulating HDL maturation and cholesterol metabolism.
†In patients with the *LDLR* IVS14+1G-A mutation, the phenotype can be altered by SNPs in the genes that encode apo A-II, cytoplasmic epoxide hydrolase 2, or growth hormone receptor.
‡Gain-of-function mutations cause autosomal dominant hypercholesterolemia[28], whereas loss-of-function mutations (most prevalent in African-Americans) result in low LDL levels[29].
¶Said to be pathognomonic for homozygous state.

Table 92.2 Important hyperlipoproteinemias. Autoantibodies against GPIHBP1 can also lead to hypertriglyceridemia. In **bold** are the major lipid abnormalities found on routine screening. AD, autosomal dominant; Apo, apolipoprotein; AR, autosomal recessive; HDL, high-density lipoprotein; IDL, intermediate-density lipoprotein; LDL, low-density lipoprotein; LPL, lipoprotein lipase; PCSK9, proprotein convertase subtilisin/kexin type 9; VLDL, very-low-density lipoprotein.

Fig. 92.2 Eruptive xanthomas due to hypertriglyceridemia. In this patient the lesions favored the extensor surface of the lower extremities, in particular the knees.

apo E_2, that is a poor ligand for the high-affinity apo B-100/E receptor (see Fig. 92.1B). This results in the poor hepatic uptake of chylomicron and VLDL remnants. As a result, the serum levels of both triglycerides and cholesterol are elevated. The cutaneous lesions that are most characteristic of this disease are tuberous or tuberoeruptive xanthomas (present in 80% of patients) and plane xanthomas of the palmar creases (*xanthoma striatum palmare*), which are present in two-thirds of patients (see below)[10].

Tendinous Xanthomas

Tendinous xanthomas are firm, smooth, nodular lipid deposits that can affect the Achilles tendons (Fig. 92.7) or the extensor tendons of the hands (Fig. 92.8), knees, or elbows. The overlying skin is normal in appearance. Ultrasound can aid in the diagnosis of subtle lesions of the Achilles tendon by demonstrating hypoechoic nodules or an increase in the anteroposterior diameter of the tendon[11]. The presence of tendinous xanthomas is almost always a clue to an underlying disorder of lipid metabolism. Lipid disorders that have been associated with this type of xanthoma include familial hypercholesterolemia, dysbetalipoproteinemia, and hyperlipidemia secondary to hypothyroidism (Table 92.3).

Tendinous xanthomas are most frequently seen in the setting of *familial hypercholesterolemia*. This disorder results from a deficiency of normal LDL receptors on cell membranes, which leads to the poor hepatic clearance of circulating LDLs and, therefore, elevated LDL cholesterol levels (Frederickson type II). This condition is inherited in an autosomal dominant fashion with a high degree of penetrance. Homozygotes can have LDL cholesterol levels of 800 to 1000 mg/dl with widespread atherosclerosis and the appearance of xanthomas during the first decade of life. Heterozygosity for the disorder is more common and is estimated to occur in 1 in 500 individuals in the US. The types of xanthomas seen in this disorder include tendinous, tuberous, tuberoeruptive, and plane (including xanthelasma). Because of its relatively

Downloaded for Anonymous User (n/a) at Egyptian Knowledge Bank from ClinicalKey.com by Elsevier on March 10, 2024. For personal use only. No other uses without permission. Copyright ©2024. Elsevier Inc. All rights reserved.

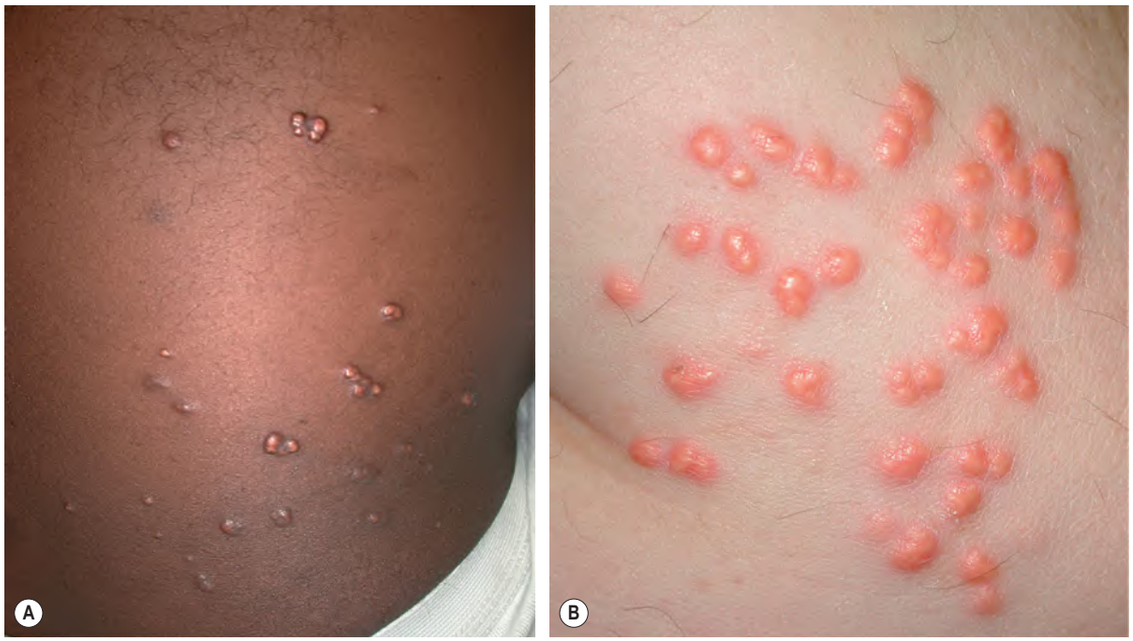

Fig. 92.3 Eruptive xanthomas. A, B The yellowish hue is influenced by the degree of pigmentation of the skin. Note the clustering of some of the lesions.

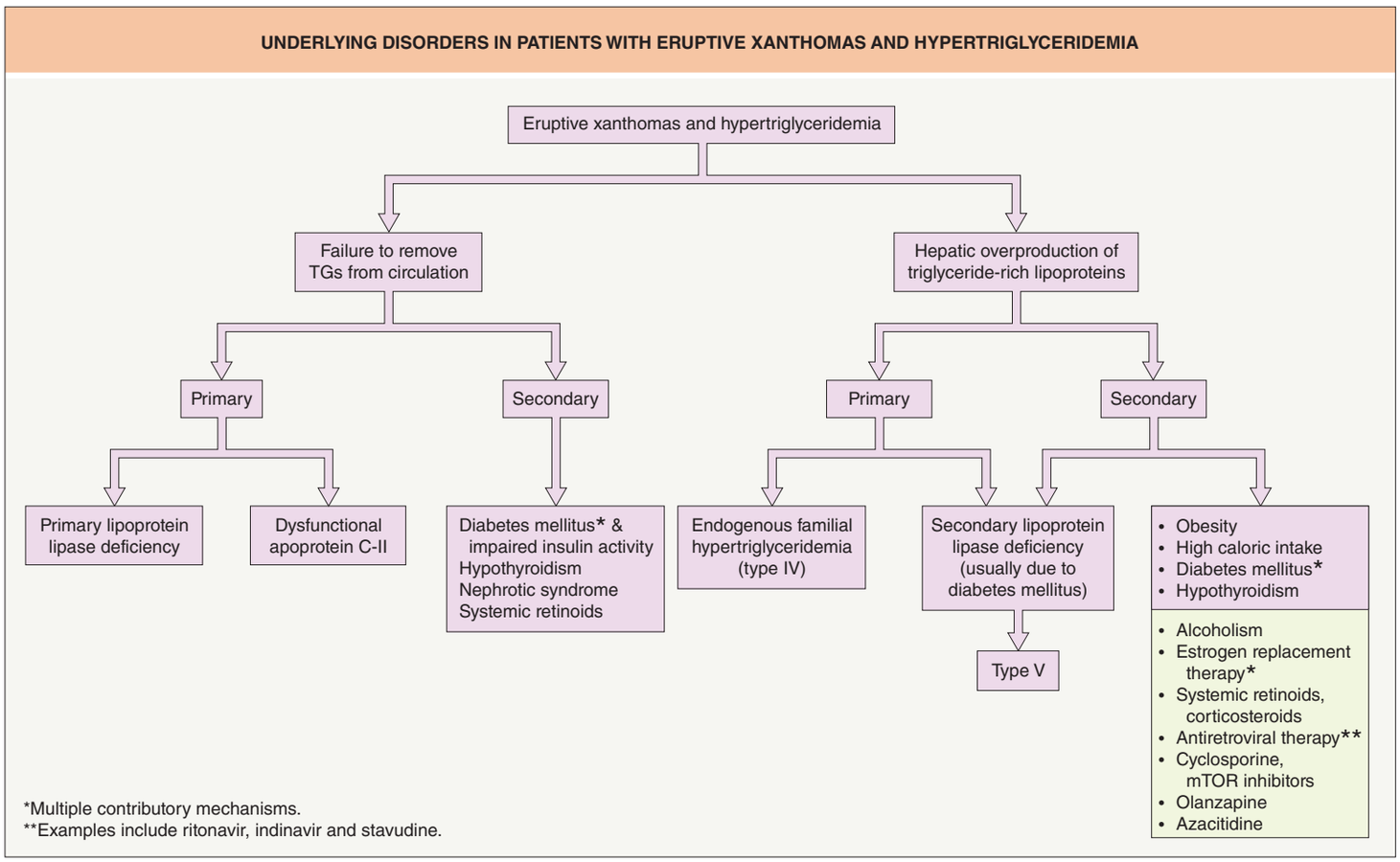

Fig. 92.4 Underlying disorders in patients with eruptive xanthomas and hypertriglyceridemia. mTOR, mammalian target of rapamycin; TGs, triglycerides.

common occurrence, patients with tendinous xanthomas are more likely to have the heterozygous form of the disease than the rare homozygous state. Plane xanthomas of the intertriginous web spaces of the fingers are thought to be pathognomonic for the homozygous condition (see Fig. 92.8)[12].

There is a closely related disorder, known as *familial defective apolipoprotein B-100*. In this dominantly inherited genetic disorder, the LDL receptor is normal. However, there is decreased affinity of LDL for the LDL receptor because the mutation affects its ligand, apo B-100 (see Fig. 92.1B). Patients may present with identical clinical findings as in familial hypercholesterolemia, although usually not as severe[13]. From a therapeutic standpoint, distinguishing this disorder from dysfunction or accelerated degradation of the LDL receptor (see Table 92.2) will become more important in the future as treatments aimed at correcting LDL receptor function become commercially available (e.g. evinacumab)[13a].

Rarely, tendinous xanthomas can develop in the absence of a lipoprotein disorder. Two examples are *cerebrotendinous xanthomatosis* and *sitosterolemia*. In cerebrotendinous xanthomatosis, an enzymatic

Downloaded for Anonymous User (n/a) at Egyptian Knowledge Bank from ClinicalKey.com by Elsevier on March 10, 2024. For personal use only. No other uses without permission. Copyright ©2024. Elsevier Inc. All rights reserved.

Fig. 92.5 Tuberoeruptive xanthomas on the elbow of a child with homozygous familial hypercholesterolemia. Note the yellowish hue. *Courtesy Julie V. Schaffer, MD.*

Fig. 92.6 Nodular tuberous xanthoma of the elbow. *Courtesy Lorenzo Cerroni, MD.*

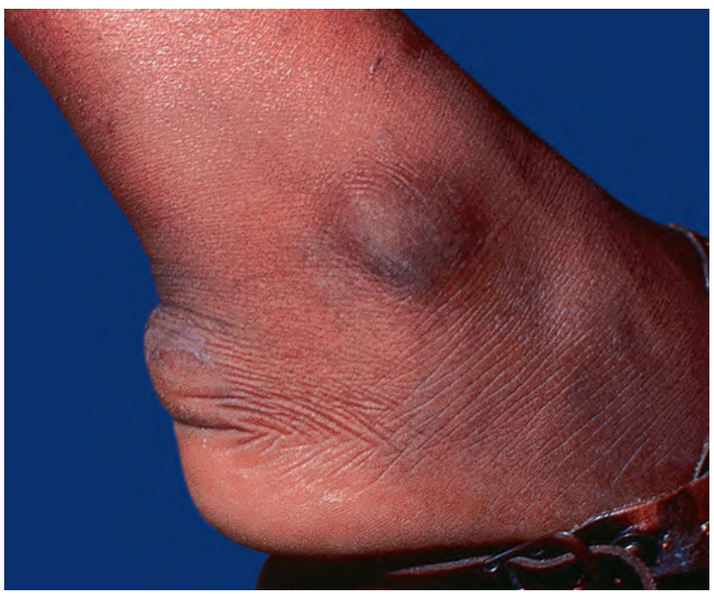

Fig. 92.7 Tendinous xanthoma. Linear swelling of the Achilles area, representing a tendinous xanthoma in a patient with dysbetalipoproteinemia.

Fig. 92.8 Tendinous xanthomas of the fingers in a patient with homozygous familial hypercholesterolemia. Note intertriginous plane xanthomas of the web spaces.

SECONDARY HYPERLIPIDEMIA – SELECTED UNDERLYING DISORDERS
• Diabetes mellitus*
• Cholestasis
• Primary biliary cholangitis (often plane xanthomas, including palmar)
• Alagille syndrome (elbows/knees, flexures, fingers, palms, helices)*,†
• Biliary atresia*
• Hypothyroidism*
• Nephrotic syndrome*
• Type I glycogen storage disease (von Gierke)*
• Lipodystrophy syndromes (see Fig. 101.1)
*Xanthomas can develop during childhood.
†Autosomal dominant disorder due to mutations in *JAG1*, which encodes the Notch signaling pathway ligand Jagged-1, or (in ~5% of patients) *NOTCH2*. Patients have cholestasis due to a paucity of intrahepatic bile ducts, elevated LDL (cholesterol) levels, cardiac defects, peculiar facies, growth retardation, and posterior embryotoxon; xanthomas within body folds may become very firm[30–32].

Table 92.3 Secondary hyperlipidemia – selected underlying disorders. In addition to a fasting lipid panel, screening blood tests include fasting glucose, liver function tests, TSH, and albumin. Other rare causes include pregnancy, multiple myeloma, and autoimmune connective tissue diseases (e.g. systemic lupus erythematosus, juvenile dermatomyositis)

defect exists in the bile acid synthetic pathway, leading to the abnormal accumulation of an intermediate known as cholestanol. This intermediate is deposited in most tissues, including the brain, and can also form tendinous xanthomas[14]. In sitosterolemia-1 and -2, an abnormal accumulation of plant sterols occurs, leading to tendinous and tuberous xanthoma formation.

Plane Xanthomas and Xanthelasma

Plane xanthomas appear as yellow to orange, non-inflammatory macules, papules, patches, and plaques. They can be circumscribed or diffuse. While anatomic locations vary, the site often serves as a clue to the particular underlying disease state. For example, intertriginous plane xanthomas may occur in body folds including the antecubital fossae (Fig. 92.9 & 92.10) or the web spaces of the fingers (see Fig. 92.8), where they are almost pathognomonic for homozygous familial hypercholesterolemia[12]. Plane xanthomas of the palmar creases, or *xanthoma striatum palmare*, are nearly diagnostic for dysbetalipoproteinemia, especially when accompanied by tuberous xanthomas[15].

Xanthelasma, or *xanthelasma palpebrarum*, are commonly observed plane xanthomas of the eyelids (Fig. 92.11). Although the presence of xanthelasma warrants investigation for hyperlipidemia, the latter is present in only about one-half of the patients with these lesions. Younger patients or those with a strong family history of hyperlipidemia are more likely to have an underlying lipid disorder and should be appropriately screened.

Plane xanthomas of cholestasis may occur as a complication of diseases such as biliary atresia or primary biliary cholangitis (previously primary biliary cirrhosis). In these conditions, unesterified cholesterol

Downloaded for Anonymous User (n/a) at Egyptian Knowledge Bank from ClinicalKey.com by Elsevier on March 10, 2024. For personal use only. No other uses without permission. Copyright ©2024. Elsevier Inc. All rights reserved.

begins to accumulate in the blood, leading to plane xanthoma formation. The lesions often begin as localized plaques on the hands and feet, but can become generalized.

Plane xanthomas can also occur in a normolipemic patient, where they may signal the presence of an underlying monoclonal gammopathy (Fig. 92.12), usually due to a plasma cell dyscrasia, but occasionally secondary to a lymphoproliferative disorder such as B cell lymphoma or Castleman disease (see Ch. 119). This type of xanthoma can also be seen in patients with chronic myelomonocytic leukemia. In gammopathy-associated plane xanthomas, monoclonal IgG is thought to bind to circulating LDL, rendering the antibody–LDL complex more susceptible to phagocytosis by macrophages[16]. Favored locations include the neck, upper trunk, flexural folds, and periorbital region. In the setting of a monoclonal gammopathy, the coexistence of plane xanthomas and necrobiotic xanthogranuloma has been observed, suggesting a disease overlap[17]. Of note, there is an entity known as hyperlipidemic myeloma in which xanthomas appear on the elbows and knees as well as within the palmar creases.

Verruciform Xanthomas

Verruciform xanthomas are asymptomatic, planar or verrucous, solitary plaques that are usually 1 to 2 cm in diameter. They occur primarily in the mouth (Fig. 92.13), but sometimes in periorificial, anogenital (including the scrotum), and acral sites. The latter are sometimes referred to as Vegas (verruciform genital-associated) and Vacas (verruciform acral-associated) xanthomas. These lesions may persist for years and there is usually no associated hyperlipidemia.

Single or multiple lesions are also seen in the setting of lymphedema, epidermolysis bullosa, pemphigus, discoid lupus erythematosus, lichen planus, and GVHD as well as within dermatofibromas and cutaneous lesions of the X-linked dominant disorder CHILD (*c*ongenital *h*emidysplasia with *i*chthyosiform erythroderma and *l*imb *d*efects) syndrome. The latter is due to mutations in *NSDHL*, which encodes 3β-hydroxysteroid dehydrogenase, an enzyme involved in cholesterol biosynthesis (see Ch. 57). In a molecular study of sporadic verruciform xanthomas, two of nine lesions were found to have a missense somatic mutation in exon 6 of *NSDHL* (only exons 4 and 6 were examined) which differed from the mutations seen in CHILD syndrome[18].

One proposal is that enzymatic dysfunction leads to an excess formation and accumulation of lipid storage droplets, followed by formation of lipid-laden dermal macrophages. Another hypothesis suggests that the foam cells result from damage to the epithelium

Fig. 92.11 Xanthelasma palpebrarum with typical yellowish hue.

Fig. 92.9 Plane xanthomas of the antecubital fossae. This young patient had dysbetalipoproteinemia.

Fig. 92.12 Normolipemic plane xanthoma. The large thin plaques have a yellow–orange color. The patient was found to have a monoclonal gammopathy. *Courtesy Whitney High, MD, JD.*

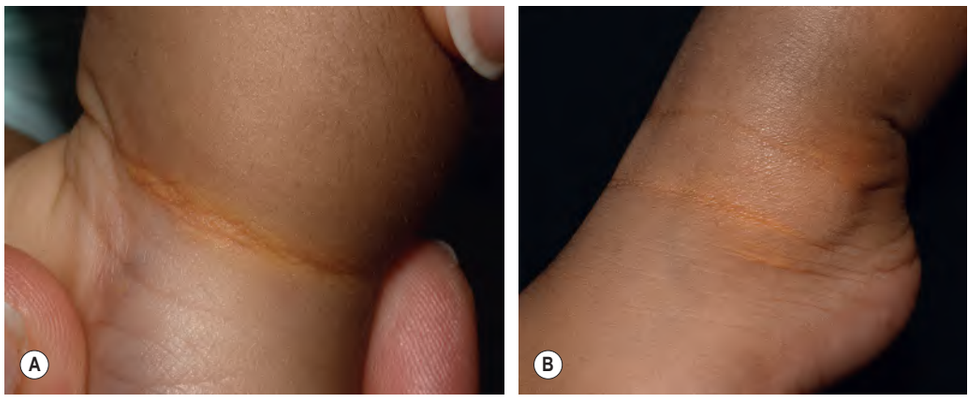

Fig. 92.10 Intertriginous plane xanthomas. Yellow–orange color in the skin folds of the wrist (**A**) and ankle (**B**) in an infant with homozygous familial hypercholesterolemia. *Courtesy Julie V. Schaffer, MD.*

Downloaded for Anonymous User (n/a) at Egyptian Knowledge Bank from ClinicalKey.com by Elsevier on March 10, 2024. For personal use only. No other uses without permission. Copyright ©2024. Elsevier Inc. All rights reserved.

Fig. 92.13 Verruciform xanthoma of the oral mucosa. *Courtesy Kishore Shetty, DDS.*

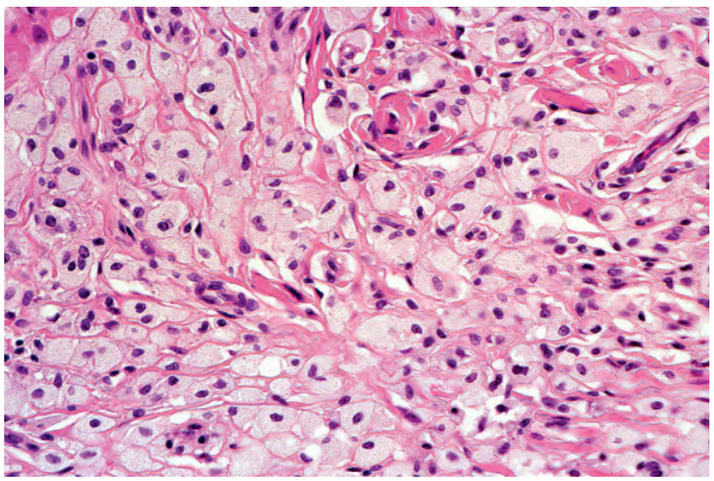

Fig. 92.14 Histology of a tuberous xanthoma. Foamy macrophages fill the dermis. *Courtesy Lorenzo Cerroni, MD.*

(e.g. from lichenoid dermatoses) and subsequent engulfing of lipids by macrophages within the dermal papillae, analogous to the amyloid deposits within the dermal papillae in lichen amyloidosis. The few foam cells beneath the epithelium may be subtle and easy to miss, in which case verruciform xanthomas may be confused histologically with warts and other papillomatous disorders. Surgery is generally curative.

PATHOLOGY

The characteristic histologic finding in xanthomas is the foam cell. Foam cells consist of macrophages that contain imbibed lipid within their cytoplasm (Fig. 92.14). All xanthomas contain dermal infiltrates of lipid, but they may vary in the degree of lipid content, the inflammatory infiltrate, the amount and location of the infiltrate, and the presence of extracellular lipid. The histologic appearance of xanthomas is somewhat altered by routine processing, as formalin fixation can remove deposits of lipid and leave artifactual clefting. Immunohistochemical staining for adipophilin can be performed to detect lipid accumulation[19]. Adipophilin, also known as adipose differentiation-related protein, is a lipid droplet-associated protein.

Eruptive xanthomas contain lipid deposits in the reticular dermis. Of note, early in lesion development, foam cells are relatively small in number and size. The initial inflammatory infiltrate is mixed, containing both neutrophils and lymphocytes. As an increase in lipidization occurs, the appearance of the lesion becomes more typical of a xanthoma, but foam cells remain fewer in number compared with other types of xanthomas. Extracellular lipids are present in the dermis, which are seen as artifactual clefts filled with a wispy faint blue–gray material.

Tuberous xanthomas demonstrate large aggregates of foam cells in the dermis, often accompanied by fibrosis, but without a large number of inflammatory cells. *Tendinous xanthomas* have a similar histology, with foam cells that are even larger in size. Cholesterol esters are present in these lesions and can be seen with polarized microscopy.

DIFFERENTIAL DIAGNOSIS OF XANTHOMAS
• Eruptive xanthomas
• Non-Langerhans cell histiocytoses
• Xanthoma disseminatum
• Papular xanthoma
• Generalized eruptive histiocytoma
• Indeterminate cell histiocytosis
• Rosai–Dorfman disease
• Juvenile xanthogranuloma (micronodular form)
• Xanthomatous lesions of Langerhans cell histiocytosis
• Disseminated granuloma annulare
• Tuberous xanthomas
• Erythema elevatum diutinum
• Multicentric reticulohistiocytosis
• Juxta-articular fibroid nodules of *Borrelia* infection
• Tendinous xanthomas
• Giant cell tumor of the tendon sheath
• Rheumatoid nodule
• Subcutaneous granuloma annulare
• Erythema elevatum diutinum
• Xanthelasma
• Syringomas
• Necrobiotic xanthogranuloma
• *A*dult-onset *a*sthma and *p*eriocular *x*anthogranuloma (AAPOX)
• Sebaceous hyperplasia
• Palpebral sarcoidosis

Table 92.4 Differential diagnosis of xanthomas. Occasionally, xanthomatous cells may be observed histologically in some cutaneous tumors (e.g. dermatofibroma), unrelated to xanthomas.

Plane xanthomas such as xanthelasma can have a unique histologic appearance. The foam cells in this type of xanthoma are more superficial than in other types of xanthomas. Small aggregates of foam cells are often present in the superficial dermis. The lesions are non-inflammatory and have minimal fibrosis. With xanthelasma, there are often clues as to the location of the lesion, such as a thin epidermis, fine vellus hair follicles, and striated muscle fibers that are characteristic of the eyelid. In *verruciform xanthomas*, there is usually hyperkeratosis, acanthosis and papillomatosis, with foamy macrophages limited to the submucosa or dermal papillae.

A distinctive *papular neutrophilic xanthoma*, in which dermal foam cells are intermingled with neutrophils and prominent nuclear dust, has been described in HIV-infected patients with an IgA gammopathy. *Xanthomatized neutrophilic dermatosis* in the setting of myelodysplastic syndrome may represent a similar condition[20]. Lastly, dermal xanthomatous cells observed in biopsies of cutaneous GVHD may be indicative of hepatic GVHD[21].

DIFFERENTIAL DIAGNOSIS

A selection of the diseases included in the differential diagnosis of xanthomas is listed in Table 92.4.

TREATMENT

The treatment of xanthomas associated with hyperlipidemia requires the identification of the underlying lipoprotein disorder and other possible exacerbating factors. In addition to dietary measures, there are several medications available for lowering lipid levels in patients with primary and secondary hyperlipidemia. Table 92.5 outlines their mechanisms of action, clinical effects, and side effects. Correction of the underlying lipid disorder leads to the eventual resolution of the xanthomas in many patients. Xanthomas that have grown slowly over years, such as tendinous and tuberous xanthomas, are often slow to regress, whereas eruptive xanthomas may disappear within weeks of aggressive therapy.

Dietary measures are an important component of lipid-lowering therapy, in addition to oral medications (see Table 92.5). Decreasing total caloric intake and the achievement of ideal body weight alone can make a significant impact on lipid levels in some patients. Dietary fat restriction to <30% of total caloric intake should be attempted. Mono-unsaturated fats such as olive oil should comprise the majority of the fat intake. Alcohol avoidance is essential, especially in patients with hypertriglyceridemia.

Downloaded for Anonymous User (n/a) at Egyptian Knowledge Bank from ClinicalKey.com by Elsevier on March 10, 2024. For personal use only. No other uses without permission. Copyright ©2024. Elsevier Inc. All rights reserved.

LIPID-LOWERING MEDICATIONS				
Class of drug	**Mechanism of action**	**Clinical effects**	**Side effects/ interactions**	**Comments**
HMG-CoA reductase inhibitors (“statins”)	• Competitive inhibition of the rate-limiting enzyme of hepatic cholesterol synthesis, with depletion of hepatocellular stores of cholesterol • Upregulation of hepatic LDL receptors (bind LDL & IDL; see Fig. 92.1) • Decreased endogenous VLDL production	• 25%–45% decrease in LDL levels • 25% decrease in VLDL levels • 10% increase in HDL levels	• Elevations in hepatic transaminases • Myopathy (risk may be increased with coadministration of other medications, e.g. cyclosporine, nicotinic acid, fibrates) • Drug-induced dermatomyositis • Interstitial granulomatous drug reaction • May increase warfarin levels	• Useful for many lipid disorders, including *heterozygous* familial hypercholesterolemia, hypercholesterolemia due to diabetes • Not effective in *homozygous* familial hypercholesterolemia (LDL receptor function is lacking)
Bile acid-binding resins (e.g. cholestyramine, colestipol, colesevelam)	• Bind to bile acids in the small intestine, preventing their reabsorption in the terminal ileum • Because of enhanced bile acid secretion, the liver must increase its synthesis of bile acids from cholesterol • Decrease in hepatic cholesterol stores leads to upregulation of hepatic LDL receptors (also increased HMG-CoA reductase activity)	• 10%–35% decrease in LDL levels (even with increase in hepatic cholesterol synthesis)	• Elevation of triglyceride levels, especially if dysbetalipoproteinemia or pre-existing hypertriglyceridemia • GI upset & gritty texture of resin • Affect absorption of medications such as digoxin, thyroxine, warfarin	• Lowering of LDL levels can be further enhanced by the addition of an HMG-CoA reductase inhibitor or nicotinic acid • Effective in *heterozygous* familial hypercholesterolemia • Not effective in *homozygous* familial hypercholesterolemia
Nicotinic acid (niacin)	• Lowers VLDL synthesis (and subsequently lowers LDL levels) • Enhances lipoprotein lipase activity (and subsequently lowers triglyceride levels)	• 20%–80% decrease in triglyceride levels (rapid) • 10%–15% decrease in LDL levels (slower) • 20–30 mg/dl increase in HDL	• Intense flushing and pruritus are common • Hepatitis • Worsening of glucose intolerance • Acanthosis nigricans, hyperpigmentation, xerosis • Increased risk of myopathy & rhabdomyolysis when coadministered with HMG-CoA reductase inhibitors	• Can be used in combination with HMG-CoA reductase inhibitors or bile acid-binding resins • Combination therapy for familial hypercholesterolemia • Treatment of severe hypertriglyceridemia refractory to fibric acid derivatives (to prevent pancreatitis)
Fibric acid derivatives (e.g. gemfibrozil, fenofibrate, clofibrate)	• Activation of lipoprotein lipase in peripheral tissues (e.g. muscle) • Decreases VLDL synthesis by suppression of the endogenous lipid pathway	• Dramatic improvement in lipid levels, with resolution of tuberous & palmar xanthomas (patients with dysbetalipoproteinemia) • Lowers triglyceride levels; prevents pancreatitis & eruptive xanthoma formation (patients with severe hypertriglyceridemia & chylomicronemia syndrome) • Increases levels of HDL	• Because of inhibition of the cytochrome P450 3A4 system, possibility of dermatologic drug–drug interactions (e.g. increased plasma levels of bexarotene or cyclosporine) • Increased risk of myopathy when administered with HMG-CoA reductase inhibitors	• Treatment of hypertriglyceridemia
Ezetimibe	• Inhibits intestinal absorption of dietary and biliary-excreted cholesterol	• ~15% reduction in LDL-C • Increases HDL by 3%	• Diarrhea • Rarely, elevated hepatic transaminases when coadministered with HMG-CoA reductase inhibitors	• Can be used in combination with HMG-CoA reductase inhibitors
PCSK9 inhibitors (e.g. alirocumab, evolocumab)	• Decreases LDL receptor degradation • Increases recirculation of the LDL receptor to the hepatocyte cell surface	• Lowers LDL cholesterol levels by 40%–60%	• Injection site reactions • Pruritus, urticaria, exanthem, cutaneous small vessel vasculitis • Transaminitis • Nasopharyngitis	• Effectively reduces LDL-C in patients with hypercholesterolemia except for those with *homozygous* familial hypercholesterolemia who lack the LDL receptor (receptor negative) • Administered subcutaneously or intravenously • No myopathy
Adenosine triphosphate-citrate lyase (ACL) inhibitors (e.g. bempedoic acid)	• ACL is an enzyme that functions upstream of HMG-CoA reductase • ACL catalyzes the formation of acetyl-CoA, a precursor of fatty acids and cholesterol • Inhibition of ACL yields similar results as HMG-CoA reductase inhibitors • Inhibits cholesterol synthesis	• 15%–25% reduction in LDL-C levels	• Upper respiratory tract infections, bronchitis • Muscle spasms • Hyperuricemia • Back, abdominal, or extremity pain • Anemia • Concomitant use with HMG-CoA reductase inhibitors may increase risk of statin-induced myopathy	• May be associated with reduced risk of cardiovascular events and diabetes • May be alternative for patients intolerant of statins or with statin-induced myopathy

Table 92.5 Lipid-lowering medications.

Continued

Downloaded for Anonymous User (n/a) at Egyptian Knowledge Bank from ClinicalKey.com by Elsevier on March 10, 2024. For personal use only. No other uses without permission. Copyright ©2024. Elsevier Inc. All rights reserved.

LIPID-LOWERING MEDICATIONS				
Class of drug	**Mechanism of action**	**Clinical effects**	**Side effects/ interactions**	**Comments**
Angiopoietin-like 3 (ANGPTL3) inhibitors (e.g. evinacumab)	• Binds to ANGPTL3 which is expressed primarily in the liver • ANGPTL3 inhibits lipoprotein lipase and endothelial lipase; inhibitors rescue enzyme activity • Promotes VLDL processing and clearance upstream of LDL formation	• Lowers levels of LDL-C (independent of the presence of LDL receptors), HDL-C, and triglycerides	• Injection site reaction • Cough, cold-like symptoms • Dizziness	• Treatment of *homozygous* familial hypercholesterolemia • Administered intravenously in combination with other lipid-lowering drugs (e.g. "statin", PCSK9 inhibitor)
Small interfering RNAs (siRNAs)	• Inclisiran inhibits translation of PCSK9	• 50% reduction in LDL-C levels	• Injection site reactions • Arthralgia, bronchitis	• Effective in *heterozygous* familial hypercholesterolemia • Administered subcutaneously in combination with a "statin"
Lipoprotein apheresis	• Physical removal of circulating lipoprotein(a)	• Lowers levels of circulating lipoprotein(a) by >60% per treatment and by ~30% long-term	• Venipuncture and anticoagulation required for procedure • Hypotension during procedure	• Treatment of *homozygous* familial hypercholesterolemia • Could be considered in patients with very high risk hyperlipidemia/cardiovascular disease • Lifelong therapy

Table 92.5 Lipid-lowering medications. Metreleptin is indicated for patients with congenital or acquired generalized lipodystrophy to address their leptin deficiency and hypertriglyceridemia. Additional treatments, e.g. apolipoprotein C-II mimetic peptides, are under investigation. C, cholesterol; GI, gastrointestinal; HDL, high-density lipoprotein; HMG-CoA, 3-hydroxy-3-methylglutaryl-coenzyme A; IDL, intermediate-density lipoprotein; LDL, low-density lipoprotein; LDL-C, low-density lipoprotein-cholesterol; PCSK9, proprotein convertase subtilisin/kexin type 9; VLDL, very low-density lipoprotein. Based on references 4,33–44.

Xanthomas, particularly xanthelasma, can be treated surgically by excision or destructive methods. When xanthelasma excision is performed, it may be followed by suture or second intention healing[22]. Reported destructive methods for xanthelasma include laser surgery (e.g. CO_2, pulsed dye, erbium:YAG), chemical agents such as trichloroacetic acid, and cryosurgery[23–26]. Despite the initial success of the chosen method, the lesions often recur. Surgical excision has also been employed in the management of tendinous xanthomas. This can be technically difficult, however, as the lipid deposits may be intertwined with the involved tendon[27]. Application of topical lovastatin/cholesterol ointment has led to improvement of the cutaneous lesions in CHILD syndrome (see Ch. 57).

Acknowledgment

The author wishes to acknowledge the late Lee T. Nesbitt Jr, MD, for his valuable contribution to this chapter in the previous editions, and Erica Ann Grilletta, MD, and Caroline Savoie, MD, for their help in researching and editing this chapter.

Additional figures and table on Laboratory evaluation of suspected hyperlipidemia, available in our eBook (see inside front cover for access code).

REFERENCES

1. Parker F. Normocholesterolemic xanthomatosis. *Arch Dermatol*. 1986;122:1253–1257.
2. Cruz PD Jr, East C, Bergstresser PR. Dermal, subcutaneous, and tendon xanthomas: diagnostic markers for specific lipoprotein disorders. *J Am Acad Dermatol*. 1988;19:95–111.
3. Lees RS, Frederickson DS. The differentiation of exogenous and endogenous hyperlipemia by paper electrophoresis. *J Clin Invest*. 1965;44:1968–1977.
4. Fras Z. Increased cardiovascular risk associated with hyperlipoproteinemia (a) and the challenges of current and future therapeutic possibilities. *Anatol J Cardiol*. 2020;23:60–69.
5. Goldstein GD. The Koebner response with eruptive xanthomas. *J Am Acad Dermatol*. 1984;10:1064–1065.
6. Santamarina-Fojo S. The familial chylomicronemia syndrome. *Endocrinol Metab Clin North Am*. 1998;27:551–567.
7. Breckenridge WC, Alaupovic P, Cox DW, Little JA. Apolipoprotein and lipoprotein concentrations in familial apolipoprotein C-II deficiency. *Atherosclerosis*. 1982;44:223–235.
8. Beigneux AP, Miyashita K, Ploug M, et al. Autoantibodies against GPIHBP1 as a cause of hypertriglyceridemia. *N Engl J Med*. 2017;376:1647–1658.
9. Rodondi N, Darioli R, Ramelet AA, et al. High risk for hyperlipidemia and the metabolic syndrome after an episode of hypertriglyceridemia during 13-cis retinoic acid therapy for acne: a pharmacogenetic study. *Ann Intern Med*. 2002;136:582–589.
10. Parker F. Xanthomas and hyperlipidemias. *J Am Acad Dermatol*. 1985;13:1–30.
11. Bude RO, Adler RS, Bassett DR. Diagnosis of Achilles tendon xanthoma in patients with heterozygous familial hypercholesterolemia: MR vs sonography. *AJR Am J Roentgenol*. 1994;162:913–917.
12. Sethuraman G, Thappa DM, Karthikeyan K. Intertriginous xanthomas – a marker of homozygous familial hypercholesterolemia. *Indian Pediatr*. 2000;37:338.
13. Rauh G, Keller C, Kormann B, et al. Familial defective apolipoprotein B100: clinical characteristics of 54 cases. *Atherosclerosis*. 1992;92:233–241.
13a. Rikhi R, Shapiro MD. Newer and emerging LDL-C lowering agents and implications for ASCVD residual risk. *J Clin Med*. 2022;11:4611.
14. Bel S, Garcia-Patos V, Rodriguez L, et al. Cerebrotendinous xanthomatosis. *J Am Acad Dermatol*. 2001;45:292–295.
15. Alam M, Garzon MC, Salen G, Starc TJ. Tuberous xanthomas in sitosterolemia. *Pediatr Dermatol*. 2000;17:447–449.
16. Daoud MS, Lust JA, Kyle RA, Pittelkow MR. Monoclonal gammopathies and associated skin disorders. *J Am Acad Dermatol*. 1999;40:507–535.
17. Marcoval J, Moreno A, Bordas X, et al. Diffuse plane xanthoma: clinicopathologic study of 8 cases. *J Am Acad Dermatol*. 1998;39:439–442.
18. Mehra S, Li L, Fan CY, et al. A novel somatic mutation of the 3β-hydroxysteroid dehydrogenase gene in sporadic cutaneous verruciform xanthoma. *Arch Dermatol*. 2005;141:1263–1267.
19. Ostler DA, Prieto VG, Reed JA, et al. Adipophilin expression in sebaceous tumors and other cutaneous lesions with clear cell histology: an immunohistochemical study of 117 cases. *Mod Pathol*. 2010;23:567–573.
20. Ferris GJ, Fabbro S, Gru A, Kaffenberger J. Xanthomatized neutrophilic dermatosis in a patient with myelodysplastic syndrome. *Am J Dermatopathol*. 2017;39:384–387.
21. Gamé D, López L, Román C, Santos-Briz Á. Xanthomatous cells in cutaneous graft-versus-host disease biopsies: a clue for the diagnosis of hepatic graft-versus-host disease. *Am J Dermatopathol*. 2018;40:754–757.
22. Eedy DJ. Treatment of xanthelasma by excision with secondary intention healing. *Clin Exp Dermatol*. 1996;21:273–275.
23. Ullmann Y, Har-Shai Y, Peled IJ. The use of CO_2 laser for the treatment of xanthelasma palpebrarum. *Ann Plast Surg*. 1993;31:504–507.
24. Schonermark MP, Raulin C. Treatment of xanthelasma palpebrarum with the pulsed dye laser. *Lasers Surg Med*. 1996;19:336–339.
25. Mannino G, Papale A, De Bella F, et al. Use of erbium: YAG laser in the treatment of palpebral xanthelasmas. *Ophthalmic Surg Lasers*. 2001;32:129–133.
26. Hawk JL. Cryotherapy may be effective for eyelid xanthelasma. *Clin Exp Dermatol*. 2000;25:351.
27. Bozentka DJ, Katzman BM. Two cases of surgically treated hand tendon xanthomas. *Am J Orthop*. 2001;30:337–339.
28. Abifadel M, Varret M, Rabés J-P, et al. Mutations in *PCSK9* cause autosomal dominant hypercholesterolemia. *Nat Genet*. 2003;34:154–156.
29. Cohen J, Pertsemlidis A, Kotowski IK, et al. Low LDL cholesterol in individuals of African descent resulting from frequent nonsense mutations in *PCSK9*. *Nat Genet*. 2005;37:161–165.

Downloaded for Anonymous User (n/a) at Egyptian Knowledge Bank from ClinicalKey.com by Elsevier on March 10, 2024. For personal use only. No other uses without permission. Copyright ©2024. Elsevier Inc. All rights reserved.

30. Schwartz R, Rehder K, Parsons DJ, Morrell DS. Intense pruritus and failure to thrive in Alagille syndrome. *J Am Acad Dermatol*. 2008;58(2 Suppl.):S9–S11.
31. Alagille D, Odievre M, Gautier M, et al. Hepatic ductular hypoplasia associated with characteristic facies, vertebral malformations, retarded physical, mental and sexual development and cardiac murmur. *J Pediatr*. 1975;86:63–71.
32. Garcia MA, Ramonet M, Ciocca M, et al. Alagille syndrome: cutaneous manifestations in 38 children. *Pediatr Dermatol*. 2005;22:11–14.
33. Dourmishev AL, Dourmishev LA. Dermatomyositis and drugs. *Adv Exp Med Biol*. 1999;455:187–191.
34. Stals H, Vercammen C, Peeters C, Morren MA. Acanthosis nigricans caused by nicotinic acid: case report and review of the literature. *Dermatology*. 1994;189: 203–206.
35. Yamamoto A, Matsuzawa Y, Yokoyama S, et al. Effects of probucol on xanthomata regression in familial hypercholesterolemia. *Am J Cardiol*. 1986;57:29H–35H.
36. Fujita M, Shirai K. A comparative study of the therapeutic effect of probucol and pravastatin on xanthelasma. *J Dermatol*. 1996;23:598–602.
37. Kajinami K, Nishitsuji M, Takeda Y, et al. Long-term probucol treatment results in regression of xanthomas, but in progression of coronary atherosclerosis in a heterozygous patient with familial hypercholesterolemia. *Atherosclerosis*. 1996;120:181–187.
38. Kuo PT, Wilson AC, Kostis JB, et al. Treatment of type III hyperlipoproteinemia with gemfibrozil to retard progression of coronary artery disease. *Am Heart J*. 1988;116:85–90.
39. Dujovne CA, Ettinger MP, McNeer JF, et al. Efficacy and safety of a potent new selective cholesterol absorption inhibitor, ezetimibe, in patients with primary hypercholesterolemia. *Am J Cardiol*. 2002;90:1092–1097.
40. Knopp RH, Gitter H, Truitt T, et al. Effects of ezetimibe, a new cholesterol absorption inhibitor, on plasma lipids in patients with primary hypercholesterolemia. *Eur Heart J*. 2003;24:729–741.
41. Yang J. Bempedoic acid for the treatment of hypercholesterolemia. *Expert Rev Cardiovasc Ther*. 2020;18:373–380.
42. Pasta A, Cremonini AL, Pisciotta L, et al. PCSK9 inhibitors for treating hypercholesterolemia. *Expert Opin Pharmacother*. 2020;21:353–363.
43. Ray KK, Wright RS, Kallend D, et al. Two phase 3 trials of inclisiran in patients with elevated LDL cholesterol. *New Engl J Med*. 2020;382:1507–1519.
44. Barter PJ, Rye KA. New era of lipid-lowering drugs. *Pharmacol Rev*. 2016;68:458–475.

Downloaded for Anonymous User (n/a) at Egyptian Knowledge Bank from ClinicalKey.com by Elsevier on March 10, 2024. For personal use only. No other uses without permission. Copyright ©2024. Elsevier Inc. All rights reserved.

eFig. 92.1 Eruptive xanthomas. Note the central yellow color.

eFig. 92.2 Eruptive xanthomas. Note the yellowish hue and "mulberry" pattern in a patient with Frederickson type IV disease.

eFig. 92.3 Tuberoeruptive xanthomas of the elbow. Note the yellowish hue.

eFig. 92.4 Nodular tuberous xanthomas of the elbows. This form occurred in a young patient with familial hypercholesterolemia.

eFig. 92.5 Large, multilobulated, nodular tuberous xanthoma of the elbow. *Courtesy Jeffrey M. Cohen, MD.*

Downloaded for Anonymous User (n/a) at Egyptian Knowledge Bank from ClinicalKey.com by Elsevier on March 10, 2024. For personal use only. No other uses without permission. Copyright ©2024. Elsevier Inc. All rights reserved.

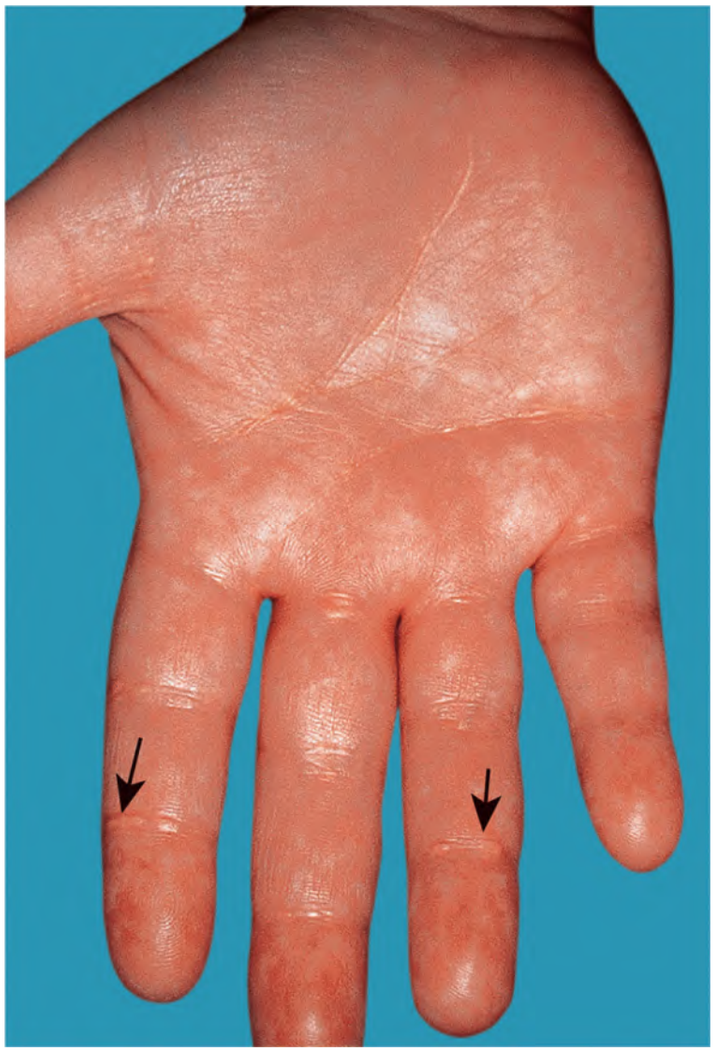

eFig. 92.6 Plane xanthomas of the palmar creases (arrows) in a patient with dysbetalipoproteinemia. They are seen in approximately two-thirds of patients with this disorder. Plane xanthomas are also seen in the setting of cholestasis, e.g. biliary atresia or primary biliary cholangitis (previously primary biliary cirrhosis).

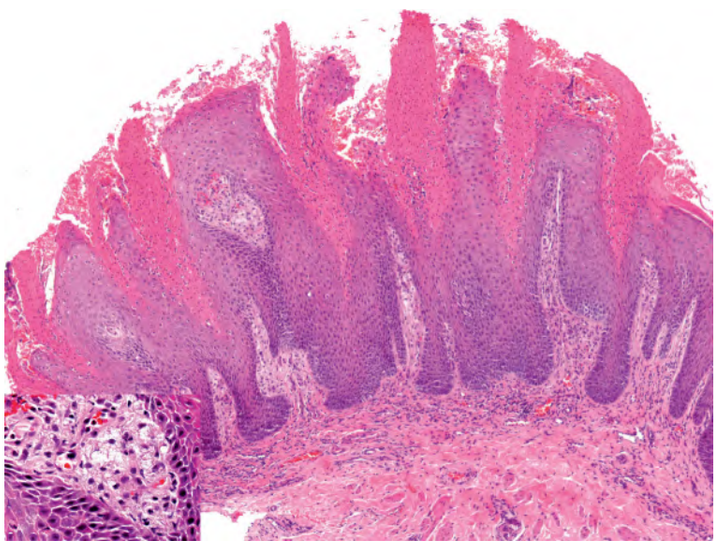

eFig. 92.8 Verruciform xanthoma. Marked parakeratosis, papillomatosis, and acanthosis. The collection of foam cells immediately below the epithelium is subtle (inset). *Courtesy Luis Requena, MD.*

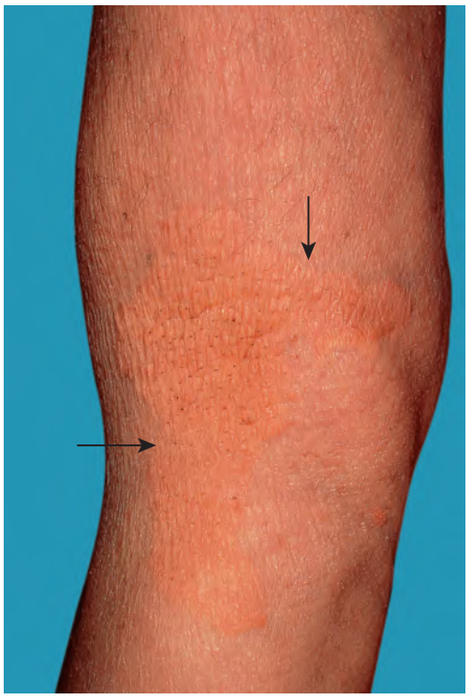

eFig. 92.7 Normolipemic plane xanthoma in a patient with a monoclonal IgG gammopathy. These lesions can be subtle clinically; arrows point to the edge of the xanthoma.

eFig. 92.9 Eruptive xanthomas in the setting of hypertriglyceridemia and uncontrolled diabetes mellitus. *Courtesy Catherine Baker, MD.*

LABORATORY EVALUATION OF SUSPECTED HYPERLIPIDEMIA
• Fasting lipid panel*
• Fasting serum glucose or hemoglobin A1C
• Liver function tests†
• Thyroid-stimulating hormone (TSH) level
• Serum albumin
*If elevated serum lipids, evaluate for systemic disease.
†If elevated serum alkaline phosphatase and bilirubin, evaluate for biliary disease.

eTable 92.1 Laboratory evaluation of suspected hyperlipidemia.

Downloaded for Anonymous User (n/a) at Egyptian Knowledge Bank from ClinicalKey.com by Elsevier on March 10, 2024. For personal use only. No other uses without permission. Copyright ©2024. Elsevier Inc. All rights reserved.